

This is a provisional PDF only. Copyedited and fully formatted version will be made available soon.



P O L I S H G Y N E C O L O G Y

GINEKOLOGIA

POLSKA

ORGAN POLSKIEGO TOWARZYSTWA GINEKOLOGICZNEGO
THE OFFICIAL JOURNAL OF THE POLISH GYNECOLOGICAL SOCIETY

ISSN: 0017-0011

e-ISSN: 2543-6767

Successful treatment of interstitial ectopic pregnancy using methotrexate

Authors: Ibrahim A. Abdelazim, Svetlana Shikanova, Mohamed H. Farag, Bakyt Karimova

DOI: 10.5603/GP.a2023.0034

Article type: Clinical vignette

Submitted: 2022-12-20

Accepted: 2023-03-03

Published online: 2023-04-24

This article has been peer reviewed and published immediately upon acceptance. It is an open access article, which means that it can be downloaded, printed, and distributed freely, provided the work is properly cited.

Articles in "Ginekologia Polska" are listed in PubMed.

Successful treatment of interstitial ectopic pregnancy using methotrexate

Ibrahim A. Abdelazim¹, Svetlana Shikanova², Mohamed H. Farag³, Bakyt Karimova²

¹*Department of Obstetrics and Gynecology, Faculty of Medicine, Ain Shams University, Cairo, Egypt*

²*Department of Obstetrics and Gynecology No1, Marat Ospanov, West Kazakhstan State Medical University, Aktobe, Kazakhstan*

³*Department of Obstetrics and Gynecology, Jaber Al-Ahmed Hospital, Ministry of Health (MOH), Kuwait*

Corresponding author:

Ibrahim A. Abdelazim

Department of Obstetrics and Gynecology, Faculty of Medicine, Ain Shams University, Cairo, Egypt

e-mail: dr.ibrahimanwar@gmail.com

INTRODUCTION

The oocyte fertilization occurs in the Fallopian tube (FT). The migration of fertilized oocytes into the uterus is facilitated by FT cilia and muscles. FT dysfunction and/or inflammation is implicated in oocytes retention and subsequent ectopic pregnancy (EP) [1]. The incidence of EP is 1.3–2.4%, and ruptured EP is a direct cause of maternal death in the first trimester of pregnancy [2].

The rising EP incidence can be explained by the increased, assisted reproduction techniques rate, tubal surgeries, and improved diagnostic techniques [2].

Prior tubal surgery, sterilization, prior EP, and intrauterine contraceptive device were considered high-risk factors for the EP. While infertility, prior pelvic inflammatory disease, smoking, and multiple partners were considered moderate risk factors for the EP [3].

This clinical vignette represents an interstitial ectopic pregnancy (IEP) successfully treated using methotrexate (MTX).

CLINICAL VIGNETTE

A 32-years-old woman, P3, previous 3 cesarean sections, presented to the emergency room, with vaginal spotting after positive pregnancy test at 6 weeks' gestation. She was diagnosed as IEP because the departmental ultrasound at initial β -human chorionic gonadotropin (β -hCG) 1540 mIU/mL, showed an empty uterus, with an eccentric gestational sac (GS) without fetal echo or fetal pulsation. The eccentric GS is more than 1 cm away from the lateral endometrial edge and surrounded by less than 5 mm myometrium, with positive interstitial line sign (ILS) (Fig. 1).

The studied woman counselled for medical treatment using MTX, because the IEP was intact, with no fetal echo or fetal pulsation, and desired future fertility. She was also counselled regarding the MTX-side effects, failure rate, serial β -hCG assay and follow up.

After written consent, she received 50 mg MTX (50 mg/BSA) at initial β -hCG 1540 mIU/mL. The 4th day β -hCG after the MTX slightly increased to 1660 mIU/mL, while the 7th day β -hCG was 1230 mIU/mL (> 15% drop of β -hCG [25.9%]). The 2nd week β -hCG was 480 mIU/mL, while, the 3rd week β -hCG was 143 mIU/mL, and the 4th week β -hCG was 53 mIU/mL (the GS completely disappeared by the follow-up ultrasound scan). The β -hCG returned to normal non-pregnant level on the 5th week after the MTX (5.1 mIU/mL [normal β -hCG 0.0–10 mIU/mL]).

A departmental approval and written consent were obtained to publish the studied women data as a clinical vignette.

DISCUSSION

The IEP occurs following fertilized ovum implantation in the interstitial portion of the FT when it traverses the uterine muscles to enter the uterine cavity [2].

The ultrasound diagnostic criteria of the IEP include an empty uterus with an eccentric GS. The eccentric GS is more than 1 cm away from the lateral endometrial edge and surrounded by less than 5 mm myometrium. The ILS is an echogenic line extending from the eccentric GS to the endometrial line and represents the interstitial portion of the FT (ILS has 80% sensitivity in diagnosing IEP) [3–5].

The treatment options for IEP depends on the gestational age at diagnosis, desired future fertility, and whether the IEP is intact or ruptured [2].

The non-surgical (medical) treatment options can be used for intact IEP [2]. The success rate of systemic MTX in the treatment of IEPs was 80%, even with high β -hCG levels and presence of fetal cardiac activity [2].

Local MTX injection can be used for treatment of IEPs, while local potassium chloride (20%) injection is preferred in IEPs with concomitant viable intrauterine pregnancy. Follow-up using serial β -hCG assay and ultrasound is needed after the medical treatment for IEPs [2].

Decreased β -hCG by $\geq 15\%$ on day 7 indicates successful MTX treatment, and the β -hCG should be monitored weekly till it reaches the non-pregnant level [2]. Another MTX-dose or surgical options should be considered, if the β -hCG does not decrease adequately ($< 15\%$ on day 7) after MTX or increased [2].

The medical treatment using MTX for the studied IEP-case, was successful because the 4th day β -hCG decreased by $> 15\%$ (25.9%) on the 7th day after the MTX (from 1660 to 1230 mIU/mL; respectively) and returned to normal non-pregnant level (5.1 mIU/mL) on the 5th week after the MTX.

Conclusion: The MTX is an effective treatment option for selected cases of intact IEPs, with desired future fertility after proper counselling.

Declaration of consent

A departmental approval and written consent were obtained to publish the studied women data as a clinical vignette.

Acknowledgment

Authors are grateful to the studied women who gave consent to publish her data as a clinical vignette.

Funding

None.

Conflict of interest

Authors declare no conflict of interest.

REFERENCES

1. Abdelazim IA, Shikanova S, Zhurabekova G, et al. Open cornual resection versus laparoscopic cornual resection in patients with interstitial ectopic pregnancies. *Eur J Obstet Gynecol Reprod Biol.* 2019; 232: 107–108, doi: [10.1016/j.ejogrb.2018.11.010](https://doi.org/10.1016/j.ejogrb.2018.11.010), indexed in Pubmed: [30466732](https://pubmed.ncbi.nlm.nih.gov/30466732/).
2. Abdelazim I, AbuFaza M, Shikanova S, et al. Diagnostic Criteria and Treatment Modalities of Ectopic Pregnancies: A Literature Review. *EMJ Repro Health.* 2021; 7(1): 83–94, doi: [DOI/10.33590/emjreprohealth/20-00118](https://doi.org/10.33590/emjreprohealth/20-00118).
3. Obaid M, Abdelazim IA, Abu-Faza M, et al. Treatment of left tubal pregnancy with foetal cardiac activity using a two-dose methotrexate regimen. *Prz Menopauzalny.* 2022; 21(2): 138–141, doi: [10.5114/pm.2022.116433](https://doi.org/10.5114/pm.2022.116433), indexed in Pubmed: [36199740](https://pubmed.ncbi.nlm.nih.gov/36199740/).
4. Abdelazim IA, Shikanova S, Mukhambetalyeva G. Regarding "Spontaneous Cornual Pregnancy after Homolateral Salpingectomy for an Earlier Tubal Pregnancy: A Case Report and Literature Review". *J Minim Invasive Gynecol.* 2019; 26(3): 574–575, doi: [10.1016/j.jmig.2018.11.018](https://doi.org/10.1016/j.jmig.2018.11.018), indexed in Pubmed: [30553036](https://pubmed.ncbi.nlm.nih.gov/30553036/).
5. Abdelazim IA, Kanshaiym S, Zhurabekova G. Regarding "Technique for the Laparoscopic Management of a Cornual Ectopic Pregnancy". *J Minim Invasive Gynecol.* 2019; 26(4): 777–778, doi: [10.1016/j.jmig.2018.12.011](https://doi.org/10.1016/j.jmig.2018.12.011), indexed in Pubmed: [30590130](https://pubmed.ncbi.nlm.nih.gov/30590130/).

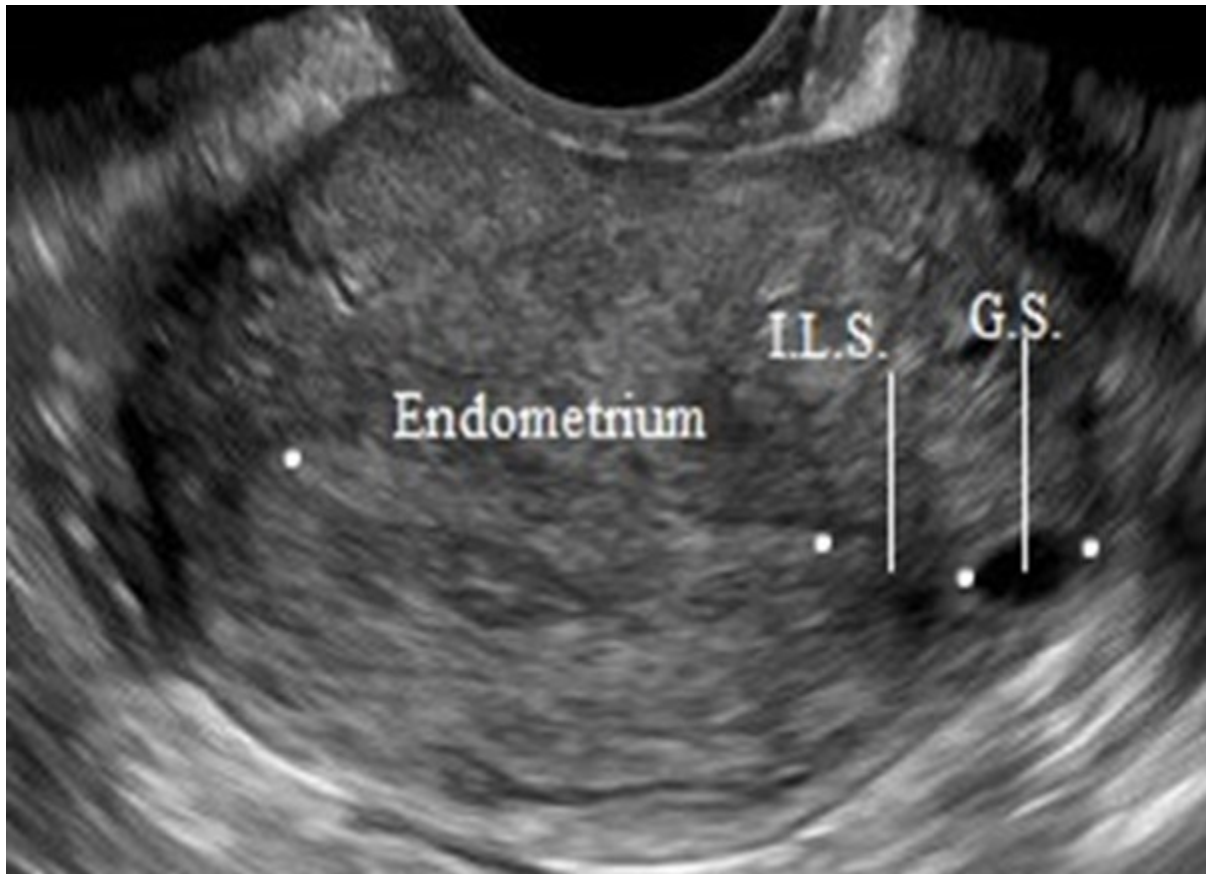


Figure 1: An ultrasound image shows an eccentric gestational sac (GS) > 1 cm away from the lateral endometrial edge and the interstitial line sign (ILS.) as an echogenic line extending from the eccentric GS to the endometrial line