

2020

Intermediate oncologic outcomes after uniportal video-assisted thoracoscopic thymectomy for early-stage thymoma

S. S. Pupovac
Northwell Health

J. Newman
Northwell Health

P. C. Lee
Zucker School of Medicine at Hofstra/Northwell

M. Alexis
Northwell Health

J. Jurado
Zucker School of Medicine at Hofstra/Northwell

See next page for additional authors

Follow this and additional works at: <https://academicworks.medicine.hofstra.edu/publications>

 Part of the [Cardiology Commons](#)

Recommended Citation

Pupovac SS, Newman J, Lee PC, Alexis M, Jurado J, Hyman K, Glassman L, Zeltsman D. Intermediate oncologic outcomes after uniportal video-assisted thoracoscopic thymectomy for early-stage thymoma. . 2020 Jan 01; 12(8):Article 7018 [p.]. Available from: <https://academicworks.medicine.hofstra.edu/publications/7018>. Free full text article.

This Article is brought to you for free and open access by Donald and Barbara Zucker School of Medicine Academic Works. It has been accepted for inclusion in Journal Articles by an authorized administrator of Donald and Barbara Zucker School of Medicine Academic Works. For more information, please contact academicworks@hofstra.edu.

Authors

S. S. Pupovac, J. Newman, P. C. Lee, M. Alexis, J. Jurado, K. Hyman, L. Glassman, and D. Zeltsman



Intermediate oncologic outcomes after uniportal video-assisted thoracoscopic thymectomy for early-stage thymoma

Stevan S. Pupovac, Joshua Newman, Paul C. Lee, Miguel Alexis, Julissa Jurado, Kevin Hyman, Lawrence Glassman, David Zeltsman

Department of Cardiovascular and Thoracic Surgery, Hofstra Northwell School of Medicine, Manhasset, NY, USA

Contributions: (I) Conception and design: SS Pupovac, D Zeltsman; (II) Administrative support: D Zeltsman; (III) Provision of study materials or patients: D Zeltsman; (IV) Collection and assembly of data: SS Pupovac; (V) Data analysis and interpretation: SS Pupovac, D Zeltsman; (VI) Manuscript writing: All authors; (VII) Final approval of manuscript: All authors.

Correspondence to: David Zeltsman, MD. Department of Cardiovascular and Thoracic Surgery, Long Island Jewish Medical Center, 270-05 76th Ave., Queens, NY 11040, USA. Email: DZeltsman@northwell.edu.

Background: Recent years have seen a trend towards utilizing a video-assisted thoracic surgery (VATS) approach for treatment of thymoma. Although increasing in practice, intermediate- and long-term oncologic outcome data is lacking for the VATS approach. There is no oncologic data for the uniportal VATS approach. We sought to evaluate the feasibility and impact on patient survival of uniportal VATS thymectomy for early-stage thymoma.

Method: The clinical outcomes for 17 patients with Masaoka stage I to II thymomas treated between January of 2009 and July of 2014 at a single institution were collected retrospectively. Primary endpoint was overall survival (OS) and secondary endpoint was recurrence-free survival (RFS).

Results: Ten women and seven men underwent uniportal VATS thymectomy; eleven had stage I thymoma and six had stage II thymoma. There were no conversions to open surgery. Operative mortality was zero. Mean tumor size was 3.8 ± 1.0 centimeters, with a range of 1.9 to 6.0 centimeters. All patients underwent a R0 resection. Five-year survival was 100%, and the estimated RFS was 100%.

Conclusions: Our findings suggest that uniportal VATS thymectomy for early-stage thymoma is feasible, and the intermediate-term oncologic outcomes are comparable to historic standards for open and multi-incision VATS thymectomy. However, additional follow-up is required to evaluate for long-term oncologic outcomes.

Keywords: Thymectomy; thymoma; uniportal; video-assisted thoracic surgery (VATS); cancer

Submitted Mar 18, 2020. Accepted for publication Jul 07, 2020.

doi: 10.21037/jtd-20-1370

View this article at: <http://dx.doi.org/10.21037/jtd-20-1370>

Introduction

Thymoma is a slow-growing tumor originating from the epithelial cells of the thymus and remains the most common anterior mediastinal neoplasm found in adults (1). Given the rarity and indolent nature of this neoplasm, significant controversy remains regarding the appropriate surgical approach towards treatment of early stage thymoma (stage I or II) (2-6).

Microscopically margin-negative resection has been well-

established as the most important prognostic indicator of overall- and recurrence-free survival (RFS) (4-10). Complete surgical resection of early-stage thymoma has historically resulted in excellent oncologic outcomes, with upwards of 100% reported 5-year survival (2-8). While classically performed through a median sternotomy, video-assisted thoracic surgery (VATS) has been reported to achieve equivalent oncologic outcomes (4-6,10-13). However, given the indolent nature of this tumor, intermediate- and long-term data is still lacking with regards to the VATS approach.




Figure 1 Two examples of the standard sub-three-centimeter incision utilized for our institution's uniportal VATS thymectomy. VATS, video-assisted thoracic surgery.

Single-incision, or uniportal, VATS thymectomy has been reported (14-17), however, to date, no data exists regarding intermediate-term oncologic outcomes. Consequently, we retrospectively evaluated the overall survival (OS) and RFS in all patients undergoing single-incision VATS thymectomy for early-stage thymoma at our institution. We present the following article in accordance with the STROBE reporting checklist, available at <http://dx.doi.org/10.21037/jtd-20-1370>.

Methods

Study population and definitions

Between January 2009 and July 2014, a comprehensive retrospective review of a prospectively collected thoracic surgery database identified all patients who underwent single-incision VATS thymectomy for early stage thymoma. The study was conducted in accordance with the Declaration of Helsinki (as revised in 2013). This study was conducted with the approval of the Northwell Health Institutional Review Board (October 6, 2017. IRB approval #17-0659), consent was waived.

Clinical staging was based on computed tomography (CT) and/or magnetic resonance imaging (MRI) findings. No patients underwent preoperative biopsies. Final pathological diagnosis was based on histology. Pathological staging was based on the Masaoka staging system (18). Histologic subtype was based on the World Health Organization (WHO) classification system (8,9).

Exclusion criteria included all patients without stage I or

II thymoma (e.g., late-stage thymoma (III and IV), thymic hyperplasia, thymic carcinoma etc.). Size, in and of itself, was not an exclusion criterion.

Surgical approach

All patients were operated upon by a single surgeon, at a single institution. The preoperative plan was to perform a unilateral single-incision (<3 cm incision; *Figure 1*) VATS thymectomy, with conversion to open surgery when clinically indicated. All specimens were removed via an endoscopic retrieval bag (which helps to facilitate the removal of large tumors once). Examples of a 5.2 and 9 cm thymoma (*Figure 2*).

We remove all suspicious lymph nodes based on preoperative imaging. Further, we perform *en bloc* resection of the thymus, perithymic, prevascular, and supradiaphragmatic lymph nodes. In addition, right para-tracheal and para-aortic lymph nodes are dissected when operating for advanced thymomas and/or thymic carcinomas.

Surgical technique and instruments

All patients are placed in left lateral decubitus position and secured to the bed, such that they can be placed at a forty-five-degree angle with regards to the floor (our preference is to utilize a bean-bag positioner with silk tape placed across the hip). A single sub-three-centimeter incision is created in the fifth intercostal space between

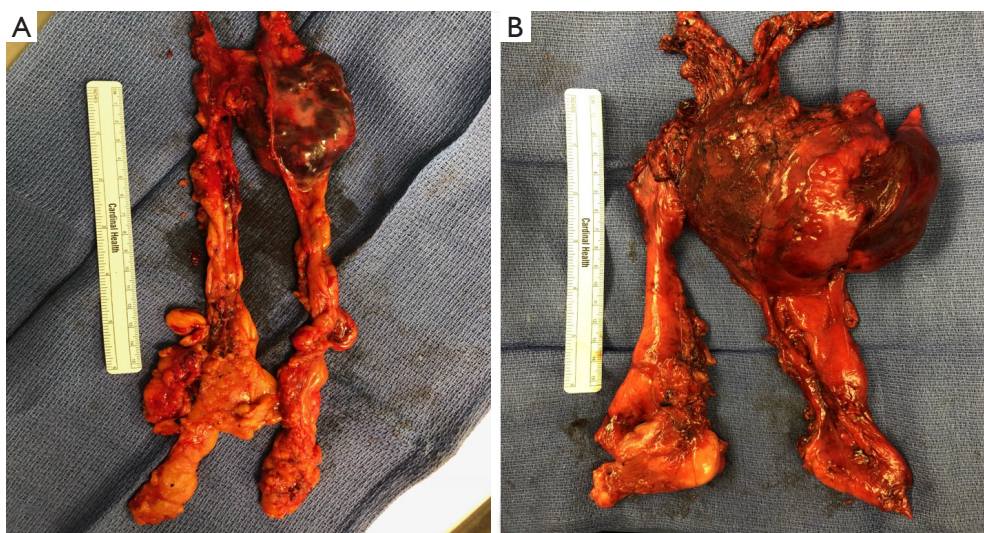


Figure 2 Two separate images of resected thymomas via uniportal VATS thymectomy. (A) 5.2 cm thymoma; (B) 9 cm thymoma. VATS, video-assisted thoracic surgery.

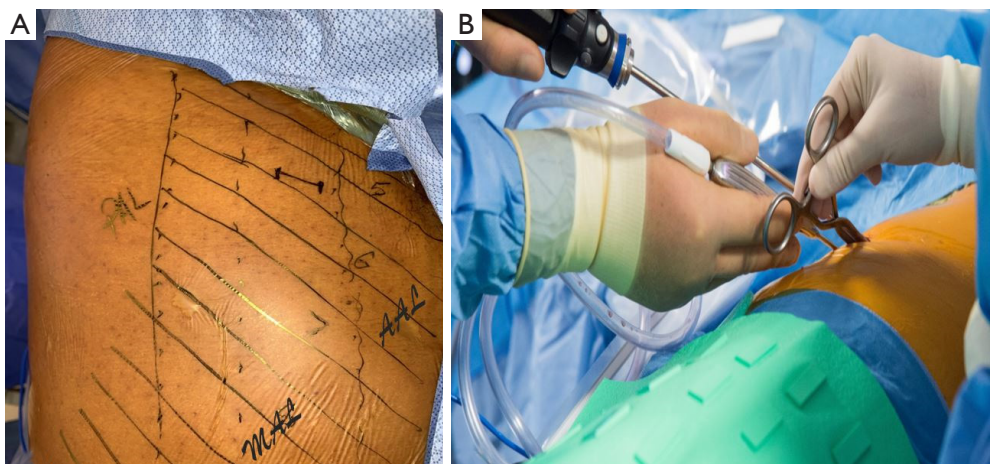


Figure 3 Example of our standard sub-three-centimeter incision (A) created in the fifth intercostal space between the mid- and anterior axillary lines (ribs are numbered) and (B) affords enough space for simultaneous use of multiple instruments. PAL, posterior axillary line; MAL, mid-axillary line; AAL, anterior axillary line.

the mid- and anterior-axillary lines (*Figure 3A*). This incision affords enough space for simultaneous use of multiple instruments (*Figure 3B*). For larger specimens, the muscular portion of the incision may be extended, however the extent of the skin incision does not need to be enlarged. The operating surgeon positions himself posterior to the patient, whereas the first assistant is subsequently anterior to the patient.

A 5 mm thirty-degree angled thoracoscope provides optimal visualization from phrenic nerve to phrenic

nerve. Dissection is carried out utilizing standard VATS instruments (curved and straight ringed forceps, curved lymph node grasper, curved blunt-tip metal suction, harmonic scalpel and endo Kittner). No SILS port or wound-protectors were utilized.

All patients receive multi-level intercostal nerve block, as well as multi-modality post-operative pain control with non-steroidal anti-inflammatory (patient's creatinine clearance and bleeding are taking under consideration) and narcotic-based, patient-controlled analgesia pump.

Follow up

All patients had short-term follow up, usually within two weeks of discharge from the hospital and then twice per year for the first year. Given the nature of the disease, all patients were encouraged to maintain yearly follow up visits indefinitely (with requisite chest CT imaging prior to follow up visits). If a patient were lost to follow up, the electronic medical records were queried for proof of life. No judgement was made regarding recurrence without chest imaging and a follow-up visit with the thoracic surgeon of record.

Data analysis

Our primary endpoint was OS and secondary endpoint was RFS. Definitions of patient demographic characteristics, perioperative variables, and postoperative outcomes were obtained from the Society of Thoracic Surgeons Adult Thoracic Surgery Database, version 2.81 (<http://www.sts.org/registries-research-center/sts-national-database/adult-thoracic-surgery-database/data-collection>).

Study data were collected and managed using REDCap electronic data capture tools hosted at Long Island Jewish Medical Center (19). REDCap (Research Electronic Data Capture) is a secure, web-based application designed to support data capture for research studies, providing: (I) an intuitive interface for validated data entry; (II) audit trails for tracking data manipulation and export procedures; (III) automated export procedures for seamless data downloads to common statistical packages; and (IV) procedures for importing data from external sources.

The OS and RFS curves were calculated using the Kaplan-Meier method.

Results

Patient demographics and operative data

Over the time period of the study, 21 patients underwent elective, first-time, single-incisions VATS thymectomy. Four patients did not meet inclusion criteria: three due to advanced-stage disease (three stage III) and one secondary to a pathologic diagnosis of thymic hyperplasia. Ultimately, seventeen patients underwent resection for early-stage thymoma. There were no documented islands or foci of thymic carcinoma on final pathology. There were ten females and seven males. The average age was 64.2 ± 14.7 and only one patient had diagnosed myasthenia gravis.

Patient demographics are summarized in *Table 1*.

Major intraoperative and perioperative data are reported in *Table 2*. Eleven of the seventeen patients were classified as stage I and six as stage IIA, according to the Masaoka classification system. The mean surgical duration was 126.9 ± 54.4 minutes. There were no conversions to open surgery. All patients underwent a R0 resection. There were no recorded phrenic nerve injuries in the entire cohort.

Clinical outcomes

For the entire cohort, 30-day mortality was 0.0% and was without major perioperative surgical complications. The median length of stay for the entire cohort was 1.0 days (range of 1.0–2.0 days), with a median follow-up of 65 months. Overall 5-year survival was 100% (*Figure 4*), with Kaplan-Meier estimated 5-year RFS of 100% (*Figure 5*).

Short- and intermediate-term outcomes are summarized in *Table 3*.

Discussion

Recent years have seen a trend towards utilizing a VATS approach for treatment of thymoma (20), owing to the well-documented advantages in perioperative outcomes of VATS (6,11-13). While short-term outcomes have shown the VATS approach to be effective (13,21), intermediate- and long-term oncologic data is lacking in larger studies. More recently, large multi-institutional studies from the Japanese Association for Research on the Thymus (JART) (22), the Chinese Alliance for Research in Thymomas (ChART) (23) and the International Thymic Malignancies Group (ITMIG) (24) have sought to address the previously underpowered and short-term follow-up studies.

As it stands, the National Comprehensive Cancer Network does not recommend VATS to be the standard approach for routine resection of thymoma, however, with regards to early-stage (I or II) disease, their stance states “minimally invasive procedures may be considered for clinical stage I–II if all oncologic goals can be met as in standard procedures, and if performed by specialized centers by surgeons with experience in these techniques (25).”

Several reports have shown single-incision VATS thymectomy to be feasible (14-17), however, despite the interest in single-incision thoracic surgery (14-17,26-28), to date, no data exists regarding intermediate-term oncologic outcomes. While technically feasible, critics will argue that given the indolent nature of thymomas, definitive

Table 1 Patient demographics

Variable	Entire cohort (n=17)
Age, years	64.2±14.7
Female gender	10 (58.8)
Hypertension	5 (29.4)
Dyslipidemia	8 (47.1)
Cerebrovascular disease	0 (0.0)
Peripheral vascular disease	0 (0.0)
Diabetes mellitus	2 (11.8)
Chronic obstructive pulmonary disease	0 (0.0)
Current or prior smoking history	12 (70.6)
Dialysis-dependent renal failure	0 (0.0)
Myasthenia gravis	1 (5.9)

Values expressed are n (%) or mean ± standard deviation.

statements should be withheld for up to ten years (1-7). However, as proponents of VATS have long-stated, since the most statistically significant predictor of OS and RFS remains extent of resection (2-6), as long as one adheres to the tenets of oncologic standards, how the neoplasm is removed should be of little consequence. Our data suggests this to be true, as we achieved a R0 resection for the entire cohort, and our 100% 5-year OS compares favorably to the historic standards of Kondo *et al.* (n=769; 5-year OS: stage I, 100%; stage II, 95%) (29), Murakawa *et al.* (n=96; 5-year OS: stage I, 91%; stage II, 97%) (30), McCart *et al.* (n=21; 5-year OS: stage I, 98%) (31) and Nakahara *et al.* (n=78; 5-year OS: stage I, 100%; stage II, 92%) (32). Although the aforementioned studies did not report their 5-year RFS, our 100% estimated RFS would compare favorably if they had.

Not surprisingly, our data also compares favorably with VATS studies which have reported 5-year OS: Sakamaki *et al.* (n=71; 5-year OS: stage I, 94.1%; stage II, 94.7%) (12), Pennathur *et al.* (n=18; estimated 5-year OS: stage I + II 100%) (33) and Chung *et al.* (n=24; 5-year OS: stage I+II, 100%) (34). Likewise, our 100% estimated 5-year RFS compares favorably with that of Sakamaki *et al.* (n=71; 5-year RFS: stage I, 94.1%; stage II, 85.4%) (12), Pennathur *et al.* (n=18; estimated 5-year RFS: stage I+II 100%) (33) and Chung *et al.* (n=24; 5-year RFS: stage I+II, 96%) (34).

As shown, single-incision VATS thymectomy for the treatment of early-stage thymoma has favorable intermediate-term oncologic outcomes as compared to the historic standards of median sternotomy and more recent

Table 2 Operative and perioperative data

Variable	Entire cohort (n=17)
Masaoka tumor stage	
Stage I	11 (64.7)
Stage IIA	6 (35.3)
Stage IIB	0 (0.0)
WHO classification	
A	0 (0.0)
AB	9 (52.9)
B1	1 (5.9)
B2	5 (29.4)
B3	2 (11.8)
TNM tumor stage	
Stage I	17 (100.0)
Stage II	0 (0.0)
Stage III (A or B)	0 (0.0)
Stage IV (A or B)	0 (0.0)
Conversions to open surgery	0 (0.0)
Duration of operation, minutes	126.9±54.4
Residual tumor classification	
R0	17 (100.0)
Tumor size	
Mean ± standard deviation, cm	3.8±1.0
Range, cm	1.9–9.0

Values expressed are n (%) or mean ± standard deviation.

multi-port VATS studies. This data lends support to the feasibility of the single-incision VATS approach for the treatment of early-stage thymoma.

While feasible, there remains no consensus regarding strict contraindications for VATS. Kimura *et al.* reported that tumors >5 cm substantially increased the risk of capsular rupture and potential seeding of the tumor (35). Alternatively, from their insights from the National Cancer Database, Burt and colleagues did not find a correlation between size and completeness of resection (20). Our data suggest that tumor size is not a prognostic factor with regards to extent of resection, with our entire cohort undergoing a R0 resection. However, while no patients were excluded from undergoing resection based on size, the high end of our range was still 9.0cm. It is our institution's belief that the

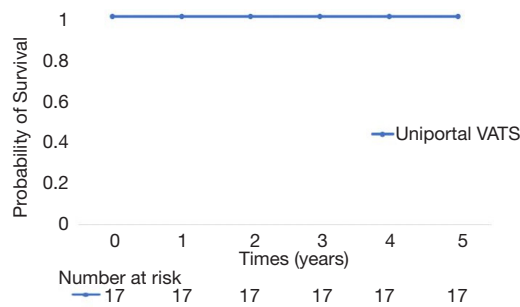


Figure 4 Kaplan-Meier plot illustrating estimated 5-year overall survival for patients undergoing uniportal VATS thymectomy. Time from thymectomy (years) plotted on the x-axis. VATS, video-assisted thoracic surgery.

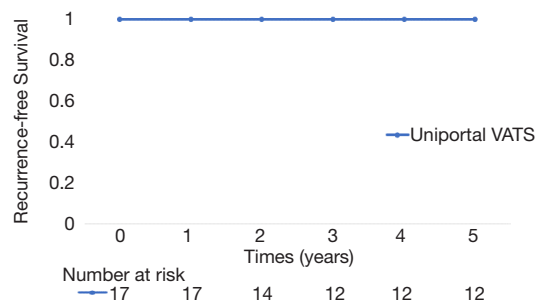


Figure 5 Kaplan-Meier plot illustrating estimated 5-year recurrence-free survival for patients undergoing uniportal VATS thymectomy. Time from thymectomy (years) plotted on the x-axis. VATS, video-assisted thoracic surgery.

ability to perform a sound oncologic procedure, not size, should be the determining factor in choosing a surgical approach.

Limitations

Our study has several limitations to be acknowledged. Despite the fact that our data is comprehensive, our sample size remains relatively small, and our analysis is retrospective and largely observational in nature. Our patient population was highly selected, consisting of those individuals who presented with imaging consistent with non-invasive disease; consequently, our results are not generalizable to patients presenting with clinically more advanced disease, such as stage III or IV thymoma. Given the rarity of this neoplasm, large multi-institutional studies are required, several of which are currently underway. Our length of follow-up can still be considered short, as recurrence has been seen upwards of ten years following initial resection.¹⁻⁷

Conclusions

In conclusion, our findings suggest that single-incision VATS thymectomy for early-stage thymoma is feasible, and the intermediate-term oncologic outcomes are comparable to historic standards for open and multi-incision VATS thymectomy. However, additional follow-up is required to evaluate for long-term oncologic outcomes.

Table 3 Short-term and intermediate-term outcomes

Variable	Entire cohort (n=17)
30-day mortality	0 (0.0)
Stroke	0 (0.0)
Reoperation for bleeding	0 (0.0)
Sepsis of any cause	0 (0.0)
New renal failure requiring dialysis	0 (0.0)
Postoperative length of hospital stay, days, median (IQR)	1 (1 to 2)
Phrenic nerve injury	0 (0.0)
Diaphragmatic palsy	0 (0.0)
Follow up, mo, median (IQR)	65 (27 to 67)
5-year overall survival	17 (100.0)
KM estimated 5-year recurrence-free survival	17 (100.0)

Values expressed are n (%) or mean ± standard deviation, unless otherwise specified. mo, months; KM, Kaplan Meier.

Acknowledgments

Poster presented at the 57th Annual Meeting Eastern Cardiothoracic Surgical Society. Naples Fl. October 2019.

Funding: None.

Footnote

Reporting Checklist: The authors have completed the STROBE reporting checklist. Available at <http://dx.doi.org/10.21037/jtd-20-1370>

Data Sharing Statement: Available at <http://dx.doi.org/10.21037/jtd-20-1370>

Peer Review File: Available at <http://dx.doi.org/10.21037/jtd-20-1370>

Conflicts of Interest: All authors have completed the ICMJE uniform disclosure form (available at <http://dx.doi.org/10.21037/jtd-20-1370>). The authors have no conflicts of interest to declare.

Ethical Statement: The authors are accountable for all aspects of the work in ensuring that questions related to the accuracy or integrity of any part of the work are appropriately investigated and resolved. The study was conducted in accordance with the Declaration of Helsinki (as revised in 2013). This study was conducted with the approval of the Northwell Health Institutional Review Board (October 6, 2017. IRB approval #17-0659), consent was waived. There were no human or animal experiments included in this study.

Open Access Statement: This is an Open Access article distributed in accordance with the Creative Commons Attribution-NonCommercial-NoDerivs 4.0 International License (CC BY-NC-ND 4.0), which permits the non-commercial replication and distribution of the article with the strict proviso that no changes or edits are made and the original work is properly cited (including links to both the formal publication through the relevant DOI and the license). See: <https://creativecommons.org/licenses/by-nc-nd/4.0/>.

References

1. Travis WD, Brambilla E, Mueller-Hermelink HK, et al. WHO classification of tumors. pathology and genetics of tumors of the lung, pleura, thymus and heart. Lyon, France: IARC Press, 2004.
2. Nakagawa K, Yokoi K, Nakajima J, et al. Is Thymectomy Alone Appropriate for Stage I (T1N0M0) Thymoma? Results of a Propensity-Score Analysis. *Ann Thorac Surg* 2016;101:520-6.
3. Ruffini E, Venuta F. Management of thymic tumors: a European perspective. *J Thorac Dis* 2014;6:S228-37.
4. Falkson CB, Bezjak A, Darling G. et al. The management of thymoma: a systematic review and practice guideline. *J Thorac Oncol* 2009;4:911-9.
5. Tomaszek S, Wigle DA, Keshavjee S, et al. Thymomas: review of current clinical practice. *Ann Thorac Surg* 2009;87:1973-80.
6. Girard N, Mornex F, Van Houtte P, et al. Thymoma: a focus on current therapeutic management. *J Thorac Oncol* 2009;4:119-26.
7. Regnard JF, Magdeleinat P, Dromer C, et al. Prognostic factors and long-term results after thymoma resection: a series of 307 patients. *J Thorac Cardiovasc Surg*. 1996;112:376-84.
8. Wright CD, Wain JC, Wong DR, et al. Predictors of recurrence in thymic tumors: importance of invasion, World Health Organization histology, and size. *J Thorac Cardiovasc Surg* 2005;130:1413-21.
9. Okumura M, Ohta M, Tateyama H, et al. The World Health Organization histologic classification system reflects the oncologic behavior of thymoma: a clinical study of 273 patients. *Cancer* 2002;94:624-32.
10. Nakagawa K, Asamura H, Matsuno Y, et al. Thymoma: a clinicopathological study based on the new World Health Organization classification. *J Thorac Cardiovasc Surg* 2003;126:1134-40.
11. Odaka M, Akiba T, Yabe M, et al. Unilateral thoracoscopic subtotal thymectomy for the treatment of stage I and II thymoma. *Eur J Cardiothorac Surg* 2010;37:824-6.
12. Sakamaki Y, Oda T, Kanazawa G, et al. Intermediate-term oncologic outcomes after video-assisted thoracoscopic thymectomy for early-stage thymoma. *J Thorac Cardiovasc Surg* 2014;148:1230-7.e1.
13. Jurado J, Javidfar J, Newmark A, et al. Minimally invasive thymectomy and open thymectomy: outcome analysis of 263 patients. *Ann Thorac Surg* 2012;94:974-81.
14. Scarci M, Pardolesi A, Solli P. Uniportal video-assisted thoracic surgery thymectomy. *Ann Cardiothorac Surg* 2015;4:567-70.
15. Wu CY, Heish MJ, Wu CF. Single port VATS mediastinal tumour resection: Taiwan experience. *Ann Cardiothorac*

- Surg 2016;5:107-11.
16. Wu L, Lin L, Liu M, et al. Subxiphoid uniportal thoroscopic extended thymectomy. *J Thorac Dis* 2015;7:1658-60.
 17. Gonzalez-Rivas D, Wu CF, de la Torre M. Uniportal video-assisted thoroscopic thymectomy and resection of a giant thymoma in a patient witness of Jehova. *J Thorac Dis* 2017;9:E556-9
 18. Masaoka A, Monden Y, Nakahara K, et al. Follow-up study of thymomas with special reference to their clinical stages. *Cancer* 1981;48:2485-92.
 19. Harris PA, Taylor R, Thielke R, et al. Research electronic data capture (REDCap) - a metadata-driven methodology and workflow process for providing translational research informatics support. *J Biomed Inform* 2009;42:377-81.
 20. Burt BM, Nguyen D, Groth SS, et al. Utilization of Minimally Invasive Thymectomy and Margin-Negative Resection for Early-Stage Thymoma. *Ann Thorac Surg* 2019;108:405-11.
 21. Cheng YJ, Kao EL, Chou SH. Videothoroscopic resection of stage II thymoma: prospective comparison of the results between thoracoscopy and open methods. *Chest* 2005;128:3010-2.
 22. Agatsuma H, Yoshida K, Yoshino I. Video-assisted thoracic surgery versus sternotomy thymectomy in patients with thymoma. *Ann Thorac Surg* 2017;104:1047-53.
 23. Gu Z, Chen C, Wang Y. Video-assisted thoroscopic surgery versus open surgery for stage I thymic epithelial tumours: a propensity score-matched study. *Eur J Cardiothorac Surg* 2018;54:1037-44.
 24. Fang W, Xiao X, Antonicelli A. Comparison of surgical approach and extent of resection for Masaoka-Koga Stage I and II thymic tumours in Europe, North America and Asia: an international thymic malignancy interest group retrospective database analysis. *Eur J Cardiothorac Surg* 2017;52:26-32.
 25. National Comprehensive Cancer Network. 2017 Thymoma and thymic carcinomas. Accessed Sept. 11 2019. Available at https://www.nccn.org/professionals/physician_gls/pdf/thymic.pdf
 26. Gonzalez-Rivas D, Damico TA, Jiang G, et al. Uniportal video-assisted thoracic surgery: a call for better evidence, not just more evidence. *Eur J Cardiothorac Surg* 2016;50:416-7.
 27. Gonzalez-Rivas D, Fieira E, Mendez L, et al. Single-port video-assisted thoroscopic anatomic segmentectomy and right upper lobectomy. *Eur J Cardiothorac Surg* 2012;42:e169-71.
 28. Migliore M. Uniportal video-assisted thoracic surgery, and the uni-surgeon: new words for the contemporary world. *J Vis Surg* 2018;4:45.
 29. Kondo K, Monden Y. Therapy for thymic epithelial tumors: a clinical study of 1,320 patients from Japan. *Ann Thorac Surg* 2003;76:878-84.
 30. Murakawa T, Nakajima J, Kohno T, et al. Results from surgical treatment for thymoma: 43 years of experience. *Jpn J Thorac Cardiovasc Surg* 2000;48:89-95.
 31. McCart JA, Gaspar L, Incelet R, et al. Predictors of survival following surgical resection of thymoma. *J Surg Oncol* 1993;54:233-8.
 32. Nakahara K, Ohno K, Hashimoto J, et al. Thymoma: results with complete resection and adjuvant postoperative irradiation in 141 consecutive patients. *J Thorac Cardiovasc Surg* 1988;95:1041-7.
 33. Pennathur A, Qureshi I, Schuchert MJ, et al. Comparison of surgical techniques for early-stage thymoma: feasibility of minimally invasive thymectomy and comparison with open resection. *J Thorac Cardiovasc Surg* 2011;141:694-701.
 34. Chung JW, Kim HR, Kim DK, et al. Long-term Results of Thoroscopic Thymectomy for Thymoma without Myasthenia Gravis. *J Int Med Res* 2012;40:1973-81.
 35. Kimura T, Inoue M, Kadota Y. The oncological feasibility and limitations of video-assisted thoroscopic thymectomy for early-stage thymomas. *Eur J Cardiothorac Surg* 2013;44:e214-8.

Cite this article as: Pupovac SS, Newman J, Lee PC, Alexis M, Jurado J, Hyman K, Glassman L, Zeltsman D. Intermediate oncologic outcomes after uniportal video-assisted thoroscopic thymectomy for early-stage thymoma. *J Thorac Dis* 2020;12(8):4025-4032. doi: 10.21037/jtd-20-1370