

2018

Ascaris in the urinary tract: A case report and review of the literature

B. Baralo

S. Gurram

Northwell Health

J. Steckel

Zucker School of Medicine at Hofstra/Northwell

M. Chulii

A. Sharpilo

Follow this and additional works at: <https://academicworks.medicine.hofstra.edu/publications>




Part of the [Urology Commons](#)

Recommended Citation

Baralo B, Gurram S, Steckel J, Chulii M, Sharpilo A. Ascaris in the urinary tract: A case report and review of the literature. . 2018 Jan 01; 17():Article 4214 [p.]. Available from: <https://academicworks.medicine.hofstra.edu/publications/4214>. Free full text article.

This Article is brought to you for free and open access by Donald and Barbara Zucker School of Medicine Academic Works. It has been accepted for inclusion in Journal Articles by an authorized administrator of Donald and Barbara Zucker School of Medicine Academic Works. For more information, please contact academicworks@hofstra.edu.



Endourology

Ascaris in the urinary tract: A case report and review of the literature

Bohdan Baralo ^{a,*}, Sandeep Gurram ^b, Joph Steckel ^b, Maksym Chulii ^a, Alexandr Sharpilo ^a^a Zhytomir Central City Hospital №1, Velyka Berdychivsyka st. 70, Zhytomir, 10002, Ukraine^b Department of Urology, Smith Institute for Urology, Northwell Health, New Hyde Park, NY, USA

ARTICLE INFO

Article history:

Received 1 August 2017

Received in revised form

28 December 2017

Accepted 4 January 2018

Available online 28 January 2018

Keywords:

Ascaris lumbricoides

Ascariasis/complications

Ureteral obstruction/parasitology

Urologic diseases/parasitology

Ureteroscopy

1. Introduction

The sites of physical migration of adult *Ascaris* include a biliary duct, liver parenchyma, pancreas, peritoneum, thoracic cavity, lacrimal duct, Eustachian tube, fallopian tube, brain, and even a pulmonary artery.¹ Areas that are not organically part of the *Ascaris* migration pattern are accessed through fistulization from sites that are normally infested with *Ascaris*.

Only a limited number of reports are available describing the location of adult *Ascaris* forms in the urinary system. This report is the first description of urinary ascariasis that has caused upper tract obstruction and the first case to describe ureteroscopic manipulation of *Ascaris lumbricoides*.

2. Case presentation

A 30 year old female was admitted from the emergency department (ED) with complaints of severe sharp pain in the left

lumbar region. She reported dull pain for two weeks prior to admission to the hospital. She had an acute worsening of symptoms which evolved to sharp and severe pain necessitating her to come to the ED. She had no previous history of urinary stone disease or urinary tract infections. On the time of admission to the ED she had normal vital signs and normal physical findings except tenderness in the left groin and positive left costovertebral angle tenderness.

Abdominal and retroperitoneal U/S, complete blood count, and urinalysis were performed in the ED. U/S revealed left proximal hydroureter and moderate left hydronephrosis. Laboratory analysis showed mild leukocytosis of 12000/mm³, normal creatinine, and urinalysis demonstrated calcium oxylate crystals but no evidence of microscopic hematuria.

She was hospitalized in the urology department for presumptive left upper tract obstruction from unknown source. Conservative treatment was initially pursued and a non-contrast CT scan was done one day after admission; however, it did not show a source of obstruction (Figs. 1 and 2). Exploratory ureteroscopy was then performed on hospital day six due to continuing renal colic.

During ureteroscopy, a six to seven mm wax-like structure was found in the distal third of the left ureter. This presumed foreign body was relocated with a Dormia N.Stone basket (Coloplast Minneapolis, MN) into the bladder, where it was then extracted cystoscopically with rigid forceps. The removed object was 11cm in length, 6–7mm wide, dark-brown, and of tight elastic consistency. The specimen underwent pathologic review and was determined to be *Ascaris lumbricoides* (Fig. 3).

The patient had an uneventful recovery. Stool for ova and parasites was negative for *Ascaris* eggs, larvae, or worms. The patient had no other source of *Ascaris* that was identified during her hospital stay, and she was discharged home in satisfactory condition.

3. Discussion

Prior studies have shown that maturation of the *Ascaris* larva into the adult worm form is only possible in the GI system. Currently there are only two theories on how *Ascaris lumbricoides* can be introduced into the urinary system. This includes fistula formation between the GI and urinary system or by retrograde migration of the adult worm through the urethra. Urethral migration is generally precipitated by stressful conditions such as fever, illness, anesthesia, or prior anthelmintic medications.^{1,2}

Abbreviations: CT, computerized tomography; U/S, ultrasound; ED, emergency department; CVA, costovertebral angle; GI, gastrointestinal.

* Corresponding author. Present address: Urology department, Vinnytsya National Medical University n.a. Pirogov, Vinnytsya, 21018, Ukraine.

E-mail address: bohdanbaralo@gmail.com (B. Baralo).

<https://doi.org/10.1016/j.eucr.2018.01.003>

2214-4420/© 2018 Published by Elsevier Inc. This is an open access article under the CC BY-NC-ND license (<http://creativecommons.org/licenses/by-nc-nd/4.0/>).

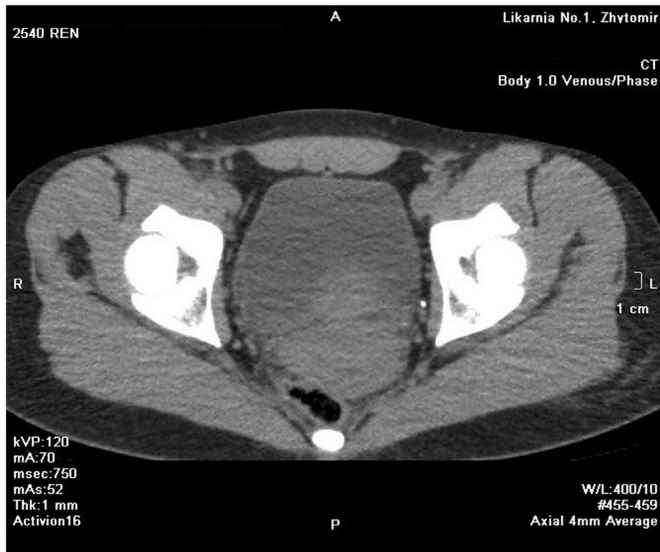


Fig. 1. CT of pelvis shows no obstructing source in the pelvis that was identifiable.

The most commonly reported site of urinary ascariasis is the bladder. There are only two other case reports which describe *Ascaris* localizing to other parts of the urinary system. Quick et al. reported a case of 39 year old male who expelled the worm form through urination and had no symptoms other than tingling sensation in the penis and painless gross hematuria.³ Further investigation showed no connection between the gastrointestinal tract and the urinary system, but revealed a right renal stone. Examinations for ova and parasites were negative for *Ascaris*.

Gupta et al. described a case of a 55 year old male with generalized edema and anuria. After catheterization two worms were entrapped into urine collection bag.⁴ Singh et al. reported a case of a 35 year old female with acute urinary retention that started two days after mebendazole treatment.⁵ *Ascaris lumbricoides* was excreted through the urinary catheter in this case. She also had *Ascaris* noted in a stool analysis and passed two *Ascaris* forms

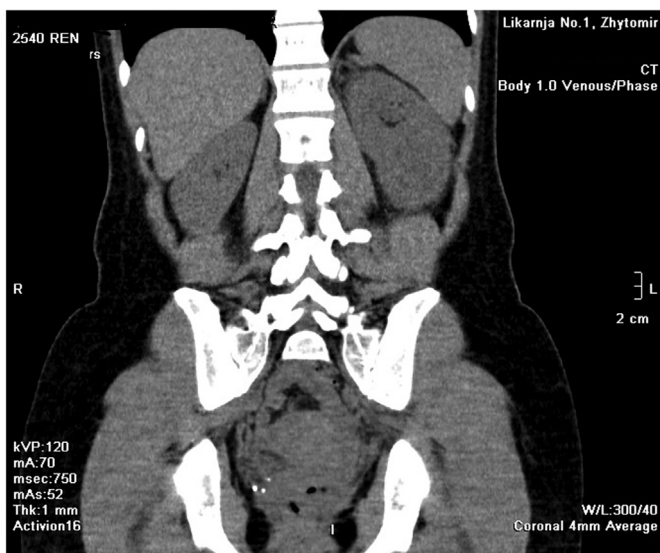


Fig. 2. Coronal images of the CT of the abdomen show no obstructing source.

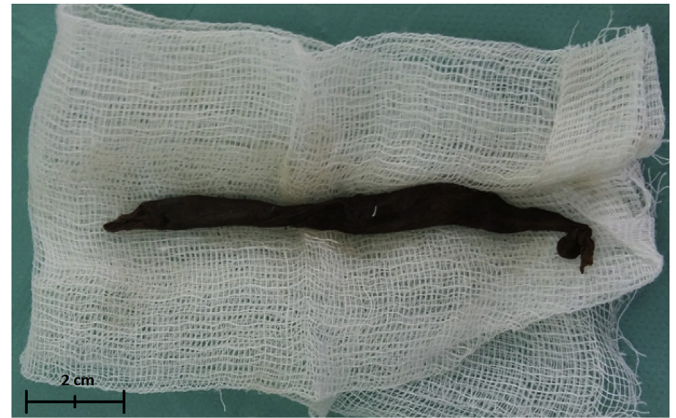

Fig. 3. Adult form of *Ascaris lumbricoides* after ureteroscopic extraction.

through the anus in next 24 hours.

Bustamante-Sarabia described a case of a 25 year old female with a history of three adult *Ascaris* worms released from a subcutaneous abscess.² On postmortem examination, a fistula that connected the transverse colon, proximal third of left ureter, and subcutaneous tissue was found. There were also six live adult *Ascaris* forms occupying the renal pelvis and major calyces. The middle third of the ipsilateral ureter was blocked with a one cm stone, and was presumptively the reason why only retrograde migration and fistulization possible.

Taylor gave us an example of a 6 year old boy who was hospitalized a few days after anti-helminthic treatment was started. He was originally admitted with abdominal pain, cough, loss of appetite, fever, and passage of two adult *Ascaris* worms from the urethra.¹ Isotope renal scan showed that the right kidney was non-functional and it was then surgically removed. On pathologic analysis, *Ascaris lumbricoides* ova in the kidney specimen were discovered.

Given the current data, we believe that our patient experienced retrograde invasion of *Ascaris* through urethra. No signs of fistulization were present either radiographically or by direct visual inspection. The patient also did not have any illness recently or receive prior anthelmintic treatment that could precipitate urinary migration of *Ascaris* forms.

4. Conclusion

This case was different and unique from the prior cases reported in the literature. This is the first case of urinary ascariasis presenting with upper tract obstruction and renal colic. This was also the first ureteroscopic extraction of *Ascaris lumbricoides* that was presented in the literature. This case reinforces the concept that diagnostic ureteroscopy has a role in patients with signs of obstruction but no true identifiable source.

Conflict of interest

None for all authors.

Funding

This research did not receive any specific grant from funding agencies in the public, commercial, or not-for-profit sectors.

References

1. Taylor KL. Ascariasis of the kidney. *Pediatr Pathol Lab Med.* 1995;15:609–615.
2. Bustamente-Sarabia J, Martuscelli A, Tay J. Ectopic ascariasis. *Am J Trop Med.* 1977;26:568–569.
3. Quick G, Sheikho SH, Walker JS. Urinary ascariasis in a man with hematuria. *South Med J.* 2001;94:454–455.
4. Gupta P, Sundaram V, Abraham G, Shantha GP, Mathew M. Obstructive uropathy from *Ascaris lumbricoides*. *Kidney Int.* 2009;75:1242.
5. Singh D, Vasudeve P, Dalela D, Sankhwar SN. *Ascaris lumbricoides*: a stranger in the urinary bladder causing urinary retention. *J Postgrad Med.* 2010;56:222–223.