

2020

Cerebellar infarction requiring surgical decompression in patient with COVID 19 pathological analysis and brief review

H. N. Patel

A. Syed

J. S. Lobel

R. Galler

Zucker School of Medicine at Hofstra/Northwell

J. Georges

See next page for additional authors

Follow this and additional works at: <https://academicworks.medicine.hofstra.edu/publications>



Part of the [Neurosurgery Commons](#)

Recommended Citation

Patel HN, Syed A, Lobel JS, Galler R, Georges J, Carmody M, Puumala M. Cerebellar infarction requiring surgical decompression in patient with COVID 19 pathological analysis and brief review. . 2020 Jan 01; 22():Article 6609 [p.]. Available from: <https://academicworks.medicine.hofstra.edu/publications/6609>. Free full text article.

This Article is brought to you for free and open access by Donald and Barbara Zucker School of Medicine Academic Works. It has been accepted for inclusion in Journal Articles by an authorized administrator of Donald and Barbara Zucker School of Medicine Academic Works. For more information, please contact academicworks@hofstra.edu.


Authors

H. N. Patel, A. Syed, J. S. Lobel, R. Galler, J. Georges, M. Carmody, and M. Puumala



Since January 2020 Elsevier has created a COVID-19 resource centre with free information in English and Mandarin on the novel coronavirus COVID-19. The COVID-19 resource centre is hosted on Elsevier Connect, the company's public news and information website.

Elsevier hereby grants permission to make all its COVID-19-related research that is available on the COVID-19 resource centre - including this research content - immediately available in PubMed Central and other publicly funded repositories, such as the WHO COVID database with rights for unrestricted research re-use and analyses in any form or by any means with acknowledgement of the original source. These permissions are granted for free by Elsevier for as long as the COVID-19 resource centre remains active.



Case Reports & Case Series

Cerebellar infarction requiring surgical decompression in patient with COVID 19 pathological analysis and brief review



Hiren N. Patel^{a,c,*}, Asma Syed^b, Jeffrey S. Lobel^d, Robert Galler^e, Joseph Georges^f, Margaret Carmody^a, Micheal Puumala^a

^a Avera McKennan Hospital, Department of Neurosurgery, USA

^b Infectious Disease, 1301 S Cliff Ave Ste 610, Sioux Falls, SD, USA

^c Newton-Wellesley Hospital, Department of Neurosurgery, 2014 Washington St, Newton, MA, USA

^d Lima Memorial Hospital, Department of Neurosurgery, 1001 Bellefontaine Ave, Lima, OH, USA

^e Northwell Health, Department of Neurosurgery, 1300 Roanoke Ave, Riverhead, NY 11901, USA

^f Cooper University Hospital, Department Neurosurgery, 1 Cooper Plaza, Camden, NJ, USA

ARTICLE INFO

Keywords:

Coronavirus
COVID-19
SARS-COV-2
Ischemic stroke
Sub-occipital craniectomy
Vasculitis
Phlebitis

ABSTRACT

Background: This report and literature review describes a case of a COVID-19 patient who suffered a cerebellar stroke requiring neurosurgical decompression. This is the first reported case of a sub-occipital craniectomy with brain biopsy in a COVID-19 patient showing leptomeningeal venous intimal inflammation.

Clinical description: The patient is a 48-year-old SARS-COV-2 positive male with multiple comorbidities, who presented with fevers and respiratory symptoms, and imaging consistent with multifocal pneumonia. On day 5 of admission, the patient had sudden change in mental status, increased C-Reactive Protein, ferritin and elevated Interleukin-6 levels. Head CT showed cerebral infarction from vertebral artery occlusion. Given subsequent rapid neurologic decline from cerebellar swelling and mass effect on his brainstem emergent neurosurgical intervention was performed. Brain biopsy found a vein with small organizing thrombus adjacent to focally proliferative intima with focal intimal neutrophils.

Conclusion: A young man with COVID-19 and suspected immune dysregulation, complicated by a large cerebrovascular ischemic stroke secondary to vertebral artery thrombosis requiring emergent neurosurgical intervention for decompression with improved neurological outcomes. Brain biopsy was suggestive of inflammation from thrombosed vessel, and neutrophilic infiltration of cerebellar tissue.

1. Introduction

The first reported case of COVID-19 was reported to the WHO in December 2019 [1]. Large vessel stroke has been shown to be a presenting sign or complication of SARS-Cov-2 infection [2]. Oxley et al reported five large vessel stroke in patients, with four requiring neuroendovascular intervention, including one patient that also required neurosurgical intervention (hemicraniectomy) [2]. We report the first case of COVID-19 vertebral artery thrombosis related cerebellar circulation stroke requiring suboccipital decompressive craniectomy.

2. Case presentation

This is a 48-year-old African American male with diabetes, hypertension, untreated latent tuberculosis, who presented with one week history of fevers, cough, shortness of breath, and hypoxia. The patient had a prior history of tuberculosis for which he had not been treated for and had not shown active disease on prior chest x-rays. Initial and hospital clinical characteristics are shown in [Supplementary Table 1](#). The patient tested positive for COVID-19 on presentation with detection of severe acute respiratory syndrome coronavirus 2 (SARS-CoV-2) viral ribonucleic acid from a nasopharyngeal swab specimen using the Cepheid Xpert Xpress SARS-CoV-2 rapid 30 min Real-time Polymerase

Abbreviations: ARDS, acute respiratory distress syndrome; BiPaP, Bilevel positive airway pressure; COVID 19, Corona Virus Disease 2019; CP, cerebellopontine; CRP, C-reactive protein; CT, computed tomography; CTA, CT angiography; CXR, chest X-ray; FiO₂, fraction of inspired oxygen; SARS-COV-2, severe acute respiratory syndrome coronavirus 2; STAT, statum which is Latin meaning immediately; t-PA, tissue plasminogen activator; WHO, World Health Organization

* Corresponding author at: Department of Neurosurgery, Avera McKennan Hospital, 1301 S Cliff Ave Ste 610, Sioux Falls, SD 57105, United States.

E-mail addresses: hpatel@partners.org (H.N. Patel), a.syed@avera.org (A. Syed), JSLobel@LimaMemorial.org (J.S. Lobel), Rgaller1@northwell.edu (R. Galler), jfgeorg@asu.edu (J. Georges), Margaret.carmody@avera.org (M. Carmody), Michael.puumala@avera.org (M. Puumala).

<https://doi.org/10.1016/j.inat.2020.100850>

Received 17 July 2020; Accepted 26 July 2020

Available online 29 July 2020

2214-7519/© 2020 The Authors. Published by Elsevier B.V. This is an open access article under the CC BY-NC-ND license

(<http://creativecommons.org/licenses/by-nc-nd/4.0/>).

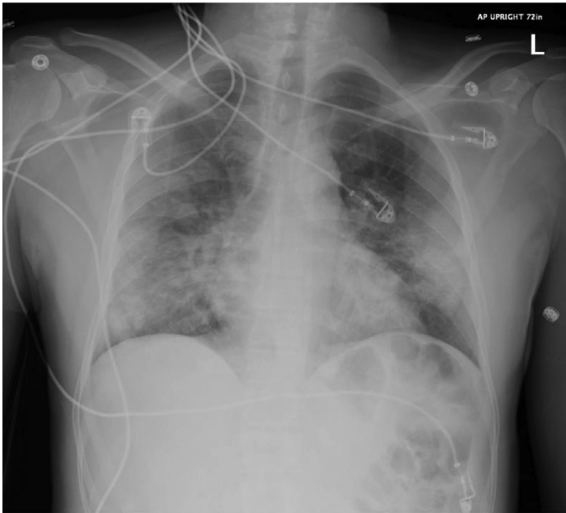


Fig. 1. Chest X-Ray on admission: Multifocal pulmonary consolidative opacities are present.

Chain Reaction (RT-PCR) assay*. Patient initial chest x-ray shown in Fig. 1.

Patient fevers had continued with a T-max of 102.0 degrees Fahrenheit. His oxygen requirement had remained stable at 2 L of nasal cannula. His work of breathing was minimal and he appeared comfortable. On review of his labs, the white count remained elevated to 11.1 per cubic millimeter, creatinine remained at 0.9 mg per deciliter, with normal liver enzymes, ferritin was at 583 ng per milliliter with a CRP of 33 mg per deciliter. Given stable oxygen requirements he was conservatively managed. The patient was started on subcutaneous heparin injection 5000 mg three times a day for deep venous thrombosis prophylaxis. Over the next 2 days the patient continued to require supplemental oxygen, and his oxygen requirement worsened to 6 L via nasal cannula, with slightly increased work of breathing on hospital day 4.

He was stable until day 5 of admission, when his oxygen requirements started to worsen. On day 5 his oxygen requirements acutely declined, and he was placed on high flow nasal cannula and later transitioned to BiPAP with an FiO₂ of 60%. He was noted to be tachypneic, and along with these changes his mental status had acutely declined with noted right gaze deviation, and aphasia. He spiked a fever of 101°F degrees Fahrenheit, and review of labs showed an increase in white count to 16.6 per cubic millimeter, along with increasing platelets to 453 per cubic millimeter. His CRP had increased from 27.8 mg per deciliter to 48.4 mg per deciliter, along with his ferritin from 723 ng per milliliter to 955 ng per milliliter. His lactate had also increased to 2.4 millimoles per liter. A CT Angiogram of the head was performed which showed thrombotic occlusion of the cervical and intracranial segments of the left vertebral artery along with thrombosis of the proximal cervical segment of the right vertebral artery and extension of the thrombus from the thrombosed left vertebral artery into the proximal basilar artery. Due to evidence of clot extension into the basilar artery and stroke symptoms it was determined that the patient had a thrombosis and not a hypoplastic vertebral artery (Fig. 2A, B). His chest x-ray remained stable. He received IV TPA and was placed on low dose heparin by the neurology team. The patient had no neurologic improvement following the administration of TPA and being placed on a heparin drip. Stroke work up revealed anti-cardiolipin IgM and Beta 2 GPI IgA antibodies, which was concerning for anti-phospholipid antibody syndrome. One dose of off-label 8 mg/kg Tocilizumab was administered via emergency use protocol, upon admission to the ICU for suspected immune dysregulation/cytokine release storm syndrome due to COVID-19. The patient was also started on dexamethasone 10 mg

daily for 5 doses for moderate ARDS. His interleukin-6 levels were also checked and these were elevated at 555 pg/ml. The remainder of the patient's stroke work up did not identify any abnormal cardiac rhythm, cardiac embolus, dissection, or atherosclerotic disease process.

Over the next 48 h, on day 6, and day 7 of admission, his mental status declined further and he was intubated. A repeat CT of the head showed increasing mass-effect on the fourth ventricle in the right cerebellar hemisphere, with effacement of the CP angle cisterns and midline shift (Fig. 2C, D).

On hospital day 9 patient had Cushing response (hypertension with bradycardia) indicating an increase in the intracranial pressure with STAT consultation of neurosurgery by the primary team. The systolic blood pressure increased to 182 mmHg and heart rate decreased to 52 beats per minute. STAT CT head showed left cerebellar stroke with mass effect on the fourth ventricle and obliteration of the paramesencephalic cistern. No gross hydrocephalus (Fig. 2E). Due to the patient rapid clinical decline, Cushing response, and radiographic findings of mass effect on the brainstem it was decided the patient would need emergent cerebellar decompression and placement of an external ventricular drainage catheter in order to alleviate intracranial hypertension. The neurologic decline was attributed to increased cerebellar edema secondary from the original stroke event. The Patient was given weight dosed Protamine 7.5 mg to reverse the heparin gtt and mannitol in anticipation for emergent suboccipital craniectomy and placement of right external ventricular drain for intracranial pressure (ICP) monitoring and drainage. The surgery was performed under COVID-19 precautions in a negative pressure operating room and all staff wore Powered Air Purifying Respirator (PAPR) throughout the case and with all clinical interactions with the patient.

The surgery was performed by the primary author with the patient supine initially for placement of right external ventricular drainage catheter (EVD) using standard landmarks at the right Kocher's point. Following EVD placement the patient was positioned prone and underwent a 4 cm × 3 cm suboccipital decompressive craniectomy with opening of the foramen magnum. A left cerebellar biopsy was obtained from infarcted tissue including an arterial and venous vessel and 1 cm × 1 cm section of parenchyma and dura.

Pathology revealed a single vessel, presumably a vein, with a small organizing thrombus adjacent to a focally proliferative intima with intimal neutrophils, without evidence of arterial vasculitis. Focal scattered neutrophils within the molecular layer of the cerebellar tissue were also noted. (Fig. 3).

On post operative day (POD) 1 patient had ICP's in the high 30 s that were controlled with mannitol, hypertonic saline and EVD drainage. Mannitol was started by the neurocritical care service and was discontinued by the neurosurgical service as there is no evidence of its benefit in a patient with external ventricular drainage. The EVD was weaned and discontinued on POD 6. Patient began to follow commands on the right side and remained hemi paretic on the left side. Patient respiratory status was improved and transferred to a rehabilitation facility and neurologically stable in follow up.

3. Discussion

Much of the pathophysiology pertaining to SARS-Cov-2 infection is not well understood. There has been some resemblance to disease caused by SARS-COV-2 to SARS-COV and MERS; with direct infection of type-II pneumocytes, via the ACE-2 receptor binding domain during the initial phase of illness [3–5]. The pathogenesis also involves immune dysregulation, which has been noted in severely ill patients with SARS-Cov-2 infection [6–8]. Two distinct syndromes have been noted in patients with COVID-19; immune dysregulation and macrophage activation syndrome [8]. An increase in inflammatory cytokines, has been noted in both, with majority of patients noted to have elevated interleukin-6 levels [8]. Levels of Interleukin-6 have also been shown to correlate with increased severity of disease, disease progression and

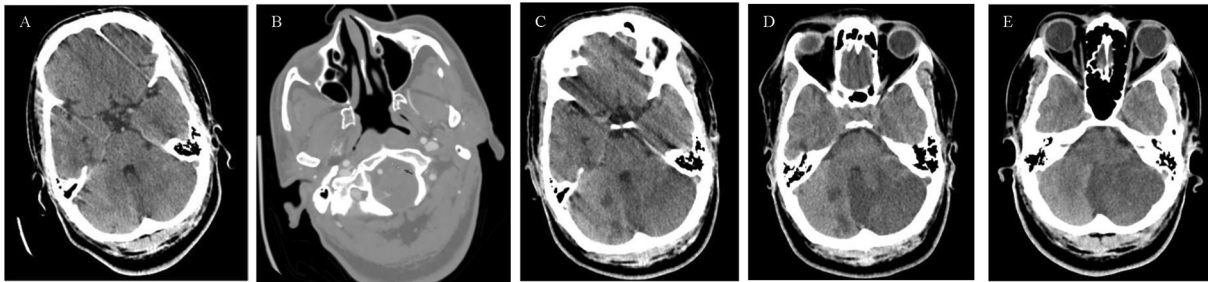


Fig. 2. Noncontrast Head CT Time Course. A. Hospital Day 5. Noncontrast head CT at time of stroke alert, note no hypodensity, no hydrocephalus and no mass effect on fourth ventricle. B. CT Angiogram head at time of stroke alert, note vertebral artery occlusion (arrows). C. Hospital Day 6. CT head non-contrast shows left cerebellar infarct with effacement of the CP angle cistern and left-to-right midline shift without hydrocephalus, fourth ventricle remains patent. D. Hospital Day 7. CT head non-contrast shows evolving left cerebellar stroke with increasing mass effect on the fourth ventricle without hydrocephalus. E. Hospital Day 9. CT head non-contrast shows left cerebellar infarct with significant mass effect on the fourth ventricle and paramesencephalic cistern. No hydrocephalus.

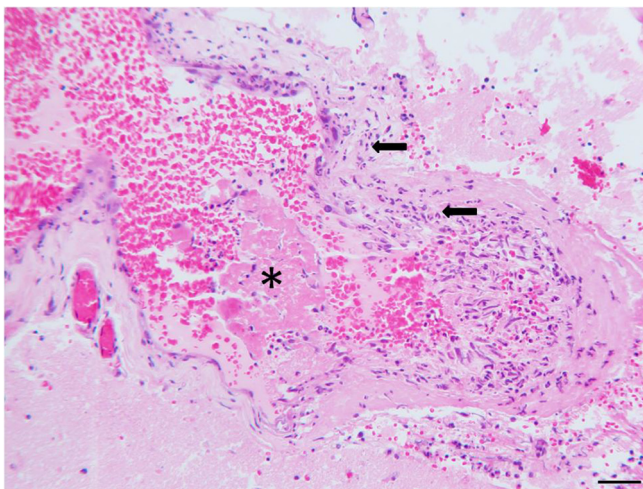


Fig. 3. H&E permanent section of left cerebellum brain biopsy, note histology leptomenigeal vein with neutrophilic infiltrates (arrows) in the blood vessel wall. The asterisk denotes a fibrin plug in the lumen of the vein. The scale bar equals 50 μ m.

poor prognosis in addition to certain other biomarkers; these include elevated ferritin, elevated white blood cell count, lymphopenia, and elevated platelet count [9,10].

Apart from biomarkers of inflammation, co-morbidities including diabetes and hypertension, have also been shown to be risk factors for severe disease [11,12]. This was also noted in our patient, who was a diabetic and had hypertension increasing his risk for progression to severe disease. He was noted to have lymphopenia, elevated CRP, ferritin, and was later shown to have increased interleukin-6 levels, showing immune dysregulation. Moreover, our patient also tested positive for anti-cardiolipin IgM and Beta 2 GPI IgA antibodies, which is concerning for anti-phospholipid antibody syndrome; which has also been described in two other diabetic patients with stroke one of which also had significant coagulopathy similar to our patient who developed sudden increase in D-dimer (> 20.0 ng per milliliter) and elevated PT, PTT and low fibrinogen levels (158 mg per deciliter), interestingly with a normal platelet count on day 6 of admission [13]. Infection accounts for the cause of 8–11% of cases of cerebral venous thrombosis [14]. Our patient had radiographic evidence of arterial thrombosis and pathological evidence of venous thrombosis. Larger studies will be helpful to examine the impact of diabetes in COVID-19 patients as a risk factor for development of anti-phospholipid antibodies, coagulopathy and stroke.

Interestingly, severity of COVID-19 has been shown to correlate with risk of coagulopathy and stroke in Caucasian patients, and in general, ethnicity has been shown have a major effect in the risk of thrombosis with African Americans at higher risk than Caucasians or

Chinese [15]. Given interleukin-6 levels have also been shown to be elevated in patients critically ill with COVID-19, it would be interesting to know if there is a correlation between risk of stroke and coagulopathy with increased levels of interleukin-6 [8]. It could be hypothesized that immune dysregulation can predispose patients to anti-phospholipid antibody syndrome or development of clinically significant coagulopathy, and hence, increase their risk of stroke. However, whether this effect holds true in the presence of co-morbidities could be better assessed in larger clinical trials.

Our patient was identified to be in a state of immune dysregulation, given increased CRP, ferritin, and interleukin-6 levels, and hence one dose of off-label Tocilizumab was given in an attempt rescue immune dysregulation by SARS-CoV-2. Tocilizumab is an Interleukin-6 receptor antagonist, shown to be beneficial in treatment of patients with severe disease from SARS-Cov-2 in smaller studies, however, larger studies are needed and are underway to examine the impact on morbidity and mortality [16,17]. Tocilizumab did not demonstrate increased risk of hypercoagulability, thrombosis or drug interaction that led to increased coagulability [18]. Some benefit was noted in our patient, with improving markers of inflammation, and respiratory status, however, the clinical picture was complicated by severity of stroke and associated edema with impending herniation.

The patient had been on supportive care prior to his stroke and was not given any medication that had side effects or drug interactions that would increase his risk of thrombosis and stroke.

Currently, treatment modalities for SARS-Cov-2 infection are limited, with need for larger studies, and randomized trials showing a benefit in outcomes and mortality. Recently, the FDA approved use of convalescent plasma for critically ill patients with COVID-19, and more recently, emergency use authorization of use of Remdesivir to allow for distribution in the United States for treatment of severe disease. At the time of this writing, Remdesivir is only available to a few sites in United States, with majority with access for compassionate use in pregnant women and children [19].

Convalescent plasma has been studied in infections with SARS-CoV and MERS, and it is hypothesized it may improve mortality in patients infected with SARS-Cov-2, with good experience noted in smaller studies [20–22]. Several clinical trials are ongoing to examine the effect of convalescent plasma, including one at our institution. It would be interesting to know if early administration of convalescent plasma is beneficial is prevention of cytokine cascade, increased levels of immunoregulatory cytokines, and immune dysregulation. This might reduce the impending severity of disease, and possibly mortality from infection.

Arterial thrombosis and associated intracerebral stroke frequency has been noted as the current COVID-19 pandemic continues [2,25,26,28]. Previous descriptions of stroke phenomenon requiring either neuro endovascular intervention or formal surgical intervention have been reported, acute ischemic events involving peripheral arterial

vessels with limb ischemia have also been noted [2,22]. Hypotheses as to the pathophysiologic causes have been discussed and a virus related state of hypercoagulability may be the direct result in select groups of individuals [2,23]. Unfortunately the systemic cause of hypercoagulability has not been pinpointed and trends associated with d-dimer elevations during the course of arterial vessel thrombosis both in our case and others have been described [24]. Whether or not the viral infection results in a vasculitic response to particular organs is unclear, and at this time early markers of inflammation may need to be followed closely in order to proactively anti-coagulate patients who may be deemed at risk of thrombus development [27,28].

The case presented from our institution, demonstrates a trend in d-dimer elevation and possible concurrent vessel thrombosis. The brain biopsy demonstrated cerebral venous neutrophilic infiltration of the intimal layer with adjacent fibrin clot formation. The artery did not show any signs of vasculitis, but that may have been secondary to sampling error. As no embolic source was uncovered during the investigations, and drug related thrombosis was ruled out, it was hypothesized our patient stroke was secondary to large vessel vasculitis and venous phlebitis as evidenced by radiologic imaging and brain biopsy. The patient was not treated with corticosteroids prior to his stroke. The patient received dexamethasone as treatment for ARDS after being admitted to the ICU. There are currently ten clinical trials underway worldwide as per clinicaltrials.gov that are looking at the efficacy of dexamethasone in COVID-19 patients. Corticosteroids as a treatment for cerebral vasculitis is well documented [29]. It would be interesting to see if these trials show lower incidence of strokes in their cohorts. COVID-19 complicated with cerebral and large vessel vasculitis and its treatment will require a need for randomized clinical trials showing benefit in outcomes and mortality.

The infectious process of COVID-19 remains a systemic event with pathophysiologic evidence of vasculitis involving the lungs, venous and arterial systems. As the disease process is further defined, it will be imperative that new diagnostic strategies are developed along with tracking of individual coagulopathy. Early neurosurgical consultations may have to be considered when patients present with neurologic changes or suspected intracranial ischemic phenomenon. As case numbers and data are compiled, trends may be noted thus simplifying treatment modalities necessary for thrombo-embolic complications.

4. Conclusion

This is a report of a patient with COVID-19 immune dysregulation who developed an acute cerebellar ischemic stroke secondary to vertebral artery thrombosis. A biopsy showed venous phlebitis with neutrophilic infiltration of the vessel wall. The patient had a large vessel occlusion from presumed arteritis with intracranial evidence of venous involvement indicating a possible pathophysiologic mechanism for incidence of thrombosis and stroke in COVID-19 patients.

Declaration of Competing Interest

The authors declare that they have no known competing financial interests or personal relationships that could have appeared to influence the work reported in this paper.

Appendix A. Supplementary data

Supplementary data to this article can be found online at <https://doi.org/10.1016/j.inat.2020.100850>.

doi.org/10.1016/j.inat.2020.100850.

References

- [1] World Health Organization. "Rolling Updates on Coronavirus Disease (COVID-19). Updated 28, April 2020." (2020).
- [2] T.J. Oxley, et al., Large-vessel stroke as a presenting feature of Covid-19 in the young, *N. Engl. J. Med.* (2020) e60.
- [3] S. Tian, W. Hu, L. Niu, H. Liu, H. Xu, S.Y. Xiao, Pulmonary pathology of early phase 2019 novel coronavirus (COVID-19) pneumonia in two patients with lung cancer, *J. Thoracic Oncol.* (2020).
- [4] B. Rockx, T. Kuiken, S. Herfst, et al., Comparative pathogenesis of COVID-19, MERS, and SARS in a nonhuman primate model, *Science* (2020).
- [5] J. Lan, J. Ge, J. Yu, S. Shan, et al., Structure of the SARS-CoV-2 spike receptor-binding domain bound to the ACE2 receptor, *Nature* (2020) 1–6.
- [6] C. Qin, L. Zhou, Z. Hu, et al., Dysregulation of immune response in patients with COVID-19 in Wuhan China, *Clin. Infect. Dis.* (2020).
- [7] B. Diao, C. Wang, Y. Tan, et al., Reduction and functional exhaustion of T cells in patients with coronavirus disease 2019 (COVID-19), *Front. Immunol.* 11 (2020) 827.
- [8] E.J. Giamarellos-Bourboulis, M.G. Netea, N. Rovina, et al., Complex immune dysregulation in COVID-19 patients with severe respiratory failure, *Cell Host Microbe* (2020).
- [9] Henry BM, De Oliveira MH, Benoit S, Plebani M, Lippi G. Hematologic, biochemical and immune biomarker abnormalities associated with severe illness and mortality in coronavirus disease 2019 (COVID-19): a meta-analysis. *Clinical Chemistry and Laboratory Medicine (CCLM)*. 2020 Apr 10;1(ahead-of-print).
- [10] Z.S. Ulhaq, G.V. Soraya, Interleukin-6 as a potential biomarker of COVID-19 progression, *Méd. Maladies Infect.* (2020).
- [11] J. Yang, Y. Zheng, X. Gou, et al., Prevalence of comorbidities in the novel Wuhan coronavirus (COVID-19) infection: a systematic review and meta-analysis, *Int. J. Infect. Dis.* (2020).
- [12] W.J. Guan, W.H. Liang, Y. Zhao, et al., Comorbidity and its impact on 1590 patients with Covid-19 in China: a nationwide analysis, *Eur. Respir. J.* (2020).
- [13] Y. Zhang, M. Xiao, S. Zhang, et al., Coagulopathy and antiphospholipid antibodies in patients with Covid-19, *N. Engl. J. Med.* 382 (17) (2020) e38.
- [14] S.M. Silvis, D.A. De Sousa, J.M. Ferro, J.M. Coutinho, Cerebral venous thrombosis, *Nat. Rev. Neurol.* 13 (9) (2017) 555.
- [15] D. McGonagle, J.S. O'Donnell, K. Sharif, P. Emery, C. Bridgewood, Immune mechanisms of pulmonary intravascular coagulopathy in COVID-19 pneumonia, *Lancet Rheumatol.* (2020).
- [16] X. Xu, M. Han, T. Li, et al., Effective treatment of severe COVID-19 patients with tocilizumab, *Proc. Natl. Acad. Sci.* (2020).
- [17] P. Luo, Y. Liu, L. Qiu, X. Liu, D. Liu, J. Li, Tocilizumab treatment in COVID-19: a single center experience, *J. Med. Virol.* (2020).
- [18] Sheppard, M., Laskou, F., Stapleton, P. P., Hadavi, S., & Dasgupta, B. (2017). Tocilizumab (actemra).
- [19] <https://www.gilead.com/purpose/advancing-global-health/covid-19/emergency-access-to-remdesivir-outside-of-clinical-trials>.
- [20] C. Shen, Z. Wang, F. Zhao, et al., Treatment of 5 critically ill patients with COVID-19 with convalescent plasma, *JAMA* 323 (16) (2020) 1582–1589.
- [21] K. Duan, B. Liu, C. Li, et al., Effectiveness of convalescent plasma therapy in severe COVID-19 patients, *Proc. Natl. Acad. Sci.* 117 (17) (2020) 9490–9496.
- [22] B. Zhang, S. Liu, T. Tan, et al., Treatment with convalescent plasma for critically ill patients with SARS-CoV-2 infection, *Chest* (2020).
- [23] R. Bellosta, L. Luzzani, G. Natalini, M.A. Pegorer, L. Attisani, L.G. Cossu, C. Ferrandina, A. Fossati, E. Conti, R.L. Bush, G. Piffaretti, Acute limb ischemia in patients with COVID-19 pneumonia, *J. Vasc. Surg.* (2020), <https://doi.org/10.1016/j.jvs.2020.04.483>.
- [24] H. Fogarty, L. Townsend, C. Ni Cheallaigh, et al., COVID-19 coagulopathy in caucasian patients, *Br. J. Haematol.* (2020).
- [25] A. Rodríguez-Pla, J.H. Stone, Vasculitis and systemic infections, *Curr. Opin. Rheumatol.* 18 (1) (2006) 39–47.
- [26] F.A. Klok, M.J. Kruip, N.J. Van der Meer, et al., Incidence of thrombotic complications in critically ill ICU patients with COVID-19, *Thromb. Res.* (2020).
- [27] F. Violi, D. Pastori, R. Cangemi, P. Pignatelli, L. Loffredo, Hypercoagulation and antithrombotic treatment in coronavirus 2019: a new challenge, *Thromb. Haemost.* (2020).
- [28] C. Lodigiani, G. Iapichino, L. Carenzo, et al., Venous and arterial thromboembolic complications in COVID-19 patients admitted to an academic hospital in Milan, Italy, *Thromb. Res.* (2020).
- [29] S. Monti, A.F. Águeda, R.A. Luqmani, F. Buttgerit, M. Cid, C. DeJaco, B. Hellmich, Systematic literature review informing the 2018 update of the EULAR recommendation for the management of large vessel vasculitis: focus on giant cell arteritis, *RMD Open* 5 (2) (2019) e001003.