

2020

## Gonococcal osteomyelitis in a pediatric patient with disseminated gonococcal infection: Implications for antimicrobial management

W. Liakos

*Zucker School of Medicine at Hofstra/Northwell*

B. Schaffler

*Zucker School of Medicine at Hofstra/Northwell*

S. Rajan

*Zucker School of Medicine at Hofstra/Northwell*

S. H. Hagmann

*Zucker School of Medicine at Hofstra/Northwell*

Follow this and additional works at: <https://academicworks.medicine.hofstra.edu/publications>




Part of the [Pediatrics Commons](#)

---

### Recommended Citation

Liakos W, Schaffler B, Rajan S, Hagmann SH. Gonococcal osteomyelitis in a pediatric patient with disseminated gonococcal infection: Implications for antimicrobial management. . 2020 Jan 01; 21():Article 7865 [ p.]. Available from: <https://academicworks.medicine.hofstra.edu/publications/7865>. Free full text article.

This Article is brought to you for free and open access by Donald and Barbara Zucker School of Medicine Academic Works. It has been accepted for inclusion in Journal Articles by an authorized administrator of Donald and Barbara Zucker School of Medicine Academic Works. For more information, please contact [academicworks@hofstra.edu](mailto:academicworks@hofstra.edu).



# Gonococcal osteomyelitis in a pediatric patient with disseminated gonococcal infection: Implications for antimicrobial management

William Liakos<sup>a,\*</sup>, Benjamin Schaffler<sup>a</sup>, Sujatha Rajan<sup>a,b</sup>, Stefan H.F. Hagmann<sup>a,b</sup>

<sup>a</sup> Donald and Barbara Zucker School of Medicine at Hofstra/Northwell, 500 Hofstra Blvd, Hempstead, New York, 11549, United States

<sup>b</sup> Steven and Alexandra Cohen Children's Medical Center, Northwell Health, Division of Pediatric Infectious Diseases, 269-01 76th Ave, Queens, New York, 11040, United States

## ARTICLE INFO

### Article history:

Received 11 June 2020

Received in revised form 16 June 2020

Accepted 16 June 2020

### Keywords:

*Neisseria gonorrhoeae*

Disseminated gonococcal infection

Gonococcal septic arthritis

Gonococcal osteomyelitis

Antibiotic resistance

## ABSTRACT

We report a case of a female teenager with gonococcal septic arthritis of the right shoulder that also caused osteomyelitis of the humeral head. Infection with *Neisseria gonorrhoeae* is a frequently diagnosed sexually transmitted infection in the sexually active teenage population and disseminated gonococcal infection (DGI) is the most common systemic manifestation of acute gonorrhoea. DGI commonly involves acute arthritis, tenosynovitis and dermatitis with less common complications of endocarditis, hepatitis and meningitis. In contrast, osteomyelitis has only rarely been reported as a result of gonococcal infection. Clinicians need to be aware of this unusual manifestation of DGI as a prolonged duration of antimicrobial treatment may be needed to assure complete resolution of this infection.

© 2020 The Authors. Published by Elsevier Ltd. This is an open access article under the CC BY-NC-ND license (<http://creativecommons.org/licenses/by-nc-nd/4.0/>).

## Introduction

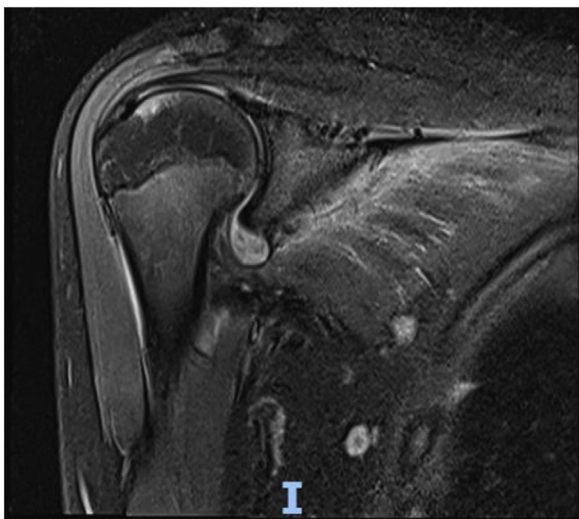
Gonorrhoea is one of the more common sexually transmitted infections worldwide and in the United States, with the potential to spread via mucous membranes including the genitourinary tract, oropharynx, rectum, as well as the conjunctivae. In the United States in 2017, the incidence of infections with *Neisseria gonorrhoeae* was 171.9 cases per 100,000, with an infection rate that has increased by 75.2 % since a low point in 2009. In comparison, in 2017 primary syphilis and chlamydia were noted at an infection rate of 12.1 cases per 100,000, and 528.8 cases per 100,000, respectively [1]. Moreover, in addition to the recently growing gonococcal infection rates, reduced antimicrobial susceptibility has been increasingly noted as well [2]. Disseminated gonococcal infection (DGI) occurs in 0.5–3 % of patients with gonorrhoea and may present as septic arthritis [3]. While other pathogens implicated in septic arthritis are known to frequently cause osteomyelitis, there are few reports of osteomyelitis secondary to gonococcal arthritis with little guidance existing for appropriate treatment courses for this condition [2]. We describe a case of gonococcal septic arthritis complicated by osteomyelitis of the humeral head in a teenage female with DGI requiring prolonged antimicrobial treatment, and review previous DGI cases with osteomyelitis reported in the literature.

## Case report

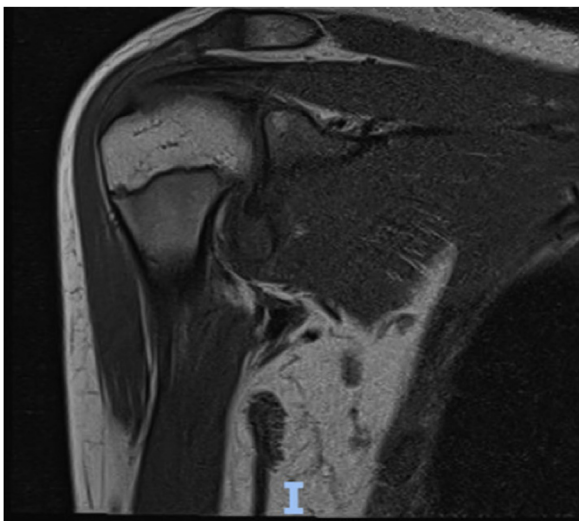
A healthy 14-year-old girl presented to our hospital with a 5-day history of worsening right shoulder pain and fever. She initially had left hip, thigh, and great toe pain with difficulty bearing weight on that leg but this resolved after one day. She presented 3 days later with worsening of her shoulder pain and decreased range of motion. She denied any trauma, or recent illness. Furthermore, international travel, exposure to animals, outdoor activity in wooded areas including tick bites, or any history of sexual activity were denied. Confronted with the diagnosis of a gonococcal infection, the patient later revealed unprotected sexual intercourse with a new male partner approximately two weeks prior to presentation. In her review of systems, no dysuria, vaginal discharge, throat pain, numbness of right arm, rashes, respiratory symptoms, redness over joint, or joint swelling were noted. Physical exam revealed an afebrile patient with stable vital signs who was in moderate distress due to pain in her right shoulder while holding her right arm to her chest. The skin over the right shoulder was intact with no obvious deformity, erythema or signs of effusion. Tenderness to palpation was noted at both anterior and posterior aspects of the shoulder joint. The active range of motion could not be accurately determined due to pain but the right shoulder could be passively flexed to 30 degrees and abducted to 25 degrees. The sensation in the right arm was intact with good capillary refill. Findings of the remainder of the physical examination were unremarkable. A radiograph of the right shoulder showed no abnormalities.

\* Corresponding author.

E-mail address: [wliakos@northwell.edu](mailto:wliakos@northwell.edu) (W. Liakos).



**Fig. 1.** T2 MRI image of right shoulder on day 6 of ceftriaxone treatment with evidence of septic arthritis and persistent joint effusion with diffuse synovial thickening, as well as a focal lesion (1.8 × 0.7 cm) on the proximal humeral epiphysis consistent with acute osteomyelitis.



**Fig. 2.** T1 MRI image at same time period as Fig. 1 with similar findings of arthritis and osteomyelitis.

Laboratory studies revealed a white blood cell count of 9300/ $\mu$ L, an elevated C-reactive protein (CRP) of 152 mg/dL, and an abnormal erythrocyte sedimentation rate (ESR) of 102 mm/h. Her urinalysis was notable for leukocyte esterase with >50 white blood cell per high powered field, and a subsequent urine sample detected *N. gonorrhoeae* by nucleic acid amplification test (NAAT) methodology. Arthrocentesis resulted in drainage of 7 ml of cloudy yellow fluid with 63,655 cells/ml with 91 % segmented neutrophils in the differential cell count. The Gram stain did not show any organisms.

The affected joint was incised and drained with placement of a Penrose drain, and empiric antimicrobial treatment with intravenous (IV) ceftriaxone (75 mg/kg/day) and IV clindamycin (30 mg/kg/day) was started. The synovial fluid culture then yielded growth of *N. gonorrhoeae* with susceptibility to ceftriaxone (MIC < 0.1  $\mu$ g/mL) which allowed continuation of the antimicrobial treatment with IV ceftriaxone alone. After 1 week of treatment, pain and mobility of the affected shoulder had not improved, and magnetic resonance imaging (MRI) demonstrated a focus of osteomyelitis in

the right humeral head (Figs. 1 and 2). At this time treatment was transitioned to oral cefixime 400 mg daily, which was continued for a total of 35 days until inflammatory markers (CRP and ESR) had normalized although joint functional recovery was incomplete (i.e. not able to raise hand above head) at 6 week follow up post-hospitalization. Patient was lost to follow up after this visit.

A literature search was conducted using PubMed with the search terms “Gonococcal Osteomyelitis” and “Gonorrhoeae Osteomyelitis”. References within articles were reviewed for additional cases. In total, we identified 18 previous cases of DGI-associated osteomyelitis in the English literature between 1968 and 2020 (Table 1).

## Discussion

DGI results from systemic spread of *N. gonorrhoeae* that has usually been sexually transmitted. DGI can occur at any age, although most are younger than 40 years of age. Historically, DGI has higher incidence in females than males, possibly with some relationship to physiologic changes associated with menstruation and pregnancy, but that trend has now reversed and infection is more common in males [1,4]. Prior symptomatic genitourinary infection is uncommonly found in patients with DGI, and the major risk factor for disseminated infection is thought to be asymptomatic mucosal infection that delays diagnosis and treatment [5]. It encompasses a wide spectrum of clinical manifestations, with the classic triad of rash, arthritis, and tenosynovitis predominating. These disseminated infections are a leading cause of acute septic arthritis in adults, as well as rarely causing endocarditis, hepatitis, or meningitis. Gonococcal osteomyelitis is also a rare manifestation of disseminated infection with *N. gonorrhoeae*, typically appearing in those patients with untreated septic arthritis for an extended period of time. In the pre-antibiotic era, DGI commonly resulted in septic arthritis and up to 85 % of patients with gonococcal infection developed radiographic features consistent with adjacent osteomyelitis [6]. Effective antimicrobial treatment of infections with *N. gonorrhoeae* have resulted in DGI becoming more of a rare occurrence, although increasing rates of antibiotic resistance have recently been noted [2,7].

The mechanism of gonococcal bone infection could be either by hematogenous spread of *N. gonorrhoeae* during early gonococcal bacteremia or by direct inoculation from the surrounding infected joint. In the presented case, we favored direct inoculation over hematogenous spread as the likely mechanism as the osteomyelitic focus was located in the epiphysis, surrounded and in direct contact with the septic joint capsule, and not in the metaphysis where most osteomyelitis following hematogenous spread occurs because of slower-flowing vasculature [8]. Further, delay of detection and treatment for DGI seem to increase the risk for developing gonococcal osteomyelitis and hence support the notion that not early bacteremia of *N. gonorrhoeae* but prolonged exposure of bone to an infected joint may result in osteomyelitis as has been described for other reported cases of gonococcal osteomyelitis, especially of the long bones [9,10]. One review of nine patients with gonococcal osteomyelitis demonstrated that symptoms of arthralgia may begin insidiously, different from the presentation of other common osteomyelitis pathogens that may present more acutely. Furthermore, it was noted that significant delay between the onset of joint symptoms and the initiation of appropriate antibiotic therapy was a common risk factor among patients found to have confirmed gonococcal osteomyelitis [6]. Our patient was symptomatic for about one week with shoulder pain, polyarthralgia symptoms, and fever before reporting to our institution, which may have been early manifestations of disseminated gonococcal infection that went unrecognized. Although surgical drainage was completed early in the hospital course and antibiotic

**Table 1**  
Cases of gonococcal osteomyelitis reported in the peer-reviewed literature since 1968.

Author (year published)	Age	Sex	Joint/bone involved	Treatment	Outcome
Keiser et al (1968) [17]	20	F	First MCP	IV PCN 5 days, oral PCN 10 days	Complete resolution
Magee (1975) [18]	14	F	First PIP	IV PCN (unknown duration)	Complete resolution
Angevine et al (1976) [19]	16	F	Second MCP	IV penicillin 3 weeks, oral PCN 3 weeks	Residual limitation -crepitation, decreased flexion, joint space narrowing
Gantz et al (1976) [20]	31	F	Second MCP	IV PCN 1 week, oral ampicillin 3 weeks	Complete resolution
Mehta and Wright (1977) [21]	20	F	Hip	IV PCN 6 days, oral ampicillin 2 weeks	Residual limitation – limited ROM and degenerative OA changes on imaging
Liftik et al (1978) [22]	25	M	MTP, MCP	IV PCN 4 days, oral ampicillin 1 week, oral tetracycline 2 weeks	Complete resolution
Rinaldi et al (1982) [23]	22	F	Left wrist	IV cefoxitin 3 weeks, Open drainage, Oral tetracycline 10days	Residual limitation - lysis and cortical erosion at the inferior radioulnar joints
Tindall and Regan-Smith (1983) [24]	29	M	Hip, shoulder	IV PCN 1 month, oral PCN 2 weeks	Permanent disability, hip replacement
Black and Cohen (1984) [6]	46	F	First MT	Oral cephalixin 1 week, Oral PCN for 5 weeks	Residual limitation -limited ROM
Hurley et al (1987) [25]	27	F	Wrist	IV and oral antibiotics for more than 6 weeks	Residual limitation – limited ROM
Ingram et al (1991) [13]	24	M	Cuneiform bone, third MTP	Oral cephalixin 7 days, Surgical debridement, IV CTX 6 weeks	Complete resolution
Duvauchelle and Pien (1994) [26]	24	M	Left foot	IV antibiotics alone 6 weeks	Complete resolution
Shibata et al (2004) <sup>a</sup> [10]	20	F	Shoulder, MTP, MCP	Oral faropenem and clarithromycin 4 days, IV cephazolin 4 days, oral minocycline 4 days, bone graft, IV minocycline 6 days, oral for 7 days	Bone erosion of the humeral and scapular necks
van der Zwan et al (2005) [9]	41	M	Right humerus	IV amoxicillin for 1 week followed by 7 weeks oral amoxicillin	Complete resolution
Rehnstrom et al (2016) [3]	61	M	Left knee	Multiple treatments due to misdiagnosis, eventually IV CTX for 9 days followed by 12 months oral cefixime	Prosthesis operation
Rehnstrom et al (2016) [3]	65	M	Left 3rd MCP	Multiple treatments due to delayed diagnosis, eventually 4 months oral cefixime	Residual limitation -impaired affected joint
Gharamti et al (2019) [11]	37	M	Right 5th metatarsal	IV ceftriaxone for 1 week	Complete resolution
Roy et al (2020) [12]	55	M	L3-L4 vertebrae	IV ceftriaxone for 8 weeks	Incomplete resolution at 8 weeks post treatment
Presented case (2020)	14	F	Right humeral head	IV ceftriaxone for 9days, oral cefixime for 35 days	Residual limitation – limited range of motion

Abbreviations: PCN=penicillin, IV=intravenous, CTX=ceftriaxone, ROM=range of motion, OA=osteoarthritis, MCP=metacarpophalangeal, MTP=metatarsophalangeal, MT=metatarsal, PIP – proximal interphalangeal.  
a=selections from Shibata 2004 and prior are adapted from Shibata et al 2004 table [10].

treatment was started promptly due to suspicion of septic arthritis, our patient's delay from onset of symptoms to seeking treatment may have been a factor in her progression to osteomyelitis.

Including the current case, we were able to review a total of 19 cases of gonococcal osteomyelitis that have been reported in the literature during the antibiotic era (Table 1) [3,9–11]. Reviewed patients had a median age (range) of 25 years (14–65) with 10 female patients and 9 male patients. This is slightly different from overall gonorrhea infection statistics, which are skewed towards males [1]. The most common location of gonococcal osteomyelitis in reported cases was the joints of the hand and wrist (40 %) followed by the joints of the foot (20 %) and shoulder joint (20 %). Two patients had an affected hip (10 %) and one had an affected knee (5 %). Some patients had multiple joints affected, which can occur but is relatively rare [6]. One case occurred in the L3-L4 vertebrae with associated discitis [12]. Comorbidities were only rarely reported, however one case was HIV-1 infected [13].

Given the rare occurrence of osteomyelitis associated with DGI, its antimicrobial treatment (antibiotic agents and duration of

the treatment) is not well defined [7,14,15]. Third-generation cephalosporins with variable duration of treatment have been mostly used. Infections in smaller bones like metatarsals were successfully treated by using parenteral ceftriaxone for one week, while infections affecting long bones appeared to need longer courses in the range of 4–6 weeks of parenteral ceftriaxone [3,9,11,12]. In one case a patient with confirmed gonococcal osteomyelitis of the knee required 12 months of treatment with oral cefixime resulting in incomplete resolution [3]. Of the five long-bone and vertebral cases for which data on treatment length was available, the average parenteral antibiotic treatment duration was 21.5 days, followed by an average oral antibiotic treatment duration of 26.3 days. Due to the increasing rates of antibiotic resistance seen with gonococcal infections, the CDC currently recommends ceftriaxone and azithromycin as first line agents for treating DGI until susceptibility results become available [1,2]. Emerging resistance will continue to limit treatment options and raises the risk for progression of DGI to osteomyelitis due to delay in effective treatment [16].

Of note, more than half of reported cases (11/19, 58 %) were affected by some form of residual limitation at last follow up visit, ranging from diminished range of motion to permanent sequelae, including bony erosions and need for prosthesis (Table 1). The presented case also had residual limitations in the form of marginally restricted range of motion at the time of last follow up 6 weeks after finishing treatment.

In conclusion, at a time of increasing incidence of *N. gonorrhoeae* infection as well as increasing antimicrobial resistance clinicians should maintain a high index of suspicion for DGI with potential progression from gonococcal septic arthritis to adjacent osteomyelitis, especially in those patients with slowly resolving symptoms. To assure full recovery, early treatment along with a prolonged antibiotic treatment course and careful follow-up evaluations of clinical symptoms resolution may be needed.

### Funding

No funding was provided for this article.

### CRediT authorship contribution statement

**William Liakos:** Conceptualization, Data curation, Writing - original draft, Writing - review & editing. **Benjamin Schaffler:** Data curation, Writing - original draft, Writing - review & editing. **Sujatha Rajan:** Methodology, Supervision, Writing - review & editing. **Stefan H.F. Hagmann:** Data curation, Investigation, Methodology, Supervision, Validation, Writing - review & editing.

### Declaration of Competing Interest

The authors declared no potential conflicts of interest with respect to the research, authorship, and/or publication of this article.

### References

- [1] 2017 sexually transmitted diseases surveillance. 2018. <https://www.cdc.gov/std/stats17/natoverview.htm>.
- [2] Belkacem A, Caumes E, Ouanich J, Jarlier V, Dellion S, Cazenave B, et al. Changing patterns of disseminated gonococcal infection in France: cross-sectional data 2009–2011. *Sex Transm Infect* 2013;89:613–5, doi:<http://dx.doi.org/10.1136/sextrans-2013-051119>.
- [3] Rehnstrom M, Unemo M, Tunback P. Gonococcal osteomyelitis resulting in permanent sequelae. *Acta Derm Venereol* 2016;96:562–3, doi:<http://dx.doi.org/10.2340/00015555-2296>.
- [4] Britigan BE, Cohen MS, Sparling PF. Gonococcal infection: a model of molecular pathogenesis. *N Engl J Med* 1985;312:1683–94, doi:<http://dx.doi.org/10.1056/nejm198506273122606>.
- [5] O'Brien JP, Goldenberg DL, Rice PA. Disseminated gonococcal infection: a prospective analysis of 49 patients and a review of pathophysiology and immune mechanisms. *Med* 1983;62:395–406.
- [6] Black JR, Cohen MS. Gonococcal osteomyelitis: a case report and review of the literature. *Sex Transm Dis* 1984;11:96–9.
- [7] Bignell C, Unemo M. European guideline on the diagnosis and treatment of gonorrhoea in adults. *Int J STD AIDS* 2012;2013(24):85–92, doi:<http://dx.doi.org/10.1177/0956462412472837>.
- [8] Thakolkaran N, Shetty AK. Acute hematogenous osteomyelitis in children. *Ochsner J* 2019;19:116–22, doi:<http://dx.doi.org/10.31486/toj.18.0138>.
- [9] van der Zwan AL, Willems WJ. Gonococcal osteomyelitis of the humeral head: a case report. *J Shoulder Elb Surg* 2005;14:333–5, doi:<http://dx.doi.org/10.1016/j.jse.2004.04.017>.
- [10] Shibata Y, Kumano T, Shinoda T, Hanada H, Notomi T, Nagayama A, et al. Gonococcal osteomyelitis of the shoulder extended from gonococcal arthritis: diagnosis by a polymerase chain reaction assay. *J Shoulder Elb Surg* 2004;13:467–71, doi:<http://dx.doi.org/10.1016/j.jse.2004.01.009>.
- [11] Gharamti AA, Pinto NC, Henao-SanMartin V, Franco-Paredes C, Henao-Martinez AF. Successful treatment of gonococcal osteomyelitis with one week of intravenous antibiotic therapy. *Int J STD AIDS* 2019;30:610–2, doi:<http://dx.doi.org/10.1177/0956462418816496>.
- [12] Roy M, Ahmad S, Roy AK. Rare presentation of vertebral discitis, osteomyelitis and polyarticular septic arthritis due to disseminated *Neisseria gonorrhoea* infection. *J Community Hosp Intern Med Perspect* 2020;10:55–9, doi:<http://dx.doi.org/10.1080/20009666.2019.1710930>.
- [13] Ingram CW, Nichole B, Martinez S, Corey GR. Gonococcal osteomyelitis: case report and review of the literature. *Arch Intern Med* 1991;151:177–9, doi:<http://dx.doi.org/10.1001/archinte.1991.00400010167027>.
- [14] Bignell C, FitzGerald M. UK national guideline for the management of gonorrhoea in adults, 2011. *Int J STD AIDS* 2011;(22):541–7, doi:<http://dx.doi.org/10.1258/ijisa.2011.011267>.
- [15] Workowski KA, Bolan GA. Sexually transmitted diseases treatment guidelines, 2015. *MMWR Recomm Rep* 2015;64:1–137.
- [16] Davies SC, Fowler T, Watson J, Livermore DM, Walker D. Annual Report of the Chief Medical Officer: infection and the rise of antimicrobial resistance. *Lancet* 2013;381:1606–9, doi:[http://dx.doi.org/10.1016/s0140-6736\(13\)60604-2](http://dx.doi.org/10.1016/s0140-6736(13)60604-2).
- [17] Keiser H, Ruben FL, Wolinsky E, Kushner I. Clinical forms of gonococcal arthritis. *N Engl J Med* 1968;279:234–40, doi:<http://dx.doi.org/10.1056/nejm196808012790503>.
- [18] Magee G. Gonococcal arthritis. *JAMA* 1975;234:1320–1, doi:<http://dx.doi.org/10.1001/jama.1975.03260260024011>.
- [19] Angevine CD, Hall CB, Jacox RF. A case of gonococcal osteomyelitis: a complication of gonococcal arthritis. *Am J Dis Child* 1976;130:1013–4, doi:<http://dx.doi.org/10.1001/archpedi.1976.02120100103018>.
- [20] Gantz NM, McCormack WM, Laughlin LW, Shauffer IA, Cohen AS. Gonococcal osteomyelitis: an unusual complication of gonococcal arthritis. *JAMA* 1976;236:2431–2, doi:<http://dx.doi.org/10.1001/jama.1976.03270220051040>.
- [21] Mehta A, Wright TA. Gonococcal arthritis in pregnancy. *Can Med Assoc J* 1977;117:1190–1.
- [22] Liftik MI, Miller JW, Brown JD. Penicillin-resistant gonococcal polyarthritis. *JAMA* 1978;239:134, doi:<http://dx.doi.org/10.1001/jama.239.2.134>.
- [23] Rinaldi RZ, Harrison WO, FAN PT. Penicillin-resistant gonococcal arthritis: a report of four cases. *Ann Intern Med* 1982;97:43–5, doi:<http://dx.doi.org/10.7326/0003-4819-97-1-43>.
- [24] Tindall EA, Regan-Smith MG. Gonococcal osteomyelitis complicating septic arthritis. *JAMA* 1983;250:2671–3, doi:<http://dx.doi.org/10.1001/jama.1983.03340190073037>.
- [25] Hurley PT, Salata RA, Hayden FG. Chronic gonococcal osteomyelitis. *South Med J* 1987;80:264–6, doi:<http://dx.doi.org/10.1097/00007611-198702000-00034>.
- [26] Duvauchelle DA, Pien FD. Gonococcal osteomyelitis: report of a penicillin-resistant strain. *Orthopedics* 1994;17:719–21.