

# **Functional Results Following Treatment of Vestibular Schwannomas: Comparative Study between Surgery and Radiation**

**Inaugural-Dissertation  
zur Erlangung des Doktorgrades der Medizin**

**der Medizinischen Fakultät  
der Eberhard Karls Universität  
zu Tübingen**

**vorgelegt von**

**Rizk, Ahmed Rizk Abdel Khalek**

**2015**

Dekan:

1. Berichterstatter:

2. Berichterstatter:

Professor Dr. I.B. Autenrieth

Professor Dr. M. Tatagiba

Professor Dr. M. Neumann

## **Index**

INDEX	3
ABBREVIATION LIST	4
FIGURE LIST	5
TABLE LIST	6
INTRODUCTION	8
OBJECTIVES	25
PATIENTS AND METHODS	26
RESULTS	31
DISCUSSION	57
CONCLUSIONS	75
REFERENCE LIST	78
ABSTRACT	92
ZUSAMMENFASSUNG	94
ACKNOWLEDGEMENT	97
CURRICULUM VITAE	99

## **Abbreviation List**

AEP	Auditory evoked potential
CPA	Cerebellopontine angle
CSF	Cerebrospinal fluid
CT	Computed tomography
EMG	Electromyography
fMEPs	Facial nerve motor evoked potentials
GR	Gardner-Robertson
HB	House-Brackmann
IAC	Internal auditory canal
IOM	Intraoperative monitoring
LINAC	Linear accelerator
MRI	Magnetic resonance imaging
MS	Microsurgery
PFO	Patent foramen oval
RS	Radiosurgery
Retrosig.	Retrosigmoid Approach
SSEPs	Somato-sensory evoked potentials
Translab.	Translabrynthine Approach
VPS	Ventriculo-peritoneal shunt
VS	Vestibular schwannoma

## **Figure List**

<b>Figure No.</b>	<b>Title</b>	<b>Page No.</b>
1	Gamma Knife Model C, the 4 mm collimator helmet and the automatic positioning system just before fixation of the patient's head	19
2	Tumor extension in both groups (presented in percentages)	25
3	Tumor control in the radiosurgery group	29
4	Sequential follow-up MR images showing transient early postradiosurgery tumor swelling of right Class T3a VS	30
5	Magnetic resonance imaging preoperative (left) and 17 months postoperative (right) of T4a VS showing complete tumor removal with no recurrence	32
6	Hearing preservation in both groups	35
7	Facial function preservation at last follow-up	37
8	Dizziness results at the last follow-up in both groups	39
9	Tinnitus results at the last follow-up in both groups	40
10	Trigeminal results at the last follow-up in both groups	41

## **Table List**

<b>Table No.</b>	<b>Title</b>	<b>Page No.</b>
1	Checklist on cohort studies comparing microsurgery (MS) and radiosurgery (RS) for solitary vestibular schwannoma	27
2	House-Brackmann facial nerve grading scale	21
3	Gardner-Robertson grading of hearing function	22
4	Radiosurgery parameters	23
5	Demographic data in both groups	25
6	Symptoms and signs before treatment	26
7	Facial nerve function before treatment	26
8	Hearing function before treatment	27
9	Tumor control in the radiosurgery group	29
10	Tumor control at the last follow up in relation to tumor extension	31
11	Cases of incomplete tumor removal (surgery group)	32
12	Hearing after treatment (at last follow-up) in cases of serviceable hearing before treatment	34
13	Hearing preservation rate (GR grade I or II) in patients having functional hearing before treatment	34

14	Facial function at last follow up	36
15	Facial nerve function preservation rate (HB grade I or II) at the last follow up	36
16	results of dizziness, tinnitus, and trigeminal nerve function after treatment in both groups	38

## **Introduction**

A vestibular schwannoma (VS) is a benign tumor that arises from the Schwann cells of either the inferior (Jacob et al. 2007; Khrais et al. 2008) or superior (Clemis et al. 1986) vestibular nerve, at the neuroglial–neurilemmal junction (Obersteiner-Redlich zone) within the internal auditory canal (Thakur et al. 2012).

### **Epidemiology:**

Vestibular schwannomas make up 6-8% of all intracranial tumors and 70-80% of all cerebellopontine angle (CPA) tumors (Ojemann 1996). The annual incidence of VSs lies between 0.5 and 1.7 cases per 100,000, and these rates are increasing with the widespread use of Magnetic resonance imaging (MRI), which allows for higher rates of detection (Myrseth et al. 2007). In a recent study, Gal et al. (2010) analyzed the database of the Surveillance, Epidemiology, and End Results program and reported that the mean age of VS detection in the United States is 53.1 years, and that the majority of lesions (84%) occur in Caucasians. In teenagers,



VS diagnosis is rare, and the tumor is usually associated with neurofibromatosis type II (NF2) (Mirzayan et al. 2007).

### **Pathogenesis:**

Vestibular schwannomas occur in two different patient groups; unilateral tumors occur sporadically in those with no family history and are not associated with other central nervous system tumors or abnormalities, whereas bilateral tumors occur in patients with NF2. In the latter, a family history usually exists, although occasionally a spontaneous mutation may occur. In some patients with NF2, other intracranial or spinal tumors, or both, do occur. Patients with NF2 often develop bilateral vestibular schwannomas, which is sufficient to make the diagnosis of the disease. Approximately 5 to 20% of patients with solitary intracranial schwannomas have NF2 (Ojemann 1996).

NF2 results from germ line or somatic mutation of a tumor suppressor gene (NF2 gene) present on chromosome 22. The NF2 gene codes for a protein named separately by the two groups who identified it in 1993; that is, schwannomin or merlin (Ruttledge and Rouleau 2005).

## **Pathology:**

Macroscopically, VSs are lobular, well-encapsulated, solid tumors. Consistency varies from firm to very soft, and adherence to surrounding structures is also quite variable (Sampath and Long 2004). The incidence of cystic VS in various studies is ranging from 7.6 to 24% of all VSs. Cystic VSs can be either large single cystic region surrounded by a relatively small amount of peripheral tissue, single cystic region in a large solid tumor, or multicystic tumor (El-Bahy et al. 2007). Microscopically, VSs consists of two types of tissue, Antoni A and Antoni B fibers. Antoni B fibers are loose, semipalisading arrangements of Schwann cells, whereas the Antoni A fibers are denser, presenting more nuclei and a firmer cytoplasm (Sampath and Long 2004).

Vestibular schwannomas usually grow slowly or remain unchanged for years or growth may progress in a stepwise pattern (Myrseth et al. 2007). Although there is variation in the literature, the results of prospective studies could be interpreted as suggesting that tumor growth is likely to be less than 2–2.5 mm/year in the majority of patients. Factors that may have prognostic implications for VS growth patterns include:

significant growth (>2 mm/year), extension into the CPA, and tumor diameter >20 mm (Thakur et al. 2012).

### **Clinical Presentation:**

The clinical presentation of VS may vary broadly depending upon tumor extension; whereas intracanalicular VS tumors often present with high-frequency sensorineural hearing loss, tinnitus, vertigo, and/or dysequilibrium, extracanalicular tumors may also present with headache, facial hypoesthesia, facial weakness, ataxia, lower cranial nerve damage, or hydrocephalus (Moffat et al. 1993).

Another factor affecting clinical presentation is the site of origin of the tumor. Hearing is significantly better preserved in patients affected by medially-arising VSs than in patients with laterally-arising tumors (Tatagiba and Acioly 2008b). Furthermore, tumors that obliterate the fundus of the internal auditory canal (IAC) cause greater hearing loss than tumors that do not reach it (Somers et al. 2001).

### **Radiological Findings:**

Magnetic resonance imaging (MRI) is now the gold standard for vestibular schwannoma diagnosis. Tumors as

small as 2–3 mm may be detected using MRI (Tatagiba and Acioly 2008a). Most VSs have an intracanalicular component and often result in widening of the IAC. However, in a minority of cases (~20%), they are purely extracanalicular, only abutting the IAC (Yamakami et al. 2002). VSs are usually hyperintense in T2WI and slightly hypointense in T1WI. They may contain cystic areas and usually show intense contrast enhancement. Heterogeneous enhancement, cystic degeneration and hemorrhagic changes occur mostly in large tumors (Mulkena 1993).

Following the Hannover grading system, tumor extension is classified as follows: T1, purely intrameatal; T2, intra- and extrameatal; T3a, filling the cerebellopontine cistern; T3b, reaching the brainstem; T4a, compressing the brainstem; and T4b, severely dislocating the brainstem and compressing the fourth ventricle (Samii and Matthies 1997a).

Computed tomography (CT) of the brain can help identify the IAC changes (expansion or erosion) that usually occur with VS. CT is also helpful for planning surgery, as it allows one to identify the anatomy of the vestibulocochlear system, the position of the jugular bulb, and pneumatization of the temporal bone (Silk et al. 2009).

The second most common type of tumor occurring in the cerebellopontine angle (CPA) is meningioma, which can be differentiated from a vestibular schwannomas by its broadly based dural attachment, a normal (not enlarged) IAC, calcification, and bony hypertrophy that occasionally narrows the IAC. Other tumors in the CPA include epidermoid, metastasis, ependymoma, and schwannomas arising from other cranial nerves, such as trigeminal schwannomas and lower cranial nerve schwannomas. However, these tumors usually lack the characteristic radiological findings of VSs, especially the changes observed in the IAC (Tatagiba and Acioly 2008a).

### **Treatment:**

Three treatment options are currently available to VS patients: conservative, surgical, or radiosurgical. The conservative treatment may be chosen for small intracanalicular tumors, especially in elderly patients and in cases where the tumor shows no significant growth (<2mm/year) within the first year, as monitored with MRI (Flint et al. 2005).

As a matter of fact, tumor size is a crucial factor when choosing the best treatment option, as it is also a major

predictor of treatment results. Large VSs represent a challenge to both surgical and radiosurgical treatment options. Although most neurologists and neurosurgeons would agree that large (>3cm) tumors are best treated surgically, hearing and facial nerve preservation following surgery are greatest when the tumor is small or medium-sized (Doherty and Friedman 2006; Arthurs et al. 2011).

### Radiosurgery


In radiosurgery, ionizing radiation beams are stereotactically focused on an intra-cranial target volume, which induces biological arrest or destructive effects of the target area with minimal irradiation of the surrounding tissues. Radiosurgery can be performed with photon devices (such as the Gamma Knife and modified linear accelerators, LINAC) or with proton- and heavy-ion charged particles generated by a cyclotron or synchrotron (Pellet et al. 2003).

Relative to LINAC, Gamma Knife radiosurgery provides rapid treatment time per isocenter, and allows for simple treatment planning and relatively better field shaping (Chang et al. 2004). Additionally, the model C Gamma Knife unit (*Figure 1*) has an automatic positioning system that provides robotic control of stereotactic coordinate localization

in order to facilitate multiple-isocenter radiosurgery (Witham and Kondziolka 2004).

Stereotactic radiosurgery for the treatment of VS introduces the risk of radiation toxicity to adjacent neurologic structures. Therefore, this treatment option represents a functional threat to hearing function, balance and the integrity of the facial nerve. Preservation of cochlear and facial nerve function is the main concern during radiosurgical dose planning for VS. Preserving brainstem function is an additional concern in the case of moderate-sized and large tumors. A combination of small beam diameter isocenters (4- and 8-mm collimators) is usually used during radiosurgery for VS. Rarely, a 14-mm collimator is used for larger tumors. Success depends on high conformity to the tumor margin (Suh and Macklis 2004).

Better hearing preservation and less trigeminal and facial neuropathy have been observed after a reduction of the prescribed radiation doses. Currently, 13 Gy is recommended at the tumor margin, as this dose has been associated with fewer complications (Suh and Macklis 2004).



**Figure 1:** *Gamma Knife Model C, the 4 mm collimator helmet and the automatic positioning system just before fixation of the patient's head (Pellet et al. 2003)*

Adverse effects of radiation are usually observed 6-18 months following radiosurgery, especially in cases where the tumor is large and the marginal dose is high. A temporary prescription of corticosteroids is usually sufficient to counteract mild to moderate symptoms associated with radiation exposure; however, additional surgery may be required to address more severe adverse effects, such as neurological deterioration (Lee et al. 2010).



Transient tumor swelling may occasionally occur following radiosurgery, which makes it difficult to adequately assess treatment outcome. However, if the tumor shows central loss of contrast enhancement, this usually indicates a positive response to treatment (Lee et al. 2010).

If radiosurgery fails and the tumor continues to grow, tumor removal is more difficult and at least one study has shown that patient outcomes are poor compared to those of patients who did not undergo radiosurgery (Pollock 2008).

A recent meta-analysis of studies evaluating the efficacy of Gamma Knife radiosurgery treatment of VS reported the following complication rates: trigeminal neuropathy (11-16%), facial neuropathy (4-19%), and hydrocephalus (2-3%) (Arthurs et al. 2011).

### Microsurgery

Microsurgery for VS can be performed using retrosigmoid, middle fossa, or translabyrinthine approaches. The retrosigmoid approach can be used for the removal of small as well as large vestibular schwannomas; in addition, it allows for hearing preservation surgery (Sampath and Long 2004). Complete tumor removal is usually possible with the

retrosigmoid approach, and the endoscope can be used to remove the portion of the tumor extending laterally into the IAC (Doherty and Friedman 2006).

Surgical removal of VS with the retrosigmoid approach can be performed with the patient in a supine, park-bench, or semi-sitting position. The semi-sitting position has the advantage of spontaneous drainage of the cerebrospinal fluid (CSF) and blood, which provides a clean surgical field, thereby reducing the dissection time and reducing the risk of damage to cranial nerves. Possible complications associated with the semi-sitting position may be minimized by doing the following: monitoring of somato-sensory evoked potentials (SSEPs) during patient positioning, performing intraoperative trans-esophageal echocardiography, and applying a central venous catheter with the tip positioned close to the superior vena cava-right atrium junction, to allow for premature detection of air embolisms (Porter et al. 1999). Even patients with a patent foramen oval (PFO) can be operated safely in the semi-sitting position under standardized anaesthesiological and neurosurgical protocols (Feigel et al. 2014).

Routine use of intraoperative auditory and facial nerve monitoring have been shown to result in increased rates of

hearing and facial nerve preservation. The auditory evoked potential (AEP) is the most widely used method for monitoring auditory function intraoperatively. Intraoperative facial nerve monitoring can be performed using direct electrical stimulation, continuous electromyography (EMG), and facial nerve motor evoked potentials (fMEPs) (Tatagiba and Acioly 2008b).

Although total tumor removal should be the aim in VS surgery, near-total removal is also accepted when a thin layer of tumor is intentionally left attached to one or more nerves or to the brainstem surface in an attempt to preserve neurological function. Long-term rates of tumor control do not differ significantly between cases of gross-total resection and cases in which a small amount of tumor is left behind (Sughrue et al. 2011).

An enlargement of the residual tumor or the IAC or CPA cisternal space observed during follow-up imaging may indicate tumor recurrence. Recurrent tumors should be treated with radiosurgery whenever possible, as repeat surgery is more difficult; repeat surgery becomes necessary in the case of large recurrent tumors or when radiosurgery has failed (Sughrue et al. 2011).

### Studies comparing Microsurgery and Radiosurgery

To the best of our knowledge, there are currently no randomized clinical trials on vestibular schwannomas (VS). Only two prospective controlled studies with predefined inclusion criteria compared microsurgery (MS) to radiosurgery (RS) for the treatment of VS (Pollock et al. 2006 and Myrseth et al. 2009). There are also four retrospective cohort studies with a matched control group, all comparing microsurgery with radiosurgery (Pollock et al. 1995, Karpinos et al. 2002, Régis et al. 2002, Myrseth et al. 2005). The patient selection criteria and results of these studies are summarized in *Table 1*.

Four of these studies (Pollock et al. 2006 and Myrseth et al. 2009, Pollock et al. 1995, Myrseth et al. 2005) included only tumors smaller than 30 mm. The study by Karpinos et al. included large and small tumors as well as recurrent tumors. Régis et al. classified tumor size based on the Koos grading system and included only stage II and III in the comparison.

Although results following microsurgery may differ based on the surgical approach used, these comparative studies included different surgical approaches in their microsurgery groups. In addition, some of these studies did not mention the type of intraoperative neurophysiological monitoring used

(Pollock et al. 2006), while others did not perform intraoperative auditory monitoring (Régis et al. 2002, Myrseth et al. 2005, Myrseth et al. 2009).

Due to a lack of long-term follow-ups, some of these studies did not report tumor control outcomes (Pollock et al. 2006, Myrseth et al. 2009). In their study, Régis et al. commented on treatment failure in the context of retreatment rate, and their results showed a failure rate of 3% in the radiosurgery group (with follow-up of 3 years) and 5% in the surgery group (follow-up of 5 years).

The relatively small patient groups and short follow-up periods are potential weaknesses of some of these comparison studies (Wolbers et al. 2013).

In the current manuscript, we present a retrospective study comparing long-term results after microsurgery and radiosurgery for vestibular schwannomas. The tumors were classified according to the Hannover Classification system, and we compared comparable tumor extension grades in microsurgery and radiosurgery. Our study included 269 patients in the microsurgery group and 427 patients in the radiosurgery group, and the mean follow-up time was 16.4 and 42.4 months, respectively. We also present the tumor control

results for a subgroup of the radiosurgery group who received follow-up of more than 2 years. All patients in both groups received the same standards of treatment. In the microsurgery group, all patients received the retrosigmoid approach in the semi-sitting position and IOM of the facial and auditory nerves; in the radiosurgery group, on the other hand, all patients received Gamma Knife radiosurgery with mean tumor margin dose of 13 Gy and mean maximum dose of 21 Gy.

**Table 1:** Checklist on cohort studies comparing microsurgery (MS) and radiosurgery (RS) for solitary vestibular schwannoma

<b>Authors &amp; Publication year</b>	<b>Pollock 2006</b>	<b>Myrseth 2009</b>	<b>Pollock 1995</b>	<b>Myrseth 2005</b>	<b>Regis 2002</b>	<b>Kaprinis 2000</b>
<b>Study Design</b>	Prospecti- ve	Prospecti-- ve	Retrospec- tive	Retrospec- tive	Retrospec- tive	Retrospecti- ve
<b>No. of Patients</b> <b>MS</b> <b>RS</b>	36 46	28 60	40 47	86 103	110 97	23 49
<b>Inclusion Criteria</b> <b>Recurrent Size</b>	No < 3 cm	No < 3 cm	No < 3cm	No < 3 cm	No Koos stage II, III	Yes All sizes
<b>Follow-up (mean in months)</b>	42	24	36	69	36	MS 24 RS 48
<b>Surgery Approach</b>	Retrosig. (25) Translab. (9) Middle fossa (2)	Retrosig. (27) Translab. (1)	Translab. Retrosig. (number not indicated)	Translab. .Retrosig. (number not indicated)	Translab. (85%) Middle Fossa (15%)	Translab. (15) Retrosig. (7) Middle Fossa(1)
<i>IOM:</i> <i>Facial</i>	Not indicated	Used	Not indicated	Used	Not indicated	Used
<i>Hearing</i>	Not indicated	Not used	Not indicated	Not used	Not used	Used

<b>Radiosurgery</b>	Gamma Knife	Gamma Knife	Gamma Knife	Gamma Knife	Gamma Knife	Gamma Knife
<i>Marginal dose</i>	Mean 12 Gy	Not indicated	Not indicated	10-12 Gy	12-14 Gy	14.5 Gy
<b>Facial preservation (%)</b>						
<i>MS</i>	83	82	78	80	67	64.7
<i>RS</i>	98	100	91	95	100	93.9
<b>Hearing preservation (%)</b>						
<i>MS</i>	5	0	14	5	36	40
<i>RS</i>	63	68	75	32	50	44
<b>Tumor Control</b>	Not included	Not included	Not included	94.2% (MS) 89.2% (RS)	Retreatment MS (9%) RS (3%)	100% (MS) 91% (RS)
<b>Vertigo or Imbalance</b>	Radiosur. better	No diff.	No diff.	Not included	Radiosur. better	No diff.
<b>Tinnitus</b>	No diff.	No diff.	No diff.	Not included	No diff.	26.5% worsening (RS) 0% worsening (MS)



## **Objectives**

In the present study, we aimed to compare the long-term treatment results of patients harboring VSs who had been previously submitted to either radiosurgical or microsurgical treatment. We paid special attention to i) resection radicality based on volumetric studies, ii) tumor recurrence, iii) preservation of facial nerve function, iv) hearing preservation, v) preservation of trigeminal nerve function, and vi) improvement in tinnitus and dizziness.

## **Patients and Methods**

We conducted a retrospective study with two groups of patients who were treated for vestibular schwannoma (VS). Patients in the first group were treated with surgery between 2004 and 2010 in the Neurosurgery Department of Tübingen University (Tübingen, Germany), and patients in the second group were treated with radiosurgery between 1997 and 2010 at the Krefeld Gamma Knife Center in Krefeld, Germany.

### **Inclusion criteria**

Inclusion criteria were as follows:

1. no previous treatment, either surgical or radiosurgical
2. absence of neurofibromatosis

### **Exclusion criteria**

- previously treated patients
- Neurofibromatosis type 2 (NFII)
- Follow-up period shorter than 6 months
- The following data were obtained from all patients:

- Symptomatology (prior to treatment).
- Neurological examination, with special emphasis on cranial nerves V-XII.
- Clinical assessment of facial nerve function using the House-Brackmann grading scale (*Table 2*).
- Audiological evaluation using pure-tone audiogram; pure tone average and speech discrimination percentage was assessed using the Gardner-Robertson grading scale (*Table 3*).
- Outcome after treatment, including:
  - Tumor control
  - Facial nerve function (House-Brackmann scale)
  - Hearing function (Gardner-Robertson scale)
  - New symptoms
  - Other complications

#### Surgical technique

Microsurgical resection was performed by single neurosurgeon (Prof. M. Tatagiba) using the retrosigmoid approach in the semi-sitting position. Intraoperative neurophysiological monitoring of hearing function (Brainstem

auditory evoked potential) and facial function (facial motor evoked potential “fMEP”, direct nerve stimulation and free running electromyography “EMG”) were used in all cases.

**Table 2:** House-Brackmann facial nerve grading scale (House and Brackmann 1985)

<b>Grade</b>	<b>Description</b>
<b>I</b>	Normal facial function in all muscles
<b>II</b>	Slight weakness noticeable only on close inspection, complete eye closure
<b>III</b>	Obvious but not disfiguring difference between two sides; forehead shows slight-to-moderate movement; complete eye closure with effort
<b>IV</b>	Obvious weakness, disfiguring asymmetry; no forehead movement; incomplete eye closure
<b>V</b>	Barely perceptible motion
<b>VI</b>	Total paralysis

### **Radiosurgical technique**

Radiosurgery was performed with a 201-source cobalt-60 Leksell Model U Gamma Knife (Elekta Instruments). MRI high-resolution, T2 and gadolinium-enhanced, T1-weighted images were obtained to localize the area of interest. Dose planning enclosed the tumor contour within 65% isodose line

in most of the cases and the average marginal dose was 13 Gy (Table 4).

**Table 3:** Gardner-Robertson grading of hearing function (Gardner and Robertson 1988)

<b>Grade</b>	<b>Description</b>	<b>Pure tone average (dB)</b>	<b>Speech discrimination score (%)</b>
<b>I</b>	Good to excellent	0-30	70-100
<b>II</b>	Serviceable	31-50	50-69
<b>III</b>	Non-serviceable	51-90	5-49
<b>IV</b>	Poor	91-100	1-4
<b>V</b>	None	Not testable	0

**Table 4:** Radiosurgery parameters

<b>Radiation treatment parameter</b>	<b>Range</b>	<b>Average</b>
<b>Central tumor dose</b>	20-28.3 Gy	21 Gy
<b>Tumor margin dose</b>	12-13 Gy	13 Gy
<b>Isocenter No.</b>	3-50	23.3
<b>Isodose line</b>	50-65%	63%

## **Statistical analysis**

Analyses were conducted using SPSS software (Version 17; SPSS, Inc., Chocago, IL). We generated a histogram to assess data distribution. Continuous variables are expressed as mean +/- standard deviation (SD), and were analyzed using paired or unpaired Student *t* tests or ANOVA. All statistical tests were two-tailed. The association between variables was analyzed using the Pearson correlation coefficient. Nonparametric equivalents, i.e. the Mann-Whitney U-test, Wilcoxon-signed ranks test and Spearmann ranked correlation coefficient were used for nonparametric data. Statistical significance was set at  $p < 0.05$ .

## Results

### Patient data

The surgery group included 269 cases (122 males and 147 females) ranging in age from 20.9 to 75.2 years (mean age = 47.8 years). The radiosurgery group, on the other hand, included 427 cases (168 males and 259 females) ranging in age from 20 to 85 years (mean age = 58.1 years).

Tumor extension in the two groups, as assessed with the Hannover grading scale, is shown in *Table 5, Figure 2*.

Groups did not differ from each other in terms of gender ( $p=0.08$ ), facial nerve function ( $p=0.112$ ) or incidence of tinnitus ( $p=0.076$ ). Tumor size, however, was significantly larger in the surgery group, which reflects the criteria used for treatment indication ( $p<0.001$ ). Hearing ( $p<0.01$ ), vestibular nerve ( $p<0.01$ ) and trigeminal nerve functions ( $p<0.001$ ) were also significantly more compromised in the surgery group (as a direct consequence of tumor size).

### Clinical complaints

In the surgery group, 209 patients (77.6%) reported tinnitus, 182 patients (67.7%) reported dizziness, and 36

patients (13.4%) reported facial hypoesthesia before surgery. In the radiosurgery group, on the other hand, 238 patients (55.7%) reported tinnitus, 307 patients (71.9%) reported dizziness, and 45 patients (10.5%) reported facial hypoesthesia before treatment (*Table 6*).

#### *Facial nerve function before treatment*

Twenty-one patients (7.8%) in the surgery group had compromised facial nerve function prior to treatment, while the same was true for 15 patients (3.5%) in the radiosurgery group. *Table 7* shows motor facial function in both groups, as assessed with the House-Brackmann (HB) grading scale. Facial nerve function before treatment did not differ significantly between both treatment groups (P value = 0.112, Spearman's rho correlation).

#### *Hearing function before treatment*

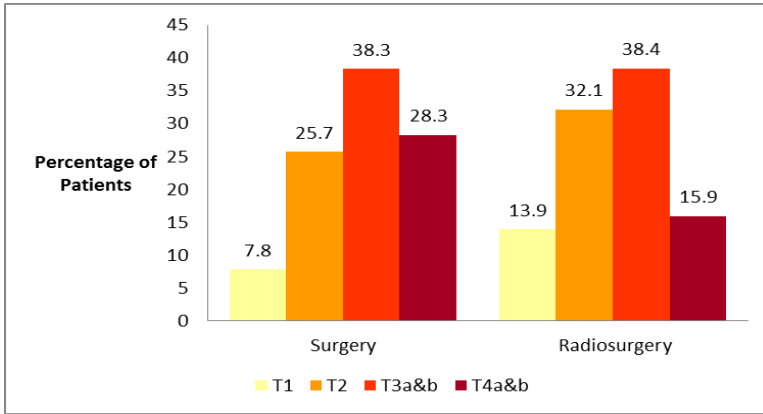
One-hundred fifty five patients (57.6%) in the surgery group and 226 patients (52.9%) in the radiosurgery group had non-functional hearing (higher than grade II on the Gardner-Robertson scale) before treatment. *Table 8* shows the Gardner-Robertson hearing scores before treatment for both groups.



Hearing was significantly compromised in the surgery group (P value < 0.01, Spearman's rho correlation).

**Table 5:** Demographic data in both groups

<b>Variable</b>	<b>Surgery group</b>	<b>Radiosurgery group</b>	<b>P Value</b>
<b>Total number</b>	269	427	
<b>Age in years</b>			
<b>Range</b>	20.9 - 75.2	20 - 85	
<b>Mean</b>	47.8	58.1	0.216
<b>Sex</b>			0.08
<b>Female</b>	147	259	
<b>Male</b>	122	168	
<b>Tumor Extension</b>			<0.001
<b>T1</b>	21	58	
<b>T2</b>	69	137	
<b>T3a&amp;b</b>	103	164	
<b>T4a&amp;b</b>	76	68	



**Figure 2:** Tumor extension in both groups (presented in percentages)

**Table 6:** Symptoms and signs before treatment

Finding before Treatment	Surgery Group					Radiosurgery Group					P-Value
	T1	T2	T3a &b	T4a &b	Total	T1	T2	T3a &b	T4a &b	Total	
<b>Dizziness</b>	14	43	67	58	<b>182</b>	28	79	93	38	<b>238</b>	<b>&lt;0.01</b>
<b>Tinnitus</b>	16	52	76	65	<b>209</b>	43	101	118	45	<b>307</b>	<b>0.076</b>
<b>Facial Hypothesis</b>	2	4	6	24	<b>36</b>	1	6	15	23	<b>45</b>	<b>&lt;0.001</b>

**Table 7:** Facial nerve function before treatment

House- Brackm ann grade	Surgery Group					Radiosurgery Group					P- Val ue
	T 1	T 2	T3a &b	T4a &b	Tot al	T 1	T 2	T3a &b	T4a &b	Tot al	
<b>I</b>	2 1	6 7	97	64	<b>248</b>	5 8	13 5	157	62	<b>412</b>	<b>0.11 2</b>
<b>II</b>	0	2	6	12	<b>20</b>	0	0	2	1	<b>3</b>	
<b>III</b>	0	0	1	0	<b>1</b>	0	2	1	2	<b>5</b>	
<b>VI</b>	0	0	0	0	<b>0</b>	0	0	2	1	<b>3</b>	
<b>V</b>	0	0	0	0	<b>0</b>	0	0	2	2	<b>4</b>	
<b>Total</b>	2 1	6 9	103	76	<b>269</b>	5 8	13 7	164	68	<b>427</b>	

**Table 8:** Hearing function before treatment

Gardner Robert son	Surgery Group					Radiosurgery Group					P Val ue
	T 1	T 2	T3a &b	T4a &b	Tot al	T 1	T2	T3a &b	T4a &b	Tot al	
<b>I</b>	5	6	8	1	<b>20</b>	1 4	21	26	8	<b>69</b>	<b>&lt;0.0 1</b>
<b>II</b>	1 0	2 8	38	18	<b>94</b>	2 0	49	48	15	<b>132</b>	
<b>III</b>	6	3 0	49	38	<b>123</b>	2 1	54	68	20	<b>163</b>	
<b>VI</b>	0	2	5	9	<b>16</b>	2	7	15	17	<b>41</b>	
<b>V</b>	0	3	3	10	<b>16</b>	1	6	7	8	<b>22</b>	
<b>Total</b>	2 1	6 9	103	76	<b>269</b>	5 8	13 7	164	68	<b>427</b>	

### Treatment results

The follow-up period for the surgery group ranged from 6 to 74 months (mean = 16.4 months), while for the radiosurgery group, it ranged from 7 to 144 months (mean = 42.4 months).

### Tumor control

Tumor volume in the radiosurgery group was measured at follow-up and compared to tumor volume before treatment; it was then classified into 3 categories: shrinkage, expansion or stable. Shrinkage was defined as a greater than 10% decrease in tumor volume, tumor expansion as a greater than 10% increase in tumor volume, and ‘stable’ was when a tumor increased or decreased in size by less than 10% relative to its pre-treatment volume.

Tumor volumetric assessment 6 months after treatment revealed tumor expansion in 148 patients (34.7%), stable tumor size in 177 patients (41.5%), and tumor shrinkage in 102 patients (23.9%). Three patients (0.7%) required urgent intervention in the form of a ventriculo-peritoneal shunt (VPS) as a result of tumor expansion and the development of hydrocephalus after radiosurgery. VPS insertion was performed 3 weeks after radiosurgery in one case, and 6 and 18 months after radiosurgery in the other 2 cases.

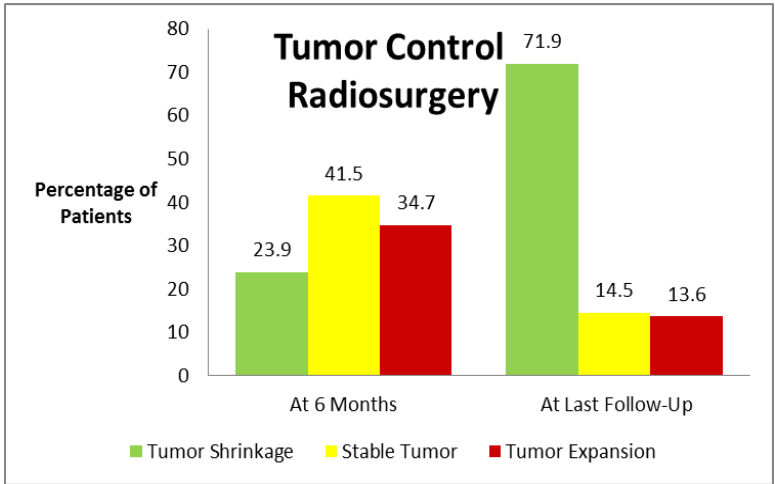
At the time of the last follow-up, however, 58 patients (13.6%) had experienced tumor expansion, 62 patients (14.5%) had tumors that remained stable, and 307 patients (71.9%) had experienced tumor shrinkage (*Table 9, Figures 3 and 4*).

The follow-up period in the radiosurgery group ranged between 7 and 144 months (mean = 42.4 months). There was a significant correlation between tumor control and time post-treatment (P value < 0.001, Pearson Correlation), so that the mean follow-up period in cases of tumor shrinkage was 49.2 months; however, in cases of stable tumors and tumor swelling, the mean follow-up period was 19 and 20.8 months, respectively.

No significant correlation was found between tumor control and tumor extension (Table 10).

**Table 9:** Tumor control in the radiosurgery group

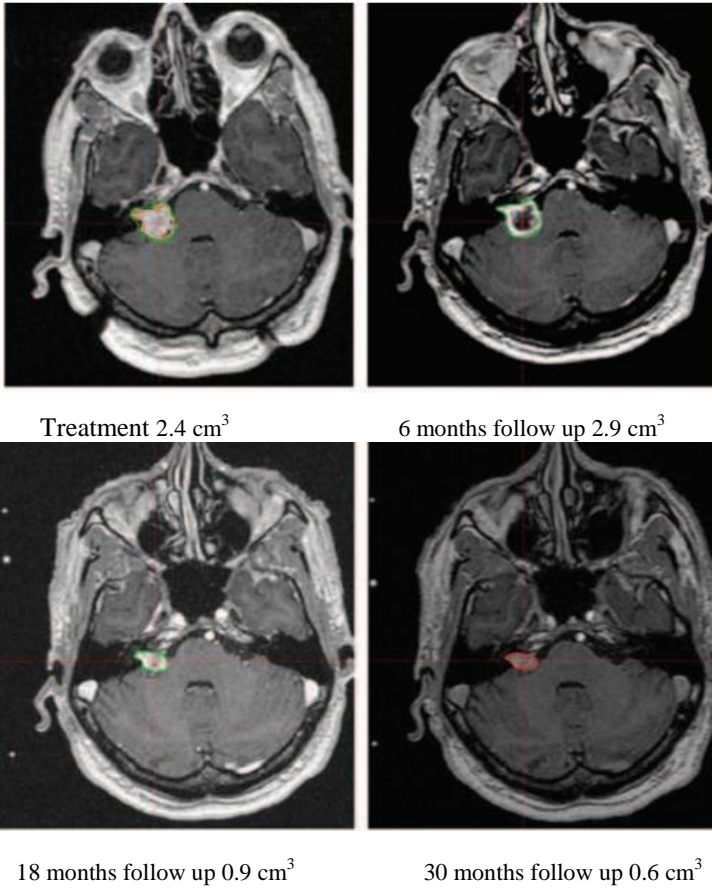
		Tumor control at last follow-up			Total
		Shrinkage	Stable	Expansion	
Tumor control at 6 months	Shrinkage	96	2	4	102
	Stable	129	37	11	177
	Expansion	82	23	43	148
Total		307	62	58	427



**Figure 3:** Tumor control in the radiosurgery group

**Table 10:** Tumor control at the last follow up in relation to tumor extension

	T1	T2	T3a&b	T4a&b
Shrinkage	41 (70.7%)	95 (69.3%)	122 (74.4%)	49 (72.1%)
Stable	11 (19%)	18 (13.1%)	20 (12.2%)	13 (19.1%)
Expansion	6 (10.3%)	24 (17.5%)	22 (13.4%)	6 (8.8%)
Total	58	137	164	68

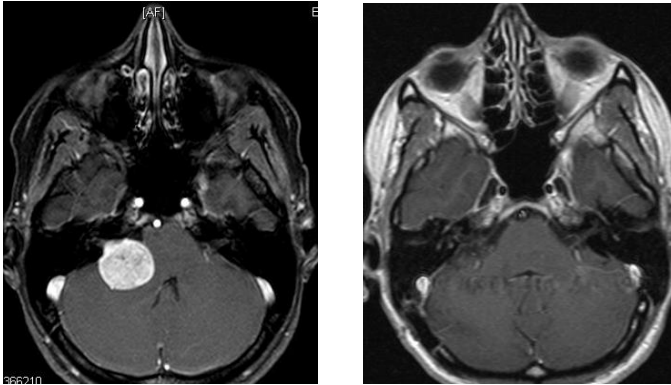


**Figure 4:** Sequential follow-up MR images showing transient early postradiosurgery tumor swelling of right Class T3a VS



Additionally, we were able to obtain long-term results for 339 patients who were followed for more than 2 years. From this group, 253 patients (74.6%) displayed tumor shrinkage, 42 patients (12.4%) had tumors that remained stable, and 44 patients (13%) experienced tumor swelling.

In the surgery group, total tumor removal was performed in 263 patients; in the remaining 6 cases (*Table 11*); a small part of the tumor was left in order to preserve the integrity of the facial nerve. After a mean follow up of 16.4 months, excellent tumor control with no tumor recurrence or increase in size of the residual tumor occurred in 268 patients (99.6%). In one patient (0.37%), tumor size had increased at follow-up, and then the residual tumor was treated by radiosurgery.



**Figure 5:** Magnetic resonance imaging preoperative (left) and 17 months postoperative (right) of T4a VS showing complete tumor removal with no recurrence

**Table 11:** Cases of incomplete tumor removal (surgery group)

Case Nr.	Tumor Extension	Patient Age at treatment (years)	Period of follow-up (months)	Increased residual size
1	T2	49	17	No
2	T3b	55	15	No
3	T3b	51	17	No
4	T4a	49	35	No
5	T4a	35	74	No
6	T4a	75	40	Increased

### Results related to the hearing function

In the surgery group, 114 patients (42.4%) had preoperative functional hearing (Gardner-Robertson grades I or II), from these patients 67 patients (58.8%) had functional hearing at the last follow-up. Hearing preservation was found to be significantly correlated with tumor extension in the surgery group (P value < 0.001, Spearman's rho correlation) (*Table 12, 13*).

In the radiosurgery group, 201 patients (47.1%) had serviceable hearing before treatment. Of these, 132 patients (65.7%) had functional hearing at the last follow-up. As was seen in the surgery group, hearing preservation was significantly correlated with tumor extension in the radiosurgery group (P value = 0.006, Spearman's rho correlation) (*Table 12, 13*).

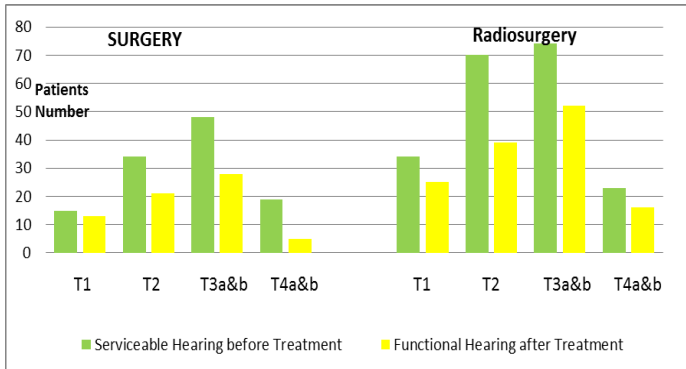
Importantly, 2 patients (1.1%) in the surgery group and 7 patients (2.5%) in the radiosurgery group had functional hearing after treatment, even though they did not have functional hearing before treatment.

At the time of the last follow-up, hearing was found to be significantly better-preserved in the radiosurgery group (P

value < 0.001, Mann-Whitney). As shown in table 13, the results hearing preservation in small tumors (Class T1, T2 and T3) were comparable between surgery and radiosurgery.

**Table 12:** Hearing after treatment (at last follow-up) in cases of serviceable hearing before treatment

<b>Gardner Robertson</b>	<b>Surgery Group</b>					<b>Radiosurgery Group</b>				
	T 1	T 2	T3a& b	T4a& b	<b>Tota l</b>	T 1	T 2	T3a& b	T4a& b	<b>Tota l</b>
<b>I</b>	3	2	1	0	<b>6</b>	1 2	1 2	23	8	<b>55</b>
<b>II</b>	1 0	1 9	27	5	<b>61</b>	1 3	2 7	29	8	<b>77</b>
<b>III</b>	1	5	11	6	<b>23</b>	9	2 8	20	6	<b>63</b>
<b>VI</b>	0	0	2	1	<b>3</b>	0	3	2	1	<b>6</b>
<b>V</b>	1	8	5	7	<b>21</b>	0	0	0	0	<b>0</b>
<b>Total</b>	1 5	3 4	46	19	<b>114</b>	3 4	7 0	74	23	<b>201</b>



**Figure 6:** Hearing preservation in both groups

**Table 13:** Hearing preservation rate (GR grade I or II) in patients having functional hearing before treatment

Tumor Extension	Hearing preservation rate (%)	
	Surgery group	Radiosurgery group
T1	86.7	73.5
T2	61.8	55.7
T3a&b	60.9	70.3
T4a&b	26.3	69.6
Total	58.8	65.7

### Facial nerve results

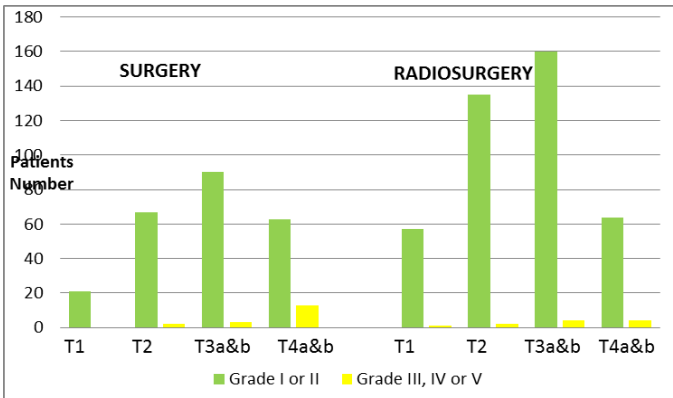
The facial nerve was anatomically preserved in 265 patients (98.5%) in the surgery group. A total of 251 patients (93.3%) had House-Brackmann (HB) grade I or II facial function at the last follow-up, and a significant correlation was found between facial function preservation and tumor extension (P value < 0.0001, Spearman's rho correlation) (*Table 14 and 15, Figure 7*).

In the radiosurgery group, on the other hand, 416 patients (97.4%) had HB grade I or II facial function at the last follow-up after treatment, and no significant correlation was found between facial function preservation and tumor extension (P value = 0.502, Spearman's rho correlation) (*Table 14 and 15, Figure 7*).

Facial function at the last follow-up was found to be significantly better in the radiosurgery group (P value < 0.001, Mann-Whitney).

**Table 14:** Facial function at last follow up

House- Brackman grade	Surgery Group					Radiosurgery Group				
	T1	T2	T3a&b	T4a&b	Total	T1	T2	T3a&b	T4a&b	Total
<b>I</b>	21	60	81	42	<b>204</b>	56	135	157	63	<b>411</b>
<b>II</b>	0	7	19	21	<b>47</b>	1	0	3	1	<b>5</b>
<b>III</b>	0	2	2	9	<b>13</b>	0	1	1	1	<b>3</b>
<b>VI</b>	0	0	1	3	<b>4</b>	0	0	1	3	<b>4</b>
<b>V</b>	0	0	0	1	<b>1</b>	1	1	2	0	<b>4</b>
<b>Total</b>	21	69	103	76	<b>269</b>	58	137	164	67	<b>427</b>



**Figure 7:** Facial function preservation at last follow-up

**Table 15:** Facial nerve function preservation rate (HB grade I or II)  
at the last follow up

Tumor Extension	Facial function preservation rate (%)	
	Surgery group	Radiosurgery group
T1	100	98.3
T2	97.1	98.5
T3a&b	97.1	98.2
T4a&b	82.9	95.5
Total	93.3	97.4

**Other symptoms:**

The presence or absence of other symptoms as well as symptom severity was compared before and after treatment in both groups.



**Table 16:** Results of dizziness, tinnitus, and trigeminal nerve function after treatment in both groups

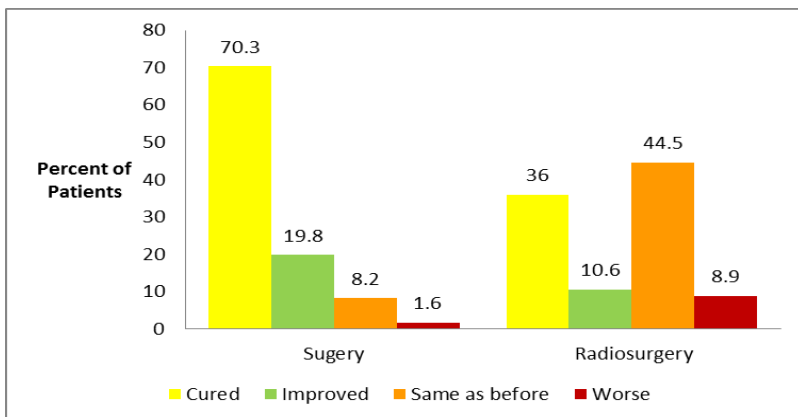
	Patients who had dizziness before treatment				New dizziness	P Value
	cured	improve	Same	worse		
<b>Surgery</b>	128 (70.3%)	36 (19.8%)	15 (8.2%)	3 (1.6%)	21 (7.8%)	<b>&lt;0.0001</b>
<b>Radiosurgery</b>	85 (36%)	25 (10.6%)	105 (44.4%)	21 (8.9%)	35 (8.2%)	
	Patients who had tinnitus before treatment				New tinnitus	P Value
	cured	improve	Same	worse		
<b>Surgery</b>	173 (82.2%)	7 (3.3%)	24 (11.5%)	5 (2.4%)	35(1.9%)	<b>&lt;0.0001</b>
<b>Radiosurgery</b>	38 (12.3%)	32 (10.4%)	217 (70.2%)	22(7.1%)	25 (5.9%)	
	Patients who had trigeminal nerve dysfunction before treatment				New trigeminal dysfunction	P Value
	cured	improve	Same	worse		
<b>Surgery</b>	35 (97.2%)	0	1 (2.8%)	0	4 (1.5%)	<b>=0.036</b>
<b>Radiosurgery</b>	25 (55.6%)	6 (13.3%)	13 (28.9%)	1 (2.2%)	14 (3.3%)	

### Results related to dizziness

In patients who complained of dizziness prior to surgery, 90.1% improved either completely or partially after treatment. Another 8.2% reported that their dizziness had remained unchanged, and an additional 7.8% developed new dizziness after surgery.

Among the radiosurgery patients who reported dizziness prior to surgery, 44.5% reported persistent dizziness following treatment, 46.6% reported improvement, 8.9% reported worsening of dizziness, and 8.2% reported developing new dizziness after radiosurgery.

The outcome related to dizziness was significantly more favorable in the surgery group (P value < 0.0001, Mann-Whitney).



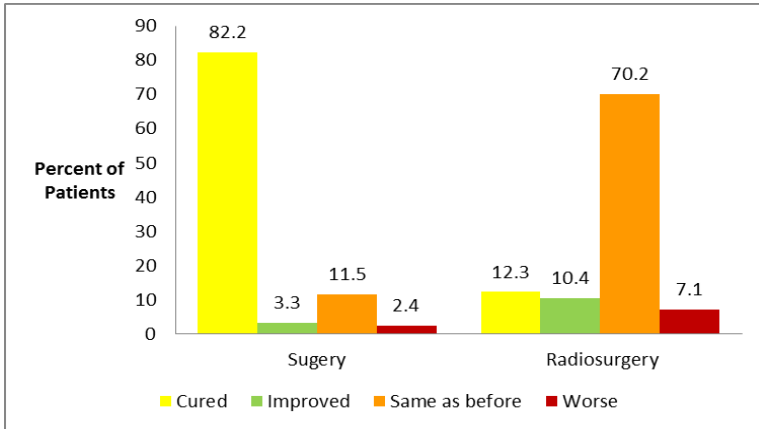
**Figure 8:** Dizziness results at the last follow-up in both groups

### Results related to Tinnitus

In patients who complained of tinnitus prior to surgery, 85.5% improved either completely or partially after treatment. Another 11.5% reported that their tinnitus had remained unchanged, and an additional 2.4% developed new tinnitus after surgery.

Among the radiosurgery patients who reported tinnitus prior to treatment, 760.2% reported persistent tinnitus following treatment and 22.7% reported improvement, however, 5.9% reported developing new tinnitus after radiosurgery.

The outcome related to tinnitus was significantly more favorable in the surgery group (P value < 0.0001, Mann-Whitney).

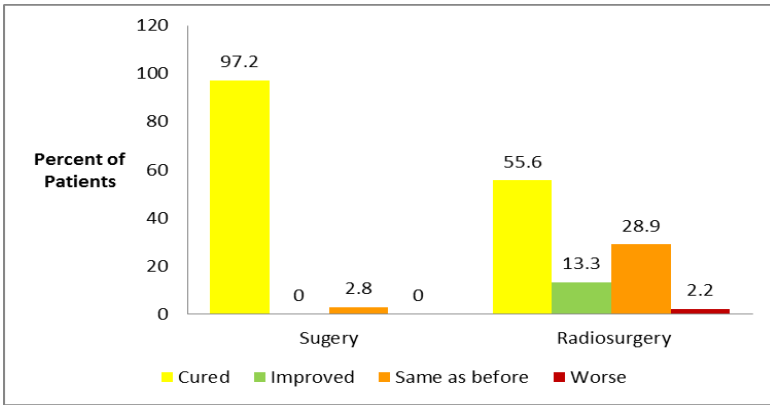


**Figure 9:** Tinnitus results at the last follow-up in both groups

### Results related to trigeminal nerve function

In the surgery group, 36 patients experienced trigeminal nerve dysfunction in the form of hypoesthesia and/or dysesthesia before treatment, and 35 of these patients improved completely after treatment (97.2%). In the radiosurgery group, on the other hand, 45 patients had trigeminal nerve dysfunction

before treatment, and 31 patients (68.9%) improved after treatment.



**Figure 10:** Trigeminal results at the last follow-up in both groups

### **Small versus large tumors**

Since tumor size influences the choice of treatment, tumors in patients in the surgery group were consistently larger. Therefore, we further analyzed patients by stratifying them into small and large tumor groups. Following the Hannover classification for vestibular schwannomas, small tumors in our group were classified as grades T1 and T2,

whereas large tumors were classified as grades T3a, T3b, T4a and T4b.

The two small tumor groups (radiosurgery and surgery) did not differ significantly from each other in terms of gender ( $p=0.082$ , Chi square), size stratification according to the Hannover classification ( $p=0.305$ , Mann Whitney U), facial nerve function ( $p=0.195$ , Mann Whitney U) and hearing function ( $p=0.925$ , Mann Whitney U), incidence of tinnitus ( $p=0.065$ , Chi square), and trigeminal symptoms ( $p=0.266$ , Chi square); however, the groups differed in terms of age ( $p<0.001$ , Mann Whitney U) and incidence of dizziness ( $p<0.05$ , Chi square).

The two large tumor groups (radiosurgery and surgery), on the other hand, did not differ significantly from each other regarding gender ( $p=0.576$ , Chi square), facial nerve ( $p=0.066$ , Mann Whitney U), hearing function ( $p=0.355$ , Mann Whitney U), incidence of tinnitus ( $p=0.544$ , Chi square), dizziness ( $p=0.138$ , Chi square), or trigeminal symptoms ( $p=0.372$ , Chi square). However, they did differ from each other regarding age ( $p<0.001$ , Mann Whitney U) and tumor size ( $p<0.01$ , Mann Whitney U, i.e., larger in the surgery group).

In terms of final tumor volume (relative to pre-treatment size), surgery proved to be superior to radiosurgery for both small and large tumors ( $p < 0.001$  in both, Mann Whitney U). Nevertheless, radiosurgery was better than surgery in preserving facial nerve and hearing functions in large tumors; however in small tumors the results were comparable between surgery and radiosurgery. We also observed a relative advantage of surgery over radiosurgery for tinnitus, dizziness and facial hypoesthesia in the case of small tumors only ( $p < 0.001$  for both dizziness and facial hypoesthesia, Chi square). For facial hypoesthesia, the difference between treatments practically disappeared with regard to large tumors.

## **Complications**

Five patients (1.2%) in the radiosurgery group developed hydrocephalus after treatment. Another eight patients (1.9%) developed trigeminal neuralgia, with transient pain in two patients and permanent pain in six patients. The most common complication after radiosurgery was facial spasm, which occurred in 16 patients (3.7%).

The most common complication after surgery was cerebrospinal fluid (CSF) rhinorrhea, which occurred in 24 patients (8.9%). The leakage stopped after lumbar drainage in 21 patients, while wound revision was indicated in three cases. Five patients (2.7%) developed trigeminal hypoesthesia. Four patients (1.5%) developed delayed postoperative hydrocephalus and ventriculo-peritoneal shunting was indicated. Two patients (0.7%) developed bilateral frontal pneumocephalus, which was treated with burr hole drainage.



## Discussion

Vestibular schwannoma (VS) has a slightly higher incidence in women (Mirzayan et al. 2007). In the present work, the male to female ratio was 1:1.17 in the surgery group and 2:3 in the radiosurgery group. A possible explanation for the larger number of female patients in the radiosurgery group is that females may be more likely than males to choose the radiation option.

Several authors have reported that the typical age for VS diagnosis is during the fifth to sixth decades of life, while patients with NF2 are usually younger (Samii et al. 2006, Myrseth et al. 2007; Tatagiba & Acioly 2008b). A few series studies comparing microsurgery and radiosurgery for treating VS documented a significantly higher average age among radiosurgery patients (Pollock et al. 2006, Myrseth et al. 2005, Karpinos et al. 2000, Regis et al. 2002, Pollock et al. 1995). The mean age in our groups was 47.8 in the surgery group and 58.1 in the radiosurgery group, which did not differ significantly.

Hearing loss and/or tinnitus are the most common complaints in VS patients, followed by dizziness and/or imbalance due to vestibular nerve dysfunction. Other complaints may be related to trigeminal or facial nerve dysfunction, and lower cranial nerve dysfunction may also occur with large VSs (Matthies and Samii 1997b; Myrseth et al. 2007). The rates of trigeminal nerve dysfunction, facial nerve dysfunction, and hearing loss in this series were significantly higher among patients who had tumors that extended more into the cerebellopontine cistern (P value < 0.001). However, tinnitus and dizziness were not related to tumor extension. In addition, both surgery and radiosurgery groups were matched regarding symptomatology prior to treatment.

The treatment options available to VS patients include observation, surgery or radiosurgery. A more conservative treatment option may be offered to a patient with a small or medium-sized tumor, especially when the patient is elderly or suffers from additional medical problems; however, it should be noted that conservative management is not without risk, as hearing loss or disabling symptoms may occur as a result of

increasing tumor size (Lin et al. 2005; Doherty and Friedman 2006).

There is some disagreement over the best treatment option for VS, especially when it comes to medium-sized tumors; however, it is commonly believed that VSs causing brainstem compression as well as cystic VSs should be treated surgically (Charabi et al. 2000).

Although randomized clinical trials represent the gold standard of evidence-based practice, it may be not possible to randomize patients between microsurgery and radiosurgery. Next best evidence is obtained from well-designed non-randomised controlled trials (Vandenbroucke 2004). The present study presents a retrospective long-term comparative analysis of VS treatment in a large number of VS patients from two different specialized centers. Patients were informed about the expected results and possible complications of both surgery and radiosurgery before they chose a treatment option.

As mentioned above, six observational studies have been published comparing microsurgery and radiosurgery for the treatment of VS (Pollock et al. 1995, Karpinos et al. 2002, Régis et al. 2002, Myrseth et al. 2005, Pollock et al. 2006, Myrseth et al. 2009). Except for the study by Karpinos et al. all

studies excluded cases of recurrent tumors as well as tumors larger than 3 cm in diameter.

We used the Hannover classification of tumor extension in our comparative study for two reasons: 1) it was the classification system used by the 2 centers from which we collected our data, and 2) tumor extension and its relation to important adjacent structures in the cerebellopontine angle may have more impact on the treatment results than tumor size alone.

Régis et al. classified tumors according to the Koos grading system and included only grade II and III tumors in their comparison. They excluded grade I and IV tumors from the comparison in order to avoid comparing large tumors treated by microsurgery with small tumors treated by radiosurgery.

The large number of cases included in our series allowed us to compare different comparable grades of tumor extension in the microsurgery and radiosurgery groups.

Three different approaches may be used for the surgical resection of VS: retrosigmoid, middle fossa and translabyrinthine. The risks can be minimized and the results

can be maximized if the operating team uses the surgical approach they are most familiar with (Matthies and Samii 1997a). The translabyrinthine approach cannot be used if hearing preservation is attempted; the middle fossa approach is recommended for small tumors. The retrosigmoid approach, instead, can be used for the removal of both large and small VSs, while preserving hearing function (Myrseth et al. 2007).

Radiosurgery can be performed by Gamma Knife, LINAC, or Proton-Radiotherapy, but Gamma Knife is the most widely used method for stereotactic radiosurgery for VS.

### **Tumor control**

Rates of total removal of VS differ widely in the literature; however, it has been reported that in experienced hands, total removal is possible in 80–99% of cases (Gormley et al. 1997; Irving et al. 1998; Lanman et al. 1999; Sampath et al. 2000; Samii et al. 2006).

The ability to completely remove VS depends on the consistency of the tumor and the presence of an arachnoid plane between the tumor and the brain. Total tumor removal is possible by dissecting the neurovascular structures from the false capsule of the tumor (Samii et al. 2006).

In cases of difficult dissection, a thin layer of tumor could be left attached to one or more cranial nerves in order to preserve their function (Kemink et al. 1991; Kameyama et al. 1996; Bloch et al. 2004; Park et al. 2006; Seol et al. 2006; Freeman et al. 2007).

The residual tumor should be reduced in size as much as possible in order to minimize the rate of regrowth (Hwang et al. 2002; Bloch et al. 2004; Sughrue et al. 2011).

Regrowth after subtotal removal of VS depends mainly on the vascularity and on the cellularity of the residual tumor. Tumor consistency may also play an important role, as cystic VSs may exhibit more rapid regrowth than solid tumors (Hwang et al. 2002).

Bloch et al. (2004) followed 52 VS patients after near-total (remnant  $\leq 25 \text{ mm}^2$  or  $\leq 2 \text{ mm}$  thick) and partial (any larger remnant) resections. The tumor recurrence rate was 3% after near-total resection and 32% after partial resection.

Sughrue et al. (2011) performed a study on 772 patients who underwent VS surgery during a 25-year period and were prospectively followed for many years postoperatively. They concluded that long-term rates of tumor control do not differ

between patients who undergo gross-total resection and those in whom a small amount of tumor is left behind.

In the present series, total tumor removal was possible in 97.8% of the cases, and subtotal removal in 2.2% of the cases (n = 6). After a follow-up period ranging between 6 and 74 months, tumor recurrence occurred only in one case (0.37% of the cases). The follow-up period in the cases of subtotal removal ranged between 15 and 74 months.

Some tumor regrowth may occur during the early period following radiosurgery for VS, usually between 6 and 24 months after radiation. This initial tumor expansion may be transient and the tumor may in fact decrease in size after the initial expansion. In large tumors, however, the initial expansion may cause compression-related symptoms and require surgical treatment (Fukouka et al. 2009).

In the present series, tumor expansion occurred in 148 patients (34.7%) six months after radiosurgery. Further follow-up showed that tumor expansion was transient in 105 patients (24.5%) and these tumors eventually decreased in size from their maximum peaks at 8-24 months after the initial expansion. However, tumor expansion resulted in clinical

deterioration in three patients (0.7%), who required the insertion of VPS after developing hydrocephalus.

The results following radiosurgery for VS are very unevenly described in the literature, including tumor growth less than or equal to 2 mm, no visible/measurable change, and further surgery required, among others (Bassim et al. 2010). Van Eck and Horstmann (2005) introduced two categories of tumor control after Gamma Knife radiosurgery for VS: "MRI-based tumor control" when no increase, or increase of less than 10% of the initial tumor volume was observed at follow-up, and "clinical tumor control" when clinical symptoms did not progress, and no further treatment was necessary. They reported that after a mean follow-up duration of 22 months, the magnetic resonance imaging–based tumor control rate was 87%, while the clinical control rate was 97.5%.

Nevertheless, more data are needed regarding long-term rates of tumor control after radiosurgery; especially for cases in which the marginal radiation dose was reduced in order to avoid cranial nerve complications. It has been documented that delayed tumor growth may occur even in cases where the tumor remained stable for 3 years after treatment (Roche et al., 2008). In addition to that, long term follow up after



radiosurgery may allow the evaluation of serious side effects and functional outcome.

In the present series, the follow-up period in the radiosurgery group ranged between 7 and 144 months, with a mean follow-up time of 42.4 months. Tumor control at the last follow-up showed tumor shrinkage in 71.9%, stable tumor in 14.5%, and tumor expansion in 13.6% of the cases. On the other hand, long-term follow-up (at least 2 years after treatment) in our series revealed tumor shrinkage in 74.6%, stable tumor in 12.4%, and tumor expansion in 13% of the cases.

### **Facial nerve Function**

It has been reported that anatomical preservation of the facial nerve is achieved in 93-99% of VS surgeries (Ojemann 1993; Sekhar et al. 1996; Gormley et al. 1997; Samii and Matthies 1997a; Sampath et al. 1997; Lanman et al. 1999; Samii et al. 2006).

Although transient deterioration of facial nerve function usually occurs after surgery, gradual recovery usually follows during the first 3 to 6 months postoperatively. Good

postoperative facial function (HB grade I or II) is achieved in 52 to 93% of cases (Samii et al. 2006).

The main predictor of facial nerve preservation after surgery is tumor size (Briggs et al. 2000; Jung et al. 2000; Staecker et al. 2000; Wiet et al. 2001). Other predictors include tumor extension, cystic tumor consistency, previous surgery or radiosurgery, and the surgeon's operative experience (Samii et al. 2006).

The rate of facial nerve palsy after radiosurgery for VS has dramatically decreased following improvement of dose planning and tumor imaging, which made smaller peripheral doses (10-14 Gy) possible (Régis et al. 2002). Yang et al. (2009b) conducted a review of 23 published studies that analyzed facial nerve outcome following radiosurgery for VS; they reported facial nerve preservation rate (HB grade I or II) of 96.2%.

In the present series, we found a significant correlation between facial function at the last follow-up and tumor extension in the surgery group; however, in the radiosurgery group, facial function preservation was not significantly influenced by tumor extension, probably because the radiation

dose at the tumor margin was kept constant across all cases, irrespective of size.

Previous studies comparing surgical and radiosurgical treatment of VS showed facial nerve function preservation (HB grade I or II) of 60-83% in surgery patients and 91-100% in radiosurgery patients (Pollock et al. 1995, Karpinos et al. 2002, Régis et al. 2002, Myrseth et al. 2005, Pollock et al. 2006, Myrseth et al. 2009).

In our series, facial function was preserved in 93.3% and 97.1% in the surgery and radiosurgery groups, respectively. In addition, facial function preservation rates were comparable between both groups for class T1 (preservation rate 100% and 98.3% in the surgery and radiosurgery groups, respectively), class T2 (preservation rate 97.1% and 98.5% in the surgery and radiosurgery groups, respectively) and class T3 tumors (preservation rate 97.1% and 98.2% in the surgery and radiosurgery groups, respectively).

### **Hearing preservation**

The rate of hearing preservation following surgery for VS ranges from 14 to 80% (Cohen 1993; Irving 1998; Koos et al. 1998). The most significant factors predicting hearing

preservation are tumor size and extension, and preoperative hearing level.

Some authors have suggested that hearing preservation surgery should be undertaken only for small or medium-sized VSs (Slattery et al. 1997; Brackmann et al. 2000; Briggs et al. 2000; Holsinger et al. 2000; Yates et al. 2003).

Hearing preservation may be possible even with large VS. Hearing preservation rates of 9.1 to 50% have been reported for tumors > 3 cm (Fischer 1992; Yokoh et al. 1993; Cohen 1992; Fahlbuch et al. 1998; Iwai et al. 2003; Yamakami et al. 2004; Raftopoulos et al. 2005; Di Maio et al. 2005) and 22.2 to 56.3% for tumors > 2 cm (Frerebeau et al. 1987; Gormley 1997; Wanibuchi et al. 2009). Samii et al. (2006) reported hearing preservation rates of 29 and 27% for T4a and T4b tumors, respectively.

We believe it is best to aim for hearing preservation in all VS surgeries by utilizing continuous auditory evoked potential (AEP) monitoring. In our series, functional hearing was preserved in 58.8% of cases having serviceable hearing before surgery, and a significant correlation was found between hearing preservation and tumor extension. It is important to mention that the rate of hearing preservation was 26.3% in

cases of class T4 tumors, which suggests that hearing preservation should be a goal even in surgeries for large tumors.

In a meta-analysis evaluating hearing results after radiosurgery for VS, hearing preservation was reported for 57% of cases. It was also found that hearing preservation was significantly better in cases treated with a <12.5 Gy marginal radiation dose. No other factors (like tumor volume or patient age) were found to have a significant influence on hearing preservation (Yang et al. 2009).

The results of previous studies comparing surgical and radiosurgical treatment of VS showed hearing preservation of 0-40% in the surgery group and 32-75% in the radiosurgery group (Pollock et al. 1995; Karpinos et al. 2002; Régis et al. 2002; Myrseth et al. 2005; Myrseth et al. 2009). However, it must be noted that these studies used different surgical approaches (including the translabyrinthine approach), and some of them did not use intraoperative neurophysiological monitoring (Régis et al. 2002; Myrseth et al. 2005; Myrseth et al. 2009).

In the radiosurgery group reported here, hearing was preserved in 65.7% of cases having serviceable hearing before

treatment, and, in contrast to what had been reported previously, it was also found to be significantly affected by tumor extension.

Hearing preservation was found to be significantly better in the radiosurgery group (P value = 0.001, Mann-Whitney). When we stratified the tumors by size, we observed that hearing preservation rates were not significantly different for small tumors; for class T1 tumors (preservation rate 86.7% and 73.5% in the surgery and radiosurgery groups, respectively), for class T2 tumors (preservation rate 61.8% and 55.7% in the surgery and radiosurgery groups, respectively), and for class T3 tumors (preservation rate 60.9% and 70.3% in the surgery and radiosurgery groups, respectively). However for class T4 tumors, hearing preservation was better in radiosurgery group (preservation rate 26.3% and 69.6% in the surgery and radiosurgery groups, respectively).

### **Other symptoms**

Results for the improvement of tinnitus, vertigo and imbalance after microsurgery and radiosurgery for VS vary widely in the literature. In a comparative study, Myrseth et al. (2009) found no significant difference between surgery and radiosurgery on tinnitus and vertigo visual analog scale scores

or balance platform tests. In another study, Pollock et al. (2006) compared microsurgery and radiosurgery on the Dizziness Handicap Inventory, a tinnitus survey, and a headache survey within 3 months of treatment and yearly. The results showed lower mean Dizziness Handicap Inventory scores in the radiosurgery group. The results of another comparative study showed worsening of tinnitus in 26.5% of irradiated cases; however tinnitus remained unchanged in 94.1% of cases in the microsurgery group (Karpinos et al. 2000). The same study reported no significant difference in experiencing worsened imbalance between the two groups (23.5% for radiosurgery vs. 22.4% for microsurgery,  $p= 0.932$ ). Other authors have reported that patients who present with imbalance do poorly with radiation treatment and are better served by surgical intervention (Coelho et al. 2008; Bassim et al. 2010). Lunsford et al. (2005) reported that tinnitus is usually unchanged after Gamma Knife radiosurgery for VS, with only infrequent cases of exacerbation.

In the surgery group of the present series, most of the patients who had dizziness or tinnitus prior to treatment improved completely or partially following surgery. This was not observed in the radiosurgery group, however, as dizziness

and tinnitus improved in 46.6% and 22.7% of patients, respectively. The results suggest that surgical treatment seemed to be a better option for patients suffering from tinnitus, dizziness, or trigeminal dysfunction before treatment, as it resulted in the significant improvement of these symptoms (P value < 0.0001, < 0.0001, = 0.036, respectively, Mann-Whitney).

New trigeminal nerve dysfunction following radiosurgery has been shown to develop in 2-16% of cases, and this seems to depend largely on the radiation dose used (Rutherford and King 2005; Sughrue et al. 2009). Fukouka et al. (2009) reported that when trigeminal pain developed after radiosurgery, it was usually transient, while numbness was usually permanent.

In the present series, new trigeminal nerve dysfunction developed in 3.3% of cases in the radiosurgery group, and 1.9% of cases developed trigeminal neuralgia. On the other hand, 2.5% of cases in the surgery group developed trigeminal nerve dysfunction postoperatively.



## **Complications**

Possible complications of microsurgery include CSF leakage 3-13% (Fischer et al. 1992; Glasscock et al. 1987), postoperative hemorrhage in 2.2% (Samii and Matthies 1997c), meningitis in 0.8- 2.5% (Ebersold et al. 1992; Wiegand and Fickel 1989), lower cranial nerve deficit in 0.5- 5.5% (Samii and Matthies 1997c) and hydrocephalus in 1-3% (Samii and Matthies 1997c). In the microsurgery group in the present series, 8.9% of cases developed CSF rhinorrhea and the leakage stopped in most cases after application of lumbar drainage; 1.5% of the operated cases developed hydrocephalus, and there were no cases of meningitis or postoperative hemorrhage requiring surgery.

Lee et al. (2010) suggested that adverse radiation effects may occur 6 to 18 months after Gamma Knife radiosurgery, and that these effects range widely, from mild effects responding to temporary corticosteroid therapy to severe effects requiring surgical treatment. They also claim that lower marginal doses around 12 Gy are associated with a low incidence of adverse radiation effects. The rate of hydrocephalus requiring intervention post-radiosurgery varied widely in the literature, ranging from 1 to 13% (Rutherford and

King 2005). In the present series, five patients (1.2%) developed hydrocephalus after radiosurgery and were treated by VPS insertion. The most common complication after radiosurgery was facial spasm, which occurred in 3.7% of cases. Another 1.9% developed trigeminal neuralgia.

Twelve cases of radiosurgery-associated malignant tumors have been reported so far worldwide (Schmitt et al. 2011). Follow-up should be conducted 5-20 years following radiation in order to detect any radiation-associated tumors that may develop. Death may result from the possible complications associated with microsurgery, however, mortality rates are very low; a recent hospital-based study described 2,643 VS surgeries in 265 US Hospitals and reported a 3-month mortality rate of 0.5% (Barker et al. 2003). In our series, no patients developed radiosurgery-related malignancy; in addition, no patients developed serious postoperative complications or surgery-related mortality.

## Conclusions

Tumor size is crucial in choosing treatment of vestibular schwannoma; several studies have compared microsurgery and radiosurgery for treatment of small and medium sized vestibular schwannoma. We compared retrospectively the results of two large centers treating vestibular schwannoma. The results in our work were divided according to tumor extension (according to Hannover tumor extension system), we compared both treatment groups then we performed separate analysis for small (Class T1 and T2) and large tumors (Class T3 and T4). Previously treated cases and cases on Neurofibromatosis type II (NF2) were excluded during our comparison. The items we depended upon during comparison included facial nerve function, hearing, tumor control, results of preoperative symptoms and complications.

The results showed that although radiosurgery was better in hearing and facial nerve preservation but the results were comparable in small tumors. So, radiosurgery offer advantage for better hearing and facial preservation only in large tumors. The results of tumor control were in favor of

microsurgery both in small and large tumors. Failure rate of radiosurgery require longer follow up especially after the application of smaller marginal radiation doses.

From our results we can conclude the following:

- 1- Microsurgery offer the opportunity for total or subtotal removal of large VS, and the long term recurrence rate is very low even in cases of incomplete removal.
- 2- Surgeons experience and the use of intraoperative neurophysiological monitoring allow complete removal of most cases of VS with high rates of hearing and facial functional preservation.
- 3- Adhering to the recent protocols of Gamma Knife radiosurgery by utilizing marginal dose of 13 Gy, high rates of hearing and facial function preservation could be achieved even in cases of large VS, and the long term results showed excellent tumor control rates.
- 4- The results of tumor control following Gamma Knife radiosurgery showed no significant correlation to tumor extension.
- 5- Radiosurgery gives better results than microsurgery regarding hearing and facial functional preservation

especially in large VS; however in cases of smaller (Class T1, T2 and T3) tumors, the results were comparable between surgery and radiosurgery.

- 6- Patients presented with tinnitus and dizziness may benefit better from microsurgery.

## Reference List

Arthurs BJ, Fairbanks RK, Demakas JJ, Lamoreaux WT, Giddings NA, Mackay AR, Cooke BS, Elaimy AL, Lee CM (2011) A review of treatment modalities for vestibular schwannoma. *Neurosurg Rev* 34: 265-277.

Bassim MK, Berliner KI, Fisher LM, Brackmann DE, Friedman RA (2010) Radiation therapy for the treatment of vestibular schwannoma: a critical evaluation of the state of the literature. *Otol Neurotol* 31: 567-573.

Barker FG 2nd, Carter BS, Ojemann RG, Jyung RW, Poe DS, McKenna MJ (2003) Surgical excision of acoustic neuroma: patient outcome and provider caseload. *Laryngoscope*; 113: 1332-1343.

Bloch DC, Oghalai JS, Jackler RK, Osofsky M, Pitts LH (2004) The fate of the tumor remnant after less-than-complete acoustic neuroma resection. *Otolaryngol Head Neck Surg* 130: 104-112.

Brackmann DE, Owens RM, Friedman RA, Hitselberger WE, De la Cruz A, House JW, Nelson RA, Luxford WM, Slattery WH 3rd, Fayad JN (2000) Prognostic factors for hearing preservation in vestibular schwannoma surgery. *Am J Otol* 21: 417-424.

Briggs RJ, Fabinyi G, Kaye AH (2000) Current management of acoustic neuromas: review of surgical approaches and outcomes. *J Clin Neurosci* 7: 521-526.

Chang S, Adler J, Steinberg G, 2004, General and Historical considerations of radiotherapy and radiosurgery, 3991-3999, Winn HR, Youmans Neurological Surgery, Saunders, Philadelphia.

Charabi S, Tos M, Thomsen J, Charabi B, Mantoni M (2000) Vestibular schwannoma growth--long-term results. *Acta Otolaryngol Suppl* 543: 7-10.

Chopra R, Kondziolka D, Niranjan A, Lunsford LD, Flickinger JC (2007) Long-term follow-up of acoustic schwannoma radiosurgery with marginal tumor doses of 12 to 13 Gy. *Int J Radiat Oncol Biol Phys* 68: 845-851.

Clemis JD, Ballad WJ, Baggot PJ, Lyon ST (1986) Relative frequency of inferior vestibular schwannoma. *Arch Otolaryngol Head Neck Surg* 112: 190-194.

Coelho DH, Roland JT Jr, Rush SA, Narayana A, St Clair E, Chung W, Golfinos JG (2008) Small vestibular schwannomas with no hearing: comparison of functional outcomes in stereotactic radiosurgery and microsurgery. *Laryngoscope* 118: 1909-1916.

Cohen NL (1992) Retrosigmoid approach for acoustic tumor removal. *Otolaryngol Clin North Am* 25: 295-310.

Cohen N, Lewis WS, Ransohoff J (1993) Hearing preservation in cerebellopontine angle tumor surgery: the NYU experience 1974-1991. *Am J Otol* 14: 423-433.

Doherty JK and Friedman RA (2006) Controversies in building a management algorithm for vestibular schwannomas. *Curr Opin Otolaryngol Head Neck Surg* 14: 305-313.

Ebersold MJ, Harner SG, Beatty CW, et al., (1992) Current Results of the Retrosigmoid Approach to Acoustic Neuroma. *J Neurosurg* 76: 901-909.

Fahlbusch R, Neu M, Strauss C (1998) Preservation of hearing in large acoustic neu-rinomas following removal via suboccipito-lateral approach. *Acta Neurochir (Wien)* 140: 771-777.

Feigl GC, Decker K, Wurms M, Krischek B, Ritz R, Unertl K, Tatagiba M (2014) Neurosurgical procedures in semi-sitting position: An evaluation of the risk of a paradoxical venous air embolism for patients with a patent foramen ovale *World Neurosurg* 81: 149-164.

Fischer G, Fischer C, Remond J (1992) Hearing preservation in acoustic neurinoma surgery. *J Neurosurg* 76: 910-917.

Flint D, Fagan P, Panarese A (2005) Conservative management of sporadic unilateral acoustic neuromas. *J Laryngol Otol* 119: 424-428.

Frerebeau P, Benezech J, Uziel A, Coubes P, Segnarbieux F, Malonga M (1987) Hearing preservation after acoustic neurinoma operation. *Neurosurgery* 21: 197-200.

Freeman SR, Ramsden RT, Saeed SR, Alzoubi FQ, Simo R, Rutherford SA, King AT (2007) Revision surgery for residual



or recurrent vestibular schwannoma. *Otol Neurotol* 28: 1076-1082.

Fukuoka S, Takanashi M, Hojyoa A, Konishi M, Tanakac C, Nakamura H (2009) Gamma Knife Radiosurgery for Vestibular Schwannomas, 45-62, Yamamoto M, Japanese Experience with Gamma Knife Radiosurgery, *Prog Neurol Surg*. Basel, Karger.

Gal TJ, Shinn J, Huang B (2010) Current epidemiology and management trends in acoustic neuroma. *Otolaryngol Head Neck Surg* 142: 677-681.

Glasscock ME III, McKennan KX, Levine SC (1987) Acoustic Neuroma Surgery: The results of Hearing Conservation Surgery. *Laryngoscope* 97: 785-789.

Gormley WB, Sekhar LN, Wright DC, Kamerer D, Schessel D (1997) Acoustic neuromas: results of current surgical management. *Neurosurgery* 41: 50-58.

Holsinger FC, Coker NJ, Jenkins HA (2000) Hearing preservation in conservation surgery for vestibular schwannoma. *Am J Otol* 21: 695-700.

House JW and Brackmann DE (1985) Facial nerve grading system. *Otolaryngol Head Neck Surg* 93: 146-147.

Hwang SK, Kim DG, Paek SH, Kim CY, Kim MK, Chi JG, Jung HW (2002) Aggressive vestibular schwannomas with postoperative rapid growth: clinicopathological analysis of 15 cases. *Neurosurgery* 51: 1381-1390.

Irving RM, Jackler RK, Pitts LH (1998) Hearing preservation in patients undergoing vestibular schwannoma surgery: comparison of middle fossa and retrosigmoid approaches. *J Neurosurg* 88: 840-845.

Iwai Y, Yamanaka K, Ishiguro T (2003) Surgery combined with radiosurgery of large acoustic neuromas. *Surg Neurol* 59: 283-289.

Jacob A, Robinson LL Jr, Bortman JS, Yu L, Dodson EE, Welling DB (2007) Nerve of origin, tumor size, hearing preservation, and facial nerve outcomes in 359 vestibular schwannoma resections at a tertiary care academic center. *Laryngoscope* 117: 2087-2092.

Jung S, Kang SS, Kim TS, Kim HJ, Jeong SK, Kim SC, Lee JK, Kim JH, Kim SH, Lee JH (2000) Current surgical results of retrosigmoid approach in extralarge vestibular schwannomas. *Surg Neurol* 53: 370-377.

Kameyama S, Tanaka R, et al. (1996) Long-term follow-up of the residual intracanalicular tumours after subtotal removal of acoustic neurinomas. *Acta Neurochir (Wien)* 138: 206-209.

Karpinos M, Teh B, Kawaguchi T, Honda Y, Yamazaki H, Hasegawa A (2002) Treatment of acoustic neuroma: stereotactic radiosurgery vs. microsurgery. *Int J Radiat Oncol Biol Phys* 54: 1410-1421.

Kemink JL, Langman AW, Niparko JK, Graham MD (1991) Operative management of acoustic neuromas: the priority of neurologic function over complete resection. *Otolaryngol Head Neck Surg* 104: 96-99.

Khrais T, Romano G, Sanna M (2008) Nerve origin of vestibular schwannoma: a prospective study. *J Laryngol Otol* 122: 128-131.

Lanman TH, Brackmann DE, Hitselberger WE, Subin B (1999) Report of 190 consecutive cases of large acoustic tumors (vestibular schwannoma) removed via the translabyrinthine approach. *J Neurosurg* 90: 617-623.

Koos WT, Day JD, Matula C, Levy DI (1998) Neurotopographic considerations in the microsurgical treatment of small acoustic neuromas. *J Neurosurg* 88: 506-512.

Lee CC, Yen YS, Pan DH, Chung WY, Wu HM, Guo WY, Chen MT, Liu KD, Shih YH (2010) Delayed microsurgery for vestibular schwannoma after gamma knife radiosurgery. *J Neurooncol* 98: 203-212.

Lin CY, Lin SL, Kao CC, Wu JL (2005) The remediation of hearing deterioration in children with large vestibular aqueduct syndrome. *Auris Nasus Larynx* 32: 99-105.

Lunsford LD, Niranjan A, Flickinger JC, Maitz A, Kondziolka D (2005) Radiosurgery of vestibular schwannomas: summary of experience in 829 cases. *J Neurosurg* 102: 195-199.

Matthies C and Samii M (1997) Management of 1000 vestibular schwannomas (acoustic neuromas): clinical presentation. *Neurosurgery* 40: 1-9.

Mirzayan MJ, Gerganov VM, Lüdemann W, Oi S, Samii M, Samii A (2007) Management of vestibular schwannomas in

young patients-comparison of clinical features and outcome with adult patients. *Childs Nerv Syst* 23: 891-895.

Moffat DA, Golledge J, Baguley DM, Hardy DG (1993) Clinical correlates of acoustic neuroma morphology. *J Laryngol Otol* 107: 290-294.

Mulkens TH, Parizel PM, Martin JJ, Degryse HR, Van de Heyning PH, Forton GE, De Schepper AM (1993) Acoustic schwannoma: MR findings in 84 tumors. *AJR Am J Roentgenol* 160: 395-398.

Myrseth E, Møller P, Pedersen PH, Vassbotn FS, Wentzel-Larsen T, Lund-Johansen M (2005) Vestibular schwannomas: clinical results and quality of life after microsurgery or gamma knife radiosurgery. *Neurosurgery* 5: 927-935.

Myrseth E, Pedersen PH, Møller P, Lund-Johansen M (2007) Treatment of vestibular schwannomas. Why, when and how? *Acta Neurochir (Wien)* 149: 647-660.

Myrseth E, Moller P, Pedersen PH, Lund-Johansen M (2009) Vestibular schwannoma: surgery or gamma knife radiosurgery? A prospective, nonrandomized study. *Neurosurgery* 64: 654-661.

Ojemann RG (1993) Management of acoustic neuromas (vestibular schwannomas) (honored guest presentation). *Clin Neurosurg* 40: 498-535.

Ojemann RG, 1996, Acoustic neuroma, 2841-2846, Winn HR, Youmans Neurological Surgery, Saunders, Philadelphia.

Park CK, Jung HW, Kim JE, Son YJ, Paek SH, Kim DG (2006) Therapeutic strategy for large vestibular schwannomas. *J Neurooncol* 77: 167-171.

Pellet W, Regis J, Roche PH, Delsanti C (2003) Relative indications for radiosurgery and microsurgery for acoustic schwannoma. *Adv Tech Stand Neurosurg* 28: 227-282.

Pollock B, Lunsford L, Kondziolka D, Flickinger J, Bissonette D, Kelsey S, Jannetta PJ (1995) Outcome analysis of acoustic neuroma management: a comparison of microsurgery and stereotactic radiosurgery. *Neurosurgery* 36: 215-224.

Pollock BE, Driscoll CL, Foote RL, Link MJ, Gorman DA, Bauch CD, Mandrekar JN, Krecke KN, Johanson CH (2006) Patient outcomes after vestibular schwannoma management: a prospective comparison of microsurgical resection and stereotactic radiosurgery. *Neurosurgery* 59: 77- 85.

Pollock BE, 2008, Vestibular Schwannoma Management: An Evidence-Based Comparison of Stereotactic Radiosurgery and Microsurgical Resection, 222-227, *Prog Neurol Surg*. Basel, Karger.

Porter JM, Pidgeon C, Cunningham AJ (1999) The sitting position in neurosurgery: a critical appraisal. *Br J Anaesth* 82: 117-128.

Raftopoulos C, Abu Serieh B, Duprez T, Docquier MA, Guerit JM (2005) Microsurgical results with large vestibular schwannomas with preservation of facial and cochlear nerve function as the primary aim. *Acta Neurochir (Wien)* 147: 697-706.

Régis J, Pellet W, Delsanti C, Dufour H, Roche PH, Thomassin JM, Zanaret M, Peragut JC (2002) Functional outcome after gamma knife surgery or microsurgery for vestibular schwannomas. *J Neurosurg* 97: 1091-1100.

Regis J, Roche PH, Delsanti C, Thomassin JM, Ouaknine M, Gabert K, Pellet W (2007) Modern management of vestibular schwannomas. *Prog Neurol Surg* 20: 129-141.

Roche PH, Khalil M, Thomassin JM, Delsanti C, and Régis J, 2008, Surgical Removal of Vestibular Schwannoma after Failed Gamma Knife Radiosurgery, 152-157, *Prog Neurol Surg*. Basel, Karger.

Rutherford SA and King AT (2005) Vestibular schwannoma management: What is the 'best' option? *Br J Neurosurg* 19: 309-316.

Ruttledge MH and Rouleau GA (2005) Role of the neurofibromatosis type 2 gene in the development of tumors of the nervous system. *Neurosurg Focus*. 19: E6.

Samii M, Gerganov V, Samii A (2006) Improved preservation of hearing and facial nerve function in vestibular schwannoma surgery via the retrosigmoid approach in a series of 200 patients. *J Neurosurg* 105: 527-535.

Samii M and Matthies C (1997a) Management of 1000 vestibular schwannomas (acoustic neuromas): hearing function in 1000 tumor resections. *Neurosurgery* 40: 248-260.

Samii M and Matthies C (1997b) Management of 1000 vestibular schwannomas (acoustic neuromas): the facial nerve--

preservation and restitution of function. *Neurosurgery* 40: 684-694.

Samii M and Matthies C (1997c) Management of 1000 vestibular schwannomas (acoustic neuromas): surgical management and results with an emphasis on complications & how to avoid them. *Neurosurgery* 40: 11-23.

Sampath P, Holliday MJ, Brem H, Niparko JK, Long DM (1997) Facial nerve injury in acoustic neuroma (vestibular schwannoma) surgery: etiology and prevention. *J Neurosurg* 87: 60-66.

Sampath P, Rini D, Long DM (2000) Microanatomical variations in the cerebellopontine angle associated with vestibular schwannomas (acoustic neuromas): a retrospective study of 1006 consecutive cases. *J Neurosurg* 92: 70-78.

Sampath P and Long DM, 2004, *Acoustic Neuroma*, 1147-1168, Winn HR, Youmans Neurological Surgery, Saunders, Philadelphia.

Schmitt WR, Carlson ML, Giannini C, Driscoll CL, Link MJ (2011) Radiation-induced sarcoma in a large vestibular schwannoma following stereotactic radiosurgery: case report. *Neurosurgery* 68: 840-846.

Sekhar LN, Gormley WB, Wright DC (1996) The best treatment for vestibular schwannoma (acoustic neuroma): microsurgery or radiosurgery? *Am J Otol* 17: 676-682.

Seol HJ, Kim CH, Park CK, Kim CH, Kim DG, Chung YS, Jung HW (2006) Optimal extent of resection in vestibular

schwannoma surgery: relationship to recurrence and facial nerve preservation. *Neurol Med Chir (Tokyo)* 46: 176-180.

Shin YJ, Lapeyre-Mestre M, Gafsi I, Cognard C, Deguine O, Tremoulet M, Fraysse B (2003) Neurotological complications after radiosurgery versus conservative management in acoustic neuromas: a systematic review-based study. *Acta Otolaryngol* 123: 59-64.

Silk PS, Lane JI, Driscoll CL (2009) Surgical approaches to vestibular schwannomas: what the radiologist needs to know. *Radiographics* 29: 1955-1970.

Slattery WH3rd, Brackmann DE, Hitselberger W (1997) Middle fossa approach for hearing preservation with acoustic neuromas. *Am J Otol* 18: 596-601.

Somers T, Casselman J, de Ceulaer G, Govaerts P, Offeciers E (2001) Prognostic value of magnetic resonance imaging findings in hearing preservation surgery for vestibular schwannoma. *Otol Neurotol* 22: 87-94.

Staecker H, Nadol JB Jr, Ojeman R, Ronner S, McKenna MJ. (2000) Hearing preservation in acoustic neuroma surgery: middle fossa versus retrosigmoid approach. *Am J Otol* 21: 399-404.

Sughrue ME, Kaur R, Rutkowski MJ, Kane AJ, Kaur G, Yang I, Pitts LH, Parsa AT (2011) Extent of resection and the long-term durability of vestibular schwannoma surgery. *J Neurosurg* 114: 1218-1223.



Sughrue ME, Yang I, Han SJ, Aranda D, Kane AJ, Amoils M, Smith ZA, Parsa AT (2009) Non-audiofacial morbidity after Gamma Knife surgery for vestibular schwannoma. *Neurosurg Focus* 27: E4.

Suh JH, Macklis RM, 2004, Principles of radiotherapy, 4005-4015, Winn HR, Youmans Neurological Surgery, Saunders, Philadelphia.

Tatagiba M and Acioly MA, 2008a, Retrosigmoid Approach to the Posterior and Middle Fossae, 137-152, Ramina R, Aguiar P, and Tatagiba M, Samii's Essentials in Neurosurgery. Springer-Verlag Berlin, Heidelberg.

Tatagiba M and Acioly MA, 2008b, Vestibular Schwannoma: Current State of the Art, 175-189, Ramina R, Aguiar P, and Tatagiba M, Samii's Essentials in Neurosurgery. Springer-Verlag Berlin, Heidelberg.

Thakur JD, Banerjee AD, Khan IS, Sonig A, Shorter CD, Gardner GL, Nanda A, Guthikonda B (2012) An update on unilateral sporadic small vestibular schwannoma. *Neurosurg Focus* 33: E1.

Vandenbroucke JP (2004) When are observational studies as credible as randomised trials? *Lancet* 363: 1728-1731.

van Eck AT and Horstmann GA (2005) Increased preservation of functional hearing after gamma knife surgery for vestibular schwannoma." *J Neurosurg* 102: 204-206.

Wanibuchi M, Fukushima T, McElveen JT Jr, Friedman AH (2009) Hearing preservation in surgery for large vestibular schwannomas. *J Neurosurg* 111: 845-854.

Wiegand DA, Fickel V (1989) Acoustic neuroma-the patient's perspective: subjective assessment of symptoms, diagnosis, therapy, and outcome in 541 patients. *Laryngoscope* 99: 179-187.

Wiet RJ, Mamikoglu B, Odom L, Hoistad DL (2001) Long-term results of the first 500 cases of acoustic neuroma surgery. *Otolaryngol Head Neck Surg* 124: 645-651.

Witham TF, Kondziolka D, 2004, Gamma knife radiosurgery, 4117-4123, Winn HR, Youmans Neurological Surgery, Saunders, Philadelphia.

Wolbers JG, Dallenga AH, Romero AM, Linge AV (2013) What intervention is best practice for vestibular schwannomas? A systematic review of controlled studies. *BMJ Open* 22: 2.

Yamakami I, Uchino Y, Kobayashi E, Yamaura A (2003) Conservative management, gamma-knife radiosurgery, and microsurgery for acoustic neurinomas: a systematic review of outcome and risk of three therapeutic options. *Neurol Res* 25: 682-690.

Yamakami I, Uchino Y, Kobayashi E, Yamaura A, Oka N (2004) Removal of large acoustic neurinomas (vestibular schwannomas) by the retrosigmoid approach with no mortality and minimal morbidity. *J Neurol Neurosurg Psychiatry*. 75: 453-458.

Yang I, Aranda D, Han SJ, Chennupati S, Sughrue ME, Cheung SW, Pitts LH, Parsa AT (2009a) Hearing preservation after stereotactic radiosurgery for vestibular schwannoma: a systematic review. *J Clin Neurosci* 16: 742-747.

Yang I, Sughrue ME, Han SJ, Fang S, Aranda D, Cheung SW, Pitts LH, Parsa AT (2009b) Facial nerve preservation after vestibular schwannoma Gamma Knife radiosurgery. *J Neurooncol* 93: 41-48.

Yates PD, Jackler RK, Satar B, Pitts LH, Oghalai JS (2003) Is it worthwhile to attempt hearing preservation in larger acoustic neuromas? *Otol Neurotol* 24: 460-464.

Yokoh A, Kobayashi S, Tanaka Y, Gibo H, Sugita K (1993) Preservation of cochlear nerve function in acoustic neurinoma surgery. *Acta Neurochir (Wien)* 123: 8-13.

## **Abstract**

### **Objective:**

Treatment of vestibular Schwannomas, represent a matter of strong controversy, and to date no class I evidence can support the benefit of certain treatment modality over the others. Expectant treatment, microsurgery, and gamma knife radiosurgery represent the most important options to be considered. The main goal of the present study is to compare the functional outcome after gamma knife and surgical treatment in the long-term follow up.

### **Patients and Methods:**

269 patients submitted to microsurgery and 427 patients treated with gamma knife in two different centers were followed up for  $16.4 \pm 13.6$  months and  $42.4 \pm 26.8$  months respectively. Tumor volumetry based on serial MR images, facial nerve function according to the House-Brackman scale, hearing function according to the Gardner-Robertson scale, tinnitus, trigeminal symptoms, and dizziness were systematically analyzed and compared between both treatment modalities.

**Results:**

Based on the normalized volumetry over time, surgery was more efficient than gamma knife on tumor control. While functional results regarding facial nerve and hearing preservation favored radiosurgery over surgery especially in large VS, the results were comparable in cases of smaller tumors (Class T1, T2 and T3). There was a relative advantage of surgery over radiosurgery for tinnitus, dizziness and facial hypoesthesia.

**Conclusion:**

Our results represent a further contribution to the field and offer evidence-based criteria to support the indication of one treatment modality according to patients' expectations and professional activity.

## **Zusammenfassung**

**Titel:** Retrospektive Vergleichsstudie zur mikrochirurgischen und radiochirurgischen Behandlung von Vestibularisschannomen

**Ziel:** Die Therapie von Vestibularisschwannomen gliedert sich weitestgehend in drei Teilbereiche: Mikrochirurgische Resektion des Tumors, strahlentherapeutische Behandlung oder sog. „Wait-Scan-Strategie“ womit eine Verlaufsbeobachtung des Tumorwachstums in festgelegten Intervallen gemeint ist. Eine evidenz-basierte Entscheidungshilfe im Sinne von Evidenz-Klasse-1 Studien, existiert in der medizinischen Literatur bis heute nicht. Das Hauptziel der vorliegenden Studie ist es daher, die funktionellen langfristigen Ergebnisse der strahlentherapeutischen Behandlung mit dem Gamma-Knife und der mikrochirurgische Behandlung zu vergleichen.

**Patienten und Methoden:** Die retrospektive Analyse der vorgelegten Studie beinhaltet 269 Patienten in der mikrochirurgische Gruppe und 427 Patienten in der radiochirurgischen Gruppe, mit medianen

Beobachtungszeiträumen von  $16.4 \pm 13.6$  Monaten in der mikrochirurgischen Gruppe und  $42.4 \pm 26.8$  Monaten in der radiochirurgischen Gruppe. Auswertung und statistische Evaluation von prä-therapeutischen Tumervolumen (Hannover-Klassifikation) und deren Veränderung im Behandlungsverlauf, N. Fazialis-Funktion anhand der House-Brackman-Skala, Hörfunktion anhand der Gardner-Robertson-Skala, Beurteilung eines persistierenden Tinnitus, Störungen der Sensibilität im Gesicht (N.trigeminus Affektion), sowie persistierende Schwindel-Symptomatik wurden retrospektiv analysiert.

**Ergebnisse:** Es zeigte sich im Langzeitsverlauf der Tumervolumetriebestimmung besser Ergebnisse nach mikrochirurgischer Behandlung. Die radiochirurgische Behandlung war bezogen auf den funktionellen Erhalt der N. fazialis sowie des Erhalt des auditorischen Systems insbesondere bei grösseren Tumoren der mikrochirurgischen Resektion überlegen, jedoch gilt dies nicht für kleine Tumore (Klasse T1, T2 und T3). Post-therapeutischer Tinnitus, Schwindelsymptomatik, sowie Beeinträchtigung der N.

trigeminus Funktion zeigten mit mikrochirurgischer Behandlung bessere Endergebnisse.

**Schlussfolgerungen:** Die Ergebnisse der vorgelegten Studie stellen einen weiteren nützlichen evidenz-basierten Beitrag zur Wahl der geeigneten Behandlungsmethode bei Patienten mit Vestibularisschwannomen dar.



## **Acknowledgement**

I would like to express my special appreciation and thanks to my supervisor **Professor Dr. Marcos Tatagiba**, he has been a tremendous mentor for me. I would like to thank him for encouraging my research and for allowing me to grow as a research scientist. His advice on both research as well as on my career have been priceless.

I am grateful to **Dr. Gerhard Horstmann**, Gamma Knife Center in Krefeld, he did not only accept to share us in the research, but he kindly encouraged me, and provided me with all data needed to accomplish this research.

This research was performed during my fellowship in the department of neurosurgery, Tübingen University, Germany. The fellowship was part of a cooperation program between the German Academic Exchange Service (DAAD) and the Egyptian Ministry of High Education. I am deeply grateful for the continuous support of all the members of the department of neurosurgery, Tübingen University during my fellowship, with special thanks to Dr. Guilherme Lepski for his great help and support in the process of publishing this work.

Last but not the least, I would like to thank my family: my mother, and to my brother and sisters for supporting me spiritually, they had to grudgingly learn to accept my separation from them and still gave me nothing but support, day after day. In particular, I must acknowledge my wife and best friend, Eman, without her love, encouragement and help; I would not have finished this thesis. I dedicate this thesis to the spirits of my father and my father-in-law.

## **Curriculum vitae**

**Name** Ahmed Rizk Abdel Khalek Rizk

**Place/ Date of Birth** Egypt/ 26-03-1980

**Nationality** Egyptian

### **Education**

**Bachelor of Medicine (Bachelor degree)**

**09/1997-12/2002**

*Benha University, Benha, Egypt*

**Master of Medicine (Master degree)**

**07/2004-06/2006**

*Department of neurosurgery, Benha University, Egypt*

**Doctor of Medicine (MD Degree)**

**01/2008-11/2013**

Department of neurosurgery, Ainshams University,  
Cairo, Egypt

## **Examinations**

- National Egyptian medical Examination (02/2002)**
- Deutsche Approbation, Heidelberg University (10/2012)**
- Examination of the European Association of Neurosurgery  
(03/2015)**
- Facharzt Examination in Neurosurgery, Trier, Germany  
(03/2015)**

## **Positions held**

1. Resident of neurosurgery, Benha University, dept. of neurosurgery from 10-07-2004 to 09-07-2007.
2. Assistant Lecturer of Neurosurgery, Benha University, Faculty of Medicine from 02-12-2007 till 01-04-2014.
3. Clinical Fellow of skull base surgery in Tübingen University- Germany from 01-10-2010 to 30-05-2013.
4. Resident of Neurosurgery, dept. of neurosurgery, Bruder Hospital, Trier, Germany, from 01-06-2013 till 18-03-2015.
5. Neurosurgery specialist (Facharzt), dept. of neurosurgery, Bruder Hospital, Trier, Germany, from 18-03-2015&still.

6. Lecturer of Neurosurgery, Benha University, Faculty of Medicine from 01-04-2014 & still.