

Exploring the Transition from General Ultrasound to Veterinary Ultrasound: Challenges and Opportunities

Misericordia University ~ Julie Myers, Kali Foltz

Abstract

Objective: The objective of the interview and research study was to identify the various challenges and opportunities that may be presented to an individual seeking a transition from human to veterinary ultrasound.

Methods: An interview was conducted between two senior sonography students and one experienced veterinary sonographer.

Results: The interview and research provided information and detail on the transition process, what a sonographer should know prior to the transition, and what benefits and obstacles a sonographer may encounter.

Discussion

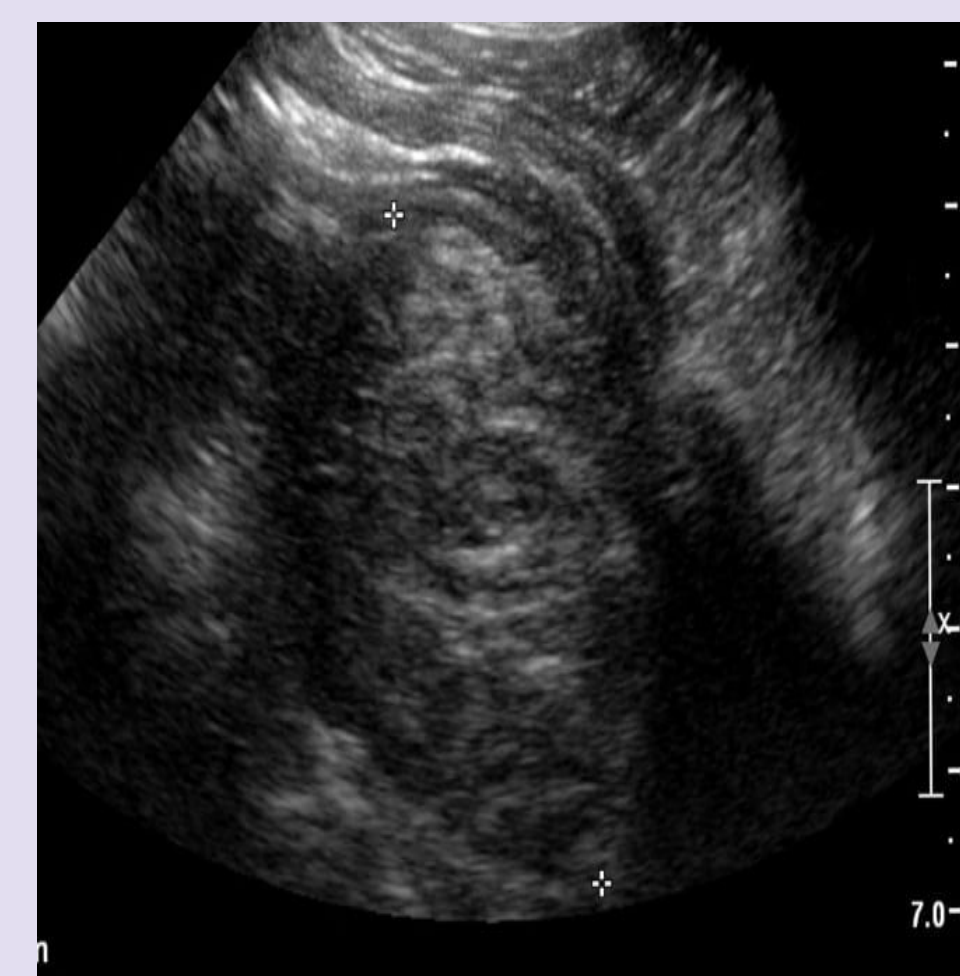
An interview and research were conducted which revealed the many similarities, challenges, and opportunities between human and veterinary sonography. Some of these include the transition process, educational background requirements, learning curves, emotional challenges, sonographic appearances, indications, follow-up imaging & care, sedation, and sonographer's role.

Similarities & Positives

- Operation of machines
- Preparation for exams
- Similar anatomy, except for some structures
- Indications
- Various patient presentations
- Can assist in biopsies and procedures

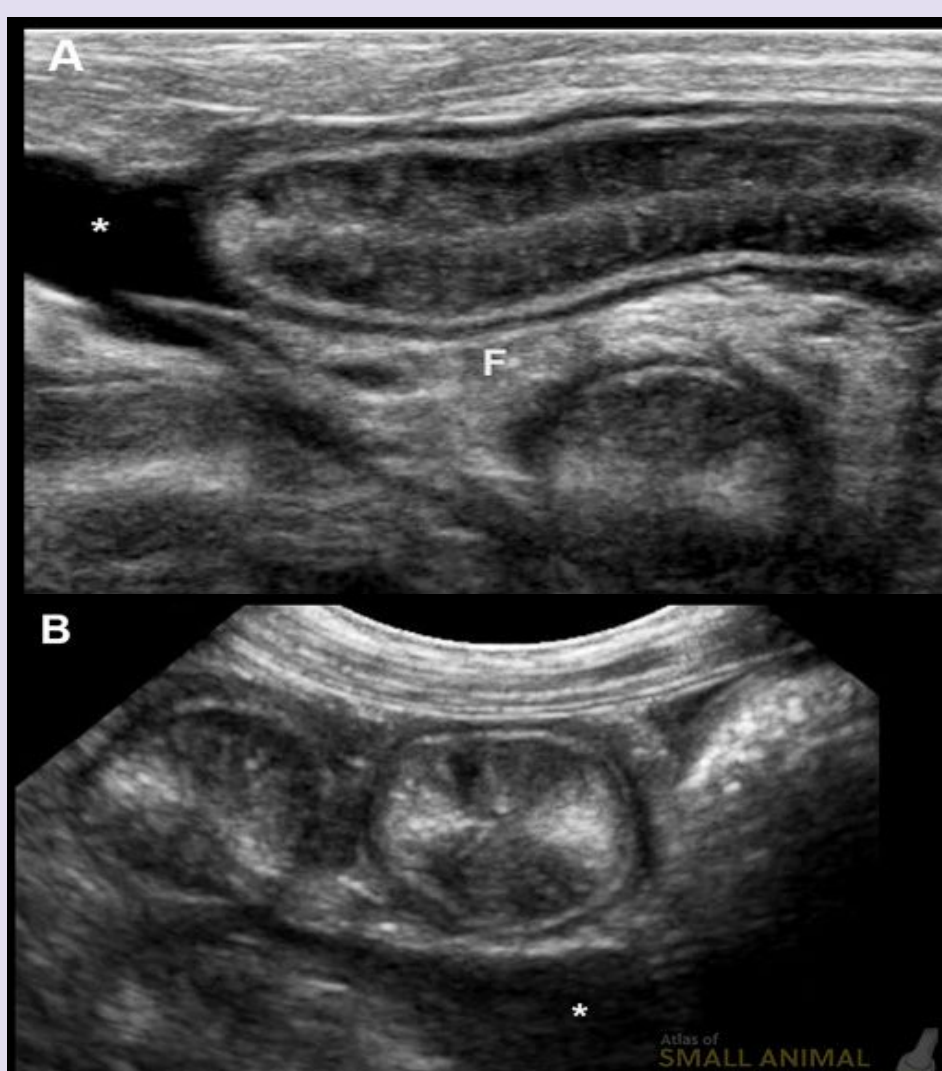
Differences & Challenges

- Emotional
- More physically demanding
- Different sonographic appearances
- Different labeling & expected velocities/measurements
- Equipment
- Safety



[Left image]: Sonographic image of a human's GI tract.

[Right image]: Longitudinal and transverse sonographic images of an animal's GI tract. Notice the clearer resolution of the bowel, borders, and striations compared to that of the human.



Benefits of Transitioning to Veterinary US

For humans

- Continuing to learn about sonography in a different way
- Experiencing new challenges
- Relief from burnout from scanning humans for a long time
- New environment

For animals

- Animals experience similar issues as humans do and require ultrasounds for diagnostic purposes.
- There is a growing need for qualified sonographers to perform exams.
- Experienced sonographers offer invaluable skills & knowledge.

Conclusion & Future Opportunities: Many similarities and differences exist between human and veterinary ultrasound, both aiding and hindering the transition between careers.

References:

d'Anjou, M.-A. (2020, March 26). *Intestinal mucosal hyperechoic striations*. Small Animal Ultrasonography. Retrieved April 17, 2023, from <https://smallanimalultrasonography.com/mucosal-hyperechoic-striations/>

Huynh, E. H. D. V. M. E., HuynhDVM, E., & BerryDVM, C. R. (2022, March 31). Ultrasonography of the gastrointestinal tract: Ileum, cecum, colon. *Today's Veterinary Practice*. Retrieved April 17, 2023, from <https://todaysveterinarypractice.com/radiology-imaging/ultrasonography-of-the-gastrointestinal-tract-ileum-cecum-colon/>