

# Are three-dimensional mapping systems useful for left bundle branch area pacing?

Eduardo Celentano, MD, FACC,<sup>\*†</sup> Barbara Ignatiuk, MD, PhD,<sup>\*</sup> Ernesto Cristiano, MD,<sup>\*</sup> Elena Bia, MD, PhD,<sup>\*</sup> Maria Lo Monaco, MD,<sup>\*</sup> Natasja M.S. de Groot, MD, PhD<sup>†</sup>

From the <sup>\*</sup>Humanitas Gavazzeni, Bergamo, Italy, and <sup>†</sup>Lowlands Institute for Bioelectric Medicine, Unit Translational Electrophysiology, Department of Cardiology, Erasmus University Medical Center, Rotterdam, The Netherlands.

## Introduction

Left bundle branch area pacing (LBBAP) has emerged as a reliable method for providing physiological pacing in patients with bradyarrhythmia and/or heart failure.<sup>1</sup> However, owing to its recent introduction in clinical practice, studies are currently underway to identify the safest and most appropriate methodology for achieving LBBAP, as well as to assess the usefulness of available tools. Three-dimensional (3D) anatomical mapping (AM) systems that do not use fluoroscopy offer an effective way to visualize cardiac activation patterns superimposed on detailed anatomical images and guide catheter maneuvering inside the heart. The use of 3D AM has been shown to be feasible and associated with a significant reduction in radiation exposure during lead implantation for permanent His bundle pacing (HBP) in simple cases.<sup>2,3</sup> However, more complex cases and those involving structural heart diseases may benefit even more. Reports on the implantation of leads for LBBAP guided by 3D AM are rare.<sup>4-7</sup> In this article, we present the first case of LBBAP guided by 3D AM with the KODEX-EPD system (EPD Solutions, Philips, Best, The Netherlands) and discuss the potential benefits of this approach in terms of safety, radiation exposure, and outcomes during the learning curve of implanters.

## Case report

A 79-year-old woman with a conventional dual-chamber pacemaker implanted in 2020 for symptomatic second-degree atrioventricular block type II and high pacing burden was referred to our institution owing to a malfunction of the right ventricle (RV) lead. The pacing threshold had increased

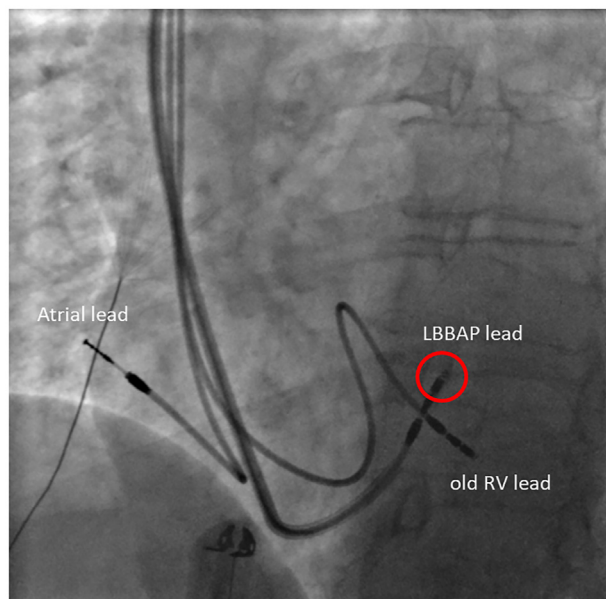
**KEYWORDS** Left bundle branch area pacing; Conduction system pacing; 3D mapping; Fluoroscopy time; Physiological pacing (Heart Rhythm Case Reports 2023; ■:1-4)

**Funding Sources:** This research did not receive any specific grant from funding agencies in the public, commercial, or not-for-profit sectors. **Disclosures:** The authors have no conflict of interest to disclose. **Address reprint requests and correspondence:** Dr Eduardo Celentano, Humanitas Gavazzeni, Bergamo, Italy. E-mail address: [eduardo.celentano@gavazzeni.it](mailto:eduardo.celentano@gavazzeni.it).

## KEY TEACHING POINTS

- The use of KODEX-EP 3D mapping system (EPD Solutions, Philips, Best, The Netherlands) in left bundle branch area pacing procedures can lead to successful and safe implantation with very low fluoroscopy. This approach can reduce the radiation exposure for patients and medical personnel.
- The 3D reconstruction of the right ventricle can facilitate the identification of the target region before pace mapping and lead screwing. This approach allows for real-time assessment of the position and depth of the lead within the septum, which can help to minimize the risk of complications.
- The anatomic approach enabled by the 3D reconstruction may have the potential to reduce the learning curve for implanters with limited experience in left bundle branch area pacing and lower the risk of complications. By providing a clear visualization of the anatomy, the system may help new implanters to more easily and accurately navigate the catheter.

to 3.5 V at 1.0 ms and the sensing amplitude had decreased to 2.5 mV. The patient agreed with LBBAP, which we considered a valid alternative to RV pacing, given the presence of an advanced atrioventricular block with a known high pacing burden, despite a nearly preserved left ventricle ejection fraction (50%). To improve the probability of favorable outcome and overall safety, we decided to use AM guidance for this procedure, as it was the first LBBAP attempt in our electrophysiology laboratory. We used the KODEX-EPD, which is a novel imaging system that uses dielectric imaging to acquire and display high-resolution anatomical images.<sup>8</sup>

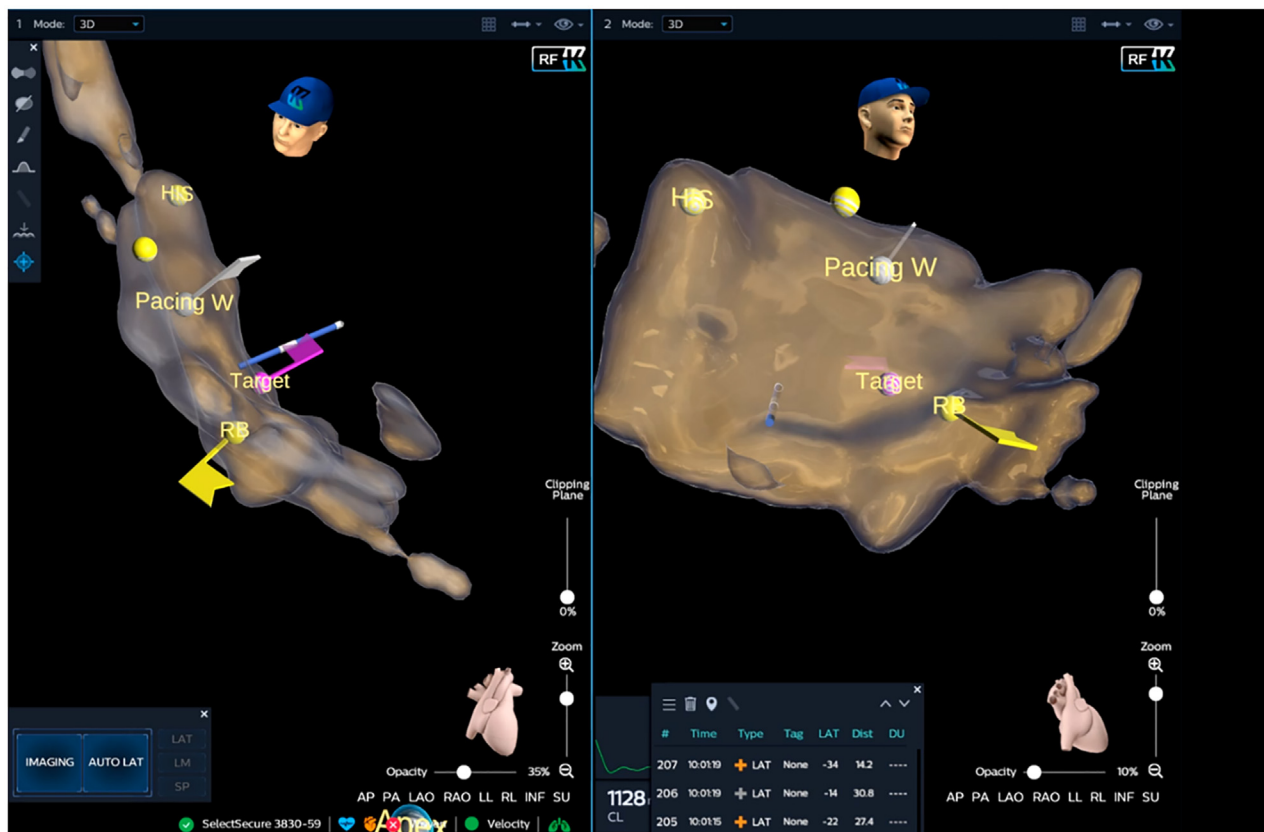

**Figure 1** Fluoroscopy image confirming full extension of the pacing lead screwing system (red circle) into the septum.

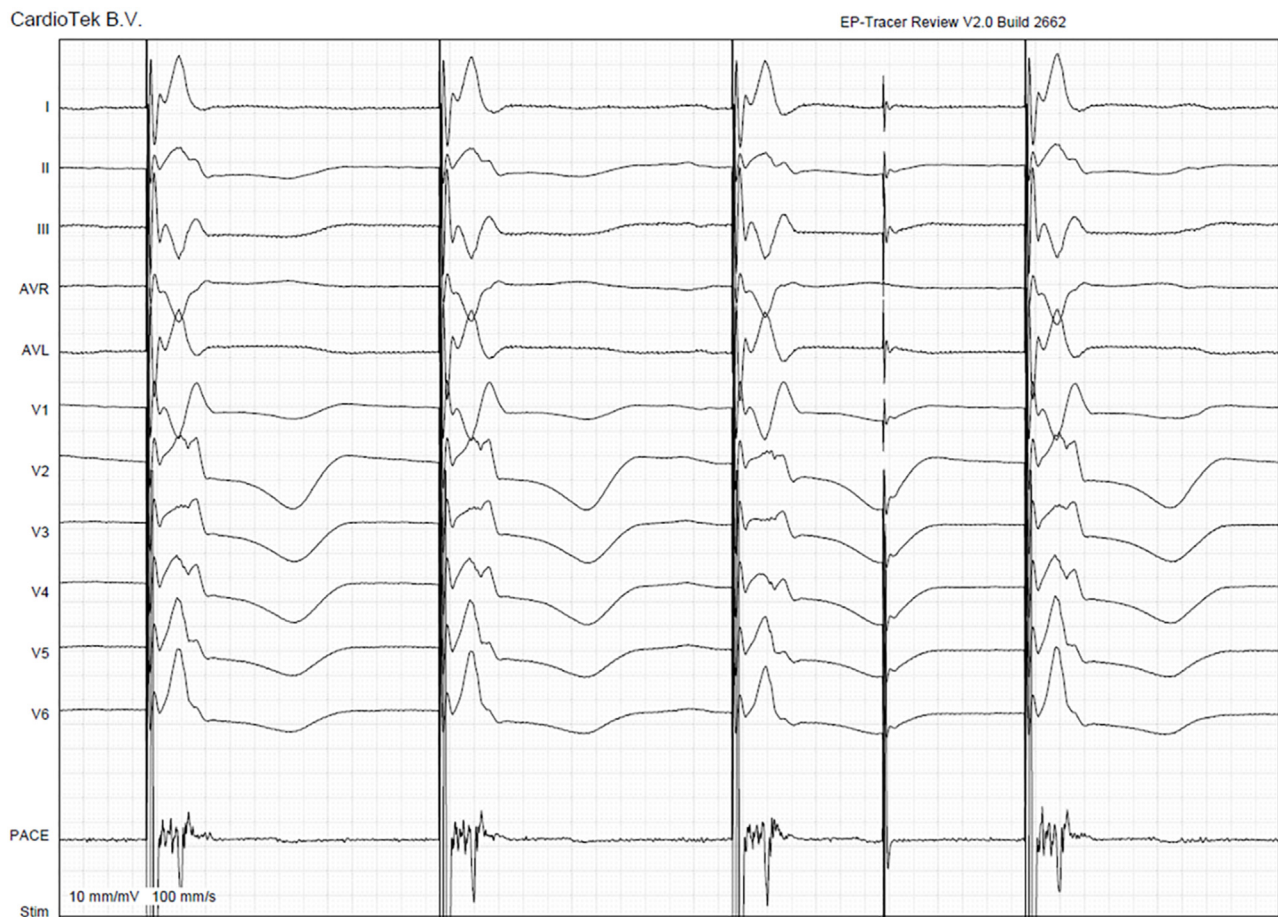Under local anesthesia, a steerable, curved, diagnostic quadripolar catheter (Biosense Webster Inc, Diamond Bar, CA) was advanced into the RV through subclavian access.

The catheter was connected to the KODEX EPD and electrophysiological workstation, which also recorded the 12-lead electrocardiogram. Using the diagnostic catheter, the RV was mapped from the tricuspid valve to the apex. The His bundle region under the tricuspid valve annulus, from which the Hisian potential could be recorded, was also marked on the 3D AM map. Subsequently, the Selectra 3D 55-42 delivery sheath (BIOTRONIK SE & Co. KG, Berlin, Germany) was prepared by flushing with saline water to activate the internal hydrophilic coating and was advanced into the RV using the provided dilator, which was then removed.

LBBAP was attempted using a 5.6F stylet-driven lead with an extendable and retractable screw for fixation (Solia S 60, BIOTRONIK SE & Co. KG). To minimize the potential risk of screw entanglement, the lead was advanced into the delivery sheath with the screw retracted. The pacing lead tip was visualized on the 3D map in bipolar configuration and guided to the target zone, which was approximately 2 cm below the His bundle region toward the RV apex. The target position was then verified with unipolar pace mapping that showed a “W” pattern in lead V<sub>1</sub>. Before screwing, contrast was injected into the delivery sheath in the left anterior oblique fluoroscopy view to confirm the perpendicular position of the lead tip to the septum. As per the recommendation for stylet-driven leads,<sup>9</sup> the screw was then fully extended during fluoroscopic imaging (**Figure 1**). Rapid



**Figure 2** Three-dimensional electrical mapping to identify left bundle branch area pacing (LBBAP) site. KODEX-EPD system (EPD Solutions, Philips, Best, The Netherlands) was used to create a 3D map of the right ventricle septal region. His bundle (HIS), right bundle (RB) branch, and target region for LBBAP were tagged prior to lead screwing. Final location of the LBBAP lead (light blue) in the septum is shown.



**Figure 3** Twelve-lead electrocardiogram and electrograms during final unipolar left bundle branch area pacing at a sweep speed of 100 mm/s. The “W” pattern can be observed in lead V<sub>1</sub> with peak left ventricular activation time of 65 ms and QRS duration of 105 ms.

screwing was performed to advance the lead tip deep into the septum. The electrocardiogram morphology during unipolar pacing was constantly monitored as the impedance changed during the screwing of the lead. Lead body rotations were applied until the QRS morphology revealed a positive terminal deflection (*r'* peak) in lead V<sub>1</sub>. In the bipolar configuration, the position of the lead within the marked target septal area was tracked and confirmed by the KODEX EPD system (Figure 2).

The delivery sheath was finally cut under minimal fluoroscopic guidance to ensure and document a stable lead position and adequate slack. The final paced QRS duration, peak left ventricular activation time, and V<sub>1</sub>–V<sub>6</sub> interpeak interval were 105 ms, 65 ms, and 40 ms, respectively (Figure 3). The LBBAP threshold was 0.8 V at 0.4 ms, with ventricular sensing greater than 10 mV and a unipolar pacing impedance of 500 ohms. LBBAP lead implantation required only 1 minute of fluoroscopy time, and no complications were observed during or after the procedure.

## Discussion

The present case showed that AM-guided LBBAP may be useful for a successful and safe procedure with low radiation exposure in the initial phase of the learning curve. There are

some potential advantages to using this approach. First, preliminarily to pace mapping and screw extension, the operator can visualize the lead tip in the reconstructed 3D geometry of the RV with very specific reference points, such as the His bundle region and RV apex, and directly navigate toward the target region. Second, since electrophysiology criteria are not 100% accurate in detecting LBBAP capture, mapping systems enable verification of the appropriateness of the final lead position and also increase the safety of the procedure. Data on LBBAP-related complications are still scarce. In the MELOS registry, complications related to the transseptal route of the lead were identified in 8.3% of patients, consisting of acute perforation to the left ventricle (3.7%) and late lead dislodgements (1.5%).<sup>1</sup>

We believe that the use of a 3D AM may help reduce the risk of these complications by determining the distance of the lead tip to other cardiac structures (ie, tricuspid valve), potentially avoiding late dislocations and enabling a real-time assessment of the depth of the lead within the septum, which potentially can be compared to the septal thickness in that region based on an echocardiogram. A perforation to the left ventricle can be a major problem owing to the associated thromboembolic risk if not acutely diagnosed. Reduction of radiation exposure is also a potential benefit of this approach.



LBBAP requires a learning curve, and it has recently been shown that the median fluoroscopy time for lead implantation is 16.0 minutes in the first 50 cases and reaches a relatively low plateau (from 4.0 to 4.5 minutes) after 100 procedures.<sup>10</sup> Using AM, we achieved our first successful LBAAP lead implantation with a fluoroscopy time as short as 1 minute. Very low radiation usage is consistent with the few published reports on AM-guided LBBAP. Using the EnSite Precision (Abbott Inc, St Paul, MN) mapping system, Vijayaraman and colleagues<sup>4</sup> and Ponnusamy and colleagues<sup>5</sup> describe successful cases with 7 minutes and 58 seconds fluoroscopy time, respectively. Coluccia and colleagues<sup>6</sup> and Giacomani and colleagues<sup>7</sup> even showed the feasibility of a zero-fluoroscopy approach for experienced operators. Beyond case reports or series, there is only 1 report on evaluation of the routine AM-guided LBBAP.<sup>11</sup> This study enrolled 32 consecutive patients with structural heart disease and advanced conduction abnormalities, reporting a 91% procedural success, absence of complications that required intervention, and a median total fluoroscopy time <1 minute.<sup>11</sup> In this study the EAM system was also the EnSite Precision.

In this case report, KODEX-EPD was used for the first time for LBBAP. This system distinguishes materials from anatomical structures and generates images based on their different dielectric properties, which are determined by their conductivity and permittivity with respect to the frequency of the electrical field. Compared to traditional impedance-based systems, this method is theoretically less susceptible to inhomogeneities in body structures and movement of organs caused by heart beats and respiration, allowing for high spatial resolution.<sup>8</sup> The KODEX-EPD has been successfully used in other HBP studies, facilitating lead implantation and significantly reducing fluoroscopy times without compromising total procedural times.<sup>12,13</sup> We used a diagnostic quadripolar catheter to create the 3D EA map of the RV, which required only a few minutes. However, previous reports using KODEX-EPD for HBP mapped the region of interest with the pacing lead alone, which may be a more efficient workflow.<sup>13</sup>

The routine use of this approach is limited by cost-effectiveness and the availability of a mapping system. Indeed, AM for HBP has been shown not to be advantageous in terms of cost-effectiveness.<sup>14</sup> More studies are required to investigate which subsets of patients would benefit from the use of a 3D AM system for LBBAP.

## Conclusion

In our LBBAP case, the novel KODEX-EP 3D mapping system was useful in achieving a successful and safe implanta-

tion procedure with very low fluoroscopy. The 3D reconstruction of the RV facilitated identification of the target region before pace mapping and lead screwing, and enabled a real-time assessment of the final position and depth of the lead within the septum using an anatomic approach. This strategy may have the potential to reduce the learning curve for implanters with limited experience in LBBAP and lower the risk of complications.

## Acknowledgments

The authors thank Antonino Spoto for technical assistance and Daniele Giacopelli for scientific advice.

## References

1. Jastrzębski M, Kielbasa G, Cano O, et al. Left bundle branch area pacing outcomes: the multicentre European MELOS study. *Eur Heart J* 2022; 43:4161–4173.
2. Sharma PS, Huang HD, Trohman RG, Naperkowski A, Ellenbogen KA, Vijayaraman P. Low fluoroscopy permanent his bundle pacing using electroanatomic mapping: a feasibility study. *Circ Arrhythm Electrophysiol* 2019; 12:e006967.
3. Richter S, Ebert M, Bertagnolli L, et al. Impact of electroanatomical mapping-guided lead implantation on procedural outcome of His bundle pacing. *Europace* 2021;23:409–420.
4. Vijayaraman P, Panikkath R, Mascarenhas V, Bauch TD. Left bundle branch pacing utilizing three dimensional mapping. *J Cardiovasc Electrophysiol* 2019; 30:3050–3056.
5. Ponnusamy SS, Bopanna D, Kumar S. Electroanatomical mapping-guided low fluoroscopy left bundle branch pacing. *JACC Clin Electrophysiol* 2020; 6:1045–1047.
6. Coluccia G, Accogli M, Panico V, Sergi C, Guido A, Palmisano P. Is it feasible to perform permanent left bundle branch area pacing, guided only by an electroanatomical mapping system? Proposal of a zero-fluoroscopy approach. *HeartRhythm Case Rep* 2022;8:233–237.
7. Giacomani S, Algarra M, Ruiz AD, Lozano JM. Zero fluoroscopy atrioventricular node ablation and left bundle branch pacing guided by electroanatomic tridimensional mapping system. *J Cardiol Cases* 2021;25:65–67.
8. Abeln BGS, van den Broek JLPM, van Dijk VF, et al. Dielectric imaging for electrophysiology procedures: the technology, current state, and future potential. *J Cardiovasc Electrophysiol* 2021;32:1140–1146.
9. De Pooter J, Wauters A, Van Heuverswyn F, Le Polain de Waroux JB. A guide to left bundle branch area pacing using stylet-driven pacing leads. *Front Cardiovasc Med* 2022;9:844152.
10. Wang Z, Zhu H, Li X, Yao Y, Liu Z, Fan X. Comparison of procedure and fluoroscopy time between left bundle branch area pacing and right ventricular pacing for bradycardia: the learning curve for the novel pacing strategy. *Front Cardiovasc Med* 2021;8:695531.
11. Richter S, Gebauer R, Ebert M, et al. Electroanatomical mapping-guided left bundle branch area pacing in patients with structural heart disease and advanced conduction abnormalities. *Europace* 2023;25:1068–1076.
12. Hua W, Liu X, Gu M, et al. Novel wide-band dielectric imaging system guided lead deployment for His bundle pacing: a feasibility study. *Front Cardiovasc Med* 2021;8:712051.
13. Scarà A, Golia P, Grieco D, et al. Low fluoroscopy permanent His bundle pacing using a new electroanatomic mapping system (KODEX EPD). A multicenter experience. *J Arrhythm* 2022;39:18–26.
14. Marini M, Ravanelli D, Martin M, et al. Is the systematic use of mapping systems during His Bundle catheter ablation cost-effective? A single-center experience. *J Arrhythm* 2020;36:720–726.