

## RECURRENT STOMAL VARICEAL BLEEDING IN CIRRHOSIS: MANAGEMENT WITH TRANSJUGULAR INTRAHEPATIC PORTOSYSTEMIC SHUNT AND EMBOLIZATION

Leandro Armani Scaffaro<sup>1</sup> , Maurício Farenzena<sup>1</sup> ,  
Mario Reis Alvares-da-Silva<sup>2,3</sup> 

### INTRODUCTION

Gastrointestinal (GI) bleeding is a common complication of cirrhosis and portal hypertension. Most cases are secondary to gastro-esophageal variceal rupture, managed endoscopically<sup>1</sup>. Stomal bleeding is rare and there's no standard therapy<sup>2</sup>. We present a case of a cirrhotic patient with recurrent stomal hemorrhage successfully treated with transjugular intrahepatic portosystemic shunt (TIPS) and stomal varices embolization.

### CASE REPORT

A 62 year-old male underwent rectal amputation plus definitive colostomy for rectal cancer in 2010. In 2016, he was diagnosed with liver cirrhosis. He remained asymptomatic until 2018, when presented episodes of GI bleeding, with hemodynamic instability, treated with terlipressin and blood transfusion. Abdominal computed tomography (CT) demonstrated cirrhosis signs (Figure 1a), and variceal veins surrounding the stoma (Figure 1b). Although he was a Child-Pugh A patient, MELD 13, and didn't present any decompensation after bleeding episodes, he wasn't considered surgical candidate for ostomy reversal, due to severe thrombocytopenia. On the other hand, cirrhosis and portal hypertension (PH) were expected to persist, and so GI bleeding were likely to relapse. The initial plan was to embolize stomal varices, but there was no splenorenal shunt to enable an access to them. TIPS was indicated to PH bleeding control. TIPS procedure was performed as standard protocol. Portography revealed significant inferior mesenteric vein varices confined to left colon and surrounding the stoma (Figure 2a). These varices were embolized with coils (Figure 2b). Portal pressures were 14 and 9 mmHg before and after TIPS delivery (Figure 3). The patient was discharged with bleeding control.

*Clin Biomed Res.* 2023;43(1):92-94

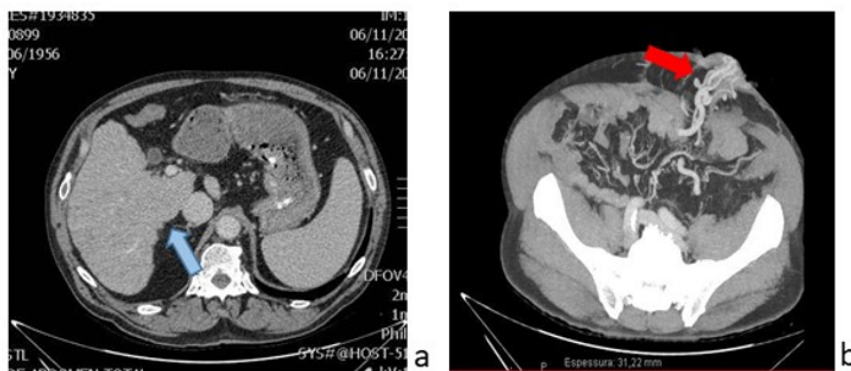
1 Unidade de Radiologia  
Intervencionista, Hospital  
de Clínicas de Porto Alegre.  
Porto Alegre, RS, Brasil.

2 Divisão de Gastroenterologia e  
Hepatologia, Hospital de Clínicas de  
Porto Alegre. Porto Alegre, RS, Brasil.

3 Programa de Gastroenterologia  
e Hepatologia, Universidade  
Federal do Rio Grande do Sul.  
Porto Alegre, RS, Brasil.

#### Corresponding author:

Leandro Armani Scaffaro  
leandroscaffaro@yahoo.com.br  
Hospital de Clínicas de Porto Alegre  
Rua Ramiro Barcelos, 2350  
90035-903, Porto Alegre, RS, Brasil.



**Figure 1:** a: Computed tomography showing typical irregular and nodular hepatic contours compatible with cirrhosis; b: Calibrous variceal veins surrounding the stoma.

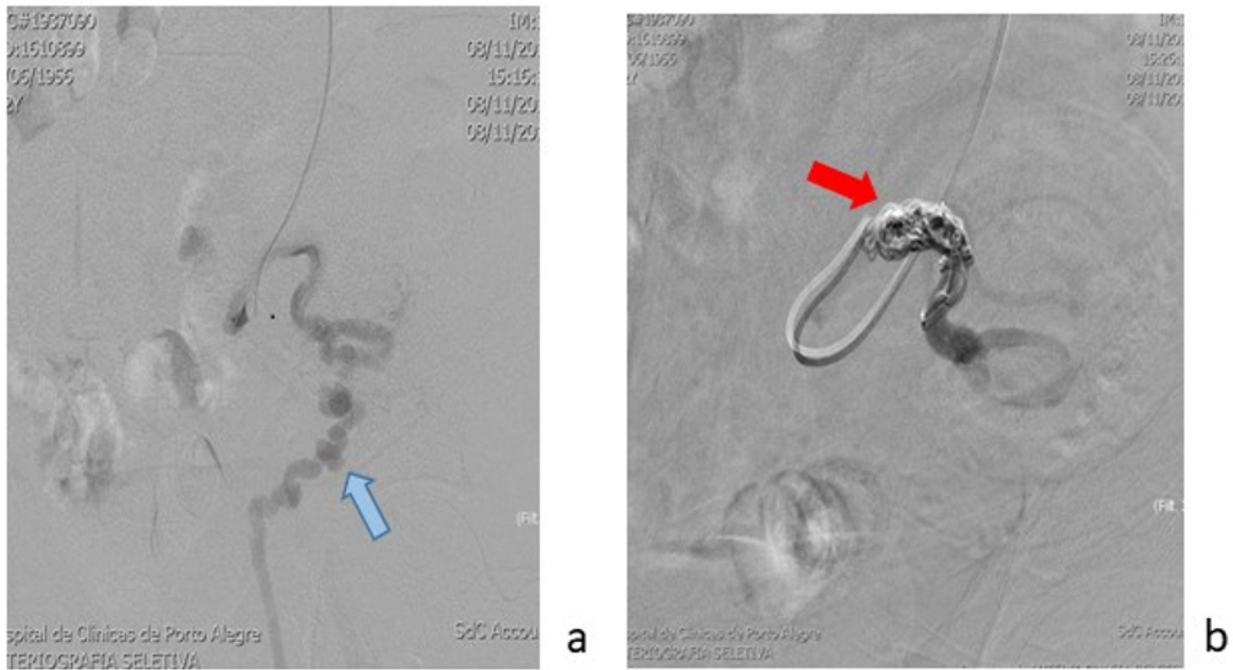

Figure 2: Digital subtraction venography after TIPS demonstrating variceal peri-stomal veins before (a) and after coil embolization (b).

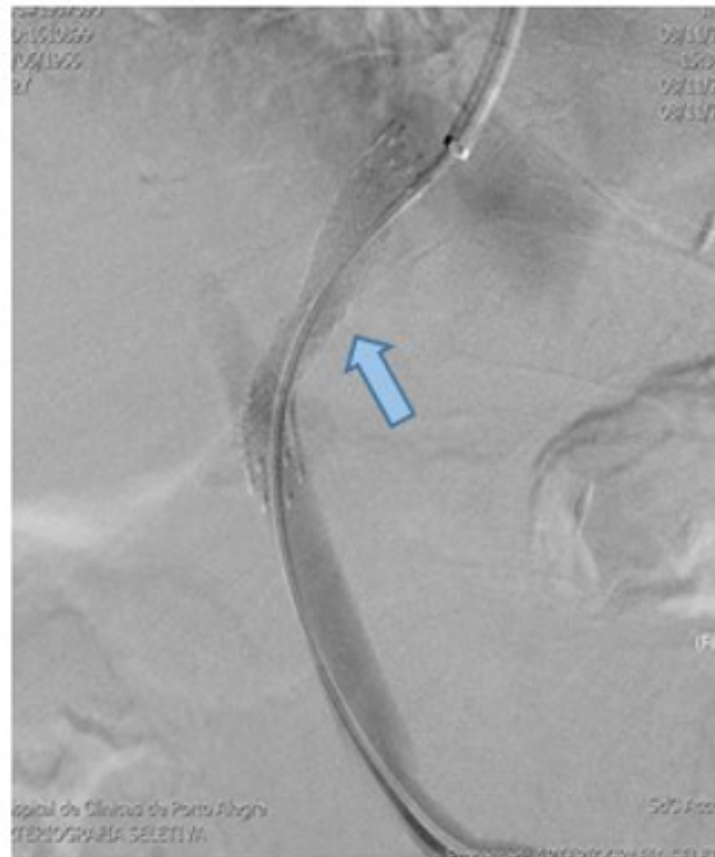


Figure 3: Digital subtraction portography showing pervious 10 mm TIPS.

## DISCUSSION

TIPS procedure is a well-established technique to PH control in uncontrolled gastroesophageal variceal bleeding. However, stomal varices are uncommon, rarely reported in the literature, and can be life threatening, with a high mortality<sup>3</sup>. There's no standard treatment for stomal bleeding, and treatment options include conservative, endoscopic, surgical or minimally invasive therapies<sup>4,5</sup>. Surgical approach is usually not indicated because of poor clinical conditions and/or decompensation risk, as well as endoscopic therapies, which are related to a high risk of GI wall necrosis. TIPS, can be used to control acute and recurrent bleeding, effectively decreasing PH and allowing approach to the varices for embolization<sup>5</sup>. Currently, there are no clear evidence that PH stomal bleeding can be controlled

by TIPS, either alone or with variceal embolization. Similar case report was recently published, describing a case of stomal bleeding controlled after TIPS and cyanoacrylate embolization, instead of coils, but in that case varices were less calibrous than in the present case<sup>2</sup>. The largest study published reported 8 cases and performed a systematic review of the literature, including 74 studies of 234 patients with stomal bleeding varices<sup>5</sup>. Authors concluded local therapy usually stops bleeding, albeit temporarily. Sclerotherapy is effective, but at the expense of unacceptable stomal damage. Decompressive therapy was required for secondary prophylaxis, including TIPS, surgical portosystemic shunts, and liver transplantation in selected cases. In conclusion, TIPS with embolization seems to be an interesting method of treating stomal varices, since they are minimal invasive procedures with rare complications.

## REFERENCES

1. Franchis R; Baveno VI Faculty. Expanding consensus in portal hypertension: report of the Baveno VI Consensus Workshop: stratifying risk and individualizing care for portal hypertension. *J Hepatol*. 2015;63(3):743-52.
2. Tran-Harding K, Winkler M, Raissi D. Bleeding stomal varices in portal hypertension. *Radiol Case Rep*. 2018;13(2):356-60.
3. Lashley DB, Saxon RR, Fuchs EF, Chin DH, Lowe BA. Bleeding ileal conduit stomal varices: diagnosis and management using transjugular transhepatic angiography and embolization. *Urology*. 1997;50(4):612-4.
4. Naidu SG, Castle EP, Kriegshauser JS, Huettl EA. Direct percutaneous embolization of bleeding stomal varices. *Cardiovasc Intervent Radiol*. 2010;33(1):201-4.
5. Spier BJ, Fayyad AA, Lucey MR, Johnson EA, Wojtowycz M, Rikkens L, et al. Bleeding stomal varices: case series and systematic review of literature. *Clin Gastroenterol Hepatol*. 2008;6(3):346-52.

Received: Jan 11, 2022

Accepted: Oct 31, 2022