


Unilateral Pelvic Lymph Node Dissection in Prostate Cancer Patients Diagnosed in the Era of Magnetic Resonance Imaging—targeted Biopsy: A Study That Challenges the Dogma

Alberto Martini , Lieke Wever, Timo F. W. Soeterik, et al. on behalf of the Young Academic Urologists Working Group on Prostate Cancer of the European Association of Urology

* Correspondence: Alberto Martini (e-mail: a.martini.md@gmail.com); Massimo Valerio (e-mail: massimo.valerio@hcuge.ch).

Full-length article available at <https://doi.org/10.1097/JU.0000000000003442>.

Study Need and Importance: The currently available clinical models for lymph node invasion (LNI) prediction are hampered by a relatively low specificity, the removed lymph nodes being negative up to 70% of the time. Up to 2016, prostate cancer (PCa) clinical staging was based mostly on digital rectal examination and prostatic biopsy according to prespecified templates, also referred to as “random” biopsy. Since then, the diagnostic pathway for prostate cancer has changed and currently consists in MRI first with subsequent targeted biopsy of the suspicious areas of the prostate along with random sampling of the gland. This represents a major step forward in managing PCa; the use of preoperative MRI provides surgeons with seminal staging information. To our knowledge, this is the first study to assess the feasibility of unilateral extended pelvic lymph node dissection (ePLND) in the era of modern PCa imaging.

What We Found: LNI contralateral to the prostatic lobe with worse tumor characteristics is rare and depends on the presence of cancer contralateral to the dominant side, its grade, and extent. Our findings provide the grounds for evaluating unilateral ePLND in future studies.

Limitations: The multi-institutional nature of our data might harbor a certain degree of unaccounted heterogeneity, especially concerning MRI acquisition, reporting, and biopsy together with the lack of external validation.

Dominant ISUP	Contralateral ISUP	Contralateral LNI
1-2	Neg biopsy or 1	1/414
2	2	3/147
3	Neg biopsy or 1	2/230
3	2	3/93
3	3	4/80

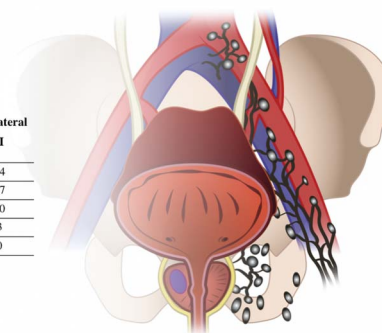


Figure. Distribution of contralateral lymph node metastases according to International Society of Urological Pathology (ISUP) grade on the dominant and contralateral sides in the absence of high-risk clinical features (prostate-specific antigen ≥ 20 ng/mL and/or extraprostatic extension or seminal vesicle invasion on multiparametric magnetic resonance imaging and/or grade group ≥ 4). LNI indicates lymph node invasion; neg, negative.

Interpretation for Patient Care: In the era of modern PCa imaging, ePLND can be omitted contralateral to the prostatic lobe with the worse tumor burden in selected patients, especially in the absence of high-risk clinical features. We propose a model for the prediction of LNI contralateral to the dominant prostate lobe that can help avoid contralateral ePLND in almost one-third of cases. Potential benefits of our model in clinical practice could be shorter operative time and lower risk of complications and costs (Figure).

Unilateral Pelvic Lymph Node Dissection in Prostate Cancer Patients Diagnosed in the Era of Magnetic Resonance Imaging—targeted Biopsy: A Study That Challenges the Dogma

Alberto Martini¹ ,^{1*} Lieke Wever,^{2,3} Timo F. W. Soeterik,² Arnas Rakauskas,⁴ Christian Daniel Fankhauser,⁵ Josias Bastian Grogg,⁵ Enrico Checcucci,⁶ Daniele Amparore,⁶ Luciano Haiquel,⁷ Lara Rodriguez-Sanchez,⁷ Guillaume Ploussard,¹ Peng Qiang,⁸ Andres Affentranger,⁸ Alessandro Marquis,⁹ Giancarlo Marra,⁹ Otto Ettala,¹⁰ Fabio Zattoni,^{11,12} Ugo Giovanni Falagario,¹³ Mario De Angelis,¹⁴ Claudia Kesch,^{15,16} Maria Apfelbeck,¹⁷ Tarek Al-Hammouri,¹⁸ Alexander Kretschmer,¹⁷ Veeru Kasivisvanathan,¹⁸ Felix Preisser,¹⁹ Emilie Lefebvre,²⁰ Jonathan Olivier,²⁰ Jan Philipp Radtke,^{15,16} Alberto Briganti,¹⁴ Francesco Montorsi,¹⁴ Giuseppe Carrieri,¹³ Fabrizio Dal Moro,^{11,12} Peter Boström,¹⁰ Ivan Jambor,¹⁰ Paolo Gontero,⁹ Peter K. Chiu,²¹ Hubert John,⁸ Petr Macek,⁷ Francesco Porpiglia,⁶ Thomas Hermanns,⁵ Roderick C.N. van den Bergh,² Jean-Paul A. van Basten,^{2,3} Giorgio Gandaglia,^{14†} and Massimo Valerio,^{22*†} on behalf of the Young Academic Urologists Working Group on Prostate Cancer of the European Association of Urology

¹Department of Urology, La Croix du Sud Hospital, Toulouse, France

²St Antonius Ziekenhuis, Nieuwegein, The Netherlands

³Department of Urology, Canisius Wilhelmina Hospital, Nijmegen, The Netherlands

⁴Department of Urology, Lausanne University Hospital and University of Lausanne, Lausanne, Switzerland

⁵Department of Urology, University Hospital Zurich, University of Zurich, Zurich, Switzerland

⁶Department of Urology, San Luigi Hospital, Turin, Italy

⁷Department of Urology, Institut Mutualiste Montsouris, Paris, France

⁸Department of Urology, Kantonsspital Winterthur, Winterthur, Switzerland

⁹Department of Urology, San Giovanni Battista Hospital, University of Turin, Turin, Italy

¹⁰Department of Urology, Turku University, Turku, Finland

¹¹Urology Unit, Academical Medical Centre Hospital, Udine, Italy

¹²Department of Surgery, Oncology, and Gastroenterology, Urology Clinic, University of Padua, Padua, Italy

¹³Department of Urology, University of Foggia, Foggia, Italy

¹⁴Unit of Urology/Division of Oncology, Urological Research Institute, IRCCS San Raffaele Hospital, Milan, Italy

¹⁵Department of Urology, University Hospital Essen, Essen, Germany

¹⁶German Cancer Consortium (DKTK)-University Hospital Essen, Essen, Germany

¹⁷Department of Urology, LMU, Munich, Germany

¹⁸Department of Urology, University College London and University College London Hospitals NHS Foundation Trust, London, United Kingdom

¹⁹Department of Urology, University Hospital Frankfurt, Frankfurt, Germany

²⁰Department of Urology, CHU Lille, Lille, France

²¹SH Ho Urology Centre, Department of Surgery, The Chinese University of Hong Kong, Hong Kong, China

²²Department of Urology, Geneva University Hospital, University of Geneva, Geneva, Switzerland

Purpose: Bilateral extended pelvic lymph node dissection at the time of radical prostatectomy is the current standard of care if pelvic lymph node dissection is indicated; often, however, pelvic lymph node dissection is performed in pN0 disease.

Submitted August 27, 2022; accepted March 21, 2023; published 000.

Support: VK's research is funded by Prostate Cancer UK and The John Black Charitable Foundation.

Conflict of Interest: AMart: Owner of shares of Oltre Medical Consulting, LLC, Toulouse, France; AK: Janssen Cilag, Bayer, Recordati; VK: Clinical Comms Group, Got IT Consulting SL, Singapore Urology Association; JPR: Astellas, Janssen Pharmaceuticals, Bayer Healthineers.

Ethics Statement: This study received Institutional Review Board approval (IRB No. GCO_21_00238). All human subjects provided written informed consent with guarantees of confidentiality.

This is an open access article distributed under the terms of the Creative Commons Attribution-Non Commercial-No Derivatives License 4.0 (CCBY-NC-ND), which permits downloading and sharing the work provided it is properly cited. The work cannot be changed in any way or used commercially without permission from the journal.

* Correspondence: La Croix du Sud Hospital, 52, Chemin de Ribaute, 31130 Quint Fonsegrives, France (telephone: +33 05 32 02 72 02; email: a.martini.md@gmail.com); Geneva University Hospital, University of Geneva, Rue Gabrielle-Perret-Gentil, 4, 1205 Geneva, Switzerland (telephone: +41 79 55 33 2 33; e-mail: massimo.valerio@hcuge.ch).

† Co-senior authors.

With the more accurate staging achieved with magnetic resonance imaging–targeted biopsies for prostate cancer diagnosis, the indication for bilateral extended pelvic lymph node dissection may be revised. We aimed to assess the feasibility of unilateral extended pelvic lymph node dissection in the era of modern prostate cancer imaging.

Materials and Methods: We analyzed a multi-institutional data set of men with cN0 disease diagnosed by magnetic resonance imaging–targeted biopsy who underwent prostatectomy and bilateral extended pelvic lymph node dissection. The outcome of the study was lymph node invasion contralateral to the prostatic lobe with worse disease features, ie, dominant lobe. Logistic regression to predict lymph node invasion contralateral to the dominant lobe was generated and internally validated.

Results: Overall, data from 2,253 patients were considered. Lymph node invasion was documented in 302 (13%) patients; 83 (4%) patients had lymph node invasion contralateral to the dominant prostatic lobe. A model including prostate-specific antigen, maximum diameter of the index lesion, seminal vesicle invasion on magnetic resonance imaging, International Society of Urological Pathology grade in the nondominant side, and percentage of positive cores in the nondominant side achieved an area under the curve of 84% after internal validation. With a cutoff of contralateral lymph node invasion of 1%, 602 (27%) contralateral pelvic lymph node dissections would be omitted with only 1 (1.2%) lymph node invasion missed.

Conclusions: Pelvic lymph node dissection could be omitted contralateral to the prostate lobe with worse disease features in selected patients. We propose a model that can help avoid contralateral pelvic lymph node dissection in almost one-third of cases.

Key Words: prostatic neoplasms, magnetic resonance imaging

EXTENDED pelvic lymph node dissection (ePLND) provides important information for staging and prognosis in newly diagnosed prostate cancer (PCa) patients. The guidelines of the European Association of Urology (EAU) and the National Comprehensive Cancer Network (NCCN) currently recommend bilateral ePLND for optimal staging of lymph node involvement (LNI) based on preoperative risk tools.^{1,2} Although the use of multivariable models and their cutoffs can substantially reduce the number of unnecessary ePLNDs with a consequent lower risk of adverse perioperative events, up to 70% of nodal dissections are “unnecessary” as they are performed in pN0 patients.³ Moreover, the therapeutic role of ePLND in patients undergoing radical prostatectomy is still under debate⁴⁻⁶; to date, ePLND has failed to clearly improve oncologic outcomes, including survival or its surrogates.^{4,7} In addition, ePLND is associated with an increased risk of morbidity, longer hospital stays, and higher costs, and should only be performed in carefully selected patients.⁸

Unfortunately, even the most modern generation of molecular imaging (prostate-specific membrane antigen [PSMA] positron emission tomography [PET]/CT) cannot yet replace ePLND due to the moderate sensitivity for detecting LNI.^{9,10} This being the case, more efficient and less burdensome strategies for ePLND are warranted. A few studies have shown that sentinel node biopsy has good diagnostic accuracy for detecting metastasis, but it might not be appropriate for PCa due to PCa’s wide lymphatic spread; moreover, its resource implications may hamper its adoption.¹¹

Unilateral node dissection in selected men might be a pragmatic and deliverable alternative. Old series

relying on random sampling of the prostate to define the side of node dissection suggest that this is not an appropriate option as contralateral lymph node metastases were identified in over 30% of cases.¹² One of the main issues related to this approach is multifocality, which is a typical feature of PCa. However, modern imaging techniques using MRI combined with targeted biopsies have improved the accuracy of defining disease aggressiveness and extension, particularly in terms of gland involvement.¹³ On these premises, we performed a study to assess the risk of contralateral LNI and to evaluate the accuracy of unilateral ePLND in the MRI era. We hypothesized that contralateral LNI depends on specific preoperative features which might be used to select candidates for unilateral pelvic lymph node dissection (PLND) among men diagnosed by MRI-targeted biopsy.

PATIENTS AND METHODS

Study Population

We relied on prospectively maintained, Institutional Review Board–approved databases. Data for the study were provided by 19 tertiary referral centers for a total of 2,359 individuals. Due to missing data, 106 patients were excluded from the study cohort.

The study was endorsed by the Young Academic Urologists Working Group on Prostate Cancer of the EAU. Centers were invited to participate if they could provide data on patients with cN0 disease who had been diagnosed and/or staged by preoperative multiparametric (mp) MRI, who had undergone radical prostatectomy with ePLND, and for whom detailed information on the LNI site was available. Overall, cN0 status was documented through conventional imaging (79%) or PSMA PET (21%) along with mpMRI information.

All patients underwent mpMRI prior to biopsy. Patients with a sole midline lesion where a dominant lobe could not be clearly identified were not eligible for the study. Imaging was performed and reported according to the Prostate Imaging-Reporting and Data System (PI-RADS) recommendations.¹⁴ All men underwent systematic plus targeted biopsy of PI-RADS ≥ 3 lesion(s) as well as radical prostatectomy between 2016 and 2021 in each tertiary referral center. Distant metastatic disease was ruled out by conventional imaging (CT scan and bone scan) or PSMA PET according to local recommendations. Men with suspicion of metastatic or nodal disease were excluded.

An ePLND was performed in patients at risk of nodal invasion according to preoperative models based on baseline characteristics.³ The ePLND template was anatomically defined and consisted of the bilateral removal of the lymph nodes overlying the external iliac artery and vein, the nodes within the obturator fossa located cranially and caudally to the obturator nerve, and the nodes medial and lateral to the internal iliac artery as per guideline recommendations.¹

mpMRI and Biopsy Technique

All patients underwent a 1.5- or 3-T mpMRI before prostate biopsy with or without an endorectal coil in compliance with the European Society of Urogenital Radiology guidelines.¹⁵ In all centers, the imaging protocol consisted of multiplanar T2-weighted images, diffusion-weighted imaging, dynamic contrast-enhanced MRI, and T1-weighted images with fat suppression; the protocol did not change substantially over the study period. Images were read and reported according to the PI-RADS guidelines by high-volume, dedicated radiologists.^{14,15} The PI-RADS v.2 has been used since 2016.¹⁴ Radiologists were not blinded to the PSA values and other clinical characteristics while reporting the scans.

All lesions with a PI-RADS score of ≥ 3 on mpMRI were subject to targeted biopsy. A minimum of 2 targeted cores per lesion were obtained. Biopsies were performed by experienced urologists with the use of real-time transrectal ultrasound guidance with or without software-based magnetic resonance/ultrasound fusion. All systematic cores were taken at the time of fusion biopsy outside the MRI-targeted area(s) according to standard protocols.

Outcomes and Covariates

The main outcome of the study was the presence of LNI on final pathology, defined as the presence of tumor cells within one or more lymph node(s) on final pathology. This outcome was analyzed ipsilateral and contralateral to the “dominant side” of the prostate. For the purpose of our analyses, we considered the 2 lobes of the prostate separately, as previously described.¹⁶⁻¹⁹ By definition, the dominant side was the lobe with worse disease features in terms of locally advanced disease on mpMRI, higher International Society of Urological Pathology (ISUP) grade, or tumor burden. Specifically, we considered the following factors hierarchically to define the dominant lobe: ISUP grade > percentage of positive cores > seminal vesicle invasion (SVI) > extraprostatic extension (EPE).²⁰ As an example, in case of equal ISUP on both sides, the dominant lobe was the one with higher tumor burden; in case

of equal ISUP and tumor burden, the dominant lobe was the one with SVI, if present, or EPE.

Patient stratification into risk groups was realized by adapting the D’Amico risk criteria¹³; specifically, the presence of PSA ≥ 20 ng/mL and/or EPE or SVI on mpMRI and/or ISUP ≥ 4 denoted high-risk PCa.

All patients included in the quantitative analysis had complete clinical, mpMRI, biopsy, and pathology data. The prostatic volume was measured on mpMRI. Imaging variables were considered as side specific and comprised, for each side: highest PI-RADS score, greater lesion’s diameter with the highest PI-RADS, number of lesions, EPE, and SVI. Regarding highest side-specific biopsy ISUP, we evaluated ISUP on both targeted and systematic biopsy.

EPE reporting (coded as side specific) was left to the discretion of the reporting radiologists and was based on any of the following criteria: presence of neurovascular bundle thickening, abutment, bulge, loss of or irregular prostatic capsule, capsular enhancement, or measurable extraprostatic disease detected at high-volume T2-weighted images. SVI (coded as side specific) was defined as: low signal intensity of T2-weighted images and/or abnormal contrast enhancement within or along the seminal vesicle, obliteration of the angle between the prostatic base and the SV, and presence of tumor extension from the prostate to the seminal vesicle.

Biopsy data were also side specific. This entailed for each side: ISUP, total positive core length in mm, and percentage of positive cores.

Statistical Analyses

To investigate differences between patients with contralateral LNI and those without, we used the Kruskal-Wallis test and χ^2 , respectively. In an effort to evaluate when to perform unilateral ePLND, a binary multivariable logistic regression model was fit to predict contralateral LNI. We evaluated the role of nondominant tumor characteristics, namely, ISUP grade (0-2 vs 3 vs 4-5) and percentage of positive cores, in predicting contralateral LNI by adjusting for proxies of worse disease features. The latter included: PSA, maximum index lesion’s diameter and SVI on mpMRI. Initially, we also considered the role of EPE on mpMRI in the multivariable model, yet, given the fact that this variable was not statistically significant when considered together with SVI on mpMRI, together with the fact that EPE is partly captured by SVI, EPE was not considered further. Since the database encompassed data from different institutions, we included institution clustering in the logistic regression using a generalized estimating model through the cluster function in Stata. A nomogram was then built based on the coefficients of the logit function. We performed internal validation through the leave-one-out cross-validation. The predicted probability, after internal validation, was used to calculate the area under the receiver operator curve (AUC), to assess calibration, and the net benefit associated with its use applying a decision curve analysis. We performed a systematic analysis of different thresholds of contralateral LNI risk, starting from 1% with increments of 0.5%.

Additionally, to confirm our hypothesis that the presence of tumor contralateral to the index lesion along with its extent and features are the major drivers of contralateral LNI, we added to the contralateral LNI model

ISUP grade on the dominant side as covariate. Given its nature, this second model is nested within the first one. The likelihood ratio test was adopted to evaluate the goodness of fit of the models.

Statistical analyses were performed on Stata 14. All tests were 2-sided, with a significance level set at $P < .05$.

RESULTS

Population Characteristics

Overall, 2,253 patients were considered. Descriptive characteristics of the patient population are provided in Table 1. The median (IQR) number of removed lymph nodes was 16 (11-22); the median number of removed lymph nodes per side was 8. LNI was documented in 302 (13%) patients: 225 (10%) had unilateral LNI and 69 (3%) bilateral LNI; in 8 (0.3%) patients, LNI was documented solely in the anterior periprostatic fat.

Overall, 211 (9%) men had LNI ipsilateral to the dominant lobe and 43 (4%) men had LNI contralateral to the dominant prostatic lobe. Compared to patients with no LNI or LNI ipsilateral to the

dominant side, individuals with contralateral LNI had higher PSA, greater prostate volume, a higher rate of unilateral or bilateral EPE and SVI on mpMRI, a greater index lesion's maximum diameter, a higher ISUP grade on both the dominant and nondominant side, and a higher rate of positive cores in the nondominant side (all $P \leq .03$). Additionally, on final pathology patients with contralateral LNI had a higher T stage and ISUP grade (both $P < .001$).

A total of 1,289 (57%) individuals had high-risk features based on modified D'Amico criteria.¹³ Among the 83 men with LNI contralateral to the dominant side, 70 (84%) had high-risk clinical features; among them LNI was bilateral in 59 cases.

In the absence of high-risk features, 1 patient out of 414 with grade group 1-2 PCa in the dominant side and without contralateral significant disease (grade group 1 or negative biopsy) had LNI contralateral to the dominant side. Figure 1 displays the distribution of contralateral lymph node metastases according to ISUP grade on the dominant and contralateral side.

Table 1. Descriptive Characteristics of the Patients Constituting the Development Cohort According to Lymph Node Invasion Contralaterally to the Dominant Prostate Lobe

	No LNI, n=1,959 (87%)	LNI ipsilateral to dominant side, n=211 (9%)	LNI contralateral to dominant side, n=83 (4%)	P value
Age at surgery, median (IQR), y	67 (62, 71)	66 (62, 70)	66 (61, 69)	.3
PSA, median (IQR), ng/mL	8 (5.6, 12.5)	11 (7.1, 17.7)	14.5 (8.8, 24.0)	< .001
Prostate volume on mpMRI, median (IQR), mL	40 (31, 54)	43 (31, 58)	45 (35, 60)	.03
ECE on mpMRI, No. (%)				
Absent	1,397 (71)	110 (52)	41 (49)	< .001
Unilateral	495 (25)	85 (40)	31 (37)	
Bilateral	67 (3)	16 (8)	11 (13)	
SVI on mpMRI, No. (%)				
Absent	1,845 (94)	177 (84)	57 (69)	< .001
Unilateral	97 (5)	27 (13)	18 (22)	
Bilateral	17 (1)	7 (3)	8 (10)	
Index lesion's maximum diameter on mpMRI, median (IQR), mm	13 (9, 17)	16 (13, 22)	20 (14, 28)	< .001
ISUP grade dominant side, No. (%)				
1	147 (8)	7 (3)	1 (1)	< .001
2	662 (34)	39 (18)	11 (13)	
3	532 (27)	61 (29)	21 (25)	
4	438 (22)	54 (26)	20 (24)	
5	180 (9)	50 (24)	30 (36)	
ISUP grade nondominant side, No. (%)				
Negative biopsy	882 (45)	88 (42)	13 (16)	< .001
1	372 (19)	27 (13)	5 (6)	
2	425 (22)	40 (19)	15 (18)	
3	152 (8)	24 (11)	19 (23)	
4	95 (5)	17 (8)	11 (13)	
5	33 (2)	15 (7)	20 (24)	
Percentage positive cores nondominant side, median (IQR) ^a	29 (17, 50)	40 (17, 67)	57 (33, 80)	< .001
Pathological T stage, No. (%)				
2	1,096 (56)	44 (21)	3 (4)	< .001
3a	657 (34)	78 (37)	19 (23)	
3b	206 (11)	89 (42)	61 (73)	
Pathological ISUP grade, No. (%)				
1	93 (5)	5 (2)	1 (1)	< .001
2	748 (38)	29 (14)	7 (8)	
3	748 (38)	78 (37)	25 (30)	
4	204 (10)	37 (18)	12 (14)	
5	166 (8)	62 (29)	38 (46)	

Abbreviations: ECE, _; IQR, interquartile range; ISUP, International Society of Urological Pathology; LNI, lymph node invasion; mpMRI, multiparametric magnetic resonance imaging; PSA, prostate-specific antigen; SVI, seminal vesicle invasion.

^a Calculated in case of positive biopsy.

Dominant ISUP	Contralateral ISUP	Contralateral LNI
1-2	Neg biopsy or 1	1/414
2	2	3/147
3	Neg biopsy or 1	2/230
3	2	3/93
3	3	4/80

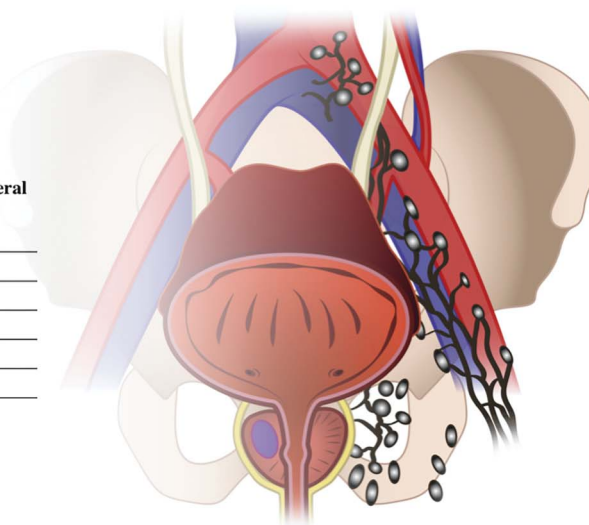


Figure 1. Distribution of contralateral lymph node metastases according to International Society of Urological Pathology (ISUP) grade on the dominant and contralateral sides in the absence of high-risk clinical features (prostate-specific antigen ≥ 20 ng/mL and/or extraprostatic extension or seminal vesicle invasion on multiparametric magnetic resonance imaging and/or grade group ≥ 4). LNI indicates lymph node invasion; neg, negative.

Contralateral LNI Prediction

Table 2 displays the multivariable binary logistic regression analysis predicting LNI contralateral to the dominant prostate side. A model including PSA, maximum diameter of the index lesion, presence of SVI on mpMRI, ISUP grade in the nondominant side, and percentage of positive cores in the nondominant side achieved an AUC of 84% (95% CI:80%-88%). Figure 2 displays the nomogram; the coefficients of the logit function are provided in Supplemental Table 1 (<https://www.jurology.com>). The benefit derived from applying the model in clinical practice according to the decision curve analysis method is shown in Figure 3, A and the calibration plot in Figure 3, B. The nomogram-derived probability of contralateral LNI showed greater net clinical benefit

Table 2. Multivariable Binary Logistic Regression Analysis Predicting Lymph Node Invasion Contralaterally to the Dominant Prostate Side

Covariate	Odds ratio	95% CI	P value
PSA	1.01	1.00,1.02	.005
Index lesion's maximum diameter on mpMRI, mm	1.05	1.03,1.07	< .001
SVI on mpMRI			
Absent	1		
Unilateral or bilateral	2.43	1.37,4.32	.002
ISUP grade nondominant side			
None or 1-2	1		
3	3.04	1.99,4.64	< .001
4-5	4.34	2.88,6.53	< .001
Percentage positive cores nondominant side	1.01	1.00,1.02	.01

Abbreviations: CI, confidence interval; ISUP, International Society of Urological Pathology; mpMRI, multiparametric magnetic resonance imaging; PSA, prostate-specific antigen; SVI, seminal vesicle invasion.

relative to the hypothetical scenarios of always performing contralateral ePLND or never, and demonstrated excellent calibration within the same range of probability. Table 3 shows the systematic analysis of the nomogram-derived cutoffs. This Table represents an outline for helping surgeons when deciding whether or not to perform ePLND contralateral to the index lesion. For example, with a cutoff of 1%, 602 (27%) contralateral lymph node dissections would be omitted with 1 (1.2%) contralateral LNI missed. Among patients who fell below the cutoff of 1%, LNI ipsilateral to the dominant lobe was documented in 33 individuals.

Sensitivity Analysis

To confirm our hypothesis, ie, that the presence of tumor contralateral to the index lesion, its extent, and grade represent major drivers of contralateral LNI, we carried out a sensitivity analysis by adding as a covariate to the model the ISUP grade on the dominant side (1-2 vs 3 vs 4-5). The model is shown in Supplemental Table 2 (<https://www.jurology.com>). Upon adding the ISUP grade in the dominant side, contralateral ISUP remained a significant predictor, whereas ISUP grade in the dominant side was not found to be a significant predictor of contralateral LNI (LR test: $P = .5$).

DISCUSSION

Despite the significant improvements that have been made over time to achieve better LNI prediction, the specificity of available models is still unsatisfactory.³ In addition, the therapeutic risk-to-benefit ratio of bilateral ePLND is poor. While the risks associated

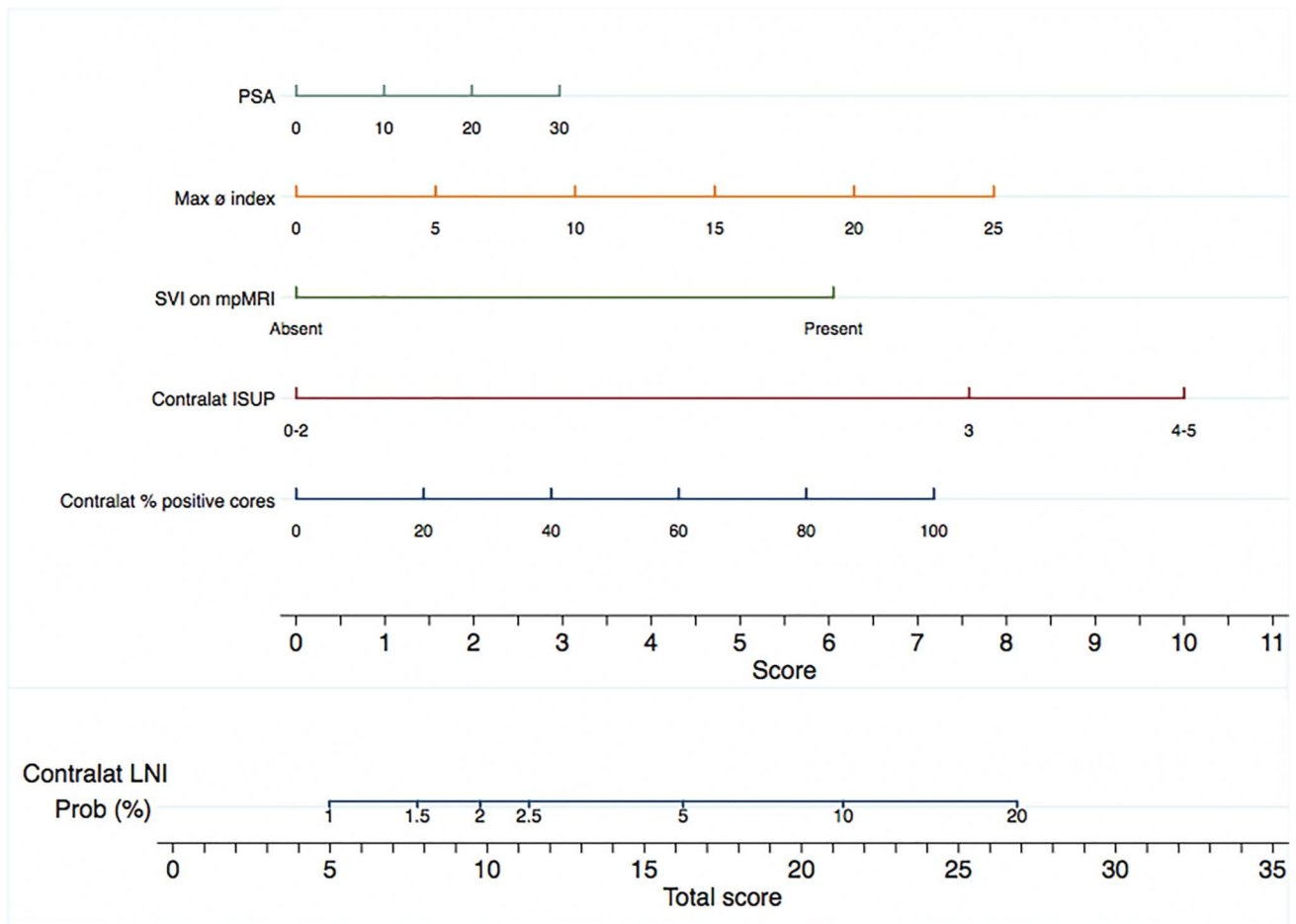


Figure 2. Nomogram for the prediction of lymph node invasion (LNI) contralateral to the prostatic lobe with worse disease features. Instructions: Locate the patient's preoperative prostate-specific antigen (PSA) on the corresponding axis. Draw a line straight downward to the score axis to determine how many points toward the probability of contralateral LNI the patient receives for his preoperative PSA. Repeat the process for each additional variable. Sum the points for each of the predictors. Locate the final sum on the total score axis. Draw a line straight up to find the patient's probability of contralateral LNI. Contralat indicates contralateral; ISUP, International Society of Urological Pathology; Max, maximum; mpMRI, multiparametric magnetic resonance imaging; Prob, probability; SVI, seminal vesicle invasion.

with bilateral ePLND are clearly measurable in terms of higher costs and increased operative time and complications, the therapeutic benefit is yet to be determined as no concrete survival advantage deriving from ePLND has been proven.⁴ Additionally, in the majority of cases the removed lymph nodes are found to be free from disease, and when nodal involvement is documented, this is rarely bilateral as our data show. The same concept has been tested in other urological malignancies where, although bilateral nodal involvement is difficult to exclude, unilateral LND has been explored.^{21,22}

Since the adoption of an image-based clinical pathway based on mpMRI and targeted biopsy, better tumor characterization in terms of aggressiveness and local extent has been achieved.²³⁻²⁵ These improvements provided us with the grounds for hypothesizing that unilateral ePLND can be envisioned in certain cases. We evaluated whether preoperative biological, imaging, and pathological characteristics

analyzed in a side-specific manner could decrease the need for bilateral ePLND in favor of an ePLND ipsilateral to the dominant prostatic side.

Our analyses demonstrate that a cancer's grade and burden in the nondominant side are strong predictors of LNI contralateral to the dominant side. This was confirmed on sensitivity analysis where tumor grade in the dominant side was not a significant predictor of contralateral LNI when added to the final model, which includes contralateral tumor grade. After presenting the LNI pattern in our cohort, we developed a model for the prediction of LNI contralateral to the dominant prostatic lobe. The model achieved high discrimination in terms of AUC, corroborating the fact that the cancer's grade and burden in the nondominant side are important predictors of LNI contralateral to the dominant side.

Presently, there is no agreement between major guidelines, eg, EAU and NCCN, on the indication for ePLND.^{1,2} While they both recommend relying

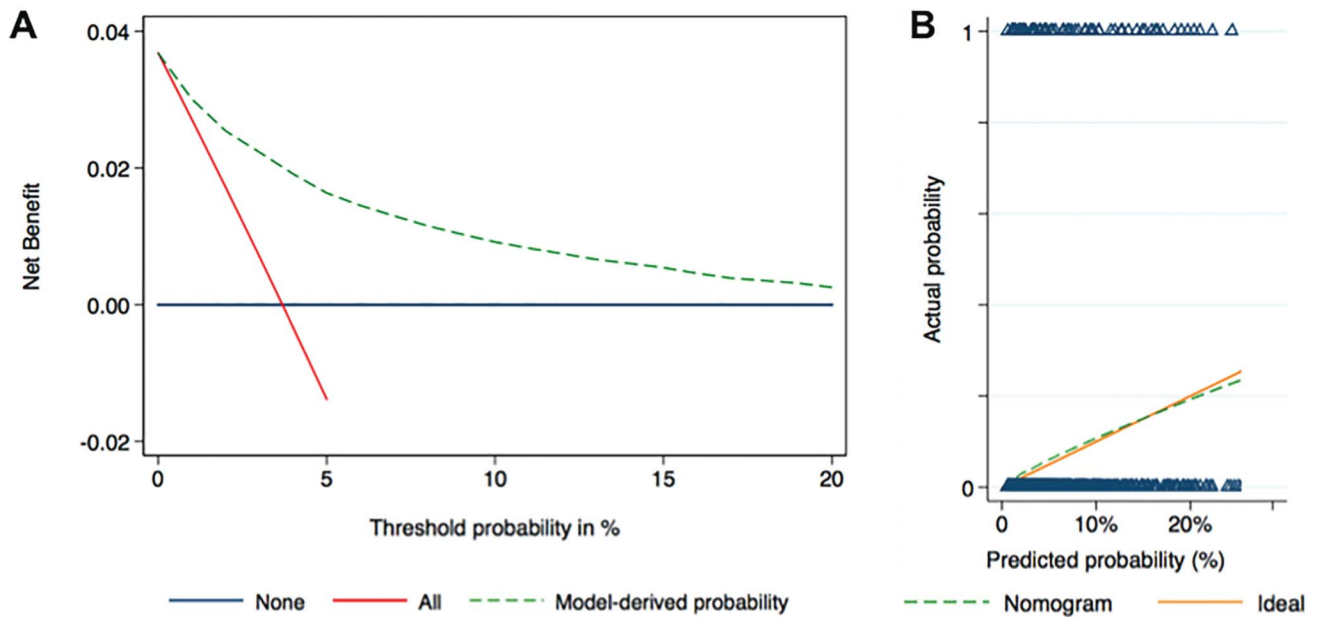


Figure 3. A, Decision curve analysis demonstrating the net benefit associated with the use of the nomogram-derived probability for lymph node invasion contralateral to the prostatic lobe with worse disease features vs the 2 hypothetical scenarios of always or never performing contralateral lymph node dissection. B, Calibration plot of observed vs predicted probability of contralateral lymph node invasion of the nomogram.

on preoperative risk tools to decide whether or not to perform ePLND, the NCCN guidelines recommend using the Memorial Sloan Kettering (MSK) nomogram, while the EAU guidelines recommend relying on one of the available externally validated tools, the MSK nomogram being one of them. Yet many of the currently available tools, including the MSK nomogram, do not reflect the current standard of care for PCa diagnosis, which now encompasses mpMRI and targeted biopsy. Not accounting for this information might lead to underestimation of the LNI risk as the comparison with models that integrate mpMRI and targeted findings demonstrates.³ Yet, bearing in mind the fact that there is no overall global standard for deciding when to perform ePLND, our model was developed in a way that can be applied in any case in which PLND is indicated irrespective of the preoperative model used, if any. Its implementation in practice could allow avoiding bilateral ePLND in almost one-third of cases. Reducing the rate of bilateral ePLND

could potentially lower the operative time and rate of complications while reducing the length of hospital stay, leading ultimately to lower overall costs. These outcomes along with recurrence data need to be evaluated in prospective series and/or a randomized controlled trial. Indeed, the implementation of our approach needs to be weighted relative to recurrences that are associated with high overall costs for health systems. Notably, the 1 patient in the development cohort who was below the 1% cutoff with a theoretically missed contralateral LNI had organ-confined disease on imaging and pathology with ISUP 2 on biopsy and pathology. LNI in this context is a rare occurrence, especially if contralateral, as our data demonstrate.

Presently, the role of PLND, its extent, and indications are a matter of controversy, as reflected by the lack of worldwide agreement on this subject.^{1,2,4} A recent randomized trial evaluated the effect of limited PLND vs ePLND on oncologic outcomes.²⁶

Table 3. Systematic Analysis of the Contralateral Lymph Node Invasion Nomogram-derived Cutoffs, After Leave-One-Out Cross-validation, to Provide Surgeons With an Outline for Performing Unilateral or Bilateral Extended Pelvic Lymph Node Dissection

Cutoff for contralateral LNI, (%)	Patients in whom unilateral ^a ePLND is recommended (below cutoff)			Patients in whom bilateral ePLND is recommended (above cutoff)		
	Overall, No. (%)	No LNI, No. (%)	LNI, No. (%)	Overall, No. (%)	No LNI, No. (%)	LNI, No. (%)
1	602 (27)	601 (99)	1 (1.2)	1,651 (73)	1,569 (95)	82 (98.8)
1.5	1,291 (57)	1,281 (99)	10 (12)	962 (43)	889 (92)	73 (88)
2	1,541 (68)	1,527 (99)	14 (17)	712 (32)	643 (90)	69 (83)
2.5	1,662 (73)	1,645 (99)	17 (21)	591 (27)	525 (89)	66 (79)

Abbreviations: ePLND, extended pelvic lymph node dissection; LNI, lymph node invasion.

^a Unilateral ePLND refers to ePLND ipsilaterally to the prostatic lobe with the index lesion.

Even though the authors found no overall benefit of one approach over the other, they reported that ePLND was associated with better biochemical recurrence-free survival among patients with ISUP 3-5.²⁶ While PLND is associated, to some extent, with some degree of overtreatment, especially among lower-risk groups, our proposed approach might improve the therapeutic ratio of ePLND.

The strength of this model lies in its large contemporary multicenter cohort. The diagnostic PCa pathway was homogeneous across all centers and included mpMRI, systematic plus MRI-targeted biopsy in case of visible lesion(s), which reflects the current standard of care.^{1,2} To the best of our knowledge, this is the first time that the feasibility of unilateral ePLND has been evaluated in the era of mpMRI-targeted biopsy.

At present, our study lacks external validation. We also acknowledge the lack of data on correlation between biopsy findings and side-specific pathological ISUP and the fact that some patients were staged also with PSMA. Patients with a pure midline lesion where a dominant lobe could not be identified were not considered eligible for the study, yet those

patients represent a minority.^{27,28} Another limitation is the lack of information about lesion location at a zonal level. Transitional and peripheral zone lesions may spread and behave differently.^{29,30} Additionally, the multi-institutional nature of our data might harbor a certain degree of unaccounted heterogeneity, especially concerning MRI acquisition, reporting, and biopsy. Although all centers were tertiary referral centers, this heterogeneity might influence the results and compromise their generalizability to low-volume centers.

CONCLUSIONS

The presence of tumor in the prostatic lobe contralateral to the side with worse disease features, along with its grade and extent, are predictors of contralateral LNI. An ePLND could be omitted contralateral to the dominant side in selected patients, especially in the absence of high-risk clinical features. We propose a model that with a 1% threshold probability of LNI can help to avoid contralateral ePLND in almost one-third of the cases. Our findings warrant external validation.

REFERENCES

1. European Association of Urology. *Guidelines: Prostate Cancer*. 2022. <https://uroweb.org/guideline/prostate-cancer/>.
2. National Comprehensive Cancer Network. *Guidelines: Prostate Cancer*; 2022.
3. Gandaglia G, Martini A, Ploussard G, et al. External validation of the 2019 Briganti nomogram for the identification of prostate cancer patients who should be considered for an extended pelvic lymph node dissection. *Eur Urol*. 2020;78(2):138-142.
4. Fossati N, Willemse PM, Van den Broeck T, et al. The benefits and harms of different extents of lymph node dissection during radical prostatectomy for prostate cancer: a systematic review. *Eur Urol*. 2017;72(1):84-109.
5. Abdollah F, Gandaglia G, Suardi N, et al. More extensive pelvic lymph node dissection improves survival in patients with node-positive prostate cancer. *Eur Urol*. 2015;67(2):212-219.
6. Froehner M, Wirth MP. Re: more extensive pelvic lymph node dissection improves survival in patients with node-positive prostate cancer. *Eur Urol*. 2015;67(6):e112.
7. Preisser F, van den Bergh RCN, Gandaglia G, et al. Effect of extended pelvic lymph node dissection on oncologic outcomes in patients with D'Amico intermediate and high risk prostate cancer treated with radical prostatectomy: a multi-institutional study. *J Urol*. 2020;203(2):338-343.
8. Oderda M, Diamand R, Albisinni S, et al. Indications for and complications of pelvic lymph node dissection in prostate cancer: accuracy of available nomograms for the prediction of lymph node invasion. *BJU Int*. 2021;127(3):318-325.
9. van Kalmthout LWM, van Melick HHE, Lavalaye J, et al. Prospective validation of gallium-68 prostate specific membrane antigen-positron emission tomography/computerized tomography for primary staging of prostate cancer. *J Urol*. 2020;203(3):537-545.
10. Perera M, Papa N, Roberts M, et al. Gallium-68 prostate-specific membrane antigen positron emission tomography in advanced prostate cancer—updated diagnostic utility, sensitivity, specificity, and distribution of prostate-specific membrane antigen-avid lesions: a systematic review and meta-analysis. *Eur Urol*. 2020;77(4):403-417.
11. Wit EMK, Acar C, Grivas N, et al. Sentinel node procedure in prostate cancer: a systematic review to assess diagnostic accuracy. *Eur Urol*. 2017;71(4):596-605.
12. Schiavina R, Gacci M, Briganti A, et al. Can side-specific biopsy findings predict the side of nodal metastasis in clinically localized prostate cancer? Results from a multicenter prospective survey. *Eur J Surg Oncol*. 2013;39(9):1019-1024.
13. Martini A, Soeterik TFW, Haverdings H, et al. An algorithm to personalize nerve sparing in men with unilateral high-risk prostate cancer. *J Urol*. 2022;207(2):350-357.
14. Barentsz JO, Weinreb JC, Verma S, et al. Synopsis of the PI-RADS v2 guidelines for multiparametric prostate magnetic resonance imaging and recommendations for use. *Eur Urol*. 2016;69(1):41-49.
15. Barentsz JO, Richenberg J, Clements R, et al. ESUR prostate MR guidelines 2012. *Eur Radiol*. 2012;22(4):746-757.
16. Ohori M, Kattan MW, Koh H, et al. Predicting the presence and side of extracapsular extension: a nomogram for staging prostate cancer. *J Urol*. 2004;171(5):1844-1849.
17. Martini A, Gupta A, Lewis SC, et al. Development and internal validation of a side-specific, multiparametric magnetic resonance imaging-based nomogram for the prediction of extracapsular extension of prostate cancer. *BJU Int*. 2018;122(6):1025-1033.
18. Soeterik TFW, van Melick HHE, Dijkstra LM, et al. Development and external validation of a novel nomogram to predict side-specific extraprostatic extension in patients with prostate cancer undergoing radical prostatectomy. *Eur Urol Oncol*. 2022;5(3):328-337.
19. Nyarangi-Dix J, Wiesenfarth M, Bonekamp D, et al. Combined clinical parameters and multiparametric magnetic resonance imaging for the prediction of extraprostatic disease—a risk model for patient-tailored risk stratification when planning radical prostatectomy. *Eur Urol Focus*. 2020;6(6):1205-1212.
20. Chierigo F, Borghesi M, Wurnschimmel C, et al. Contemporary pathological stage distribution

- after radical prostatectomy in North American high-risk prostate cancer patients. *Clin Genitourin Cancer*. 2022;20(5):e380-e389.
21. Kiss B, Paerli M, Schonendorf D, Burkhard FC, Thalmann GN, Roth B. Pelvic lymph node dissection may be limited on the contralateral side in strictly unilateral bladder cancer without compromising oncological radicality. *Bladder Cancer*. 2016;2(1):53-59.
 22. Gerdtsen A, Thor A, Grenabo Bergdahl A, et al. Unilateral or bilateral retroperitoneal lymph node dissection in nonseminoma patients with post-chemotherapy residual tumour? Results from RETROP, a population-based mapping study by the Swedish Norwegian Testicular Cancer Group. *Eur Urol Oncol*. 2022;5(2):235-243.
 23. Ahmed HU, El-Shater Bosaily A, Brown LC, et al. Diagnostic accuracy of multi-parametric MRI and TRUS biopsy in prostate cancer (PROMIS): a paired validating confirmatory study. *Lancet*. 2017;389(10071):815-822.
 24. Kasivisvanathan V, Rannikko AS, Borghi M, et al. MRI-targeted or standard biopsy for prostate-cancer diagnosis. *N Engl J Med*. 2018;378(19):1767-1777.
 25. Martini A, Cumarasamy S, Tewari AK. MRI-targeted biopsy for prostate-cancer diagnosis. *N Engl J Med*. 2018;379(6):589.
 26. Lestingi JFP, Guglielmetti GB, Trinh QD, et al. Extended versus limited pelvic lymph node dissection during radical prostatectomy for intermediate- and high-risk prostate cancer: early oncological outcomes from a randomized phase 3 trial. *Eur Urol* 2021;79(5):595-604.
 27. Valerio M, Anello C, Freeman A, et al. Identifying the index lesion with template prostate mapping biopsies. *J Urol*. 2015;193(4):1185-1190.
 28. Nassiri N, Chang E, Lieu P, et al. Focal therapy eligibility determined by magnetic resonance imaging/ultrasound fusion biopsy. *J Urol*. 2018;199(2):453-458.
 29. Kachanov M, Leyh-Bannurah SR, Roberts MJ, et al. Optimizing combined magnetic resonance imaging (MRI)-targeted and systematic biopsy strategies: sparing the multiparametric MRI-negative transitional zone in presence of exclusively peripheral multiparametric MRI-suspect lesions. *J Urol*. 2022;207(2):333-340.
 30. Teloken PE, Li J, Woods CG, Cohen RJ. The impact of prostate cancer zonal origin on pathological parameters at radical prostatectomy and subsequent biochemical failure. *J Urol*. 2017;198(6):1316-1323.

EDITORIAL COMMENT

Although extended pelvic lymph node dissection (ePLND) during radical prostatectomy is considered the gold standard staging tool, it is associated with increased morbidity.¹ Therefore, Martini et al investigated reducing bilateral ePLND to unilateral ePLND in selected cases, without compromising short-term oncologic outcomes.² In their novel nomogram, based on a multi-institutional data set from 19 tertiary referral centers, the rate of lymph node invasion (LNI) was 13% in both development and validation cohorts. Very well according to the authors' hypothesis, LNI was predominantly found on the ipsilateral side of the prostatic lobe with the worst disease features and yielded an impressive area under the curve of 84%. Nevertheless, it is noteworthy that LNI was also found contralaterally. For example, in the development cohort, including 269 LNI patients, contralateral LNI was found in 71 patients (26% of LNI patients). Also in the validation cohort, including 27 LNI patients, contralateral LNI was found in 12 patients (44% of LNI patients).

Therefore, although the authors should be congratulated for this innovative nomogram, the above-mentioned findings require further discussions on the

primary lymphatic landing sites of prostate cancer. In this regard, lymphatic drainage of the prostate has been shown to exist bilaterally, thus questioning the biological rationale behind the findings of Martini et al. Furthermore, it must be kept in mind that prostate cancer may also spread beyond close locoregional lymph nodes.³ In this regard, the only randomized trial investigating the oncologic effect of limited pelvic lymph node dissection vs extended pelvic lymph node dissection was not conclusive due to the very comparable total lymph node counts in both groups, which is the reason why ePLND should still be considered standard of care.⁴ Therefore, the findings by Martini et al must be considered in the light of lacking sufficient prospectively collected long-term data on the oncologic safety of limited and/or ipsilateral lymph node dissection.

Christoph Würnschimmel,^{1,2} Philipp Baumeister,^{1,2} and Agostino Mattei^{1,2}

¹ Department of Urology, Luzerner Kantonsspital Lucerne, Switzerland

² Faculty of Medicine and Health Sciences, University of Lucerne Lucerne, Switzerland

REFERENCES

1. Briganti A, Chun FKH, Salonia A, et al. Complications and other surgical outcomes associated with extended pelvic lymphadenectomy in men with localized prostate cancer. *Eur Urol*. 2006;50(5):1006-1013.
2. Martini A, Wever L, Soeterik T, et al. Unilateral pelvic lymph node dissection in prostate cancer patients diagnosed in the era of magnetic resonance imaging—targeted biopsy: a study that challenges the dogma. *J Urol* 2023;210(1):000-000.
3. Mattei A, Fuechsel FG, Bhatta Dhar N, et al. The template of the primary lymphatic landing sites of the prostate should be revisited: results of a multimodality mapping study. *Eur Urol*. 2008;53(1):118-125.
4. Lestingi JFP, Guglielmetti GB, Trinh Q-D, et al. Extended versus limited pelvic lymph node dissection during radical prostatectomy for intermediate- and high-risk prostate cancer: early oncological outcomes from a randomized phase 3 trial. *Eur Urol*. 2021;79(5):595-604.

REPLY BY AUTHORS

We appreciate the comment by Würnschimmel et al on our article on unilateral pelvic lymph node dissection (PLND).¹ First of all, the reader should note that the manuscript does not have a development/validation subdivision, as per advice of the statistical reviewers our main analyses changed during the review process. The figures/rates reported by Würnschimmel et al refer to an older version of the manuscript.

We would like to underline that the rationale of our study was to explore a personalized alternative to a “one-size-fits-all” approach consisting of bilateral extended pelvic lymph node dissection (ePLND) whenever ePLND is indicated. We believe that the era of revisiting the extent of PLND according to preoperative parameters has come with the MRI/targeted biopsy pathway. The present study confirms our views.

It is important to note that we do not advocate for unilateral ePLND in each case, hence criticizing our study based on the “overall” rate of contralateral

lymph node invasion does not seem appropriate. Also, the argument that lymphatic drainage is bilateral does not justify a strategy that has shown lack of robust therapeutic benefit and a non-negligible morbidity.

Two randomized trials—and not “only 1”—on limited vs extended PLND challenged the indication for the latter in light of no therapeutic benefit.^{2,3} We acknowledge that in one of them, the lymph node count was similar between the groups (Touijer et al²; not Lestingi et al³ as referenced by Würnschimmel et al).

Finally, we would like to highlight that the concept we are promoting is already an accepted standard in the surgical field. For instance, an increased risk of positive margins does not justify bilateral nerve excision in all patients at radical prostatectomy.⁴ We believe that we should engage in looking forward rather than looking backward. As per Sir W.L.S. Churchill’s quote, “To improve is to change; to be perfect is to change often.”

REFERENCES

1. Martini A, Wever L, Soeterik T, et al. Unilateral pelvic lymph node dissection in prostate cancer patients diagnosed in the era of magnetic resonance imaging—targeted biopsy: a study that challenges the dogma. *J Urol.* 2023;210(1):000-000.
2. Touijer KA, Sjoberg DD, Benfante N, et al. Limited versus extended pelvic lymph node dissection for prostate cancer: a randomized clinical trial. *Eur Urol Oncol.* 2021;4:532-539.
3. Lestingi JFP, Guglielmetti GB, Trinh QD, et al. Extended versus limited pelvic lymph node dissection during radical prostatectomy for intermediate- and high-risk prostate cancer: early oncological outcomes from a randomized phase 3 trial. *Eur Urol.* 2021;79(5):595-604.
4. Martini A, Soeterik TFW, Haverdings H, et al. An algorithm to personalize nerve sparing in men with unilateral high-risk prostate cancer. *J Urol.* 2022;207(2):350-357.