



Subepicardial Cardiomyopathy: A Disease Underlying J-Wave Syndromes and Idiopathic Ventricular Fibrillation

Chris Miles¹, BSc, MBChB, PhD; Bastiaan J. Boukens, PhD; Chiara Scrocco², MD; Arthur A.M. Wilde³, MD, PhD; Koonlawee Nademanee⁴, MD, CCDS; Michel Haissaguerre⁵, MD; Ruben Coronel, MD, PhD*; Elijah R. Behr⁶, MA, MD*

ABSTRACT: Brugada syndrome (BrS), early repolarization syndrome (ERS), and idiopathic ventricular fibrillation (iVF) have long been considered primary electrical disorders associated with malignant ventricular arrhythmia and sudden cardiac death. However, recent studies have revealed the presence of subtle microstructural abnormalities of the extracellular matrix in some cases of BrS, ERS, and iVF, particularly within right ventricular subepicardial myocardium. Substrate-based ablation within this region has been shown to ameliorate the electrocardiographic phenotype and to reduce arrhythmia frequency in BrS. Patients with ERS and iVF may also exhibit low-voltage and fractionated electrograms in the ventricular subepicardial myocardium, which can be treated with ablation. A significant proportion of patients with BrS and ERS, as well as some iVF survivors, harbor pathogenic variants in the voltage-gated sodium channel gene, *SCN5A*, but the majority of genetic susceptibility of these disorders is likely to be polygenic. Here, we postulate that BrS, ERS, and iVF may form part of a spectrum of subtle subepicardial cardiomyopathy. We propose that impaired sodium current, along with genetic and environmental susceptibility, precipitates a reduction in epicardial conduction reserve, facilitating current-to-load mismatch at sites of structural discontinuity, giving rise to electrocardiographic changes and the arrhythmogenic substrate.

Key Words: arrhythmogenic cardiomyopathies ■ Brugada syndrome ■ ventricular fibrillation

Some arrhythmia syndromes appear to occur in the absence of overt structural abnormalities. The long QT syndrome is one such example.¹ The now well-defined pathophysiological basis of long QT syndrome and associated arrhythmias in the absence of structural myocardial abnormalities characterizes the syndrome as a dominant (if not 100% genetic) ion channel disease, a channelopathy. Various other channelopathies have been described, including Brugada syndrome (BrS), catecholaminergic polymorphic ventricular tachycardia, and short QT syndrome. BrS, a leading cause of autopsy-negative sudden death,² is defined by coved J-point (ST-segment) elevation in the right precordial leads in association with ventricular fibrillation (VF) in the absence of structural

abnormalities. J-point elevation is also a requisite feature of the early repolarization syndrome (ERS), which refers to the finding of early repolarization pattern in patients with idiopathic VF (iVF). BrS and ERS therefore constitute a continuous spectrum of J-wave phenotypic expression in the ECG, and thus have been designated J-wave syndromes.³ Other clinical entities can mimic the electrocardiographic pattern observed in BrS, but are etiologically distinct and elicited by other factors, such as myocardial ischemia, metabolic abnormalities, or mechanical compression.⁴ Early repolarization pattern is also more commonly observed in competitive athletes compared with the general population.⁵ In the absence of an overt electrical or structural phenotype, iVF exists as a

The opinions expressed in this article are not necessarily those of the editors or of the American Heart Association.

Correspondence to: Elijah R Behr, MA, MD, Cardiovascular Clinical Academic Group, Molecular and Clinical Sciences Research Institute, St George's University of London, Cranmer Terrace, London, SW17 0RE UK, Email ebehr@sgul.ac.uk; or Ruben Coronel, Amsterdam UMC, Location AMC, Meibergdreef 9, 1105 AZ Amsterdam, Netherlands, Email r.coronel@amsterdamumc.nl

*R. Coronel and E.R. Behr contributed equally.

For Sources of Funding and Disclosures, see page 1630.

© 2023 The Authors. *Circulation* is published on behalf of the American Heart Association, Inc., by Wolters Kluwer Health, Inc. This is an open access article under the terms of the [Creative Commons Attribution](https://creativecommons.org/licenses/by/4.0/) License, which permits use, distribution, and reproduction in any medium, provided that the original work is properly cited.

Circulation is available at www.ahajournals.org/journal/circ

Nonstandard Abbreviations and Acronyms

ACM	arrhythmogenic cardiomyopathy
BrS	Brugada syndrome
CMR	cardiac magnetic resonance
ERS	early repolarization syndrome
iVF	idiopathic ventricular fibrillation
OFT	outflow tract
RV	right ventricular
RVOT	right ventricular outflow tract
VF	ventricular fibrillation

diagnosis of exclusion, referring to the occurrence of VF without a pathophysiological explanation.⁶

Because the 3 disorders, in at least some patients, share the presence of subtle changes in the extracellular matrix, a common pathophysiological basis for BrS, ERS, and iVF appears plausible (Figure 1). The presence of a vulnerable electrophysiological substrate, in conjunction with triggers commonly arising from the Purkinje system or right ventricular (RV) outflow tract (RVOT), likely plays an important role in arrhythmogenesis, particularly when combined with genetic and environmental modifiers. This is consistent with our view that syndromic descriptions of BrS and ERS point to a different region of the heart and to a different severity of the microstructural changes, whereas iVF may

be associated with abnormalities in various regions. In contrast to primary cardiomyopathic disorders, in which the heart muscle appears both structurally and functionally abnormal, alterations in ion channel interfaces and protein architecture have led some to recognize cardiac channelopathies as a subgroup of primary cardiomyopathies rather than purely electrical diseases.⁷ We therefore propose that most patients with BrS, ERS, or iVF have a common subepicardial cardiomyopathy based on nontransmural, subtle microstructural changes present within the subepicardial myocardium.⁸ Whether these microstructural changes are also present in patients with other primary electrical diseases is unclear, although a recent study by Pappone et al⁹ suggests that, in patients with long QT syndrome, cardiac structural abnormalities may be present as well. Here, we discuss the replacement of the syndromic descriptions of BrS, ERS, and iVF with a common unifying pathophysiological definition.

EVIDENCE OF STRUCTURAL DISEASE IN THESE PHENOTYPES

The presence of an apparently abnormal myocardial substrate in BrS has been widely reported in the literature, but the histological descriptions vary. Cardiomyopathic changes, including myocardial fibrofatty replacement of the RV free wall or the presence of inflammatory infiltrates, have been described in a series of studies.^{10–13} Microstructural abnormalities have been reported in an

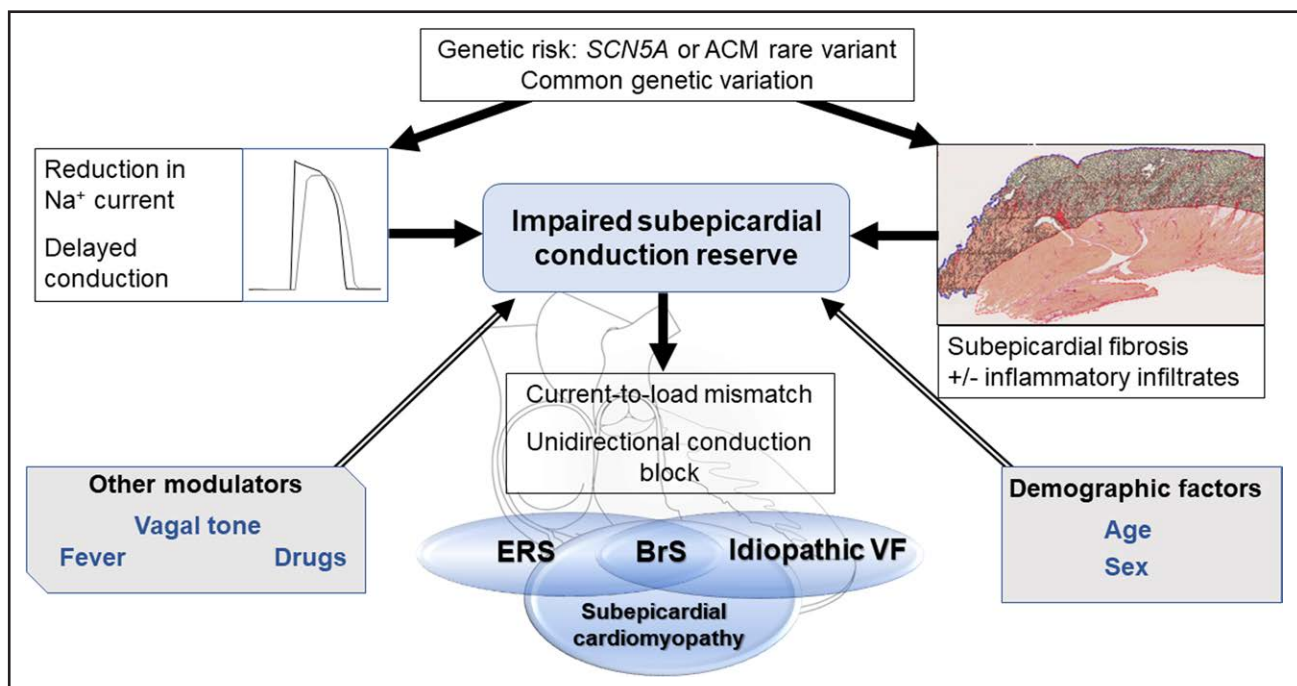


Figure 1. Proposed mechanisms and modulating factors underlying arrhythmogenesis in the subepicardial cardiomyopathy, giving rise to BrS, ERS, and idiopathic VF.

ACM indicates arrhythmogenic cardiomyopathy; BrS, Brugada syndrome; ERS, early repolarization syndrome; and VF, ventricular fibrillation.

earlier case series of 6 individuals with apparent iVF, one of whom fulfilled contemporary electrocardiographic criteria for BrS.¹⁴ A recent study by Miles et al¹⁵ reported pathological and clinical characteristics in a group of 28 decedents with BrS compared with control subjects without cardiac death. Quantitative analysis of cardiac tissue components demonstrated a 45% increase in collagen content among the BrS group compared with control subjects. Increases in collagen were observed across all sampled regions of RV and left ventricular myocardium, with the highest collagen proportions within the subepicardium of the RVOT. These findings suggest that fibrosis predominates in RV subepicardial myocardium but also appears to represent an adverse remodeling process in both ventricles. However, the syndromic description of BrS classifies patients as having RVOT disease, failing to recognize its true extent.¹⁶

Although BrS and ERS are often considered distinct arrhythmia syndromes, overlapping clinical and pathophysiological features are increasingly recognized. It has been proposed that the electrocardiographic J wave, previously characterized in experimental studies by accentuation of the notch in the subepicardial action potential (caused by the transient outward potassium current [I_{to}]), can also be caused by or related to activation delay,^{17,18} underpinning a spectrum of BrS and ERS disease phenotypes associated with malignant ventricular arrhythmias and sudden cardiac death.³ The conventional view of ERS as an exclusive disorder of enhanced local early repolarization in the absence of apparent structural cardiac abnormalities has also been challenged.^{19,20} Boukens et al²⁰ recently documented the presence of fibrosis within regions of inferior RV myocardium colocalizing with electrophysiological J waves observed during epicardial unipolar mapping. Here, transmural myocardial biopsies were obtained from a patient with ERS with recurrent VF undergoing epicardial mapping and ablation. High-resolution activation mapping identified the latest moment of electrical activation within the inferior RV free wall, in which high-amplitude local J waves were present on unipolar recordings occurring after the moment of slurring/notching in the QRS complex of the ECG. Extensive subepicardial fibrosis was observed histologically, along with fragments of surviving myocardium.

In patients with iVF, microstructural changes with potentials similar to those observed in BrS can also occur. More than two-thirds of 50 patients with iVF who underwent comprehensive exclusion of underlying cardiac causes showed evidence of low-amplitude and fractionated electrograms detected during electrophysiological catheter mapping procedures, indicative of abnormal conduction and arrhythmogenicity.²¹ Abnormal conduction was found predominantly in RV (65%) subepicardial myocardium, whereas Purkinje premature ventricular contractions were the dominant cause in patients

with iVF without conduction alterations. Concordant with biventricular fibrotic involvement in BrS,¹⁵ microstructural alterations of the left ventricular myocardium with or without the RV myocardium were identified in a significant minority (35%). Localized abnormal electrograms within both ventricles were also commonly reported in a series of patients with iVF subjected to endocardial and epicardial mapping.²² Here, Haïssaguerre et al²² identified sites of abnormal ECGs among 15 of 24 patients with iVF. Furthermore, abnormal areas were found to colocalize with VF drivers; clinical recurrences were reduced after substrate-based ablation. The presence of myocardial fibrosis and fatty infiltration in cardiac tissue has also been associated with the distribution of J waves on the 12-lead ECG.²³

A COMMON UNDERLYING PATHOPHYSIOLOGY?

The underlying pathophysiology of BrS has been a matter of much debate.²⁴ The 2 main electrophysiological hypotheses are the repolarization and depolarization theories.²⁵ The repolarization theory is based on experiments in perfused canine RV wedge preparations and refers to transmural dispersion of repolarization in the absence of structural abnormalities.²⁶ According to this hypothesis, the notch of the action potential is accentuated due to reduction of net inward Na^+ current ($NaV1.5$), along with nonuniform increases in the I_{to} within the subepicardial myocardium. In the depolarization theory, ST-segment elevation observed in the right precordial leads is explained by severely compromised conduction, including slow or asynchronous conduction, localized block, and absence of activation within the RVOT, creating a large potential difference with respect to the body of the RV.^{27–30} Reduction of sodium current by sodium channel blockade, the presence of a *SCN5A* pathogenic variant, high-rate pacing, or extrasystoles can unmask the substrate.^{27,29} Experimental models also provide a mechanistic basis for the association between fibrosis and BrS. For example, a study using a haploinsufficient *SCN5A*^{+/-} mouse model demonstrated fibrotic changes within both ventricles; epicardial activation analysis also showed increased late conducting components.³¹ Conduction deficits and myocardial fibrosis have been elegantly described in a porcine model of *SCN5A* deficiency, underscoring the pleiotropic nature of sodium channel disease.³²

It has been proposed that a reduction of sodium current is caused by current-to-load mismatch and localized conduction block, resulting in excitation failure within fibrotic myocardium in the RV epicardium.²⁸ In a porcine model and in computer simulations, Hoogendijk et al²⁹ showed that localized excitation failure by current-to-load mismatch can cause ST-segment elevation modulated

by the balance of sodium current, I_{Na} , and calcium current. In the presence of structural discontinuities, a decrease in depolarizing (or an increase in the repolarizing) current may result in unidirectional conduction block. These findings are concordant with clinical data demonstrating excitation failure and localized RV epicardial activation delay in BrS myocardium.^{33,34}

The most compelling data in favor of the depolarization hypothesis were put forward by Nademanee et al,³⁰ who studied 9 patients with BrS with recurrent VF and frequent implantable cardioverter defibrillator discharges. Electroanatomic mapping showed low-voltage fragmented electrograms of prolonged duration over the epicardial aspect of the RVOT. Catheter ablation resulted in normalization of the type 1 Brugada electrocardiographic pattern, and no further arrhythmia was inducible, a phenomenon also observed by others.³⁵ In our view, these findings suggested that localized J-point and ST-segment elevation is a consequence of delayed depolarization of the RVOT with current-to-load mismatch at areas of cardiac tissue discontinuity. This was made plausible by recording of delayed monophasic unipolar electrograms after sodium channel blocker administration in patients with BrS with or without early repolarization pattern.³⁶ A monophasic morphology of a unipolar electrogram is commonly accepted as a sign of absence of local activation.^{37,38} These monophasic potentials are visible in lead V_1 as a J-point elevation.³⁹

Similar observations have been made in patients with ERS.^{19,20} In an electroanatomic study of 58 patients with inferolateral J waves/ERS, 2 distinct electrical subtypes were identified. The majority was made up of those with depolarization abnormalities located predominantly at the inferior part of RV epicardium. A smaller group included individuals with no apparent depolarization abnormality but early repolarization unipolar signals (pure ERS) in which Purkinje-related VF triggers likely predominate.¹⁹ Mechanisms underlying iVF often relate to the presence of premature ventricular contraction triggers arising from the distal Purkinje system, and this classification should be considered after careful exclusion of covert structural or molecular cardiac causes.

Others have questioned the role of delayed conduction in BrS. The canine wedge model demonstrated fractionated electrograms and late potentials as a consequence of perturbations in epicardial repolarization (reactivation of calcium current) and action potential duration,⁴⁰ although these electrograms show different characteristics in timing and continuity compared with those in human patients with BrS.³⁹ Radiofrequency ablation of myocardium showing fractionated potentials mitigated the BrS electrocardiographic phenotype.⁴¹ Furthermore, important differences have also been described in the electrocardiographic response of BrS and ERS to sodium channel blockade,⁴² which appears to accentuate J-wave amplitude in BrS while causing a reduction in ERS. Although this suggests that distinct mechanisms may underlie both

conditions, computer simulation data indicate that differences in J-wave manifestation occur due to regional patterns of delayed activation and reduction in sodium current. Additional conduction slowing in the entire heart (eg, by sodium channel blockade) may attenuate J waves and J-point elevations on the ECG because of masking due to global QRS widening.¹⁸ In humans with BrS, the presence of late potentials on the signal-averaged ECG has been associated with a positive response to the sodium channel blocker provocation test.⁴³

UNDERLYING GENETIC CAUSES

Since the landmark discovery of pathogenic variants in the first gene linked to BrS,⁴⁴ *SCN5A* remains the only gene consistently associated with the clinical phenotype. To date, >300 mutations in *SCN5A* have been associated with BrS that underlie ≈20% of patients meeting diagnostic criteria.⁴⁵ Pathogenic *SCN5A* variants in BrS cause loss of function due to reduction in the amplitude of the sodium channel current by reduced expression or altered voltage-gating properties. *SCN5A* variants have been described in various other cardiac pathologies, including long QT syndrome, premature cardiac conduction defect, and dilated cardiomyopathy. However, it should be noted that not all *SCN5A* variants are pathogenic, according to the Koch or Bradford Hill criteria.^{46,47} In fact, Probst et al⁴⁸ found that within families with hereditary BrS and a pathogenic *SCN5A* variant, the genetic variant can be absent in symptomatic patients who comply with the syndromic criteria. Furthermore, given the relatively modest monogenic contribution of *SCN5A* to the BrS phenotype, it is clear that inheritance patterns are more complex than previously thought.⁴⁹

Bezzina and et al⁵⁰ provided initial support for this idea through a genome-wide association study exploring the role of common genetic variation in BrS. They identified 3 loci associated with BrS: rs10428132 and rs11708996, both at *SCN5A/SCN10A*, and rs9388451 near *HEY2*. These common variants were thought to account for ≈7% of variance in BrS susceptibility. Furthermore, disease risk increased consistently with increasing numbers of carried risk alleles. A follow-up study suggested that the weighted contribution of these variants may allow an individualized approach to diagnosis along with established clinical factors.⁵¹ A strong polygenic susceptibility was underscored by a further, much larger genome-wide association study implicating 21 common variants at 12 loci in BrS.⁵²

The presence of *SCN5A* variants has also been reported in ERS, albeit at a lower diagnostic yield.^{53,54} In a study of 262 probands with BrS and 104 with ERS, Zhang et al⁵⁴ identified a 10% yield of pathogenic *SCN5A* variants in the ERS group compared with 23% for BrS. This is further supported by patients with ERS undergoing ablation being more likely to harbor an *SCN5A*

variant.¹⁹ This suggests that overlapping genetic features may underlie a significant minority of J-wave syndromes, ultimately contributing to reduced conduction reserve within RV epicardium.⁵⁵ Furthermore, previous studies have shown that NaV1.5 may also have a role in the maintenance of normal cardiac structural integrity. Loss of NaV1.5 in heterozygous *SCN5A*^{+/-} murine models has resulted in conduction defects, in keeping with premature cardiac conduction defect, and the occurrence of age-dependent fibrotic cardiac remodeling, which appears to be triggered by activation of a transforming growth factor- β signaling pathway.^{31,56,57}

EVIDENCE FOR GENETIC OVERLAP WITH ARRHYTHMOGENIC CARDIOMYOPATHY

Genetic variants in the desmosomal gene *PKP2* have been associated with clinically affected patients with BrS, and, conversely, *SCN5A* has been implicated in the pathogenesis of arrhythmogenic cardiomyopathy (ACM).^{58,59} The majority of annotated ACM pathogenic *PKP2* variants are radical alternations (frameshift or nonsense mutations), but nonsynonymous variants have also been associated with additional cardiac phenotypes such as BrS.⁶⁰ This suggests a pleotropic role of the plakophilin-2 protein, which may have additional functions besides linking cadherins to intermediate filaments in the cytoskeleton.⁶¹ These findings are emphasized by experimental models detailing a molecular interaction between desmosomal proteins and the sodium channel, suggesting that both disease states may exist on a continuum, manifesting variable degrees of electrical and structural dysfunction.^{62,63} For example, biochemical, patch clamp, and optical mapping experiments have reported important associations between plakophilin-2 and NaV1.5 at a cellular level while also demonstrating adverse effects of *PKP2* knockdown on sodium current function.⁶⁴ Similarly, *PKP2* variants were functionally detrimental to sodium channel current in a series of patients with *SCN5A*-negative BrS, all of whom failed to exhibit structural features of cardiomyopathy.⁶⁵ Functional *in vitro* evaluation resulted in decreased sodium current at sites of cell-to-cell contact. This was reversed after transfection of wild-type *PKP2* in cellular models but not in mutant forms associated with BrS.

Additional studies have shown deleterious interactions between pathogenic variants in other desmosomal genes and sodium current, as in the cases of *DSG2*,⁶⁶ *DSP*,⁶⁷ and *JUP*.⁶⁸ The clinical phenotype of BrS has also been observed in a patient with a pathogenic *LMNA* variant.⁶⁹ However, such genes currently have insufficient evidence for their inclusion in genetic testing panels for BrS.⁷⁰ Survivors of unexplained cardiac arrest, including patients with iVF, may also harbor pathogenic variants in *SCN5A* in a small proportion, but more significantly, disease-causing variants in cardiomyopathy-

related genes, including ACM, have been implicated in 10%.⁷¹ Indeed, interaction between pathogenic desmosomal variants and calcium current may also represent an important arrhythmia mechanism in the absence of overt structural defects. The concept of a desmosome-diad axis has been proposed whereby disruption of the desmosome can lead to downregulation of the calcium handling protein integrin β 1D, which precipitates hyperphosphorylation of RYR2 (Ser-2030) and predisposes to catecholaminergic polymorphic ventricular tachycardia-like ventricular arrhythmias.^{72,73} Moreover, disruption of calcium current homeostasis has also been reported in *PKP2*-deficient mice, in which an RV-predominant arrhythmogenic substrate was observed in advance of any overt cardiomyopathic changes.⁷⁴ However, we presume that much of the remaining heritability in ERS and iVF could also have a polygenic basis.

CLINICAL OVERLAP WITH CARDIOMYOPATHY

Over recent years, several studies have reported overlapping clinical features between ACM and BrS in some patients, suggesting that a common disease pathway may underlie such cases.^{75,76} Several investigators have postulated that such changes may relate to changes in the connexome,⁷⁷⁻⁷⁹ a network at the intercalated disk that integrates mechanical junctions, gap junctions, and the voltage-gated sodium channel.

Case series have documented RV electromechanical abnormalities (including epsilon waves) in BrS and the presence of a provokable type 1 Brugada ECG in patients meeting task force criteria for ACM.^{76,80-82} Furthermore, the association between BrS and morphological abnormalities of the RV has been explored⁸³⁻⁸⁷ (Table 1). Gray et al⁹¹ compared cardiac magnetic resonance (CMR) imaging data among patients with BrS, patients with ACM, and control subjects. The BrS cohort was characterized by increased volumes and abnormal function of the RVOT compared with controls, but, unlike the ACM group, the BrS group did not show global RV dilatation or systolic impairment. Some patients with BrS also demonstrate left ventricular late gadolinium enhancement on CMR,⁸³ suggesting a degree of phenotypic overlap with cardiomyopathies such as ACM. One CMR study showed emergence of focal septal late gadolinium enhancement in 4 patients with BrS during follow-up, suggesting that a progressive evolution of imaging abnormalities occurs in some patients (Figure 2).⁹³ Despite these reports, not all CMR studies have shown such changes.⁹⁰ Moreover, there are a lack of data indicating evolving myocardial impairment in patients with BrS. This is in line with our view that microstructural changes are minor, undetectable by conventional imaging, and unlikely to cause overt myocardial dysfunction (Figure 3). Nonetheless, in one study,

Table 1. Studies Detailing Electrophysiological and CMR Features of Subjects With BrS, ERS, and iVF

Study type and cohort(s)	Main findings	Reference
Electrophysiological and voltage mapping		
Comparative study: patients with BrS, n=22 (36% <i>SCN5A+</i>); control subjects, n=12	Fractionation of electrograms (defined as the presence of ≥ 2 intrinsic deflections with a $dV/dt \leq -0.04$ V/s, separated by ≥ 10 ms, in the unipolar signal with corresponding deflections in the bipolar electrogram) higher in patients with BrS than in control subjects (data on 28 subjects) Electrogram duration higher in patients with BrS compared with control subjects (data on 28 subjects) Conduction slowing in subjects with spontaneous BrS pattern compared with those with drug-induced BrS or control subjects, with longer paced activation time and longer paced QRS at basic cycle length (data on 19 subjects) No differences in repolarization parameters (mean activation recovery interval, mean repolarization time, and dispersion parameters) between patients with BrS and control subjects (data on 28 subjects)	88
Comparative study: patients with BrS, n=18 (6% <i>SCN5A+</i>); control subjects, n=20	Significant prolongation of the sinus rhythm electrograms in the RVOT vs apex in patients with BrS, not evident in control subjects Electrograms significantly more prolonged and complex in the RVOT segments of patients with BrS vs control subjects Electrograms in the RVOT segments more polyphasic than RV body and apex in patients with BrS, not evident in control subjects Significant differences in activation recovery time in the midportion of the restitution curve between patients with BrS and control subjects Significant differences in the activation recovery time at apex and base in patients with BrS at both long and short diastolic intervals, not evident in control subjects	89
Observational study: patients with BrS, n=14 (29% <i>SCN5A+</i>)	Abnormal epicardial electroanatomic voltage maps, characterized by low-voltage (<1.5 mV) areas, present at baseline and increasing after class I drug challenge, with no endocardial abnormalities Substrate elimination by epicardial ablation	35
Observational study: patients with BrS, n=6 (33% <i>SCN5A+</i>)	Abnormal (fractionated and delayed) epicardial electrograms in RVOT, defined as: (1) low voltage (≤ 1 mV); (2) split or fractionated with multiple potentials; and (3) wide duration (≥ 70 ms) or late potentials with distinct potentials extending beyond the end of the QRS complex Ameliorative effect of epicardial radiofrequency ablation (100%)	13
Observational study: patients with BrS with ER pattern, n=33 (27% <i>SCN5A+</i>)	Abnormal epicardial electrograms defined as: (1) low voltage (≤ 1 mV); (2) split or fractionated with multiple potentials; and (3) wide duration (≥ 70 ms) localized at the anterior RVOT/RV epicardium (100%), inferior RV epicardium (91%), or posterolateral LV (3%) Ameliorative effect of epicardial radiofrequency ablation (90%; data on 32 subjects)	19
Observational study: patients with ERS, n=18 (0 <i>SCN5A+</i>)	Abnormal epicardial electrograms defined as: (1) low voltage (≤ 1 mV); (2) split or fractionated with multiple potentials; and (3) wide duration (≥ 70 ms) in 7/18 subjects (39%) localized at the inferior RV epicardium (100%), anterior RVOT/RV epicardium (60%), or apical and posterior LV epicardium (20%) Ameliorative effect of epicardial radiofrequency ablation in 100% of patients with ERS with elimination of prominent J wave (data on 4 subjects)	20
Case report: 1 subject with ERS (genetics NA)	Fractionated unipolar epicardial electrograms identified in RV inferior wall and ablated with long-term normalization of the cardiac rhythm and the QRS complex	20
Observational study: patients with iVF, n=50 (genetics NA)	Low amplitude and fractionated electrograms were found in 34/50 patients (68%) Isolated Purkinje abnormalities in 20% of patients No abnormalities in 12% of patients	21
CMR imaging		
Comparative study: patients with BrS, n=20 (0 <i>SCN5A+</i>); matched control subjects, n=20	RVOT area enlarged in patients with BrS compared with control subjects High intramyocardial T1 signal similar to fat signal in 20% of patients with BrS, not present in control subjects No LGE data	85
Comparative study: patients with BrS, n=30 (30% <i>SCN5A+</i>); matched control subjects, n=30	Presence of RV contractility abnormalities in 50% of BrS patients (especially in the anterior-apical segment and in the RVOT) Significant enlargement of the right ventricular inflow tract in BrS compared with controls No LGE in patients with BrS or control subjects	84
Comparative study: patients with BrS, n=29 (genetics NA); matched control subjects, n=29	No differences in LV and RV dimensions and ejection fraction RV wall motion abnormalities (especially hypokinesia, and mostly in the RV inferior wall) in 66% of patients with BrS and 76% of control subjects No LGE in patients with BrS or control subjects	90
Comparative study: patients with BrS, n=81 (20% <i>SCN5A+</i>); matched control subjects, n=30	Larger RV volumes and lower RV ejection fraction in patients with BrS with <i>SCN5A</i> pathogenic/likely pathogenic variants compared with noncarriers and control subjects No LGE in patients with BrS or control subjects (1 attributed to myocarditis)	87
Comparative study: patients with BrS, n=78 (33% <i>SCN5A+</i>); matched control subjects, n=78	Lower RV ejection fraction and higher end-systolic volume in patients with BrS compared with control subjects LGE in 8% of patients with BrS (localized in the left ventricular midwall in 5%), not present in control subjects	83

(Continued)

Table 1. Continued

Study type and cohort(s)	Main findings	Reference
Electrophysiological and voltage mapping		
Comparative study: patients with BrS, n=42 (17% <i>SCN5A+</i>), matched control subjects, n=42	Abnormal RVOT morphology in 67% of patients with BrS Larger RVOT volumes and wall motion abnormality in patients with BrS compared with control subjects RV volume and function similar between patients with BrS and control subjects No LGE in patients with patients with BrS or control subjects	91
Comparative study: patients with BrS, n=106 (21% <i>SCN5A+</i>); control subjects, n=25	Lower RV ejection fraction and cardiac index in patients with BrS compared with control subjects RVOT area enlarged in patients with BrS compared with control subjects No LGE in patients with BrS or control subjects	92
Observational study: patients with BrS, n=18 (19% <i>SCN5A+</i>)	Four of 18 subjects (22%) developed LGE on follow-up, typically localized to the RV side of the basal septum Increase in RV end-systolic volume over time Four of 18 subjects (22%) showed a reduction in RV ejection fraction >10% over time	93

BrS indicates Brugada syndrome; CMR, cardiac magnetic resonance; ER, early repolarization; ERS, early repolarization syndrome; iVF, idiopathic ventricular fibrillation; LGE, late gadolinium enhancement; LV, left ventricle; NA, not available; RV, right ventricle; and RVOT, right ventricular outflow tract.

structural RVOT abnormalities appeared to confer a worse prognosis in BrS, representing a potential marker for arrhythmic risk.⁹⁵ The Table 1 summarizes previously published electrophysiological and imaging data on the apparent microstructural substrate present in BrS, ERS, and iVF. To the best of our knowledge, CMR imaging has not been studied in ERS or iVF.

Figure 3 shows the relationship between these disorders and the severity of the microstructural changes with respect to their detectability by various diagnostic methods. Depending on the resolution of the imaging or diagnostic method used, the syndromes are defined as structural heart disease or progressive or not. However, gadolinium enhancement lacks sensitivity for diffuse patterns of interstitial fibrosis, which may be better served by novel imaging techniques such as T1 mapping.

PREDILECTION OF LOCATION

There is a potentially shared predilection of location of the microstructural abnormalities and VF origin in the subepicardial (right) ventricular myocardium in at least a subset of patients with 1 of the 3 syndromes. This raises the question of the cause for this predilection. A possible explanation may be found in cardiac development. The progenitor cells of the left ventricular and RV compartments have a different developmental history and have been exposed to different signals and gene programs before their differentiation.⁹⁶ Studies in chickens have revealed that the RVOT is derived from the outflow tract (OFT) of the embryonic and fetal heart.⁹⁷ The electrophysiological properties and gene expression in the cardiomyocytes of the prenatal OFT differ from

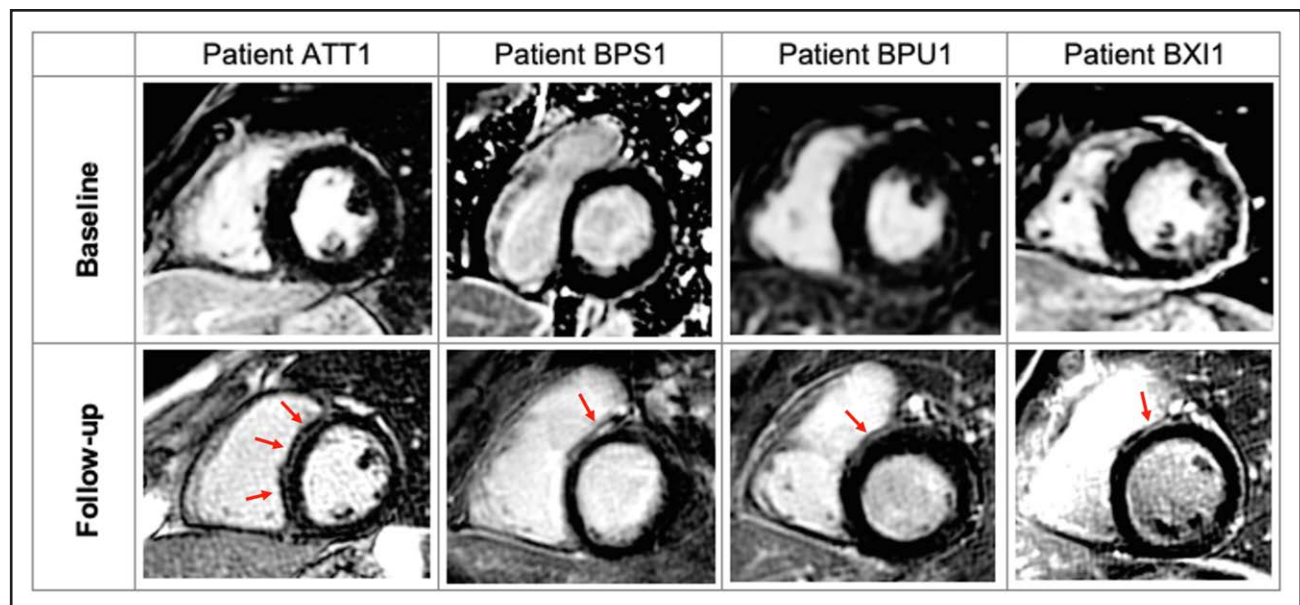


Figure 2. Development of LGE on CMR imaging during follow-up in patients with BrS.

Four (22%) patients (ATT1, BPS1, BPU1, and BXI1) developed focal septal late gadolinium enhancement (LGE) during assessment with serial cardiac magnetic resonance (CMR). Average time between follow-up imaging was 5.0 ± 1.7 years. BrS indicates Brugada syndrome. Reproduced with permission from Isbister et al.⁹³ Copyright © 2023 Elsevier.

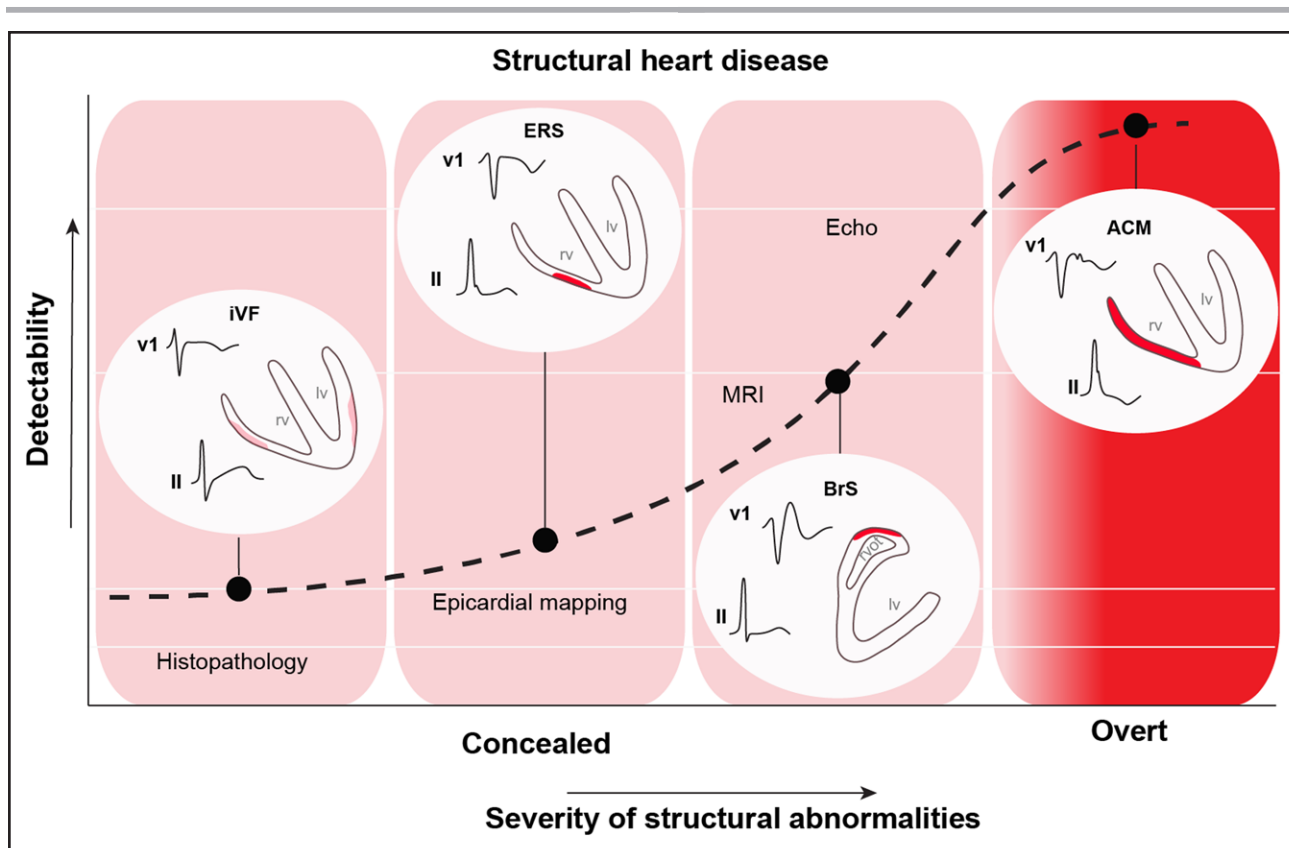


Figure 3. Detectability and severity of structural abnormalities in BrS, ERS, and ACM with respect to cardiac diagnostic modalities.

ACM indicates arrhythmogenic cardiomyopathy; BrS, Brugada syndrome; ERS, early repolarization syndrome; iVF, idiopathic ventricular fibrillation; and MRI, magnetic resonance imaging. Adapted from Boukens et al⁹⁴ with permission. Copyright © 2020 Elsevier.

those of the ventricles. The prenatal OFT conducts the cardiac impulse slowly, and the main protein responsible for intercellular electrical communication, connexin43, is not expressed in the OFT. Some remnants of these phenotypic differences may be maintained in the OFT, when it matures to form the RVOT. This may explain why the RVOT may form the basis for reentrant arrhythmias that are facilitated by slow conduction and uncoupling.⁹⁸

A role for cardiac development in disease susceptibility is further supported by the genome-wide association study that associated BrS with several common variants in or near genes encoding transcription factors crucial for electrophysiological patterning of the ventricular myocardium during development, such as *TBX5*, *HEY2*, *IRX3*, and *IRX5*.⁵² These transcription factors directly or indirectly modulate the expression of *SCN5A* and could be causally related to reentry by slowing conduction.^{50,99,100} *TBX5* and *IRX3* are expressed predominantly in the ventricular conduction system and have been associated with atrioventricular conduction disturbance and iVF, respectively.^{101,102} *HEY2* and *IRX5* are expressed in the ventricular myocardium and dictate the transmural gradient in I_{to} .^{103,104} In mice, *IrX5* is expressed in an endocardial-to-epicardial gradient and represses the expression of *Kcnd2*, a potassium channel carrying I_{to} , leading to low

I_{to} magnitude in the subendocardium. On the other hand, *Hey2* is expressed in an epicardial-to-endocardial gradient. Mice heterozygous for *Hey2* show reduced *Kcnd2* expression and lower I_{to} magnitude in the subepicardium compared with controls, indicating that *Hey2* is required for high magnitude of I_{to} in the subepicardium.¹⁰⁴ Computer simulation experiments have shown that large I_{to} reduces sodium current, contributes to a slower conduction in the subepicardium than the subendocardium (especially in the presence of sodium channel blockers), and, in the presence of subtle structural discontinuities, facilitates conduction block.^{29,105}

CLINICAL IMPLICATIONS

Microstructural defects within the cardiac architecture of patients with BrS, ERS, and iVF or their electrophysiological manifestations are increasingly recognized. From our previous hypothesis of impaired epicardial conduction reserve in the RVOT underlying the BrS,⁵⁵ we postulate that impaired conduction, along with genetic and environmental susceptibility, within sites of microstructural discontinuity in patients with BrS and a large proportion of patients with ERS and iVF, precipitates a reduction in epicardial conduction reserve, which, in turn, leads to

the arrhythmogenic substrate and can give rise to the electrocardiographic phenotype in BrS and inferolateral J waves in ERS (Figure 1).

There are currently major deficiencies in our ability to diagnose the underlying cause in cases of initially unexplained cardiac arrest with no apparent structural cardiac abnormality. The rapidly expanding use of high-density electroanatomic mapping and digital analysis software may facilitate digital quantification of tissue and cellular components in which histological changes are subtle or localize to particular regions of myocardium. When combined with machine learning algorithms, this may allow artificial intelligence–led diagnostics and a reduced reliance on current qualitative and descriptive techniques used in cardiac pathology. Future studies may also consider mRNA sequencing of tissue specimens to enable transcriptome-wide analysis of molecular pathways implicated in collagen synthesis, which could enable the development of metabolically targeted therapies. Furthermore, modern imaging modalities such as CMR T1 mapping or photon-counting computed tomography have provided an invaluable opportunity to visualize fibrosis patterns in vivo. This could potentially facilitate objective comparisons of such phenotypes and may have implications for clinical practice, particularly early detection of these pathologies. For example, high-resolution imaging techniques used to detect and longitudinally assess myocardial fibrosis could form the basis of future investigations into its role in arrhythmic risk stratification and local therapy. Understanding the histological and electrophysiological substrate may also help in developing morphometric diagnostic criteria for a subepicardial cardiomyopathy.

CONCLUSIONS

BrS, ERS, and iVF potentially form part of a spectrum of a common disease defined by subtle subepicardial microstructural abnormalities: a subepicardial cardiomyopathy. Although genetic susceptibility is uncertain and variable, these microstructural abnormalities are consistent with the electrocardiographic characteristics of each of the syndromes, the mechanism of arrhythmogenesis, and the relationship with modulating genetic and environmental factors.

ARTICLE INFORMATION

Received August 1, 2022; accepted March 27, 2023.

Affiliations

Cardiovascular Clinical Academic Group, St. George's University Hospitals' NHS Foundation Trust and Molecular and Clinical Sciences Institute, St. George's, University of London, UK (C.M., C.S., E.R.B.). Department of Medical Biology, University of Amsterdam, the Netherlands (B.J.B.). University of Maastricht, Cardiovascular Research Institute Maastricht, Maastricht University Medical Center, the Netherlands (B.J.B.). Amsterdam UMC, University of Amsterdam, Department

of Cardiology, the Netherlands (A.A.M.W.). Amsterdam Cardiovascular Sciences, Heart Failure and Arrhythmias, the Netherlands (A.A.M.W.). European Reference Network for rare, low-prevalence, and complex diseases of the heart: ERN GUARD-Heart (A.A.M.W., M.H.). Center of Excellence in Arrhythmia Research Chulalongkorn University, Department of Medicine, Chulalongkorn University, Thailand (K.N.). Pacific Rim Electrophysiology Research Institute, Bumrungrad Hospital, Bangkok, Thailand (K.N.). Institut Hospitalo-Universitaire Liryc, Electrophysiology and Heart Modeling Institute, Pessac, France (M.H.). Department of Electrophysiology and Cardiac Stimulation, Centre Hospitalier Universitaire de Bordeaux, France (M.H.). Department of Experimental Cardiology, Amsterdam University Medical Centers, Cardiovascular Science, the Netherlands (R.C.). Mayo Clinic Healthcare, London, UK (E.R.B.).

Sources of Funding

Dr Miles is the recipient of a British Heart Foundation clinical research training fellowship (FS/18/28/33549). Drs Behr and Miles received research funding from the Robert Lancaster Memorial Fund, sponsored by McColl's Retail Group Ltd, UK. Dr Wilde receives research funding from CVON (Predict-2). Dr Behr and the GenUCA investigators received research funding from the British Heart Foundation.

Disclosures

None.

REFERENCES

- Modell SM, Lehmann MH. The long QT syndrome family of cardiac ion channelopathies: a HuGE review. *Genet Med*. 2006;8:143–155. doi: 10.1097/01.gim.0000204468.85308.86
- Papadakis M, Papatheodorou E, Mellor G, Raju H, Bastiaenen R, Wijeyeratne Y, Wasim S, Ensam B, Finocchiaro G, Gray B, et al. The diagnostic yield of Brugada syndrome after sudden death with normal autopsy. *J Am Coll Cardiol*. 2018;71:1204–1214. doi: 10.1016/j.jacc.2018.01.031
- Antzelevitch C, Yan GX, Ackerman MJ, Borggrefe M, Corrado D, Guo J, Gussak I, Hasdemir C, Horie M, Huikuri H, et al. J-wave syndromes expert consensus conference report: emerging concepts and gaps in knowledge. *Europace*. 2017;19:665–694. doi: 10.1093/europace/euw235
- Anselm DD, Evans JM, Baranchuk A. Brugada phenocopy: a new electrocardiogram phenomenon. *World J Cardiol*. 2014;6:81–86. doi: 10.4330/wjcv.v6.i3.81
- Noseworthy PA, Weiner R, Kim J, Keelara V, Wang F, Berkstresser B, Wood MJ, Wang TJ, Picard MH, Hutter AM, et al. Early repolarization pattern in competitive athletes. *Circ Arrhythm Electrophysiol*. 2011;4:432–440. doi: 10.1161/CIRCEP.111.962852
- Conte G, Giudicessi JR, Ackerman MJ. Idiopathic ventricular fibrillation: the ongoing quest for diagnostic refinement. *Europace*. 2021;23:4–10. doi: 10.1093/europace/evaa211
- Maron BJ, Towbin JA, Thiene G, Antzelevitch C, Corrado D, Arnett D, Moss AJ, Seidman CE, Young JB; American Heart Association. Contemporary definitions and classification of the cardiomyopathies: an American Heart Association scientific statement from the Council on Clinical Cardiology, Heart Failure and Transplantation Committee; Quality of Care and Outcomes Research and Functional Genomics and Translational Biology Interdisciplinary Working Groups; and Council on Epidemiology and Prevention. *Circulation*. 2006;113:1807–1816. doi: 10.1161/CIRCULATIONAHA.106.174287
- Behr ER. J-wave syndromes, SCN5A, and cardiac conduction reserve: two sides of the same coin? *J Am Coll Cardiol*. 2021;78:1618–1620. doi: 10.1016/j.jacc.2021.09.003
- Pappone C, Ciconte G, Anastasia L, Gaita F, Grant E, Micaglio E, Locati ET, Calovic Z, Vicedomini G, Santinelli V. Right ventricular epicardial arrhythmogenic substrate in long-QT syndrome patients at risk of sudden death. *EP Europace*. 2023;25:948–955. doi: 10.1093/europace/evac264
- Corrado D, Nava A, Buja G, Martini B, Fasoli G, Oselladore L, Turrini P, Thiene G. Familial cardiomyopathy underlies syndrome of right bundle branch block, ST segment elevation and sudden death. *J Am Coll Cardiol*. 1996;27:443–448. doi: 10.1016/0735-1097(95)00485-8
- Frustaci A, Priori SG, Pieroni M, Chimenti C, Napolitano C, Rivolta I, Sanna T, Bellocchi F, Russo MA. Cardiac histological substrate in patients with clinical phenotype of Brugada syndrome. *Circulation*. 2005;112:3680–3687. doi: 10.1161/CIRCULATIONAHA.105.520999
- Coronel R, Casini S, Koopmann TT, Wilms-Schopman FJG, Verkerk AO, de Groot JR, Bhuiyan Z, Bezzina CR, Veldkamp MW, Linnenbank AC, et al. Right ventricular fibrosis and conduction delay in a patient with clinical

- signs of Brugada syndrome: a combined electrophysiological, genetic, histopathologic, and computational study. *Circulation*. 2005;112:2769–2777. doi: 10.1161/CIRCULATIONAHA.105.532614
13. Nademanee K, Raju H, De Noronha SV, Papadakis M, Robinson L, Rothery S, Makita N, Kowase S, Boonmee N, Vitayakritsirikul V, et al. Fibrosis, connexin-43, and conduction abnormalities in the Brugada syndrome. *J Am Coll Cardiol*. 2015;66:1976–1986. doi: 10.1016/j.jacc.2015.08.862
 14. Martini B, Nava A, Thiene G, Buja GF, Canciani B, Scognamiglio R, Daliento L, Dalla Volta S. Ventricular fibrillation without apparent heart disease: description of six cases. *Am Heart J*. 1989;118:1203–1209. doi: 10.1016/0002-8703(89)90011-2
 15. Miles C, Asimaki A, Ster IC, Papadakis M, Gray B, Westaby J, Finocchiaro G, Bueno-Beti C, Ensam B, Basu J, et al. Biventricular myocardial fibrosis and sudden death in patients with Brugada syndrome. *J Am Coll Cardiol*. 2021;78:1511–1521. doi: 10.1016/j.jacc.2021.08.010
 16. Coronel R, Berecki G, Opthof T. Why the Brugada syndrome is not yet a disease: syndromes, diseases, and genetic causality. *Cardiovasc Res*. 2006;72:361–363. doi: 10.1016/j.cardiores.2006.09.004
 17. Boukens BJ, Opthof T, Coronel R. J-waves in epicardial electrograms can guide ablation of arrhythmogenic substrates. *Circ Res*. 2019;124:205–207. doi: 10.1161/CIRCRESAHA.118.314414
 18. Meijborg VMF, Potse M, Conrath CE, Belterman CNW, de Bakker JMT, Coronel R. Reduced sodium current in the lateral ventricular wall induces inferolateral J-waves. *Front Physiol*. 2016;7:365. doi: 10.3389/fphys.2016.00365
 19. Nademanee K, Haissaguerre M, Hocini M, Nogami A, Cheniti G, Duchateau J, Behr ER, Saba M, Bokan R, Lou Q, et al. Mapping and ablation of ventricular fibrillation associated with early repolarization syndrome. *Circulation*. 2019;140:1477–1490. doi: 10.1161/CIRCULATIONAHA.118.039022
 20. Boukens BJ, Benjachoulamas V, van Amersfoort S, Meijborg VM, Schumacher C, Jensen B, Haissaguerre M, Wilde A, Prechawat S, Huntrakul A, et al. Structurally abnormal myocardium underlies ventricular fibrillation storms in a patient diagnosed with the early repolarization pattern. *JACC Clin Electrophysiol*. 2020;6:1395–1404. doi: 10.1016/j.jacep.2020.06.027
 21. Haissaguerre M, Duchateau J, Dubois R, Hocini M, Cheniti G, Sacher F, Lavergne T, Probst V, Surget E, Vigmond E, et al. Idiopathic ventricular fibrillation: role of Purkinje system and microstructural myocardial abnormalities. *JACC Clin Electrophysiol*. 2020;6:591–608. doi: 10.1016/j.jacep.2020.03.010
 22. Haissaguerre M, Hocini M, Cheniti G, Duchateau J, Sacher F, Puyo S, Cochet H, Takigawa M, Denis A, Martin R, et al. Localized structural alterations underlying a subset of unexplained sudden cardiac death. *Circ Arrhythm Electrophysiol*. 2018;11:e006120. doi: 10.1161/CIRCEP.117.006120
 23. Funabashi N, Kobayashi Y. J waves reaching to equal or more than 2 of 3 LV inferior wall leads may predict the presence of organized myocardial fibrotic or fat change in survivors of ventricular fibrillation. *Eur Heart J*. 2022;43:ehab849.037. doi: 10.1093/eurheartj/ehab849.037
 24. Wilde AAM, Postema PG, Di Diego JM, Viskin S, Morita H, Fish JM, Antzelevitch C. The pathophysiological mechanism underlying Brugada syndrome: depolarization versus repolarization. *J Mol Cell Cardiol*. 2010;49:543–553. doi: 10.1016/j.jmcc.2010.07.012
 25. Blok M, Boukens BJ. Mechanisms of arrhythmias in the Brugada syndrome. *Int J Mol Sci*. 2020;21:7051. doi: 10.3390/ijms21197051
 26. Litovsky SH, Antzelevitch C. Transient outward current prominent in canine ventricular epicardium but not endocardium. *Circ Res*. 1988;62:116–126. doi: 10.1161/01.res.62.1.116
 27. Boukens BJ, Potse M, Coronel R. Fibrosis and conduction abnormalities as basis for overlap of Brugada syndrome and early repolarization syndrome. *Int J Mol Sci*. 2021;22:1570. doi: 10.3390/ijms22041570
 28. Hoogendijk MG, Potse M, Linnenbank AC, Verkerk AO, den Ruijter HM, van Amersfoort SCM, Klaver EC, Beekman L, Bezzina CR, Postema PG, et al. Mechanism of right precordial ST-segment elevation in structural heart disease: excitation failure by current-to-load mismatch. *Heart Rhythm*. 2010;7:238–248. doi: 10.1016/j.hrthm.2009.10.007
 29. Hoogendijk MG, Potse M, Vinet A, de Bakker JMT, Coronel R. ST segment elevation by current-to-load mismatch: an experimental and computational study. *Heart Rhythm*. 2011;8:111–118. doi: 10.1016/j.hrthm.2010.09.066
 30. Nademanee K, Veerakul G, Chandanamatta P, Chaothawee L, Ariyachaijanich A, Jirasirojanakorn K, Likittanasombat K, Bhuripanyo K, Ngarmukos T. Prevention of ventricular fibrillation episodes in Brugada syndrome by catheter ablation over the anterior right ventricular outflow tract epicardium. *Circulation*. 2011;123:1270–1279. doi: 10.1161/CIRCULATIONAHA.110.972612
 31. Jeevaratnam K, Poh Tee S, Zhang Y, Rewbury R, Guzadhur L, Duehmke R, Grace AA, Lei M, Huang CLH. Delayed conduction and its implications in murine *Scn5a*^{+/-} hearts: independent and interacting effects of genotype, age, and sex. *Pflugers Arch*. 2011;461:29–44. doi: 10.1007/s00424-010-0906-1
 32. Park DS, Cerrone M, Morley G, Vasquez C, Fowler S, Liu N, Bernstein SA, Liu FY, Zhang J, Rogers CS, et al. Genetically engineered SCN5A mutant pig hearts exhibit conduction defects and arrhythmias. *J Clin Invest*. 2015;125:403–412. doi: 10.1172/JCI176919
 33. Ten Sande JN, Coronel R, Conrath CE, Driessen AHG, De Groot JR, Tan HL, Nademanee K, Wilde AAM, De Bakker JMT, Van Dessel PFHM. ST-segment elevation and fractionated electrograms in Brugada syndrome patients arise from the same structurally abnormal subepicardial RVOT area but have a different mechanism. *Circ Arrhythm Electrophysiol*. 2015;8:1382–1392. doi: 10.1161/CIRCEP.115.003366
 34. Vigmond EJ, Efimov IR, Rentschler SL, Coronel R, Boukens BJ. Fractionated electrograms with ST-segment elevation recorded from the human right ventricular outflow tract. *Heart Rhythm Case Rep*. 2017;3:546–550. doi: 10.1016/j.hrcr.2017.08.010
 35. Brugada J, Pappone C, Berrueto A, Vicedomini G, Manguso F, Ciconte G, Giannelli L, Santinelli V. Brugada syndrome phenotype elimination by epicardial substrate ablation. *Circ Arrhythm Electrophysiol*. 2015;8:1373–1381. doi: 10.1161/CIRCEP.115.003220
 36. Nademanee K, Veerakul G, Nogami A, Lou Q, Hocini M, Coronel R, Behr ER, Wilde A, Boukens BJ, Haissaguerre M. Mechanism of the effects of sodium channel blockade on the arrhythmogenic substrate of Brugada syndrome. *Heart Rhythm*. 2022;19:407–416. doi: 10.1016/j.hrthm.2021.10.031
 37. Franz MR. Current status of monophasic action potential recording: theories, measurements and interpretations. *Cardiovasc Res*. 1999;41:25–40. doi: 10.1016/s0008-6363(98)00268-5
 38. Janse MJ, Kleber AG. Electrophysiological changes and ventricular arrhythmias in the early phase of regional myocardial ischemia. *Circ Res*. 1981;49:1069–1081. doi: 10.1161/01.res.49.5.1069
 39. Haissaguerre M, Nademanee K, Sacher F, Cheniti G, Hocini M, Surget E, Dubois R, Vigmond E, Bernus O. Multisite conduction block in the epicardial substrate of Brugada syndrome. *Heart Rhythm*. 2022;19:417–426. doi: 10.1016/j.hrthm.2021.10.030
 40. Szél T, Antzelevitch C. Abnormal repolarization as the basis for late potentials and fractionated electrograms recorded from epicardium in experimental models of Brugada syndrome. *J Am Coll Cardiol*. 2014;63:2037–2045. doi: 10.1016/j.jacc.2014.01.067
 41. Patocskaï B, Yoon N, Antzelevitch C. Mechanisms underlying epicardial radiofrequency ablation to suppress arrhythmogenesis in experimental models of Brugada syndrome. *JACC Clin Electrophysiol*. 2017;3:353–363. doi: 10.1016/j.jacep.2016.10.011
 42. Kawata H, Noda T, Yamada Y, Okamura H, Satomi K, Aiba T, Takaki H, Aihara N, Isoe M, Kamakura S, et al. Effect of sodium-channel blockade on early repolarization in inferior/lateral leads in patients with idiopathic ventricular fibrillation and Brugada syndrome. *Heart Rhythm*. 2012;9:77–83. doi: 10.1016/j.hrthm.2011.08.017
 43. Cheung CC, Mellor G, Deyell MW, Ensam B, Batchvarov V, Papadakis M, Roberts JD, Leather R, Sanatani S, Healey JS, et al. Comparison of ajmaline and procainamide provocation tests in the diagnosis of Brugada syndrome. *JACC Clin Electrophysiol*. 2019;5:504–512. doi: 10.1016/j.jacep.2019.01.026
 44. Chen Q, Kirsch GE, Zhang D, Brugada R, Brugada J, Brugada P, Potenza D, Moya A, Borggrefe M, Breithardt G, et al. Genetic basis and molecular mechanism for idiopathic ventricular fibrillation. *Nature*. 1998;392:293–296. doi: 10.1038/32675
 45. Kapplinger JD, Tester DJ, Alders M, Benito B, Berthet M, Brugada J, Brugada P, Fressart V, Guerschicoff A, Harris-Kerr C, et al. An international compendium of mutations in the SCN5A-encoded cardiac sodium channel in patients referred for Brugada syndrome genetic testing. *Heart Rhythm*. 2010;7:33–46. doi: 10.1016/j.hrthm.2009.09.069
 46. Falkow S. Molecular Koch's postulates applied to microbial pathogenicity. *Rev Infect Dis*. 1988;10(suppl 2):S274–S276.
 47. Hill AB. The environment and disease: association or causation? *J R Soc Med*. 1965;58:295–300.
 48. Probst V, Wilde AAM, Barc J, Sacher F, Babuty D, Mabo P, Mansourati J, Le Scouarnec S, Kyndt F, Le Caignec C, et al. SCN5A mutations and the role of genetic background in the pathophysiology of Brugada syndrome. *Circ Cardiovasc Genet*. 2009;2:552–557. doi: 10.1161/CIRCGENETICS.109.853374
 49. Arking DE, Pulit SL, Crotti L, Van Der Harst P, Munroe PB, Koopmann TT, Sotoodehnia N, Rossin EJ, Morley M, Wang X, et al; CARE Consortium. Genetic association study of QT interval highlights role for calcium signaling pathways in myocardial repolarization. *Nat Genet*. 2014;46:826–836. doi: 10.1038/ng.3014

50. Bezzina CR, Barc J, Mizusawa Y, Remme CA, Gourraud JB, Simonet F, Verkerk AO, Schwartz PJ, Crotti L, Dagradi F, et al. Common variants at SCN5A-SCN10A and HEY2 are associated with Brugada syndrome, a rare disease with high risk of sudden cardiac death. *Nat Genet*. 2013;45:1044–1049. doi: 10.1038/ng.2712
51. Tadros R, Tan HL, El Mathari S, Kors JA, Postema PG, Lahrouchi N, Beekman L, Radivojkov-Blagojevic M, Amin AS, Meitinger T, et al; ESCAPE-NET Investigators. Predicting cardiac electrical response to sodium-channel blockade and Brugada syndrome using polygenic risk scores. *Eur Heart J*. 2019;40:3097–3107. doi: 10.1093/eurheartj/ehz435
52. Barc J, Tadros R, Glinge C, Chiang DY, Jouni M, Simonet F, Jurgens SJ, Baudic M, Nicastro M, Potet F, et al; KORA-Study Group. Genome-wide association analyses identify new Brugada syndrome risk loci and highlight a new mechanism of sodium channel regulation in disease susceptibility. *Nat Genet*. 2022;54:232–239. doi: 10.1038/s41588-021-01007-6
53. Watanabe H, Nogami A, Ohkubo K, Kawata H, Hayashi Y, Ishikawa T, Makiyama T, Nagao S, Yagihara N, Takehara N, et al. Electrocardiographic characteristics and SCN5A mutations in idiopathic ventricular fibrillation associated with early repolarization. *Circ Arrhythm Electrophysiol*. 2011;4:874–881. doi: 10.1161/CIRCEP.111.963983
54. Zhang ZH, Barajas-Martínez H, Xia H, Li B, Capra JA, Clatot J, Chen GX, Chen X, Yang B, Jiang H, et al. Distinct features of probands with early repolarization and Brugada syndromes carrying SCN5A pathogenic variants. *J Am Coll Cardiol*. 2021;78:1603–1617. doi: 10.1016/j.jacc.2021.08.024
55. Behr ER, Ben-Haim Y, Ackerman MJ, Krahn AD, Wilde AAM. Brugada syndrome and reduced right ventricular outflow tract conduction reserve: A final common pathway? *Eur Heart J*. 2021;42:1073–1081. doi: 10.1093/eurheartj/ehaa1051
56. Derangeon M, Montnach J, Cerpa CO, Jagu B, Patin J, Toumaniantz G, Girardeau A, Huang CLH, Colledge WH, Grace AA, et al. Transforming growth factor β receptor inhibition prevents ventricular fibrosis in a mouse model of progressive cardiac conduction disease. *Cardiovasc Res*. 2017;113:464–474. doi: 10.1093/cvr/cvx026
57. Royer A, Van Veen TAB, Le Bouter S, Marionneau C, Griol-Charhbilí V, Léoni AL, Steenman M, Van Rijen HVM, Demolombe S, Goddard CA, et al. Mouse model of SCN5A-linked hereditary Lenegre's disease age-related conduction slowing and myocardial fibrosis. *Circulation*. 2005;111:1738–1746. doi: 10.1161/01.CIR.0000160853.19867.61
58. Campuzano O, Fernández-Falgueras A, Iglesias A, Brugada R. Brugada syndrome and PKP2: evidences and uncertainties. *Int J Cardiol*. 2016;214:403–405. doi: 10.1016/j.ijcard.2016.03.194
59. Te Riele ASJM, Agullo-Pascual E, James CA, Leo-Macias A, Cerrone M, Zhang M, Lin X, Lin B, Rothenberg E, Sobreira NL, et al. Multilevel analyses of SCN5A mutations in arrhythmogenic right ventricular dysplasia/cardiomyopathy suggest non-canonical mechanisms for disease pathogenesis. *Cardiovasc Res*. 2017;113:102–111. doi: 10.1093/cvr/cvw234
60. Novelli V, Malkani K, Cerrone M. Pleiotropic phenotypes associated with PKP2 variants. *Front Cardiovasc Med*. 2018;5:184. doi: 10.3389/fcvm.2018.00184
61. Cerrone M, Remme CA, Tadros R, Bezzina CR, Delmar M. Beyond the one gene-one disease paradigm complex genetics and pleiotropy in inheritable cardiac disorders. *Circulation*. 2019;140:595–610. doi: 10.1161/CIRCULATIONAHA.118.035954
62. Cerrone M, Delmar M. Desmosomes and the sodium channel complex: implications for arrhythmogenic cardiomyopathy and Brugada syndrome. *Trends Cardiovasc Med*. 2014;24:184–190. doi: 10.1016/j.tcm.2014.02.001
63. Rivaud MR, Delmar M, Remme CA. Heritable arrhythmia syndromes associated with abnormal cardiac sodium channel function: ionic and non-ionic mechanisms. *Cardiovasc Res*. 2020;116:1557–1570. doi: 10.1093/cvr/cvaa082
64. Sato PY, Musa H, Coombs W, Guerrero-Serna G, Patiño GA, Taffet SM, Isom LL, Delmar M. Loss of plakophilin-2 expression leads to decreased sodium current and slower conduction velocity in cultured cardiac myocytes. *Circ Res*. 2009;105:523–526. doi: 10.1161/CIRCRESAHA.109.20418
65. Cerrone M, Lin X, Zhang M, Agullo-Pascual E, Pfenniger A, Chkourko Guskay H, Novelli V, Kim C, Tirasawadichai T, Judge DP, et al. Missense mutations in plakophilin-2 cause sodium current deficit and associate with a Brugada syndrome phenotype. *Circulation*. 2014;129:1092–1103. doi: 10.1161/CIRCULATIONAHA.113.003077
66. Rizzo S, Lodder EM, Verkerk AO, Wolswinkel R, Beekman L, Pillichou K, Basso C, Remme CA, Thiene G, Bezzina CR. Intercalated disc abnormalities, reduced Na⁺ current density, and conduction slowing in desmoglein-2 mutant mice prior to cardiomyopathic changes. *Cardiovasc Res*. 2012;95:409–418. doi: 10.1093/cvr/cvs219
67. Gomes J, Finlay M, Ahmed AK, Ciaccio EJ, Asimaki A, Saffitz JE, Quarta G, Nobles M, Syrris P, Chaubey S, et al. Electrophysiological abnormalities precede overt structural changes in arrhythmogenic right ventricular cardiomyopathy due to mutations in desmoplakin-A combined murine and human study. *Eur Heart J*. 2012;33:1942–1953. doi: 10.1093/eurheartj/ehr472
68. Asimaki A, Kapoor S, Plovie E, Arndt AK, Adams E, Liu ZZ, James CA, Judge DP, Calkins H, Churko J, et al. Identification of a new modulator of the intercalated disc in a zebrafish model of arrhythmogenic cardiomyopathy. *Sci Transl Med*. 2014;6:240ra74. doi: 10.1126/scitranslmed.3008008
69. Armaroli A, Balla C, Trabanelli C, Selvatici R, Brieda A, Sette E, Bertini M, Mele D, Biffi M, Campo GC, et al. Lamin A/C missense mutation R216C pinpoints overlapping features between Brugada syndrome and laminopathies. *Circ Genom Precis Med*. 2020;13:e002751. doi: 10.1161/CIRCGEN.119.002751
70. Hosseini SM, Kim R, Udupa S, Costain G, Jobling R, Liston E, Jamal SM, Szybowska M, Morel CF, Bowdin S, et al; National Institutes of Health Clinical Genome Resource Consortium. Reappraisal of reported genes for sudden arrhythmic death: evidence-based evaluation of gene validity for Brugada syndrome. *Circulation*. 2018;138:1195–1205. doi: 10.1161/CIRCULATIONAHA.118.035070
71. Grondin S, Davies B, Cadrin-Tourigny J, Steinberg C, Cheung CC, Jorda P, Healey JS, Green MS, Sanatani S, Alqarawi W, et al. Importance of genetic testing in unexplained cardiac arrest. *Eur Heart J*. 2022;43:3071–3081. doi: 10.1093/eurheartj/ehac145
72. Wang Y, Li C, Shi L, Chen X, Cui C, Huang J, Chen B, Hall DD, Pan Z, Lu M, et al. Integrin β 1D deficiency-mediated RyR2 dysfunction contributes to catecholamine-sensitive ventricular tachycardia in arrhythmogenic right ventricular cardiomyopathy. *Circulation*. 2020;141:1477–1493. doi: 10.1161/CIRCULATIONAHA.119.043504
73. Delmar M, Alvarado FJ, Valdivia HH. Desmosome-dyad crosstalk: an arrhythmogenic axis in arrhythmogenic right ventricular cardiomyopathy. *Circulation*. 2020;141:1494–1497. doi: 10.1161/CIRCULATIONAHA.120.046020
74. Kim JC, Pérez-Hernández M, Alvarado FJ, Maurya SR, Montnach J, Yin Y, Zhang M, Lin X, Vasquez C, Heguy A, et al. Disruption of Ca²⁺ homeostasis and connexin 43 hemichannel function in the right ventricle precedes overt arrhythmogenic cardiomyopathy in plakophilin-2-deficient mice. *Circulation*. 2019;140:1015–1030. doi: 10.1161/CIRCULATIONAHA.119.039710
75. Corrado D, Zorzi A, Cerrone M, Rigato I, Mongillo M, Bauce B, Delmar M. Relationship between arrhythmogenic right ventricular cardiomyopathy and Brugada syndrome. *Circ Arrhythm Electrophysiol*. 2016;9:e003631. doi: 10.1161/CIRCEP.115.003631
76. Kataoka S, Serizawa N, Kitamura K, Suzuki A, Suzuki T, Shiga T, Shoda M, Hagiwara N. An overlap of Brugada syndrome and arrhythmogenic right ventricular cardiomyopathy/dysplasia. *J Arrhythm*. 2016;32:70–73. doi: 10.1016/j.joa.2015.10.007
77. Basso C, Corrado D, Marcus FI, Nava A, Thiene G. Arrhythmogenic right ventricular cardiomyopathy. *Lancet*. 2009;373:1289–1300. doi: 10.1016/s0140-6736(09)60256-7
78. Leo-Macias A, Agullo-Pascual E, Delmar M. The cardiac connexome: non-canonical functions of connexin43 and their role in cardiac arrhythmias. *Semin Cell Dev Biol*. 2016;50:13–21. doi: 10.1016/j.semcdb.2015.12.002
79. Vermij SH, Abriel H, van Veen TAB. Refining the molecular organization of the cardiac intercalated disc. *Cardiovasc Res*. 2017;113:259–275. doi: 10.1093/cvr/cvw259
80. Ben-Haim Y, Asimaki A, Behr ER. Brugada syndrome and arrhythmogenic cardiomyopathy: overlapping disorders of the connexome? *Europace*. 2021;23:653–664. doi: 10.1093/eurpace/euaa277
81. Marras E, Basso C, Sciarra L, Delise P. Unexplained syncope, Brugada-like ECG and minimal structural right ventricular abnormalities: what is the right diagnosis? *J Cardiovasc Med*. 2009;10:273–275. doi: 10.2459/jcm.0b013e328322fc09
82. Letsas KP, Efremidis M, Weber R, Korantzopoulos P, Protonotarios N, Prappa E, Kounas SP, Evagelidou EN, Xydonas S, Kalusche D, et al. Epsilon-like waves and ventricular conduction abnormalities in subjects with type 1 ECG pattern of Brugada syndrome. *Heart Rhythm*. 2011;8:874–878. doi: 10.1016/j.hrthm.2011.01.043
83. Bastiaenen R, Cox AT, Castelletti S, Wijeyeratne YD, Colbeck N, Pakroo N, Ahmed H, Bunce N, Anderson L, Moon JC, et al. Late gadolinium enhancement in Brugada syndrome: a marker for subtle underlying cardiomyopathy? *Heart Rhythm*. 2017;14:583–589. doi: 10.1016/j.hrthm.2016.12.004
84. Catalano O, Antonaci S, Moro G, Mussida M, Frascaroli M, Baldi M, Cobelli F, Baiardi P, Nastoli J, Bloise R, et al. Magnetic resonance investigations in Brugada syndrome reveal unexpectedly high rate of structural abnormalities. *Eur Heart J*. 2009;30:2241–2248. doi: 10.1093/eurheartj/ehp252

85. Papavassiliu T, Wolpert C, Flüchter S, Schimpf R, Neff W, Haase KK, Düber C, Borggrefe M. Magnetic resonance imaging findings in patients with Brugada syndrome. *J Cardiovasc Electrophysiol*. 2004;15:1133–1138. doi: 10.1046/j.1540-8167.2004.03681.x
86. Papavassiliu T, Veltmann C, Doesch C, Haghi D, Germans T, Schoenberg SO, Van Rossum AC, Schimpf R, Brade J, Wolpert C, et al. Spontaneous type 1 electrocardiographic pattern is associated with cardiovascular magnetic resonance imaging changes in Brugada syndrome. *Heart Rhythm*. 2010;7:1790–1796. doi: 10.1016/j.hrthm.2010.09.004
87. Rudic B, Schimpf R, Veltmann C, Doesch C, Tülümen E, Schoenberg SO, Borggrefe M, Papavassiliu T. Brugada syndrome: clinical presentation and genotype-correlation with magnetic resonance imaging parameters. *Europace*. 2016;18:1411–1419. doi: 10.1093/europace/euv300
88. Postema PG, van Dessel PFHM, de Bakker JMT, Dekker LRC, Linnenbank AC, Hoogendijk MG, Coronel R, Tijssen JGP, Wilde AAM, Tan HL. Slow and discontinuous conduction conspire in Brugada syndrome: a right ventricular mapping and stimulation study. *Circ Arrhythm Electrophysiol*. 2008;1:379–386. doi: 10.1161/CIRCEP.108.790543
89. Lambiase PD, Ahmed AK, Ciaccio EJ, Brugada R, Lizotte E, Chaubey S, Ben-Simon R, Chow AW, Lowe MD, McKenna WJ. High-density substrate mapping in Brugada syndrome: combined role of conduction and repolarization heterogeneities in arrhythmogenesis. *Circulation*. 2009;120:106–117, 1–4. doi: 10.1161/CIRCULATIONAHA.108.771401
90. Tessa C, Del Meglio J, Ottonelli AG, Diciotti S, Salvatori L, Magnacca M, Chioccioli M, Lera J, Vignali C, Casolo G. Evaluation of Brugada syndrome by cardiac magnetic resonance. *Int J Cardiovasc Imaging*. 2012;28:1961–1970. doi: 10.1007/s10554-012-0009-5
91. Gray B, Gnanappa GK, Bagnall RD, Femia G, Yeates L, Ingles J, Burns C, Puranik R, Grieve SM, Semsarian C, et al. Relations between right ventricular morphology and clinical, electrical and genetic parameters in Brugada Syndrome. *PLoS One*. 2018;13:e0195594. doi: 10.1371/journal.pone.0195594
92. Hohneck A, Overhoff D, Rutsch M, Rudic B, Tülümen E, Wolpert C, Hetjens S, Akin I, Borggrefe M, Papavassiliu T. Risk stratification of patients with Brugada syndrome: the impact of myocardial strain analysis using cardiac magnetic resonance feature tracking. *Hellenic J Cardiol*. 2021;62:329–338. doi: 10.1016/j.hjc.2021.05.003
93. Isbister JC, Gray B, Offen S, Yeates L, Naoum C, Medi C, Raju H, Semsarian C, Puranik R, Sy RW. Longitudinal assessment of structural phenotype in Brugada syndrome using cardiac magnetic resonance imaging. *Heart Rhythm O2*. 2023;4:34–41. doi: 10.1016/j.hrthm.2022.10.004
94. Boukens BJ, Nademanee K, Coronel R. Reply: J-wave syndromes: where's the scar? *JACC Clin Electrophysiol*. 2020;6:1863–1864. doi: 10.1016/j.jacep.2020.10.003
95. Scheirlyncx E, Chivulescu M, Lie OH, Motoc A, Koulalis J, de Asmundis C, Sieira J, Chierchia GB, Brugada P, Cosyns B, et al. Worse prognosis in Brugada syndrome derives from the arrhythmogenic cardiomyopathy features. *JACC Clin Electrophysiol*. 2020;6:1353–1363. doi: 10.1016/j.jacep.2020.05.026
96. Zaffran S, Kelly RG, Meilhac SM, Buckingham ME, Brown NA. Right ventricular myocardium derives from the anterior heart field. *Circ Res*. 2004;95:261–268. doi: 10.1161/01.RES.0000136815.73623.BE
97. de la Cruz M, Sánchez Gómez C, Arteaga MM, Argüello C. Experimental study of the development of the truncus and the conus in the chick embryo. *J Anat*. 1977;123:661–686.
98. Boukens BJ, Sylva M, de Gier-De Vries C, Remme CA, Bezzina CR, Christoffels VM, Coronel R. Reduced sodium channel function unmasks residual embryonic slow conduction in the adult right ventricular outflow tract. *Circ Res*. 2013;113:137–141. doi: 10.1161/CIRCRESAHA.113.301565
99. Kimura Y, Aiba T, Sasano T, Furukawa T, Kusano K, Shimizu W. IRX3 variant as a modifier of Brugada syndrome with frequent ventricular fibrillation. *HeartRhythm Case Rep*. 2016;2:465–468. doi: 10.1016/j.hrcr.2016.06.002
100. al Sayed ZR, Canac R, Cimarosti B, Bonnard C, Gourraud JB, Hamamy H, Kayserili H, Girardeau A, Jouni M, Jacob N, et al. Human model of IRX5 mutations reveals key role for this transcription factor in ventricular conduction. *Cardiovasc Res*. 2021;117:2092–2107. doi: 10.1093/cvr/cvaa259
101. van Ouwerkerk AF, Bosada FM, van Duijvenboden K, Houweling AC, Scholman KT, Wakker V, Allaart CP, Uhm JS, Mathijssen IB, Baartscheer T, et al. Patient-specific TBX5-G125R variant induces profound transcriptional deregulation and atrial dysfunction. *Circulation*. 2022;145:606–619. doi: 10.1161/CIRCULATIONAHA.121.054347
102. Koizumi A, Sasano T, Kimura W, Miyamoto Y, Aiba T, Ishikawa T, Nogami A, Fukamizu S, Sakurada H, Takahashi Y, et al. Genetic defects in a His-Purkinje system transcription factor, IRX3, cause lethal cardiac arrhythmias. *Eur Heart J*. 2016;37:1469–1475. doi: 10.1093/eurheartj/ehv449
103. Kim KH, Rosen A, Bruneau BG, Hui CC, Backx PH. Iroquois homeodomain transcription factors in heart development and function. *Circ Res*. 2012;110:1513–1524. doi: 10.1161/CIRCRESAHA.112.265041
104. Veerman CC, Podliesna S, Tadros R, Lodder EM, Mengarelli I, de Jonge B, Beekman L, Barc J, Wilders R, Wilde AAM, et al. The Brugada syndrome susceptibility gene *HEY2* modulates cardiac transmural ion channel patterning and electrical heterogeneity. *Circ Res*. 2017;121:537–548. doi: 10.1161/CIRCRESAHA.117.310959
105. Portero V, Wilders R, Casini S, Charpentier F, Verkerk AO, Remme CA. KV4.3 expression modulates NaV1.5 sodium current. *Front Physiol*. 2018;9:178. doi: 10.3389/fphys.2018.00178