

Choledochal cyst with prenatal diagnosis and postnatal management: A case report

Quiste de colédoco con diagnóstico prenatal y manejo postnatal: un reporte de caso

Lisbeth Andreina Medina Torres*  and Jeisson Hincapié Álvarez 



Open Access

Correspondence:

lisbethandreinatorres24@gmail.com
Mariangel Clinic. Dumian Medical
Tulua-Valle del Cauca, Colombia.

First draft submitted:
20-08-2022

Accepted for publication:
13-10-2022

Published on line:
30-11-2022

Key words:

Biliary atresia; Biliary cystic malformation; Choledochal cyst; Prenatal diagnosis; neonate; rare malformations.

Palabras clave:

Atresia biliar; diagnóstico prenatal; malformación quística biliar; malformaciones infrecuentes; neonato; quiste colédoco.

Citation:

Medina Torres L, Hincapié Álvarez J. Choledochal cyst with prenatal diagnosis and postnatal management. *Magna Scientia UCEVA* 2022;2:2 157-163. <https://doi.org/10.54502/msuceva.v2n2a2>

Abstract

Cystic dilatation of the bile duct is part of a wide spectrum of biliary pathology with different etiopathogenic mechanisms. Choledochal cysts are rare malformations of the bile ducts. It is diagnosed in most cases during early childhood, although it can present at any age of life. The clinical presentation is variable and can be manifested by abdominal pain, palpable mass, cholestatic jaundice or by symptoms linked to the development of some of its complications: pancreatitis, cholangitis or rupture. The diagnosis is made through abdominal ultrasound and is completed with a magnetic cholangiography the recommended treatment is complete surgical resection that prevents the appearance of complications. A case of ultrasound prenatal diagnosis presented at 29 weeks of gestation along with its evolution, management and postnatal treatment, it is also the first case in this health center located in Valle del Cauca.

Resumen

La dilatación quística de la vía biliar forma parte de un amplio espectro de patología biliar con diferentes mecanismos etiopatogénicos. Los quistes de colédoco son malformaciones infrecuentes de las vías biliares. Se diagnostica en la mayoría de los casos durante la infancia temprana, aunque puede presentarse a cualquier edad de la vida. La presentación clínica es variable pudiendo manifestarse por dolor abdominal, masa palpable ictericia colestática o por síntomas vinculados al desarrollo de algunas de sus complicaciones: pancreatitis, colangitis o ruptura. El diagnóstico se realiza a través de la ecografía abdominal y se completa con una colangio resonancia magnética, el tratamiento recomendado es la resección quirúrgica completa que previene la aparición de complicaciones. Se presenta un caso de diagnóstico prenatal ecográfico a las 29 semanas de gestación junto con su evolución, manejo y tratamiento postnatal, además es primer caso en este centro de salud ubicado en el Valle del Cauca.



Introduction

Choledochal cysts are congenital malformations of the bile ducts due to dilation of the common bile duct, predominant in women and in Asian countries [1,2]. The etiology of this pathology is still unclear [3,4]. The advancement of fetal ultrasonographic detection have allowed to an increasing in its prenatal diagnosis, with the finding being a simple cystic image at the level of the right upper fetal hemiabdomen, in the second or third trimester of gestation, constituting the greatest diagnostic certainty by visualizing the communication between the cystic image and bile duct [5].

The importance of prenatal diagnosis lies in early postnatal surgical management, due to complications that occur in cases of asymptomatic newborns [3,6]. Previous researches have postulated the existence of an alteration in the pancreatobiliary junction with sphincter of Oddi dysfunction, which ends up favoring a reflux of pancreatic enzymes into the biliary system [7-9]. Nevertheless, there are other theories involving congenital weakness of the duct wall, mucosal abnormalities, obstruction of the distal biliary system, and even congenital infections [10-12].

Case report

This is a female patient, the daughter of a 22-year-old mother, primiparous, with no contributing personal and family history, in the obstetric ultrasound performed at 20 weeks, a compatible double-bubble image, finding an etiology to be determined, diagnostic impression of esophageal or duodenal atresia (see figure 1).

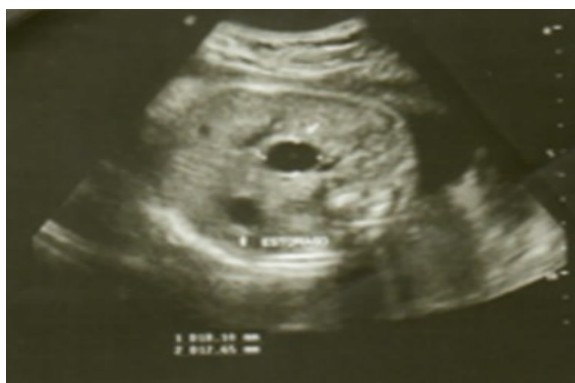

Figure 1 Prenatal ultrasound (20 weeks) compatible with the double bubble sign. Diagnostic impression: esophageal atresia or duodenal atresia

In the third trimester, the abdominal circumference is in upper percentiles for gestational age due to an increasing in the cyst size, the obstetric ultrasound is performed again at 29 weeks, which reports an intra-abdominal cystic image of 26 x 21 mm in the right hypochondrium without central vascularization by color Doppler study and found in a contiguous relationship with the gallbladder with a diagnosis of probable choledochal cyst. The childbirth takes place at 39 weeks; the weight at birth is 3135 grams. In the immediate neonatal care, no malformations were found and the abdominal evaluation is normal. Subsequently, an abdominal ultrasound was performed (see figure 2).

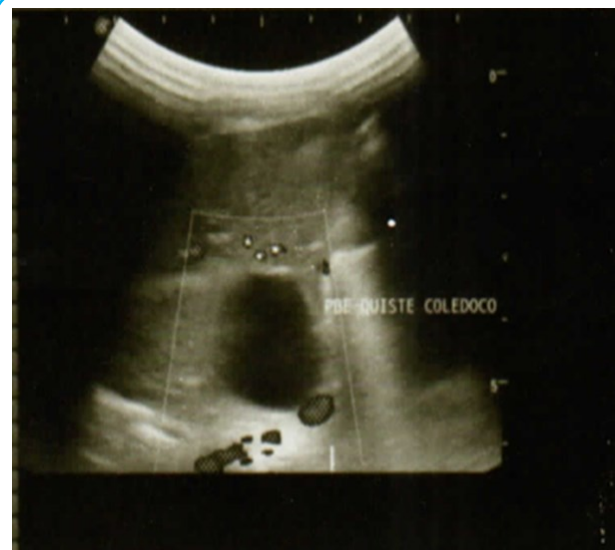

Figure 2 Postnatal ultrasound

A 60x41x45 mm choledochal cyst was evident (figure 2). No ascitis, gallbladder not visible. Pancreas, spleen sonographically normal. In the magnetic resonance cholangiography, which was performed at 34 days of life, a cystic image of large volume and oval morphology of 45x48x45 mm was identified, and in the sequences, an apparent communication with the bile duct was observed, suspicious of a choledochal cyst with deviation of the bile duct; a retroperitoneum towards the left posterior region, as well as slight rejection of both kidneys. The liver did not present focal lesions and was slightly displaced by the cystic image described previously. The contrasted sequences have allowed to establish a lesion delimitation observing its perihepatic location. It is worth mentioning that is kept under control by external consultation by the pediatric surgery service (in another health center) (see figure 3).

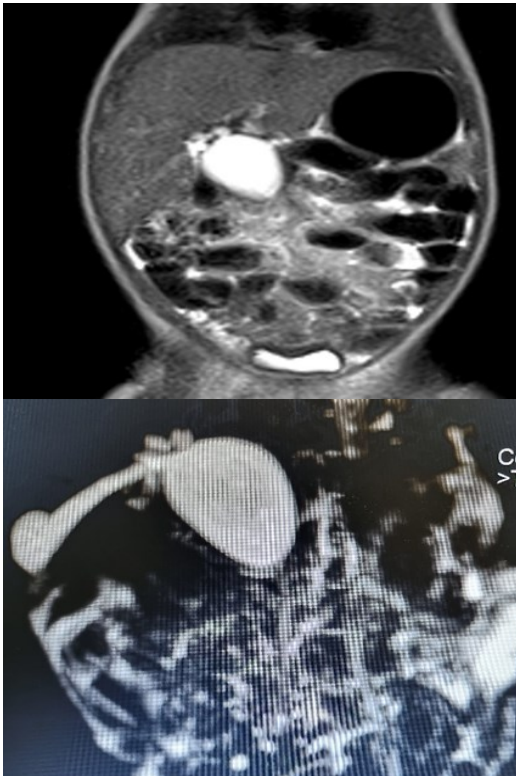


Figure 3 Magnetic resonance cholangiography (CRM): at 34 days of life. Oval cystic image suspicious of choledochal cyst with deviation of the retroperitoneum with slight rejection of both kidneys.

At 15 months of age, the patient went to the emergency department with fever for approximately 6 days, in addition to an increasing abdominal girth, vomiting, and canker sores. On physical examination: feverish to touch, vital signs were within normal limits. A distended abdomen was evidenced, with hepatomegaly five (5) cm below the costal margin, without pain on palpation. Laboratory tests found the following baselines: *i*) total bilirubin: 3.78 mg/dl; *ii*) indirect bilirubin: 3.3 mg/dl; *iii*) direct bilirubin: 0.48 mg/dl; *iv*) hemoglobin: 8.50mg/dl and *v*) hematocrit: 26 (30%), however, did not performed any jaundice. A total abdominal ultrasound was performed that showed hepatomegaly with a homogeneous increasing in the echogenicity of the liver parenchyma and a cystic-looking image of 665×51 mm with 360 cc, choledochal cyst, bile sludge; the rest is within normal parameters. On the third day of admission, the patient presented elevated blood pressure figures. Immediately afterwards, a double contrast computed tomography of the abdomen was requested due to the report of the total abdomen ultrasound with contrast, which reported that the changes described at the level of the upper right hemiabdomen, were related to a

cystic lesion with a content of approximately 760cc. A compression in the right renal vein, shows a septum inside and on its periphery, which covers the entire area of the epigastrium and mesogastrium, displaces loops, whose lesion has grown to the retroperitoneal area, displacing the cava vena (see figure 4).

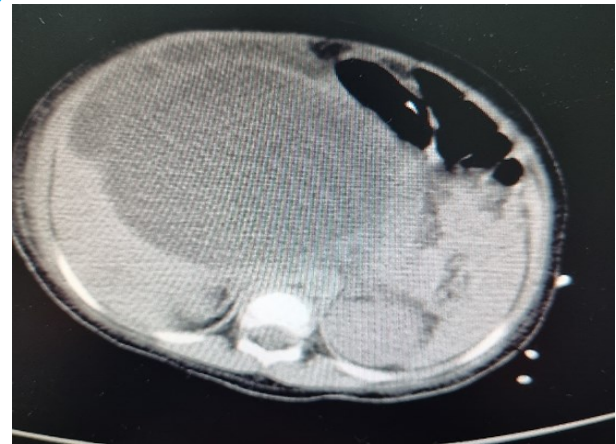


Figure 4 CT of the abdomen with double contrast (15 months old): cystic lesion with a content of 760 cc compression of the right renal vein encompassing the epigastrium and mesogastrium area displaces loops and vena cava

In the evaluation for pediatric surgery, it was decided to perform a surgical procedure. A right transverse incision was carried out with an approach to the peritoneal cavity, and a large retroperitoneal mass of 20×20cm was found. When separating the transverse colon, it was evidenced that the mass corresponds to a large choledochal cyst; the caliber of the common hepatic duct was 3 mm. Subsequently, the choledochal cyst was resected, biliodigestive bypass was performed with Roux Y and a drain was left, respectively (see figure 5).

The patient tolerated the procedure satisfactorily. She was kept off the oral route for 10 days and then enteral feeding was started, with good evolution. Control liver and kidney function tests were within normal limits. Pathology reported acute cholecystitis with pyocolecyst, unrepresented lithiasis, lesion-free cystic margin, choledochal cyst, pericystic ganglion without pathological changes. The patient was discharged on postoperative day 15 without any complications and it was evidenced that up to three months of follow-up, the evolution has been favorable.

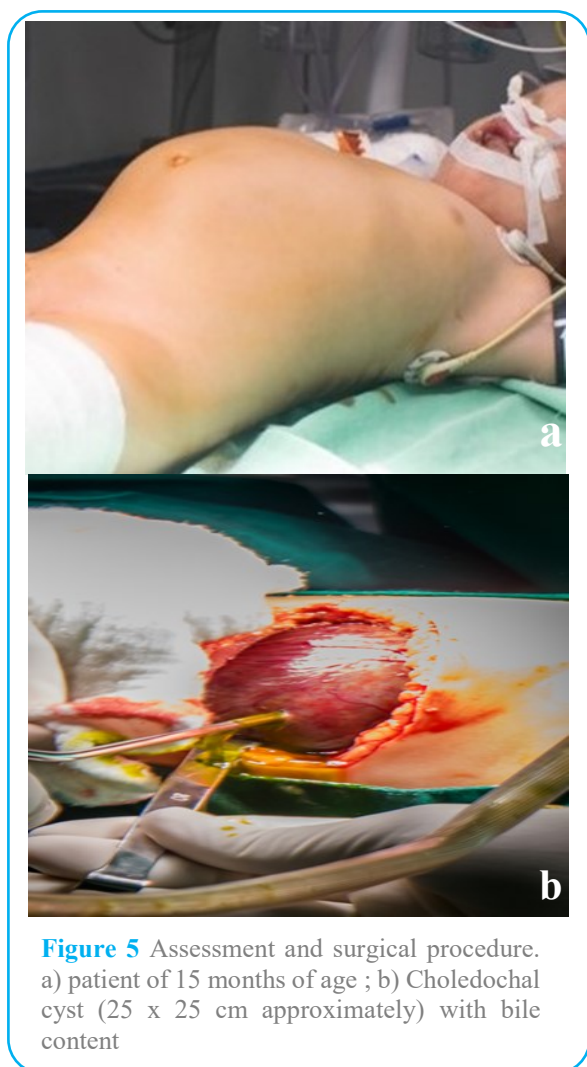


Figure 5 Assessment and surgical procedure. a) patient of 15 months of age ; b) Choledochal cyst (25 x 25 cm approximately) with bile content

Discussion

The choledochal cyst (CC) is a rare congenital anomaly first described by Váter in 1723. In 1817, Todd reported a case, and it was not until 1852 that Douglas published the first documented case [2]. It is the first case reported in this health center and area of Valle de Cauca, Colombia. In the West, it has a frequency rate of approximately 1 in 2 million live births [10,13,14] and it predominates in the female sex (4:1 or more), as occurred with the newborn presented in this case report. It is more common in Asian countries and it is presumed that two thirds of the total cases in the world, are registered in Japan [1,11,15].

The etiology has not yet been well established. Various theories have been proposed, the best known and accepted is the one that involves the union of the pancreatic duct with the common bile duct, 1 or 2 cm proximal to the sphincter of Oddi, creating an

abnormal common duct (more than 15 mm in length), which allows secretion to reflux. pancreatic and causes damage to the wall and subsequent dilation of the common bile duct. Todani, for example, showed that most cases of choledochal cyst have a long common duct and various angles of confluence of the mentioned ducts [16-18]. Contrary to this theory, it is stated that CC can be diagnosed prenatally, before the exocrine function of the pancreas begins [19,20].

By virtue of the above, other causes have been mentioned such as: *i*) the lack of fusion between the intrahepatic and extrahepatic ducts; *ii*) local arterial occlusion; *iii*) infections; *iv*) autoimmune processes and *v*) other eventual prenatal lesions. It must be considered that no theory explains the wide predominance in the female sex and that some familial cases suggest a possible genetic predisposition. The case presented here is of a female fetus. Technical advances in diagnostic methods, specifically ultrasonography (US), have made it possible to considerably increase the number of cases diagnosed during pregnancy, while at the same time giving rise to a new group: newborns with prenatal diagnosis [21,22]. Diagnosis by US can be made in the second and even late in the third trimester of pregnancy with normal ultrasounds sometimes reported in the morphological evaluation at 20 to 24 weeks [23,24]. Characteristically, a simple anechoic image is detected in the upper hemiabdomen, in front of the right kidney, very close to the portal vein; it can be visualized to the right or to the left of the hepatic duct or located close to the gallbladder. The diagnosis of certainty is established when a communication between the cyst and the bile duct is visualized.

The most widely accepted classification was reported by Todani et al. in 1977 [3,6], derived from the original Alonso-Lej classification and based on the location of the cyst in the bile duct (see figure 6). Five types of CC are described and classified as follows: *i*) type I (80%-90% of the total CC); *ii*) type II; *iii*) type III; *iv*) type IV (15%-20% of the total CC) and *v*) type V or the Caroli disease [3]. Type I, the most common (80%), consists of cystic dilatation of the common bile duct with a normal intrahepatic bile duct. The dilation can be spherical (Ia), segmental (Ib) or fusiform (Ic). Type II, common hepatic duct or common bile duct diverticulum, rare. Type III or choledochoceles, dilation of the intrapancreatic common bile duct in the duodenal wall; it is the least frequent modality. Type IV is intrahepatic and/or extrahepatic cystic dilatation of the bile ducts; it is

subdivided into type IV A based on the location of the cyst in the bile duct (figure 6).

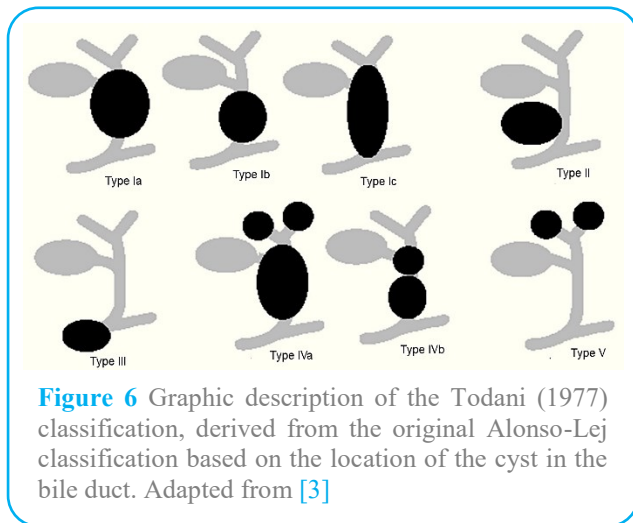


Figure 6 Graphic description of the Todani (1977) classification, derived from the original Alonso-Lej classification based on the location of the cyst in the bile duct. Adapted from [3]

In the case presented here, the diagnosis was made in the third trimester, as a finding in the ultrasonographic study in an asymptomatic pregnant woman and in a fetus without compressive tumor or hemodynamic involvement. The Doppler study allowed us to corroborate the cystic nature of the tumor and the probable benign behavior. To date, no similar cases had been reported at the institution where the research was carried out. The differential diagnosis includes other abdominal cystic lesions: bile duct atresia with cystic dilation of part of the biliary tree, ovarian cyst, kidney cyst, congenital liver cysts, cystic lymphoma, among others. The advantage of prenatal diagnosis is that it allows the neonatal team to guide the pathology with a perinatal approach. Thus, adequate neonatal support and prompt postnatal surgical planning could be provided according to the case, as explained in this study. During pregnancy, the behavior must be expectant, prioritizing delivery at natural term. After birth, the diagnosis can be confirmed by US and/or magnetic resonance cholangiography, as it was carried out in this case report. Treatment consists of the CC resection and performance of a hepatic-jejuno anastomosis with a Y Roux. In the absence of symptoms, it is stated that surgery should be carried out as early as possible, in order to avoid the serious complications caused by CC: cholangitis, liver

abscesses, portal hypertension, cirrhosis and likewise, malignant degeneration. All these complications increase their frequency considerably in direct relation to the age of the patient. Surgery, in the case presented, was performed in the late neonatal period using the technique of choice of surgical resection of the choledochal cyst with a Y- Roux biliodigestive diversion. The post-surgical evolution was favorable and up to three months of follow-up no complications had been reported.

Conclusion

The choledochal cyst (CC) is a rare disease, predominantly in childhood and adolescence. The average prenatal diagnosis of routine ultrasound is possible and allows early surgical intervention, in search of preventing subsequent complications.

Consent for publication

The authors read and approved the final manuscript.

Competing interest

The authors declare no conflict of interest. This document only reflects their point of views and not that of the institution to which they belong.

Acknowledgments

The authors would like to thank Dr. Luis Mauricio Figueroa Gutiérrez. Assistant Professor at the Universidad del Valle, Colombia for his valuable collaboration and unconditional support for respecting our suggestions and ideas and for the direction and rigor that he has provided to them.

Author details

Lisbeth Medina Torres

Medical specialist in pediatric surgery and minimally invasive surgery. General physician Latin American School of Medicine in Havana Cuba; Postgraduate at Central University of Venezuela. Minimally invasive surgery and endopraxis at Javeriana

University. Member of the Society of Pediatric Surgery of Colombia.



Jeisson Hincapié Álvarez

General Physician. Specialist in Family Medicine. Specialist in General Surgery. Digestive endoscopy with training and specialization in Retrograde Cholangiopancreatography Latin American School of Medicine Havana-Cuba



References

- [1] Baison GN, Bonds MM, Helton WS, Kozarek RA. Choledochal cysts: Similarities and differences between Asian and Western countries. *World J Gastroenterol* 2019;25:3334–43. <https://doi.org/10.3748/wjg.v25.i26.3334>
- [2] Huerta Sáenz I, Elías J, Torres E. Quiste de colédoco fetal: diagnóstico prenatal y manejo perinatal. *Rev Per Ginecol Obstet* 2013;59:59–62. <http://www.scielo.org.pe/pdf/rgo/v59n1/a10v59n1.pdf>.
- [3] Giha S, Redondo Y, Quintero G. Quiste de colédoco: diagnóstico y manejo intraoperatorio. *Pediatría (Bucur)* 2016;49:64–7. <https://doi.org/10.1016/j.rcpe.2016.04.004>
- [4] Corrochano M, LLanos R, García A. Quiste de colédoco en una lactante de tres meses de edad: diagnóstico prenatal y manejo quirúrgico. *Rev Pediatr Esp* 2013;4:84–8. <https://wp-intercienciamedica-prd.azurewebsites.net/wp-content/uploads/2021/07/Quiste-de-coledoco-en-una-lactante-de-tres-meses-de-edad-diagnostico-prenatal-y-manejo-quirurgico.pdf>.
- [5] Soares KC, Arnaoutakis DJ, Kamel I, Rastegar N, Anders R, Maithel S, et al. Choledochal Cysts: Presentation, Clinical Differentiation, and Management. *J Am Coll Surg* 2014;219:1167–80. <https://doi.org/10.1016/j.jamcollsurg.2014.04.023>
- [6] López Ruiz R, Aguilera Alonso D, Muñoz Aguilar G, Fonseca Martín R. Quistes de colédoco, una causa inusual de ictericia en pediatría. Presentación de serie de casos. *Rev Chil Pediatr* 2016;87:137–42. <https://doi.org/10.1016/j.rchipe.2015.08.009>
- [7] Peñaloza- Ramírez A, Coral- Argoty E, Castro-Rodríguez M, Álvarez- Gil J, Aponte-Ordoñez P. Disfunción del esfínter de Oddi: un reporte de caso. *Rev Colomb Gastroenterol* 2021;36:52–8. <https://doi.org/10.22516/25007440.550>
- [8] Sugita R. Pancreaticobiliary reflux as a high-risk factor for biliary malignancy: Clinical features and diagnostic advancements. *World J Hepatol* 2015;7:1735. <https://doi.org/10.4254/wjh.v7.i13.1735>
- [9] Calzadilla J, Sanhueza N, Farías S, González F. Recurrent pancreatitis secondary to sphincter of Oddi dysfunction: case report. *Medwave* 2016;16:e6585–e6585. <https://doi.org/10.5867/medwave.2016.09.6585>
- [10] Machado K, Cascino C, Ghione A, Montano A. Quiste de colédoco. Presentación en un lactante con fiebre. Caso clínico. *Arch Pediatr Urug* 2011;82:23–8. <http://www.scielo.edu.uy/pdf/adp/v82n1/v82n1a05.pdf>
- [11] Singham J, Yoshida EM, Scudamore CH. Choledochal cysts: part 1 of 3: classification and pathogenesis. *Can J Surg* 2009;52:434–40. PMID:19865581.
- [12] DeJesus J, Hughes B, Geisler E, Defilippo C, Gaffey J, Radhakrishnan RS. Type II choledochal cyst of the cystic duct in a 3-month-old. *J Pediatr Surg Case Rep* 2022;86:102440. <https://doi.org/10.1016/j.epsc.2022.102440>
- [13] Farías Molina SM, Castillo Machado RL, Sanhueza Palma NC, Calzadilla Riveras JA. Todani choledochal cyst type II: case report and review. *Medwave* 2016;16:e6583–e6583. <https://doi.org/10.5867/medwave.2016.09.6583>
- [14] Torres M, Becerra M, Calderón B, Salinas I, Ruiz M, Ventura J. Choledochal Cyst. Biliary Tract - Review and Recent Progress [Working Title], IntechOpen; 2022. <https://doi.org/10.5772/intechopen.106451>
- [15] Baison GN, Bonds MM, Helton WS, Kozarek RA. Choledochal cysts: Similarities and differences between Asian and Western countries. *World J Gastroenterol* 2019;25:3334–43. <https://doi.org/10.3748/wjg.v25.i26.3334>
- [16] Dezerega P, Sepúlveda E, González G, Pérez P, Jara M, Vásquez M. Tumores fetales: II parte. *Rev Chilena Ultras* 2006;9:24–33. <http://www.sochumb.cl/wp-content/uploads/2018/06/US-10-2-2007-b.pdf>.
- [17] Gürsoy Çoruh A, Gülpınar B, Baş H, Erden A. Frequency of bile duct confluence variations in subjects with pancreas divisum: an analysis of MRCP findings. *Diagn Interv Radiol* 2018;24:72–6. <https://doi.org/10.5152/dir.2018.17200>
- [18] Kim JY, Kim HJ, Han HY. A Case Report of an Unusual Type of Choledochal Cyst with Choledocholithiasis: Saccular Dilatation of the Confluent Portion of Both Intrahepatic Ducts. *Journal of the Korean Society of Radiology* 2015;73:252. <https://doi.org/10.3348/jksr.2015.73.4.252>
- [19] Kumar M, Rajagopalan S. Choledochal cyst. *Med J Armed Forces India* 2012;68:296–8. <https://doi.org/10.1016/j.mjafi.2012.04.011>
- [20] Hamid R, Bhat NA, Ahmad M, Singh B. Choledochal Cyst (CDC). *Gastrointestinal Surgery - New Technical Proposals*, InTech; 2018. <https://doi.org/10.5772/intechopen.72938>
- [21] Whitworth M, Bricker L, Mullan C. Ultrasound for fetal assessment in early pregnancy. *Cochrane Database Syst Rev* 2015;2015:CD007058. <https://doi.org/10.1002/14651858.CD007058.pub3>

[22] Carlson LM, Vora NL. Prenatal Diagnosis: Screening and Diagnostic Tools. *Obstet Gynecol Clin North Am* 2017;44:245–56. <https://doi.org/10.1016/j.ogc.2017.02.004>

[23] Bricker L, Medley N, Pratt JJ. Routine ultrasound in late pregnancy (after 24 weeks' gestation). *Cochrane Database Syst Rev* 2015;2015:CD001451. <https://doi.org/10.1002/14651858.CD001451.pub4>

[24] Wilson ECF, Wastlund D, Moraitis AA, Smith GCS. Late pregnancy ultrasound to screen for and manage potential birth complications in nulliparous women: a cost-effectiveness and value of information analysis. *Value in Health* 2021;24:513–21. <https://doi.org/10.1016/j.jval.2020.11.005>