


Is the brain involved in patients with late-onset Pompe disease?

Jan J. A. van den Dorpel¹  | Willemijn M. C. van der Vlugt² |
 Marjolein H. G. Dremmen³ | Ryan Muetzel⁴ | Esther van den Berg² |
 Roos Hest² | Joni de Kriek² | Esther Brusse⁵ | Pieter A. van Doorn⁵ |
 Ans T. van der Ploeg¹ | Johanna M. P. van den Hout¹ |
 Nadine A. M. E. van der Beek⁵

¹Department of Pediatrics, Erasmus MC, University Medical Center Rotterdam, Center for Lysosomal and Metabolic Diseases, Rotterdam, The Netherlands

²Department of Neurology, Erasmus MC, University Medical Center Rotterdam, Rotterdam, The Netherlands

³Department of Radiology, Erasmus MC, University Medical Center Rotterdam, Rotterdam, The Netherlands

⁴Department of Child and Adolescent Psychiatry/Psychology, Erasmus MC, University Medical Center Rotterdam, Rotterdam, The Netherlands

⁵Department of Neurology, Erasmus MC, University Medical Center Rotterdam, Center for Lysosomal and Metabolic Diseases, Rotterdam, The Netherlands

Correspondence

Nadine A. M. E. van der Beek,
 Department of Neurology, Erasmus MC,
 University Medical Center Rotterdam,
 Center for Lysosomal and Metabolic
 Diseases, PO Box 2040, 3000 CA
 Rotterdam, The Netherlands.
 Email: n.beek@erasmusmc.nl

Funding information

Research on Pompe disease at Erasmus MC is financially supported by Prinses Beatrix Spierfonds (project number W. OR16-07), ZonMw (grant number 152001005), Sophia Foundation for

Abstract

Our objective was to investigate brain structure, cerebral vasculature, and cognitive function in a cohort of patients with late-onset Pompe disease, with particular reference to the differences from those with the classic infantile phenotype, where extensive white-matter abnormalities (WMA) and impaired cognition on long-term enzyme treatment are reported in a subset of patients. Brain imaging (T1, T2, T2 fluid-attenuated inversion recovery, susceptibility-weighted images, and magnetic resonance angiography–time of flight) was combined with extensive cognitive testing of general intelligence (Wechsler IQ Test, Montreal Cognitive Assessment [MoCA]) and specific neuropsychological domains (verbal fluency, cognitive flexibility, attention, memory, and visuospatial abilities). We included 19 patients with late-onset Pompe disease (age range 11–56 years). Two patients showed mild punctate WMA within normal range for age, with a Fazekas score (FS) of 1 to 2. Magnetic resonance angiography revealed a slight vertebrobasilar dolichoectasia in two patients yet did not show any aneurysms or vascular dissections. Most patients had age-adjusted scores within the normal range for the Wechsler index scores (verbal comprehension, perceptual reasoning, working memory, and processing speed) and combined total intelligence (IQ) score (median 101, interquartile range 91–111; one patient had a below-average score for total IQ) as well as for the specific domains verbal fluency, attention, and memory. A subset of patients performed suboptimally on the Rey Complex Figure Test (9/14 patients) or cube-copying/clock-drawing test of the MoCA (8/10 patients). We therefore concluded that our study showed no brain abnormalities, other than minor microvascular lesions considered within normal range for age, nor

The corresponding author takes full responsibility for the data, has full access to all data, and has the right to publish all data apart from any sponsor.

This is an open access article under the terms of the [Creative Commons Attribution-NonCommercial](https://creativecommons.org/licenses/by-nc/4.0/) License, which permits use, distribution and reproduction in any medium, provided the original work is properly cited and is not used for commercial purposes.

© 2021 The Authors. *Journal of Inherited Metabolic Disease* published by John Wiley & Sons Ltd on behalf of SSIEM.

Medical Research (SSWO; project number S17–32), and Metakids (project number 2016–063). Dr. van der Beek received a postdoctoral fellowship from the Prinses Beatrix Spierfonds (W.F16-03). The authors confirm independence from the sponsors; the content of the article has not been influenced by the sponsors.

Communicating Editor: David Cassiman

general cognitive impairment in late-onset Pompe patients. These findings are in sharp contrast with the widespread WMA and cognitive problems found in some classic infantile patients.

KEYWORDS

cognition, dolichoectasia, MRI brain imaging, neuropsychological assessment, Pompe disease, white-matter abnormalities

1 | INTRODUCTION

Pompe disease is a metabolic myopathy caused by a partial or total lack of the lysosomal enzyme acid alpha-glucosidase. This results in glycogen accumulation, particularly in muscle tissue, but it has also been found in the brain of patients with the relentlessly progressive classic infantile phenotype, who die within the 1st year of life when untreated.^{1–3} One of the limitations of enzyme-replacement therapy (ERT) with recombinant human acid alpha-glucosidase, the current standard treatment, is that it cannot pass the blood-brain barrier. It has now become clear that some patients with the classic infantile form develop white-matter abnormalities (WMA) of the brain, which may be accompanied by a change in cognitive functioning.^{4–6}

At present, it remains controversial whether brain involvement is confined to classic infantile patients. Data are limited in patients with late-onset Pompe disease, which is characterized mainly by limb-girdle and respiratory weakness.^{7,8}

Some studies suggest, on the bases of magnetic resonance (MR) imaging, that these patients may have WMA or vascular abnormalities, for example, dolichoectasias or aneurysms in the brain,^{9–12} while others argue that the WMA are age-related brain changes, similar to what is found in control groups.^{13,14}

We therefore investigated brain structure and cognitive function in a cohort of patients with late-onset Pompe disease.

2 | METHODS

2.1 | Patients

The study was conducted at the Center for Lysosomal and Metabolic Diseases, Erasmus MC University Medical Center in Rotterdam. This is the single reference center for Pompe patients in the Netherlands. We included 19 children and adults with a confirmed diagnosis of late-onset Pompe disease, and all patients were followed at

regular intervals at our outpatient clinic. The diagnosis was made by diagnostic enzyme analysis in leukocytes and/or fibroblasts and by mutation analysis. Exclusion criteria were (1) patients with devices that are contraindicated in MRI studies, (2) inability to lie in supine position without mechanical ventilation for at least 60 minutes, and (3) age > 60 years, to minimize age-related vascular pathology. The study protocol was approved by the institutional review board at the Erasmus MC, University Medical Center (MEC-2007-103; amendment 11). Written informed consent was provided by all patients and/or caregivers. We gathered additional information on the following: (1) cerebrovascular risk factors (ie, obesity, smoking, hypertension, and type II diabetes), (2) mobility aids, (3) respiratory function, and (4) educational level (Verhage scale).¹⁵

2.2 | Brain imaging

MR images were acquired on a 3 Tesla General Electric Discovery MR750w MRI System (GE, Milwaukee, Wisconsin) using an eight-channel head coil. Scanning protocol consisted of Coronal 3D T1 (TR/TE: 8.77/3.4 ms; slice thickness 1.0 mm; matrix 220 × 220), Sagittal T2 CUBE fluid-attenuated inversion recovery (FLAIR) (TR/TE: 5500/148 ms; matrix 224 × 224), Axial T2 Propeller (TR/TE: 8507/100 ms; slice thickness 2.0 mm, matrix 320 × 320), Axial 3D susceptibility-weighted images (SWI) (TR/TE: 37.8/23 ms; slice thickness 1.0 mm; matrix 256 × 200), and magnetic resonance angiography–time of flight (MRA-TOF) of internal carotid arteries and circle of Willis (TR/TE 21/2.2; matrix 224 × 224). All MR images were assessed by an experienced neuroradiologist (MD). In patients with abnormalities on brain MRI, well-established rating scales were used to quantify these abnormalities. Global atrophy and hippocampal atrophy were, respectively, rated using the global cortical atrophy (GCA) scale and medial temporal lobe atrophy (MTA) scale.^{16,17} In patients with WMA (other than 1–2 aspecific small lesions), the Fazekas scale was used to quantify WMA.¹⁸

2.3 | Neuropsychological assessment (NPA)

Neuropsychological tests were administered within 24 hours of the MRI. We used (1) the Wechsler IQ test (Wechsler Intelligence Scale for Children-third edition for age 6-16 years; Wechsler Adult Intelligence Scale-fourth edition for ages >16 years)¹⁹ and (2) the Montreal Cognitive Assessment (MoCA; only in the age group >40 years) as measures of general cognitive functioning. Furthermore, based on our own experience in testing classic infantile Pompe patients⁴ and previous literature,¹¹ we added the following tests to explore more specific domains: (3) the word fluency test to test semantic and phonological verbal fluency,²⁰ (4) the trail making test as a measure of cognitive flexibility,²¹ (5) the d2 test of attention as measure of visual selective attention,²² (6) the auditory verbal learning test to test memory, and²³ (7) the Rey Complex Figure Test (RCFT) copy trial to assess visuospatial abilities.²⁴ Outcomes were adjusted for age and educational level using normative data. The mean score within the general population for the Wechsler IQ test is 100, with an SD of 15 points. We therefore regarded a score of 85 or above as “normal intelligence,” a score between 70 and 84 (−2 to −1 SD) as “below-average intelligence,” and a score below 70 (lower than −2 SD) as intellectual disability. In a similar way, a score above 115 (above +1 SD) was noted as “above-average intelligence.”

2.4 | Statistical analysis

Descriptive information was calculated with R Statistical Software (version 3.6.1, RStudio, Inc., Boston, Massachusetts).

3 | RESULTS

Patient characteristics and MRI findings are shown in Table 1. The age of the 19 patients ranged from 11 to 56 years. Median disease duration was 18 years (range 8-29). Three patients were still asymptomatic at the time of assessment. Two (patients 5 and 8) were diagnosed because of an affected sibling (age of onset in their siblings, 9 and 5 years), while one (patient 1) was diagnosed after finding hyperCKemia during routine blood testing. We considered inclusion of these asymptomatic patients important as part of early detection of potential changes on MRI brain or NPA. All symptomatic patients were treated with ERT, with a median duration of 10 years (range 4-14). The two youngest patients were still attending regular primary school,

and educational level for the other patients varied from average level secondary school to university degree. None of the patients self-reported any cognitive problems.

3.1 | Brain imaging

Most patients (12/19) had a completely normal MRI and MRA (Table 1). Three patients, one child (patient 1), one young adult (patient 5) (both still asymptomatic), and one adult (patient 18) aged over 50 years, showed one or two aspecific focal punctate WMA, while two patients (patients 10 and 16), aged between 40 and 50 years, had punctate WMA with an FS of 1 to 2 (Figure 1A). One patient (patient 11) showed mild-to-moderate supratentorial and infratentorial atrophy, reflected by a GCA score of 1 to 2 and MTA score of 1. The ventricular size was normal in all patients (mean Evans index 0.24 [range 0.21-0.29; normal: <0.30]). In addition, as an incidental finding, we found a solitary cerebral cavernous hemangioma and a posterior fossa meningioma in two other patients (patients 13 and 18, respectively), both requiring no further treatment. SWI sequence revealed no calcifications or microbleeds. MRA-TOF sequence revealed a slight vertebrobasilar dolichoectasia (diameter 4 mm) in two patients (patients 11 and 18) (Figure 1B) but no aneurysms, dissections, or other vascular abnormalities.

3.2 | Neuropsychological assessment

The majority of patients had age-adjusted scores within the normal range for the Wechsler index scores (verbal comprehension, perceptual reasoning, working memory, and processing speed) and combined total intelligence score, as well as for the specific domains verbal fluency, attention, and memory (Table 2). Looking at the Wechsler total IQ score, one patient (patient 1) had a below-average intelligence, while another patient (patient 15) scored above average on total IQ. With regard to the Wechsler index scores, five patients had a below-average score on one or two of the index scores, while seven patients scored above average on one to three of the index scores. We considered this to be normal variation within the population under study. Nine patients performed below the fifth percentile of age and education-matched controls on the RCFT copy trial (visuospatial domain), using a more fragmented approach in reproducing the figure (Figure 1C-D). MoCA revealed normal total scores (≥ 26) in all 10 patients in whom this test was performed, although eight incorrectly performed one (6/10) or two (2/10) of the visuospatial subtests (cube copying or clock drawing).

TABLE 1 Clinical features and radiological findings in 19 patients with late-onset Pompe disease

Patient ID	Age at symptom onset (yrs)	Age at start ERT (yrs)	Age MRI and NPA (yrs)	GAA genotype	CVRF (Ob, S, Ht DMII)	FVC upright (%) / FVC supine (%)	6MWT (m)	Mobility aids	MRI findings	MRA findings
1	AS	—	11	c.-32-13T>G c.525del	Ob	103/96	412	—	1 small aspecific WMH	—
2	1	1	11	c.-32-13T>G c.2135T>C	—	109/100	512	—	—	—
3 ^a	9	10	17	c.-32-13T>G c.525del	—	82/73	544	—	—	NA
4	5	8	17	c.-32-13T>G c.2331+2T>A	—	96/90	592	—	—	—
5 ^a	AS	—	20	c.-32-13T>G c.525del	—	91/90	562	—	2 small aspecific WMH	—
6	3	6	20	c.1643C>T c.2481 +102_2646 +31del	—	81/69	434	—	—	—
7 ^b	5	11	21	c.-32-13T>G c.525del	—	104/98	697	—	—	—
8 ^b	AS	—	23	c.-32-13T>G c.525del	—	103/93	720	—	—	—
9	13	14	26	c.-32-13T>G c.1933G>A	—	72/52	540	—	—	—
10	28	34 ^c	43	c.-32-13T>G c.379_380delTG	—	83/68	333	Wheelchair (partial)	Subcortical WMH (FS) 1) Mild atrophy	—
11	23	30	44	c.-32-13T>G c.172C>T	—	73/50	454	Cane	Atrophy (GCA1-2, MTA 1, cerebellar)	Vertebrobasilar dolichoectasia (4 mm)
12	23	31	44	c.-32-13T>G c.525del	Ob	81/64	520	—	—	—
13	17	41	45	c.-32-13T>G c.2608C>T	—	96/67	458	—	Cavernous hemangioma	—
14	24	35	47	c.-32-13T>G c.2481 +102_2646 +31del	Ob	89/68	431	—	—	—

TABLE 1 (Continued)

Patient ID	Age at symptom onset (yrs)	Age at start ERT (yrs)	Age MRI and NPA (yrs)	GAA genotype	CVRF (Ob, S, Ht DMII)	FVC upright (%) / FVC supine (%)	6MWT (m)	Mobility aids	MRI findings	MRA findings
15	30	40	50	c.-32-13T>G 1548G>A	—	84/62	541	—	—	—
16	21	46	50	c.-32-13T>G c.525del	—	86/68	500	—	Periventricular/ subcortical WMH (FS 1–2)	—
17	32	39	50	c.-32-13T>G c.525del	S	98/86	518	—	—	—
18	27	45	51	c.-32-13T>G c.525del	—	69/56	405	Wheelchair (partial)	1 small aspecific WMH, Cerebellar meningioma	Vertebrobasilar dolichoectasia (4 mm)
19	37	44	56	c.-32-13T>G c.525del	—	84/58	285	Wheelchair (partial)	—	—

Abbreviations: 6MWT (m), 6-minute walking test (meters); AS, Asymptomatic; CVRF, cerebrovascular risk factors; DMII, diabetes mellitus type II; ERT, enzyme replacement therapy; FS, Fazekas score; FVC, forced vital capacity; GAA, acid α -glucosidase; GCA, global cortical atrophy; Ht, hypertension; MTA, medial temporal lobe atrophy; NA, not available; NPA, neuropsychological assessment; Ob, obesity; S, smoking; WMH, white-matter hyperintensities on T2 sequence; yrs, years.

^aSiblings, one still asymptomatic, both diagnosed after sibling.

^bSiblings, one still asymptomatic, both diagnosed after sibling.

^cERT was discontinued at age 39.5 years, at request of patient.

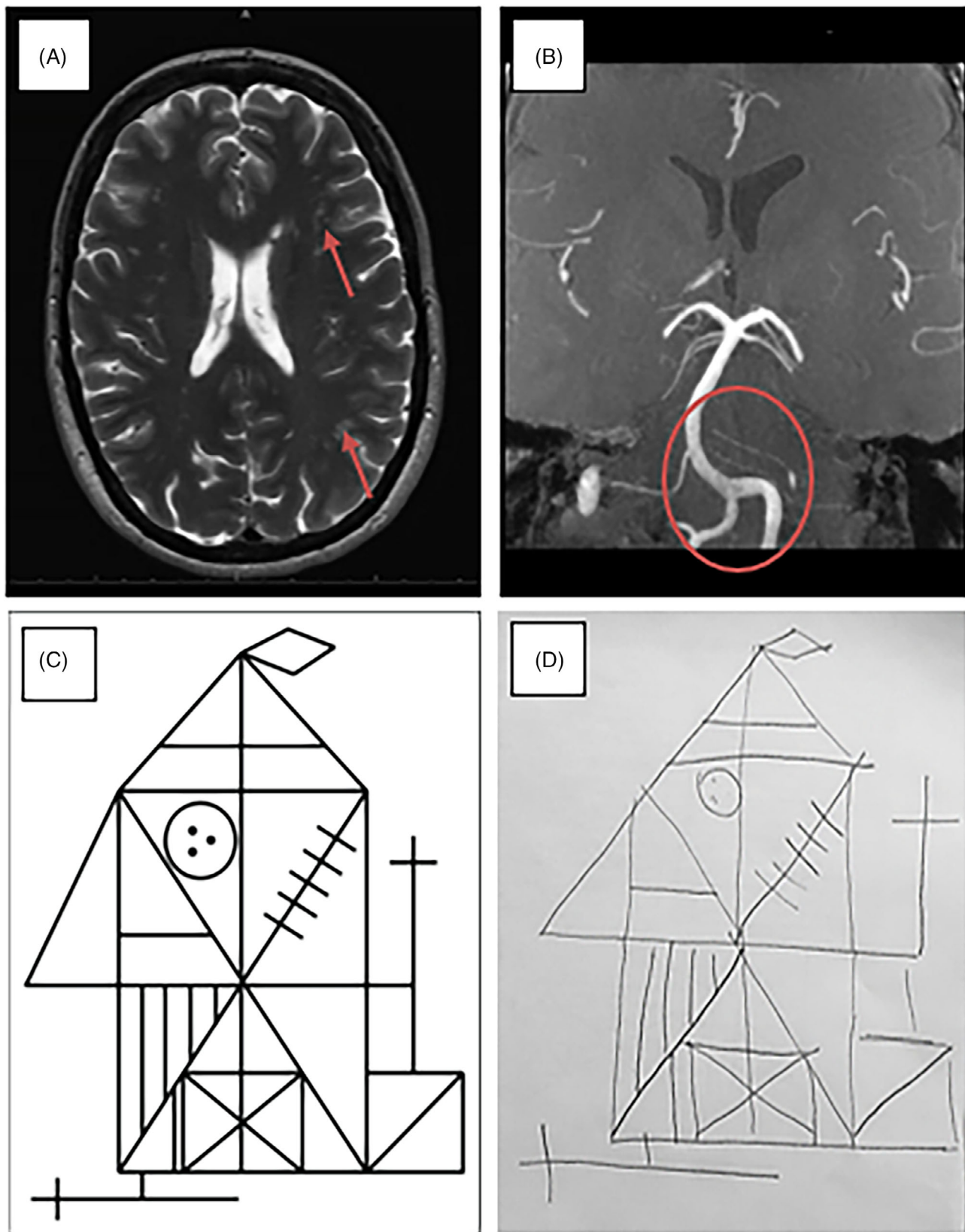


FIGURE 1 Brain MRI and Rey complex figure test (RCFT) in late-onset Pompe patients. A, T2 image, periventricular, and subcortical WM hyperintensities, Fazekas score 1 to 2 (patient 16). B, MRA-TOF, vertebrobasilar dolichoectasia, diameter 4 mm (patient 18). C, RCFT template. D, Example of RCFT in which patient used a fragmented approach in figure copying. MRA-TOF, Magnetic resonance angiography–time of flight; WM, white-matter

4 | DISCUSSION

We did not find signs of general cognitive impairment or WMA, other than mild focal microvascular lesions, considered within normal range for age, in this subset of late-onset Pompe patients. This is in sharp contrast with the widespread WMA and cognitive problems found in some classic infantile patients.

4.1 | Brain imaging—WMA

We found mild punctate WMA (FS 1-2) in two patients (11%) only, which was considered to be within normal range for the age.^{25,26} This low proportion is in line with

the findings of recent MRI studies in Belgian (1/27)¹⁴ and Italian (5/14)¹² patients with late-onset Pompe disease but contrasts with those in another study in Italian patients (n = 21)¹¹ in which a prevalence of WMA of almost 60% was found. A recent German study comparing 19 Pompe patients with 38 controls matched for age and cerebrovascular risk factors failed to show any differences between the groups.¹³ There may be two main reasons for this. First, we deliberately included relatively young patients without significant cerebrovascular risk factors, while older age¹¹ and high-cerebrovascular-risk profile¹³ are known to be associated with the occurrence of WMA. Second, none of our patients had severe respiratory dysfunction, which is also associated with increased prevalence of WMA.^{10,27}

TABLE 2 Results of neuropsychological assessment in patients with late-onset Pompe disease

Test instrument	Score ^a Mean ± SD	Low score ^b N (%)
Intelligence scale (Wechsler)		
Verbal comprehension	98 ± 10	0/17 (0)
Perceptual reasoning	103 ± 13	0/17 (0)
Working memory	100 ± 13	0/17 (0)
Processing speed	105 ± 13	0/17 (0)
Total IQ	101 ± 12	0/19 (0)
Verbal fluency		
WFT—phonological	54 ± 13	0/16 (0)
WFT—semantic	52 ± 14	0/17 (0)
Cognitive flexibility		
TMT—A	57 ± 10	0/17 (0)
TMT—B	51 ± 9	0/17 (0)
TMT—B-A	47 ± 9	1/17 (6)
Visual selective attention		
D2—processing speed	53 ± 10	0/16 (0)
D2—concentration	55 ± 9	0/16 (0)
Memory		
AVLT—trial	51 ± 8	0/17 (0)
AVLT—immediate recall	52 ± 10	0/17 (0)
AVLT—delayed recall	51 ± 10	0/17 (0)
Visuospatial ability		
RCFT	30 ± 3	9/14 (64)

Abbreviations: AVLT, auditory verbal learning test; D2, D2 Test of Attention; IQ, Intelligence quotient; NA, not applicable; RCFT, Rey Complex Figure Test; TMT, trail making test; WFT, word fluency test.

^aAge-adjusted norm scores.

^bWechsler: Population mean 100, SD 15, low score <70; WFT/TMT/DS/AVLT: population mean 50, SD 10, low score <30; RCFT score <28.9 is <5th percentile, score >32.4 is >50th percentile.

4.2 | Brain imaging—vascular

We did not find any cerebrovascular abnormalities other than a vertebrobasilar dolichoectasia in 2 of 18 (11%) of patients.

Various cerebrovascular abnormalities have been reported in late-onset Pompe patients,²⁸ of which (dolicho)ectasia of vertebral and/or basilar arteries is most common, with a prevalence of 52% to 72% in several relatively larger studies.^{10-12,29} Other findings include the presence of intracranial aneurysms (up to 14% of patients)^{10,11} and increased arterial wall stiffness.^{30,31} These abnormalities are hypothesized to be due to glyco-gen accumulation in the arterial wall or vasodilatation as a consequence of increased pCO₂ pressure due to respiratory failure associated with Pompe disease. The lower prevalence of vascular abnormalities we find compared to other studies is likely due to the fact that patients were younger and without respiratory failure.

4.3 | Cognition

The majority of our patients performed within the normal range on measures of general intelligence or processing speed—domains that are commonly affected in classic infantile patients. We only found slight subnormal visuospatial functioning in a subset of patients. In total, 9/16 patients scored <5th percentile on the Rey complex figure task. With regard to the patients in whom we found an FS of 1 or 2, patient 10 was one of the patients who scored <5th percentile but patient 16 scored >50th percentile. Therefore, this does not seem directly related. All patients regularly visited our outpatient clinic, and none of them showed complaints regarding impaired visuospatial function or general cognitive impairment in everyday life.

The subnormal visuospatial functioning in a subset of patients was an unexpected finding. A previous study¹¹ showed similar results on the MoCA visuospatial subtest, but a proper explanation is currently lacking. Confounding due to motor weakness is unlikely since none of the included patients exhibited muscle weakness of the hands.

Further research in larger cohorts looking into other methods such as diffusion tensor imaging (DTI), functional MRI or spectroscopy, or perhaps the use of additional neuropsychological tests is required for better understanding of the current findings.

5 | CONCLUSION

Contrary to the findings in a subset of classic infantile patients, we did not find substantial brain lesions or signs of general cognitive impairment in this group of patients with late-onset Pompe disease.

CONFLICT OF INTEREST

Jan J. A. van den Dorpel, Willemijn M. C. van der Vlugt, Marjolein H. G. Dremmen, Ryan Muetzel, Esther van den Berg, Roost Hest, Joni de Kriek, Esther Brusse, and Pieter A. van Doorn report no disclosures relevant to this manuscript. Ans T. van der Ploeg, Johanna M. P. van den Hout and Nadine A. M. E. van der Beek received funding for research, clinical trials, and as advisor from Sanofi Genzyme and Amicus Therapeutics under agreements with Erasmus MC University Medical Center.

AUTHOR CONTRIBUTIONS

Jan J. A. van den Dorpel: Study design; data acquisition, analysis, and interpretation; writing – original draft; read and approved the final version of the manuscript; fulfilled the criteria for authorship; agreed with its contents. **Willemijn M. C. van der Vlugt:** Data analysis and interpretation; manuscript revision; read and approved the final version of the manuscript; fulfilled the criteria for authorship; agreed with its contents. **Marjolein H. G. Dremmen:** Data analysis and interpretation; manuscript revision; read and approved the final version of the manuscript; fulfilled the criteria for authorship; agreed with its contents. **Ryan Muetzel:** Data analysis and interpretation; manuscript revision; read and approved the final version of the manuscript; fulfilled the criteria for authorship; agreed with its contents. **Esther van den Berg:** Data analysis and interpretation; manuscript revision; read and approved the final version of the manuscript; fulfilled the criteria for authorship; agreed with its contents. **Roost Hest:** Data acquisition, analysis,

and interpretation; manuscript revision; read and approved the final version of the manuscript; fulfilled the criteria for authorship; agreed with its contents. **Joni de Kriek:** Data acquisition, analysis, and interpretation; manuscript revision; read and approved the final version of the manuscript; fulfilled the criteria for authorship; agreed with its contents. **Esther Brusse:** Data analysis and interpretation; manuscript revision; read and approved the final version of the manuscript; fulfilled the criteria for authorship; agreed with its contents. **Pieter A. van Doorn:** Study conception and design; data interpretation; manuscript revision; read and approved the final version of the manuscript; fulfilled the criteria for authorship; agreed with its contents. **Ans T. van der Ploeg:** Study conception and design; data interpretation; manuscript revision; read and approved the final version of the manuscript; fulfilled the criteria for authorship; agreed with its contents. **Johanna M. P. van den Hout:** Study conception and design; data interpretation; manuscript revision; read and approved the final version of the manuscript; fulfilled the criteria for authorship; agreed with its contents. **Nadine A. M. E. van der Beek:** Study conception and design; data interpretation; manuscript revision; writing – original draft; read and approved the final version of the manuscript; fulfilled the criteria for authorship; agreed with its contents.

DATA AVAILABILITY STATEMENT

Anonymized data will be shared by request from any qualified investigator for the sole purpose of replicating procedures and results presented in the article and as long as data transfer is in agreement with EU legislation on the general data protection regulation.

ETHICS STATEMENT

All procedures followed were in accordance with the ethical standards of the responsible committee on human experimentation (institutional and national) and with the Helsinki Declaration of 1975, as revised in 2000. This study was approved by the Institutional Review Board at the Erasmus MC University Medical Center, and further details are provided in the methods section of our manuscript.

INFORMED CONSENT STATEMENT

Informed consent was obtained from all patients and/or their caregivers for being included in the study; all forms are on file and available in case of request.

ORCID

Jan J. A. van den Dorpel  <https://orcid.org/0000-0003-0948-7313>

REFERENCES

- Kishnani PS, Hwu WL, Mandel H, et al. A retrospective, multi-national, multicenter study on the natural history of infantile-onset Pompe disease. *J Pediatr*. 2006;148:671-676.
- Reuser AJ, Hirschhorn R, Kroos MA. Pompe disease: glycogen storage disease type II, acid alpha-glucosidase (acid maltase) deficiency. In: Valle D, Beaudet AL, Vogelstein B, eds. *The Online Metabolic & Molecular Bases of Inherited Disease (OMMBID)*. New York: McGraw Hill; 2018. <https://ommbid.mhmedical.com>
- van den Hout HM, Hop W, van Diggelen OP, et al. The natural course of infantile Pompe's disease: 20 original cases compared with 133 cases from the literature. *Pediatrics*. 2003;112:332-340.
- Ebbink BJ, Poelman E, Aarsen FK, et al. Classic infantile Pompe patients approaching adulthood: a cohort study on consequences for the brain. *Dev Med Child Neurol*. 2018;60:579-586.
- Korlimarla A, Spiridigliozzi GA, Crisp K, et al. Novel approaches to quantify CNS involvement in children with Pompe disease. *Neurology*. 2020;95:e718-e732.
- McIntosh PT, Hobson-Webb LD, Kazi ZB, et al. Neuroimaging findings in infantile Pompe patients treated with enzyme replacement therapy. *Mol Genet Metab*. 2018;123:85-91.
- Hagemans ML, Hop WJ, Van Doorn PA, Reuser AJ, Van der Ploeg AT. Course of disability and respiratory function in untreated late-onset Pompe disease. *Neurology*. 2006;66:581-583.
- van der Beek NA, de Vries JM, Hagemans ML, et al. Clinical features and predictors for disease natural progression in adults with Pompe disease: a nationwide prospective observational study. *Orphanet J Rare Dis*. 2012;7:88.
- Korlimarla A, Lim JA, Kishnani PS, Sun B. An emerging phenotype of central nervous system involvement in Pompe disease: from bench to bedside and beyond. *Ann Transl Med*. 2019;7:289.
- Montagnese F, Granata F, Musumeci O, et al. Intracranial arterial abnormalities in patients with late onset Pompe disease (LOPD). *J Inherit Metab Dis*. 2016;39:391-398.
- Musumeci O, Marino S, Granata F, et al. Central nervous system involvement in late-onset Pompe disease: clues from neuroimaging and neuropsychological analysis. *Eur J Neurol*. 2019;26:442-e435.
- Pichiecchio A, Sacco S, De Filippi P, et al. Late-onset Pompe disease: a genetic-radiological correlation on cerebral vascular anomalies. *J Neurol*. 2017;264:2110-2118.
- Schneider I, Hensel O, Zierz S. White matter lesions in treated late onset Pompe disease are not different to matched controls. *Mol Genet Metab*. 2019;127:128-131.
- Vanherpe P, Fieuws S, D'Hondt A, et al. Late-onset Pompe disease (LOPD) in Belgium: clinical characteristics and outcome measures. *Orphanet J Rare Dis*. 2020;15:83.
- Verhage F. *Intelligentie en leeftijd bij volwassenen en bejaarden* [Dissertation]. Assen, the Netherlands: Van Gorcum; 1964.
- Pasquier F, Leys D, Weerts JG, Mounier-Vehier F, Barkhof F, Scheltens P. Inter- and intraobserver reproducibility of cerebral atrophy assessment on MRI scans with hemispheric infarcts. *Eur Neurol*. 1996;36:268-272.
- Scheltens P, Leys D, Barkhof F, et al. Atrophy of medial temporal lobes on MRI in "probable" Alzheimer's disease and normal ageing: diagnostic value and neuropsychological correlates. *J Neurol Neurosurg Psychiatry*. 1992;55:967-972.
- Fazekas F, Chawluk JB, Alavi A, Hurtig HI, Zimmerman RA. MR signal abnormalities at 1.5 T in Alzheimer's dementia and normal aging. *AJR Am J Roentgenol*. 1987;149:351-356.
- Wechsler D. *Wechsler Intelligence Scale for Adults*. London: The Psychological Corporation; 1997.
- Schmand B, Groenink SC, van den Dungen M. Letterfluency: psychometrische eigenschappen en Nederlandse normen. [Letter fluency: psychometric properties and Dutch normative data]. *Tijdschr Gerontol Geriatr*. 2008;39:64-76.
- Corrigan JD, Hinkley NS. Relationships between parts A and B of the trail making test. *J Clin Psychol*. 1987;43:402-409.
- Brickenkamp R, Oosterveld P. *D2: aandachts-en concentratietest*. Amsterdam, the Netherlands: Hogrefe; 2014.
- Van der Elst W, van Boxtel MP, van Breukelen GJ, Jolles J. Rey's verbal learning test: normative data for 1855 healthy participants aged 24-81 years and the influence of age, sex, education, and mode of presentation. *J Int Neuropsychol Soc*. 2005;11:290-302.
- Caffarra P, Vezzadini G, Dieci F, Zonato F, Venneri A. Rey-Osterrieth complex figure: normative values in an Italian population sample. *Neurol Sci*. 2002;22:443-447.
- Lechner H, Schmidt R, Fazekas F, et al. White matter lesions on magnetic resonance imaging in a healthy elderly population: correlations to vascular risk factors and carotid atherosclerosis. *J Stroke Cerebrovasc Dis*. 1994;4:224-228.
- Vernooij MW, Ikram MA, Tanghe HL, et al. Incidental findings on brain MRI in the general population. *N Engl J Med*. 2007;357:1821-1828.
- van Dijk EJ, Vermeer SE, de Groot JC, et al. Arterial oxygen saturation, COPD, and cerebral small vessel disease. *J Neurol Neurosurg Psychiatry*. 2004;75:733-736.
- van Kooten HA, Roelen CHA, Brusse E, et al. Cardiovascular disease in non-classic Pompe disease: a systematic review. *Neuromuscul Disord*. 2021;31:79-90.
- Laforet P, Petiot P, Nicolino M, et al. Dilative arteriopathy and basilar artery dolichoectasia complicating late-onset Pompe disease. *Neurology*. 2008;70:2063-2066.
- Nemes A, Soliman O II, Geleijnse ML, et al. Increased aortic stiffness in glycogenosis type 2 (Pompe's disease). *Int J Cardiol*. 2007;120:138-141.
- Wens SCA, Kuperus E, Mattace-Raso FUS, et al. Increased aortic stiffness and blood pressure in non-classic Pompe disease. *J Inherit Metab Dis*. 2014;37:391-397.

SUPPORTING INFORMATION

Additional supporting information may be found in the online version of the article at the publisher's website.

How to cite this article: van den Dorpel JJA, van der Vlugt WMC, Dremmen MHG, et al. Is the brain involved in patients with late-onset Pompe disease? *J Inherit Metab Dis*. 2022;45(3):493-501. doi:10.1002/jimd.12469