

**Structural Heart?**  
It is a cutting-edge journal of structural heart disease, covering all aspects of the field. It is a must-read for all structural heart specialists.

**Heart team?**  
A multidisciplinary team of interventional cardiologists, cardiac surgeons, and imaging specialists working together to provide the best care for their patients.

**Heart failure?**  
The most common cause of death in developed countries, heart failure is a complex condition that requires a multidisciplinary approach to management.

**Structural Heart**  
Volume 2, Number 1  
February 2021  
ISSN: 2688-1022  
DOI: 10.1080/26881022.2021.1938318

# Limitations of Transcatheter Heart Valve Replacement Depth Assessment by Invasive Angiography—a Multi-Detector Computed Tomography Analysis

Tijmen W. Hokken, Ikram El Azzouzi, Quinten M. Wolff, Maarten P. Van Wiechen, Joris F. Ooms, Ricardo Budde & Nicolas M. Van Mieghem

To cite this article: Tijmen W. Hokken, Ikram El Azzouzi, Quinten M. Wolff, Maarten P. Van Wiechen, Joris F. Ooms, Ricardo Budde & Nicolas M. Van Mieghem (2021): Limitations of Transcatheter Heart Valve Replacement Depth Assessment by Invasive Angiography—a Multi-Detector Computed Tomography Analysis, Structural Heart, DOI: [10.1080/24748706.2021.1938318](https://doi.org/10.1080/24748706.2021.1938318)

To link to this article: <https://doi.org/10.1080/24748706.2021.1938318>



© 2021 The Author(s). Published with license by Taylor & Francis Group, LLC.



Published online: 26 Aug 2021.



Submit your article to this journal [↗](#)




Article views: 216



View related articles [↗](#)



View Crossmark data [↗](#)



## Limitations of Transcatheter Heart Valve Replacement Depth Assessment by Invasive Angiography—a Multi-Detector Computed Tomography Analysis

Hijmen W. Hokken, MD<sup>a</sup>, Ikram El Azzouzi, MSc<sup>a</sup>, Quinten M. Wolff, BSc <sup>a</sup>, Maarten P. Van Wiechen, MD <sup>a</sup>, Joris F. Ooms, MD <sup>a</sup>, Ricardo Budde, MD, PhD<sup>b</sup>, and Nicolas M. Van Mieghem, MD, PhD<sup>a</sup>

<sup>a</sup>Department of Cardiology, Erasmus University Medical Center, Rotterdam, The Netherlands; <sup>b</sup>Department of Radiology, Erasmus University Medical Center, Rotterdam, The Netherlands

### Introduction

Transcatheter aortic valve replacement (TAVR) is an established treatment for severe aortic stenosis (AS); however, the transcatheter heart valve (THV) implantation depth (ID) is associated with conduction disturbances and paravalvular leakage (PVL).<sup>1,2</sup> The THV ID is typically determined by invasive angiography in a plane perpendicular to the native valve in which the 3 cusps are aligned and the (virtual) aortic annulus can be identified as a reference. However, there is no universal consensus on ID measurement, and angiography-based techniques have been proposed to optimize final THV ID.<sup>1</sup> The aim of this study was to correlate ID measurements by invasive angiography with multidetector computed tomography (MDCT).

### Methods

All patients with a computed tomography (CT) scan post TAVR were included in this retrospective study. A dedicated database captured relevant baseline characteristics and procedure data. The study was conducted in accordance with the declaration of Helsinki and did not fall under the scope of the Medical Research Involving Human Subjects Act per Institutional Review Board's review. Due to the retrospective nature of the study, informed consent was not required.

### Measurement of the ID

ID was measured by invasive angiography after final THV release in the catheterization laboratory. The optimal plane for angiography was determined prior to the THV implantation and required alignment of the noncoronary (bottom), right (middle), and left (upper) cusps. CAAS software (Pie Medical, Maastricht, the Netherlands) was used to measure by angiography the ID from the THV inflow portion in the left ventricular outflow to the noncoronary cusp (NCC) and left coronary cusp (LCC), respectively. Similarly the ID was measured by MDCT using the double oblique view in 3Mensio (Pie Medical, Maastricht, the Netherlands). An integrated approach using the baseline

MDCT prior to TAVR was used to help identify the virtual annulus when this was obscured by the THV on the follow-up CT. A measurement variability of 0.5 mm difference in ID length between the 2 methods was established as an acceptable accuracy in terms of clinical relevance.

### Statistical analysis

Distributions of continuous variables were tested for normality with the Shapiro–Wilk test. Continuous variables were reported as mean  $\pm$  standard deviation if normally distributed or as median (25th–75th percentile) if nonnormally distributed. Categorical variables were reported as number and percentage. A Bland–Altman plot was used to assess agreement between the 2 modalities, and the intraclass correlation coefficient (ICC) was calculated for the 2 modalities. All statistics were performed with SPSS software version 25.0 (SPSS, Chicago, IL).

### Results

In total, 105 patients underwent a CT scan before and after TAVR. Mean age was 76.7 ( $\pm 7.2$ ) years and 50.5% were male. Of these patients, 28.6% had a bicuspid aortic valve (BAV). Indications for CT scan post TAVR were study related (32.4%), regular follow-up (53.3%), and suspected endocarditis (8.6%).

Overall, 13.3% of the ID measurements by invasive angiography and MDCT were within the accepted variability of 0.5 mm. The invasive angiography and MDCT Bland–Altman plot and correlation are represented in **Figure 1**. The Bland–Altman plot showed a mean difference ( $\pm$ SD) of 0.62 mm ( $\pm 3.47$ ) and the ICC ranged between 0.46 [95% confidence interval (CI) 0.30–0.60] and 0.63 [95%CI 0.48–0.74]. The correlation coefficient for tricuspid aortic valves varied from 0.40 [95%CI 0.20–0.58] to 0.63 [95%CI 0.46–0.75] and for BAV from 0.58 [95%CI 0.29–0.78] to 0.61 [95%CI 0.30–0.80].

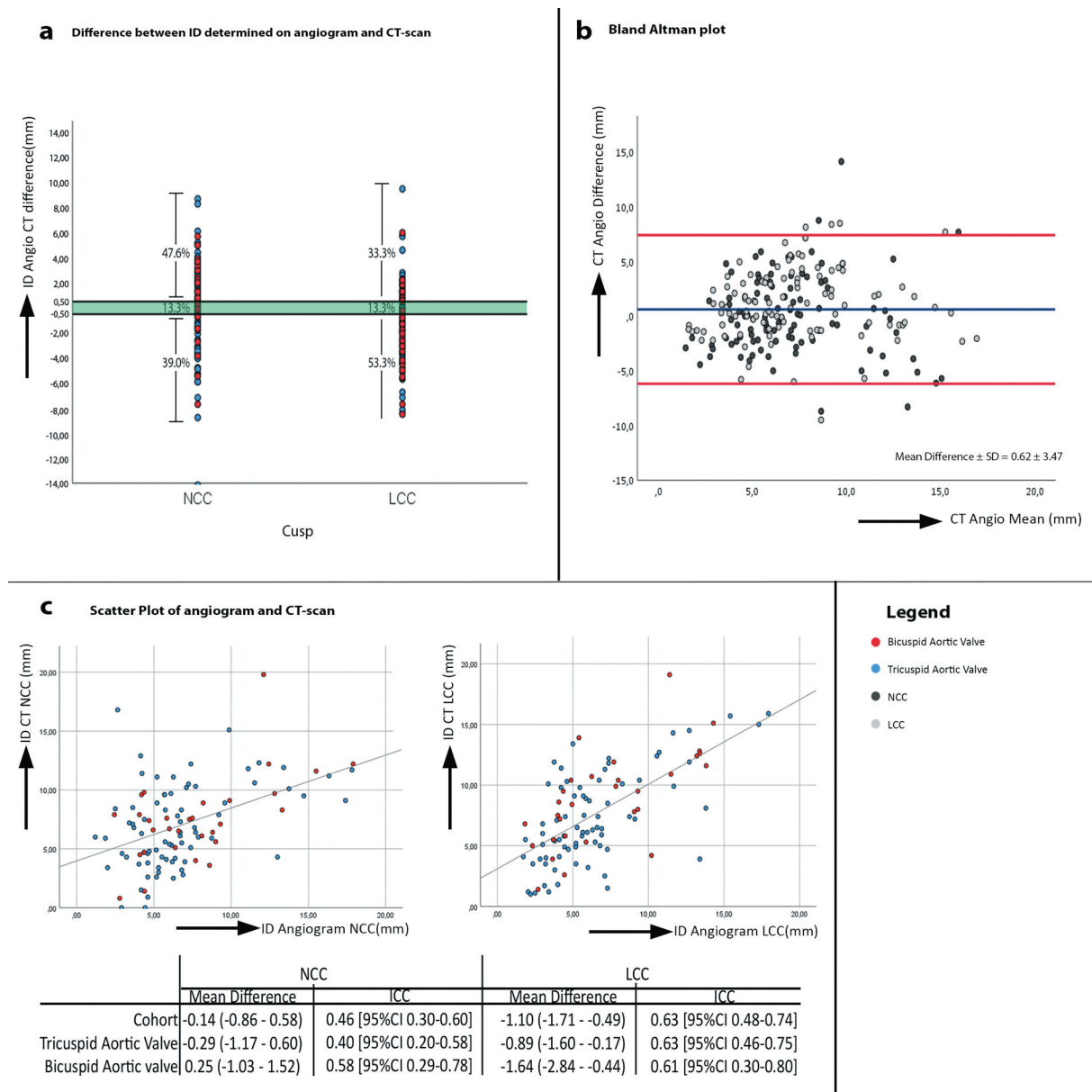
All measurements of the ID with MDCT were determined by one experienced imager. The intraobserver variability was 0.96 ([95%CI 0.92–0.99],  $p < 0.001$ ). Two imagers determined

**CONTACT** Nicolas M. Van Mieghem n.vanmieghem@erasmusmc.nl Department of Interventional Cardiology, Thoraxcenter, ErasmusMC, Office Nt 645, Dr Molewaterplein 40 3015 GD Rotterdam, The Netherlands.

**Abbreviations:** AS, aortic stenosis; BAV, bicuspid aortic valve; ICC, intraclass correlation coefficient; ID, implantation depth; LCC, left coronary cusp; MDCT, multidetector computed tomography; NCC, noncoronary cusp; TAVR, transcatheter aortic valve replacement; THV, transcatheter heart valve; PVL, paravalvular leakage.

© 2021 The Author(s). Published with license by Taylor & Francis Group, LLC.

This is an Open Access article distributed under the terms of the Creative Commons Attribution-NonCommercial-NoDerivatives License (<http://creativecommons.org/licenses/by-nc-nd/4.0/>), which permits non-commercial re-use, distribution, and reproduction in any medium, provided the original work is properly cited, and is not altered, transformed, or built upon in any way.



**Figure 1.** Central illustration.

**A:** Numerous differences between ID length measured on angiogram and CT scan. **B:** Bland–Altman plot with mean difference. **C:** scatter plot of the ID length with the mean differences and interclass correlation coefficients. ID = implantation depth, NCC = noncoronary cusp, LCC = left coronary cusp, CT = computed tomography, SD = standard deviation, ICC = interclass correlation coefficients.

the invasive angiography ID measurements. The interobserver variability between the two imagers was 0.74 ([95%CI 0.20–0.91],  $p = 0.005$ ).

## Discussion

Our results highlight the poor correlation between ID measurements by invasive angiography and MDCT.

Optimal THV ID is important to mitigate inadequate sealing around the annulus that may result in paravalvular leak (PVL) or profound interaction with the interventricular membranous septum and atrioventricular conduction system that may result in high-degree block and need for permanent pacemakers.<sup>2,3</sup> Our study demonstrates fundamental limitations of ID assessment by invasive angiography, compared to MDCT as reference, in

tricuspid and bicuspid aortic valve stenosis and underscores the unmet clinical need for accurate per procedural ID interpretation. MDCT was considered to be the reference for ID measurement because of the ability to produce multiplanar reconstructions and create three-dimensional anatomical representations that allow determination of implantation depth without foreshortening. The commonly used “optimal projection” method with commissural alignment may be an oversimplification because it is static and ignores device–host interactions that may modify the anatomical reality during TAVR. Furthermore, invasive angiography is restricted to “lumenography” and lacks additional anatomical information that is available with MDCT. Rotational angiography could overcome intrinsic limitations of conventional angiography, such as foreshortening, and resulted in more accurate ID measurements but requires additional (diluted) contrast and radiation and

was not available in this study.<sup>4</sup> Novel invasive angiography concepts with the likes of cusp overlay and double-S-curve techniques and dynamic image fusion (overlay of echocardiography or MDCT imaging on real-time fluoroscopy imaging) claim superior ID appreciation due to mitigating possible displacement by avoiding foreshortening of the annular anatomy and delivery catheter. However, these theoretical concepts still require confirmation in prospective studies with MDCT as reference.

### Study limitations

Our study is a single-center retrospective analysis. The post-TAVR MDCT scans are not part of routine clinical practice and were only performed in a selected set of patients. We also included both tricuspid and bicuspid aortic valve anatomies. We believe optimal projection algorithms are similar because most patients with bicuspid AS who are TAVR candidates now have a tricommissural phenotype.<sup>5</sup>

### Conclusion

Current invasive angiography-derived THV ID assessment is inaccurate and new concepts should focus on superior ID appreciation, moving forward with TAVR to find the optimal ID for patient-specific anatomy.

### ORCID

Quinten M. Wolff  <http://orcid.org/0000-0002-8664-7758>

Maarten P. Van Wiechen  <http://orcid.org/0000-0001-6026-8605>

Joris F. Ooms  <http://orcid.org/0000-0001-7881-7609>

### Funding

There was no specific funding for this correspondence.

### Disclosure statement

N. van Mieghem received research grants and advisory fees from Abbott, Boston Scientific Corporation, Edwards Lifesciences, Medtronic, Teleflex, and Daiichi Sankyo; received advisory fees from Ancora Heart.

The other authors had no conflicts to declare.

### References

1. Piayda K, Hellhammer K, Veulemans V, et al. Navigating the “optimal implantation depth” with a self-expandable TAVR device in daily clinical practice. *JACC Cardiovasc Interv.* 2020;13(6):679–688. doi:10.1016/j.jcin.2019.07.048. PMID: 31838114.
2. Athappan G, Patvardhan E, Tuzcu EM, et al. Incidence, predictors, and outcomes of aortic regurgitation after transcatheter aortic valve replacement: meta-analysis and systematic review of literature. *J Am Coll Cardiol.* 2013;61(15):1585–1595. doi:10.1016/j.jacc.2013.01.047. PMID: 23500308.
3. Jilaihawi H, Zhao Z, Du R, et al. Minimizing permanent pacemaker following repositionable self-expanding transcatheter aortic valve replacement. *JACC Cardiovasc Interv.* 2019;12(18):1796–1807. doi:10.1016/j.jcin.2019.05.056. PMID: 31473236.
4. Rodriguez-Olivares R, El Faquir N, Rahhab Z, et al. Determinants of image quality of rotational angiography for on-line assessment of frame geometry after transcatheter aortic valve implantation. *Int J Cardiovasc Imaging.* 2016;32(7):1021–1029. doi:10.1002/ccd.23217. PMID: 21735526.
5. Jilaihawi H, Chen M, Webb J, et al. A bicuspid aortic valve imaging classification for the TAVR era. *JACC Cardiovasc Imaging.* 2016;9(10):1145–1158. doi:10.1016/j.jcmg.2015.12.022. PMID: 27372022.