

Craniosynostosis: the brain & sleep

Robbin de Goederen

Colofon

Craniosynostosis: the brain & sleep

ISBN 978-94-6416-018-5

Copyright © 2020 Robbin de Goederen

All rights reserved. No part of this thesis may be reproduced, stored, or transmitted in any way or by any means without prior permission of the author, or when applicable, of the publishers of the scientific papers.

Layout & printing Ridderprint BV – www.ridderprint.nl

Cover design Mark de Goederen – www.viewgood.nl

This thesis was financially supported by:

NVPC, ReBuS-IT, Boele beheer, OSG, and Stichting Hoofdzaak

Craniosynostosis: the brain & sleep

Craniosynostose: het brein & slaap

Proefschrift

ter verkrijging van de graad van doctor aan de
Erasmus Universiteit Rotterdam
op gezag van de rector magnificus

Prof.dr. R.C.M.E. Engels

en volgens besluit van het College voor Promoties.
De openbare verdediging zal plaatsvinden op

vrijdag 4 september 2020 om 11:30 uur

door

Robbin de Goederen

geboren te Rotterdam

Promotiecommissie

Promotoren:

Prof.dr. I.M.J. Mathijssen

Prof.dr. K.F.M. Joosten

Overige leden:

Prof.dr. A. Boudewyns

Prof.dr. M.K. Ikram

Prof.dr. E.B. Wolvius

Table of contents

Part 1	Introduction	7
Chapter 1	Introduction	9
Part 2	Obstructive Sleep Apnea: Treatment and Diagnostics	37
Chapter 2	Evaluation of the OSA-treatment protocol in syndromic craniosynostosis during the first six years of life	39
Chapter 3	Improvement in sleep architecture is associated with the indication of surgery in syndromic craniosynostosis	57
Chapter 4	Electrocardiographic variables in children with syndromic craniosynostosis and primary snoring to mild obstructive sleep apnea: significance of identifying respiratory arrhythmia during sleep	79
Part 3	Cerebral Venous Flow and Intracranial Hypertension	
Chapter 5.1	Pilot case-control study of intracranial venous physiology in craniosynostosis	99
Chapter 5.2	Letter to the editor. Altered intracranial venous physiology	115
Chapter 5.3	Response to letter to the editor	119
Chapter 6	Dural sinus volume in children with syndromic craniosynostosis and intracranial hypertension	123
Part 4	Summary and Discussion	143
Chapter 7	Discussion	145
Chapter 8	Summary	159
Chapter 9	Nederlandse samenvatting	165
Appendices	List of publications	172
	PhD portfolio	174
	Curriculum vitae	179
	Dankwoord	180

PART 1

Introduction



CHAPTER 1

Introduction



Craniosynostosis

Rudolf Ludwig Carl Virchow, professor of pathology in Würzburg, Germany at the time, was the first to describe cases of craniosynostosis in 1851 (1). In his manuscript, he already explains the involvement of the cranial sutures in skull growth:

“We know for certain that the suture itself provides the material for the ossification, i.e., the stroma where calcium salts are deposited. Therefore, it is easy to see that in general a skull bone can only grow evenly in all directions when ossiferous sutures exist on all sides. When neighboring skull bones fuse prematurely through the total ossification of their common suture, i.e., through synostosis, then their further growth at this place is limited. ... Should this happen to many sutures at the same time, then a microcephalic skull forms.”

As described by Virchow, premature fusion of the cranial sutures impairs skull growth and results in anatomic malformations of the skull, known as craniosynostosis. Already in utero, the cranial sutures start to fuse around 15 to 18 weeks of gestation (2). Isolated craniosynostosis, or non-syndromic craniosynostosis, occurs in 7.2 per 10,000 births (3,4). The most common craniosynostosis types are scaphocephaly, fusion of the sagittal suture, and trigonocephaly, fusion of the metopic suture. An overview of the skull sutures and different type of craniosynostosis is presented in **figure 1** Syndromic forms, often with multiple fused sutures, are rarer and occur in 0.9 per 10,000 births (4). The most common forms of syndromic craniosynostosis are Apert, Crouzon, Muenke, and Saethre-Chotzen syndrome (5). More detailed information on the individual syndromes is presented in **table 1**.

Yet, there is still a large proportion of children with multiple fused sutures without a known genetic mutation, referred to as multisuture or complex craniosynostosis. Over the last years, an increasing number of genetic changes have been found and linked to craniosynostosis, such as *TCF12*, *IL11RA*, and *ERF*.

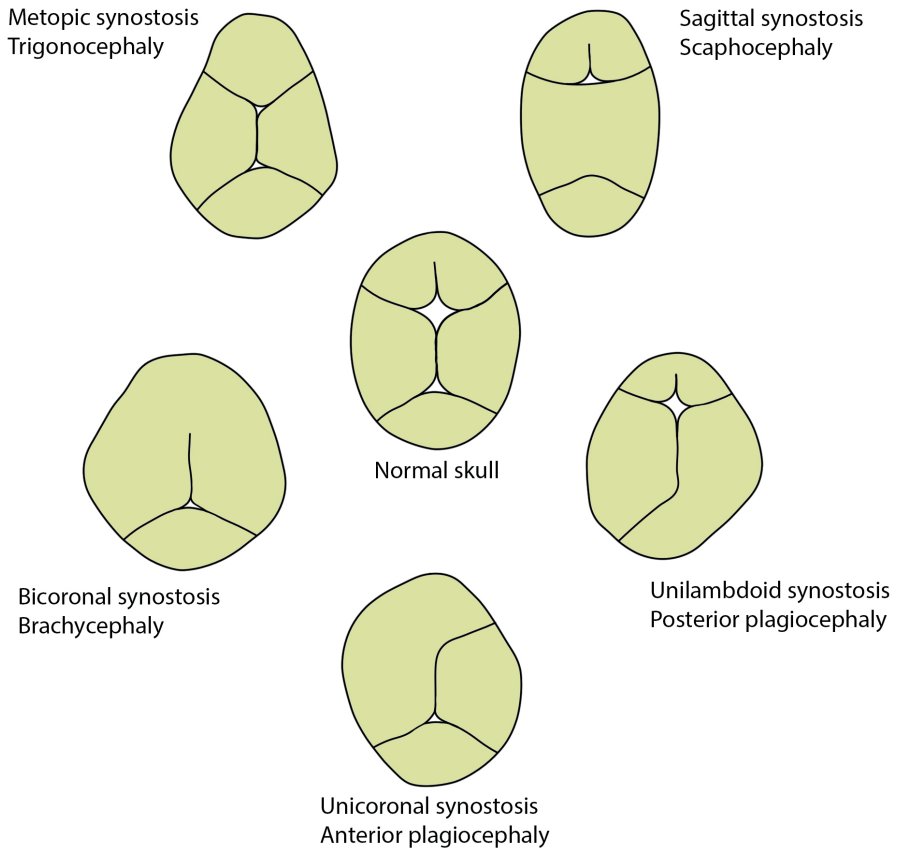


Figure 1: Overview of cranial sutures and different types of craniosynostosis.

Syndrome	Apert	Crouzon	Saethre-Chotzen	Muenke	Complex
Incidence	1/100,000	1/62,500	1/37,500	1/30,000	1/25,000
Gene involved	<ul style="list-style-type: none"> FGFR2 -S252W mutation -P253R mutation 1372 BP deletion 	<ul style="list-style-type: none"> FGFR1 -P252R mutation FGFR2 -Several mutations FGFR3 -A391E mutation 	<ul style="list-style-type: none"> TWIST1 -Several mutations or deletions 	<ul style="list-style-type: none"> FGFR3 - P250R mutation 	Unknown
Phenotype	<ul style="list-style-type: none"> - Midface hypoplasia -Hypertelorism - Exorbitism - High-arched palate - Dental crowding - Cleft palate - Crossbow-shaped lips - Severe syndactyly hands and feet 	<ul style="list-style-type: none"> - Midface hypoplasia -Hypertelorism - Exorbitism - Class III malocclusion 	<ul style="list-style-type: none"> - Ptosis - Down slant - Low frontal hairline 	<ul style="list-style-type: none"> - Hearing loss - Behavioral issues 	<ul style="list-style-type: none"> - Variable spectrum of additional features
Sutures involved	Most often bicoronal	Most often multi-sutural, progression into pansynostosis	Most often bicoronal	Most often bicoronal	Any suture
Neuropsychological development	Mental retardation IQ 77 (59 – 94)	Some developmental delay in severe cases IQ 103 (54 – 133)	Normal IQ 100 (52 – 144)	Learning disabilities IQ 95 (73 – 124)	IQ 94 (49 – 133)
OSA (%)	70%	65%	15 - 60%	7 - 75%	7 - 72%
ICH (%)	80%	60%	33%	8%	Highly variable

Table 1: Shows an overview of the characteristics of the most common craniosynostosis syndromes (3,4,6-11).

Sleep disordered breathing and altered sleep in syndromic craniosynostosis

Sleep disordered breathing

Although sleep is essential to every human being, there are also several diseases that would not exist without sleep, with sleep disordered breathing (SDB) being the most important. The term SDB represents a range of diseases with increasing severity that goes from primary snoring to Obstructive Sleep Apnea (OSA) as the most serious disorder. All SDB entities are characterized by nighttime airway dysfunction resulting from an increased upper airway resistance and increased pharyngeal collapsibility. Snoring, breathing stops, and increased work of breathing are frequent phenomena (12).

Primary snoring

The mildest form of SDB is primary snoring. Primary snoring includes patients who habitually snore more than 3 nights per week, but do not suffer from apneas, hypopneas, arousals, or gas exchange abnormalities (12). Although this condition seems harmless, it has been linked to neurocognitive impairment in children (13). Especially in children with syndromic craniosynostosis, snoring is a common condition. More than 75% of all patients suffer from it (14).

Upper airway resistance syndrome (UARS)

More severe than primary snoring is the upper airway resistance syndrome (UARS). Patients with UARS snore and have an increased work of breathing. The increased respiratory effort causes frequent arousals, but does not lead to apneas or hypopneas (15). Patients may suffer from daytime sleepiness, morning headaches, and enuresis (16). In children, the symptoms can be similar to those of OSA, which makes it hard to distinguish between the two without further diagnostics (17).

The absence of apneas and hypopneas makes UARS challenging to diagnose. The increased respiratory effort is most adequately measured by an esophageal pressure monitor (18). This will show an increasingly negative pressure during inspiration. However, esophageal pressure monitoring is invasive and cumbersome, especially in children. The intrathoracic

pressure swings cause some other cardiorespiratory phenomena that can be observed instead. Firstly, the intrathoracic pressure swings are caused by a relative obstruction at the level of the pharynx. To ensure adequate airflow into the lungs, the patients increase their work of breathing to overcome the increased pharyngeal resistance. This process causes the thorax and abdomen to move out of synchrony; a phenomenon that is called paradoxical breathing. Secondly, the increased intrathoracic pressure swings cause exaggerated respiratory arrhythmia. Baroreceptors at the base of the carotid artery are stimulated by the increase in intrathoracic pressure, causing them to repetitively stimulate the vagal nerve. Increased vagal activity causes the exaggerated respiratory arrhythmia in UARS and in some patients, it may even cause daytime hypotension. The increased vagal activity (i.e. sympathetic activity) can be detected by Heart Rate Variability (HRV) analysis (19,20). Since many children with syndromic craniosynostosis snore, it is important for the clinician to distinguish between primary snoring and UARS and HRV analysis might be a helpful tool.

Obstructive sleep apnea

The most classical form of SDB is obstructive sleep apnea (OSA). Children with OSA may suffer from inattention, hyperactivity, enuresis, behavioral problems, daytime sleepiness, failure to thrive, and morning headaches. OSA is characterized by nighttime breathing obstructions.

Many people assume OSA only occurs in middle-aged obese men; however, the opposite is true. In the general pediatric population, OSA prevalence can be as high as 4%, with a peak at 4 years of age (21). The main cause of OSA in children of 4 years of age is enlargement of the tonsils (22). The enlarged tonsils narrow the airway and cause apneas and hypopneas during sleep.

During wakefulness, the nose is the narrowest site of the airway. During sleep, however, the airway resistance in the pharynx rises to an even higher level, also in individuals without sleep-related breathing disorders (23). This increased resistance is caused by relaxation of the pharyngeal dilator muscles which usually ensure patency of the airway at the pharyngeal level. Being a complex organ designed as a rigid tube with a collapsible part in the middle, the pharynx is involved with both respiration and digestion. During respiration, the pharynx must increase its

size to provide enough room for air to pass. As an organ of digestion, on the other hand, the pharynx must close to protect the larynx and nasopharynx, and direct food and liquids to the esophagus. To fulfill these diverse functions, it is equipped with a set of at least 20 muscle pairs that control its size and shape.

To ensure patency of the airway during sleep, the activation of the pharyngeal dilators is necessary. Their activity is modulated by a reflex system by the respiratory control center in the medulla with input from pharyngeal mechanoreceptors responding to stimuli such as decreased airflow, increased negative pressure, and increased blood carbon dioxide levels (24). The pharyngeal dilator muscles counteract forces that tend to narrow the airway. The collapsing forces include gravity in supine position, decreased neuromuscular tone of pharyngeal muscles, intraluminal negative pressure generated during inspiration, and anatomical narrowing of the airway by skeletal or soft-tissue malformations.

Children with OSA do not experience apneas or difficulty of breathing during the day. While awake, the pharyngeal dilators' muscular tone is markedly higher than during sleep, and can easily compensate for the forces that tend to narrow the airway. However, during sleep the activity of the pharyngeal muscles is reduced (25-27). In children with OSA, that means the pharyngeal dilators are not fully able to keep the airway open during sleep. The forces that tend to close the airway are simply too strong to be overcome by the pharyngeal dilators.

Children are generally better capable of keeping their airway open than adults, and are more likely to suffer from prolonged obstructive hypoventilation, than from distinct repetitive apneas. This is because their pharyngeal dilators are sufficiently strong to ensure a partially open airway (28).

Respiratory control is modulated by a feedback loop better known as loop gain (29,30). Hypercapnia and hypoxia stimulate the chemoreceptors in the carotid body and in the brainstem, which in turn increases the respiratory drive. Low carbon dioxide levels dampen the respiratory drive. In patients with OSA, this loop gain system can become more sensitive and can cause exaggerated reaction to hypercapnia and hypocapnia. It may destabilize the respiratory drive and cause periodic breathing (31).

Children with syndromic craniosynostosis have an increased risk of developing SDB due to the abnormal anatomy of the midface and mandible, and thus of multiple levels of the upper airway collapse. Children with Apert or Crouzon syndrome have a prevalence of OSA of 40% to 68% (11,32-34). Children with Muenke syndrome, on the other hand, have a low prevalence of OSA, approximately 8% (9). This difference is supposedly explained by the syndromes' phenotypes. Doerga et al. showed that endoscopy was useful in determining the different levels of obstruction in the different syndromes (35). **Figure 2** shows the different levels of the airway that can be involved in the obstruction. Apert and Crouzon syndromes are characterized by midface hypoplasia, while Muenke syndrome is not. Additionally, other airway anomalies can be present such as laryngomalacia and subglottic stenosis (36).

The prevalence of OSA in syndromic craniosynostosis is highest in infants and improves naturally with increasing age and growth of the airway. It is unlikely for a child with syndromic craniosynostosis to develop OSA once over the age of 6 years (11).

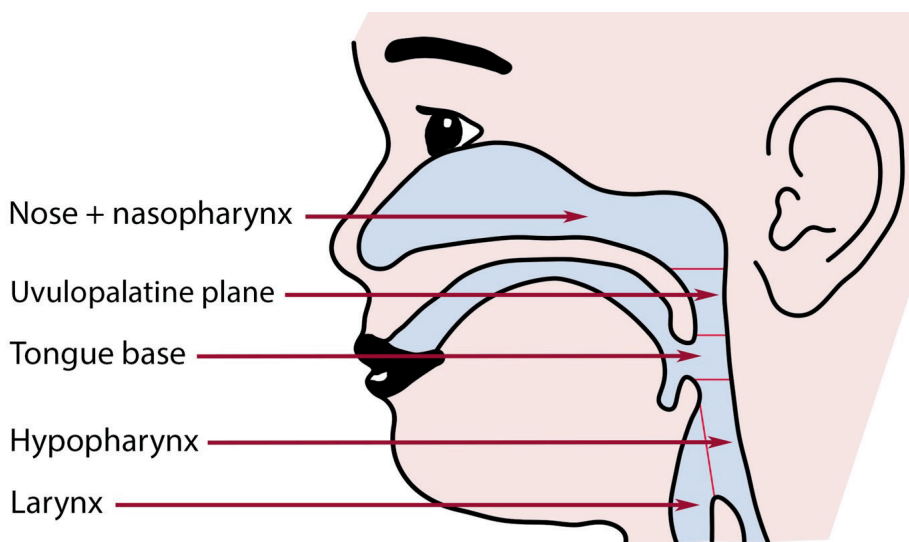


Figure 2: Anatomical levels of possible obstruction. Adapted from Doerga et al. (35).

Obstructive sleep apnea in syndromic craniosynostosis: diagnosis

Clinical symptoms

Obstructive sleep apnea is notoriously difficult to diagnose and is often under-recognized by general practitioners (37). The most important symptoms are snoring, restless sleep, apneas during sleep, daytime sleepiness, and behavioral or concentration difficulties (12,38). However, simply screening for these symptoms has not proven useful in the diagnosis. Screening parental report on habitual snoring has a high sensitivity but a low specificity, while parental report on witnessed apneas has a high specificity but a low sensitivity (39,40). In addition to the earlier mentioned symptoms patients with OSA may also suffer from other symptoms such as enuresis, excessive sweating, and morning headaches (37,41-43). If not treated adequately, OSA can have serious cardiovascular and neurocognitive consequences (38).

Questionnaires

Correctly diagnosing SDB and identifying the exact underlying pathology is challenging. Several methods are available to detect SDB. However, there is a great difference in their sensitivity and specificity. In the choice of the appropriate test, also availability and costs must be taken into consideration.

The cheapest and most accessible method is a questionnaire. Many pediatric questionnaires have been developed over the years. Probably the most popular and oldest one is the questionnaire by Brouillette et al. (44). This questionnaire combines three items (snoring, witnessed apneas, and difficulty breathing) to indicate if a child has an increased risk of having OSA. However, its sensitivity and specificity are low (45). Another, more elaborate questionnaire is the pediatric sleep questionnaire (PSQ) created by Chervin et al. (46). It is a 22-item questionnaire with questions on snoring, excessive daytime sleepiness, and behavioral problems. Its sensitivity and specificity are better than the Brouillette questionnaire, but still expert consensus remains that questionnaires are only useful as initial screening tools or that they can be used in a low resource setting (12).

Knowing questionnaires alone are unlikely to ever have satisfactory sensitivity and specificity, Villa et al. combined an extensive questionnaire with physical examination (47). They developed the Sleep Clinical Record (SCR). The sensitivity (91.9%) of the SCR was high in children with tonsillar hypertrophy or obesity, but the specificity was low (40.6%). To date, the SCR has never been tested in children with syndromic craniosynostosis.

Questionnaires are less useful in children with syndromic craniosynostosis. Nearly all questionnaires are developed for children without other medical conditions and with adenotonsillar hypertrophy as the cause of OSA. These questionnaires are based upon the observation of snoring and witnessed apneas and assume the prevalence of OSA is not higher than 2-5%. The fact that approximately 75% of children with syndromic craniosynostosis snores makes it notoriously difficult for caregivers to recognize clinically important signs of OSA, making most currently available questionnaires less useful to detect OSA in this particular population in their current forms (14).

There is, however, one questionnaire that has been proven useful in this population, the OSA-18 questionnaire. The OSA-18 questionnaire is not a screening tool for OSA but was designed to evaluate OSA-related quality of life. The OSA-18 questionnaire can discriminate between the health problems related to the specific syndrome and those related to OSA. Bannink et al. validated the questionnaire in 119 children with syndromic craniosynostosis and a healthy control group of 459 children (48) and it was found that it is valid for use also in the craniosynostosis population

Questionnaire	Items	Outcome
Brouillette OSA score	3 questions	Poor sensitivity and specificity for the prediction of PSG results
Pediatric Sleep Questionnaire	22 questions	Useful tool for prediction of oAHI >5/h, OSA-related neurobehavioural morbidity and improvement after adenotonsillectomy
OSA-18	18 questions	Poor sensitivity and specificity for the prediction of PSG results.
Sleep Clinical Record (SCR)	Combination of history and ENT exam	High sensitivity, but poor specificity

Table 2: Overview of OSA questionnaires.

Poly(somno)graphy

The gold standard to diagnose OSA is a level 1 polysomnography (PSG), but there are other methods to study OSA overnight. The simplest form of an overnight study is a single channel recording. Nocturnal oximetry is the most frequently used single channel recording. Oximetry is an abbreviated, low-cost alternative that can be used when the more expensive level 1 PSG is unavailable. With oximetry, oxygen desaturations can be objectified. It is possible to calculate the oxygen desaturation index (ODI) 3% or 4%. Several studies have used different cut-off values in an attempt to identify the child with OSA (49). Overall, sensitivity and specificity range from 60% to 80% to detect moderate or severe OSA. A different approach in oximetry scoring is the McGill oximetry score (50). This scoring system not only takes into account the number of desaturations, but also the severity of the desaturations (<90%) and whether there are more than 3 clusters of desaturations of at least 10-30 minutes. The McGill oximetry score has a high specificity (close to 100%), but a low sensitivity (around 40%). Thus, it is a useful tool to confirm OSA, but not as a screening tool.

The gold standard to diagnose OSA is a polysomnography (PSG). A level 1 PSG is the most advanced type of PSG. During this examination, the patient is sleeping overnight in a sleep laboratory and a physician is present during the night to supervise. Channels being recorded are the following: nasal flow, chest and abdominal movement, electrocardiogram (ECG), electrooculogram, chin electromyogram, limited or complete EEG, blood-oxygen saturation,

transcutaneous carbon dioxide, blood-gas sampling, and a full-night video recording. In our center the level 1 PSGs are performed using a thermistor instead of a nasal cannula. This is done because children with syndromic craniosynostosis often have an anatomically obstructed nose.

In the home setting, polysomnography is also possible, but is then referred to as a level 2 study, because there is no technician present to oversee the study. However, usually, home sleep apnea testing is done with fewer channels being recorded. Typically, this would only include nasal flow, chest and abdominal movement, and blood-oxygen saturation. This type of examination is usually referred to as polygraphy or a level 3 study. A polygraphy can be used as a screening method in syndromic craniosynostosis and is cheaper and more available than a level 1 PSG. A polygraphy has a higher chance of failing than a level 1 PSG, but can also be repeated more easily (51).

A PSG is scored according to the rules defined by the American Association of Sleep Medicine (AASM) (52). A child is considered to have OSA if the obstructive apnea hypopnea index (oAHI) is higher than one, indicating that a child has more than one obstructive apnea or hypopnea per hour. OSA is then subdivided into mild, moderate, and severe. An oAHI between one and five is considered mild, an oAHI between five and ten is considered moderate and higher than ten is considered severe.

Heart Rate Variability

The rhythm of the heart, or heart rate, is influenced by many factors, more than we currently understand. One important heart rate modulator is the autonomic nervous system. The sympathetic nervous system, for example, increases the heart rate frequency, and can cause tachycardia (53). Contrastingly, the parasympathetic nervous system, through innervation of the vagal nerve, reduces the heart rate and counteracts the effects of the sympathetic nervous system (54). However, the true situation is probably even more complex.

Past researchers have tempted to quantify the rhythms of the heart in order to get a hold on autonomic nervous system activity and derived several parameters from the Heart Rate Variability (HRV) on an ECG. Variables concerning the HRV can be calculated by measuring a set of RR-intervals, the time between two R peaks on an ECG, over an extended period of time. The

RR-intervals are then analyzed in two domains, the time domain and the frequency domain. The time domain includes simple statistics such as averages and standard deviations. The parameters from the frequency domain are calculated after a Fast Fourier Transform and allow for the analysis of the variance and distribution among the frequency spectra (55). Frequency analysis in HRV is very similar to frequency analysis of sound with Hz as the SI unit. Over the years, researchers developed methods to distinguish sympathetic from parasympathetic activity from HRV analysis (56).

Given the fact that a level 1 PSG also includes a full night ECG recording, this opens up the possibility for a full night's analysis of HRV in children with syndromic craniosynostosis. Children with severe OSA probably express more sympathetic activity and less parasympathetic activity than children without OSA, as evidenced by HRV (57). Children with UARS suffer from OSA-specific symptoms but do not show any clear signs of respiratory disturbance on a PSG, except for marked respiratory arrhythmia (16,58). HRV might be a useful tool to distinguish those who suffer from UARS based on their respiratory arrhythmia and those who do not.

Altered sleep

Sleep is a naturally occurring state of altered consciousness, characterized by decreased sensory activity and reduced muscle activity. Humans and almost all animals known to man exhibit sleep or sleep-like states, indicating its importance for basic survival, much like eating and breathing (59). Basic experiments in rodents have shown that sleep deprivation causes excessive loss of body weight, severe skin lesions, the inability to regulate body temperature, and it can be lethal within weeks (60,61). In humans, sleep deprivation increases reaction time, decreases learning capabilities, and increases the risk of seizures (62).

Sleep is essential for regeneration of the mind and body, but despite decades of research, it is still unclear why sleep is restorative and vital. Studies have shown that sleep plays a big role in learning and memory processing (63,64). The brain's depleted glycogen storage is restored during sleep and neurotoxins that have built up during wakefulness are removed from the brain's interstitial fluid (65). Not only the brain benefits from sleep, but also the rest of the body does.

Sleep deprivation studies in mice and rats have shown increased cancer rates and decreased immune system functioning (66,67).

Generally speaking, human sleep can be divided into two distinct states: Rapid Eye Movement (REM) sleep and Non-REM (NREM) sleep. The latter can then be subdivided into N1, N2, and N3, with N1 being lightest sleep and N3 deepest sleep (52). N3 sleep is also called deep sleep or slow-wave sleep and it is characterized by low brain activity and slow brain waves seen on the electroencephalogram (EEG). REM sleep, on the other hand, is characterized by nearly wake-like brain activity. REM sleep is also called dream sleep because of vivid and hallucinatory dreaming occurring in this phase.

REM sleep and NREM sleep occur in an alternating fashion. In adolescents and adults, a typical sleep cycle of REM and NREM takes approximately 90 minutes. This would mean that a person goes through 4 to 6 sleep cycles during a normal night of sleep. Infants spend around 50% of their night's sleep in REM sleep, or active sleep as it is called in the first 3 months of life. With increasing age, the time spent in REM sleep decreases to approximately 25% at 2 years of age (68-70).

In contrast, the brain is activated during REM sleep and the eyes move rapidly, but the rest of the body is hypotonic. Sensory inputs and motor outputs are simultaneously blocked during REM sleep. This general hypotonia also occurs at the level of the pharynx, making REM sleep the phase in which SDB is most likely to occur.

The organization of sleep is also referred to as sleep architecture. The quality of a night's sleep is not only determined by the duration of the sleep period, but also by the quality of the sleep architecture. A night's sleep with good quality consists of approximately 20-25% REM sleep and 20-40% N3 sleep in children (71). In order to achieve this, one should cycle through the sleep stages as efficiently as possible, with few arousals and awakenings. The integrity of a night's sleep can be expressed by variables such as the sleep efficiency, sleep quality, and the number of arousals (52).

Patients with OSA usually have normal sleep duration, but their sleep architecture is disturbed. The recurrent airway obstructions cause arousal from sleep and disturb the sleep cycle of the patient, lowering the sleep quality and the sleep efficiency (72). This sleep architecture

disturbance also occurs in children with syndromic craniosynostosis and OSA. Children with moderate to severe OSA showed lower sleep efficiency and less REM sleep in a study with 39 children with syndromic craniosynostosis (73). In a subgroup of five patients undergoing a monobloc procedure, the amount of REM sleep increased postoperatively. However, the number of patients in this study was small and therefore lacked the power to fully investigate the effect of OSA on sleep architecture, let alone the effect of surgery.

Obstructive sleep apnea treatment in craniosynostosis

For the treatment of OSA in children with craniosynostosis there are several options, both invasive and non-invasive. Treatment of OSA should only be considered in case of moderate or severe OSA. Children with mild OSA should only be treated if they have symptoms, otherwise it is not necessary to treat them. Non-invasive treatment options include the use of nasal corticosteroids, high flow oxygen (Optiflow), Continuous Positive Airway Pressure (CPAP) or Bi-level Positive Airway Pressure (BiPAP). Nasal corticosteroids should only be used as temporary solution in children with mild OSA and symptoms (74).

Nasopharyngeal tube

A nasopharyngeal tube (NPT) is a tube that can be placed in an infant's nasopharynx to keep the airway from collapsing. There is a lack of evidence supporting the effectiveness of NPT in treating OSA in syndromic craniosynostosis with midface hypoplasia. It might be used as a temporary solution to secure the airway while the infant's airway can grow and further surgical solutions can be planned, while trying to avoid a tracheostomy.

CPAP and BiPAP

Other treatment options for children with moderate or severe OSA as they await surgical treatment are CPAP or BiPAP. Both treatment options are applied through a mask that is placed over the nose and/or mouth during the night. Though, in children with syndromic craniosynostosis the usage of CPAP or BiPAP masks can be complicated by the facial malformations. The combination of air-leakage and the inability to close the eyes in some

patients, can cause corneal abrasions (75). Physicians should make sure the mask fits properly. Custom-made masks can help ensure a good fit and prevent these corneal lesions.

Adenotonsillectomy

Adenotonsillectomy (ATE) is an important treatment choice to treat OSA in children with syndromic craniosynostosis after the first year of life. However, different results about the effect of ATE as a treatment for OSA in syndromic craniosynostosis are reported (76). A retrospective cohort study by Zandieh et al. included 47 children with Apert and Crouzon/Pfeiffer syndromes. In 13 patients with OSA, an ATE was performed. Following ATE, the mean oAHI was not significantly different and OSA persisted in 11 of 13 children (77). Another study by Amonoo-Kuofi et al. included a retrospective analysis on the data of 26 patients with syndromic craniosynostosis. Fifteen patients (60%) showed a decrease in OSA severity score after adenotonsillectomy. Overall, there was a significant improvement in the mean ODI4% and mean nadir of dips in blood-oxygen saturation after the surgery. The authors state that ATE can also be beneficial if the tonsils are small, but underline that respiratory problems in syndromic craniosynostosis are multifactorial and may need additional therapy (78).

Midface advancement/monobloc

Midface advancement surgery, such as Le Fort III or monobloc advancement surgery is used in children with syndromic craniosynostosis and midface hypoplasia to treat airway obstruction, exorbitism, and in the case of monobloc distraction also providing cranial vault expansion (79). Monobloc surgery is a risky procedure with 1-2% mortality and high morbidity (80). During this procedure both the forehead and the midface are advanced by combining a fronto-orbital advancement with a maxillary distraction. The technique of distraction allows for a greater expansion than the classical instant advancement.

Many surgeons try to delay midface advancement and aim to perform surgery between 5 and 8 years of age (81). Firstly, this is done because the surgical procedure is easier in older children and with less complications, because the craniofacial skeleton is more ossified and easier to mobilize (82,83). Secondly, in the very young it is impossible to achieve a sufficient level of

advancement for the adult face, resulting in a number of re-interventions at a later age. A monobloc distraction can be considered even in the very young, but is generally only considered in severe cases of exorbitism (84,85). In older children and adults, and patients with cerebral drains, monobloc distraction can be dangerous because of a delayed cerebral re-expansion, increasing the risk of meningitis or frontal bone necrosis (80).

It is important to assess the severity of a patient's symptoms and decide what the most ideal treatment protocol for that patient is. Some severe cases might need early surgery, while less severe cases can do with a delay or a less invasive treatment. Facial surgery should be avoided during puberty, as uncertainty about appearance is common at this age and children may experience psychological difficulties with their changing appearance.

Intracranial hypertension

Together with OSA, ICH is one of the most important complications in children with syndromic craniosynostosis. The prevalence of ICH can be as high as 60% in Crouzon syndrome and 80% in Apert syndrome (6,86). There are four main contributors to ICH in syndromic craniosynostosis:

- Craniocerebral disproportion
- Cerebro-spinal fluid (CSF) outflow obstruction/impaired resorption/excessive production
- OSA
- Venous hypertension

Basically, all contributors cause a disproportion between the size of the cranial vault and the volume inside the cranial vault. Once the compliance of the cranial sutures has stopped, the skull is a closed box that contains three compartments. These compartments are CSF, blood, and the brain itself. The Monro-Kellie doctrine dictates that if one compartment takes up more volume, the other compartments have to compensate for it (87). A normal intracranial pressure (ICP) is generally below 10 mmHg. Values between 10-15 mmHg are considered borderline elevated ICP, and an ICP higher than 15 mmHg is considered increased (88). Although, there is

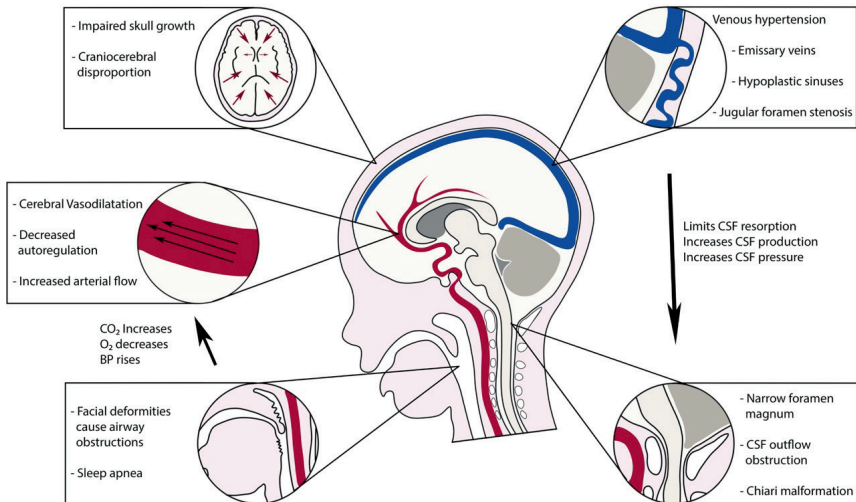


Figure 4: Pathophysiological processes concerning intracranial hypertension in children with syndromic craniosynostosis. By courtesy of Doerga et al. (111).

Cerebral spinal fluid

In a study by De Jong et al., children with syndromic craniosynostosis had an increased CSF volume (90). The increased CSF volume could be caused by an increased production, decreased resorption, or decreased outflow of CSF. CSF is produced in the choroid plexus in the ventricles. Blood flows through the capillaries in the choroid plexus and is filtered to produce CSF (95). The CSF flows through the ventricle system and is then resorbed by the granulations and arachnoid villi in the subarachnoid spaces, back into the venous system.

There is evidence that *FGFR2* is expressed in the choroidal plexus (96). One theory is that the mutation in the choroid plexus might lead to excessive production of CSF. Another theory is that CSF resorption is obstructed by an increased pressure in the venous dural sinus. Lastly, CSF outflow through the foramen magnum can be obstructed by hindbrain herniation, a common phenomenon in children with syndromic craniosynostosis (97).

Obstructive sleep apnea and intracranial hypertension

OSA causes ICH in children with syndromic craniosynostosis (98). The recurrent apneas and hypopneas occurring in these children repetitively lower the oxygen saturation, increase the carbon dioxide concentration and increase the arterial blood pressure. These phenomena affect cerebral autoregulation and increase cerebral blood flow (99). Blood flow velocity in the middle cerebral artery during an apneic period can rise to a level of 20-200% higher than the velocity during wakefulness (100,101). Jennum and Børghesen measured the pO₂, pCO₂, the ICP, and the arterial blood pressure while performing a PSG in six adults with severe OSA and have shown a direct relation between apneas and subsequent increases in ICP (99). During the beginning of an apnea, the arterial blood pressure and the ICP initially decreased, but during the apnea the ICP increased associated with a decrease in pO₂ and with an increase in pCO₂. At the termination of an apnea, the ICP and the arterial blood pressure both rose sharply. Additionally, because most apneas occur during REM sleep, a phase that is characterized by vasodilation and an already increased blood flow, this is the phase the ICP increases the most (98,102).

Venous hypertension

Children with syndromic craniosynostosis are prone to aberrant cerebral venous anatomy (94,103). Many patients show large circulatory important occipital and mastoidal emissary veins. These transosseous emissary veins are also present in healthy individuals without syndromic craniosynostosis (104,105). The emissary veins probably gain circulatory importance as compensation for obstructions in cerebral venous drainage, such as dural sinus stenosis, hypoplastic transverse sinuses, and jugular foramen stenosis. The hypothesis of venous hypertension is that the aberrant cerebral venous anatomy causes a relative downstream obstruction, eventually leading to an ICP increase (106-108). Even though much research on venous hypertension has been done, it is still unclear why certain patients develop ICH and others do not (94,109,110). More research is needed to investigate cerebral hemodynamics and their relation to ICH.

Aim of this thesis

The aim of this thesis is to better understand pathophysiology and treatment of sleep disordered breathing and intracranial hypertension in children with syndromic craniosynostosis. More knowledge on these subjects will lead to new insights and new treatment options for children with syndromic and complex craniosynostosis and will eventually improve functional and neurodevelopmental outcome. The introduction to the thesis has been presented in this chapter, **chapter 1**.

The long-term effectiveness of our institution's OSA-treatment protocol is evaluated in **Chapter 2** of this thesis. The effectiveness of the treatment of all children that have undergone PSG screening for sleep-disordered breathing since the start of the prospective cohort study at our institution will be evaluated. The minimum duration of follow-up will be six years. The outcome of this study will help physicians in their decision for the best treatment.

Chapter 3 will study the effect of OSA-treatment and cranial vault surgery on sleep architecture.

The usefulness of HRV analysis in the diagnosis of children with syndromic craniosynostosis and UARS will be studied using a level 1 PSG in **chapter IV**. HRV analysis will allow the evaluation of the sympathetic and parasympathetic nervous systems, which has never been done in syndromic craniosynostosis before.

Chapter 5 of this thesis will study cerebral venous flow by measuring the flow velocity of the superior sagittal sinus and the internal cerebral vein in infants with craniosynostosis and healthy control subjects. This study will evaluate the hypothesis of venous hypertension leading to a decrease in venous flow velocity.

Chapter 6 will study the volumes of the sagittal, transverse, and straight sinus on 3D T2-weighted MRI images. In this study, the effects of cranial growth and ICH will be evaluated. The outcomes of this study will help understand the pathophysiology behind ICH in syndromic craniosynostosis.

Chapter 7 will include the general discussion, evaluating and integrating all the results of the previous chapters in this thesis.

References

1. Persing JA, Jane JA, Shaffrey M: Virchow and the pathogenesis of craniosynostosis: a translation of his original work. *Plast Reconstr Surg* 83:738-742, 1989
2. Mathijssen IM, van Splunder J, Vermeij-Keers C, Pieterman H, de Jong TH, Mooney MP, et al: Tracing craniosynostosis to its developmental stage through bone center displacement. *J Craniofac Genet Dev Biol* 19:57-63, 1999
3. Robin NH, Falk MJ, Haldeman-Englert CR: FGFR-Related Craniosynostosis Syndromes, in Adam MP, Ardinger HH, Pagon RA, Wallace SE, Bean LJH, Stephens K, et al (eds): *GeneReviews*((R)), 1993
4. Cornelissen M, Ottelander B, Rizopoulos D, van der Hulst R, Mink van der Molen A, van der Horst C, et al: Increase of prevalence of craniosynostosis. *J Craniomaxillofac Surg* 44:1273-1279, 2016
5. Johnson D, Wilkie AO: Craniosynostosis. *Eur J Hum Genet* 19:369-376, 2011
6. Abu-Sittah GS, Jeelani O, Dunaway D, Hayward R: Raised intracranial pressure in Crouzon syndrome: incidence, causes, and management. *J Neurosurg Pediatr* 17:469-475, 2016
7. Maliepaard M, Mathijssen IM, Oosterlaan J, Okkerse JM: Intellectual, behavioral, and emotional functioning in children with syndromic craniosynostosis. *Pediatrics* 133:e1608-1615, 2014
8. Spruijt B, Joosten KF, Driessen C, Rizopoulos D, Naus NC, van der Schroeff MP, et al: Algorithm for the Management of Intracranial Hypertension in Children with Syndromic Craniosynostosis. *Plast Reconstr Surg* 136:331-340, 2015
9. den Ottelander BK, de Goederen R, van Veelen MC, van de Beeten SDC, Lequin MH, Dremmen MHG, et al: Muenke syndrome: long-term outcome of a syndrome-specific treatment protocol. *J Neurosurg Pediatr*:1-8, 2019
10. Kilcoyne S, Luscombe C, Scully P, Jayamohan J, Magdum S, Wall S, et al: Language Development, Hearing Loss, and Intracranial Hypertension in Children With TWIST1-Confirmed Saethre-Chotzen Syndrome. *J Craniofac Surg* 30:1506-1511, 2019
11. Driessen C, Joosten KF, Bannink N, Bredero-Boelhauer HH, Hoeve HL, Wolvius EB, et al: How does obstructive sleep apnoea evolve in syndromic craniosynostosis? A prospective cohort study. *Arch Dis Child* 98:538-543, 2013
12. Kaditis AG, Alonso Alvarez ML, Boudewyns A, Alexopoulos EI, Ersu R, Joosten K, et al: Obstructive sleep disordered breathing in 2- to 18-year-old children: diagnosis and management. *Eur Respir J* 47:69-94, 2016
13. Brockmann PE, Urschitz MS, Schlaud M, Poets CF: Primary snoring in school children: prevalence and neurocognitive impairments. *Sleep Breath* 16:23-29, 2012
14. Bannink N, Mathijssen IM, Joosten KF: Can parents predict obstructive sleep apnea in children with syndromic or complex craniosynostosis? *Int J Oral Maxillofac Surg* 39:421-423, 2010
15. Pepin JL, Guillot M, Tamisier R, Levy P: The upper airway resistance syndrome. *Respiration* 83:559-566, 2012
16. Guilleminault C, Stoohs R, Clerk A, Cetel M, Maistros P: A cause of excessive daytime sleepiness. The upper airway resistance syndrome. *Chest* 104:781-787, 1993
17. Guilleminault C, Khrantsov A: Upper airway resistance syndrome in children: a clinical review. *Semin Pediatr Neurol* 8:207-215, 2001
18. Arnold WC, Guilleminault C: Upper airway resistance syndrome 2018: non-hypoxic sleep-disordered breathing. *Expert Rev Respir Med* 13:317-326, 2019
19. Guilleminault C, Faul JL, Stoohs R: Sleep-disordered breathing and hypotension. *Am J Respir Crit Care Med* 164:1242-1247, 2001
20. Lin C, Lo MT, Guilleminault C: Exploring the Abnormal Modulation of the Autonomic Systems during Nasal Flow Limitation in Upper Airway Resistance Syndrome by Hilbert-Huang Transform. *Front Med (Lausanne)* 4:161, 2017

21. Lumeng JC, Chervin RD: Epidemiology of pediatric obstructive sleep apnea. *Proc Am Thorac Soc* 5:242-252, 2008
22. Nolan J, Brietzke SE: Systematic review of pediatric tonsil size and polysomnogram-measured obstructive sleep apnea severity. *Otolaryngol Head Neck Surg* 144:844-850, 2011
23. Rowley JA, Zahn BR, Babcock MA, Badr MS: The effect of rapid eye movement (REM) sleep on upper airway mechanics in normal human subjects. *J Physiol* 510 (Pt 3):963-976, 1998
24. Sant'Ambrogio G, Mathew OP: Laryngeal receptors and their reflex responses. *Clin Chest Med* 7:211-222, 1986
25. Jeffries B, Brouillette RT, Hunt CE: Electromyographic study of some accessory muscles of respiration in children with obstructive sleep apnea. *Am Rev Respir Dis* 129:696-702, 1984
26. Katz ES, White DP: Genioglossus activity during sleep in normal control subjects and children with obstructive sleep apnea. *Am J Respir Crit Care Med* 170:553-560, 2004
27. Katz ES, Marcus CL, White DP: Influence of airway pressure on genioglossus activity during sleep in normal children. *Am J Respir Crit Care Med* 173:902-909, 2006
28. McNamara F, Issa FG, Sullivan CE: Arousal pattern following central and obstructive breathing abnormalities in infants and children. *J Appl Physiol* (1985) 81:2651-2657, 1996
29. Khoo MC, Kronauer RE, Strohl KP, Slutsky AS: Factors inducing periodic breathing in humans: a general model. *J Appl Physiol Respir Environ Exerc Physiol* 53:644-659, 1982
30. Naughton MT: Loop gain in apnea: gaining control or controlling the gain? *Am J Respir Crit Care Med* 181:103-105, 2010
31. Susarla SM, Thomas RJ, Abramson ZR, Kaban LB: Biomechanics of the upper airway: Changing concepts in the pathogenesis of obstructive sleep apnea. *Int J Oral Maxillofac Surg* 39:1149-1159, 2010
32. Pijpers M, Poels PJ, Vaandrager JM, de Hoog M, van den Berg S, Hoeve HJ, et al: Undiagnosed obstructive sleep apnea syndrome in children with syndromal craniofacial synostosis. *J Craniofac Surg* 15:670-674, 2004
33. Lo LJ, Chen YR: Airway obstruction in severe syndromic craniosynostosis. *Ann Plast Surg* 43:258-264, 1999
34. Inverso G, Brustowicz KA, Katz E, Padwa BL: The prevalence of obstructive sleep apnea in symptomatic patients with syndromic craniosynostosis. *Int J Oral Maxillofac Surg* 45:167-169, 2016
35. Doerga PN, Spruijt B, Mathijssen IM, Wolvius EB, Joosten KF, van der Schroeff MP: Upper airway endoscopy to optimize obstructive sleep apnea treatment in Apert and Crouzon syndromes. *J Craniomaxillofac Surg* 44:191-196, 2016
36. Mathews F, Shaffer AD, Georg MW, Ford MD, Goldstein JA, Jabbour N, et al: Airway anomalies in patients with craniosynostosis. *Laryngoscope*, 2018
37. Joosten KF, Larramona H, Miano S, Van Waardenburg D, Kaditis AG, Vandenbussche N, et al: How do we recognize the child with OSAS? *Pediatr Pulmonol* 52:260-271, 2017
38. Tan HL, Alonso Alvarez ML, Tsaoussoglou M, Weber S, Kaditis AG: When and why to treat the child who snores? *Pediatr Pulmonol* 52:399-412, 2017
39. Brietzke SE, Katz ES, Roberson DW: Can history and physical examination reliably diagnose pediatric obstructive sleep apnea/hypopnea syndrome? A systematic review of the literature. *Otolaryngol Head Neck Surg* 131:827-832, 2004
40. Certal V, Catumbela E, Winck JC, Azevedo I, Teixeira-Pinto A, Costa-Pereira A: Clinical assessment of pediatric obstructive sleep apnea: a systematic review and meta-analysis. *Laryngoscope* 122:2105-2114, 2012

41. Alexopoulos EI, Malakasioti G, Varlami V, Miligkos M, Gourgoulianis K, Kaditis AG: Nocturnal enuresis is associated with moderate-to-severe obstructive sleep apnea in children with snoring. *Pediatr Res* 76:555-559, 2014
42. Sedky K, Bennett DS, Carvalho KS: Attention deficit hyperactivity disorder and sleep disordered breathing in pediatric populations: a meta-analysis. *Sleep Med Rev* 18:349-356, 2014
43. Bonuck KA, Freeman K, Henderson J: Growth and growth biomarker changes after adenotonsillectomy: systematic review and meta-analysis. *Arch Dis Child* 94:83-91, 2009
44. Brouillette R, Hanson D, David R, Klemka L, Szatkowski A, Fernbach S, et al: A diagnostic approach to suspected obstructive sleep apnea in children. *J Pediatr* 105:10-14, 1984
45. Schechter MS, Section on Pediatric Pulmonology SoOSAS: Technical report: diagnosis and management of childhood obstructive sleep apnea syndrome. *Pediatrics* 109:e69, 2002
46. Chervin RD, Hedger K, Dillon JE, Pituch KJ: Pediatric sleep questionnaire (PSQ): validity and reliability of scales for sleep-disordered breathing, snoring, sleepiness, and behavioral problems. *Sleep Med* 1:21-32, 2000
47. Villa MP, Paolino MC, Castaldo R, Vanacore N, Rizzoli A, Miano S, et al: Sleep clinical record: an aid to rapid and accurate diagnosis of paediatric sleep disordered breathing. *Eur Respir J* 41:1355-1361, 2013
48. Bannink N, Maliepaard M, Raat H, Joosten KF, Mathijssen IM: Reliability and validity of the obstructive sleep apnea-18 survey in healthy children and children with syndromic craniosynostosis. *J Dev Behav Pediatr* 32:27-33, 2011
49. Kaditis A, Kheirandish-Gozal L, Gozal D: Pediatric OSAS: Oximetry can provide answers when polysomnography is not available. *Sleep Med Rev* 27:96-105, 2016
50. Nixon GM, Kermack AS, Davis GM, Manoukian JJ, Brown KA, Brouillette RT: Planning adenotonsillectomy in children with obstructive sleep apnea: the role of overnight oximetry. *Pediatrics* 113:e19-25, 2004
51. Bannink N, Mathijssen IM, Joosten KF: Use of ambulatory polysomnography in children with syndromic craniosynostosis. *J Craniofac Surg* 21:1365-1368, 2010
52. Berry RB, Budhiraja R, Gottlieb DJ, Gozal D, Iber C, Kapur VK, et al: Rules for scoring respiratory events in sleep: update of the 2007 AASM Manual for the Scoring of Sleep and Associated Events. Deliberations of the Sleep Apnea Definitions Task Force of the American Academy of Sleep Medicine. *J Clin Sleep Med* 8:597-619, 2012
53. Schwartz PJ, Pagani M, Lombardi F, Malliani A, Brown AM: A cardiocardiac sympathovagal reflex in the cat. *Circ Res* 32:215-220, 1973
54. Hirsch JA, Bishop B: Respiratory sinus arrhythmia in humans: how breathing pattern modulates heart rate. *Am J Physiol* 241:H620-629, 1981
55. Seely AJ, Macklem PT: Complex systems and the technology of variability analysis. *Crit Care* 8:R367-384, 2004
56. Malik M, Camm AJ: Components of heart rate variability--what they really mean and what we really measure. *Am J Cardiol* 72:821-822, 1993
57. Kwok KL, Yung TC, Ng DK, Chan CH, Lau WF, Fu YM: Heart rate variability in childhood obstructive sleep apnea. *Pediatr Pulmonol* 46:205-210, 2011
58. Kaditis A, Kheirandish-Gozal L, Gozal D: Algorithm for the diagnosis and treatment of pediatric OSA: a proposal of two pediatric sleep centers. *Sleep Med* 13:217-227, 2012
59. Miyazaki S, Liu CY, Hayashi Y: Sleep in vertebrate and invertebrate animals, and insights into the function and evolution of sleep. *Neurosci Res* 118:3-12, 2017
60. Rechtschaffen A, Bergmann BM: Sleep deprivation in the rat: an update of the 1989 paper. *Sleep* 25:18-24, 2002

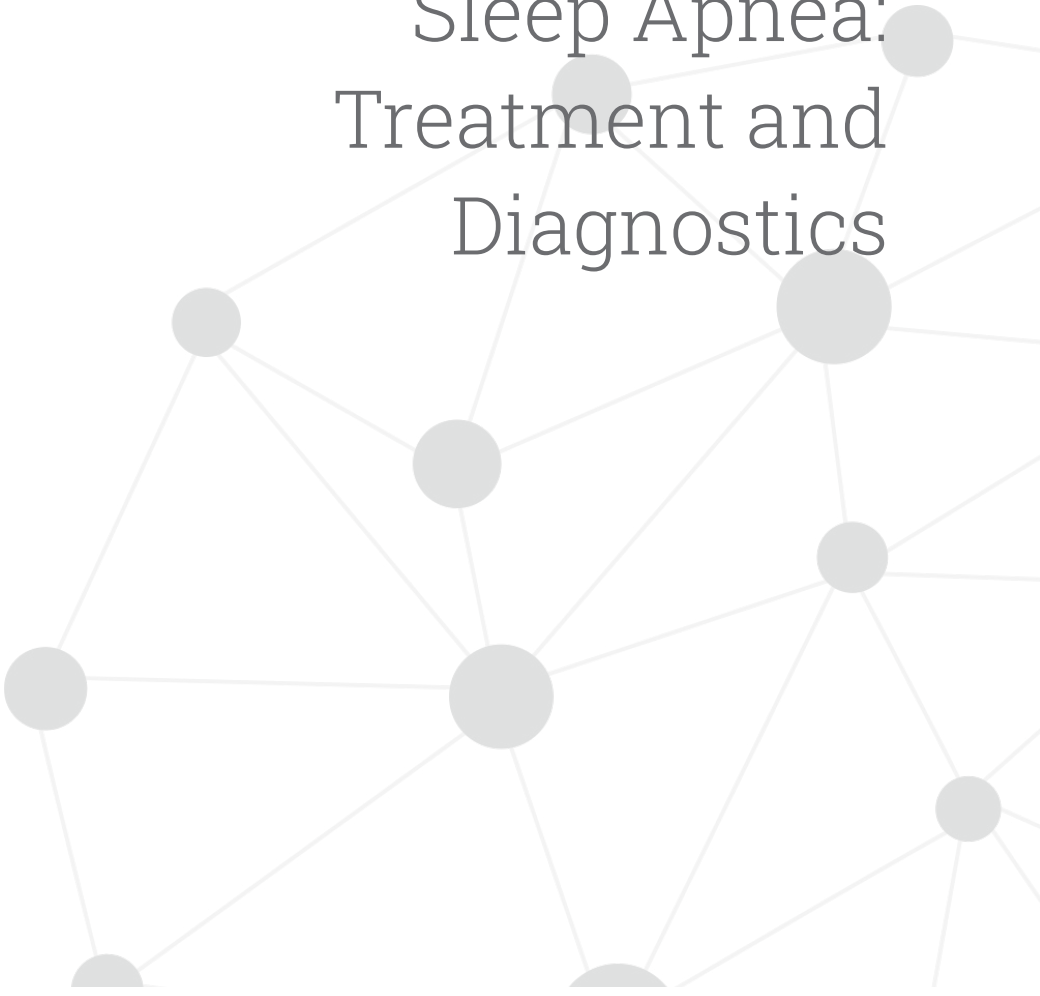61. Rechtschaffen A, Bergmann BM, Everson CA, Kushida CA, Gilliland MA: Sleep deprivation in the rat: X. Integration and discussion of the findings. *Sleep* 12:68-87, 1989
62. Malow BA: Sleep deprivation and epilepsy. *Epilepsy Curr* 4:193-195, 2004
63. Plihal W, Born J: Effects of early and late nocturnal sleep on declarative and procedural memory. *J Cogn Neurosci* 9:534-547, 1997
64. Born J, Wilhelm I: System consolidation of memory during sleep. *Psychol Res* 76:192-203, 2012
65. Xie L, Kang H, Xu Q, Chen MJ, Liao Y, Thiyagarajan M, et al: Sleep drives metabolite clearance from the adult brain. *Science* 342:373-377, 2013
66. Zager A, Andersen ML, Ruiz FS, Antunes IB, Tufik S: Effects of acute and chronic sleep loss on immune modulation of rats. *Am J Physiol Regul Integr Comp Physiol* 293:R504-509, 2007
67. Owens RL, Gold KA, Gozal D, Peppard PE, Jun JC, Dannenberg AJ, et al: Sleep and Breathing ... and Cancer? *Cancer Prev Res (Phila)* 9:821-827, 2016
68. Sankupellay M, Wilson S, Heussler HS, Parsley C, Yuill M, Dakin C: Characteristics of sleep EEG power spectra in healthy infants in the first two years of life. *Clin Neurophysiol* 122:236-243, 2011
69. Anders TF, Emde RN, Parmelee AH: A manual of standardized terminology, techniques and criteria for scoring of states of sleep and wakefulness in newborn infants: UCLA Brain Information Service/BRI Publications Office, NINDS Neurological Information Network, 1971
70. Anders TF, Keener M: Developmental course of nighttime sleep-wake patterns in full-term and premature infants during the first year of life. I. *Sleep* 8:173-192, 1985
71. Ohayon MM, Carskadon MA, Guilleminault C, Vitiello MV: Meta-analysis of quantitative sleep parameters from childhood to old age in healthy individuals: developing normative sleep values across the human lifespan. *Sleep* 27:1255-1273, 2004
72. Chervin RD, Fetterolf JL, Ruzicka DL, Thelen BJ, Burns JW: Sleep stage dynamics differ between children with and without obstructive sleep apnea. *Sleep* 32:1325-1332, 2009
73. Spruijt B, Mathijssen IM, Bredero-Boelhouwer HH, Cherian PJ, Corel LJ, van Veelen ML, et al: Sleep Architecture Linked to Airway Obstruction and Intracranial Hypertension in Children with Syndromic Craniosynostosis. *Plast Reconstr Surg* 138:1019e-1029e, 2016
74. Kheirandish-Gozal L, Bhattacharjee R, Bandla HPR, Gozal D: Antiinflammatory therapy outcomes for mild OSA in children. *Chest* 146:88-95, 2014
75. Geurtsen M, Otte R, Corel L, Mathijssen I, Joosten K: Sometimes the Power of Science is Driven by the Ratio of Love. *J Craniofac Surg* 30:e573-e574, 2019
76. Saengthong P, Chaitusaney B, Hirunwiwatkul P, Charakorn N: Adenotonsillectomy in children with syndromic craniosynostosis: a systematic review and meta-analysis. *Eur Arch Otorhinolaryngol* 276:1555-1560, 2019
77. Zandieh SO, Padwa BL, Katz ES: Adenotonsillectomy for obstructive sleep apnea in children with syndromic craniosynostosis. *Plast Reconstr Surg* 131:847-852, 2013
78. Amonoo-Kuofi K, Phillips SP, Randhawa PS, Lane R, Wyatt ME, Leighton SE: Adenotonsillectomy for sleep-disordered breathing in children with syndromic craniosynostosis. *J Craniofac Surg* 20:1978-1980, 2009
79. Taylor BA, Brace M, Hong P: Upper airway outcomes following midface distraction osteogenesis: a systematic review. *J Plast Reconstr Aesthet Surg* 67:891-899, 2014
80. Arnaud E, Di Rocco F: Faciocraniosynostosis: monobloc frontofacial osteotomy replacing the two-stage strategy? *Childs Nerv Syst* 28:1557-1564, 2012
81. Taylor JA, Bartlett SP: What's New in Syndromic Craniosynostosis Surgery? *Plast Reconstr Surg* 140:82e-93e, 2017
82. Kumar AR, Steinbacher D: Advances in the Treatment of Syndromic Midface Hypoplasia Using Monobloc and Facial Bipartition Distraction Osteogenesis. *Semin Plast Surg* 28:179-183, 2014

83. Tahiri Y, Taylor J: An Update on Midface Advancement Using Le Fort II and III Distraction Osteogenesis. *Semin Plast Surg* 28:184-192, 2014
84. Mathijssen IM: Guideline for Care of Patients With the Diagnoses of Craniosynostosis: Working Group on Craniosynostosis. *J Craniofac Surg* 26:1735-1807, 2015
85. Coeugnet E, Dhellemmes P, Vinchon M, Wolber A, Pellerin P: Midfacial distraction without osteotomy using a transfacial pin and external devices. *J Craniofac Surg* 23:184-189, 2012
86. Marucci DD, Dunaway DJ, Jones BM, Hayward RD: Raised intracranial pressure in Apert syndrome. *Plast Reconstr Surg* 122:1162-1168; discussion 1169-1170, 2008
87. Wilson MH: Monro-Kellie 2.0: The dynamic vascular and venous pathophysiological components of intracranial pressure. *J Cereb Blood Flow Metab* 36:1338-1350, 2016
88. Dunn LT: Raised intracranial pressure. *J Neurol Neurosurg Psychiatry* 73 Suppl 1:i23-27, 2002
89. Renier D, Sainte-Rose C, Marchac D, Hirsch JF: Intracranial pressure in craniostenosis. *J Neurosurg* 57:370-377, 1982
90. de Jong T, Rijken BF, Lequin MH, van Veelen ML, Mathijssen IM: Brain and ventricular volume in patients with syndromic and complex craniosynostosis. *Childs Nerv Syst* 28:137-140, 2012
91. Breakey RWF, Knoops PGM, Borghi A, Rodriguez-Florez N, O'Hara J, James G, et al: Intracranial Volume and Head Circumference in Children with Unoperated Syndromic Craniosynostosis. *Plast Reconstr Surg* 142:708e-717e, 2018
92. Driessen C, Mathijssen IM, De Groot MR, Joosten KF: Does central sleep apnea occur in children with syndromic craniosynostosis? *Respir Physiol Neurobiol* 181:321-325, 2012
93. Driessen C, Eveleens J, Bleyen I, van Veelen ML, Joosten K, Mathijssen I: Optical coherence tomography: a quantitative tool to screen for papilledema in craniosynostosis. *Childs Nerv Syst* 30:1067-1073, 2014
94. Florisson JM, Barmpalios G, Lequin M, van Veelen ML, Bannink N, Hayward RD, et al: Venous hypertension in syndromic and complex craniosynostosis: the abnormal anatomy of the jugular foramen and collaterals. *J Craniomaxillofac Surg* 43:312-318, 2015
95. Lun MP, Monuki ES, Lehtinen MK: Development and functions of the choroid plexus-cerebrospinal fluid system. *Nat Rev Neurosci* 16:445-457, 2015
96. Chan CT, Thorogood P: Pleiotropic features of syndromic craniosynostoses correlate with differential expression of fibroblast growth factor receptors 1 and 2 during human craniofacial development. *Pediatr Res* 45:46-53, 1999
97. Cinalli G, Renier D, Sebag G, Sainte-Rose C, Arnaud E, Pierre-Kahn A: Chronic tonsillar herniation in Crouzon's and Apert's syndromes: the role of premature synostosis of the lambdoid suture. *J Neurosurg* 83:575-582, 1995
98. Gonzalez S, Hayward R, Jones B, Lane R: Upper airway obstruction and raised intracranial pressure in children with craniosynostosis. *Eur Respir J* 10:367-375, 1997
99. Jennum P, Borgesen SE: Intracranial pressure and obstructive sleep apnea. *Chest* 95:279-283, 1989
100. Klingelhofer J, Hajak G, Sander D, Schulz-Varzegi M, Ruther E, Conrad B: Assessment of intracranial hemodynamics in sleep apnea syndrome. *Stroke* 23:1427-1433, 1992
101. Hajak G, Klingelhofer J, Schulz-Varzegi M, Sander D, Staedt J, Conrad B, et al: Cerebral perfusion during sleep-disordered breathing. *J Sleep Res* 4:135-144, 1995
102. Hayward R, Gonzalez S: How low can you go? Intracranial pressure, cerebral perfusion pressure, and respiratory obstruction in children with complex craniosynostosis. *J Neurosurg* 102:16-22, 2005
103. Tischfield MA, Robson CD, Gillette NM, Chim SM, Sofela FA, DeLisle MM, et al: Cerebral Vein Malformations Result from Loss of Twist1 Expression and BMP Signaling from Skull Progenitor Cells and Dura. *Dev Cell* 42:445-461 e445, 2017

104. Baltasvias G, Parthasarathi V, Aydin E, Al Schameri RA, Roth P, Valavanis A: Cranial dural arteriovenous shunts. Part 1. Anatomy and embryology of the bridging and emissary veins. *Neurosurg Rev* 38:253-263; discussion 263-254, 2015
105. Kim LK, Ahn CS, Fernandes AE: Mastoid emissary vein: anatomy and clinical relevance in plastic & reconstructive surgery. *J Plast Reconstr Aesthet Surg* 67:775-780, 2014
106. Taylor WJ, Hayward RD, Lasjaunias P, Britto JA, Thompson DN, Jones BM, et al: Enigma of raised intracranial pressure in patients with complex craniosynostosis: the role of abnormal intracranial venous drainage. *J Neurosurg* 94:377-385, 2001
107. Sainte-Rose C, LaCombe J, Pierre-Kahn A, Renier D, Hirsch JF: Intracranial venous sinus hypertension: cause or consequence of hydrocephalus in infants? *J Neurosurg* 60:727-736, 1984
108. Ghali GZ, Zaki Ghali MG, Ghali EZ, Srinivasan VM, Wagner K, Rothermel A, et al: Intracranial venous hypertension in craniosynostosis: mechanistic underpinnings and therapeutic implications. *World Neurosurg*, 2018
109. Copeland AE, Hoffman CE, Tsitouras V, Jeevan DS, Ho ES, Drake JM, et al: Clinical Significance of Venous Anomalies in Syndromic Craniosynostosis. *Plast Reconstr Surg Glob Open* 6:e1613, 2018
110. Hayward R: Venous hypertension and craniosynostosis. *Childs Nerv Syst* 21:880-888, 2005
111. Doerga P, De Goederen R, Van Ceelen MLC, Joosten KFM, Tasker RC, Mathijssen IMJ: What we know about intracranial hypertension in syndromic craniosynostosis. Yet unpublished manuscript.

PART 2

Obstructive Sleep Apnea: Treatment and Diagnostics



CHAPTER 2

Evaluation of the OSA-treatment protocol in syndromic craniosynostosis during the first six years of life

Robbin de Goederen*, Sumin Yang*, Bas Pullens, Eppo B. Wolvius, Koen F.M. Joosten, Irene M.J. Mathijssen

Submitted

* Authors contributed equally

CHAPTER 3

Improvement in Sleep Architecture is associated with the Indication of Surgery in Syndromic Craniosynostosis

Robbin de Goederen, Koen F.M. Joosten, Bianca K. den
Ottelander, Mark J.W. van der Oest, Els M.M. Bröker-
Schenk, Marie-Lise C. van Veelen, Eppo B. Wolvius, Sarah
L. Versnel, Robert C. Tasker, Irene M.J. Mathijssen

Plastic and Reconstructive Surgery Global Open, September 2019

Abstract

Background: Children with syndromic craniosynostosis (sCS) often suffer from obstructive sleep apnea (OSA) and intracranial hypertension (ICH). Both OSA and ICH might disrupt sleep architecture. However, it is unclear how surgically treating OSA or ICH affects sleep architecture. The aim of this study was twofold: to explore the usefulness of sleep architecture analysis in detecting disturbed sleep and to determine whether surgical treatment can improve it.

Methods: Eighty-three children with sCS and 35 control subjects, who had undergone a polysomnography (PSG), were included. Linear-mixed models showed the effects of OSA and ICH on sleep architecture parameters. In a subset of 19 patients, linear regression models illustrated the effects of OSA-indicated and ICH-indicated surgery on pre-to-postoperative changes.

Results: An increase in obstructive-apnea/hypopnea index (oAHI) was significantly associated with an increase in N2-sleep, arousal index, and respiratory-arousal index and a decrease in REM-sleep, N3-sleep, sleep efficiency, and sleep quality. ICH and having sCS were not related to any change in sleep architecture. OSA-indicated surgery significantly increased the total sleep time and sleep efficiency and decreased the arousal index and respiratory-arousal index. ICH-indicated surgery significantly decreased REM-sleep, N1-sleep, sleep efficiency, and sleep quality.

Conclusions: For routine detection of disturbed sleep in individual subjects, PSG-assessed sleep architecture is currently not useful. OSA does disrupt sleep architecture, but ICH does not. OSA-indicated surgery improves sleep architecture, which stresses the importance of treating OSA to assure adequate sleep. ICH-indicated surgery affects sleep architecture, although it is not clear whether this is a positive or negative effect.

Introduction

Many children with syndromic craniosynostosis (sCS) are at risk of abnormally disturbed sleep. For example, there is the problem of upper airway obstruction (UAO), potentially of multiple etiologies, caused by hypoplasia of several facial structures (1). In Apert or Crouzon syndrome, during early life, these abnormalities translate in to the problem of obstructive sleep apnea (OSA) in as many as two-thirds of the patients (2). Then, there is also the problem of intracranial hypertension (ICH), which may be a major problem on its own, or a factor that during sleep interacts with the respiratory physiology of UAO and OSA (3,4). In sCS, ICH has a number of potential causes including OSA, hydrocephalus, cerebral venous hypertension, and craniocerebral disproportion (5-7).

We have previously shown that children with sCS with no OSA or ICH have normal sleep pattern, which was determined by the presence of normal total sleep time (TST), normal number of arousals, and normal sleep architecture using electroencephalography (EEG) derived hypnograms (8). In contrast, sCS children with moderate-to-severe OSA had higher arousal index, higher respiratory effort-related arousal (RERA) index, lower sleep efficiency, less rapid-eye movement (REM) sleep, and more non-REM stage 1 (N1) sleep. ICH, on the other hand, was only related to higher RERA index; however, this was probably related to the mild OSA that those patients had. Of further interest, we found that 5 of these cases undergoing monobloc surgery showed some improvement in sleep architecture. As it was not clear whether this improvement was the result of treating the OSA, or the ICH, in this report we have extended the number of sCS children with PSG, as well as the number of pre-to-postoperative observations. The aim of this study was twofold: to evaluate the role of sleep architecture in the diagnostic work-up of children with sCS and to investigate the consequences of elective surgery for OSA and ICH on sleep architecture.

Patients and Methods

This report comes from ongoing prospective work in a national sCS cohort evaluated and managed at the Dutch Craniofacial Center (Sophia Children's Hospital – Erasmus University

Medical Center, Rotterdam, The Netherlands). As such, all clinical care follows protocolized management (9), and studies are approved by the institutional research ethics board for human studies (MEC-2005-273 and MEC-2017-1143).

The inclusion criteria for this report were: age ≤ 18 years; diagnosis of sCS; and, performance of level 1 polysomnography (PSG). Eighty-three cases were compared with 35 control subjects. The controls did not have OSA on PSG, and there was no likelihood of ICH on clinical examination. These subjects were selected from four groups of referrals: cases undergoing PSG, but otherwise well; or cases of non-syndromic unicoronal synostosis (cases without a *TCF12* mutation; *TWIST 1* mutation; or *FGFR 1, 2, or 3* mutation); or cases being investigated for brief resolved unexplained event (BRUE) (10); or cases with unexplained daytime sleepiness.

Polysomnography

All children underwent one or more video-assisted PSG (Brain RT, OSG, Rumst, Belgium). During the PSG, several cardiorespiratory parameters were assessed: electrocardiography, nasal airflow (thermistor), chest and abdominal wall motion, a capillary blood gas test, arterial blood oxygen-hemoglobin saturation using pulse oximetry (SpO_2), and transcutaneous partial pressure of carbon dioxide ($tcpCO_2$). EEG was recorded continuously and used for sleep architecture analysis. The PSG-derived variables were used in the analysis if the TST was at least 360 minutes, and free from artifacts.

Respiratory

PSG studies were assessed according to the American Academy of Sleep Medicine (AASM) 2012 updated guidance for scoring pediatric respiratory events (11). A physician first scored all respiratory events for clinical purposes. For this report, all PSGs were revalidated (RdG) and scored using the criteria we have previously published (8).

The obstructive-apnea/hypopnea index (oAHI) was calculated by dividing the sum of all obstructive apneas and hypopneas by the TST. The severity of OSA was categorized as: **Mild**, an oAHI ≥ 1 and < 5 ; **Moderate**, an oAHI ≥ 5 and < 10 ; and **Severe**, an oAHI ≥ 10 .

Sleep architecture

Hypnograms were generated using the 2012 AASM guidance on scoring (11). The EEG and chin-EEG signals were assessed in 30-second epochs according to the same criteria as in our previous work (8).

Sleep efficiency was defined as the TST divided by the total time in bed. To calculate sleep quality, the sum of the amount of REM-sleep and N3-sleep was divided by TST. Wake time After Sleep Onset (WASO) was defined as the total time (in minutes) awake between the first moment of falling asleep until the last moment waking up.

Arousals were also scored according to the criteria we previously published (8). If an arousal lasted longer than 30 s, it was considered an awakening. Since the 2012 AASM update, respiratory effort-related arousals (RERAs) are often scored as hypopnea, which may lead to an apparent reduction in RERA frequency. Therefore, in this study, a respiratory arousal was included and defined as an arousal that followed a respiratory event, such as an apnea or hypopnea. The arousal index was calculated by dividing the number of arousals by the TST. The same was true for the respiratory arousal index.

Intracranial hypertension

The presence or absence of ICH at the time of each PSG was established by using information from invasive ICP measurements, optical coherence tomography (OCT) scans, or fundoscopy.

An invasive ICP measurement was considered normal if baseline pressure during the day and night was below or equal to 10 mmHg. Baseline pressure between 10 and 15 mmHg was considered normal or borderline abnormal based on the height and duration of plateau waves. Plateau waves were considered normal if the pressure stayed below 25 mmHg, and borderline abnormal when the pressure was between 25 and 35 mmHg. Plateau waves above 35 mmHg were considered abnormal. The duration of plateau waves was considered normal if it was shorter than 10 minutes, borderline abnormal between 10 and 20 minutes, and abnormal if longer than 20 minutes. If the baseline pressure during ICP monitoring was greater than 15 mmHg, it was considered abnormal (12).

OCT imaging (Spectralis OCT scanner, Heidelberg Engineering, Heidelberg, Germany) was used to assess total retinal thickness (TRT). In our clinic, the normal range of TRT has been derived from 67 healthy 4-to-12-year-old children (*unpublished data*), and we use values above the 97.5th percentile to indicate abnormality (i.e., TRT > 503 μm).

ICH was defined as being present when one or more of the following was true: a positive funduscopy with pseudopapilledema ruled out, a positive invasive ICP measurement, or an increased TRT.

Surgical treatment

Our surgical treatment for children with sCS includes cranial vault expansion within the first year of life: occipital distraction with springs for Apert and Crouzon syndrome; and, a fronto-orbital advancement for Saethre-Chotzen and Muenke syndrome.

If a child develops OSA within the first year, the initial treatment is based on the severity of the OSA: prone positioning, oxygen support, continuous positive airway pressure (CPAP), or the insertion of a tracheal cannula. Endoscopy of the upper airway is performed to identify the levels of obstruction in cases with moderate to severe OSA. This mainly concerns patients with Apert and Crouzon syndrome. Based on the results from the endoscopy, a monobloc distraction with or without mandibular distraction is performed from 2 years of age and above. Otherwise, such surgery is delayed until the age of 7 to 9 years of age.

In complex craniosynostosis (children with multiple fused sutures, but without a known genetic mutation), the choice of treatment depends on the skull deformity and associated OSA and/or ICH. If a child develops ICH during follow-up, a subsequent cranial vault expansion is considered depending on the cause and severity, unless obvious hydrocephalus is detected for which a third ventriculostomy is performed or a ventriculoperitoneal shunt is inserted.

Statistical analysis

Statistical analysis was performed in the statistical programming language R (R Core Team, 2013, Vienna, Austria). To determine disrupted sleep architecture, we performed a linear-mixed model, and investigated the effects of OSA, ICH and the presence of sCS versus control

status. All subjects (sCS and control group) were included in the model, and all PSGs were included in the model to account for the correlation between repeated measurements over time in each patient. For each sleep architecture parameter (dependent variable) the model was adjusted to achieve the best fit. The independent variables were 'ICH', 'oAHI', 'patient vs. control', 'age' and 'gender'. Effects of the variables were checked for linearity and adjusted. Outliers were excluded from analysis. Spline interpolation was used in case of non-linearity and if it improved the fit of the model. The appropriate random-effects structure that best fitted the data was selected based on likelihood ratio tests. The appropriate fixed-effects structure was selected using F and likelihood ratio tests. Residual plots were used to validate the models' assumptions.

To evaluate the effect of surgical treatment on sleep architecture, analysis was performed in a subset of 19 patients who underwent a PSG preoperatively and postoperatively. The different types of surgery performed were categorized based on their indication, i.e., correction of OSA (oAHI ≥ 5 , moderate-to-severe OSA) and/or ICH. Surgeries for OSA included adenotonsillectomy, nasal septum corrections and mandibular distraction osteotomy. Surgery performed for OSA when the preoperative oAHI was below 5, was not considered as OSA-indicated. Surgeries for ICH included all calvarial expansions. Monobloc surgery can be indicated for OSA, or ICH, or both. Cranial vault surgery carried out as part of the standard protocol, but in a patient without signs of ICH, was not scored as being an ICH-indicated procedure.

In the pre-to-postoperative group, change in scores (delta-scores) in sleep architecture parameters were calculated. Then the linear regression models with the delta-scores as dependent variables were created. The independent variables were age at the time of surgery, whether the indication of surgery was OSA or not, and if the indication of surgery was ICH or not. Afterwards, we performed a post-hoc power analysis for the linear regression models; a power of 0.80 and above was considered sufficient.

Results

Patients

Eighty-three patients (43 males, 51.8%) with sCS underwent PSG and were screened for ICH (**Table 1**). Forty-nine patients underwent only one PSG, 21 patients two PSGs, eight patients three PSGs, three patients four PSGs, and two patients five PSGs.

Effects of OSA and ICH on sleep architecture

Scatterplots of all sleep architecture parameters of children with sCS and OSA or ICH against a locally estimated scatterplot smoothing (LOESS) curve of control subjects and children with sCS without OSA or ICH are presented in **Figure 1**. **Table 2** shows the effects of oAHI, the presence of ICH, and having a sCS on sleep architecture parameters. A one-point increase in oAHI was associated with an increase in both the arousal index and the respiratory arousal index, with 0.13 ($p<0.001$) and 0.15 ($p<0.001$) events/hour, respectively. Every point increase in oAHI was also associated with a decrease in sleep quality of -0.28% ($p=0.010$), decrease in sleep efficiency of -0.19% ($p=0.038$), and decrease in the amount of N3-sleep of -0.21% ($p=0.039$). In addition, in regard to the amount of N2-sleep, every point increase in oAHI was associated with increase in amount of N2-sleep 0.25% ($p=0.004$). After the exclusion of outliers, the presence of ICH was not associated with any change in sleep architecture. However, in two very young infants with multiple bone defects due to hydrocephalus, the wake time after sleep onset (WASO) was greatly increased at 479.5 and 471.0 minutes. Having sCS was not associated with any changes in sleep architecture.

	Total population sCS		Pre-to-postoperative population sCS		Control population	
	n=83		n=19		n=35	
Age at first (or pre-op) PSG, yr (median, IQR)	3.08	(0.58 – 8.89)	2.06	0.56 – 5.00	4.41	(1.49 – 7.82)
Age post-op PSG yr (median, IQR)	-	-	3.64	1.93 – 5.99	-	-
Age at surgery yr (median, IQR)	-	-	2.90	0.87 – 5.15	-	-
Male (n, %)	43	51.8%	13	68.4%	15	42.9%
ICH (n, %)	25*	30.1%	8 [†]	42.1%	0	0%
OSA (n, %)						
No	48*	57.8%	4 [†]	21.1%	35	100%
Mild	18*	21.7%	9 [†]	47.4%	0	0%
Moderate	7*	8.4%	3 [†]	15.8%	0	0%
Severe	10*	12.0%	3 [†]	15.8%	0	0%
Diagnoses (n, %)						
Apert	20	24.1%	8	42.1%	-	-
Crouzon	31	37.3%	8	42.1%	-	-
Muenke	9	10.8%	1	5.3%	-	-
Saethre-Chotzen	10	12.0%	1	5.3%	-	-
TCF12	2	2.4%	0	0%	-	-
IL11RA	1	1.2%	0	0%	-	-
Complex craniosynostosis	10	12.0%	1	5.3%	-	-
ICH-indicated surgery (n, %)	-	-	4	21.1%	-	-
OSA-indicated surgery (n, %)	-	-	2	10.5%	-	-
Both ICH-indicated and OSA-indicated surgery (n, %)	-	-	4	21.1%	-	-
No ICH-indicated nor OSA-indicated surgery (n, %)	-	-	9	47.4%	-	-

Table 1: Patient characteristics of the total group of children with craniosynostosis (sCS), the subgroup of children with sCS with preoperative and postoperative measurements, and the healthy control population. ICH=intracranial hypertension, OSA = obstructive sleep apnea.

*Maximum OSA stage measured in one of the polysomnographies, and ICH scored if present during one of the PSGs (this table only).

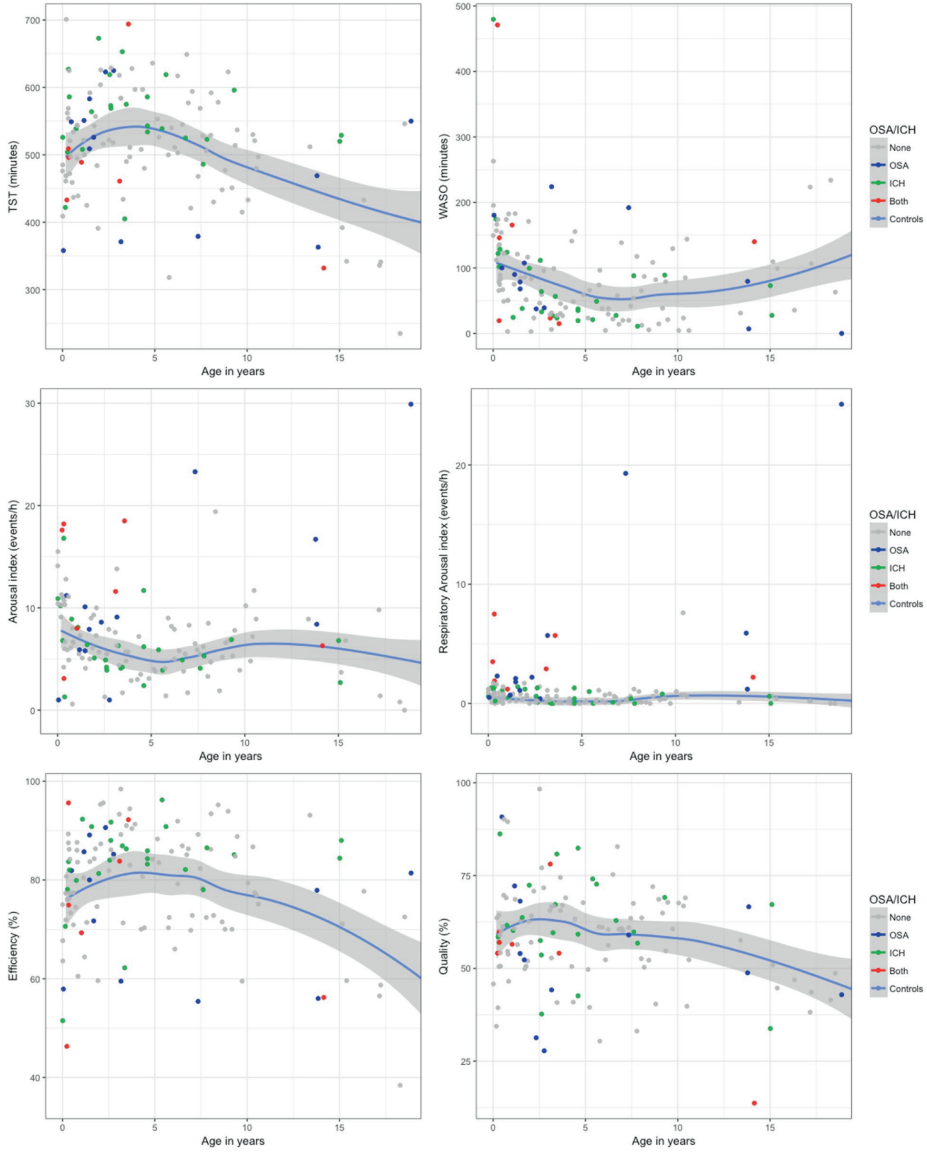
[†]OSA stage or presence of ICH at the time of the first PSG.

Effect of surgery on sleep architecture

A subset of 19 patients underwent PSG before and after surgery. The characteristics of this subset of patients are presented in **Table 1**. The median interval between the preoperative PSG and surgery was 0.20 years (IQR: 0.13 – 0.54), the median interval between the surgery and the postoperative PSG was 0.74 years (IQR: 0.31 – 1.04), and the median interval between the preoperative and postoperative PSG was 1.10 years (IQR: 0.69 – 1.45). Scatterplots of all pre-to-postoperative changes in sleep architecture parameters of this subgroup of children with sCS against a LOESS curve of control subjects and children with sCS without OSA or ICH are presented in **Figure 2**. The results of the linear regression models of the delta-scores of the different sleep architecture parameters are presented in **Table 3**. The results show that surgery with an OSA indication is associated with decrease in the arousal index (-6.89 , $p=0.030$) and the respiratory arousal index (-5.49 , $p=0.013$). OSA-indicated surgery was also associated with increase in TST of 96.26 minutes ($p=0.025$), and with increase in sleep efficiency of 13.55% ($p=0.017$). Surgery with an ICH indication was associated with decrease in sleep efficiency of -15.37% ($p=0.006$) and with decrease in sleep quality of -11.27% ($p=0.032$). The latter being explained by significant decrease in the amount of REM-sleep of -11.23% ($p=0.001$) and by an increase in the amount of N1-sleep of 12.36% ($p=0.034$).

	Mean	Regression coefficient		p-value
TST (min)	513.6	oAHI	-0.91	0.108
		ICH	8.15	0.780
		Patient vs. control	0.13	0.993
Arousal (events/h)	6.86	oAHI	0.13	<0.001*
		ICH	-0.87	0.625
		Patient vs. control	0.69	0.362
Resp. Arousal (events/h)	0.96	oAHI	0.15	<0.001*
		ICH	-0.71	0.466
		Patient vs. control	0.34	0.405
WASO (min)	82.97	oAHI	0.61	0.219
		ICH	14.94	0.608
		Patient vs. control	-0.12	0.991
Efficiency (%)	78.47	oAHI	-0.19	0.038*
		ICH	-6.97	0.157
		Patient vs. control	3.17	0.114
Quality (%)	59.1	oAHI	-0.28	0.010*
		ICH	4.14	0.501
		Patient vs. control	-2.33	0.335
REM (%)	21.59	oAHI	-0.11	0.036*
		ICH	-3.37	0.266
		Patient vs. control	0.20	0.865
N1 (%)	13.41	oAHI	0.05	0.412
		ICH	6.50	0.067
		Patient vs. control	-0.10	0.946
N2 (%)	27.06	oAHI	0.25	0.004*
		ICH	-6.38	0.170
		Patient vs. control	1.19	0.541
N3 (%)	38.54	oAHI	-0.21	0.039*
		ICH	0.32	0.951
		Patient vs. control	-1.58	0.493

Table 2: OSA and ICH in relation to sleep architecture. Linear-mixed model of 118 subjects with a total of 177 measurements of sleep architecture using polysomnography, of which 83 subjects with 138 measurements are children with syndromic craniosynostosis (sCS) and 35 healthy control subjects with 39 measurements. The effect of the obstructive-apnea/hypopnea index (oAHI), intracranial hypertension (ICH) and the effect of having a sCS compared to being a control subject is being presented. Data are corrected for gender and age at the time of the polysomnography. TST = Total Sleep Time, WASO = Wake time After Sleep Onset, REM = rapid eye movement sleep, N1 = non-REM stage 1 sleep, N2 = non-REM stage 2 sleep, N3 = non-REM stage 3 sleep or deep sleep.



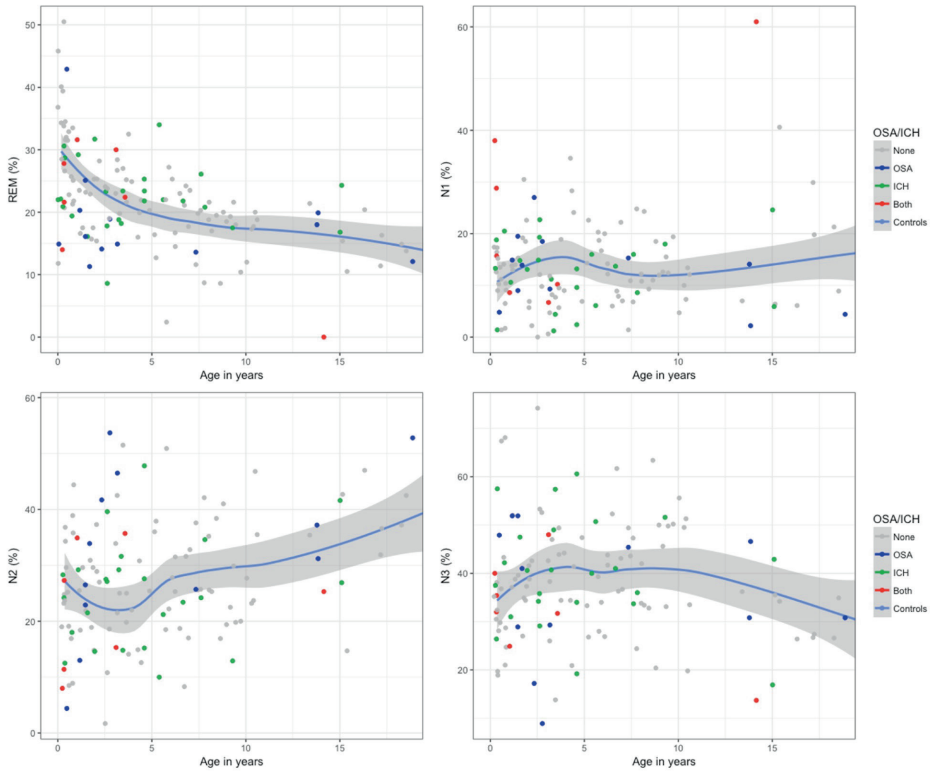
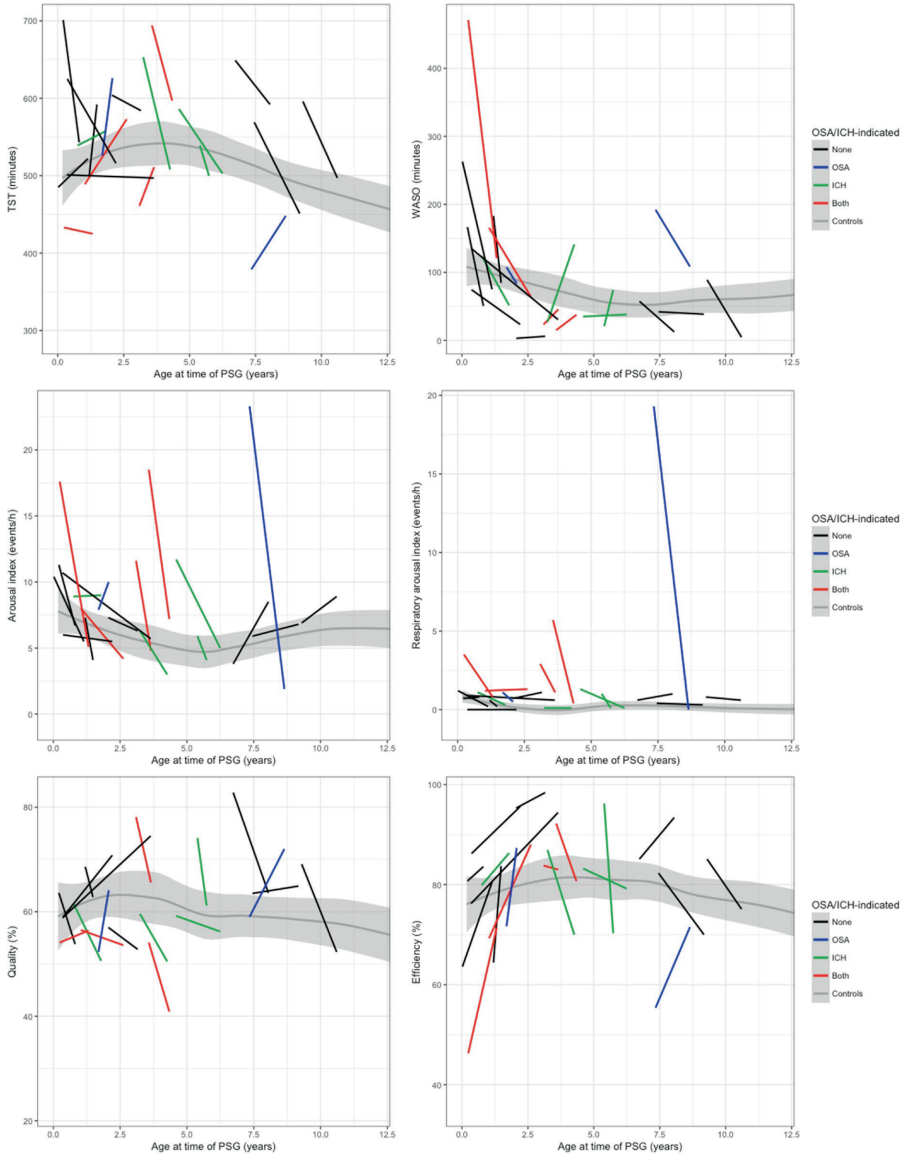


Figure 1: Scatterplots of sleep architecture parameters of the total population of children with syndromic craniosynostosis (sCS) against a locally estimated scatterplot smoothing (LOESS) curve and its standard error of 99 polysomnographies of control subjects and children with sCS with an obstructive-apnea/hypopnea index (oAHI) <1 and without intracranial hypertension (ICH). TST = Total Sleep Time, WASO = Wake time After Sleep Onset, REM = rapid eye movement sleep, N1 = N-stage 1 sleep, N2 = N-stage 2 sleep, N3 = N-stage 3 sleep or deep sleep, OSA = obstructive sleep apnea.



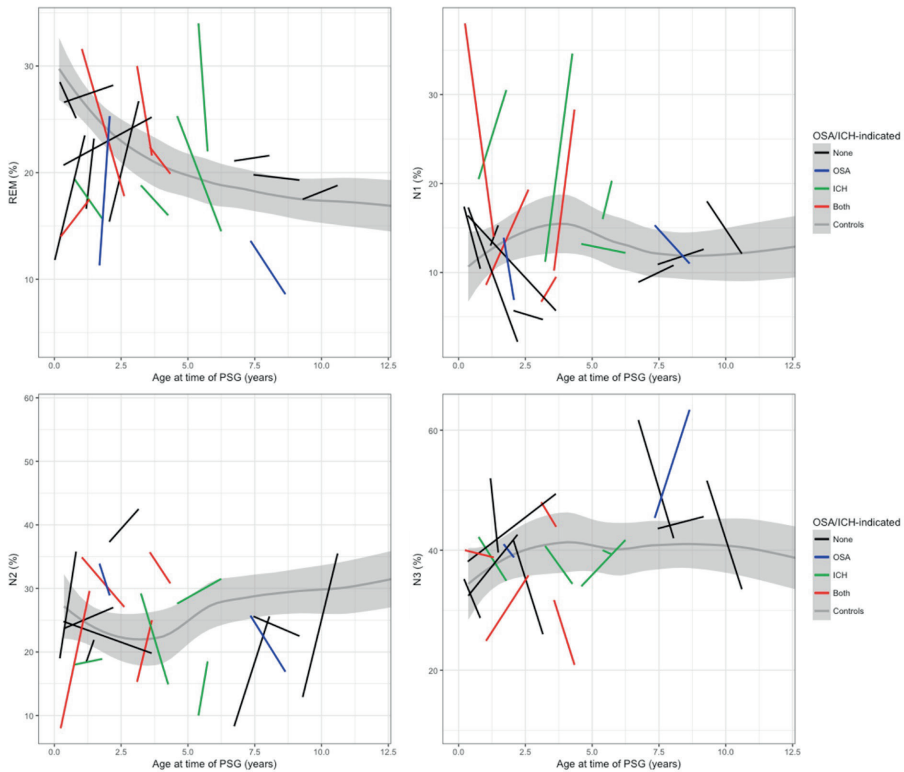


Figure 2: Scatterplots of all pre-to-postoperative changes in sleep architecture parameters of the subgroup of 19 children with syndromic craniosynostosis (sCS) with a preoperative and postoperative polysomnography, against a locally estimated scatterplot smoothing (LOESS) curve and its standard error of 99 polysomnographies of control subjects and children with sCS with an obstructive-apnea/hypopnea index (oAHI) <1 and without intracranial hypertension (ICH). Every line represents one subject; the left end of the line represents the preoperative measurement, the right end the postoperative one. The color of the line represents the type of surgery the subject has undergone. TST = Total Sleep Time, WASO = Wake time After Sleep Onset, REM = rapid eye movement sleep, N1 = N-stage 1 sleep, N2 = N-stage 2 sleep, N3 = N-stage 3 sleep or deep sleep.

	Median Pre-op (IQR) n=19	Median Post-op (IQR) n=19	Surgical indication	Regression coefficient	R ²	p- value	Post-hoc power
TST (min)	539.0 (494.5 – 614.5)	509.5 (500.8 – 569.0)	OSA ICH	96.26 -39.07	0.35	0.025* 0.303	0.85
Arousal (events/h)	8.0 (6.6 – 11.5)	4.9 (4.1 – 6.7)	OSA ICH	-6.89 -0.79	0.32	0.030* 0.776	0.80
Resp. Arousal (events/h)	1.0 (0.7 – 1.3)	0.4 (0.1 – 0.7)	OSA ICH	-5.49 1.70	0.42	0.013* 0.371	0.93
WASO (min)	89.0 (31.0 – 166.0)	69.0 (47.0 – 102.2)	OSA ICH	-55.86 60.99	0.26	0.277 0.212	0.68
Efficiency (%)	82.3 (70.5 – 85.7)	80.0 (71.4 – 85.5)	OSA ICH	13.55 -15.37	0.63	0.017* 0.006*	0.99
Quality (%)	59.4 (57.5 – 67.4)	56.3 (51.4 – 63.4)	OSA ICH	7.80 -11.27	0.38	0.137 0.032*	0.89
REM (%)	19.8 (16.0 – 26.0)	17.7 (15.8 – 21.2)	OSA ICH	1.24 -11.23	0.55	0.690 0.001*	0.99
N1 (%)	13.6 (10.4 – 17.1)	16.7 (11.3 – 26.3)	OSA ICH	-4.25 12.36	0.31	0.453 0.034*	0.78
N2 (%)	24.3 (16.0 – 28.8)	26.1 (18.6 – 29.4)	OSA ICH	-3.58 -1.09	0.05	0.570 0.856	0.16
N3 (%)	40.9 (35.9 – 45.0)	38.8 (35.1 – 41.1)	OSA ICH	6.19 -0.58	0.10	0.320 0.921	0.27

Table 3: Effect of OSA-indicated and ICH-indicated surgery on changes in sleep architecture. Linear regression models of the delta-scores of sleep architecture parameters. The effect of surgical treatment, based on its indication for obstructive sleep apnea (OSA) and/or intracranial hypertension (ICH), corrected for age at the time of surgery. TST = Total Sleep Time, WASO = Wake time After Sleep Onset, REM = rapid eye movement sleep, N1 = non-REM stage 1 sleep, N2 = non-REM stage 2 sleep, N3 = non-REM stage 3 sleep or deep sleep.

Discussion

In this study of pediatric patients with sCS we have three main observations. First, OSA does, and ICH does not, affect sleep architecture. Second, surgery for moderate-to-severe OSA improves sleep architecture. Third, surgery for ICH affects sleep architecture in a way that is different to the way it is after OSA-indicated surgery. Taken together, we have extended our previously-reported preliminary observations (8) in sCS, and now affirm that in our practice, sleep architecture analysis is used as valuable information in the assessment of children with sCS.

The scatterplots in **Figure 1** show that sleep architecture parameters vary greatly between subjects, both with and without sCS. Hence, it was difficult to establish certain cut-off values for normal or abnormal sleep architecture. We found that OSA on its own had a disruptive effect on sleep architecture, which is generally similar to findings in other reports (13-15). In addition, a few studies show that surgical treatment does not improve sleep architecture (16-19), but this literature contrasted with our finding that there was a small improvement with surgical treatment for OSA in patients with sCS. This finding is supported by an increase in sleep efficiency and TST, and a decrease in the number of arousals and respiratory arousals. However, there was no improvement in the percentage of REM-sleep or in sleep quality in the linear regression model.

Not much is known about the effect of ICH on sleep architecture. Our findings suggest that sCS children with ICH have normal sleep architecture. However, based on our own clinical experience, parents of children with ICH do report that their child sleeps more restlessly than other children. It is possible that this effect is too subtle or irregular to detect using only a single night PSG. However, we did find a disturbed sleeping pattern in two young infants with pronounced hydrocephalus. We cannot be sure if the increased pressure is related to the disturbed sleeping pattern, but it remains an interesting topic of research. In the present study, we found that cranial vault surgery for ICH did have an effect on sleep architecture. In the pre-to-postoperative analysis, ICH-indicated surgery decreased sleep efficiency, sleep quality and the percentage of REM-sleep, while increasing the percentage of N1-sleep. The plots of **Figure 2** show that in all but one subject who underwent ICH-indicated surgery there was a decrease in the amount of REM-sleep.

The pathophysiological processes underlying our findings are unknown. In a study of 28 adults with normal-pressure hydrocephalus, wakefulness and cerebral blood flow (CBF) were investigated before and after ventricular shunting (20). Postoperatively, patient wakefulness increased and CBF increased in the hippocampal regions. Spruijt et al. (21) showed that in 12 sCS children with ICH and abnormal CBF-indices – as shown by transcranial Doppler with increased peak systolic velocities and higher resistance indices – that cranial vault surgery normalized these parameters, suggesting a change in CBF in children with ICH. In the present study, if we assume that there is a similar change in CBF (we did not measure it), then this change might be the cause of changes in REM-sleep and N1-sleep, sleep quality and sleep efficiency. Further multimodal monitoring research is needed to determine whether the changes in sleep efficiency and quality are beneficial or not and if they are permanent or temporary. Nevertheless, we still consider surgical treatment for ICH in sCS an essential part of the treatment protocol.

Our study does have three main limitations. The first limitation is the small sample size. Since sCS is a very rare condition, and because we only started PSG in this population in 2012, it is a challenge to quickly increase the number of patients. Between our preliminary report in 2016 (8) and now, we have added 14 patients (almost threefold increase) to the pre-to-postoperative analysis, and 44 patients to the total population (more than doubled). The small sample size also means that only large changes in sleep architecture parameters are detected, and we may have missed subtle changes in sleep architecture parameters we did not have enough power for in the pre-to-postoperative analysis (i.e. WASO, N1, N2, and N3). Nonetheless, we are able to draw some conclusions and insights into the effects of surgery on sleep architecture in children sCS. Second, it was not possible to deal with any first night effects in the PSG findings because we did not have the capacity to perform studies on two or three consecutive nights. However, as all patients were exposed to the first night effect, it was still possible to compare measurements between subjects. Third, we have a pragmatic method for defining ICH. The gold standard approach is to diagnose ICH using invasive ICP measurements. We consider this method too invasive in this population – the risks of invasive monitoring outweigh the benefits of making the diagnosis invasively rather than noninvasively – and so we

use OCT, fundoscopy, magnetic resonance imaging, and the head circumference for our diagnosis. Although not as accurate as an invasive measurement, we think that our methodology is sensitive enough to establish the presence of ICH.

In children with sCS, PSG-assessed sleep architecture adds valuable information in the diagnostic work-up of OSA. For example, it allows for the detection of arousals, assessment of sleep quality and sleep efficiency, and is useful to more adequately calculate the TST. The results of this study show that OSA disrupts sleep architecture but ICH does not. Surgery for OSA improves sleep architecture, stressing the importance of treating OSA to assure adequate sleep. Surgery for ICH affects sleep architecture, although it is still not clear whether this is a positive or negative effect.

References

1. Doerga PN, Spruijt B, Mathijssen IM, Wolvius EB, Joosten KF, van der Schroeff MP: Upper airway endoscopy to optimize obstructive sleep apnea treatment in Apert and Crouzon syndromes. *J Craniomaxillofac Surg* 44:191-196, 2016
2. Driessen C, Joosten KF, Bannink N, Bredero-Boelhouwer HH, Hoeve HL, Wolvius EB, et al: How does obstructive sleep apnoea evolve in syndromic craniosynostosis? A prospective cohort study. *Arch Dis Child* 98:538-543, 2013
3. Hayward R, Gonsalez S: How low can you go? Intracranial pressure, cerebral perfusion pressure, and respiratory obstruction in children with complex craniosynostosis. *J Neurosurg* 102:16-22, 2005
4. de Jong T, Bannink N, Bredero-Boelhouwer HH, van Veelen ML, Bartels MC, Hoeve LJ, et al: Long-term functional outcome in 167 patients with syndromic craniosynostosis; defining a syndrome-specific risk profile. *J Plast Reconstr Aesthet Surg* 63:1635-1641, 2010
5. Rijken BF, den Ottelander BK, van Veelen ML, Lequin MH, Mathijssen IM: The occipitofrontal circumference: reliable prediction of the intracranial volume in children with syndromic and complex craniosynostosis. *Neurosurg Focus* 38:E9, 2015
6. Florisson JM, Barmpalios G, Lequin M, van Veelen ML, Bannink N, Hayward RD, et al: Venous hypertension in syndromic and complex craniosynostosis: the abnormal anatomy of the jugular foramen and collaterals. *J Craniomaxillofac Surg* 43:312-318, 2015
7. Thompson DN, Jones BM, Harkness W, Gonsalez S, Hayward RD: Consequences of cranial vault expansion surgery for craniosynostosis. *Pediatr Neurosurg* 26:296-303, 1997
8. Spruijt B, Mathijssen IM, Bredero-Boelhouwer HH, Cherian PJ, Corel LJ, van Veelen ML, et al: Sleep Architecture Linked to Airway Obstruction and Intracranial Hypertension in Children with Syndromic Craniosynostosis. *Plast Reconstr Surg* 138:1019e-1029e, 2016
9. Mathijssen IM: Guideline for Care of Patients With the Diagnoses of Craniosynostosis: Working Group on Craniosynostosis. *J Craniofac Surg* 26:1735-1807, 2015
10. Tieder JS, Bonkowsky JL, Etzel RA, Franklin WH, Gremse DA, Herman B, et al: Brief Resolved Unexplained Events (Formerly Apparent Life-Threatening Events) and Evaluation of Lower-Risk Infants. *Pediatrics* 137, 2016
11. Berry RB, Budhiraja R, Gottlieb DJ, Gozal D, Iber C, Kapur VK, et al: Rules for scoring respiratory events in sleep: update of the 2007 AASM Manual for the Scoring of Sleep and Associated Events. Deliberations of the Sleep Apnea Definitions Task Force of the American Academy of Sleep Medicine. *J Clin Sleep Med* 8:597-619, 2012
12. Tamburrini G, Caldarelli M, Massimi L, Santini P, Di Rocco C: Intracranial pressure monitoring in children with single suture and complex craniosynostosis: a review. *Childs Nerv Syst* 21:913-921, 2005
13. Goh DY, Galster P, Marcus CL: Sleep architecture and respiratory disturbances in children with obstructive sleep apnea. *Am J Respir Crit Care Med* 162:682-686, 2000
14. Chervin RD, Fetterolf JL, Ruzicka DL, Thelen BJ, Burns JW: Sleep stage dynamics differ between children with and without obstructive sleep apnea. *Sleep* 32:1325-1332, 2009
15. Choi JH, Kim EJ, Choi J, Kwon SY, Kim TH, Lee SH, et al: Obstructive sleep apnea syndrome: a child is not just a small adult. *Ann Otol Rhinol Laryngol* 119:656-661, 2010
16. Lee CH, Hsu WC, Chang WH, Lin MT, Kang KT: Polysomnographic findings after adenotonsillectomy for obstructive sleep apnoea in obese and non-obese children: a systematic review and meta-analysis. *Clin Otolaryngol* 41:498-510, 2016
17. Frank Y, Kravath RE, Pollak CP, Weitzman ED: Obstructive sleep apnea and its therapy: clinical and polysomnographic manifestations. *Pediatrics* 71:737-742, 1983

18. Marcus CL, Carroll JL, Koerner CB, Hamer A, Lutz J, Loughlin GM: Determinants of growth in children with the obstructive sleep apnea syndrome. *J Pediatr* 125:556-562, 1994
19. Liu SY, Huon LK, Ruoff C, Riley RW, Strohl KP, Peng Z: Restoration of Sleep Architecture after Maxillomandibular Advancement: Success Beyond the Apnea-Hypopnea Index. *Int J Oral Maxillofac Surg* 46:1533-1538, 2017
20. Tullberg M, Hellstrom P, Piechnik SK, Starmark JE, Wikkelso C: Impaired wakefulness is associated with reduced anterior cingulate CBF in patients with normal pressure hydrocephalus. *Acta Neurol Scand* 110:322-330, 2004
21. Spruijt B, Tasker RC, Driessen C, Lequin MH, van Veelen ML, Mathijssen IM, et al: Abnormal transcranial Doppler cerebral blood flow velocity and blood pressure profiles in children with syndromic craniosynostosis and papilledema. *J Craniomaxillofac Surg* 44:465-470, 2016

CHAPTER 4

Electrocardiographic variables in children with syndromic craniosynostosis and primary snoring to mild obstructive sleep apnea: significance of identifying respiratory arrhythmia during sleep

Ellaha Kakar, Linda J.A. Corel, Robert C. Tasker,
Robbin de Goederen, Eppo B. Wolvius, Irene
M.J. Mathijssen, Koen F.M. Joosten

Sleep Medicine, 2018

Abstract

Background In the spectrum of children with symptomatic sleep disordered breathing (SDB), some individuals – such as those with upper airway resistance syndrome (UARS) – do not have abnormalities on polysomnography (PSG). In this study we have assessed whether assessment of respiratory arrhythmia (RA) and heart rate variability (HRV) analysis helps in management of children with syndromic craniosynostosis and none-to-mild obstructive sleep apnea (OSA).

Methods Prospective cohort study in children aged 1 – 18 years old with syndromic craniosynostosis. Children were selected for HRV analysis from the ECG if their obstructive apnea-hypopnea index (oAHI) was between zero and five per hour (i.e., oAHI \leq 5/hour). Subjects were divided into groups based on the presence or absence of respiratory arrhythmia (with or without RA respectively) using the electrocardiogram (ECG). The main analysis included studying the relationship between RA and HRV, symptoms, interventions, and sleep architecture.

Results We identified 42 patients with, at worst, mild OSA. We found higher parasympathetic control and higher total power in children with RA during the non-rapid eye movement (non-REM) sleep. Children with RA also have a relatively higher percentage of paradoxical breathing during non-REM sleep ($p = 0.042$). Intracranial hypertension was distributed equally between groups. Last, RA patients showed increased parasympathetic activity that further increased in non-REM sleep.

Conclusion In syndromic craniosynostosis cases with SDB and PSG showing oAHI \leq 5/hour, the presence of RA may indicate subsequent need for treatment interventions, and a trend toward higher occurrence of clinical symptoms. ECG analyses of HRV variables in subjects with RA demonstrate increased parasympathetic activity and total power. Such findings may add to the diagnosis of apparently asymptomatic children.

Introduction

Craniosynostosis is a congenital disorder characterized by premature fusion of skull sutures which can be part of a syndrome such as Apert, Crouzon, Muenke or Saethre-Chotzen syndrome (1). Two-thirds of these children have sleep disordered breathing (SDB), particularly obstructive sleep apnea (OSA) (2). In such children OSA is mainly caused by a combination of anatomical abnormalities of the upper airway at the level of the tongue base and palate, as well as decreased pharyngeal muscular tone during sleep. Symptoms include sleep-associated apnea, snoring, frequent awakenings, sweating, enuresis, and daytime sleepiness. Notably, apnea and oxygen-hemoglobin desaturations on pulse oximetry (SpO_2) induce tonic activation of chemoreflex activity, and an increase in sympathetic nerve activity, which causes sympathetic predominance (3-7). During the daytime, there may be headaches, behavioral changes, and daytime tiredness, which can lead to physical, functional, and social impairment (8).

Within the spectrum of sleep-disordered breathing (SDB) in children with craniosynostosis severe OSA necessitates treatment, whereas the consequences of mild OSA are less clear. Moderate forms of SDB, like the upper airway resistance syndrome (UARS) (9), are considered when there are symptoms of OSA, yet no abnormality on polysomnography (PSG). These children suffer from a partially obstructed upper airway, but recognizable obstructive events or abnormal respiratory gas exchange is not observed (10). Common symptoms are snoring, increased respiratory effort, and frequent arousals. Together, these problems may cause tiredness during the day and excessive sleepiness. Given that UARS is more common than OSA (10,11), the use of OSA indicators to assess severity may underestimate UARS in children (9,11,12).

Since there is a need for refining the clinical evaluation in cases of craniosynostosis with milder forms of SDB, we reasoned that an indirect, non-invasive approach to diagnosis using changes in respiratory arrhythmia (RA) and changes in the heart rate variability (HRV) may be of value. RA shows the absolute difference in heart rate above or below baseline heart rate. HRV describes the variations between consecutive heartbeats and is decreased in patients with OSA (13-16). Currently, HRV is only used as a warning sign for myocardial infarction and diabetic neuropathy, but it can be used to assess autonomic balance (17-19), which may be important in

understanding the pathophysiology of SDB (14,20-24). As a secondary outcome, we assessed interventions and intracranial hypertension in this sample. We hypothesize that children with RA are more likely to undergo interventions and acquire intracranial hypertension.

Methods

Patients

The Ethics Committee of the Erasmus Medical Center (MEC-2005-273) approved this human subjects study of *post hoc* analysis of data collected from a prospective, observational cohort (enrollment period March 2012 to March 2016) at the Dutch Craniofacial Center (Sophia Children's Hospital – Erasmus University Medical Center, Rotterdam, The Netherlands). We included children aged between 1 and 18 years with syndromic (i.e., Apert, Crouzon, Muenke, Saethre-Chotzen syndromes, based on genetic analysis), or complex craniosynostosis (defined as multiple suture synostoses in which no genetic cause is found yet), or unicoronal craniosynostosis.

Polysomnography

All patients had undergone overnight, in-hospital, level 1 PSG that included assessment of the following cardiorespiratory and neurophysiologic variables: nasal airflow (thermistor), chest, and abdominal wall motion, SpO₂, transcutaneous partial pressure of carbon dioxide, and electrocardiogram (ECG). PSG data were analyzed using Shell+ BrainRT Software (Suite Version 2.0; O.S.G. Rumst, Belgium), using ECG frequency of 250Hz for sampling. A study was considered suitable for analysis if it provided a total sleep time (TST) of at least 360 minutes, free of artifact. Respiratory events were scored using the *American Academy of Sleep Medicine* (AASM) criteria (25).

An *obstructive event* was defined as a reduction in nasal airflow of $\geq 90\%$ (apnea) or 30-90% (hypopnea), for at least two breaths, in the presence of thoracic and abdominal breathing movement. Hypopnea was only included in the analysis if it was associated with a subsequent SpO₂-desaturation of at least 3% from baseline, or with an arousal. Central apnea/hypopnea meets the same criteria as the above *obstructive event* definition, but without the presence of

thoracic and abdominal breathing movement. A mixed apnea had to meet the central apnea criteria and be associated with absence, in one part, and presence, in the other part, of thoracic and abdominal breathing movement. The oxygen desaturation index (ODI) was assessed by dividing the total number of SpO₂ desaturations by the TST in hours (25). A respiratory effort related arousal (RERA) was defined as the sequence of breaths lasting at least 10 s which did not meet criteria for an apnea or hypopnea and was characterized by increasing respiratory effort leading to an arousal from sleep. Sleep quality (i.e., sum of rapid eye movement [REM] sleep and slow wave sleep [SWS or N3] divided by the TST) and sleep efficiency (i.e., TST divided by the time in bed [TIB]) were also evaluated. EEG is performed to score the sleep stage (25,26). In the current report, children were selected for HRV analysis from the ECG if their obstructive apnea-hypopnea index (oAHI) was between zero and five per hour (i.e., oAHI \leq 5/hour).

Paradoxical breathing is present when the child's thoracic and abdominal movements are not synchronous. It is considered a sensitive indicator for increased airway resistance (27). Even though it may be normal physiology, the percentage of paradoxical breathing is higher in children with breathing problems. Respiration was assessed as paradoxical if the lowest peak of the chest motion was synchronous with the highest peak of the abdominal motion, and *vice versa*. The percentage of paradoxical breathing was calculated using the duration of paradoxical breathing divided by the TST, and multiplied by 100.

Respiratory arrhythmia (RA) was defined as an absolute difference in heart rate of more than 10 beats per minute change above or below baseline heart rate.

Outcome variables

Clinical evaluations comprised of the five symptoms assessed from patient records, divided into two main groups; breathing and sleep abnormalities, at the time of PSG. These were assessed as followed: breathing abnormalities; snoring, audible breathing, and oral breathing, and sleep abnormalities; restless sleep and tiredness. Subjects were categorized as having symptoms if at least one of the above was present, no difference was made in the total number of symptoms with which the child was presenting. Any intervention, or treatment, in relation to timing of OSA and PSG was also recorded. These interventions included surgical interventions

(i.e., adenotonsillectomy, midface advancement [monobloc, facial bipartition, or Le Fort III] mandibular advancement, nasal septum correction, and maxillary widening), and non-surgical interventions (i.e., nasal corticosteroid spray) (28). We also assessed whether these children suffered from intracranial hypertension. In our protocol (29-33), all patients were routinely screened for the presence of symptoms/signs related to possible intracranial hypertension, including: downward deflection of the occipital-frontal head circumference growth trajectory; and, papilledema diagnosed by a pediatric ophthalmologist with a funduscopic examination or optical coherence tomography (OCT). In some cases, invasive intracranial pressure (ICP) monitoring was carried out. The determination of “intracranial hypertension” used in the current report was based on assessments made near the time of the PSG (\pm 3 months) and follow-up at one year after PSG (\pm 3 months).

Assessment of HRV

HRV was determined by measuring the RR-interval of the ECG-signal using Kubios HRV software (Biosignal Analysis and Medical Imaging Group (BSAMIG), Department of Applied Physics, University of Eastern Finland, Kuopio, FINLAND) (17) HRV variables were analyzed using the time and frequency domains, as well as by using non-linear analysis (**Table 1**). For the frequency domain analysis, the frequency bands were set as followed: LF; 0.04–0.15 Hz, and HF (0.15–0.4 Hz).

In order to analyze the HRV data, we divided the PSG dataset into two minute epochs, that were artifact-free during both REM and non-REM (NREM) sleep stages (16). This approach allowed evaluation of persistent changes in HRV after respiratory events, without other events potentially influencing heart rate (13,17,34-36). Artifacts were defined as respiratory events (i.e., apnea, hypopnea, arousals, SpO₂ desaturation \geq 3%), sighs, and movements during sleep.

Analysis	Variable	Definition
Time domain analysis	SDNN	The standard deviation (SD) of the normal-to-normal [NN] intervals, i.e., all intervals between adjacent QRS complexes resulting from sinus node depolarization. The SDNN reflects both short and long term variation within the RR interval series, and is an estimate of overall HRV
	RMSSD	The square root of the mean squared differences of successive NN intervals, which is a measure of short-term variability
	RRti	HRV triangular index which is the integral of the density distribution divided by the maximum of the density distribution, and is an estimate of overall HRV
Frequency domain analysis	LF	Low frequency components, which are mainly from sympathetic origin, but may also arise from parasympathetic activity
	HF	High frequency components (arising from respiratory sinus arrhythmia [RSA] and breathing), which are of parasympathetic origin
	LF/HF ratio	The ratio of low-to-high frequency power components, which reflects autonomic balance
	TP	Total power, a measure of the total power of all frequency components
Non-linear analysis ^a	SD1	SD1 is the dispersion (standard deviation) of points <i>perpendicular</i> to the axis of line-of-identity and gives a measure of short-term variability
	SD2	SD2 is the dispersion (standard deviation) of points <i>along</i> the axis of line-of identity and gives a measure of long-term variability

Table 1: HRV measures Non-linear analysis (Poincare plot): the Poincare HRV plot is a graph in which each RR interval (X-axis) is plotted against the next RR interval (Y-axis) as a type of “delay map”

Statistical analysis

Non-parametric statistical methods were used based on the small sample size in each group and the not normally distribution of the RA-groups. Occurrence of symptoms was compared to the occurrence of RA. Variables were subsequently compared between groups, using either a chi-square test (expected value above five) or fisher’s exact test (expected value below five). The Mann Whitney U test was used for comparing continuous variables between two categorical variables. Variables with a p -value <0.05 was considered statistically significant. Results are presented as median (range) or median (interquartile range [IQR]). Power calculation was not feasible without prior information. Hence, in the exploratory analyses of the impact of RA and HRV variables we describe sensitivity, specificity, likelihood ratio of a positive result (LR+), and changes from pre- to post-test probability of the outcome of interest.

Results

We identified 42 craniosynostosis patients with $\text{oAHI} \leq 5/\text{hour}$ (30 cases with $\text{oAHI} < 1/\text{hour}$; and, 12 cases with $\text{oAHI} \geq 1/\text{hour}$). Their diagnoses were: Apert ($n=5$), Crouzon ($n=14$), Muenke ($n=2$), Saethre-Chotzen ($n=4$), complex craniosynostosis ($n=9$), and unicoronal synostosis ($n=8$). The mean age at time of PSG was 6.8 years (range: 1.0 – 18.0 years) and 45% (19/42) of cases were male.

RA, clinical evaluation, and interventions

On comparing those with and without RA, we found that RA was present in 22/42 patients, and those with and without this phenomenon were similar in age (6.4 [IQR, 3.5-9.3] versus 5.5 [1.7-10.5] years, $p = 0.80$), and had similar baseline respiratory rate (17.0 [15.0-21.0] versus 18.0 [16.0-21.5] breaths/minute, $p = 0.21$), see **Table 2**.

Overall 31/42 (74% pre-test probability) had one or more symptoms. 86.4%(19/22) of the RA+ group had one or more symptoms compared with 60% (12/20) of the RA- group ($p = 0.052$), see **Table 3**. On exploratory analysis, when considering the presence of RA as a “diagnostic test” of presence of one or more symptoms we found with a sensitivity of 0.61, a specificity of 0.73, and a LR+ of 2.26, that the post-test probability of one or more symptoms was 86.4%. In regard to interventions, 21/42 (50% pre-test probability) underwent one or more interventions. 54.5% (12/22) of the RA+ group underwent one or more interventions, compared with 45.0% (9/20) of the RA- group ($p = 0.54$), see Table 4. On exploratory analysis, when considering the presence of RA as a “diagnostic test” of subsequent interventions we found with a sensitivity of 0.57, a specificity of 0.48 and a LR+ of 1.1, that the post-test probability of subsequent intervention was 52,3%. Furthermore, the occurrence of intracranial hypertension in the RA+ and RA- groups, at the time of the PSG (18% vs. 15%) and one year later (0.0% vs. 0.0%), was no different ($p = 0.56$ and 0.52, respectively) (see **Table 5**).

Variable	With RA (mean (IQR))	Without RA (median (IQR))	p-value
Age (years)	6.4 (3.5-9.3)	5.5 (1.7-10.5)	0.80
Respiratory rate (/min)	17.0 (15.0-21.0)	18.0 (16.0-21.5)	0.21
Mean heart rate (/min)	81.5 (73.7-90.3)	83.9 (72.0-106.2)	0.47
ODI (events/h)	1.8 (0.6-5.4)	1.4 (0.9-2.7)	0.49
Sleep quality (%)	47.3 (39.0-53.1)	44.9 (36.0-51.7)	0.45
Sleep efficiency (%)	85.4 (77.7-91.6)	79.2 (68.3-86.3)	0.09
Arousal index	0.0 (0.0-1.2)	0.0 (0.0-4.2)	0.46
Awakenings (n)	6.5 (4.0-9.8)	8.0 (5.5-16.5)	0.12
RERA/TST (n)	5.5 (1.8-8.5)	6.5 (2.3-10.8)	0.40
Paradoxical breathing (%)	14.5 (6.5-33.8)	11.0 (3.3-19.3)	0.26
Paradoxical breathing, NREM (%)	12.5 (4.8-25.8)	2.0 (0.0-14.8)	0.042
Paradoxical breathing, REM (%)	26.0 (8.0-35.0)	30.5 (0.3-48.5)	0.31

Table 2: Demographics. RA, respiratory arrhythmia; ODI, oxygen desaturation index; RERA; respiratory effort related arousal, IQR; interquartile range

Symptom assessment	With RA (n=22)	Without RA (n=20)	Symptoms	With RA (n=22)	Without RA (n=20)
Breathing abnormalities (%)	86.4 (19/22)	55.0 (11/20)	Snoring (%)	68.1 (15/22)	45.0 (9/20)
			Audible breathing (%)	54.5 (12/22)	20.0 (4/20)
			Oral breathing (%)	22.7 (5/22)	0.0 (0/20)
Sleep abnormalities (%)	45.5 (10/22)	35.0 (7/20)	Restless sleep (%)	45.5 (10/22)	30.0 (6/20)
Symptoms total (%)	86.4 (19/22)	60.0 (12/20)	Tiredness (%)	27.3 (6/22)	25.0 (5/20)

Table 1: Symptom assessment. RA, respiratory arrhythmia; n, group size

*Intervention	With RA (n=22)	Without RA (n=20)	<i>p</i> -value (chi-square)
Surgical (%)	40.9 (9/22)	35.0 (7/20)	
Non-surgical (%)	22.7 (5/22)	20.0 (4/20)	
Total (%)	54.5 (12/22)	45.0 (9/20)	0.54

Table 4: Intervention assessment. RA, respiratory arrhythmia; n, group size

*One child can be scored more than once, because of a combination treatment of surgical and non-surgical interventions

Variable	With RA	Without RA	<i>p</i> -value (Fisher's exact)
IH at time of PSG (%)	18	15	0.56
IH 1 year post PSG (%)	0.05	0	0.52

Table 5: Intracranial hypertension occurrence at time of PSG and 1 year post PSG. RA, respiratory arrhythmia; IH, intracranial hypertension; PSG, polysomnography

HRV analysis

In the HRV analysis (using time domain and non-linear analysis variables), there were significantly higher values for a range of variables during both NREM and REM sleep (**Tables 6 and 7**). In the frequency domain, high frequency (HF) was significantly higher and the low-to-high frequency ratio (LF/HF) was significantly lower in the RA+ group, during both sleep states. Moreover, in the frequency domain, the total power of the frequency bands during the NREM sleep was significantly higher in the RA+ group (4970.0 vs. 1334.0, $p = 0.011$) (**Table 6**). A higher percentage of paradoxical breathing during NREM sleep was found in the RA+ group, compared with the RA- group (19.0% versus 9.2%, $p = 0.042$) (see **Table 2**). There was no difference in sleep characteristics between both groups (see **Table 2**).

Variable	With RA (median (IQR))	Without RA (median (IQR))	<i>p</i> -value
SDNN	73.8 (45.3-94.0)	37.75 (23.8-62.4)	0.013
RMSSD	87.6 (45.7-120.0)	44.3 (25.2-74.3)	0.017
RRti	19.1 (11.9-26.4)	9.8 (5.9-17.3)	0.00
SD1	62.2 (32.5-85.1)	31.4 (18.0-52.8)	0.02
SD2	106.8 (75.8-135.1)	69.7 (56.5-112.6)	0.09
LF	915.5 (343.0-1831.5)	490.5 (213.5-1294.5)	0.18
HF	3680.0 (1196.8-6475.8)	793.5 (281.5-2492.5)	0.00
LF/HF ratio	0.3 (0.2-0.3)	0.6 (0.4-1.1)	0.00
TP	4970.0 (1763.5-8488.0)	1334.0 (493.3-3916.5)	0.011

Table 6: HRV variables in the time domain, non-linear, and frequency domain analyses during NREM sleep. RA, respiratory arrhythmia; SDNN, standard deviation of the normal to normal intervals; RMSSD, square root of the mean squared differences of successive NN intervals; RRti, HRV triangular index; LF, low frequency; HF, high frequency, IQR; interquartile range, TP; total power

Variable	With RA (median (IQR))	Without RA (median (IQR))	<i>p</i> -value
SDNN	55.0 (34.9-80.2)	40.0 (24.2-50.4)	0.039
RMSSD	62.5 (39.1-104.5)	41.5 (22.1-55.3)	0.023
RRti	12.1 (8.4-17.8)	7.9 (5.1-12.1)	0.045
SD1	44.5 (27.8-74.3)	29.6 (15.7-39.4)	0.025
SD2	98.0 (66.6-129.4)	72.1 (50.9-105.5)	0.096
LF	903.0 (407.8-1616.5)	564.0 (246.5-996.8)	0.212
HF	1675.5 (668.3-4297.3)	600.0 (180.5-1377.3)	0.019
LF/HF ratio	0.5 (0.3-0.6)	0.9 (0.6-1.3)	0.002
TP	2977.5 (1052.8-6443.3)	1211.0 (478.5-2428.5)	0.060

Table 7: HRV variables in the time domain, non-linear, and frequency domain analyses during REM sleep. RA, respiratory arrhythmia; SDNN, standard deviation of the normal to normal intervals; RMSSD, square root of the mean squared differences of successive NN intervals; RRti, HRV triangular index; LF, low frequency; HF, high frequency, IQR; interquartile range, TP; total power

Discussion

In this pilot study of children with syndromic craniosynostosis and primary snoring to mild OSA (oAHI \leq 5/hour) we made two significant observations. First, in about one-half of the patients in our practice, RA was evident in the PSG test. Second, the presence of RA+ in non-to-mild OSA may be indicative of higher parasympathetic activity, particularly during NREM sleep. Taken together, these data provide important insight into the pathophysiology of SDB during NREM sleep in patients with syndromic craniosynostosis.

We also found that children with RA had a trend toward more clinical symptoms. Remarkably, we did not find any differences in sleep architecture, as we have reported in more severe cases of SDB in craniosynostosis (2,8,37). It could be argued that symptoms were not severe enough to alter sleep architecture. Additionally, we did not find a difference in rate of finding IH. However, on closer inspection of HRV we did make some key observations.

In the analyses of different HRV variables we found that the RA+ group had higher HF and a lower LF/HF ratio, which means that there was increased parasympathetic activity compared to the RA- group. This finding makes sense since the HF power is driven by the parasympathetic activity, which in turn is associated with respiratory activity. This physiology may account for overriding or possible limitation in increased sympathetic activity associated with OSA (38,39). Comparing this finding to previous studies of children who actually have OSA, a higher level of sympathetic activity is the usual finding. Liao et al. (14) compared children with none-or-mild SDB with children with moderate-or-worse SDB and found that the more severe cases exhibited impaired HRV with excess sympathetic and weaker parasympathetic activity. Muzumdar et al. (13) showed increased sympathetic activity in children with OSA before adenotonsillectomy; after adenotonsillectomy there was an improvement in SDB and the level of sympathetic activity decreased. The most important difference between these studies and our current report is that study participants were children without a chronic condition, and our subjects all had syndromic craniosynostosis. However, we have not excluded the possibility that our subjects had some explanation for impairment of cardiac autonomic modulation as part of their underlying syndrome.

During two different states (NREM versus REM) we found that NREM disclosed a further shift to parasympathetic activity in the RA+ group. Liao et al. (16) reported a shift in cardiac autonomic modulation across sleep stages in children without SDB: a shift towards parasympathetic control from wake-to-NREM sleep, and a shift towards sympathetic control on entering REM sleep. Moreover, in cases of mild SDB, there was a similar pattern across sleep stages (16). Therefore, similarly to our study, there is less parasympathetic control during REM sleep. Furthermore, we found that total power is significantly higher in children with RA during NREM sleep; implying that this group has to put significantly more effort in maintaining hemodynamic stability during NREM sleep. Additionally, in children with RA we have identified a higher percentage of paradoxical breathing during NREM sleep. We speculate that this finding may, therefore, be caused by relatively higher parasympathetic activity in NREM sleep. A possible explanation for the fact that the RA+ group had increased parasympathetic activity compared to the RA- group might be that the severity and the duration of the RA+ group may not yet be sufficient enough to impact autonomic modulation in the RA+ group (16). This may therefore be a predictive finding for OSA in the clinical evaluation.

Another explanation can be found in the normal physiology of healthy subjects (40). Intense or acute activation of the autonomic nervous system in combination with acute changes in blood pressure lead to higher risk for arrhythmias and SDB (40-42). This is caused by changes in impulse generation and oxygen metabolism of the heart or in the baroreflex function (40,42). Therefore, RA might be caused by the interactions in the sympathetic and parasympathetic system. Adrenergic stimulation will increase automaticity of Purkinje fibers and when the vagal nerve is activated on a background of enhanced automaticity sinus rate is reduced.(40) A question remains, however; whether changes in sympathetic and parasympathetic activity in the RA+ group are related to changes in blood pressure in different sleep stages or to a difference in autonomic modulation, which might be specifically different in these children.

Our study had several limitations. First, in an ideal physiological assessment we should compare HRV analyses with esophageal pressure monitoring, so as to quantify airway flow-limitation (43). This technique is too invasive for our clinical subjects and protocol (43). Therefore, we are unable to identify cases of UARS (i.e., moderate SDB with symptoms of OSA and no

abnormality on PSG). However, we have used the oAHI index as a biomarker of severity in airflow limitation and identified a subgroup in which interventions for OSA are more likely – that may be likened to UARS, albeit with the circuitous definition of those with RA. Second, we did not carry out systematic assessment of patient symptoms, but rather used the report of clinical symptoms recorded in the clinical notes. Third, our study group encompasses a wide age range (1 – 18 years) and, as such, we may have missed some relationship between symptom severity and significance, and the evolution of airway development. Fourth, we did not compare our data with a control group but rather studied graded-severity within a subset of cases with craniosynostosis. A control group might have given us reference values for the HRV variables. Finally, due to the small sample size we were obligated to use non-parametric statistical testing which is less reliable to detect a real effect.

In conclusion, in patients with syndromic craniosynostosis, SDB and PSG showing oAHI ≤ 5 /hour, the presence of RA may indicate a trend toward higher occurrence of clinical symptoms. Furthermore, analysis of HRV variables in subjects with RA demonstrates an increase in parasympathetic activity that changes more during NREM sleep. Therefore, ECG analyses for RA and HRV variables may be a potentially useful aid in the present diagnostic work-up of apparently asymptomatic children with syndromic craniosynostosis screened for SDB.

References

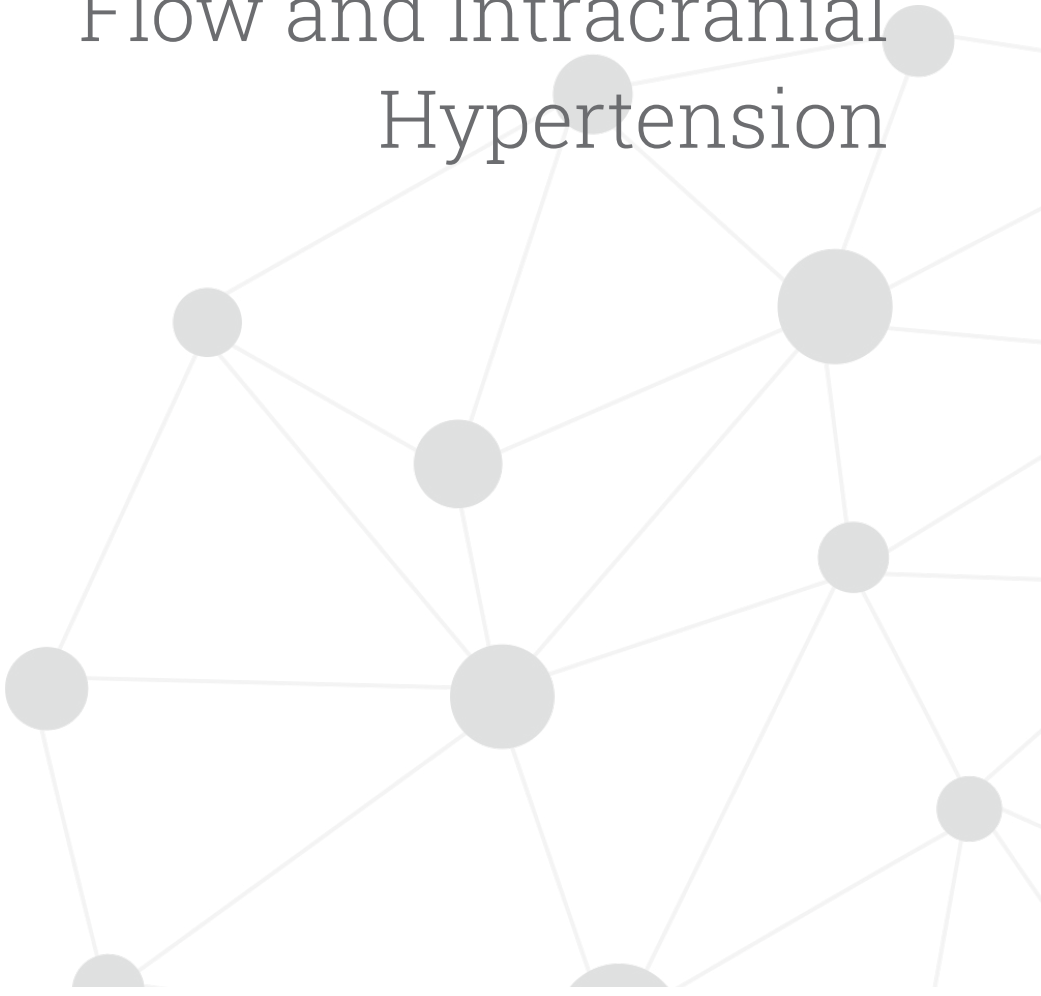
1. Sharma VP, Fenwick AL, Brockop MS, McGowan SJ, Goos JA, Hoogeboom AJ, et al: Mutations in TCF12, encoding a basic helix-loop-helix partner of TWIST1, are a frequent cause of coronal craniosynostosis. *Nat Genet* 45:304-307, 2013
2. Driessen C, Joosten KF, Bannink N, Bredero-Boelhouwer HH, Hoeve HL, Wolvius EB, et al: How does obstructive sleep apnoea evolve in syndromic craniosynostosis? A prospective cohort study. *Arch Dis Child* 98:538-543, 2013
3. Waradekar NV, Sinoway LI, Zwillich CW, Leuenberger UA: Influence of treatment on muscle sympathetic nerve activity in sleep apnea. *Am J Respir Crit Care Med* 153:1333-1338, 1996
4. Somers VK, Dyken ME, Mark AL, Abboud FM: Sympathetic-nerve activity during sleep in normal subjects. *N Engl J Med* 328:303-307, 1993
5. Somers VK, Dyken ME, Clary MP, Abboud FM: Sympathetic neural mechanisms in obstructive sleep apnea. *J Clin Invest* 96:1897-1904, 1995
6. Narkiewicz K, Somers VK: Sympathetic nerve activity in obstructive sleep apnoea. *Acta Physiol Scand* 177:385-390, 2003
7. Lavie L: Obstructive sleep apnoea syndrome--an oxidative stress disorder. *Sleep Med Rev* 7:35-51, 2003
8. Bannink N, Mathijssen IM, Joosten KF: Can parents predict obstructive sleep apnea in children with syndromic or complex craniosynostosis? *Int J Oral Maxillofac Surg* 39:421-423, 2010
9. Guillemainault C, Stoohs R, Clerk A, Cetel M, Maistros P: A cause of excessive daytime sleepiness. The upper airway resistance syndrome. *Chest* 104:781-787, 1993
10. Kaditis A, Kheirandish-Gozal L, Gozal D: Algorithm for the diagnosis and treatment of pediatric OSA: a proposal of two pediatric sleep centers. *Sleep Med* 13:217-227, 2012
11. Guillemainault C, Winkle R, Korobkin R, Simmons B: Children and nocturnal snoring: evaluation of the effects of sleep related respiratory resistive load and daytime functioning. *Eur J Pediatr* 139:165-171, 1982
12. Pepin JL, Guillot M, Tamisier R, Levy P: The upper airway resistance syndrome. *Respiration* 83:559-566, 2012
13. Muzumdar HV, Sin S, Nikova M, Gates G, Kim D, Arens R: Changes in heart rate variability after adenotonsillectomy in children with obstructive sleep apnea. *Chest* 139:1050-1059, 2011
14. Liao D, Li X, Rodriguez-Colon SM, Liu J, Vgontzas AN, Calhoun S, et al: Sleep-disordered breathing and cardiac autonomic modulation in children. *Sleep Med* 11:484-488, 2010
15. Kwok KL, Yung TC, Ng DK, Chan CH, Lau WF, Fu YM: Heart rate variability in childhood obstructive sleep apnea. *Pediatr Pulmonol* 46:205-210, 2011
16. Liao D, Li X, Vgontzas AN, Liu J, Rodriguez-Colon S, Calhoun S, et al: Sleep-disordered breathing in children is associated with impairment of sleep stage-specific shift of cardiac autonomic modulation. *J Sleep Res* 19:358-365, 2010
17. Tarvainen MP, Niskanen JP, Lipponen JA, Ranta-Aho PO, Karjalainen PA: Kubios HRV--heart rate variability analysis software. *Comput Methods Programs Biomed* 113:210-220, 2014
18. Van Eyck A, Van Hoorenbeeck K, De Winter BY, Van Gaal L, De Backer W, Verhulst SL: Sleep disordered breathing and autonomic function in overweight and obese children and adolescents. *ERJ Open Res* 2, 2016
19. Dehkordi P, Garde A, Karlen W, Petersen CL, Wensley D, Dumont GA, et al: Evaluation of cardiac modulation in children in response to apnea/hypopnea using the Phone Oximeter(). *Physiol Meas* 37:187-202, 2016
20. Montesano M, Miano S, Paolino MC, Massolo AC, Ianniello F, Forlani M, et al: Autonomic cardiovascular tests in children with obstructive sleep apnea syndrome. *Sleep* 33:1349-1355, 2010

21. Vlahandonis A, Yiallourou SR, Sands SA, Nixon GM, Davey MJ, Walter LM, et al: Long-term changes in heart rate variability in elementary school-aged children with sleep-disordered breathing. *Sleep Med* 15:76-82, 2014
22. Nisbet LC, Yiallourou SR, Walter LM, Horne RS: Blood pressure regulation, autonomic control and sleep disordered breathing in children. *Sleep Med Rev* 18:179-189, 2014
23. Gil E, Vergara JM, Bianchi AM, Laguna P: Obstructive sleep apnea syndrome analysis in children by decreases in the amplitude fluctuations of pulse photoplethysmography: role of recording duration and heart rate variability. *Conf Proc IEEE Eng Med Biol Soc* 2007:6090-6093, 2007
24. Deng ZD, Poon CS, Arzeno NM, Katz ES: Heart rate variability in pediatric obstructive sleep apnea. *Conf Proc IEEE Eng Med Biol Soc* 1:3565-3568, 2006
25. Berry RB, Budhiraja R, Gottlieb DJ, Gozal D, Iber C, Kapur VK, et al: Rules for scoring respiratory events in sleep: update of the 2007 AASM Manual for the Scoring of Sleep and Associated Events. Deliberations of the Sleep Apnea Definitions Task Force of the American Academy of Sleep Medicine. *J Clin Sleep Med* 8:597-619, 2012
26. Verhulst SL, Schrauwen N, Haentjens D, Van Gaal L, De Backer WA, Desager KN: Reference values for sleep-related respiratory variables in asymptomatic European children and adolescents. *Pediatr Pulmonol* 42:159-167, 2007
27. Standards and indications for cardiopulmonary sleep studies in children. American Thoracic Society. *Am J Respir Crit Care Med* 153:866-878, 1996
28. Teo DT, Mitchell RB: Systematic review of effects of adenotonsillectomy on cardiovascular parameters in children with obstructive sleep apnea. *Otolaryngol Head Neck Surg* 148:21-28, 2013
29. Napp J, Mathejczyk JE, Alves F: Optical imaging in vivo with a focus on paediatric disease: technical progress, current preclinical and clinical applications and future perspectives. *Pediatr Radiol* 41:161-175, 2011
30. Driessen C, Eveleens J, Bleyen I, van Veelen ML, Joosten K, Mathijssen I: Optical coherence tomography: a quantitative tool to screen for papilledema in craniosynostosis. *Childs Nerv Syst* 30:1067-1073, 2014
31. El-Dairi MA, Asrani SG, Enyedi LB, Freedman SF: Optical coherence tomography in the eyes of normal children. *Arch Ophthalmol* 127:50-58, 2009
32. Lee KM, Woo SJ, Hwang JM: Differentiation of optic nerve head drusen and optic disc edema with spectral-domain optical coherence tomography. *Ophthalmology* 118:971-977, 2011
33. Vartin CV, Nguyen AM, Balmitgere T, Bernard M, Tilikete C, Vighetto A: Detection of mild papilloedema using spectral domain optical coherence tomography. *Br J Ophthalmol* 96:375-379, 2012
34. Stein PK, Pu Y: Heart rate variability, sleep and sleep disorders. *Sleep Med Rev* 16:47-66, 2012
35. Heart rate variability. Standards of measurement, physiological interpretation, and clinical use. Task Force of the European Society of Cardiology and the North American Society of Pacing and Electrophysiology. *Eur Heart J* 17:354-381, 1996
36. Wang YP, Kuo TB, Li JY, Lai CT, Yang CC: The relationships between heart rate deceleration capacity and spectral indices of heart rate variability during different breathing frequencies. *Eur J Appl Physiol* 116:1281-1287, 2016
37. Goroza E, Sagy M, Sagy N, Bock K: Severity assessment of obstructive sleep apnea syndrome (OSAS) in pediatric patients. *Clin Pediatr (Phila)* 48:528-533, 2009
38. Widdicombe J: Reflexes from the lungs and airways: historical perspective. *J Appl Physiol* (1985) 101:628-634, 2006
39. Yu J: An overview of vagal airway receptors. *Sheng Li Xue Bao* 54:451-459, 2002
40. Verrier RL, Muller JE, Hobson JA: Sleep, dreams, and sudden death: the case for sleep as an autonomic stress test for the heart. *Cardiovasc Res* 31:181-211, 1996

41. Shusterman V, Troy WC, Abdelmessih M, Hoffman S, Nemej J, Strollo PJ, et al: Nighttime instabilities of neurophysiological, cardiovascular, and respiratory activity: integrative modeling and preliminary results. *J Electrocardiol* 48:1010-1016, 2015
42. Walter LM, Yiallourou SR, Vlahandonis A, Sands SA, Johnson CA, Nixon GM, et al: Impaired blood pressure control in children with obstructive sleep apnea. *Sleep Med* 14:858-866, 2013
43. Baydur A, Behrakis PK, Zin WA, Jaeger M, Milic-Emili J: A simple method for assessing the validity of the esophageal balloon technique. *Am Rev Respir Dis* 126:788-791, 1982

PART 3

Cerebral Venous Flow and Intracranial Hypertension



CHAPTER 5.1

Pilot Study of Intracranial Venous Physiology in Craniosynostosis

Martijn J. Cornelissen, Robbin de Goederen, Priya Doerga, Iris E. Cuperus, Marie-Lise C. van Veelen, Maarten Lequin, Paul Govaert, Irene M.J. Mathijssen, Jeroen Dudink, Robert C. Tasker

Journal of Neurosurgery: Pediatrics, 2018

Abstract

Objective In addition to craniocerebral disproportion, other factors such as Chiari malformation type I, obstructive sleep apnea, and venous outflow obstruction, are considered to have a role in the occurrence of intracranial hypertension in craniosynostosis. This pilot study examined cerebral venous flow velocity in order to better characterize the complex intracranial venous physiology of craniosynostosis.

Methods The authors performed a prospective cohort study of craniosynostosis patients ($n = 34$) referred to a single national (tertiary) craniofacial unit. Controls ($n = 28$) consisted of children who were referred to the unit's outpatient clinic did not have craniosynostosis. Transfontanelle ultrasound scans with venous Doppler flow velocity assessment were performed at the first outpatient clinic visit and after each surgery, if applicable. Mean venous blood flow velocities of the internal cerebral vein (ICV_v) and the superior sagittal sinus (SSS_v) were recorded and blood flow waveform was scored.

Results Preoperatively, SSS_v was decreased in craniosynostosis patients compared with controls (7.57 vs 11.31 cm/sec, $p = 0.009$). ICV_v did not differ significantly between patients and controls. Postoperatively, SSS_v increased significantly (7.99 vs 10.66 cm/sec, $p = 0.023$). Blood flow waveform analyses did not differ significantly between patients and controls.

Conclusions Premature closure of cranial sutures was associated with decreased SSS_v but not ICV_v; indicating an effect on the superficial rather than deep venous drainage. Further Doppler ultrasound studies are needed to test the hypothesis that at an early stage of craniosynostosis pathology SSS_v, but not pulsatility, is abnormal, and that abnormality in both SSS_v and the superficial venous waveform reflect more advanced stage of evolution in suture closure.

Introduction

Craniosynostosis occurs in approximately 1 in 1500 births and results in abnormal shape of the cranium and increased risk of intracranial hypertension (ICHT) (1). In published series, the prevalence of ICHT ranges 1 to 85%, and it is particularly high in the syndromic cases of craniosynostosis (2-5). Historically, the development of ICHT in craniosynostosis was attributed solely to skull growth restriction (i.e., craniocerebral disproportion) (6). Now, however, the accumulated evidence suggests that other factors may also be relevant (7-11), including: cranial vault venous outflow obstruction, ventriculomegaly (or hydrocephalus if progressive), tonsillar herniation or presence of Chiari malformation type I, and obstructive sleep apnea (OSA). These pathophysiological features are rarely seen in single-suture craniosynostosis patients, and so we have to conclude that they are unlikely to account for the development of ICHT in such patients. In our previous work we have recognized a discrepancy in the rate of ICHT by suture involvement that is not readily explained by any of the mechanisms outlined above. For example, in cases of metopic suture synostosis, the rate of ICHT is low (1%-2%), irrespective of relatively small intracranial volume after surgery (5,12). The opposite is true in sagittal suture synostosis patients; that is, despite a relatively larger intracranial volume, ICHT is found in 6-10% of patients (13,14).

In this context, clinical researchers have focused on cerebral venous drainage in craniosynostosis, albeit with few definitive studies. We know that there is an interaction between superior sagittal sinus (SSS) pressure (P_{SSS}) and intracranial pressure (ICP). For example, as early as 1984, Sainte-Rose et al. suggested that a rise in P_{SSS} due to obstruction resulted in a rise in ICP (11). We also know that the mean blood flow velocity of the SSS (SSS_v), measured using Doppler ultrasound in single-suture cases of craniosynostosis, differs from the norm (15). Last, we know that cranial venous drainage is different in craniosynostosis patients (8,10). Taking all of the above evidence together, we conclude that abnormality in cerebral venous dynamics is an important physiological feature of single-suture craniosynostosis. However, understanding the interaction between cerebral venous blood flow, cerebrospinal fluid (CSF) drainage and ICP also requires consideration of anatomy. For example, the superficial venous drainage system, as reflected in the SSS, drains blood from the lateral aspects of the anterior portion of the cerebral hemispheres and collects CSF from the arachnoid granulations. The intracerebral vein (ICV) is a

component of the deep venous drainage system, and on each side of the brain it takes blood from the choroid plexus and thalamic and caudate nuclei. Therefore, in the current pilot investigation we have used Doppler ultrasound to examine cerebral venous flow velocity in the superficial and deep cerebral venous drainage systems to better characterize the complex intracranial venous physiology of craniosynostosis. Comparing both venous drainage systems enables us to examine the effect of craniosynostosis on the deep and superficial venous drainage system and, therefore, to evaluate the effect of corrective surgery on venous drainage and to identify possible targets to prevent ICHT.

Methods

This study was approved by our institution's medical ethical committee. Informed consent was obtained from all participants. Participants with syndromic and nonsyndromic craniosynostosis were recruited from craniosynostosis patients presenting to the Dutch craniofacial center in 2016. The healthy control group was also recruited at our center and comprised patients referred for nonsynostotic occipital plagiocephaly, metopic ridging, or nonsyndromic cleft lip.

Patient management

Craniosynostosis patients were treated according to our center's previously published treatment protocol (16). Briefly, this meant that fronto-orbital advancement and remodeling was performed between 9 and 12 months of age for the following indications: metopic synostosis, unicoronal synostosis, Saethre-Chotzen's syndrome, and Muenke's syndrome. Sagittal synostosis patients were treated with springs, which were inserted at 5-6 months of age and removed approximately 12 weeks later. Patients with lambdoid synostosis, Apert's syndrome, or Crouzon's syndrome were treated with a posterior decompression with the use of springs at around 5-6 months of age (with the springs removed 12 weeks later).

Doppler ultrasound procedure and analyses

Prospective, transfontanelle ultrasound scans with Doppler studies were performed using an Esaote MyLab Twice ultrasound scanner. Scans were carried out at the first outpatient clinic visit and follow-up evaluation after each surgery. Controls underwent only 1 ultrasound study at the time of presentation to the outpatient clinic. During the ultrasound procedure, patients were positioned either supine or with the head of the bed elevated to maximum of 30°. Studies were carried out when a child was quiet and at rest. Data from agitated or crying children were excluded because of the influence of heart rate variability and raised intrathoracic pressure on measurement of SSS_v and mean venous blood flow velocity of the ICV (ICV_v).

ICV_v was measured in the sagittal plane using a convex ultrasound probe at 6.5 MHz (or at 4.5 MHz in those with larger skulls). As position and flow direction were the same in all patients and controls, we did not use any angle correction in the measurements. SSS_v was measured in the coronal plane using a linear probe (6.5 MHz frequency) and an angle of 30° to 45°. The Doppler range gate (2.2 mm) was constant in all measurements.

All ultrasound and Doppler data were obtained by one of two observers (M.J.C. or P.D.) and digitally stored. (The interobserver agreement for mean ICV_v and mean SSS_v , as assessed by intraclass correlation coefficient, was >0.95.) The ICV blood flow waveform produced by spectral analysis using image-processing software (Esaote MyLab) was scored using a previously described categorization (**table 1**) (17). Two observers (M.J.C. and R.d.G.) scored the waveform independently. Instances of disagreement between the scorers was resolved by open evaluation and agreed consensus. The evaluators' kappa statistics were 0.89 and 0.73 for the ICV and SSS_v waveforms, respectively.

Statistical analyses

The sample size for our pilot study was based on previous guidelines (16) and our center's medical ethics committee's recommendations. The statistical analyses assumed normal distribution for ICV_v and SSS_v data. A multivariate analysis of variance (MANOVA) test was performed to assess the effect of craniosynostosis on SSS_v and ICV_v . The chi-square test was used for assessment of waveform categorical data. Finally, in the comparisons of pre- to postoperative

change, we used the preoperative data along with the data from after the last (or most recent) operation. Post hoc nonparametric testing (Kruskall-Wallis or Wilcoxon signed rank test) was performed when appropriate.

Grade	Waveform
0	Steady waveform; constant perfusion speed
1	Fluctuating waveform; minimum speed is never less than half the maximum speed
2	Fluctuating waveform; Minimum speed is less than half the maximum speed, but never drops to 0 cm/s.
3	Fluctuating waveform; Minimum speed drops to 0 cm/s

Table 1: Blood flow waveform categories as described by Ikeda et al. (17)

Results

We recruited 34 craniosynostosis patients, including 14 patients with sagittal synostosis, 11 with metopic synostosis, 2 with unicoronal synostosis, 1 with lambdoid synostosis, 1 with Saethre-Chotzen's syndrome, 3 with Muenke's syndrome, and 2 with Crouzon's syndrome. Postoperatively, we were able to obtain ultrasound scans in 22 (65%) of 34 these patients (8 with sagittal suture synostosis, 9 with metopic synostosis, 1 with lambdoid synostosis, 1 with Saethre-Chotzen's syndrome, 2 with Muenke's syndrome, and 1 with Crouzon's syndrome). The control group comprised 28 patients (24 with nonsynostotic occipital plagiocephaly or metopic ridging, 2 with cleft lip, and 2 unaffected twin siblings of craniosynostosis patients).

None of the patients with craniosynostosis had papilledema at the time of initial assessment. One patient with Muenke's developed papilledema after the preoperative ultrasound study, and for this reason she underwent posterior cranial vault decompression. Additionally, 1 patient with Crouzon's syndrome developed papilledema after the first ultrasound. At time of the postoperative ultrasound study the papilledema was resolving in both cases but had not completely disappeared. None of the other patients had papilledema at the postoperative assessment.

Preoperative ICV_v and SSS_v

Table 2 summarizes the initial findings in the 3 categories of study groups (patients with nonsyndromic or syndromic craniosynostosis and controls). The age distribution differed significantly between groups (Kruskal-Wallis test, $p < 0.001$). Post hoc testing showed no significant difference with regard to age at ultrasound between the syndromic and nonsyndromic craniosynostosis groups (Mann-Whitney U-test, $p = 0.24$), but it did show a significant difference between the nonsyndromic group and controls (Mann-Whitney U-test, $p = 0.001$). There was no significant difference in occipitofrontal head circumference (OFC) (ANOVA, $p = 0.20$).

Variable	Mean \pm SEM (no of measurements)			
	Nonsyndromic craniosynostosis	Syndromic Craniosynostosis	All patients	Controls
Age in mos	4.04 \pm 0.57 (28)	2.71 \pm 0.72 (6)	3.81 \pm 0.49 (34)	6.04 \pm 0.42 (28)
OFC*	+0.62 \pm 0.24 (28)	-0.32 \pm 0.79 (6)	+0.45 \pm 0.24 (34)	+0.15 \pm 0.25 (22)
SSS _v in cm/sec	7.80 \pm 0.51 (23)	6.66 \pm 0.71 (6)	7.57 \pm 0.44 (29)	11.31 \pm 1.06 (26)
ICV _v in cm/sec	10.00 \pm 0.34 (22)	8.57 \pm 0.76 (5)	9.74 \pm 0.33 (27)	9.68 \pm 0.29 (26)

Table 2: Preoperative baseline characteristics and mean blood flow velocities in cm/s for both patient groups and controls.

* OFC in standard deviations compared to the national normal values.

We performed a MANOVA analysis to test whether there were significant differences with regard to venous flow velocity between craniosynostosis patients and controls, correcting for age at ultrasound and OFC. This analysis showed significantly lower venous blood flow velocity in the SSS_v in craniosynostosis patients compared with controls (**table 3**). Age at ultrasound and OFC were not significant contributors to this effect. Additional testing did not show statistically significant differences between nonsyndromic and syndromic craniosynostosis patients after correction for age at ultrasound and OFC.

	Mean ± SEM		F	df	p value
	Craniosynostosis	Controls			
SSS _v	7.37 ± 0.33	11.51 ± 1.13	7.253	1	0.009*
ICV _v	9.74 ± 0.34	9.30 ± 0.30	0.180	1	0.612

Table 3: MANOVA correcting for age at time of ultrasound and OFC.

df = degree of freedom.

Velocities are presented in centimeters/second. Design: Intercept + age at ultrasound + OFC + craniosynostosis. Adjusted R² = 0.25.

* Statistically significant.

Venous Blood flow waveform

Preoperative cerebral venous blood flow waveform scores are shown in **table 4**. The chi-square test did not show any significant differences in distribution among the different groups for the 2 measurements.

Variable	Nonsyndromic craniosynostosis	Syndromic craniosynostosis	Controls
ICV			
Grade 0	5	0	3
Grade 1	17	5	23
Grade 2	0	0	0
Grade 3	0	0	0
Total	22	5	26
SSS			
Grade 0	7	1	5
Grade 1	12	4	19
Grade 2	4	1	2
Grade 3	0	0	0
Total	23	6	26

Table 4: Distribution of preoperative blood flow waveform grades in patients with nonsyndromic or syndromic craniosynostosis and controls. Values are numbers of patients. The preoperative venous blood flow waveform grades are based on the scoring system described in Table 1. No significant differences were found for ICV ($p = 0.77$) or SSS waveform ($p = 0.62$) using the chi-square test.

Postoperative blood flow velocity

Preoperative and postoperative cerebral venous blood flow velocity of the SSS were gained in 15 patients: 4 patients with scaphocephaly, 6 with trigonocephaly, 1 with lambdoid synostosis, 1 with Crouzon's syndrome, 1 with Saethre-Chotzen's syndrome, and 2 with Muenke's syndrome. A related-Samples Wilcoxon signed-rank test showed a significant increase in SSS_v postoperatively (median 7.25 cm/sec [IQR 6.75-8.95 cm/sec] vs 10.20 cm/sec [IQR 8.95-12.20 cm/sec], $p = 0.023$). The ICV_v remained unchanged (median 9.90 cm/sec [IQR 7.95-10.98 cm/sec] vs 10.15 cm/sec [IQR 8.00-11.35 cm/sec], $p = 0.68$). **Figure 1** shows patient-specific pre- to postoperative change of the SSS_v.

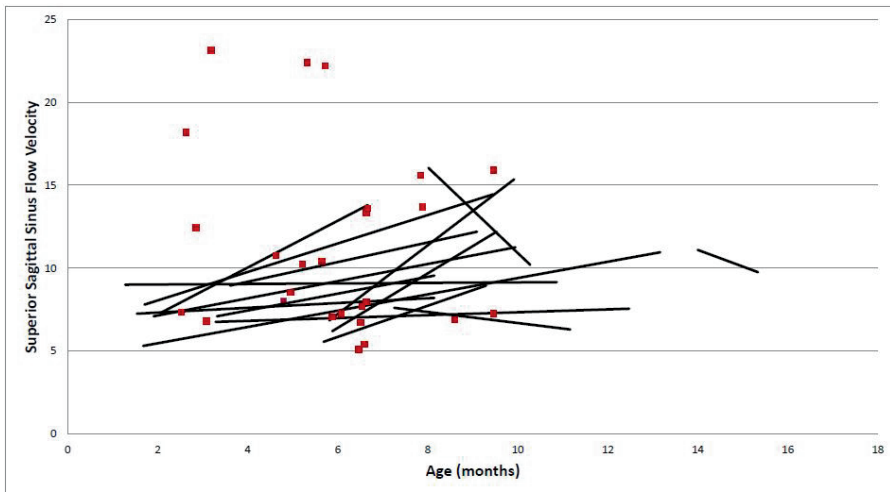


Figure 1: Preoperative to postoperative change in superior sagittal sinus flow velocity of the patients. Each black line indicates the data from 1 patient. The red squares represent point data from controls. See text for details.

Discussion

This study assessed cerebral venous blood flow velocity and blood flow waveform in patients with craniosynostosis compared with controls using Doppler ultrasound. Before surgery, patients with craniosynostosis showed lower SSS_v compared to controls, that increased postoperatively. There was no difference in ICV_v at any time, and blood flow waveform characteristics were similar in both cases and controls.

Previous studies have reported on the interaction between hydrocephalus and hydrodynamic and hemodynamic pressures (i.e., raised ICP and P_{SSS}) in various patient groups (11,15,18,19). For example, in children with achondroplasia and hydrocephalus, cine phase-contrast MRI shows reduced SSS_v (19). Hirabuki et al. hypothesized that the reduced cerebral venous blood flow, as indicated by reduced SSS_v , was the result of venous outflow obstruction (19). In our current findings, we have taken measurements from both the superficial and deep cerebral venous drainage systems as a test of the anatomy before and after any potential point of venous constriction or compression. The resulting data indicate that premature closure of cranial sutures may, in itself, be related to decreased SSS_v and thus reduced cerebral venous drainage from the superficial system, i.e., at a point proximate to the confluence of the straight sinus and SSS. In contrast to these observations, Mursch et al. found higher SSS_v in craniosynostosis patients (15); it should, however, be noted that these measurements were made at the site of venous constriction/compression. Of interest, de Souza and Pinto showed that the diameter of the SSS is related to sagittal suture growth (20). These findings, together with our own, strengthen the hypothesis that cerebral venous outflow obstruction due to venous constriction or compression is caused by the presence of a synostotic suture. Consistent with this idea is our observation that decreased SSS_v is also found in single-suture craniosynostosis patients (**table 2**); until now, cerebral venous hypertension has been considered an attribute of syndromic craniosynostosis (8,10). In fact, we think that this physiology may be important in the etiology of ICHT in unisutural craniosynostosis patients, particularly as OSA, Chiari malformation type I, and hydrocephalus are not found in this patient group. Furthermore, the postoperative increase in SSS_v may also reflect that venous obstruction/compression caused by the synostotic suture has been relieved and resistance into venous outflow in the superficial drainage system

has been lowered. Since we only performed postoperative analyses in 15 patients, these findings should be confirmed in a larger study.

In regard to the characteristics of the cerebral venous waveform in craniosynostosis, Mursch et al. previously reported that such patients had different SSS pulsatility measurements (i.e., pulsatility index and resistance index) (15). We could not reproduce these findings when using a system of scoring venous blood flow waveform profiles. Taken together with the above discussion on SSS_v , this observation suggests that we may have been seeing patients early in the course of uncorrected natural history; that is, at an early stage of pathology when there is premature suture fusion with an effect on SSS_v but pulsatility remains unchanged. The state in which craniosynostosis influences both SSS_v and SSS waveform pulsatility most likely represents a more severe or later stage.

There are some limitations in this study that need to be considered. First, we have little comparative data. Even though the cranial venous outflow of patients with craniosynostosis has been a subject of research over the past decade, we have only one quantitative study of SSS_v , until now. The present study was designed as a pilot project to explore potential effects of craniosynostosis on the superficial and deep cerebral venous drainage systems, and we hope that our findings will stimulate research in other clinical centers. Second, in accordance with our institution's medical research ethics advice for pilot studies, we could only recruit up to 15 patients in each diagnostic group, which, at this preliminary stage, limits the generalization of our findings. Third, postoperative analyses were limited by the presence of closure of the anterior fontanelle – the radiological “window” for examining the SSS and ICV. We have no control over this limitation, but in the future dynamic cerebral MRI venography may provide useful information. Fourth, flow velocity is not equal to flow volume. In this study, we showed that there is a lower flow velocity in the SSS, but it is not yet proven if this also means a lower flow volume. However, we do believe a lower flow velocity is more likely to represent a lower flow volume in this case, especially given the flow velocity increase postoperatively. Last, technical components of Doppler ultrasound studies had the potential to add to variability, e.g., angle of insonation, patient activity and positioning. We have limited these potential technical effects by

standardizing our approach and excluding data that are inadequate (e.g., because patients were restless or moving).

Therefore, considering the results of the present study, and the above limitations, our hypothesis is that cerebral venous drainage and outflow has a role in the etiology of ICHT, even in single suture craniosynostosis patients. This finding should be confirmed in future studies, which should also explore potential differences between the different types of craniosynostosis. It would also be interesting to test whether patients with an affected suture in the midline (i.e., metopic or sagittal synostosis) show a more profound effect of suture closure on SSS_v compared with the other subtypes of craniosynostosis. In addition, the effect of surgery should be evaluated, especially the possible hierarchy in severity (i.e., closed suture with decreased SSS_v vs decreased SSS_v with abnormal venous waveform).

Conclusions

This pilot study of cerebral venous outflow patterns in craniosynostosis patients shows that premature closure of cranial sutures is associated with decreased SSS_v , but not ICV_v - that is an effect on the superficial venous drainage rather than deep venous drainage. Further Doppler ultrasound studies are needed, not only to confirm the current findings, but also to test the hypothesis that at an early stage of craniosynostosis pathology SSS_v is abnormal while pulsatility is normal, and that abnormalities in both SSS_v and the superficial venous waveform reflect a more advanced stage of evolution in suture closure.

References

1. Cornelissen M, Ottelander B, Rizopoulos D, van der Hulst R, Mink van der Molen A, van der Horst C, et al: Increase of prevalence of craniosynostosis. *J Craniomaxillofac Surg* 44:1273-1279, 2016
2. de Jong T, Bannink N, Bredero-Boelhouwer HH, van Veelen ML, Bartels MC, Hoeve LJ, et al: Long-term functional outcome in 167 patients with syndromic craniosynostosis; defining a syndrome-specific risk profile. *J Plast Reconstr Aesthet Surg* 63:1635-1641, 2010
3. Renier D, Lajeunie E, Arnaud E, Marchac D: Management of craniosynostoses. *Childs Nerv Syst* 16:645-658, 2000
4. Marucci DD, Dunaway DJ, Jones BM, Hayward RD: Raised intracranial pressure in Apert syndrome. *Plast Reconstr Surg* 122:1162-1168; discussion 1169-1170, 2008
5. Cornelissen MJ, Loudon SE, van Doorn FE, Muller RP, van Veelen MC, Mathijssen IM: Very Low Prevalence of Intracranial Hypertension in Trigenocephaly. *Plast Reconstr Surg* 139:97e-104e, 2017
6. Renier D, Sainte-Rose C, Marchac D, Hirsch JF: Intracranial pressure in craniostenosis. *J Neurosurg* 57:370-377, 1982
7. Di Rocco C, Frassanito P, Massimi L, Peraio S: Hydrocephalus and Chiari type I malformation. *Childs Nerv Syst* 27:1653-1664, 2011
8. Florisson JM, Barmpalios G, Lequin M, van Veelen ML, Bannink N, Hayward RD, et al: Venous hypertension in syndromic and complex craniosynostosis: the abnormal anatomy of the jugular foramen and collaterals. *J Craniomaxillofac Surg* 43:312-318, 2015
9. Gault DT, Renier D, Marchac D, Jones BM: Intracranial pressure and intracranial volume in children with craniosynostosis. *Plast Reconstr Surg* 90:377-381, 1992
10. Hayward R: Venous hypertension and craniosynostosis. *Childs Nerv Syst* 21:880-888, 2005
11. Sainte-Rose C, LaCombe J, Pierre-Kahn A, Renier D, Hirsch JF: Intracranial venous sinus hypertension: cause or consequence of hydrocephalus in infants? *J Neurosurg* 60:727-736, 1984
12. Maltese G, Tarnow P, Wikberg E, Bernhardt P, Lagerlof JH, Tovetjarn R, et al: Intracranial volume before and after surgical treatment for isolated metopic synostosis. *J Craniofac Surg* 25:262-266, 2014
13. van Veelen MC, Jippes M, Carolina JA, de Rooi J, Dirven CM, van Adrichem LN, et al: Volume measurements on three-dimensional photogrammetry after extended strip versus total cranial remodeling for sagittal synostosis: A comparative cohort study. *J Craniomaxillofac Surg* 44:1713-1718, 2016
14. Florisson JM, van Veelen ML, Bannink N, van Adrichem LN, van der Meulen JJ, Bartels MC, et al: Papilledema in isolated single-suture craniosynostosis: prevalence and predictive factors. *J Craniofac Surg* 21:20-24, 2010
15. Mursch K, Enk T, Christen HJ, Markakis E, Behnke-Mursch J: Venous intracranial haemodynamics in children undergoing operative treatment for the repair of craniosynostosis. A prospective study using transcranial colour-coded duplex sonography. *Childs Nerv Syst* 15:110-116; discussion 117-118, 1999
16. Mathijssen IM: Guideline for Care of Patients With the Diagnoses of Craniosynostosis: Working Group on Craniosynostosis. *J Craniofac Surg* 26:1735-1807, 2015
17. Ikeda T, Amizuka T, Ito Y, Mikami R, Matsuo K, Kawamura N, et al: Changes in the perfusion waveform of the internal cerebral vein and intraventricular hemorrhage in the acute management of extremely low-birth-weight infants. *Eur J Pediatr* 174:331-338, 2015
18. Olivero WC, Rekate HL, Chizeck HJ, Ko W, McCormick JM: Relationship between intracranial and sagittal sinus pressure in normal and hydrocephalic dogs. *Pediatr Neurosci* 14:196-201, 1988

19. Hirabuki N, Watanabe Y, Mano T, Fujita N, Tanaka H, Ueguchi T, et al: Quantitation of flow in the superior sagittal sinus performed with cine phase-contrast MR imaging of healthy and achondroplastic children. *AJNR Am J Neuroradiol* 21:1497-1501, 2000
20. de Souza RB, Pinto FC: Could craniometric measurements explain the growth of the superior sagittal sinus? *Pediatr Neurosurg* 48:225-228, 2012

CHAPTER 5.2

Letter to the editor. Altered
intracranial venous physiology

Surya Sri Krishna Gour, Mohit Agrawal, Dattaraj Sawarkar

Journal of Neurosurgery: Pediatrics, 2018



TO THE EDITOR: We read with keen interest the article by Cornelissen et al. (1) describing the role of intracranial venous physiology in intracranial hypertension in craniosynostosis (Cornelissen MJ, de Goederen R, Doerga P, et al: Pilot study of intracranial venous physiology in craniosynostosis. *J Neurosurg Pediatr* 21:626–631, June 2018). We commend the authors for attempting to study the role of altered intracranial venous physiology with the use of Doppler and the possible role in raised intracranial pressure (ICP), especially in patients with nonsyndromic craniosynostosis. However, we would like to seek clarifications on some of the shortcomings that we found in the study. Papilledema was used as a measure of intracranial hypertension in this study. Although it is highly specific, the sensitivity of papilledema in assessing intracranial hypertension is only 22% in children less than 8 years of age (2). Use of ICP monitoring would have been a better measure to identify intracranial hypertension. It was not described whether the study population was evaluated for variables like Chiari I, hydrocephalus, obstructive sleep apnea (OSA), altered cranial venous outflow, and craniocerebral disproportion (CCD); these factors are known to contribute to raised ICP in patients with syndromic craniosynostosis (3), and thus may confound the results. Doppler assessment is highly operator dependent and is affected by various factors like level of activity and head end elevation (4). In this study, measurements were taken at various degrees of head end elevation (0°–30°) and also could not be performed in a few patients in the postoperative period due to lack of a radiological window. The use of noninvasive techniques like MR venography could overcome these limitations. The study population was heterogeneous (syndromic and nonsyndromic) and consisted of patients who underwent different procedures, which probably would have had varied effects, and the subjects were evaluated at different points of time, which would have led to bias. The authors also fail to describe the mechanism by which superior sagittal sinus velocity increases postoperatively in patients with nonsagittal craniosynostosis like metopic craniosynostosis if it is hypothesized that a synostotic sagittal suture is responsible for venous outflow obstruction (5). Finally, we would like to congratulate the authors for reporting on an alternative cause for raised ICP in patients with craniosynostosis and for considering possible therapeutic interventions in the future. This article paves the way for further such studies with a larger and more homogeneous population.

References

1. Cornelissen MJ, de Goederen R, Doerga P, Cuperus I, van Veelen ML, Lequin M, et al: Pilot study of intracranial venous physiology in craniosynostosis. *J Neurosurg Pediatr*:1-6, 2018
2. Tuite GF, Chong WK, Evanson J, Narita A, Taylor D, Harkness WF, et al: The effectiveness of papilledema as an indicator of raised intracranial pressure in children with craniosynostosis. *Neurosurgery* 38:272-278, 1996
3. Mathijssen IM: Guideline for Care of Patients With the Diagnoses of Craniosynostosis: Working Group on Craniosynostosis. *J Craniofac Surg* 26:1735-1807, 2015
4. Mursch K, Enk T, Christen HJ, Markakis E, Behnke-Mursch J: Venous intracranial haemodynamics in children undergoing operative treatment for the repair of craniosynostosis. A prospective study using transcranial colour-coded duplex sonography. *Childs Nerv Syst* 15:110-116; discussion 117-118, 1999
5. de Souza RB, Pinto FC: Could craniometric measurements explain the growth of the superior sagittal sinus? *Pediatr Neurosurg* 48:225-228, 2012

CHAPTER 5.3

Response to letter to the editor

Martijn J. Cornelissen, Robbin de Goederen,
Irene M. J. Mathijssen, Robert C. Tasker

Journal of Neurosurgery: Pediatrics, 2018



Response

We thank Gour et al. for the letter about our pilot work on intracranial venous physiology in patients with craniosynostosis. Our report is the first to analyze intracranial venous outflow and its relation to intracranial hypertension. In so doing, we have used the data for generating new hypotheses that could help in rational therapies in our patients. To be clear, we entirely accept the criticisms raised by Gour et al.: the operator dependence in Doppler ultrasound, validity of papilledema, and heterogeneity in causes of intracranial hypertension. We, too, are concerned about such limitations when studying the in vivo pathophysiology of craniosynostosis, and value the opportunity to discuss our thoughts on these matters. First, in regard to measurements with Doppler ultrasound. Such measurements are influenced by the angle of insonation and the patient's position, which may lead to bias unless a standardized technique and protocol is used, as was done in our study. Second, the debate about using papilledema goes far beyond the scope of a brief letter. We acknowledge that in the diagnosis of intracranial hypertension in craniosynostosis, Tuite et al. showed that the sensitivity is low (approximately 0.22) in young children (1). Recent reports, however, have shown variation in occurrence of papilledema according to craniosynostosis subtype. For example, at our center we have identified papilledema in 10%, 2%, and up to 50% of cases with sagittal (2,3), metopic (4), and syndromic craniosynostosis (5), respectively. This diagnosis-related prevalence of papilledema corresponds with the previously reported occurrence of intracranial hypertension. Therefore, in our practice, we remain convinced of the value of funduscopy. Third, there is no doubt that we are dealing with a complex pathophysiological problem that may include interactions between OSA, Chiari I, hydrocephalus, altered cranial venous outflow, and CCD. Of these factors, OSA, hydrocephalus, CCD, and Chiari I are found in Apert and Crouzon syndrome (6-9). Our study only included 2 cases with Crouzon syndrome. In one case OSA, hydrocephalus, and Chiari I malformation were present. In theory, the OSA or the Chiari I malformation could have caused intracranial hypertension instead of abnormal cranial venous outflow. In the other patient, there was no evidence of OSA, hydrocephalus, or Chiari I malformation. In the nonsyndromic craniosynostosis cases we only review CT scans and occipitofrontal circumference (OFC) measurements routinely because OSA, hydrocephalus, altered cranial venous outflow, and Chiari I malformation are rarely

present. Taking all of the above together, readers should consider our study as the first step to improving what is known about cranial venous outflow in patients with craniosynostosis. Our pilot study indicates an alteration in cerebral venous outflow that appears to be associated with the occurrence of intracranial hypertension. In the future, our aim is to clarify this matter further, and we thank Gour et al. for their invaluable contribution to the discussion.

References

1. Tuite GF, Chong WK, Evanson J, Narita A, Taylor D, Harkness WF, et al: The effectiveness of papilledema as an indicator of raised intracranial pressure in children with craniosynostosis. *Neurosurgery* 38:272-278, 1996
2. Florisson JM, van Veelen ML, Bannink N, van Adrichem LN, van der Meulen JJ, Bartels MC, et al: Papilledema in isolated single-suture craniosynostosis: prevalence and predictive factors. *J Craniofac Surg* 21:20-24, 2010
3. van Veelen ML, Eelkman Rooda OH, de Jong T, Dammers R, van Adrichem LN, Mathijssen IM: Results of early surgery for sagittal suture synostosis: long-term follow-up and the occurrence of raised intracranial pressure. *Childs Nerv Syst* 29:997-1005, 2013
4. Cornelissen MJ, Loudon SE, van Doorn FE, Muller RP, van Veelen MC, Mathijssen IM: Very Low Prevalence of Intracranial Hypertension in Trigenocephaly. *Plast Reconstr Surg* 139:97e-104e, 2017
5. de Jong T, Bannink N, Bredero-Boelhouwer HH, van Veelen ML, Bartels MC, Hoeve LJ, et al: Long-term functional outcome in 167 patients with syndromic craniosynostosis; defining a syndrome-specific risk profile. *J Plast Reconstr Aesthet Surg* 63:1635-1641, 2010
6. Driessen C, Joosten KF, Bannink N, Bredero-Boelhouwer HH, Hoeve HL, Wolvius EB, et al: How does obstructive sleep apnoea evolve in syndromic craniosynostosis? A prospective cohort study. *Arch Dis Child* 98:538-543, 2013
7. Florisson JM, Barmpalios G, Lequin M, van Veelen ML, Bannink N, Hayward RD, et al: Venous hypertension in syndromic and complex craniosynostosis: the abnormal anatomy of the jugular foramen and collaterals. *J Craniomaxillofac Surg* 43:312-318, 2015
8. Rijken BF, Lequin MH, van der Lijn F, van Veelen-Vincent ML, de Rooi J, Hoogendam YY, et al: The role of the posterior fossa in developing Chiari I malformation in children with craniosynostosis syndromes. *J Craniomaxillofac Surg* 43:813-819, 2015
9. Spruijt B, Joosten KF, Driessen C, Rizopoulos D, Naus NC, van der Schroeff MP, et al: Algorithm for the Management of Intracranial Hypertension in Children with Syndromic Craniosynostosis. *Plast Reconstr Surg* 136:331-340, 2015

CHAPTER 6

Dural Sinus Volume in Children with Syndromic Craniosynostosis and Intracranial Hypertension

Robbin de Goederen, Iris E. Cuperus, Robert C. Tasker, Bianca K. den Ottelander, Marjolein H.G. Dremmen, Marie-Lise C. van Veelen, Jochem K.H. Spoor, Koen F.M. Joosten, Irene M.J. Mathijssen

Journal of Neurosurgery: Pediatrics, 2020

Abstract

Introduction: Intracranial hypertension is a major concern in children with syndromic craniosynostosis (sCS). Cerebral venous hypertension caused by cerebral venous outflow obstruction is believed to contribute to intracranial hypertension. The authors therefore hypothesized that cerebral venous volume would be increased in those children with sCS and intracranial hypertension.

Methods: In a case series of 105 children with sCS, of whom 32 had intracranial hypertension, cerebral MRI techniques were used to quantify the volume of the superior sagittal sinus, straight sinus (StrS) and both transverse sinuses.

Results: Linear regression showed that total cerebral venous volume increased by 580.8 mm³ per cm increase in occipitofrontal head circumference ($p < 0.001$). No significant difference was found between the intracranial hypertension group and the nonintracranial hypertension group ($p = 0.470$). Multivariate ANOVA showed increased StrS volume (as a proportion of total volume) in the intracranial hypertension group (8.5% vs 5.1% in the nonintracranial hypertension group, $p < 0.001$). Multivariate logistic regression showed that 100-mm³ increase in StrS volume is associated with increased odds of having intracranial hypertension by 60% (OR 1.60, 95% CI 1.24 – 2.08).

Conclusion: Although intracranial hypertension was not associated with total cerebral venous volume increase, it was associated with an isolated increase in StrS volume. Hence, it is unlikely that general cerebral venous outflow obstruction is the mechanism of intracranial hypertension in sCS. Rather, these findings indicate either a central cerebral vulnerability to intracranial hypertension or a mechanism involving venous blood redistribution.

Introduction

Intracranial hypertension is a major concern in children with syndromic craniosynostosis (sCS), and in Apert and Crouzon syndromes the incidence is as high as 53% (1,2). There are many complications of prolonged intracranial hypertension, with the most severe being irreversible visual loss (2). Intracranial hypertension may also impair neurodevelopment, and impact behavior and learning (1,3).

Initially, surgeons thought that limited growth of the cranial vault was the main reason for intracranial hypertension in children with craniosynostosis. Treatment focused primarily on increasing the intracranial volume. Over the years, more and more evidence showed that not only did reduced cranial growth affect the intracranial pressure (ICP), but also other factors such as obstructive sleep apnea (OSA) and cranial venous hypertension (4-7).

Even currently, the mechanisms that account for intracranial hypertension in children with sCS are not fully understood, but anomalous cerebral venous drainage patterns are often found in such children. It appears that these anomalies may limit cerebral venous outflow and could thereby indirectly perturb CSF reabsorption. For example, many patients with sCS have absent or stenotic cerebral venous sinuses – especially of the transverse sinus (TS), sigmoid sinus and jugular complex (8-10) – that are related to an underlying genetic mutation (11). These patients also have venous drainage through big emissary veins near the occiput and, in some cases, these emissary veins are the main drainage system of the brain (8-10,12).

Another condition that is somewhat similar to intracranial hypertension in craniosynostosis is idiopathic intracranial hypertension (IIH). Patients suffering from IIH experience symptoms from intracranial hypertension such as disabling headaches and papilledema. Their ICP is indeed increased, but without an identifiable cause (13). Over the years, researchers have found that many patients with IIH have increased ICP due to TS stenosis (14). These stenoses can be resolved by stenting the sinus or by performing a lumbar puncture. In study by Rohr et al., the authors measured the dural sinus volumes before and after lumbar puncture (15). They reported that patients with IIH had significantly smaller sinus volumes than the healthy control group. Upon normalization of the ICP, the sinus volumes increased significantly, independent from the disappearing TS stenosis.

Taken these findings together, it is unknown to what extent venous anomalies contribute to the development of intracranial hypertension in children with sCS. The hypothesis that a narrower jugular foramen (and thereby restricted outflow of the sinuses) causes intracranial hypertension in sCS children is controversial (9,16,17). As a first step in examining this venous obstruction hypothesis in children with sCS we tested whether intracranial hypertension is associated with a change in dural sinus volumes.

Methods

Patients

This study is part of an ongoing national clinical program for children with sCS or complex craniosynostosis (multiple-suture craniosynostosis without a known genetic mutation) treated at the Dutch Craniofacial Centre (Sophia Children's Hospital – Erasmus University Medical Center, Rotterdam, The Netherlands). The study was approved by our institutional research ethics committee for human studies and all children are managed according to a previously described protocol (18). In this report, we focus on cerebral MRI scans performed between 2008 and 2018. All children who had undergone a 3D T2-weighted scan with isometric voxels of the brain were eligible for inclusion, and were then split into two groups based on the presence or absence of intracranial hypertension. Of 346 children with sCS being treated in our center during the prespecified time period, 105 children had an eligible MR image. Hence, we have included MRI scans of 32 children in the intracranial hypertension group and 73 children in the non-intracranial hypertension group.

Intracranial hypertension

As described elsewhere (18), the presence of intracranial hypertension in our clinical protocol was based on findings that included fundoscopic tests; optical coherence tomography (OCT) (Spectralis OCT scanner, Heidelberg Engineering), invasive ICP measurements, and the size of the cerebral ventricles on MRI. Hydrocephalus was diagnosed when the enlargement of the ventricles was progressive on two consecutive MRI or CT scans, or if the frontooccipital horn ratio (FOHR) was > 0.44 . Only patients with untreated hydrocephalus were included in this part of the

study. Children were scored as having intracranial hypertension when they had papilledema, hydrocephalus, a positive invasive ICP measurement, or an increased total retina thickness on OCT. All children underwent fundoscopic tests at least on a yearly basis and more frequently if there was clinical suspicion of intracranial hypertension.

MRI Acquisition

All MRI scans were performed on a 1.5-T scanner (MR Signa Excite HD, GE Healthcare) and the imaging protocol included a 3D sagittal T2-weighted MRI sequence with isometric voxels. The imaging parameters were slice thickness 1.6 mm, no slice gap, field of view 20 cm, matrix size 224 x 224, TE 90 msec, and TR 2500 msec. Infants and small children who were unable to lie still during the MRI scan were scanned under general anesthesia, as per the clinical algorithm.

In the current clinical protocol for sCS, all children are scheduled for a brain MRI shortly after their first visit to our center and at age 4. Children with Apert and Crouzon syndrome undergo additional MRI at 2 years of age. When the neurosurgeon suspects intracranial hypertension or tonsillar herniation, an additional MRI scan may be performed. The 3D T2-weighted sequence with isometric voxels was added to the scanning protocol in 2008, and therefore not all of our patients with sCS have undergone such a scan.

Segmentation of dural sinuses

MRI scans in DICOM format were imported into the 3D Slicer program (19) (version 4.8.0.) and the Editor tool was used for cerebral venous sinus segmentation. Three-dimensional reconstructions of the dural sinuses were made and measurements taken in all anatomical planes. Sinuses of interest included the superior sagittal sinus (SSS), the straight sinus (StrS) and both TSs (the sigmoid sinus was included with the TS volume). The crista galli was defined as the initial point of the SSS, and the confluence of the dural sinuses (CoS) was considered the end point. In the StrS, the confluence of the great cerebral vein and the inferior sagittal sinus was defined as the starting point and the CoS the end point. The CoS was considered the initial point of the TS and the jugular foramen its end point. All segmentations were performed by one researcher (I.E.C.) who was blinded to the presence or absence of intracranial hypertension in

the patient. A second independent researcher (R.D.G.) checked the segmentation, also while blinded to the intracranial hypertension status of the subject. To determine reproducibility of the segmentation, the scans of 10 randomly selected subjects were segmented again after a few months by the second researcher. The intraclass correlation coefficient was calculated using the total volume only. Once consensus on the segmentation was achieved, a 3D model of the segmented sinuses was created and the total sinus volume was calculated in cubic millimeters (mm^3).

The two researchers divided the segmented volume of all the sinuses by consensus. The SSS was cleaved superiorly to the CoS, the StrS anteriorly to the CoS, and the TSs medially in the CoS. Finally, the split 3D model was made (**Figure 1**) and each separate volume of interest was calculated. The TS with the greater volume was considered the dominant TS, and the one with the lower volume the nondominant TS. Furthermore, all children were evaluated on the presence of occipital emissary veins based on their MRI scan together with contrast-enhanced CT scans if present. Patients were scored as having occipital emissary veins when, upon visual inspection, one of the veins had a bigger diameter than approximately 33% of the diameter of the distal part of the SSS.

Statistical analysis

Statistical analyses were performed using the statistical programming language R (version 3.6.0, R Foundation for Statistical Computing). All data were checked for normality and nonnormally distributed data were log-transformed when needed. Simple between-group comparisons were conducted using the Student t-test for unpaired data. Linear regression analysis was performed to evaluate the effect of age, occipitofrontal head circumference (OFC), and intracranial hypertension on the total cerebral volume. To compare the total difference in individual dural sinus volumes (i.e., SSS volume, StrS volume, TS dominant volume, and TS nondominant volume) between the intracranial hypertension and the nonintracranial hypertension group, a multivariate ANOVA (MANOVA) was performed. In this analysis, the dural sinus volumes were presented as a proportion of the total volume. To evaluate the effect size of

the significant differences found in the MANOVA, a multivariate logistic regression was performed, correcting for age and OFC z-score.

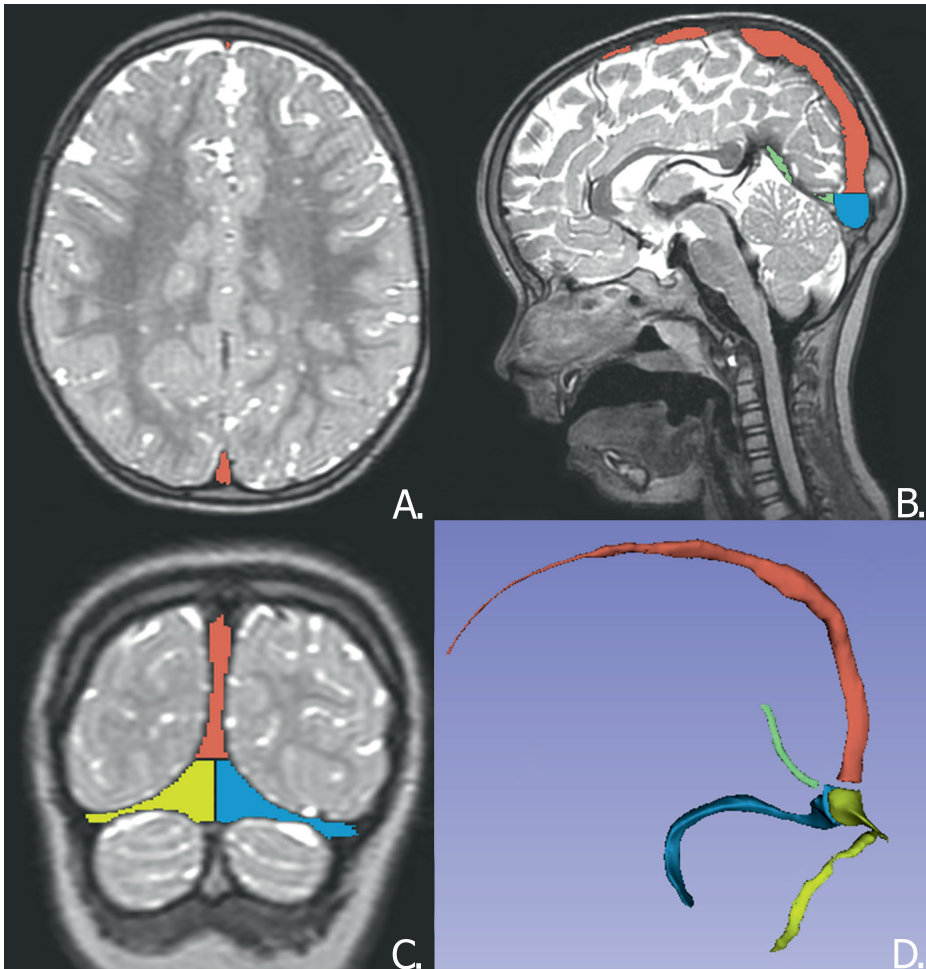


Figure 1: T2-weighted MR images showing the segmentation of the dural sinus volumes. *Red* represents the SSS, *green* the StrS, and *yellow* and *blue* the TSs. A: Coronal image. B: Midsagittal image. C: Axial image at the level of the confluence of sinuses. D: Three-dimensional image of the segmented sinuses.

Results

Patient characteristics and mean sinus volumes per group are presented in **table 1**. As expected, patients with intracranial hypertension more frequently showed occipital emissary veins than the nonintracranial hypertension group (65.6% vs. 39.7%). **Table 2** shows further details on the exact diagnostic criteria used for the diagnosis of intracranial hypertension. **Figure 2** shows scatterplots of the total sinus volumes set on an x-axis of age, with a fitted linear regression line based on the presence of intracranial hypertension; age was log-transformed for the regression due to a nonnormal distribution. The same method was performed for the total volumes against the OFC. The intraclass correlation coefficient was 0.99 (95% CI 0.97 – 1.00). Linear regression showed that OFC had the biggest impact on total volume with an increase of 580.8 mm³ per cm ($p < 0.001$). Log(age) and intracranial hypertension had no significant effect on the total volume (β 2486.8 [$p=0.219$] and β -108.4 [$p=0.843$], respectively). After normalizing the total volumes by dividing them by OFC, an unpaired Student t-test showed no significant difference between the intracranial hypertension group and the nonintracranial hypertension group ($p = 0.470$).

A MANOVA comparing the combination of individual sinus volumes between the two groups showed a significant difference (Pillai's Trace 0.208, $p < 0.001$). The post hoc analysis of the MANOVA showing the influence of the individual dural sinus volumes is presented in **table 3**. The results show that the difference between the groups is caused by an increased StrS volume proportion of the total volume in the intracranial hypertension group, i.e., 8.5% vs. 5.1% in the nonintracranial hypertension group ($p < 0.001$; **figure 3**). All other volumes were not significantly different between the groups. An example of a clear increase of the StrS on an MR image of a child with Crouzon and intracranial hypertension is shown in **figure 4**.

Variable	Intracranial hypertension group	Nonintracranial hypertension group
No. of patients	32	73
Median age (IQR), yrs	2.44 (0.64 – 4.08)	3.97 (0.62 – 6.15)
Male : Female	23/9	29/44
Mean OFC cm (range)	47.1 (36.0 – 54.0)	48.5 (38.0 – 60.0)
Mean OFC z-score (range)	-0.25 (-3.0 to 2.63)	0.001 (-3.32 – 3.23)
Diagnosis, n (%)		
Apert syndrome	6 (18.8)	15 (20.5)
Crouzon syndrome	15 (46.9)	23 (31.5)
Muenke syndrome	0 (0)	11 (15.1)
Saethre-Chotzen syndrome	4 (12.5)	7 (9.6)
TCF12 mutation	0 (0)	6 (8.2)
Complex craniosynostosis	7 (21.9)	11 (15.1)
Mean FOHR (range)	0.39 (0.21 – 0.68)	0.34 (0.26 – 0.53)
Hydrocephalus, n (%)	8 (25)	0 (0)
Anesthesia, n (%)*	31 (96.9)	56 (76.7)
Operated, n (%)†	19 (59.4)	49 (67.1)
Occipital emissary veins, n (%)	21 (65.6)	29 (39.7)
Mean total sinus vol (range), mm ³	7663.4 (1930.1 – 20593.5)	3922.1 (786.5 – 7161.4)
Mean SSS vol (range), mm ³	3922.1 (786.5 – 7161.4)	4175.0 (1030.7 – 9107.8)
Mean StrS vol (range), mm ³	553.8 (84.4 – 1080.4)	404.3 (61.4 – 1030.9)
Mean TS dominant vol (range), mm ³	2157.4 (284.3 – 6386.1)	2561.0 (511.7 – 7760.5)
Mean TS nondominant vol (range), mm ³	969.3 (0 – 6062.9)	1167.6 (42.0 – 4060.86)

Table 1: Characteristics of the total study population of children with sCS according to intracranial hypertension.

*MRI performed under general anesthesia.

†Children who had undergone cranial vault surgery prior to the scan

Diagnostic Variable	No.
Method of diagnosing intracranial hypertension	32
Papilledema	27
Hydrocephalus	9
Invasive ICP measurement	3
OCT	1
<hr/>	
Specification	
Only papilledema	19
Papilledema + positive ICP measurement	3
Hydrocephalus + papilledema	4
Papilledema + positive OCT	1
Only Hydrocephalus	5

Table 2: Characteristics of intracranial hypertension diagnosing criteria. The top half represents the total count of occurring events; the bottom half provides specifics on the combination of events occurring in the same patients.

Variable	Intracranial hypertension (mean, SD)	Non-intracranial hypertension (mean, SD)	F statistic	<i>p</i> Value
SSS vol, (%)	53.6 (9.3)	51.4 (7.5)	0.88	0.350
StrS vol, (%)	8.5 (4.6)	5.1 (2.2)	25.71	<0.001*
TS dominant, (%)	26.1 (8.3)	29.0 (7.4)	2.66	0.106
TS nondominant, (%)	10.8 (7.7)	13.5 (5.8)	3.29	0.073

Table 3: MANOVA of dural sinus volumes in the intracranial versus nonintracranial hypertension groups. Mean dural sinus volumes, presented as a proportion of the total volume, for the intracranial hypertension group versus nonintracranial hypertension groups. The presented *p* value is the result of a post hoc analysis of the MANOVA.

* Statistically significant

Multivariate logistic regression analysis of the statistical predictive value of the StrS volume on the presence of intracranial hypertension, corrected for age and OFC z-score, was then performed. The analysis showed that an StrS volume increase of 100 mm³ had an OR of 1.60 (95% CI 1.24 – 2.08). This indicates that the odds of having intracranial hypertension increases by 60% with every 100-mm³ increase in StrS volume.

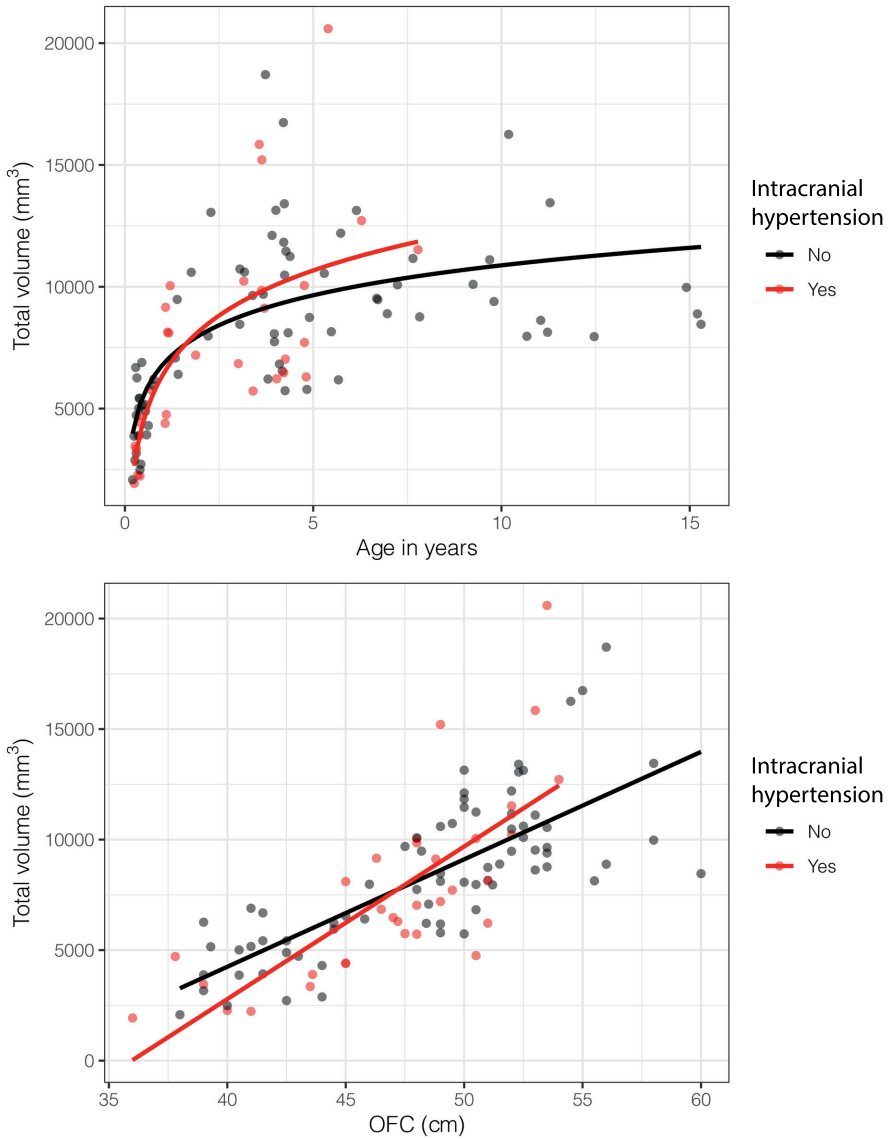


Figure 2: Scatterplots of the total sinus volumes against age (*upper*) and OFC, with a fitted regression line per group. Age was log-transformed in the fitted regression line.

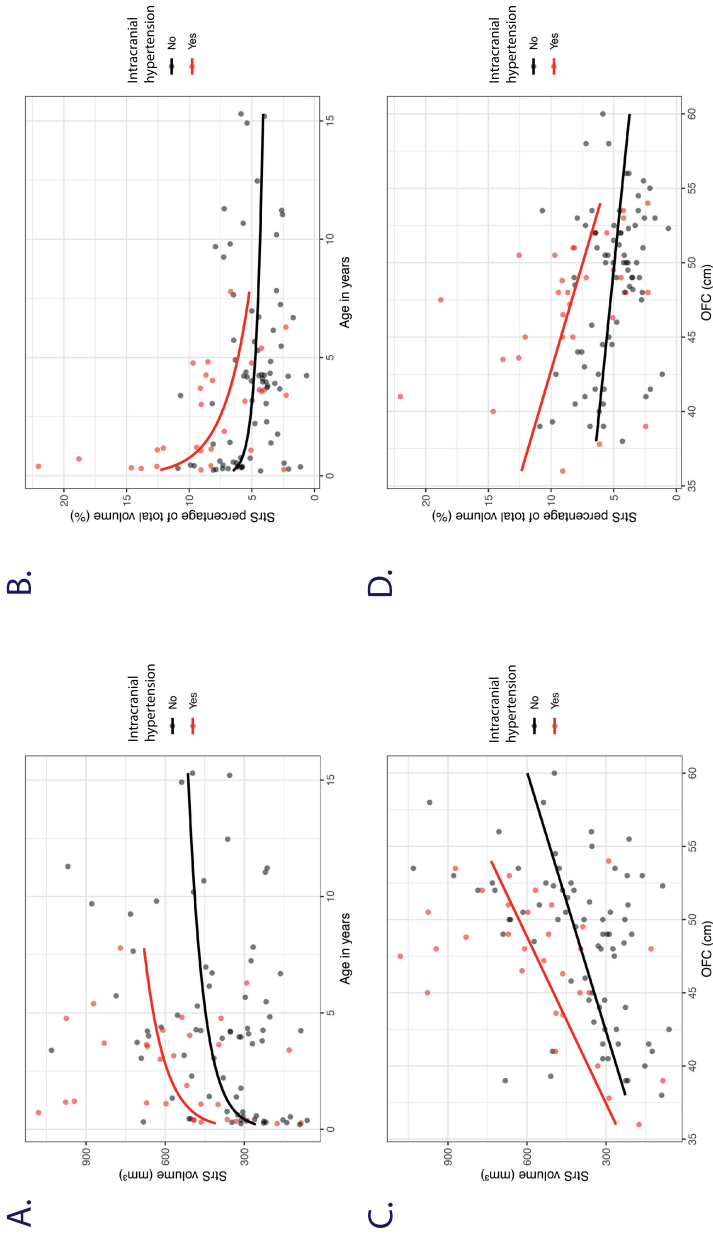
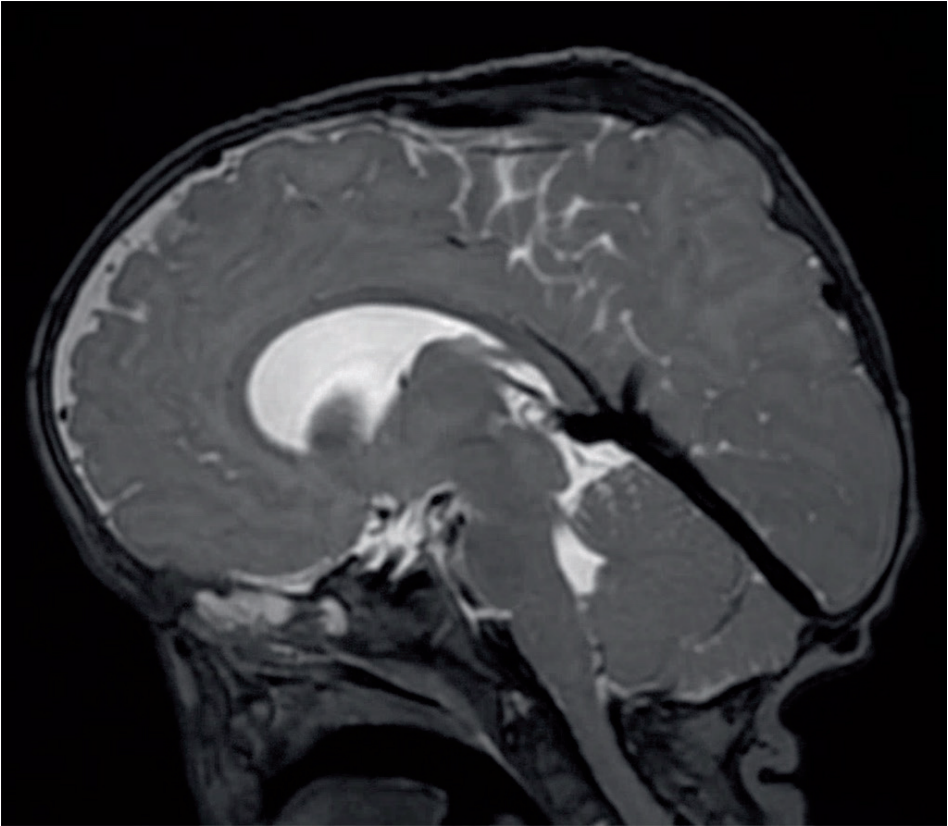


Figure 3: Scatterplots of the StrS against age and OFC, with a fitted regression line per group. Panels A and C represent the absolute volumes, while panels B and D represent the StrS as proportions of the total volume. Age was log-transformed in the fitted regression lines.



6

Figure 4: Midsagittal T2-weighted MR image of a child with Crouzon syndrome and intracranial hypertension, showing a marked distension of the StrS.

Discussion

This study in children with sCS shows that dural sinus volumes are strongly correlated with head circumference. There was no difference in total volume between the intracranial hypertension group and the nonintracranial hypertension group. However, there was a measurable increase of the StrS volume in the presence of intracranial hypertension, while in the other sinuses this was not the case. Moreover, every 100-mm³ increase in StrS volume increases

the odds of having intracranial hypertension by 60%. Hence the results of this study show cerebral blood volume redistribution in children with intracranial hypertension, but it is unclear how the regional volume changes in StrS are explained.

Intracranial hypertension in sCS may be caused by 1 out of 4 contributors: craniocerebral disproportion, venous hypertension, CSF outflow obstruction, and OSA. For each contributor, we will discuss their possible relation to an increase in dural sinus volumes. The first contributor to intracranial hypertension is craniocerebral disproportion. In a previous study, we showed that stagnating head growth was the most important predictor of developing intracranial hypertension (18). In the Monro-Kellie doctrine (20), if skull growth is impaired, there is competition among brain growth, cerebral blood volume, and CSF volume. As a consequence, the arterial blood pressure and arterial inflow to the brain are increased to preserve the cerebral perfusion (21,22). For example, in a previous study, we showed that children with sCS and intracranial hypertension had higher transcranial Doppler flow velocity in the middle cerebral artery, which normalized after cranial vault expansion (23). An increase in arterial flow also means an increase in central cerebral venous flow, which could explain the increased volume of the StrS observed in the current study.

The second contributor to intracranial hypertension is venous hypertension, or venous outflow obstruction. Children with sCS can have many cerebral venous malformations, including aplastic TS, abundant emissary veins, and malformations of the jugular/sigmoid complex (9,11,12,24). Most of the malformations could potentially cause an obstruction of cerebral venous outflow. Sainte-Rose et al. confirmed that venous obstruction caused intracranial hypertension in some children (5). Venous bypassing of the obstruction successfully resolved the intracranial hypertension in one of these children. An increase in StrS volume raises the suspicion of venous outflow obstruction distally to the StrS as a possible cause of the intracranial hypertension in these children. However, the results of our study do not provide any additional clues to the site of an obstruction.

The third known contributor to intracranial hypertension is CSF outflow obstruction. The most common consequence of CSF outflow obstruction is ventriculomegaly and ultimately hydrocephalus. The size of the ventricles is easily quantified in this study by measuring the FOHR.

In this study, the size of the FOHR was not associated with dural sinus volumes. In an exploratory analysis (data not presented), we accounted for the interaction between FOHR and intracranial hypertension and found that increased StrS volume was solely attributed to intracranial hypertension. Eight children in this study had untreated hydrocephalus at the time of MRI, but this condition was not related to any changes in sinus volumes.

The last contributor to intracranial hypertension, OSA, is unlikely to be related to any volumetric changes in dural sinuses. OSA increases the ICP by intracerebral vasodilatation caused by hypercapnia when apneas occur, which is mostly during REM sleep (25). During the present study, the patients were either awake or intubated, and therefore did not have apneas during the MRI. In addition, exploratory statistical analysis showed that OSA did not have an effect on sinus volumes (data not presented).

Of further interest was the difference in effect of intracranial hypertension between the StrS and the other dural sinuses. At the moment, it is unclear how this difference can be explained and the current data do not provide the answers to this question. However, two theories could explain this difference. The first theory involves the positioning of the different dural sinuses and their direct surroundings. The sinuses of the superficial cerebral venous system (SSS and TS) are located directly adjacent to bone of the skull (26,27). Surgeons in our center report exaggerated thinning of the bone at the location of the superficial dural sinuses, which seems to confirm that these sinuses compress the adjacent skull. The StrS, however, is part of the deep cerebral venous system and is located in the tentorium. While pressure increases in all dural sinuses, the StrS, not being restricted by bone, could be the one that expands most easily, possibly explaining why the volume of the StrS increases and the volumes of the other sinuses do not. The second theory is related to the emissary veins connecting the superficial intracerebral venous system to the extracerebral venous system together with the theory of increased flow in cases of intracranial hypertension. The superficial cerebral venous system has emissary veins through the skull (28-30), through which blood can exit the intracranial space in case of increased blood flow, while blood from the deep veins can only travel through the StrS to the superficial system (29). The higher flow and pressures in the SSS at the level of the CoS might cause a relative obstruction for the StrS, increasing its volume. Taking all of the above together, the most prudent hypothesis for

the association between intracranial hypertension and increased StrS but normal total dural sinus volume is either a redistribution in regional cerebral blood flow (i.e., away from the superficial cortical structures and toward the central gray matter), or the rerouting of blood through the emissary veins and avoiding regular superficial structures in venous drainage, which is not possible for the deeper central tissue.

This study has some limitations. The first limitation is that our MRI scans were not contrast-enhanced. Contrast enhancement could increase the accuracy of the volume segmentation. However, this factor was probably of minor influence because we used identical methods for both children with and without intracranial hypertension with a high reproducibility. Second, the children in our study most probably did not have a peak in ICP during the scan, because the peaks of ICP in sCS are mostly REM sleep related (31). Therefore, we were not able to account for the dynamic aspects of intracranial hypertension. However, even with this suboptimal timing of imaging, we still found an increase of the StrS volume. Even though the StrS volume is less than 5% of the total volume, the increase in volume is remarkable. Future studies could focus on dynamic imaging to measure volumes and flow velocities during REM sleep. The third limitation is the variable timing of the eligible MR images. Given the limited availability of the needed MRI sequence, we chose to include a wide range of ages and correct for age or OFC in the statistical analyses afterwards. This approach made it impossible to properly investigate the effect of surgery on the sinus volumes, something that could be accomplished in future research. The fourth limitation was the fact that we used OFC as a proxy for intracranial volume. The intracranial volume was difficult to measure on the 3D T2-weighted MRI sequence we used in this study. This was mostly because of the poor visualization of bone on this sequence. We believe OFC to be a useful proxy, as we have verified this in one of our previous studies (32). The fifth limitation was the limited availability of the 3D T2-weighted MRI sequence with isometric voxels that we used in this study. Only one third of the patients had such a scan available following its introduction in the scanning protocol in 2008. Thus, a lot of children that already had an MRI scan did not have the correct sequence available. Therefore, there might have been a selection bias that could influence the generalizability of the results. Lastly, we did not perform invasive ICP measurements in all patients, but relied mostly on fundoscopy to diagnose

intracranial hypertension. This might result in a false-negative outcome and missing episodes of intracranial hypertension. Given the long-term and frequent follow-up of our patients, the impact of these missed cases is probably limited.

Conclusion

This study shows that in children with sCS, intracranial hypertension is associated with increased StrS volume, but total cerebral venous volume is unchanged. In our view, these findings rule out a focal restriction of dural sinus flow as cause of intracranial hypertension, and may suggest a mechanism of venous blood redistribution. However, further research should focus on dynamic studies of regional cerebral blood flow and venous flow in order to explore venous blood volume redistribution.


References

1. Renier D, Sainte-Rose C, Marchac D, Hirsch JF: Intracranial pressure in craniostenosis. *J Neurosurg* 57:370-377, 1982
2. de Jong T, Bannink N, Bredero-Boelhouwer HH, van Veelen ML, Bartels MC, Hoeve LJ, et al: Long-term functional outcome in 167 patients with syndromic craniosynostosis; defining a syndrome-specific risk profile. *J Plast Reconstr Aesthet Surg* 63:1635-1641, 2010
3. Renier D, Lajeunie E, Arnaud E, Marchac D: Management of craniosynostoses. *Childs Nerv Syst* 16:645-658, 2000
4. Gault DT, Renier D, Marchac D, Jones BM: Intracranial pressure and intracranial volume in children with craniosynostosis. *Plast Reconstr Surg* 90:377-381, 1992
5. Sainte-Rose C, LaCombe J, Pierre-Kahn A, Renier D, Hirsch JF: Intracranial venous sinus hypertension: cause or consequence of hydrocephalus in infants? *J Neurosurg* 60:727-736, 1984
6. Hayward R: Venous hypertension and craniosynostosis. *Childs Nerv Syst* 21:880-888, 2005
7. Gonzalez S, Hayward R, Jones B, Lane R: Upper airway obstruction and raised intracranial pressure in children with craniosynostosis. *Eur Respir J* 10:367-375, 1997
8. Jeevan DS, Anlsow P, Jayamohan J: Abnormal venous drainage in syndromic craniosynostosis and the role of CT venography. *Childs Nerv Syst* 24:1413-1420, 2008
9. Taylor WJ, Hayward RD, Lasjaunias P, Britto JA, Thompson DN, Jones BM, et al: Enigma of raised intracranial pressure in patients with complex craniosynostosis: the role of abnormal intracranial venous drainage. *J Neurosurg* 94:377-385, 2001
10. Copeland AE, Hoffman CE, Tsitouras V, Jeevan DS, Ho ES, Drake JM, et al: Clinical Significance of Venous Anomalies in Syndromic Craniosynostosis. *Plast Reconstr Surg Glob Open* 6:e1613, 2018
11. Tischfield MA, Robson CD, Gilette NM, Chim SM, Sofela FA, DeLisle MM, et al: Cerebral Vein Malformations Result from Loss of Twist1 Expression and BMP Signaling from Skull Progenitor Cells and Dura. *Dev Cell* 42:445-461 e445, 2017
12. Florisson JM, Barmpalios G, Lequin M, van Veelen ML, Bannink N, Hayward RD, et al: Venous hypertension in syndromic and complex craniosynostosis: the abnormal anatomy of the jugular foramen and collaterals. *J Craniomaxillofac Surg* 43:312-318, 2015
13. Mollan SP, Markey KA, Benzimra JD, Jacks A, Matthews TD, Burdon MA, et al: A practical approach to, diagnosis, assessment and management of idiopathic intracranial hypertension. *Pract Neurol* 14:380-390, 2014
14. Farb RI, Vanek I, Scott JN, Mikulis DJ, Willinsky RA, Tomlinson G, et al: Idiopathic intracranial hypertension: the prevalence and morphology of sinovenous stenosis. *Neurology* 60:1418-1424, 2003
15. Rohr A, Bindeballe J, Riedel C, van Baalen A, Bartsch T, Doerner L, et al: The entire dural sinus tree is compressed in patients with idiopathic intracranial hypertension: a longitudinal, volumetric magnetic resonance imaging study. *Neuroradiology* 54:25-33, 2012
16. Booth CD, Figueroa RE, Lehn A, Yu JC: Analysis of the jugular foramen in pediatric patients with craniosynostosis. *J Craniofac Surg* 22:285-288, 2011
17. Rich PM, Cox TC, Hayward RD: The jugular foramen in complex and syndromic craniosynostosis and its relationship to raised intracranial pressure. *AJNR Am J Neuroradiol* 24:45-51, 2003
18. Spruijt B, Joosten KF, Driessen C, Rizopoulos D, Naus NC, van der Schroeff MP, et al: Algorithm for the Management of Intracranial Hypertension in Children with Syndromic Craniosynostosis. *Plast Reconstr Surg* 136:331-340, 2015
19. Fedorov A, Beichel R, Kalpathy-Cramer J, Finet J, Fillion-Robin JC, Pujol S, et al: 3D Slicer as an image computing platform for the Quantitative Imaging Network. *Magn Reson Imaging* 30:1323-1341, 2012

20. Wilson MH: Monro-Kellie 2.0: The dynamic vascular and venous pathophysiological components of intracranial pressure. *J Cereb Blood Flow Metab* 36:1338-1350, 2016
21. Guild SJ, Saxena UA, McBryde FD, Malpas SC, Ramchandra R: Intracranial pressure influences the level of sympathetic tone. *Am J Physiol Regul Integr Comp Physiol*, 2018
22. Paton JF, Dickinson CJ, Mitchell G: Harvey Cushing and the regulation of blood pressure in giraffe, rat and man: introducing 'Cushing's mechanism'. *Exp Physiol* 94:11-17, 2009
23. Spruijt B, Tasker RC, Driessen C, Lequin MH, van Veelen ML, Mathijssen IM, et al: Abnormal transcranial Doppler cerebral blood flow velocity and blood pressure profiles in children with syndromic craniosynostosis and papilledema. *J Craniomaxillofac Surg* 44:465-470, 2016
24. Martinez-Perez D, Vander Woude DL, Barnes PD, Scott RM, Mulliken JB: Jugular foraminal stenosis in Crouzon syndrome. *Pediatr Neurosurg* 25:252-255, 1996
25. Jennum P, Borgesen SE: Intracranial pressure and obstructive sleep apnea. *Chest* 95:279-283, 1989
26. Kilic T, Akakin A: Anatomy of cerebral veins and sinuses. *Front Neurol Neurosci* 23:4-15, 2008
27. Uddin MA, Haq TU, Rafique MZ: Cerebral venous system anatomy. *J Pak Med Assoc* 56:516-519, 2006
28. Baltsavias G, Parthasarathi V, Aydin E, Al Schameri RA, Roth P, Valavanis A: Cranial dural arteriovenous shunts. Part 1. Anatomy and embryology of the bridging and emissary veins. *Neurosurg Rev* 38:253-263; discussion 263-254, 2015
29. Andeweg J: The anatomy of collateral venous flow from the brain and its value in aetiological interpretation of intracranial pathology. *Neuroradiology* 38:621-628, 1996
30. Kim LK, Ahn CS, Fernandes AE: Mastoid emissary vein: anatomy and clinical relevance in plastic & reconstructive surgery. *J Plast Reconstr Aesthet Surg* 67:775-780, 2014
31. Yokota A, Matsuoka S, Ishikawa T, Kohshi K, Kajiwara H: Overnight recordings of intracranial pressure and electroencephalography in neurosurgical patients. Part II: Changes in intracranial pressure during sleep. *J UOEH* 11:383-391, 1989
32. Rijken BF, den Ottelander BK, van Veelen ML, Lequin MH, Mathijssen IM: The occipitofrontal circumference: reliable prediction of the intracranial volume in children with syndromic and complex craniosynostosis. *Neurosurg Focus* 38:E9, 2015

PART 4

Summary and Discussion



CHAPTER 7

General Discussion



This thesis aimed to help clinicians better understand the pathophysiology, diagnosis and treatment of sleep disordered breathing and intracranial hypertension in children with syndromic craniosynostosis.

Implications of results

Over the last few decades, it became clear that obstructive sleep disordered breathing (SDB) is an important condition with severe complications if left untreated, particularly in children with syndromic craniosynostosis. SDB is a syndrome of upper airway dysfunction during sleep characterized by snoring and/or increased respiratory effort that result from increased upper airway resistance and pharyngeal collapsibility. SDB has a number of clinical entities; primary snoring, upper airway resistance, obstructive hypoventilation and obstructive sleep apnea syndrome (OSA) (1,2). Especially the Apert and Crouzon syndromes have a high incidence of OSA due to their facial malformations (3). Earlier studies from our group have already stressed the importance of proper diagnosis and treatment of SDB (3-5).

As SDB and its treatment have been of great interest to our craniofacial center over the last few decades, already in 2006, our center started a longitudinal cohort study including all syndromic craniosynostosis children from our center. The data from this cohort provided us with sufficient information to study the first six years of life in 83 patients and evaluate the treatments they received and their results. Hence, the aim of **chapter 2** was to evaluate the outcome of our OSA-treatment protocol in these children.

The results showed that out of the 32 patients who initially had OSA, 84.4% of the patients were free of OSA after either expectant care or surgical treatment. In contrast to what many would assume, in a large number of patients with mild OSA, and even half of the patients with moderate OSA, the OSA resolved spontaneously. It seems that also in syndromic craniosynostosis, clinicians should take into account the possibility of spontaneous resolution of mild OSA. Especially in infants and toddlers, the chance of spontaneous resolution is high. Natural growth of the airway and a diminished number of pediatric airway infections could resolve the OSA. Clinicians should take this into consideration and might consider a follow-up polysomnography (PSG) to evaluate the evolution of the patient's OSA. In more severe cases the

probability of spontaneous resolution decreases, but is still possible. The decision for surgical treatment should not be based only on one single PSG, but the severity and evolution of the symptoms have to be taken into account in the decision-making.

Concerning surgical treatment, we found that adenotonsillectomy (ATE) had a high success rate of 90% and a low recurrence rate. The success rate of ATE in our study was higher than the reported 60% coming from two earlier studies (6,7). Obviously, ATE will not resolve OSA in all children with syndromic craniosynostosis because the airway obstruction is considered to be at multiple levels in most of the children. In order to properly evaluate the level of obstruction, children with OSA should undergo an evaluation by an Ear-Nose-Throat (ENT) physician, including an upper airway endoscopy to evaluate the level of the airway obstruction (8).

In our patient group, monobloc surgery, possibly in combination with mandibular distraction on indication, was an effective procedure to resolve moderate to severe OSA in six patients. After a median follow-up time of 5.8 years, the treatment has been successful in all patients so far, with a lasting improvement on the airway. The median age of surgery was 2.4 year of age. Earlier studies in the literature reported treating their patients at an older age of 6.3 and 7.8 years old (9,10). Many surgeons in the field prefer to perform a monobloc procedure when the patient is older and assume more stable respiratory outcome because of this timing. Our results, however, show that a monobloc procedure can also be performed at a much younger age, with a high success rate and a low OSA-recurrence rate.

Level 1 polysomnography (PSG) in the syndromic craniosynostosis population, in our center, is done since 2012. With this level 1 PSG, also sleep architecture can be measured. In **chapter 3** we wanted to investigate if surgery for OSA would improve sleep architecture and what the effect of cranial surgery was on patients with ICH. We included 83 children with syndromic craniosynostosis and 35 healthy control subjects. In 19 patients, we were able to do a preoperative to postoperative analysis. The results confirmed that OSA disrupts sleep architecture but ICH does not. The results also showed that surgery for OSA improved sleep architecture, stressing the importance of adequately treating OSA in this population. The effect of surgery for ICH on sleep architecture, on the other hand, was not expected. Children who had

had cranial surgery for ICH had decreased sleep efficiency, sleep quality, and percentage of REM-sleep, while their percentage of N1-sleep increased postoperatively. It was unclear to us what these changes meant and how they were caused. Future research is needed to answer this question.

In our continuous effort to improve sleep diagnostics, we investigated a new parameter in the diagnosis of SDB in **chapter 4** of this thesis, namely heart rate variability (HRV). In our clinical practice, we noticed that the diagnosis of upper airway resistance syndrome (UARS) is notably difficult using our PSG set-up without esophageal manometry, which is the golden standard to measure UARS (11). UARS is characterized by snoring, increased work of breathing, frequent arousals, but no recognizable obstructive events or gas exchange abnormalities (1,2,12,13). Hence, the obstructive apnea hypopnea index (oAHI) on the PSG is lower than 1. The only PSG finding that suggests the presence of UARS is the marked respiratory arrhythmia (RA) seen on the electrocardiogram (ECG). These cardiac changes lead us to believe HRV might be of use to detect the child with UARS based on its ECG.

We included 42 children with syndromic craniosynostosis without OSA or with mild OSA. Children with respiratory arrhythmia (RA) showed a trend toward having more clinical symptoms than those without.

The results of the HRV analysis also showed, in contrast to what we initially expected, that children with RA demonstrated increased parasympathetic activity and no increase in sympathetic activity. An explanation is that the increased intrathoracic pressure occurring with UARS leads to vagal activation by the carotid baroreceptors (14-16). From this study, we concluded that HRV might be an additional tool in the scoring of a PSG, especially in diagnosing UARS.

HRV analysis should be included in the PSG software in order to be able to use it in clinical practice. Automated analysis of the ECG signal can easily be done by a data scientist. Several studies have created machine learning algorithms that automatically extract HRV information from the ECG and can even predict the probability of OSA (17,18). Future research should also implement this in the PSG analysis in syndromic craniosynostosis.

ICH is a frequent and still poorly understood phenomenon in syndromic craniosynostosis. In the second part of this thesis we attempted to further improve our understanding of one of the least understood contributors to ICH, venous hypertension.

In **chapter 5** of this thesis we performed a pilot study with transfontanellar ultrasound. We studied the role of venous outflow patterns of the deep (internal cerebral vein [ICV]) and the superficial (superior sagittal sinus [SSS]) cerebral venous drainage systems. We showed that premature closure of cranial sutures is associated with a decreased SSS flow velocity, but not a decreased ICV velocity. This suggests an effect on the superficial venous drainage rather than on the deep venous drainage. The SSS flow might be limited by the overlying stenotic suture. A study by Hirabuki et al., in patients with achondroplasia and hydrocephalus shows similar results with diminished blood flow velocity in the SSS (19). In a study by Mursch et al., on the other hand, the authors describe an increase in SSS velocity and pulsatility in craniosynostosis patients. However, they performed the ultrasound through the posterior fontanelle and measured the flow at or near the point of obstruction, while we measured the flow just after the obstruction. Blood flow accelerates at the point of obstruction, but rapidly slows down before and after the obstruction. Thus, both studies seem to confirm the hypothesis that the stenotic suture directly influences the underlying sinus and limits the flow.

Children with syndromic craniosynostosis are more likely to have intracranial venous anomalies because of their genetic mutations, although there are many differences between syndromes and even within syndromes (20). Anomalies such as hypoplastic transverse sinuses, persistent fetal sinuses, stenotic jugular foramina, and circulatory important emissary veins are not uncommon (21). Venous hypertension caused by insufficient outflow capacity is thought to be one of the factors contributing to ICH in craniosynostosis (22-24). The emissary veins serve as an overflow mechanism and can compensate for the failure of the regular outflow channels.

In **chapter 6** we attempted to further investigate the role of cerebral veins in ICH. For this study, we cross-sectionally included the MRIs of 105 children. We measured the volumes of the dural sinuses and divided the population into two groups, based on ICH. The results showed that

in children with syndromic craniosynostosis, ICH is associated with an increased volume of the straight sinus, but the total cerebral venous volume is unchanged.

These results confirm our hypothesis that there is involvement of venous blood in ICH. The exact mechanism of venous hypertension, however, is still not understood, but this study might contribute to a better understanding. The increased volume of the straight sinus might indicate a relative obstruction of blood going from the deep venous drainage system to the superficial venous drainage system. Future studies on cerebral hemodynamics are needed to further understand the mechanism of blood drainage and its involvement in ICH.

Inspired by Hayward et al., we have started to construct our unifying theory on the mechanisms involving ICH and OSA (25,26). The findings of this thesis have been added to this theory and are presented in **figure 1**.

Strengths

The first and most important strength of this thesis is the large cohort of children with syndromic craniosynostosis that are prospectively followed in one single institution that is a national referral center in the Netherlands. The size of the cohort of approximately 400 subjects with longitudinal data is unprecedented in the world of syndromic craniosynostosis. This opens the doors to perform more robust statistical analyses than before, allowing the detection of smaller differences between groups and syndromes.

Being a national referral center for the Netherlands, the study cohort in our center exists of all patients being born with syndromic craniosynostosis in our country which minimizes the chance of a selection bias in our study population. The duration of treatment includes the entire youth of these patients and ensures a long follow-up time for all of them. This allows prospective studies in addition to the more commonly performed cross-sectional studies. The long follow-up time in combination with the complexity and diverse presentation of syndromic craniosynostosis resulted in a large amount of diagnostic data at our disposal.

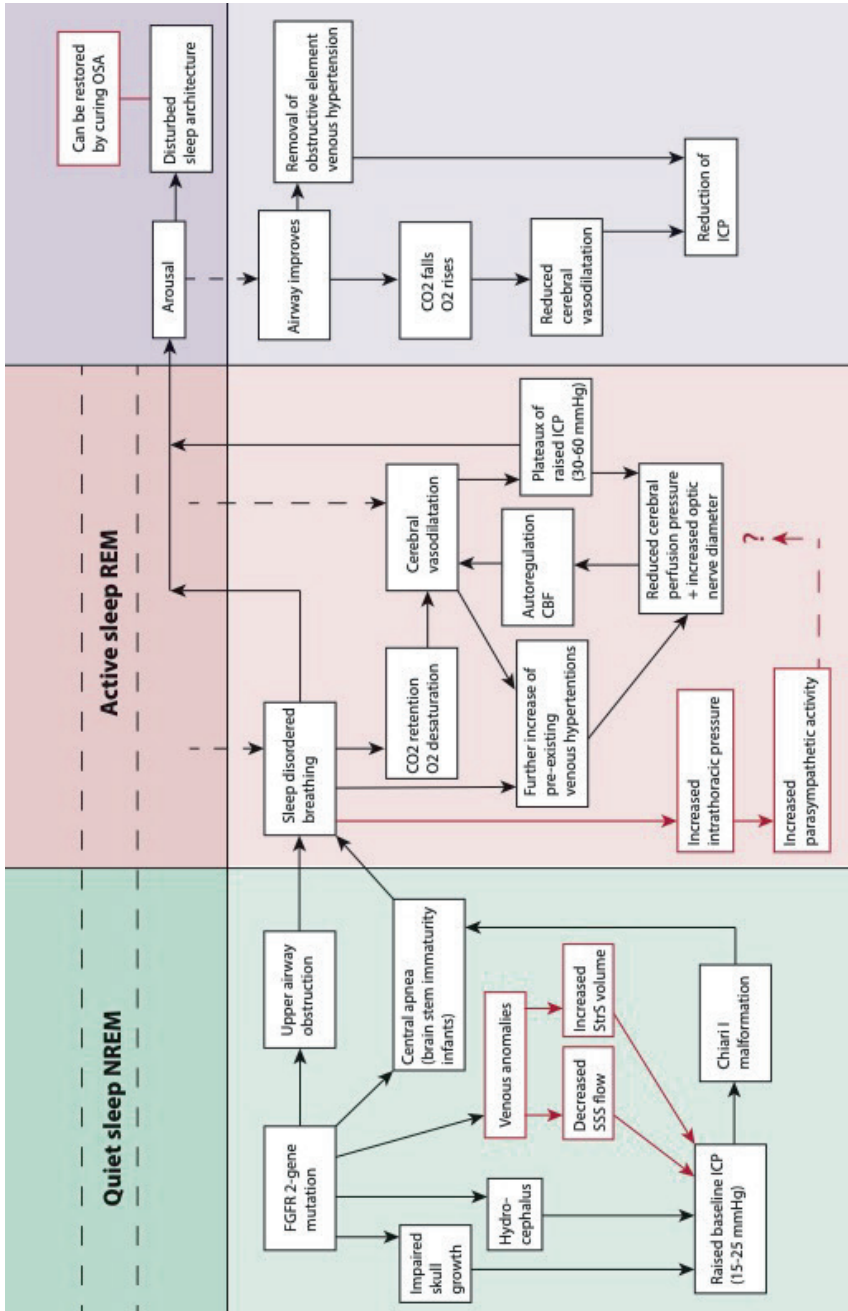


Figure 1: Updated version of the unifying theory concerning intracranial hypertension and sleep disordered breathing in syndromic craniosynostosis. The red boxes indicate what this thesis has added to the theory. Adapted from Spruijt et al. (27).

Considerations

Our studies have its limitations when interpreting the results. One major limitation in our studies was the method of diagnosing ICH. In our current protocol, we regularly screen all the patients with fundoscopies and OCT-scanning and we monitor skull growth by frequently measuring the occipitofrontal head circumference (OFC). When a patient presents with clinical symptoms that might be caused by ICH, the patient undergoes additional fundoscopic screening combined with an MRI. In case the results of these diagnostics are still inconclusive, only then an invasive measurement is considered. For research, the optimal method of diagnosing ICH would be a protocol of regular invasive intracranial pressure (ICP) measurements. However, the invasiveness of an ICP measurement makes this undesirable. Instead, the treating physicians are bound to the use of the protocol explained above. All the studies included in this thesis were confronted with this limitation. However, given the expertise of our physicians in treating craniosynostosis, we are convinced that this protocol is adequate for the detection ICH in this population.

A second limitation is heterogeneity among patients. Syndromic craniosynostosis is a name for a collection of syndromes that have the craniosynostosis in common. However, the syndromes are caused by many different mutations in several genes (28,29). Even within a syndrome, patients can show great differences in presentation of conditions. Crouzon syndrome for example, has a large spectrum of disease presentation. Children with the mildest presentation have virtually no problems other than mild facial malformations, while the most severe presentations may have severe morbidities. This heterogeneity, especially in combination with the low prevalence of syndromic craniosynostosis, also has a negative effect on the generalizability of the results of the projects included in this thesis. The heterogeneity amongst patients also had its effect on the types of treatments, reducing the number of patients with similar diagnoses following a similar treatment protocol.

Lastly, all research in this thesis was based on data from a single center with a standardized treatment protocol of pro-active cranial surgery during infancy in an attempt to prevent ICH. Some centers prefer a more conservative treatment protocol, and only perform

cranial surgery at the first sign of ICH. Also, other centers tend to perform fewer diagnostics, which makes it difficult to compare our outcomes with them.

Conclusion

This thesis focuses on SDB and ICH in syndromic craniosynostosis. SDB in syndromic craniosynostosis is a complex problem and can be caused by obstructions at multiple level. Long-term follow-up and frequent screening is needed to timely detect SDB and to provide the adequate treatment. If treated following our protocol, virtually all cases of SDB can be cured and sleep architecture can be restored. ATE is an important part of the treatment protocol. Monobloc surgery, combined with mandibular distraction in selected cases, can resolve SDB with good long-term results.

A level 1 PSG is the gold standard for the diagnosis of SDB. HRV can be used to better diagnose UARS, and can be used to evaluate the balance of the autonomic nervous system.

Patients with craniosynostosis have several cerebral venous anomalies. The flow velocity in the SSS is decreased in all patients. The straight sinus has an increased volume in children with ICH. Clinicians should keep in mind that children with craniosynostosis can have congenital cerebral venous malformations that may indicate ICH. These malformations, especially clinically important emissary veins, warrant extra caution during cranial vault surgery.

This thesis has added some valuable new insights to the unifying theory of syndromic craniosynostosis, obstructive sleep apnea, and intracranial hypertension.

Future perspectives

The study cohort that started in 2006 is ever growing. Thus, more data is being generated that allow for better analyses and more follow-up time. At the time of writing, in 2020, children being born in 2006 are now 14 years of age. In a few years, the first children will become adults. Future research projects should focus on the long-term outcome of treatments given in the first years of life. Neurocognitive outcomes in adolescents of subjects that have suffered from ICH during childhood have to be studied.

New techniques in neuroimaging should also be used for research in syndromic craniosynostosis. Increasing computing power has led to some new and useful ultrasound modalities (30). Ultrafast Doppler, for example, is a new ultrasound imaging modality using the increased framerate that allows the instantaneous capture of all flow velocities in every pixel of an ultrasound image (31). This technique makes it possible to perform transfontanellar functional ultrasonography (32-35). In syndromic craniosynostosis, it might be interesting to investigate the effect of OSA and ICH on cerebral microcirculation. If this technique could be combined with a PSG, it might just be possible to quantify the changes in micro-perfusion during an apnea or during a plateau-wave of intracranial pressure.

The moment a subject is scheduled for a level 1 PSG, is the moment to add new measurements. Since many channels are already being recorded, the burden of adding a new observation is minimal and makes it easier to combine data from different channels. In this way, a better understanding can be generated of the processes involved in OSA, ICH, and sleep in general. An example of a parameter that can be added is blood pressure. Blood pressure presumably plays a big role in OSA and ICH, but is a parameter that has scarcely been investigated in this population (36,37). Blood pressure changes can be measured by the pulse transit time (PTT), or can be done use continuous blood pressure monitoring using a finger cuff.

Recently, a group from Boston developed a method to non-invasively measure ICP (38). This method combines blood pressure analysis with Transcranial Doppler imaging (TCD) of the middle cerebral artery. The results of this method are promising and give a good estimation of the actual ICP. Adding this method to our level 1 PSG set-up would open up many possibilities in the field of research on ICH in syndromic craniosynostosis.

To be able to arrive at large study cohorts, it is inevitable that research groups should work together. Furthermore, every center has its own treatment protocol. Many parts of those treatment protocols are based on expert opinion, not on extensive research. The single center nature of most studies prevents the comparison of treatment protocols and thus cannot be perfected. Recently, a collaboration of European centers of expertise in craniosynostosis has been formed, The European Reference Network: Craniofacial Anomalies and ENT Disorders. This collaboration is starting a joined European research database of standardized patient-reported

outcome measures and neurocognitive outcomes. This makes it possible to compare outcomes between different centers in different countries and even with different languages. These standard outcome measures will help improve treatment protocols all over the world.

References

1. Kaditis AG, Alonso Alvarez ML, Boudewyns A, Abel F, Alexopoulos EI, Ersu R, et al: ERS statement on obstructive sleep disordered breathing in 1- to 23-month-old children. *Eur Respir J* 50, 2017
2. Kaditis AG, Alonso Alvarez ML, Boudewyns A, Alexopoulos EI, Ersu R, Joosten K, et al: Obstructive sleep disordered breathing in 2- to 18-year-old children: diagnosis and management. *Eur Respir J* 47:69-94, 2016
3. Driessen C, Joosten KF, Bannink N, Bredero-Boelhouwer HH, Hoeve HL, Wolvius EB, et al: How does obstructive sleep apnoea evolve in syndromic craniosynostosis? A prospective cohort study. *Arch Dis Child* 98:538-543, 2013
4. Bannink N, Mathijssen IM, Joosten KF: Can parents predict obstructive sleep apnea in children with syndromic or complex craniosynostosis? *Int J Oral Maxillofac Surg* 39:421-423, 2010
5. Bannink N, Nout E, Wolvius EB, Hoeve HL, Joosten KF, Mathijssen IM: Obstructive sleep apnea in children with syndromic craniosynostosis: long-term respiratory outcome of midface advancement. *Int J Oral Maxillofac Surg* 39:115-121, 2010
6. Amonoo-Kuofi K, Phillips SP, Randhawa PS, Lane R, Wyatt ME, Leighton SE: Adenotonsillectomy for sleep-disordered breathing in children with syndromic craniosynostosis. *J Craniofac Surg* 20:1978-1980, 2009
7. Willington AJ, Ramsden JD: Adenotonsillectomy for the management of obstructive sleep apnea in children with congenital craniosynostosis syndromes. *J Craniofac Surg* 23:1020-1022, 2012
8. Doerga PN, Spruijt B, Mathijssen IM, Wolvius EB, Joosten KF, van der Schroeff MP: Upper airway endoscopy to optimize obstructive sleep apnea treatment in Apert and Crouzon syndromes. *J Craniomaxillofac Surg* 44:191-196, 2016
9. Glover CD, Fernandez AM, Huang H, Derderian C, Binstock W, Reid R, et al: Perioperative outcomes and management in midface advancement surgery: a multicenter observational descriptive study from the Pediatric Craniofacial Collaborative Group. *Paediatr Anaesth* 28:710-718, 2018
10. Mathijssen I, Arnaud E, Marchac D, Mireau E, Morisseau-Durand MP, Guerin P, et al: Respiratory outcome of mid-face advancement with distraction: a comparison between Le Fort III and frontofacial monobloc. *J Craniofac Surg* 17:880-882, 2006
11. Arnold WC, Guilleminault C: Upper airway resistance syndrome 2018: non-hypoxic sleep-disordered breathing. *Expert Rev Respir Med* 13:317-326, 2019
12. Guilleminault C, Stoohs R, Clerk A, Cetel M, Maistros P: A cause of excessive daytime sleepiness. The upper airway resistance syndrome. *Chest* 104:781-787, 1993
13. Guilleminault C, Khramtsov A: Upper airway resistance syndrome in children: a clinical review. *Semin Pediatr Neurol* 8:207-215, 2001
14. Hirsch JA, Bishop B: Respiratory sinus arrhythmia in humans: how breathing pattern modulates heart rate. *Am J Physiol* 241:H620-629, 1981
15. Katona PG, Jih F: Respiratory sinus arrhythmia: noninvasive measure of parasympathetic cardiac control. *J Appl Physiol* 39:801-805, 1975

16. Salsone M, Vescio B, Quattrone A, Rocchia F, Sturniolo M, Bono F, et al: Cardiac parasympathetic index identifies subjects with adult obstructive sleep apnea: A simultaneous polysomnographic-heart rate variability study. *PLoS One* 13:e0193879, 2018
17. Nakayama C, Fujiwara K, Matsuo M, Kano M, Kadotani H: Development of sleep apnea syndrome screening algorithm by using heart rate variability analysis and support vector machine. *Conf Proc IEEE Eng Med Biol Soc* 2015:8165-8168, 2015
18. Nakayama C, Fujiwara K, Sumi Y, Matsuo M, Kano M, Kadotani H: Obstructive sleep apnea screening by heart rate variability-based apnea/normal respiration discriminant model. *Physiol Meas* 40:125001, 2019
19. Hirabuki N, Watanabe Y, Mano T, Fujita N, Tanaka H, Ueguchi T, et al: Quantitation of flow in the superior sagittal sinus performed with cine phase-contrast MR imaging of healthy and achondroplastic children. *AJNR Am J Neuroradiol* 21:1497-1501, 2000
20. Tischfield MA, Robson CD, Gilette NM, Chim SM, Sofela FA, DeLisle MM, et al: Cerebral Vein Malformations Result from Loss of Twist1 Expression and BMP Signaling from Skull Progenitor Cells and Dura. *Dev Cell* 42:445-461 e445, 2017
21. Florisson JM, Barmpalios G, Lequin M, van Veelen ML, Bannink N, Hayward RD, et al: Venous hypertension in syndromic and complex craniosynostosis: the abnormal anatomy of the jugular foramen and collaterals. *J Craniomaxillofac Surg* 43:312-318, 2015
22. Copeland AE, Hoffman CE, Tsitouras V, Jeevan DS, Ho ES, Drake JM, et al: Clinical Significance of Venous Anomalies in Syndromic Craniosynostosis. *Plast Reconstr Surg Glob Open* 6:e1613, 2018
23. Jeevan DS, Anlsow P, Jayamohan J: Abnormal venous drainage in syndromic craniosynostosis and the role of CT venography. *Childs Nerv Syst* 24:1413-1420, 2008
24. Sainte-Rose C, LaCombe J, Pierre-Kahn A, Renier D, Hirsch JF: Intracranial venous sinus hypertension: cause or consequence of hydrocephalus in infants? *J Neurosurg* 60:727-736, 1984
25. Spruijt B, Joosten KF, Driessen C, Rizopoulos D, Naus NC, van der Schroeff MP, et al: Algorithm for the Management of Intracranial Hypertension in Children with Syndromic Craniosynostosis. *Plast Reconstr Surg* 136:331-340, 2015
26. Hayward R: Venous hypertension and craniosynostosis. *Childs Nerv Syst* 21:880-888, 2005
27. Spruijt B, Mathijssen IM, Bredero-Boelhouwer HH, Cherian PJ, Corel LJ, van Veelen ML, et al: Sleep Architecture Linked to Airway Obstruction and Intracranial Hypertension in Children with Syndromic Craniosynostosis. *Plast Reconstr Surg* 138:1019e-1029e, 2016
28. Johnson D, Wilkie AO: Craniosynostosis. *Eur J Hum Genet* 19:369-376, 2011
29. Twigg SR, Wilkie AO: New insights into craniofacial malformations. *Hum Mol Genet* 24:R50-59, 2015
30. de Goederen R, Vos HJ, de Jong N, Horsch S, Dudink J: Future applications of advanced neonatal cerebral ultrasound. *Paediatrics and Child Health* 28:28-33, 2018
31. Tanter M, Fink M: Ultrafast imaging in biomedical ultrasound. *IEEE Trans Ultrason Ferroelectr Freq Control* 61:102-119, 2014
32. Osmanski BF, Pezet S, Ricobaraza A, Lenkei Z, Tanter M: Functional ultrasound imaging of intrinsic connectivity in the living rat brain with high spatiotemporal resolution. *Nat Commun* 5:5023, 2014
33. Mace E, Montaldo G, Cohen I, Baulac M, Fink M, Tanter M: Functional ultrasound imaging of the brain. *Nat Methods* 8:662-664, 2011
34. Mace E, Montaldo G, Osmanski BF, Cohen I, Fink M, Tanter M: Functional ultrasound imaging of the brain: theory and basic principles. *IEEE Trans Ultrason Ferroelectr Freq Control* 60:492-506, 2013
35. Errico C, Osmanski BF, Pezet S, Couture O, Lenkei Z, Tanter M: Transcranial functional ultrasound imaging of the brain using microbubble-enhanced ultrasensitive Doppler. *Neuroimage* 124:752-761, 2015

36. Nisbet LC, Yiallourou SR, Biggs SN, Nixon GM, Davey MJ, Trinder JA, et al: Preschool children with obstructive sleep apnea: the beginnings of elevated blood pressure? *Sleep* 36:1219-1226, 2013
37. Nisbet LC, Nixon GM, Yiallourou SR, Biggs SN, Davey MJ, Trinder J, et al: Sleep-disordered breathing does not affect nocturnal dipping, as assessed by pulse transit time, in preschool children: evidence for early intervention to prevent adverse cardiovascular effects? *Sleep Med* 15:464-471, 2014
38. Fanelli A, Vonberg FW, LaRovere KL, Walsh BK, Smith ER, Robinson S, et al: Fully automated, real-time, calibration-free, continuous noninvasive estimation of intracranial pressure in children. *J Neurosurg Pediatr*:1-11, 2019

CHAPTER 8

Summary



The aim of this thesis is to better understand pathophysiology and treatment of sleep disordered breathing and intracranial hypertension in children with syndromic craniosynostosis.

Part 1: Chapter 1 is an introduction to all aspects involved in this thesis. Premature fusion of the cranial sutures leads to anatomic malformations of the skull, known as craniosynostosis. It is a rare disorder occurring in 7.2 per 10,000 births. Syndromic forms of craniosynostosis are even rarer, occurring in 0.9 per 10,000 births. The most commonly known forms of syndromic craniosynostosis are Apert, Crouzon, Muenke, and Saethre-Chotzen syndrome. Due to facial malformations at multiple levels in the airway, children with syndromic forms of craniosynostosis have a great risk of developing SDB, up to 68% in some syndromes.

SDB is a syndrome of upper airway dysfunction during sleep characterized by snoring and/or increased respiratory effort that result from increased upper airway resistance and pharyngeal collapsibility. SDB has a number of clinical entities: primary snoring, upper airway resistance syndrome, obstructive hypoventilation, and obstructive sleep apnea syndrome (OSA). Diagnosing SDB can be done by questionnaires, but the gold standard is performing a polysomnography (PSG). Using a PSG, the apnea-hypopnea index can be calculated, and is used for the classification of the OSA severity. Variables such as heart rate variability (HRV) and sleep architecture analysis offer to investigate sleep more in depth. HRV can be used to investigate the autonomic nervous system's balance (i.e., sympathetic and parasympathetic activity). Sleep architecture analysis is used to measure sleep quality and the division of rapid eye movement (REM) sleep and other sleep stages during the night.

Given the high morbidity of SDB, it is important to adequately treat children who suffer from it. Treatment can be non-surgical (e.g., nasal corticosteroids, nasal oxygen support, or continuous positive airway pressure [CPAP]), or it can be surgical (e.g., adenotonsillectomy, mandibular advancement, tracheal cannulation, or midface advancement surgery).

A second major complication in children with syndromic craniosynostosis is ICH. In Apert syndrome, the prevalence can be as high as 83%. Several theories on the development of ICH exist. Craniocerebral disproportion caused by skull growth arrest while the brain continues to grow may cause a rise in intracranial pressure. Furthermore, venous hypertension due to

impaired outflow capabilities caused by embryological defects of the cerebral venous system may lead to ICH. Similarly, apneas that characterize OSA cause elevated blood pressure and decreases in pO_2 and increases in pCO_2 . This leads to cerebral vasodilation and leads to an increase in arterial cerebral blood flow, which in turn increases the intracranial pressure. Lastly, ICH can be caused by cerebrospinal fluid (CSF) outflow obstruction or disrupted resorption.

Part 2 of this thesis focusses on SDB, its treatment and its diagnosis. **Chapter 2** describes a study that evaluates the long-term effectiveness of our institute's OSA-treatment protocol. All children with syndromic craniosynostosis that have at least 6 years of follow-up and who have undergone a polysomnography are included in this study. The results show that expectant care is often sufficient to resolve mild OSA, as 75% resolves spontaneously. Also in moderate OSA, 50% has spontaneous resolution. Adenotonsillectomy is successful in 90% of all patients treated, making adenotonsillectomy an important part of the OSA-treatment. Monobloc surgery, often combined with an adenotonsillectomy or mandibular distraction, is successful in all patients at a median follow-up time of 5.8 years.

Chapter 3 describes a study investigating sleep architecture derived from all level 1 PSGs made in children with syndromic craniosynostosis treated in our center. This study describes the usefulness of sleep architecture analysis in detecting disturbed sleep and investigates whether surgical treatment can improve it. The results show that OSA disrupts sleep architecture, but ICH does not. Linear-mixed models show that an increase in obstructive-apnea/hypopnea index (oAHI) is significantly associated with an increase in aberrant sleep characteristics such as a decrease in REM-sleep and sleep quality. In a subset of 19 patients, linear regression models illustrate that OSA-indicated surgery significantly increases the total sleep time and sleep efficiency and decreases the arousal index and respiratory-arousal index, stressing the importance of treating OSA to assure adequate sleep. ICH-indicated surgery, on the other hand, significantly decreases REM-sleep, N1-sleep, sleep efficiency, and sleep quality, although it is not clear whether this is a positive or negative effect.

In **Chapter 4**, in a subset of patients with craniosynostosis, the usefulness of HRV analysis in distinguishing the patients with UARS and primary snoring is investigated. The primary snoring

group and UARS group are divided based on the presence of marked respiratory arrhythmia, characterizing UARS. The results show that children with UARS show a greater total power (i.e., greater variance in heart rate) and more parasympathetic activity than children with primary snoring during non-REM sleep. This effect is probably explained by the increased vagal stimulation caused by the increased intrathoracic pressure in children with UARS. Finding a way to incorporate HRV analysis in the standard PSG analysis might help to identify patients with UARS.

Part 3 focusses on our further understanding of the pathophysiological processes involved in ICH, further building our unifying theory on intracranial hypertension and obstructive sleep apnea in syndromic craniosynostosis. **Chapter 5** describes a prospective pilot study on cerebral venous flow velocities examined by transfontanellar ultrasound.

Preoperatively, the flow velocity in the superior sagittal sinus (SSS) of children with craniosynostosis is significantly lower than in controls. However, the flow velocity in the internal cerebral vein (ICV) is not significantly different between patients and controls, indicating an effect on the superficial rather than deep venous drainage. Postoperatively, the flow velocity in the SSS increases significantly.

Chapter 6 focusses on the abnormal venous anatomy and its involvement in ICH in syndromic craniosynostosis. T2-weighted 3D MRI scans with isometric voxels are used to quantitatively measure the cerebral blood volume of the SSS, the straight sinus (StrS) and both transverse sinuses (TS). Linear regression shows that the total cerebral venous volume linearly correlates with the occipitofrontal head circumference. ICH does not have an effect on total cerebral venous volume. However, multivariate analysis of variance shows that ICH is associated with an increased StrS volume. Every 100-mm³ increase in StrS volume is associated with increased odds of having intracranial hypertension by 60%. It is unlikely that general cerebral venous outflow obstruction is the mechanism of intracranial hypertension in syndromic craniosynostosis. Rather, these findings indicate either a central cerebral vulnerability to ICH or a mechanism involving venous blood redistribution, possibly through hemodynamically important emissary veins.

In **Chapter 7**, the results described in this thesis are discussed. SDB occurs frequently in children with syndromic craniosynostosis, which warrants intensive follow-up. Thoroughly examining every individual case of SDB and localizing the level(s) of obstruction allows for the adequate treatment choice. The results of treating OSA are good on the long-term. Children with OSA have disturbed sleep architecture, but adequately treating the OSA also restores the sleep architecture to normal. HRV analysis has proven useful in identifying the patient with UARS and can be add as an additional tool. Cerebral venous anomalies play a part in the development of ICH in syndromic craniosynostosis. This thesis has added further knowledge in our understanding the pathophysiology of obstructive sleep apnea and intracranial hypertension and their interaction.

CHAPTER 9

Nederlandse samenvatting



Het doel van dit proefschrift is om de pathofysiologie van slaapafhankelijke ademhalingsstoornissen (SAAS) en intracranieële hypertensie bij kinderen met syndromale craniosynostose beter te begrijpen.

The aim of this thesis is to better understand pathophysiology and treatment of sleep disordered breathing and intracranial hypertension in children with syndromic craniosynostosis.

Deel 1: Hoofdstuk 1 is een introductie voor alle aspecten uit dit proefschrift. Vroegtijdige sluiting van de schedelnaden leidt tot een anatomische misvorming van de schedel, die craniosynostose wordt genoemd. Het is een zeldzame aandoening die bij 7,2 van de 10.000 geboortes voorkomt. De syndromale vormen van craniosynostose zijn nog zeldzamer, die komen slechts bij 0,9 van de 10.000 geboortes voor. De meest voorkomende vormen van craniosynostose zijn het Apert, Crouzon, Muenke en het Saethre-Chotzen syndroom. Door misvormingen op meerdere niveaus van de luchtweg hebben kinderen met een syndromale vorm van craniosynostose een groot risico om SAAS te ontwikkelen. Bij sommige syndromen is de prevalentie van SAAS wel 68%.

SAAS is een syndroom van bovenste luchtweg dysfunctie tijdens slaap dat wordt gekarakteriseerd door verhoogde weerstand in de bovenste luchtweg en het dichtvallen van de farynx die zorgen voor snurken en/of verhoogde inspiratoire inspanning. SAAS kan worden onderverdeeld in een aantal klinische beelden: primair snurken, Upper Airway Resistance Syndrome (UARS), obstructieve hypoventilatie en obstructief slaap apneu syndroom (OSA). Het diagnosticeren van SAAS kan worden gedaan door middel van vragenlijsten, maar de gouden standard is het uitvoeren van een polysomnografie (PSG). Met een PSG kan de apneu-hypopneu index worden berekend die wordt gebruikt om de ernst van de OSA te bepalen. Variabelen zoals Heart Rate Variability (HRV) en slaap architectuur analyse kunnen worden gebruikt om slaap nog beter te analyseren. Door middel van HRV kan de balans van het autonome zenuwstelsel worden onderzocht (sympathische en parasympathische activiteit). Sleep architectuur analyse wordt gebruikt om de slaap kwaliteit en de verdeling Rapid Eye Movement (REM) slaap en andere slaapstadia te bepalen.

Aangezien SAAS een hoge morbiditeit heeft, is het belangrijk om kinderen met SAAS adequaat te behandelen. De behandeling kan niet-chirurgisch zijn, voorbeelden hiervan zijn nasale corticosteroïden, nasale zuurstof ondersteuning, of Continuous Positive Airway Pressure (CPAP). SAAS kan ook chirurgisch worden behandeld met bijvoorbeeld een adenotonsillectomie (ATE), mandibulaire distractie, een trachea canule, of een distractie van het middegezicht.

Een tweede belangrijke complicatie bij kinderen met syndromale craniosynostose is ICH. Bij het Apert syndroom is de prevalentie van ICH maar liefst 83%. Er bestaan verschillende theorieën over het ontstaan van ICH. De eerste is craniocerebrale disproportie die ontstaat door het afremmen van de schedelgroei terwijl de hersenen wel doorgroeien, waardoor een relatief ruimtegebrek ontstaat en daardoor de intracranieële druk oploopt. Verder is er de theorie van veneuze hypertensie door belemmerde veneuze afvoer die ontstaat door embryologische aanlegstoornissen van het cerebrale veneuze systeem die kan leiden tot ICH. Zo kan ook OSA leiden tot ICH. Door de apneus stijgt de bloeddruk en de hoeveelheid CO₂ in het bloed, terwijl de hoeveelheid zuurstof in het bloed daalt. De toename van CO₂ en afname van zuurstof zorgen voor vasodilatatie in het brein, wat leidt tot een toename van arteriële bloedinstroom. Dit alles zorgt ervoor dat de druk in de schedel stijgt. Als laatste kan ICH worden veroorzaakt door belemmering van de liquor drainage of door een verminderde resorptie.

Deel 2 van dit proefschrift richt zich op SAAS, de behandeling en de diagnose. **Hoofdstuk 2** beschrijft een studie naar de effectiviteit van het OSA-behandelprotocol van ons centrum op de lange termijn. Alle kinderen met syndromale craniosynostose die minstens 6 jaar follow-up hebben en een PSG hebben ondergaan worden in deze studie geïnccludeerd. De resultaten laten zien dat een expectatieve behandeling vaak voldoende is om milde OSA te behandelen; 75% geneest spontaan. Ook bij de matig-ernstige OSA geneest 50% van de kinderen spontaan. ATE is succesvol bij 90% van alle behandelde patiënten, wat maakt dat ATE een belangrijk onderdeel is van het OSA-behandelprotocol. Monobloc chirurgie, vaak gecombineerd met een ATE of mandibulaire distractie, is succesvol in alle patiënten met een mediane follow-up duur van 5,8 jaar.

Hoofdstuk 3 beschrijft een studie naar slaap architectuur, afgeleid van alle level 1 PSG's die zijn gemaakt bij kinderen met syndromale craniosynostose die in ons centrum zijn behandeld. Deze studie beschrijft het nut van slaap architectuur analyse om verstoorde slaap te detecteren en onderzoekt of chirurgische behandeling het kan verbeteren. De resultaten laten zien dat OSA de slaap architectuur verstoort en dat ICH dat niet doet. Uit een linear-mixed model analyse blijkt dat een toename in obstructieve apneu-hypopneu index (oAHI) significant gerelateerd is aan een toename van verstoorde slaap variabelen zoals een vermindering van de slaapkwaliteit en een vermindering van de hoeveelheid REM-slaap. Uit een sub-analyse van 19 patiënten blijkt dat OSA-geïndiceerde chirurgie de totale slaaptijd significant verlengt, de slaapefficiëntie verhoogt en de hoeveelheid arousals en respiratoire arousals vermindert. Hieruit blijkt dat het belangrijk is om OSA adequaat te behandelen. Echter, chirurgie met ICH als indicatie vermindert de slaapkwaliteit, de slaapefficiëntie, de hoeveelheid REM-slaap en de hoeveelheid N1-slaap. Het is onduidelijk of dit een positief of negatief effect is.

Het nut van HRV-analyse bij het onderscheiden van kinderen die primair snurken van kinderen met UARS wordt beschreven in **Hoofdstuk 4**. De groepen primair snurken en UARS worden onderverdeeld op basis van de aanwezigheid van respiratoire aritmie, iets wat karakteristiek is voor UARS. Uit de resultaten blijkt dat kinderen met UARS een grotere "total power" hebben (een grotere variantie van het hartritme) en meer parasymphatische activiteit dan kinderen met primair snurken. Dit effect kan waarschijnlijk worden verklaard door een toegenomen vagale stimulatie die wordt veroorzaakt door de toegenomen intrathoracale druk bij kinderen met UARS. Het toevoegen van HRV-analyse aan de standaard PSG kan helpen patiënten met UARS te herkennen.

Deel 3 concentreert zich op het beter begrijpen van de pathofysiologie van ICH in craniosynostose. **Hoofdstuk 5** beschrijft een prospectieve studie naar cerebrale veneuze stroomsnelheden door middel van echo-Doppler. Preoperatief zijn de stroomsnelheden in de sinus sagittalis superior (SSS) significant lager bij kinderen met craniosynostose dan bij gezonde controles. De stroomsnelheid in de vena cerebri interna (ICV) is echter niet significant verschillend tussen patiënten en controles. Dit duidt op een probleem dat met name effect heeft

op het oppervlakkige systeem en niet op het diepe systeem. Postoperatief neemt de snelheid in de SSS weer significant toe.

Hoofdstuk 6 richt zich op de abnormale anatomie en zijn rol in het ontstaan van ICH bij kinderen met syndromale craniosynostose. T2-gewogen 3D MRI-scans met isometrische voxels worden gebruikt om het cerebrale bloedvolume van de SSS, de sinus rectus (StrS) en beide sinus transversa (TS) te kwantificeren. Uit Lineaire regressie blijkt dat het totale cerebraal veneuze volume recht evenredig is aan de schedelomtrek. ICH heeft geen effect op het totale cerebraal veneuze volume. ICH is echter wel geassocieerd met een toegenomen StrS volume. Elke 100 mm³ toename van het StrS volume gaat gepaard met een 60% toename van de kans op het hebben van ICH. Concluderend lijkt het onwaarschijnlijk dat gegeneraliseerde veneuze afvoedbelemmering het mechanisme achter ICH is in syndromale craniosynostose. De resultaten lijken er meer op te wijzen dat het centrale deel van de hersenen vatbaarder is voor ICH. Of er moet sprake zijn van een mechanisme van herverdeling van bloed, mogelijk door hemodynamisch belangrijke collateralen.

In **Hoofdstuk 7** worden de resultaten uit dit proefschrift besproken. SAAS komt vaak voor bij kinderen met syndromale craniosynostose, reden voor intensieve follow-up. Bij elk geval van SAAS moet grondig worden onderzocht welke niveaus van de luchtweg betrokken zijn om een adequate behandeling te kunnen kiezen. De lange termijn resultaten van de OSA-behandeling zijn goed. Kinderen met OSA hebben een verstoorde slaap architectuur, maar adequate behandeling van de OSA kan dit herstellen. HRV-analyse is nuttig gebleken bij de diagnose van kinderen met UARS en kan worden gebruikt als nieuw diagnosticum. Cerebraal veneuze aanlegstoornissen spelen een rol in de ontwikkeling van ICH bij kinderen met syndromale craniosynostose. Dit proefschrift heeft ervoor gezorgd dat we meer zijn gaan begrijpen over de pathofysiologie omtrent obstructief slaap apneu en intracranieële hypertensie en hun interactie.

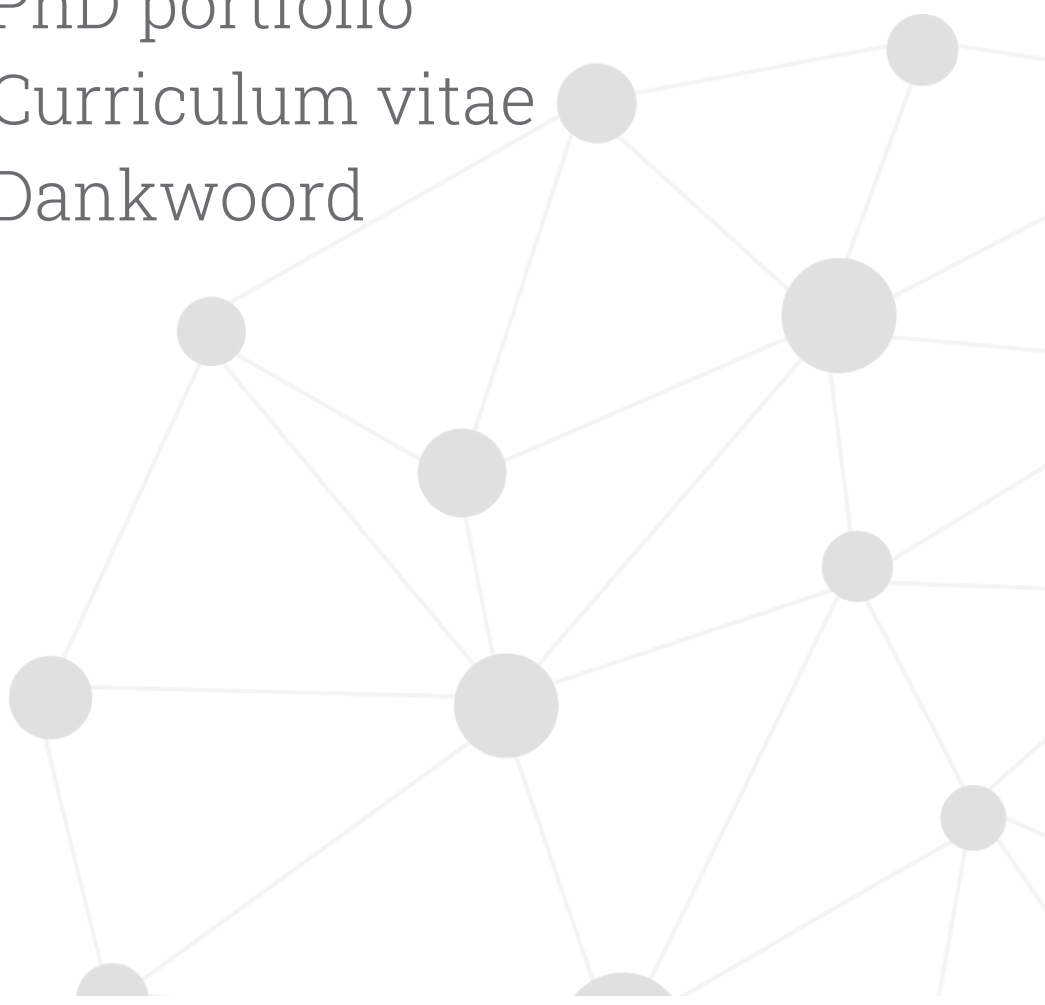APPENDICES

List of publications

PhD portfolio

Curriculum vitae

Dankwoord



List of publications

Sleep related breathing disorders and indications for polysomnography in preterm infants.

Joosten K, **de Goederen R**, Pijpers A, Allegaert K.

Early human development. 2017;113:114-9.

Effect of Preterm Birth on Echogenicity in Basal Ganglia.

De Goederen R, Raets MMA, Ecury-Goossen GM, de Jonge RCJ, Ramenghi LA, Koning IV, et al.

Ultrasound in medicine & biology. 2017;43(10):2192-9.

Letter to the Editor: Raised intracranial pressure and cognitive delay in craniosynostosis.

Mathijssen I, **de Goederen R**, Versnel SL, Joosten KFM, van Veelen MC, Tasker RC.

Journal of neurosurgery Pediatrics. 2017:1-5.

Future applications of advanced neonatal cerebral ultrasound.

De Goederen R, Vos HJ, de Jong N, Horsch S, Dudink J.

Paediatrics and Child Health. 2018;28(1):28-33.

Electrocardiographic variables in children with syndromic craniosynostosis and primary snoring to mild obstructive sleep apnea: significance of identifying respiratory arrhythmia during sleep.

Kakar E, Corel LJA, Tasker RC, **de Goederen R**, Wolvius EB, Mathijssen IMJ, et al.

Sleep Med. 2018;45:1-6.

Pilot study of intracranial venous physiology in craniosynostosis.

Cornelissen MJ, **de Goederen R**, Doerga P, Cuperus I, van Veelen ML, Lequin M, et al.

Journal of neurosurgery Pediatrics. 2018:1-6.

Muenke syndrome: long-term outcome of a syndrome-specific treatment protocol.

Den Ottelander BK, **de Goederen R**, van Veelen MC, van de Beeten SDC, Lequin MH, Dremmen MHG, et al.

Journal of neurosurgery Pediatrics. 2019:1-8.

Improvement in Sleep Architecture is associated with the Indication of Surgery in Syndromic Craniosynostosis.

De Goederen R, Joosten KFM, den Ottelander BK, van der Oest MJW, Broker-Schenk EMM, van Veelen MC, et al.

Plast Reconstr Surg Glob Open. 2019;7(9):e2419.

Dural sinus volume in children with syndromic craniosynostosis and intracranial hypertension.

De Goederen R, Cuperus IE, Tasker RC, den Ottelander BK, Dremmen MHG, van Veelen MC, et al.

Journal of neurosurgery Pediatrics. 2020:1-8.

Intracranial hypertension and cortical thickness in syndromic craniosynostosis.

Wilson AT, den Ottelander BK, **de Goederen R**, Van Veelen MC, Dremmen MHG, Persing JA, et al.

Developmental medicine and child neurology. 2020.

Diagnostic and predictive value of Doppler ultrasound for evaluation of the brain circulation in preterm infants: a systematic review.

Camfferman FA, **de Goederen R**, Govaert P, Dudink J, van Bel F, Pellicer A, et al.

Pediatric research. 2020;87(Suppl 1):50-8.

PhD portfolio

Name PhD student: Robbin de Goederen
 Erasmus MC department: Plastic and Reconstructive surgery, and Hand surgery
 PhD period: October 2016 – March 2020
 Promotors: Prof.dr. I.M.J. Mathijssen
 Prof.dr. K.F.M. Joosten

PhD training	Year	ECTS
General academic skills		
Basiscursus Regelgeving en Organisatie (BROK), <i>Erasmus University Medical Center, Rotterdam</i>	2017	1
Scientific integrity course, <i>Erasmus University Medical Center, Rotterdam</i>	2017	0.3
Endnote course, <i>Erasmus University Medical Center, Rotterdam</i>	2017	0.3
OpenClinica course <i>Erasmus University Medical Center, Rotterdam</i>	2017	0.3
Gemstracker course, <i>Erasmus University Medical Center, Rotterdam</i>	2017	0.3
Biomedical English writing and communication, <i>Erasmus University Medical Center, Rotterdam</i>	2018-2019	4

In-depth courses

Scoren van respiratoire slaap events, <i>Sleep vision, Nijmegen</i>	2019	0.3
Neurovascular ultrasound course, <i>Wake Forest Medical Center, Winston Salem, NC, USA</i>	2018	1
R-statistical programming course, <i>Datacamp</i>	2018	1
Programming with Python, <i>Datacamp</i>	2018	1

Presentations

Improvement in Sleep Architecture is associated with the Indication of Surgery in Syndromic Craniosynostosis ISCSFS meeting, <i>Cancun, Mexico</i>	2017	1
OSA in syndromic craniosynostosis ACE AAA meeting, <i>Erasmus University Medical Center, Rotterdam</i>	2018	0.3

Conference attendance

European Reference Network meeting, <i>Erasmus University Medical Center, Rotterdam</i>	2017	0.3
OSG-user meeting, <i>Antwerpen, Belgium</i>	2017	0.3
PhD-day, <i>Erasmus University Medical Center, Rotterdam</i>	2019	0.3

Lecturing

Dysmorphologie lecture 3 rd year medical students, <i>Erasmus University Medical Center, Rotterdam</i>	2017-2019	3
Neuro-embryology, <i>Erasmus University College, Rotterdam</i>	2018-2020	3

Supervision

2 nd year medical students, Erasmus MC, <i>OSA-sleep questionnaires in craniosynostosis</i>	2017	1
Iris Cuperus, Erasmus MC, <i>Venous hypertension in syndromic craniosynostosis</i>	2018	5
Pleun van der Plas, Erasmus MC, <i>Mandibular length in Pierre Robin sequence</i>	2018	5
Maria Silos Viu, TU Delft, <i>Non-contact sleep analysis in children</i>	2018	3
Kevin Cinca, Erasmus MC, <i>PSQ in craniosynostosis</i>	2019	1
Shijing Pu, TU Eindhoven, <i>Non-contact sleep analysis in children</i>	2019	3

Committee boardmanship

Honours Class alumni vereniging	2016-2017	0.3
Educational committee, Sophia onderzoekers vertegenwoordiging (SOV)	2017-2019	2
Promeras, promovendi vertegenwoordiging	2018-2019	2

Other

Redesigning OpenClinica Database, <i>Erasmus University Medical Center, Rotterdam</i>	2018-2019	4
Use Case Craniosynostose, I&T department, <i>Erasmus University Medical Center, Rotterdam</i>	2019	1

Curriculum vitae

Robbin de Goederen was born in Rotterdam, the Netherlands (29-01-1991) and raised in Oud-Beijerland. He graduated from the Gymnasium at the RSG Hoeksche Waard in 2009. In the meantime, he was selected to attend the Junior Med School at the Erasmus MC in 2007. It was there he became passionate about medicine and started his education at the medical faculty of the Erasmus MC directly after high school. He was selected to join the Honours Class during his first year. During his medical training, he started research projects in the Neonatology department and started making cerebral ultrasound scans under supervision of Jeroen Dudink. For his master thesis, he continued in the field of cerebral ultrasound in the Gaslini Children's hospital in Genoa, Italy during a 5-month period (Luca A. Ramenghi). After graduating his medical training, he was directly accepted as a PhD student under the supervision of Irene Mathijssen and Koen Joosten. He was then accepted as resident not in training in the department of Pediatrics of the Meander hospital in Amersfoort.



Dankwoord

Professor Mathijssen en professor Joosten, Irene en Koen, bedankt voor jullie supervisie gedurende mijn promotie. Bedankt dat jullie me scherp hielden en alleen akkoord gingen met het allerbeste. Het was altijd fijn dat jullie heel snel waren met feedback geven, dit hoefde nooit langer te duren dan een paar dagen, jullie hebben een hoop tijd in mij gestopt. Koen, heel erg bedankt voor de vele brainstorm momenten aan jouw tafeltje. Je hebt heel veel voor me gedaan, bedankt daarvoor. Verdiend professor.

Onderzoekers van de plastische, verloren en weggestopt op 15-hoog-achter waren we lotgenoten. Kapotte liften, oude meubels en overal kasten. Mede dankzij onze sloffen was dat een stuk beter te doen. We hebben aardig wat avonden, nachten en weekenden op de 15^e doorgebracht. De maandelijkse decadente lunch heeft ons aardig wat goede restaurants in Rotterdam doen leren kennen en hield het moraal hoog. Ik hoop dat jullie nog veel mooie dingen doen met zijn allen en ik wens jullie het allerbeste!

Cranio-onderzoekers, uiteraard ook nog speciale aandacht voor jullie. We waren echt een team. We hebben onze eigen cranio bijeenkomsten georganiseerd om elkaar bij te staan en te ondersteunen. Hierdoor was het niet ieder voor zich, maar konden we elkaar ondersteunen. Priya, Bianca, Hansje en Steph, wat een mooie vakantie hebben we achter het congres in Mexico geplakt. Hansje heeft ons hier het belang van het limoentje nog maar eens fijn uitgelegd. Dat zullen we nooit vergeten.

Hansje, Miranda, Elin, Jacoba, en Mariska, zonder jullie ondersteuning wordt het niets. Bedankt voor de vele kletsmomentjes en het PSG's beoordelen samen. Hansje, geniet van je welverdiende pensioen, bedankt voor alles wat je voor de cranio-kinderen hebt gedaan.

Jeroen, jij ook bedankt. Dankzij jou had ik deze promotieplek niet gekregen. Jij hebt mij in eerste instantie enthousiast gemaakt voor onderzoek en voor neonatologie. Door jou wil ik kinderarts

worden. Ik hoop dat we nog vele projecten samen mogen doen. Heel veel succes in het WKZ, tijd om professor te worden.

De Sadhorns, Ruben, Huub, Yordi en Joey. Vrienden voor het leven, al sinds jaar en dag. Bedankt voor alle geweldige dingen die we samen hebben mogen doen. Bedankt dat jullie er altijd voor me waren en voor de nodige afleiding konden zorgen. Ondanks de altijd aanwezige cynische en soms sadistische ondertoon zit jullie hart op de goede plek. Ik hoop de rest van mijn leven met jullie te mogen genieten.

Papa en Mama, bedankt dat jullie me hebben gemaakt. Bedankt dat jullie mij en Mark zo ruimdenkend en zo goed hebben opgevoed. Jullie hebben ons altijd gesteund in de dingen waar we goed in waren, waar we energie van kregen. Jullie hebben ons geleerd dat iedereen zijn kwaliteiten heeft en dat niemand beter is dan een ander. Mooi motto waar ik de rest van mijn leven aan vast zal houden. Jullie zijn de beste ouders die ik me kan wensen.

Mark, lief broertje, bedankt! Mijn creatieve tegenpool. Je bent een fantastische cameraman en film-editor, ik ben ervan overtuigd dat je je jeugdroom om regisseur te worden gaat verwezenlijken. Bedankt voor het ontwerpen van de cover van dit proefschrift. Jij ook bedankt Brigit, zorg goed voor m'n broertje.

Ook wil ik Lodewijk bedanken. Hoe kan ik ook anders, ik zie je elke dag en je hebt me een hoop steun gegeven in het laatste jaar van mijn promotie. Zelfs in het weekend kom je me wakker maken om tijdig aan mijn promotie te kunnen beginnen. Je hebt heel wat uren naast mij op de bank gezeten terwijl ik zat te werken. Je bent in korte tijd heel belangrijk voor me worden.

Liefste Rianneke, jij van iedereen het meest bedankt. Zonder jou was het echt nooit gelukt. Jij bent mijn beste maatje en steun en toeverlaat. Ik wil de rest van mijn leven samen met jou de wereld verkennen en genieten van ons huis en toekomstige gezinnetje. Bedankt dat je er altijd voor me bent, ik zal er ook altijd voor jou zijn.

