



# Changing Roots

Remodelling after the Ross Operation

Aart Mookhoek



# CHANGING ROOTS: REMODELLING AFTER THE ROSS OPERATION

Aart Mookhoek

Cover photo of Ross Island, situated near Antarctica, showing the impressive heights of Mount Erebus

Cover: Mount Erebus - Bruno Pagnanelli

Lay-out: Nikki Vermeulen - Ridderprint BV

Printing:  **RIDDERPRINT** - [www.ridderprint.nl](http://www.ridderprint.nl)

ISBN: 978-94-6299-445-4

© Aart Mookhoek

All rights reserved. No part of the material protected by this copyright notice may be reproduced or utilized in any form or by any electronic, mechanical, or other means, now known or hereafter invented, including photocopying and recording, or in any information storage and retrieval system without prior written permission of the author.

# CHANGING ROOTS: REMODELLING AFTER THE ROSS OPERATION

Veranderende wortels:  
remodelleren na de Ross operatie

Proefschrift

ter verkrijging van de graad van doctor aan de  
Erasmus Universiteit Rotterdam  
op gezag van de  
rector magnificus

Prof.dr. H.A.P. Pols

en volgens besluit van het College voor Promoties.

De openbare verdediging zal plaatsvinden op

16 november 2016 om 13:30 uur

door

**Aart Mookhoek**  
geboren te Beverwijk

**Erasmus University Rotterdam**

The logo of Erasmus University Rotterdam, featuring the word "Erasmus" in a stylized, cursive script.

## **Promotiecommissie**

Promotoren: Prof.dr. J.J.M. Takkenberg  
Prof.dr. A.J.J.C. Bogers

Overige leden: Prof.dr. W.A. Helbing  
Prof.dr. M.G. Hazekamp  
Prof.dr. F.J. van Kemenade

Copromotor: Dr. P.H. Schoof

Financial support by the Dutch Heart Foundation for the publication of this thesis is gratefully acknowledged.

If it were me, when the book arrives,  
I would immediately start scanning  
pages to find any trace of me.

...

You do not need to look very  
hard to find your shadow here.  
Your fingerprints are on these pages.

...

*Excerpt from "The First Poem of the Imaginary Book" by Sarah Kay*

## Table of contents

<b>Chapter 1</b>	General introduction	9
<b>Chapter 2</b>	Ross Procedure in Neonates and Infants: A European Multicenter Experience  <u>Mookhoek</u> , Charitos, Hazekamp, Bogers, Hörer, Lange, Hetzer, Sachweh, Riso, Stierle, Takkenberg, Schoof <i>Ann Thorac Surg. 2015;100:2278-84.</i>	21
<b>Chapter 3</b>	Echocardiography Findings after the Ross Operation in Neonates and Infants  <u>Mookhoek</u> , Rebel, Bogers, Bökenkamp, Hazekamp, Meijboom, Schoof, Andrinopoulou, Hruda, Kuipers, Filippini, Takkenberg <i>Submitted</i>	37
<b>Chapter 4</b>	Valve-sparing Reoperations after Ross Procedure: a European Multicenter Experience  <u>Mookhoek</u> , De Kerchove, El Khoury, Weimar, Luciani, Mazzucco, Bogers, Aicher, Schäfers, Charitos, Stierle, Takkenberg <i>J Thorac Cardiovasc Surg. 2015;5223:1490-1497.</i>	49
<b>Chapter 5</b>	Early Failure of Valve-sparing Reoperation after Ross Operation  <u>Mookhoek</u> , Robertus, Bekkers, Bogers <i>Submitted</i>	63
<b>Chapter 6</b>	Pulmonary Autograft Valve Explants Show Typical Degeneration  <u>Mookhoek</u> , De Heer, Bogers, Takkenberg, Schoof <i>J Thorac Cardiovasc Surg. 2010;139:1416-1419.</i>	69
<b>Chapter 7</b>	Biomechanics of Failed Pulmonary Autografts Compared to Normal Pulmonary Roots  <u>Mookhoek</u> , Krishnan, Chitsaz, Kuang, Ge, Schoof, Bogers, Takkenberg, Tseng <i>Accepted (Ann Thorac Surg)</i>	79
<b>Chapter 8</b>	Biomechanics of Pulmonary Autografts Compared to Native Aortic Roots  <u>Mookhoek</u> , Krishnan, Chitsaz, Kuang, Ge, Schoof, Bogers, Takkenberg, Tseng <i>Accepted (Ann Thorac Surg)</i>	93



<b>Chapter 9</b>	<b>Material Properties of Explanted Pulmonary Autograft Leaflets Compared to Native Aortic and Pulmonary Leaflets</b>	<b>105</b>
	<u>Mookhoek, Kuang, Wisneski, Bogers, Takkenberg, Tseng, Schoof</u> <i>Submitted</i>	
<b>Chapter 10</b>	<b>Biomechanical Characterization of Chronic Dissection after Ross Procedure</b>	<b>115</b>
	<u>Mookhoek, Kuang, Tseng, Bogers</u>	
<b>Chapter 11</b>	<b>General discussion</b>	<b>121</b>
<b>Chapter 12</b>	<b>Summary</b>	<b>137</b>
	Nederlandse samenvatting	141
	PhD portfolio	145
	List of publications	147
<b>Dankwoord</b>		<b>149</b>
<b>About the author</b>		<b>155</b>



# Chapter I

## **General Introduction**



## Aortic Valve Disease

Aortic valve (AV) disease is relatively common with an estimated prevalence in the United States of AV stenosis and regurgitation of 0.4% and 0.5%, respectively [1]. Degenerative, age-related changes are the major cause of AV disease in developed countries. As such, this supports the finding that the prevalence of AV disease increases markedly with age [1]. Changing demographics and increasing life expectancy will result in an increase in the number of patients with AV disease over the coming years.

The function of the aortic valve is to ensure unidirectional blood flow from the left ventricle to the systemic circulation. In keeping with its function, AV disease is subdivided into two entities based on hemodynamic consequences: aortic valve stenosis (AS) and regurgitation (AR). In AS, outflow of the systemic ventricle to the aorta is obstructed, which in adults is most often the result of aortic valve leaflet thickening and stiffening through calcification. Leaflet calcification is an age-related phenomenon, which may be accelerated by hemodynamic abnormalities such as exist in congenital bicuspid aortic valve disease (BAV). A BAV is the most common congenital cardiac abnormality with an estimated prevalence in live births of 1.4% [2]. In addition, BAV disease is associated with aortic root dilation and dissection [3, 4]. In AR, closure of valve leaflets is impaired from a decrease in coaptation surface from aortic root dilatation or by leaflet perforation from endocarditis. Interestingly, it is not uncommon for AS and AR in adults to be present at the same time. Leaflet thickening and stiffening in AS may decrease the ability of valve leaflets to coapt and thereby reduce the coaptation surface. Rheumatic heart disease following rheumatic fever, nowadays rare in developed countries but unfortunately still common in the developing world, may lead to leaflet destruction resulting in both AS and AR [5].

Aortic valve disease can be benign when hemodynamic consequences are limited. However, moderate to severe AS or AR may result in significantly reduced quality of life and life expectancy. Although the pathophysiological mechanisms in AS and AR are different, both may result in symptomatic left ventricular dysfunction. This may present as dyspnoea on exertion, fatigue, angina pectoris, syncope and / or heart failure. In people with symptomatic AS, sudden cardiac death is a relatively rare but real threat. The severity of symptoms combined with the relatively high and increasing prevalence underscores the worldwide burden of disease associated with AV disease.

## Evolution of Aortic Valve Surgery

Medical management of AV disease may result in adequate relief of symptoms. However, drug therapy does not lead to regression or halt progression of the disease [6]. Therefore, repair or replacement of the valve may become necessary over time. Nowadays, transcatheter aortic valve implantation may be performed in selected patients [7]. However,

the focus of this thesis concerns the vast majority of patients with AV disease who receive surgical treatment.

Charles Hufnagel was the first to implant a ball-and-cage mechanical valve in the descending aorta of a patient with severe AR in 1952 [8, 9]. This landmark achievement marks the beginning of surgical treatment in AV disease. Introduction of cardiopulmonary bypass in the mid-1950s allowed surgeons to engage with the aortic valve directly [10, 11]. In the early to mid-1960s, surgeons began to set up aortic valve replacement (AVR) programs and developed most types of valve substitutes available today. This era has been coined appropriately as the great “*valve rush*” [12].

At present, the majority of AVRs are performed with a mechanical or biological valve substitute. Mechanical valves have evolved from the early ball-and-cage design to a bileaflet valve. The advantage of a mechanical valve substitute is durability, which in most patients is lifelong. The disadvantage is the requirement of lifelong oral anticoagulation use to prevent thromboembolic complications. Use of oral anticoagulation is associated with significant morbidity and mortality due to bleeding complications. Biological valves can be divided into two main categories: human tissue valves and bioprostheses made from porcine or bovine tissue. The advantage of biological valves is that lifelong oral anticoagulation use is not required. The disadvantage is the increased reoperation rate, as durability is limited, that is inversely correlated with age at implantation.

After the pioneering work performed in the 1960s, AVR has evolved from a complex procedure with high operative mortality to a routine procedure with limited associated morbidity and mortality. However, the search for the ideal aortic valve substitute described by Dwight Harken in the early-1960s is still ongoing [13]. Implantation of mechanical valves is still associated with bleeding complications and biological valves with the need for reoperation. Given the limitations of current AV substitutes, a focus on valve preservation in patients with AR has emerged. In isolated AV disease, repair of one or more leaflets may preserve the native aortic valve [14]. In addition, in patients with AR due to aortic root dilatation, valve-sparing aortic root replacement may be performed. Although data from long term follow-up studies is still pending, selected patients are expected to benefit from these approaches.

## **Ross procedure**

There is another alternative to traditional AV substitutes. In 1967, Donald Ross published a seminal paper in *The Lancet* on AVR with a pulmonary autograft [15]. Struggling with the limitations of available AV substitutes at the time, he proposed that the patient’s own pulmonary valve would be the ideal candidate for use as an AV substitute in AVR.

The first step of the procedure published in 1967 is to create a cylindrical graft from the pulmonary valve by transecting the pulmonary trunk proximally and distally close

to the valve annulus. Second, the diseased aortic valve is excised. Third, the pulmonary autograft is transplanted into the aortic position and a human tissue valve (homograft) is used to reconstruct the right ventricular outflow tract (RVOT). Technical complexity of the procedure has led to development of modifications to the original “sub-coronary” technique. In the “root replacement” technique, distal transection of the pulmonary trunk is performed at the level of the sinotubular junction [16]. This technique requires reimplantation of the coronary arteries in the pulmonary autograft, but makes preservation of the unique and complex three dimensional architecture of the root easier. In the “inclusion cylinder” technique, the root replacement technique is modified by placing the pulmonary autograft root in the native aortic root for additional support [17].

The procedure as described by Donald Ross, which now bears his name, has several advantages. First, use of oral anticoagulation is not required. Second, autograft tissue remains viable and can therefore facilitate somatic growth when transplanted into children and young adults [18]. Third, hemodynamic performance of pulmonary autografts is assumed to be superior to other valve substitutes, which might translate to better recovery of the left ventricle and subsequent improved life expectancy after the Ross procedure. Fourth, the finding that aortic and pulmonary valves are derived from a common embryological truncus led researchers to suggest that transplanting a native pulmonary valve into the aortic position may result in remodelling towards an aortic phenotype. This supports the idea that the pulmonary autograft is an aortic valve substitute for life. However, the Ross procedure also carries a number of disadvantages.

## Debate

Use of the Ross procedure in adults requiring AVR is not widespread, with only a handful of centres worldwide offering this procedure to a select patient population [19]. The Ross procedure has been a topic of academic debate for decades and its popularity is continuously shifting. Despite the advantages of the Ross procedure, the current debate focusses on three major points of criticism: creation of double prosthetic valve disease, technical complexity and limited autograft durability.

In his seminal paper, Dr. Ross stated that “... *the problem of the homograft has now been transferred to the pulmonary area*” [15]. Patients with single valve disease will, in effect, have double valve disease after the Ross procedure. The RVOT, nowadays reconstructed using a human tissue valve or bioprosthesis, requires reoperation at some point. Evaluation of long-term follow-up studies shows that results in single centre studies are consistently better than those reported by registries. This finding may reflect technical complexity, as low-volume centres contributing to registries will have less experience and expertise with the Ross procedure. Young cardiothoracic surgeons nowadays are hesitant to learn this complex procedure due to the risk of less favourable early outcomes [20]. This fact

is compounded by the lack of consensus on which Ross technique to use. In addition, the community of surgeons dedicated to performing the Ross procedure in adults is small, which results in few mentors worldwide to enthuse and teach. The major concern raised by opponents of the Ross procedure in adult patients is the reported increase in pulmonary autograft reoperation rates after the first postoperative decade. Use of the root replacement technique is associated with progressive autograft root dilatation resulting in valvular regurgitation.

The 2014 ACC / AHA guidelines on management of valvular heart disease acknowledge these points of criticism, with a focus on technical complexity [21]. They recommend that the Ross procedure may be considered when performed by experienced surgeons and should be limited to use in young adults in whom oral anticoagulation use is not desirable (Class IIB, level of evidence C). The 2012 ESC / EACTS guidelines on management of valvular heart disease state similar arguments [22]. The authors report that use of the Ross procedure in adults is rare; no official recommendation has been included in the guidelines.

Both guidelines refer to the 2010 seminal publication in *The Lancet* of a single centre randomized clinical trial (RCT) in 216 patients comparing the Ross procedure to AVR using a human tissue valve [23]. Ten years follow-up in the Ross group shows 95% freedom from reoperation on the autograft and RVOT graft combined. Actuarial survival at ten years was superior in the Ross group (97%) compared to the donor valve group (83%). Strikingly, survival in the Ross group was similar to the age and sex-matched general population. When writing the recommendations for the 2014 ACC / AHA guidelines, this publication appears to have been disregarded and in the manuscript the committee stated that “... *these outstanding results have not been generally replicated*” [21]. This statement is remarkable as this is the only published RCT comparing the Ross procedure to conventional AVR. Moreover, a recent publication from the German Ross Registry has replicated these results in a prospective, multicentre study with 1779 patients [24]. After ten years, freedom from reoperation on the autograft and RVOT graft combined was 91.1%. Similar to results from the RCT, survival at ten years follow-up was comparable with the age and sex-matched general population. Whether the observed survival benefit of the Ross procedure reflects the superior hemodynamic performance of the pulmonary autograft or patient selection bias, remains a topic of a heated debate.

In contrast to reoperation rates and late mortality, quality of life (QoL) after AVR has not been studied extensively. In a Canadian study, QoL was included in a comparison of long-term follow-up after AVR with either a mechanical or biological valve substitute [25]. The results show superior QoL in patients who received biological valves. These findings are corroborated by a more recent study showing superior QoL at mid-term follow-up in patients who received aortic valve repair or AVR with a pulmonary autograft compared to AVR with a mechanical valve substitute [26].



## Unsolved issues

The choice of valve substitute in AVR should be a shared decision making process involving both clinicians and informed patients, especially given the value-sensitive nature of the decision [27]. Clinicians have the obligation to support and embrace scientific studies and interpret the data in order to best inform their patients and engage them in prosthetic valve selection. The aim of this thesis is to identify and address key unsolved questions regarding the Ross procedure.

The available literature shows a focus on studies reporting on long-term follow-up after the Ross procedure in adults. Published experience in neonates and infants is mostly limited to small, single centre studies with short to mid-term follow-up [28-31]. The Ross procedure is the treatment of choice for neonates and infants with severe left ventricular outflow tract obstruction requiring AVR. Therefore, it is important to answer questions regarding changes in left ventricular (LV) function in patients with severely impaired pre-operative LV function, changes in pulmonary autograft dimensions during somatic growth, and both long-term function and durability of the pulmonary autograft valve.

Aortic valve repair and valve-sparing aortic root replacement techniques have been introduced into the armamentarium of surgeons confronted with patients requiring a reoperation on the pulmonary autograft after the Ross procedure. Preservation of the autograft valve may conserve some of the benefits of the original Ross procedure. Moreover, several studies have reported favourable short-term outcomes [32-34]. However, possible factors associated with failure are not well studied and long-term durability of the autograft leaflets is unknown.

Fundamental research on the remodelling response of the pulmonary autograft in humans is limited. A few studies have shown that autograft tissue displays a remodelling response and remains viable [35, 36]. The interesting question that remains unanswered is whether the native pulmonary valve can undergo phenotypic transformation upon exposure to the systemic circulation to resemble the native aortic valve.

## Thesis Outline and Aims

This thesis aims to improve our understanding of long-term consequences of pulmonary autograft exposure to the systemic circulation after the Ross procedure. To this end, I have evaluated clinical outcome after the Ross procedure in different patient populations and studied remodelling in explanted pulmonary autografts.

In **Chapters 2** and **3**, clinical outcome following the Ross procedure in neonates and infants is presented. In **Chapter 2**, the focus is on identifying variables associated with increased risk of early and/or late death following the Ross procedure. **Chapter 3** aims to

answer the question how pulmonary autograft function and dimensions change in growing patients. Moreover, longitudinal analysis of left ventricular function is presented.

**Chapters 4 and 5** focus on valve-sparing reoperations after the Ross procedure. **Chapter 4** aims to identify variables associated with increased risk of reintervention after a valve-sparing reoperation. **Chapter 5** is a case report presenting a young patient who required early reintervention after a valve-sparing reoperation.

Histological analysis of explanted pulmonary autograft leaflet is the focus of **Chapters 5 and 6**. The focus of **Chapter 6** is to examine how pulmonary autograft leaflets change after exposure to the systemic circulation. The central question of the chapter is whether native pulmonary leaflets become identical to native aortic leaflets. The case report in **Chapter 5** offers a unique opportunity to study how leaflets change after autograft root dilatation is reversed following valve-sparing autograft root replacement.

In **Chapters 7 to 10** a biomechanical analysis of explanted pulmonary autografts is presented. **Chapter 7** compares wall stiffness of the autograft wall to the native pulmonary root at pulmonic pressures. In **Chapter 8**, a similar study presents a comparison between the autograft wall and native aortic root at systemic pressures. The focus of **Chapter 9** is on measuring leaflet stiffness of pulmonary autografts and offering a comparison with native aortic and pulmonary leaflets. **Chapter 10** is a case report showing the material properties of a dissected autograft wall specimen.

## **Discussion**

In **Chapter 11**, the findings in this thesis will be discussed with a focus on the (potential) impact on clinical practice in aortic valve disease. Future studies will be proposed following a discussion of the limitations of the studies presented in this thesis as well as existing knowledge gaps.

## References

1. Nkomo VT, Gardin JM, Skelton TN, Gottdiener JS, Scott CG, Enriquez-Sarano M. Burden of valvular heart diseases: a population-based study. *Lancet*. 2006;368(9540):1005-1011.
2. Hoffman JI, Kaplan S. The incidence of congenital heart disease. *J Am Coll Cardiol*. 2002;39(12):1890-1900.
3. Fedak PW, Verma S, David TE, Leask RL, Weisel RD, Butany J. Clinical and pathophysiological implications of a bicuspid aortic valve. *Circulation*. 2002;106(8):900-904.
4. Morgan-Hughes GJ, Roobottom CA, Owens PE, Marshall AJ. Dilatation of the aorta in pure, severe, bicuspid aortic valve stenosis. *Am Heart J*. 2004;147(4):736-740.
5. Watson G, Jallow B, Le Doare K, Pushparajah K, Anderson ST. Acute rheumatic fever and rheumatic heart disease in resource-limited settings. *Arch Dis Child*. 2015;100(4):370-375.
6. Hutcheson JD, Aikawa E, Merryman WD. Potential drug targets for calcific aortic valve disease. *Nat Rev Cardiol*. 2014;11(4):218-231.
7. Gooley R, Cameron JD, Meredith IT. Transcatheter Aortic Valve Implantation - Yesterday, Today and Tomorrow. *Heart Lung Circ*. 2015;24(12):1149-1161.
8. Hufnagel CA, Harvey WP. The surgical correction of aortic regurgitation preliminary report. *Bull Georgetown Univ Med Cent*. 1953;6(3):60-61.
9. Hufnagel CA, Harvey WP, Rabil PJ, Mc DT. Surgical correction of aortic insufficiency. *Surgery*. 1954;35(5):673-683.
10. Miller BJ, Gibbon JH, Jr., Greco VF, Smith BA, Cohn CH, Allbritten FF, Jr. The production and repair of interatrial septal defects under direct vision with the assistance of an extracorporeal pump-oxygenator circuit. *J Thorac Surg*. 1953;26(6):598-616; discussion 631-592.
11. Gibbon JH, Jr. Application of a mechanical heart and lung apparatus to cardiac surgery. *Minn Med*. 1954;37(3):171-185; passim.
12. Edmunds LH, Jr. Evolution of prosthetic heart valves. *Am Heart J*. 2001;141(5):849-855.
13. Harken DE, Taylor WJ, Lefemine AA, Lunzer S, Low HB, Cohen ML, et al. Aortic valve replacement with a caged ball valve. *Am J Cardiol*. 1962;9:292-299.
14. Boodhwani M, El Khoury G. Aortic valve repair: indications and outcomes. *Curr Cardiol Rep*. 2014;16(6):490.
15. Ross DN. Replacement of aortic and mitral valves with a pulmonary autograft. *Lancet*. 1967;2(7523):956-958.
16. Stelzer P. The Ross procedure: state of the art 2011. *Semin Thorac Cardiovasc Surg*. 2011;23(2):115-123.
17. Skillington PD, Fuller JA, Grigg LE, Yapanis AG, Porter GF. Ross procedure. Inserting the autograft using a fully supported root replacement method; techniques and results. *J Heart Valve Dis*. 1999;8(6):593-600.
18. Elkins RC, Knott-Craig CJ, Ward KE, McCue C, Lane MM. Pulmonary autograft in children: realized growth potential. *Ann Thorac Surg*. 1994;57(6):1387-1393; discussion 1393-1384.
19. Yacoub MH, El-Hamamsy I, Sievers HH, Carabello BA, Bonow RO, Stelzer P, et al. Under-use of the Ross operation--a lost opportunity. *Lancet*. 2014;384(9943):559-560.
20. Treasure T, Hasan A, Yacoub M. Is there a risk in avoiding risk for younger patients with aortic valve disease? *BMJ*. 2011;342:d2466.

21. Nishimura RA, Otto CM, Bonow RO, Carabello BA, Erwin JP, 3rd, Guyton RA, *et al.* 2014 AHA/ACC Guideline for the Management of Patients With Valvular Heart Disease: a report of the American College of Cardiology/American Heart Association Task Force on Practice Guidelines. *Circulation.* 2014;129(23):e521-643.
22. Vahanian A, Alfieri O, Andreotti F, Antunes MJ, Baron-Esquivias G, Baumgartner H, *et al.* Guidelines on the management of valvular heart disease (version 2012): the Joint Task Force on the Management of Valvular Heart Disease of the European Society of Cardiology (ESC) and the European Association for Cardio-Thoracic Surgery (EACTS). *Eur J Cardiothorac Surg.* 2012;42(4):S1-44.
23. El-Hamamsy I, Eryigit Z, Stevens LM, Sarang Z, George R, Clark L, *et al.* Long-term outcomes after autograft versus homograft aortic root replacement in adults with aortic valve disease: a randomised controlled trial. *Lancet.* 2010;376(9740):524-531.
24. Sievers HH, Stierle U, Charitos EI, Takkenberg JJ, Horer J, Lange R, *et al.* A multicentre evaluation of the autograft procedure for young patients undergoing aortic valve replacement: update on the German Ross Registry. *Eur J Cardiothorac Surg.* 2015;49(1):212-218.
25. Ruel M, Kulik A, Lam BK, Rubens FD, Hendry PJ, Masters RG, *et al.* Long-term outcomes of valve replacement with modern prostheses in young adults. *Eur J Cardiothorac Surg.* 2005;27(3):425-433; discussion 433.
26. Aicher D, Holz A, Feldner S, Kollner V, Schafers HJ. Quality of life after aortic valve surgery: replacement versus reconstruction. *J Thorac Cardiovasc Surg.* 2011;142(2):e19-24.
27. Korteland NM, Bras FJ, van Hout FM, Kluin J, Klautz RJ, Bogers AJ, *et al.* Prosthetic aortic valve selection: current patient experience, preferences and knowledge. *Open Heart.* 2015;2(1):e000237.
28. Luciani GB, Lucchese G, Carotti A, Brancaccio G, Abbruzzese P, Caianiello G, *et al.* Two decades of experience with the Ross operation in neonates, infants and children from the Italian Paediatric Ross Registry. *Heart.* 2014;100(24):1954-1959.
29. Maeda K, Rizal RE, Lavrsen M, Malhotra SP, Akram SA, Davies R, *et al.* Midterm results of the modified Ross/Konno procedure in neonates and infants. *Ann Thorac Surg.* 2012;94(1):156-162; discussion 162-153.
30. Ohye RG, Gomez CA, Ohye BJ, Goldberg CS, Bove EL. The Ross/Konno procedure in neonates and infants: intermediate-term survival and autograft function. *Ann Thorac Surg.* 2001;72(3):823-830.
31. Shinkawa T, Bove EL, Hirsch JC, Devaney EJ, Ohye RG. Intermediate-term results of the Ross procedure in neonates and infants. *Ann Thorac Surg.* 2010;89(6):1827-1832; discussion 1832.
32. Charitos EI, Takkenberg JJ, Hanke T, Gorski A, Botha C, Franke U, *et al.* Reoperations on the pulmonary autograft and pulmonary homograft after the Ross procedure: An update on the German Dutch Ross Registry. *J Thorac Cardiovasc Surg.* 2012;144(4):813-821; discussion 821-813.
33. de Kerchove L, Boodhwani M, Etienne PY, Poncelet A, Glineur D, Noirhomme P, *et al.* Preservation of the pulmonary autograft after failure of the Ross procedure. *Eur J Cardiothorac Surg.* 2010;38(3):326-332.
34. Luciani GB, Lucchese G, De Rita F, Puppini G, Faggian G, Mazzucco A. Reparative surgery of the pulmonary autograft: experience with Ross reoperations. *Eur J Cardiothorac Surg.* 2012;41(6):1309-1314; discussion 1314-1305.

35. Rabkin-Aikawa E, Aikawa M, Farber M, Kratz JR, Garcia-Cardena G, Kouchoukos NT, *et al.* Clinical pulmonary autograft valves: pathologic evidence of adaptive remodeling in the aortic site. *J Thorac Cardiovasc Surg.* 2004;128(4):552-561.
36. Schoof PH, Takkenberg JJ, van Suylen RJ, Zondervan PE, Hazekamp MG, Dion RA, *et al.* Degeneration of the pulmonary autograft: an explant study. *J Thorac Cardiovasc Surg.* 2006;132(6):1426-1432.



# Chapter 2

## **Ross Procedure in Neonates and Infants: a European Multicenter Experience**

**Aart Mookhoek, Efstratios I Charitos, Mark G Hazekamp, Ad J J C Bogers, Jürgen Hörer,  
Rüdiger Lange, Roland Hetzer, Joerg S Sachweh, Arlindo Riso, Ulrich Stierle,  
Johanna J M Takkenberg, Paul H Schoof**

## **Abstract**

### **Background**

Infants and neonates with severe left ventricular outflow tract obstruction may require pulmonary autograft replacement of the aortic root. In this retrospective multicenter cohort study, we present our experience with the Ross procedure in neonates and infants with a focus on mid-term survival and pulmonary autograft durability.

### **Methods**

Retrospective observational study of 76 infants (age < 1 year) operated on in 6 congenital cardiac centers in The Netherlands and Germany between 1990 and 2013.

### **Results**

Patients had a pulmonary autograft replacement of the aortic valve with (68%) or without (32%) septal myectomy. Median patient age was 85 days (range 6 – 347 days). Early mortality (n=13, 17%) was associated with neonatal age, pre-operative use of intravenous inotropic drugs and congenital aortic arch defects. Five patients (9%) died during follow-up. Freedom from autograft reintervention was 98% at ten years. Echocardiography demonstrated good valve function, with no or trace regurgitation in 73% of patients. Freedom from right ventricular outflow tract reintervention was 51% at ten years. Univariable analysis demonstrated superior freedom from reintervention of pulmonary homografts compared to aortic homografts or xenografts.

### **Conclusions**

Pulmonary autograft replacement of the aortic valve in neonates and infants is a high risk operation but offers a durable neo-aortic valve. Mid-term durability reflects successful adaptation of the autograft to the systemic circulation. Late mortality associated with heart failure was an unexpected finding.



## Introduction

Congenital aortic stenosis (AS) is a relatively common type of congenital heart disease with an estimated worldwide incidence of 0.22 per 1000 live births.<sup>1</sup> Although surgical valvotomy or trans-catheter balloon valvuloplasty may be considered as the first choice of treatment in neonates and infants with critical AS, replacement of the aortic valve may become necessary over time.<sup>2</sup> Aortic root replacement using a pulmonary autograft was first performed in a neonate in 1989 and has subsequently gained acceptance as a valuable and reproducible strategy in young children.<sup>3</sup> Attracted by the alleged growth potential of the pulmonary autograft, surgeons have reported on this operation in neonates and infants with increasing frequency over the past years.<sup>4-9</sup> However, reported long-term experience with the Ross procedure in neonates and infants is limited to a few small single center studies.<sup>10,11</sup> Therefore, we present our data from an international multicenter experience with the Ross procedure in neonates and infants with a focus on mid-term survival and autograft reintervention.

## Methods

Institutional review board permission for this study was obtained in each participating center. Informed consent was obtained from parents or legal guardians.

### Patient inclusion and data collection

Pre-operative patient characteristics, peri-operative surgical details and post-operative follow-up data of all patients who had an aortic valve replacement with a pulmonary autograft as an infant (age < 1 year) or neonate (age < 30 days) were obtained from the German-Dutch Ross Registry (congenital cardiac centers of Rotterdam, München, Berlin and Hamburg) and from two additional centers (congenital cardiac centers of Leiden and Utrecht). In total, 76 neonates and infants, operated on between 1990 and 2013, were included in the study.

### Data analysis

Statistical analyses were performed using IBM SPSS version 20.0 (IBM, Somers, NY, USA). Normal distribution of data was assessed using the Shapiro-Wilk test. Reported values are quoted as mean  $\pm$  standard deviation or median and interquartile range for continuous variables and percentages for discrete variables.

Overall survival and right ventricular outflow tract (RVOT) graft durability, defined as freedom from any reintervention, were visualized using Kaplan-Meier curves. Curves were truncated at the follow-up time when the proportion of patients at risk dropped below

10%. 95% confidence intervals were calculated using log transformation of the cumulative hazard function.

The predictive value of several variables on peri-operative mortality was assessed with a univariable analysis based on binary logistic regression. Variables included gender, body surface area, number of aortic valve cusps, presence of severe mitral regurgitation and yes / no status regarding pre-operative use of intravenous inotropic drugs, age <30 days (neonate), emergency surgery (operation before start next working day after decision to operate) and congenital aortic arch defects. Multiple imputation with 100 iterations was performed to manage missing values in the following parameters: body surface area (18%), number of aortic valve cusps (12%), use of inotropes (21%) and circulatory arrest strategy (9%). Spearman's correlation coefficient was used to assess correlations between variables included in the univariable analyses.

With Cox regression, a univariable analysis of the predictive value on RVOT graft intervention of several variables was assessed. Variables included age <30 days (neonate) yes / no, graft type (pulmonary homograft, aortic homograft or xenograft) and graft diameter.

## Results

Pre-operative patient characteristics are shown in Table 1. Two babies were born prematurely (gestational age 33 and 35 weeks) after induction of labor for chronic severe left ventricular dysfunction. Both underwent balloon valvuloplasty of the aortic valve shortly after birth. On day 97 and 20, respectively, the aortic valve was replaced with a pulmonary autograft. Both patients survived and remained in good clinical condition now more than six years after the operation.

**TABLE 1** Pre-operative patient characteristics

Total patients		76
Sex	Male	60 (79%)
	Female	16 (21%)
Age at Surgery (in days) *	Median	85
	Interquartile range	39 - 166
	Range	6 - 347
	Neonates (<30 days)	17 (22%)
Height (n=62) †		59 ± 9 cm
Weight (n=68) †		5.1 ± 2.0 kg
IV inotropes (n=60)		14 (23%)
Aortic valve	Unicuspid	9%
	Bicuspid	58%

TABLE I Pre-operative patient characteristics (Continued)

	Tricuspid	22%
	Unspecified	11%
Indication	Stenosis	66%
	Regurgitation	16%
	Combined	18%
Concomitant CHD ‡		46 (61%)
	PFO	18
	Endocardial fibroelastosis	16
	VSD	16
	ASD	11
	IAA	11
	Mitral dysplasia	7
	Hypoplastic arch	6
	Coarctation	5
	Shone's complex	1
	HOCM	1
Previous intervention ‡		58 (76%)
<i>Balloon valvuloplasty</i>		37
<i>Surgical valvotomy</i>		10
<i>Other cardiac surgery ‡</i>		23
	VSD closure	8
	ASD closure	7
	Aortic arch repair	6
	Coarctation repair	5
	Rashkind	5
	IAA repair	4
	Bilateral PA banding	2
	Atrial septostomy	1
	PFO closure	1
	MVP	1
	TVP	1
	Septal myectomy	1
	Enlargement ascending aorta	1
	Fetal balloon dilatation	1

Number of patients with available data is indicated by "(n=)" for variables with missing data. \*Age at surgery does not conform to a normal distribution. †Values represent mean  $\pm$  standard deviation. ‡Overlapping categories. IV indicates intravenous; CHD, congenital heart disease; PFO, patent foramen ovale; VSD, ventricular septal defect; ASD, atrial septal defect; IAA, interrupted aortic arch; HOCM, hypertrophic obstructive cardiomyopathy; MVP, mitral valve plasty; TVP, tricuspid valve plasty.

## Ross procedure

An overview of peri-operative characteristics, including in-hospital complications, is provided in Table 2. The aortic root was replaced with the pulmonary autograft root in all patients, without use of external support. The left ventricular outflow tract was enlarged to allow size matching the autograft in 52 patients by septal myectomy (modified Konno procedure). The septal incision was closed with autograft muscle in the majority of patients according to the operative reports. In six patients, a separate pericardial or Gore-Tex patch was used to reconstruct the ventricular septum. Circulatory arrest was used when concomitant aortic arch repair was necessary (n=10).

**TABLE 2** Peri-operative characteristics

Procedure (n=74)	Emergency	5 (7%)	
	Elective	69 (93%)	
Septal myectomy		52 (68%)	
Perfusion time (n=64) *		204 ± 80	minutes
Cross-clamp time (n=68) *		138 ± 43	minutes
Circulatory arrest (n=69) *		10 (14%)	
		40 ± 22	minutes
RVOT	Pulmonary Homograft	38%	
	Aortic Homograft	13%	
	Xenograft	46%	
	Unknown	3%	
Concomitant surgery*		29 (38%)	
	PFO closure	11	
	VSD closure	6	
	Resection endocardial fibroelastosis	6	
	Arch reconstruction	5	
	IAA repair	5	
	Isolated septal myectomy	3	
	MVP	3	
	Atrial septostomy	2	
	MVR	2	
	TVP	2	
	Pulmonary artery debanding	2	
	Ascending aorta repair	2	
Hospital stay (n=62) * †		21 ± 14	days
Complications (n=62) † ‡		29 (46%)	
	Low cardiac output	10	
	Total AV-block	9	
	Tamponade	9	

TABLE 2 Peri-operative characteristics (Continued)

	Transient pulmonary hypertension	3
	Endocarditis	2
	Temporary renal dialysis	2
	LCA obstruction	2
	Ventricular fibrillation	1
	Sternal instability	1
	Sternal wound infection	1
	Pneumothorax	1
	Cerebral parenchymal bleeding	1
	Convulsion	1
	Capillary leak syndrome	1
	Thromboembolism	0
Post-operative interventions † ‡	Resternotomy	14
	Temporary pacemaker	7
	Resuscitation	6
	Permanent pacemaker	3
	ECMO	1
	Sternal refixation	1
In-hospital death		13 (17%)
	Intra-operative	5
	<i>Failure to wean from CPB</i>	4
	<i>Uncontrolled hemorrhage</i>	1
	Post-operative	8
	<i>MOF following ECMO</i>	3
	<i>Septic shock</i>	2
	<i>LV failure</i>	1
<i>Unknown</i>	2	

Number of patients with available data is indicated by "(n=)" for variables with missing data. \* Values represent mean  $\pm$  standard deviation. † Excluding 13 in-hospital deaths. ‡ Overlapping categories. RVOT indicates right ventricular outflow tract; PFO, patent foramen ovale; VSD, ventricular septal defect; IAA, interrupted aortic arch; MVP, mitral valve plasty; MVR, mitral valve replacement; TVP, tricuspid valve plasty; ASD, atrial septal defect; AV, atrioventricular; LCA, left coronary artery; CPB, cardio-pulmonary bypass; MOF, multiorgan failure; ECMO, extracorporeal membrane oxygenation; LV, left ventricle.

### Intra-operative course

Obstruction of the left coronary artery was suspected intra-operatively in two patients with poor left ventricular function and failure to come off bypass. In one patient, the left coronary button was reimplanted, which resulted in improved contractility and allowed this patient to be weaned successfully from bypass. In the other patient, the RVOT graft was elongated to relieve tension on the left coronary artery and button.

## Early deaths

In-hospital death occurred in 13 patients (17%); 8 in neonates (47% of all neonates) and 5 in infants (8% of all infants). Autograft failure was not observed in these patients. Rather, cause of death was related to low output failure in the majority of these patients. In total, 7 patients could not be weaned from bypass: 4 patients (1 neonate) died intra-operatively and 3 patients (all neonates) received ECMO and died several days later. When ECMO was initiated in the operating room, in-hospital mortality was 100%. Limited information in surgical notes and absence of performed autopsies prevented a more detailed description of early mortality.

Univariable analysis demonstrated several variables potentially associated with increased risk of peri-operative mortality (Table 3). These variables were also correlated with each other: being a neonate at the time of the Ross procedure correlated with a lower body surface area (Rho -0.521,  $P < 0.001$ ), pre-operative use of inotropes (Rho 0.602,  $P < 0.001$ ) and concomitant arch repair (Rho 0.273,  $P = 0.031$ ). With respect to congenital aortic arch defects, no hospital mortality occurred in the 4 neonates who had their arch repaired during the Ross operation, whereas 4 out of 8 neonates died who had undergone aortic arch repair in a previous operation.

## Post-operative course

Total AV-block developed in nine survivors; normal AV conduction returned in seven, two patients required a permanent pacemaker, one of whom had a septal myectomy (modified Konno procedure).

Fourteen patients underwent re-sternotomy for bleeding (N=9) or hemodynamic instability and resuscitation (N=5). Visual inspection of coronary buttons did not reveal abnormalities. Additional imaging of coronary circulation was not performed. Two patients who required re-sternotomy died during follow-up (patients 2 and 5 in Table 4).

One patient required reoperation for a residual ventricular septal defect one month after the Ross procedure.

One patient received ECMO treatment for 5 days due to deterioration of left ventricular function on the first post-operative day. This patient, operated 16 days after birth, had been treated by both fetal and neonatal aortic valve balloon dilatation prior to the Ross procedure. At last follow-up, two months after the Ross procedure, the patient was in good clinical condition.

**TABLE 3** Univariable analysis of peri-operative mortality

Variable	Odds Ratio	95% Confidence Interval	P-value
Neonate	9.6	(2.6 – 35.9)	0.001
Inotropy	16.5	(3.0 – 89.6)	0.001
Emergency	9.2	(1.4 – 61.8)	0.023
Arch repair	5.5	(1.2 – 25.0)	0.026

**TABLE 4** Causes of late mortality and characteristics of the initial Ross procedure

Patient	1	2	3	4	5
Cause of death	Interventionwat	HF	Unknown	HF	HF
Interval Ross (years)	1,0	1,1	1,2	1,8	11,6
Sex	Male	Male	Male	Male	Male
Age at Ross (days)	174	74	52	104	146
Aortic valve	Bicuspid	Bicuspid	Bicuspid	Bicuspid	Unicuspid
Concomitant CHD	-	EFE	-	ASD	EFE + CoA
Septal myectomy	No	Yes	No	Yes	No
Complications	-	Tamponade	-	-	Tamponade
Reinterventions	-	Resuscitation	-	-	Resuscitation
Hospital stay (days)	11	26	10	26	46

HF indicates heart failure; CHD, congenital heart disease; EFE, left ventricular endocardial fibroelastosis; CoA, aortic coarctation; ASD, atrial septal defect.

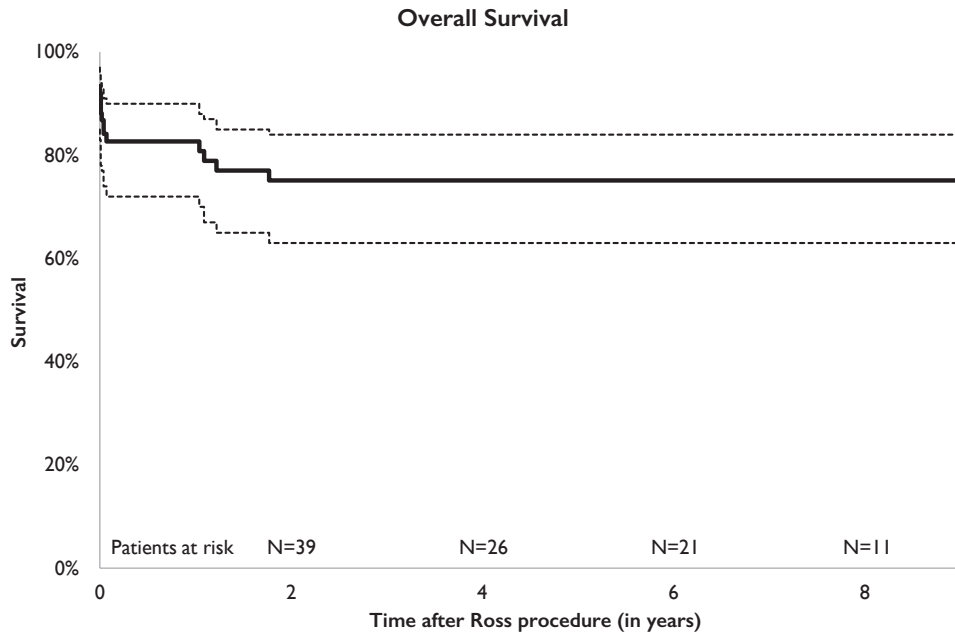
## Follow-up

Follow up of patients who survived to discharge after the Ross procedure was 92% complete, with a median duration of 3.6 years (range 23 days to 17 years, 44 patients had a follow-up of more than 1 year).

## Late deaths

Five patients (9%) died during follow-up (Table 4). A Kaplan-Meier curve visualizes overall survival (Figure 1). Autograft failure was not observed in any of these five patients. Patient 1 died upon reintervention for a stenotic Contegra conduit (Medtronic, Minneapolis, MN, USA). Balloon dilatation produced a conduit dissection in this patient. Subsequent emergency surgery in attempt to replace the conduit caused myocardial damage and biventricular failure. The patient died from multiple cerebral infarctions following ECMO support. Patient 2 was readmitted to hospital a year after the Ross procedure with symptomatic heart failure. Echocardiography demonstrated poor biventricular function with pulmonary hypertension. The patient died from sepsis after placement of a central venous access device. Patient 3 died of unknown causes three months after RVOT graft

replacement. Ventricular function and cardiac rhythm were normal in this patient. In patient 4, heart failure was the cause of death. An echocardiogram performed six weeks before death demonstrated severe right ventricular dilatation with massive RVOT graft regurgitation as well as signs of left ventricle restrictive cardiomyopathy. Patient 5 died following an episode of ventricular fibrillation associated with heart failure. This patient was known to have left and right ventricular dysfunction with severe pulmonary hypertension.



**FIGURE I** Kaplan-Meier curve of overall survival

### Autograft reinterventions

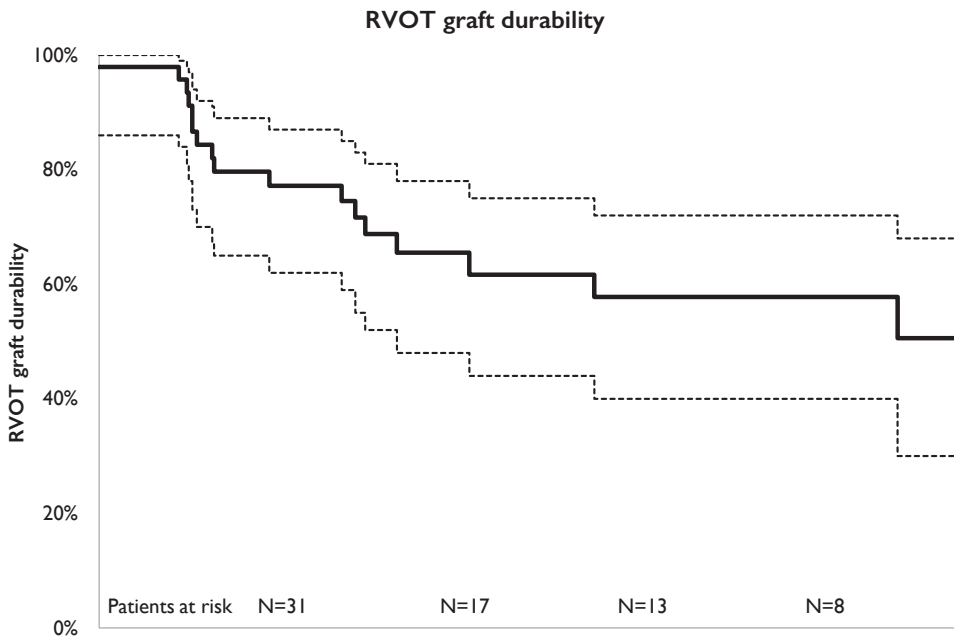
Only one patient required reintervention on the autograft during follow-up. This patient had a Ross-Konno procedure at the age of 13 days for multilevel left-sided outflow tract obstruction. Reoperation was performed 75 days after the initial Ross procedure for autograft regurgitation. Upon reoperation, a leaflet tear was identified and successfully repaired. A technical cause of this tear seemed likely. Good autograft valve function was maintained at 10 years of follow-up. None of the autografts were explanted and freedom from autograft reintervention for the entire cohort was 98% at ten years follow-up.



## RVOT graft reinterventions

During follow-up, 17 patients (30%) underwent a total of 31 interventions on the RVOT graft: 18 surgical replacements, 12 balloon dilatations and 1 percutaneous valve implantation. The median time to first intervention was 1.3 years, ranging from 279 days to almost 9 years. Freedom from RVOT reintervention was 51% at ten years follow-up. In the majority of cases (87%), graft stenosis was the indication for reintervention. Two patients, who both had a xenograft (Contegra I, Shelhigh I) implanted, developed endocarditis during follow-up: one patient was successfully treated with antibiotics, the other underwent surgical replacement.

Univariable analysis demonstrated graft type to be associated with an increased hazard of RVOT reintervention. Freedom from reintervention was higher in pulmonary homografts compared to aortic homografts (HR=7.633, CI 1.391 - 41.901, P=0.019) and xenografts (HR=6.157, CI 1.357 - 27.933, P=0.018). A Kaplan-Meier curve visualizes freedom from RVOT graft reintervention (Figure 2).



**FIGURE 2** Kaplan-Meier curve of freedom from any RVOT graft reintervention

## Other interventions

Three patients underwent other major cardiac interventions during follow-up. One had balloon dilatation of the right pulmonary artery due to compression by the autograft 1.2 years after the Ross procedure. Another patient had mechanical mitral valve replacement after 2.8 years together with an RVOT graft replacement. One patient underwent isolated resection of discrete subaortic stenosis located at the site of the proximal suture line after 4.5 years.

## Echocardiographic follow-up

At latest follow-up, 52 patients (74%) were still alive and their latest echocardiographic report was reviewed. Left ventricular ejection fraction was normal in 42 patients (95%) and reduced in 2 patients (5%) at last follow up.

Autograft regurgitation in late survivors was absent or minimal in 73% of patients, grade I in 18% and grade II in 10%. Regurgitation greater than grade II was not described in any patient. Six patients had more than 10 years of follow-up (range 10.8 – 16.9 years). In those patients, autograft and left ventricular function were good at last follow-up.

The RVOT graft had a peak gradient less than 30 mmHg in 25 patients (60%), between 30 and 60 in 11 patients (26%) and more than 60 in 6 patients (14%).

## Comment

Replacement of the aortic root with the pulmonary autograft, with or without enlargement of the left ventricular outflow tract by septal myectomy, has become an important surgical treatment modality for infants and neonates with critical aortic stenosis. Our study has expanded the clinical knowledge in this complex patient population.

Early mortality in our cohort was substantial, especially in neonatal patients. Woods et al. analyzed the Society of Thoracic Surgeons Congenital Heart Surgery database for in-hospital mortality following the Ross procedure in 145 neonates and infants. In-hospital mortality for their entire cohort was 16%, with a marked difference between neonates (29%) and infants (11%).<sup>5</sup> In our cohort, this difference was even more pronounced with 47% early mortality in neonates and 8% in infants. The high early mortality in neonates relative to results from the STS database should be perceived in the context of time as our series includes pioneer cases operated on before the year 2000. Similar to other investigators, we have shown that pre-operative use of intravenous inotropic drugs and congenital aortic arch defects are correlated with a higher risk of early death. Not surprisingly, these variables were correlated with neonatal age at the time of surgery. Interestingly, all neonates who underwent concomitant aortic arch repair survived the early post-operative period. However, patients who received aortic arch repair prior to the Ross procedure were

more likely to die within the first 30 days after the Ross procedure. Congenital aortic arch defects and neonatal age at the time of the Ross procedure have also been shown by other investigators to be associated with early death.<sup>5,6,12</sup> In contrast to the study by Lo Rito et al.<sup>7</sup>, pre-operative severe mitral regurgitation was not recognized as a risk factor for early mortality in our cohort. In our study, only a few patients were reported to have severe mitral valve regurgitation. In summary, we found that early mortality was higher in neonates, who more often had congenital aortic arch defects and were in poor clinical condition prior to the Ross procedure evidenced by pre-operative use of inotropes.

Coronary reimplantation after enlargement of the left ventricular outflow tract appears a critical issue. It demands accurate surgical assessment to determine the optimal position of the button on the much larger neo-aorta. Two of our patients with signs of myocardial ischemia needed a second pump run to change the position of the coronary button. Post-operative course was uneventful in both patients. Although not confirmed by angiography, we suspect that myocardial ischemia due to compromised coronary flow may have played a significant role in patients who died of undetermined low cardiac output. In the literature, malposition of a coronary button resulting in coronary flow obstruction following the Ross procedure in neonates and infants has been reported.<sup>8,11</sup> In a publication by Elder et al., two cases of right coronary artery occlusion were described: one patient died following myocardial ischemia, while in the other the lesion was clinically silent and apparently compensated for by adequate collateralization.<sup>11</sup>

Our study revealed that, in addition to the early mortality risk, there is also a late mortality risk. Despite adequate relief of left ventricular outflow tract obstruction, low output failure due to poor ventricular function may evolve late after the operation and result in late mortality. This happened to three of our patients. Unfortunately, limited data prevented us from analyzing these cases in more detail. Based on the current data, we cannot distinguish whether heart failure was related to intra-operative damage or caused by inadequacy of left sided structures.

Reassuring findings of this study are that young children with complex aortic valve disease who are severely symptomatic can be adequately treated by means of the Ross operation, survive and that autograft valve function remains excellent with no or only trace regurgitation in 73% of patients at 3,6 years mean follow up. No autografts were replaced and reoperation on the autograft was necessary in only one patient with an early, possibly technical, valve failure requiring repair of a torn leaflet. These results indicate that, during somatic growth, the autograft appears to adapt to the demands of the systemic circulation. Nevertheless, we recognize that more follow-up is needed to assess long term valve durability. Previous reports on autograft durability in neonates and infants are less convincing. While Brancaccio *et al.* found a significant drop in durability at ten years, Elder *et al.* reported results similar to our findings.<sup>11,12</sup>

Reinterventions on the RVOT graft were common and remain a substantial drawback of the Ross procedure. Both structural valve deterioration and patient growth play a significant role in development of graft stenosis. Reinterventions were not without risk, as illustrated by the death of one of our patients following balloon dilatation of the RVOT graft Maeda *et al.* suggested freedom from reintervention of pulmonary homografts might be superior to aortic homografts.<sup>8</sup> Brancaccio *et al.* demonstrated superior freedom from reintervention of homografts compared to xenografts.<sup>12</sup> Interestingly, Poynter *et al.* showed superior freedom from reintervention of xenografts compared to homografts.<sup>13</sup> This is in contrast to our finding of superior freedom from reintervention of pulmonary homografts compared to both aortic homografts and xenografts..

### Limitations

The retrospective nature of this study imposed constraints on data collection. We were confronted with missing values and several patients who were lost to follow-up. As missing values and lost patients are thought to have arisen (completely) at random, we feel confident no bias has been introduced. Multiple imputation allowed preservation of study power.

Low absolute number of late deaths and RVOT reoperations precluded use of multivariable analyses. To compensate, correlations between variables which were significant in univariable analyses were assessed.

Median follow-up duration in the present study was limited. However, the information from the peri-operative and immediate post-operative period collected in the present study, has already offered valuable insights and may impact surgical management of future patients.

### Conclusions

Pulmonary autograft replacement of the aortic valve with or without septal myectomy is an adequate surgical treatment for infants and neonates with critical aortic valve stenosis. Durability and function of the pulmonary autograft remained good during follow-up. No patients required autograft explantation. Similar to other series, early mortality was highest in neonates. Late death may occur due to heart failure warranting close surveillance of these patients.

## References

1. van der Linde D, Konings EE, Slager MA et al. Birth prevalence of congenital heart disease worldwide: a systematic review and meta-analysis. *J Am Coll Cardiol.* 2011;58:2241-47.
2. McLean KM, Lorts A, Pearl JM. Current treatments for congenital aortic stenosis. *Curr Opin Cardiol.* 2006;21:200-4.
3. Ziemer G, Beierlein W, Salehi-Gilani S. Aortic root remodeling 13,5 years after neonatal Ross operation. *Thorac Cardiovasc Surg* 2004;52 suppl.1. S46-7.
4. Schoof PH, Cromme-Dijkhuis AH, Bogers JJ et al. Aortic root replacement with pulmonary autograft in children. *J Thorac Cardiovasc Surg.* 1994;107:367-73.
5. Woods RK, Pasquali SK, Jacobs ML et al. Aortic valve replacement in neonates and infants: an analysis of the Society of Thoracic Surgeons Congenital Heart Surgery Database. *J Thorac Cardiovasc Surg.* 2012;144:1084-9.
6. Shinkawa T, Bove EL, Hirsch JC, Devaney EJ, Ohye RG. Intermediate-term results of the Ross procedure in neonates and infants. *Ann Thorac Surg.* 2010;89:1827-32.
7. Lo Rito M, Davies B, Brawn WJ et al. Comparison of the Ross/Ross-Konno aortic root in children before and after the age of 18 months. *Eur J Cardiothorac Surg.* 2014 [Epub ahead of print].
8. Maeda K, Rizal RE, Lavrsen M et al. Midterm results of the modified Ross/Konno procedure in neonates and infants. *Ann Thorac Surg.* 2012;94:156-62.
9. Nelson JS, Pasquali SK, Pratt CN, Yu S, Donohue JE, Loccoh E, Ohye RG, Bove EL, Hirsch-Romano JC. Long-Term Survival and Reintervention After the Ross Procedure Across the Pediatric Age Spectrum. *Ann Thorac Surg.* 2015;99:2086-95.
10. Fadel BM, Manlhiot C, Al-Halees Z et al. The fate of the neo-aortic valve and root after the modified Ross-Konno procedure. *J Thorac Cardiovasc Surg.* 2013;145:430-7.
11. Elder RW, Quaegebeur JM, Bacha EA, Chen JM, Bourlon F, Williams IA. Outcomes of the infant Ross procedure for congenital aortic stenosis followed into adolescence. *J Thorac Cardiovasc Surg.* 2013;145:1504-11.
12. Brancaccio G, Polito A, Hoxha S et al. The Ross procedure in patients aged less than 18 years: The midterm results. *J Thorac Cardiovasc Surg.* 2014;147:383-8.
13. Poynter JA, Eghtesady P, McCrindle BW et al. Association of pulmonary conduit type and size with durability in infants and young children. *Ann Thorac Surg.* 2013;96:1695-702.



# Chapter 3

## **Echocardiography Findings after the Ross Operation in Neonates and Infants**

**Aart Mookhoek, Bas R Rebel, Ad J J C Bogers, Regina Bökenkamp, Mark G Hazekamp,  
Folkert J Meijboom, Paul H Schoof, Eleni-Rosalina Andrinopoulou, Jaroslav Hruda,  
Irene M Kuipers, Luc HPM Filippini, Johanna J M Takkenberg**

*Submitted*

## **Abstract**

### **Background**

Long-term follow-up after the Ross operation in neonates and infants is still limited. While waiting for patients to reach puberty, echocardiography may offer insights into possible future events. Therefore, we used advanced statistical methods to study evolution over time of left ventricular function, autograft dimensions and valve function.

### **Methods**

In a retrospective multicenter study, echocardiograms of 42 neonates and infants who survived a Ross operation between 1990 and 2013 were analyzed. An echocardiography protocol was developed for this study to measure ejection fraction, autograft root dimensions, severity of valve regurgitation and stenosis and endocardial fibroelastosis. Evolution over time of echocardiographic variables was analyzed using mixed-effects models.

### **Results**

Median follow-up was 3.2 years (interquartile range 1.0 – 7.2 years). Three patients (7%) died during follow-up. No patient required autograft reintervention, 10 patients required right-sided reinterventions. Left ventricular function significantly improved over time ( $p < 0.001$ ) with an increase in fractional shortening from  $26 \pm 14\%$  pre-operatively to  $34 \pm 2\%$  at last follow-up. Evolution of autograft root diameter showed an increase at the sinotubular junction level ( $p < 0.001$ ) with a Z-score increase from  $2.6 \pm 1.1$  to  $3.1 \pm 1.3$ . No time-related changes were observed in autograft valve regurgitation or stenosis. Pulmonary regurgitation and stenosis increased significantly over time ( $p < 0.001$  and  $p = 0.014$ , respectively).

### **Conclusions**

The Ross operation offers adequate relief of left ventricular outflow tract obstruction in neonates and infants. The first decade after the operation is characterized by an improvement of left ventricular function. Moreover, autograft root growth is parallel to somatic growth with preservation of autograft valve function.



## Introduction

Treatment options for neonates and infants with severe left ventricular outflow tract obstruction are limited. When biventricular repair is feasible, the Ross operation is currently considered the treatment of choice [1]. Additionally, surgical valvotomy and balloon valvuloplasty are firmly established techniques which may delay the need for aortic valve replacement and allow patients to grow [2]. The rationale behind this approach is to delay a complex operation with high early mortality, especially in neonates.

In recent years, several studies have reported clinical experience with the Ross operation in neonates and infants [3-6]. Interestingly, several patients who underwent the Ross operation as neonate or infant have now reached puberty. However, long-term follow-up is still limited as the majority of patients have been operated in the last decade. While waiting for more patients to reach puberty and beyond, advanced statistical methods may aid in prediction of future events based on analysis of echocardiographic parameters [7]. For instance, evolution of pulmonary autograft dimensions in the rapidly growing child may offer information on whether the expected increase in root dimension is parallel to or out of pace with somatic growth. In addition, we are interested in whether left ventricular function normalizes after the Ross operation in neonates and infants with severely impaired left ventricular function.

To answer these questions, we performed a retrospective multicenter echocardiography study in patients who underwent a Ross operation as neonate or infant in The Netherlands.

## Patients and Methods

Institutional review board permission for this retrospective observational study in which echocardiograms were re-evaluated was obtained in participating centers (Erasmus MC IRB approval THCHOZ 2012-13). Informed consent was obtained from the patient's parents or legal guardians.

### Patient inclusion

Neonates (age < 30 days) and infants (age < 1 year) who underwent aortic valve replacement with a pulmonary autograft in congenital cardiac centers in Rotterdam, Leiden and Utrecht (The Netherlands) between 1990 and 2013 for whom echocardiographic follow-up was available were included in the study. As we were interested in the post-operative evolution over time of echocardiographic variables, patients who died in-hospital or within 30 days after the operation were excluded from the study.

## Data collection

The current study is a satellite project from a large European initiative to study the Ross operation in neonates and infants [8]. Data regarding pre-operative patient characteristics, surgical details and follow-up data after the operation were collected retrospectively as part of this initiative. Echocardiographic exams were collected at several time points for each patient: last exam prior to operation, last exam prior to discharge from hospital after operation, at 3, 6, 9 and 12 months and annually thereafter. When a patient had a valve-related reintervention during follow-up, the last exam prior to reintervention and last exam prior to discharge were also collected. Because of the retrospective nature of this study, there was no uniformity in echocardiographic recording between participating centers.

To minimize inter-observer variability in reporting, an echocardiography protocol was developed for this study (Appendix 1). Measurements of pulmonary autograft annulus, sinus and sinotubular junction diameter in systole as well as left ventricular end diastolic and systolic dimensions were transformed into Z-scores based on data from Pettersen et al. [9], measurements of ascending aorta diameter based on data from Warren et al. [10]. To allow Z-score calculation, body surface area was calculated using the Mosteller formula [11]. Peak velocity measurements over the semilunar valves were transformed into stenosis grades: 0, less than 2m/s; 1, between 2 and 2.9m/s; 2, between 3 and 3.9 m/s; 3, more than 4m/s. Fibroelastosis was graded according to its distribution in the left ventricle: 0, no fibroelastosis; 1, limited to papillary muscles; 2, papillary muscles and less than 50% of endocardium involvement; 3, papillary muscles and more than 50% of endocardium involvement. Re-evaluation of the echocardiograms using our protocol was performed by one experienced pediatric cardiologist from each participating center: Rotterdam (BR), Leiden (RB) and Utrecht (FM).

## Statistical analysis

Descriptive data analysis was performed using IBM SPSS version 21.0 (IBM, Somers, NY, USA). Normal distribution of data was assessed using the Shapiro-Wilk test. Reported values are quoted as mean and standard deviation or median and interquartile range for continuous variables and percentages for discrete variables. Overall survival and freedom from right ventricular outflow tract (RVOT) reintervention after the Ross operation were analyzed using the Kaplan-Meier method. Paired samples t-tests were performed to analyze autograft diameter comparing the first and last exam during follow-up. Ninety-five percent confidence intervals were calculated using log transformation of the cumulative hazard function.

Advanced statistical analyses were performed using R (version 3.1.1, available at [www.r-project.org](http://www.r-project.org)). Evolution over time of the echocardiographic variables of interest was analyzed accounting for the correlation between repeated measurements in each patient

using mixed-effects models [7]. For these analyses, the last echocardiographic exam prior to the Ross operation was excluded. Analysis of pulmonary regurgitation and stenosis was performed using all data obtained prior to the first reintervention on the right ventricular outflow tract. For the purpose of mixed-effects modelling of autograft and pulmonary stenosis grade, stenosis grade 2 and 3 were combined.

Mixed-effects models consist of fixed effects describing the average evolution over time of a specific variable and random effects describing the evolution over time for each patient. We corrected for age at the time of the Ross operation and presence of septal myectomy in the fixed effects component of the model for all variables, except for the Z-score of the sinotubular junction diameter due to limited available data. Longitudinal analysis of aortic stenosis grade was not possible as in only one patient autograft stenosis grade greater than zero was measured during follow-up.

## Results

During the inclusion period, 50 neonates and infants underwent the Ross operation in the participating centers. There were seven early deaths and in one patient no echocardiographic follow-up was available. As a result, 42 patients were included in the study (Table 1).

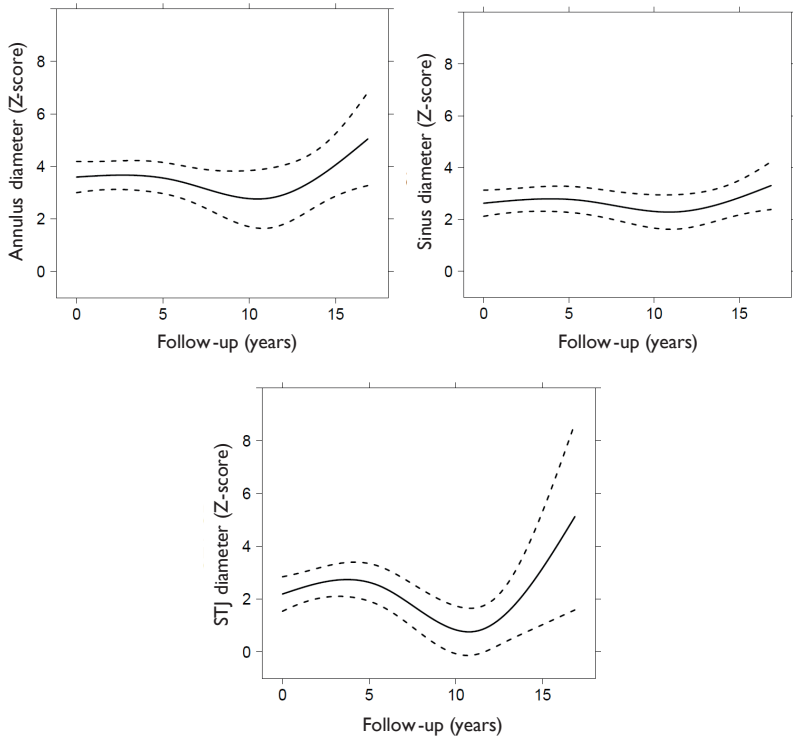
**TABLE 1** Patient characteristics

Total patients		42
Sex	Male	34 (81%)
	Female	8 (19%)
Concomitant CHD *		29 (69%)
	Aortic arch interruption / hypoplasia	9 (21%)
	Aortic coarctation	4 (10%)
	Mitral dysplasia	2 (5%)
Age at Ross	Neonates	5 (12%)
	Infants	37 (88%)
	Range	16 – 347 days
Emergency surgery		1 (2%)
Septal myectomy		32 (76%)
RVOT graft	Pulmonary homograft	23 (55%)
	Aortic homograft	5 (12%)
	Xenograft	14 (33%)

\* Only major congenital heart disease listed, overlapping categories. CHD indicates congenital heart disease; RVOT, right ventricular outflow tract.

Median follow-up after the Ross operation was 3.2 years (interquartile range 1.0 – 7.2, range 0.1 – 16.9). Three patients died during follow-up: 1 at reintervention on the right

ventricular outflow tract (RVOT) graft after one year, 1 of cardiogenic shock after two years and 1 of sudden cardiac death 12 years after the Ross operation. Estimated survival after 5 years was 93.2% (95% CI 84.6 – 100.0%). No patient required reintervention on the pulmonary autograft. The RVOT graft required reintervention 17 times in 10 patients. Freedom from RVOT reintervention at 5 years was 68.2% (95% CI 51.6 – 90.3%).

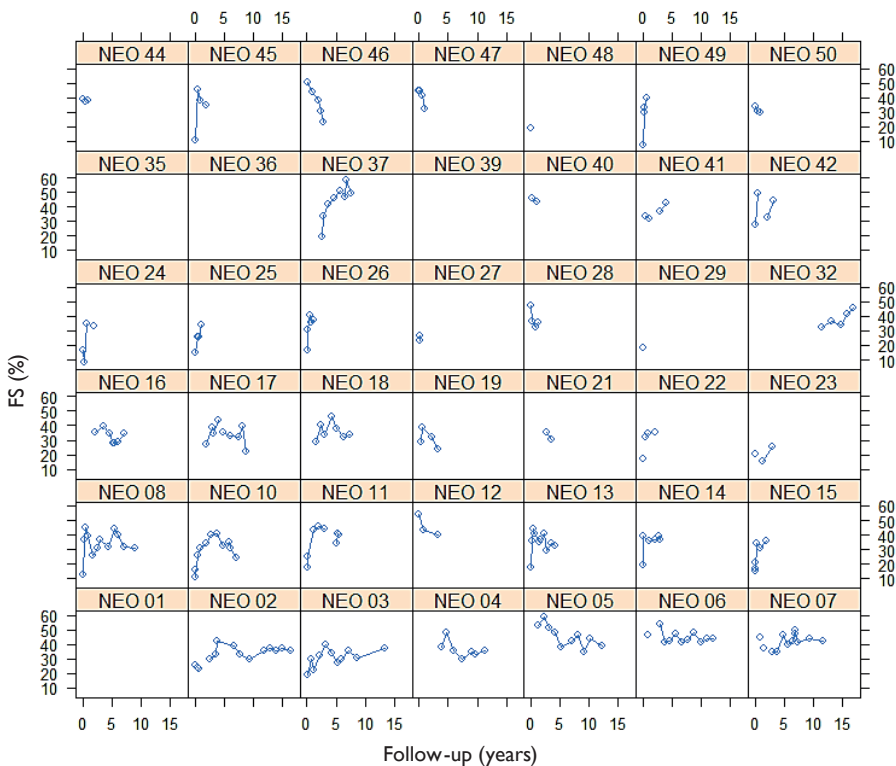


**FIGURE 1** Evolution over time of autograft root diameter  
Autograft root diameter at the level of the annulus (A), sinus (B) and sinotubular junction (C). Continuous line represents mean Z-score, while dashed lines represent the 95% confidence interval. STJ indicates sinotubular junction.

In total, 306 echocardiographic exams were evaluated (median number per patient 6, range 1 to 16). On average, left ventricular systolic function was impaired at the time of the last exam prior to discharge from hospital after Ross operation with a mean fractional shortening of  $26 \pm 14\%$ . Mixed-effects models showed an overall improvement over time in fractional shortening ( $34 \pm 2\%$ ,  $p < 0.001$ ). Individual patient evolution was variable, with five patients showing deterioration of left ventricular function with a continuous decrease in fractional shortening over time (patients 12, 21, 46, 47 and 48 in Figure 1). In patient

46, obstruction of the left coronary artery was suspected intra-operatively upon failure to come off bypass. After coronary button reimplantation, contractility improved and the patient was successfully weaned from bypass.

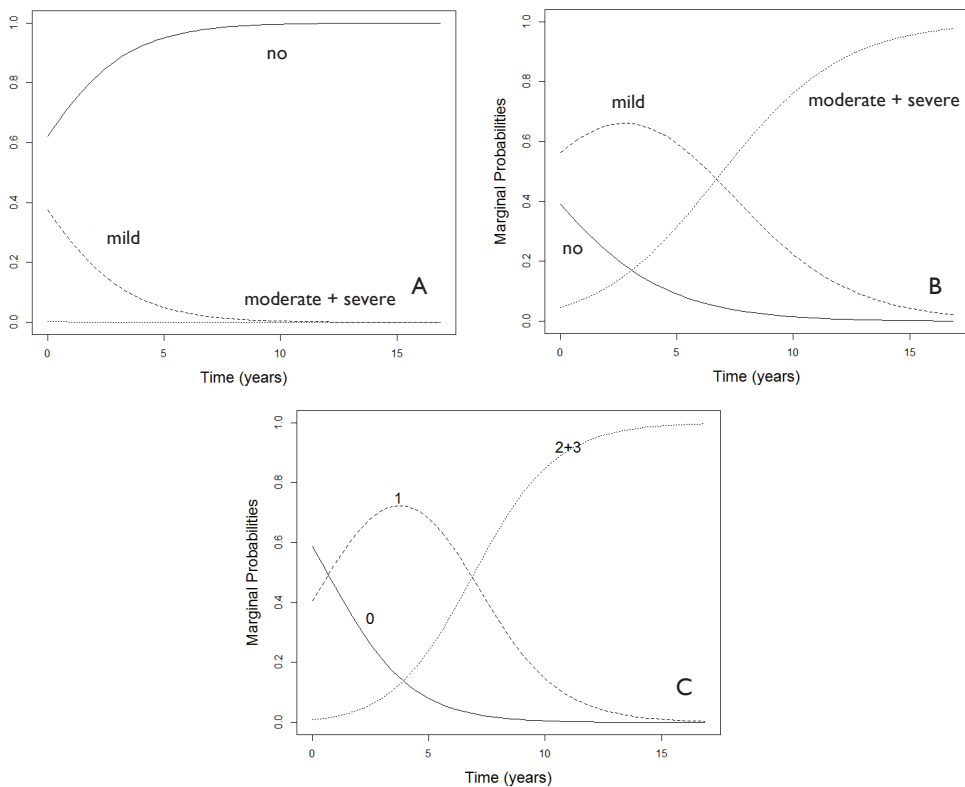
Comparing the first and last exam after the operation (median interval 3.7 years, interquartile range 1.6 – 7.4), dimensions of the pulmonary autograft increased at each level of the root: annulus (12 to 19 mm,  $p<0.001$ ), sinus (16 to 25 mm,  $p<0.001$ ) and sinotubular junction (14 to 20 mm,  $p=0.002$ ). The autograft root was dilated directly after the Ross operation at the level of the annulus (Z-score  $3.2\pm 1.9$ ), sinus (Z-score  $2.6\pm 1.1$ ) and sinotubular junction (Z-score  $2.4\pm 1.7$ ). At the last exam during follow-up, dilatation was still present at the level of the annulus (Z-score  $3.4\pm 1.6$ ), sinus (Z-score  $3.1\pm 1.3$ ) and sinotubular junction (Z-score  $2.7\pm 1.5$ ). Analysis with mixed-effects models showed a significant Z-score increase over time only at the level of the sinotubular junction ( $p<0.001$ ) (Figure 2).



**FIGURE 2** Patient-specific evolution over time of fractional shortening  
Individual patients are represented by “NEO” followed by a number for each patient. FS indicates fractional shortening.

Prior to the Ross operation, echocardiographic features of endocardial fibroelastosis were present in 22 patients: 9 patients with grade 1, 10 with grade 2 and 3 with grade 3. A decrease in endocardial fibroelastosis grade was observed in four patients (18%): grade 3 to 1 in the first post-operative month, grade 2 to 1 in the first post-operative month, grade 1 to 0 after six months and grade 2 to 0 after three years.

Autograft valve function was good in the majority of patients at the time of discharge after Ross operation with one patient having greater than mild autograft valve regurgitation and one patient having greater than grade 1 autograft valve stenosis. Mixed-effects models did not show time-related changes in autograft valve regurgitation ( $p=0.113$ ), which is illustrated by our prognostic model (Figure 3A). Since only one patient presented with autograft valve stenosis, longitudinal analysis was not possible.



**FIGURE 3** Patient-specific prediction of valve function evolution over time Severity of autograft regurgitation (A), pulmonary regurgitation (B) and pulmonary stenosis (C).

Function of the RVOT graft was good in the majority of patients at the time of discharge after Ross operation with five patients having greater than mild pulmonary regurgitation and one patient having more than grade I pulmonary stenosis. Mixed-effects models showed an increase over time in both pulmonary regurgitation ( $p=0.014$ ) and pulmonary stenosis ( $p<0.001$ ) (Figure 3B and C).

Regurgitation of the mitral and tricuspid valve at the time of discharge after Ross operation was limited to three and two patients, respectively. Mixed-effects modeling did not show time-related changes in mitral ( $p=0.259$ ) or tricuspid regurgitation ( $p=0.161$ ).

## Comment

We have shown an improvement in left ventricular systolic function after the Ross operation in neonates and infants. While the majority of patients had (severely) impaired left ventricular function at the time of the operation, function at latest follow-up was restored to normal in the majority of patients. Our findings closely resemble those from Frigiola et al. in pediatric patients, who showed increased left ventricular ejection fraction after the Ross operation [12]. Despite improvement in left ventricular systolic function, endocardial fibroelastosis persisted in the majority of patients.

The autograft root was shown to be dilated directly after the Ross operation according to aortic Z-scores. One could argue that the Z-scores on which this statement is based, were developed for native aortic valves whereas the autograft valve is in fact a native pulmonary valve. Consequently, aortic Z-scores in the context of the Ross operation should be interpreted with caution. More important is that at the level of the annulus and sinus, diameter increase during follow-up was parallel to somatic growth as Z-scores remained stable over time. Similarly, Lo Rito et al. showed stable Z-scores during follow-up in patients who underwent the Ross operation below the age of 18 months [13]. Interestingly, we have shown an autograft root diameter increase out of pace with somatic growth at the level of the sinotubular junction. In addition, we report a cautious trend towards increased Z-scores at all levels of the pulmonary autograft root after the first decade.

Autograft valve function remained good during follow-up. Autograft stenosis was present in only one patient and autograft regurgitation did not progress over time in any patient. These findings explain the 100% freedom from autograft reoperation in our series. Freedom from autograft reoperation was similarly favorable in the series from Birmingham [13]. Interestingly, there is a somewhat puzzling discrepancy between the Dutch and British series compared to the findings of the Italian Pediatric Ross Registry [6]. In the Italian series 6 of 29 infants (20.7%) were reoperated after a mean follow up of  $8.4\pm 4.9$  years.

Progression of both pulmonary regurgitation and stenosis were anticipated and in accordance with other studies on the use of these grafts in neonates and infants. The relatively low number of reoperations most likely reflects our short follow-up duration and future reinterventions due to progression of pulmonary regurgitation and stenosis should be anticipated. RVOT graft dysfunction remains an important drawback of the Ross operation when performed at an early age.

Application of mixed-effects modelling allows us to make predictions for future patients while accounting for the special features of the data, such as the correlation between measurements obtained from the same patient. Based on our dataset, we have predicted the evolution over time of left ventricular function, as measured by fractional shortening, for a patient aged 113 days receiving the Ross operation with septal myectomy (Figure 3). Future studies may focus on increasing the power of these predictive models and integrating them in decision making in daily clinical practice.

## Limitations

To study the evolution over time of the echocardiographic variables of interest, we excluded patients who did not survive the early post-operative period as they did not contribute to echocardiographic follow-up. The result of this selection is creation of a cohort with limited coexisting congenital heart disease compared to previously reported cohorts [4,5].

Retrospective re-evaluation of echocardiographic exams in the setting of a multicenter study was associated with several limitations. There were certain differences, both between centers and within centers over time, in the quality and range of views and modalities of stored images. In addition, early echocardiographic exams were stored on videotapes, which made re-evaluation difficult.

Missing data, data loss and limited follow-up duration prevented more detailed data analysis. In the future, we would like to correct for more baseline covariates and study the possible interaction between baseline covariates and evolution over time of echocardiographic variables of interest. More data and a longer follow-up duration will also increase the accuracy of our prediction models, which may allow them to be implemented in clinical practice.

## Conclusions

The Ross operation offers adequate relief of left ventricular outflow tract obstruction in neonates and infants. During the first decade after the operation an improvement of left ventricular function is observed. Moreover, autograft root growth is parallel to somatic growth with preservation of autograft valve function.



## References

1. Stelzer P. The Ross procedure: state of the art 2011. *Semin Thorac Cardiovasc Surg.* 2011;23:115-23.
2. Hraška V, Sinzobahamya N, Haun C, et al. The long-term outcome of open valvotomy for critical aortic stenosis in neonates. *Ann Thorac Surg.* 2012;94:1519-26.
3. Shinkawa T, Bove EL, Hirsch JC, et al. Intermediate-term results of the Ross procedure in neonates and infants. *Ann Thorac Surg.* 2010;89:1827-32.
4. Maeda K, Rizal RE, Lavrsen M, et al. Midterm results of the modified Ross/Konno procedure in neonates and infants. *Ann Thorac Surg.* 2012;94:156-62.
5. Elder RW, Quaegebeur JM, Bacha EA, Chen JM, Bourlon F, Williams IA. Outcomes of the infant Ross procedure for congenital aortic stenosis followed into adolescence. *J Thorac Cardiovasc Surg.* 2013;145:1504-11.
6. Luciani GB, Lucchese G, Carotti A, et al. Two decades of experience with the Ross operation in neonates, infants and children from the Italian Paediatric Ross Registry. *Heart.* 2014;100:1954-9.
7. Andrinopoulou ER, Rizopoulos D, Jin R, Bogers AJ, Lesaffre E, Takkenberg JJ. An introduction to mixed models and joint modeling: analysis of valve function over time. *Ann Thorac Surg.* 2012;93:1765-72.
8. Mookhoek A, Charitos EI, Hazekamp MG, et al. Ross Procedure in Neonates and Infants: a European Multicenter Experience. *Ann Thorac Surg.* 2015;100:2278-84.
9. Pettersen MD, Du W, Skeens ME, Humes RA. Regression equations for calculation of z scores of cardiac structures in a large cohort of healthy infants, children, and adolescents: an echocardiographic study. *J Am Soc Echocardiogr.* 2008;21:922-34.
10. Warren AE, Boyd ML, O'Connell C, Dodds L. Dilatation of the ascending aorta in paediatric patients with bicuspid aortic valve: frequency, rate of progression and risk factors. *Heart.* 2006;92:1496-500.
11. Mosteller RD. Simplified calculation of body-surface area. *N Engl J Med.* 1987;317:1098.
12. Frigiola A, Varrica A, Satriano A, et al. Neo-aortic valve and root complex evolution after Ross operation in infants, children, and adolescents. *Ann Thorac Surg.* 2010;90(4):1278-85.
13. Lo Rito M, Davies B, Brawn WJ, et al. Comparison of the Ross/Ross-Konno aortic root in children before and after the age of 18 months. *Eur J Cardiothorac Surg.* 2014;46:450-7; discussion 457.

## Appendix I Echocardiographic protocol

Variable	Measurement	View	Modality
Root diameter	In mm, inner edge to inner edge at 90° relative to blood flow	PLAX	2D
Sinus	In mm, inner edge to inner edge at 90° relative to blood flow, maximum diameter	PLAX	2D
STJ	In mm, inner edge to inner edge at 90° relative to blood flow	PLAX	2D
Ascending aorta	In mm, inner edge to inner edge at 90° relative to blood flow	PLAX / suprasternal	2D
Aortic regurgitation	Grade 0 / 1 / 2 / 3, experience of cardiologist	ALAX / 5Ch / suprasternal	CD
Aortic stenosis	Peak velocity In m/s	ALAX / 5Ch / suprasternal	CW
	Mean gradient In mmHg	ALAX / 5Ch / suprasternal	CW
	IndexedAVA In cm/m <sup>2</sup>	PSAX	2D
Pulmonary regurgitation	Grade 0 / 1 / 2 / 3, experience of cardiologist	PSAX	CD
Pulmonary stenosis	Peak velocity In m/s	PSAX / PLAX tilted	CW
Mitral regurgitation	Grade 0 / 1 / 2 / 3, experience of cardiologist	4Ch	CD
Tricuspid regurgitation	Grade 0 / 1 / 2 / 3, experience of cardiologist	4Ch	CD
LV function	FS In %	PLAX	M-mode
	LVEDD In mm	PLAX / PSAX	M-mode
	LVEDS In mm	PLAX / PSAX	M-mode
Fibroelastosis	Grade 0 / 1 / 2 / 3, based on distribution	4Ch	2D

STJ indicates sinotubular junction; AVA, aortic valve area; FS, fractional shortening; LVEDD, left ventricular end diastolic dimension; LVEDS, left ventricular end systolic dimension; PLAX, parasternal long axis; ALAX, apical long axis; 5Ch, 5 chamber; PSAX, parasternal short axis; 4Ch, 4 chamber; CD, color Doppler; CW, continuous wave Doppler.

# Chapter 4

## **European Multicentre Experience with Valve-sparing Reoperations after the Ross Procedure**

**Aart Mookhoek, Laurent de Kerchove, Gebrine El Khoury, Timo Weimar,  
Giovanni Battista Luciani, Alessandro Mazzucco, Ad J J C Bogers, Diana Aicher,  
Hans-Joachim Schäfers, Efstratios I Charitos, Ulrich Stierle, Johanna J M Takkenberg**

## **Abstract**

### **Objectives**

Autograft valve preservation at reoperation may conserve some of the advantages of the Ross procedure. However, results of long-term follow-up are lacking. In this retrospective multicentre study, we present our experience with valve-sparing reoperations after the Ross procedure with focus on long-term outcome.

### **Methods**

A total of 86 patients from 6 European centres who underwent valve-sparing reoperation after the Ross procedure between 1997 and 2013 were included in the study.

### **Results**

Reoperation was performed a median of 9.1 years after the Ross procedure in patients with a median age of 38.4 years (interquartile range 27.1-51.6 years). Pre-operative severe autograft regurgitation (grade  $\geq 3$ ) was present in 46% of patients. In-hospital mortality was 1%. During a median follow-up of 4.3 years, 3 more patients died of non-cardiac causes resulting in a cumulative survival at 8 years of 89% (95% CI: 65%-97%). Fifteen patients required a reintervention after valve-sparing reoperation, mostly due to prolapse or retraction of autograft cusps. Freedom from reintervention was 76% (95% CI: 57%-87%) at 8 years. The reintervention hazard was increased in patients with isolated and/or severe aortic regurgitation at valve-sparing reoperation. In patients without reintervention after valve-sparing autograft reoperation (N=63), severe aortic regurgitation was present in 3% at last follow-up.

### **Conclusions**

Valve-sparing autograft reoperations after the Ross procedure carry a low operative risk, with acceptable reintervention rates in the first post-operative decade. Patients with isolated and/or severe autograft regurgitation have an increased hazard of reintervention after valve-sparing reoperation, and require careful preoperative weighing of surgical options.

## Introduction

Aortic valve replacement through the Ross procedure offers patients a living valve substitute with good hemodynamics and freedom from long-term use of anticoagulation. The main concern following the Ross procedure in adult patients is reoperation on the autograft due to progressive root dilatation and/or autograft insufficiency.<sup>1</sup>

Historically, reoperations following the Ross procedure consisted of excision of autograft material followed by a Bentall procedure.<sup>2</sup> Nowadays, surgeons prefer to attempt a preservation of the autograft valve when possible by performing a valve-sparing reoperation in an attempt to maintain the advantages associated with a functioning autograft valve.<sup>3,4</sup> However, concern exists about the long-term fate of the autograft cusps after the valve-sparing reoperation.

Evidence on outcome after valve-sparing reoperations after the Ross procedure is scarce, as only a few centres have published their short-term results.<sup>4,5</sup> This study aims to determine the durability of valve-sparing reoperations after the Ross procedure in the first postoperative decade in a retrospective European multicentre cohort study.

## Methods

Institutional review board permission for this study was obtained in each centre. Informed written consent was obtained from all patients. The study was performed in accordance with the Declaration of Helsinki.

### Patient inclusion and data collection

All patients who received a valve-sparing reoperation after the Ross procedure in one of the six participating centres were included in the study. Our cohort includes several patients which have been reported upon previously by Luciani et al. (N=17), De Kerchove et al. (N=26) and Charitos et al. (N=24).<sup>4,6</sup>

Pre-operative patient characteristics including information on the initial Ross procedure, peri-operative surgical data on the valve-sparing reoperation after the Ross procedure and post-operative follow-up data were retrospectively collected in each of the participating centres. In total, 86 patients operated between 1997 and 2013 were included in the study.

### Data analysis

Statistical analyses were performed using IBM SPSS 21.0 (IBM, Somers, NY, USA). Normal distribution of continuous data was assessed using the Shapiro-Wilk test. Continuous variables are displayed as mean  $\pm$  standard deviation or median  $\pm$  (interquartile) while discrete variables are displayed as counts and percentages.

**TABLE 1** Patient characteristics at initial Ross procedure

<b>Total patients</b>		<b>86</b>
<b>Sex</b>	Male	<b>69 (80%)</b>
	Female	<b>17 (20%)</b>
<b>Age at Ross procedure*</b>	Median	<b>29.9</b>
	Interquartile range	<b>16.5 – 42.2</b>
	Range	<b>7.5 – 58.3</b>
<b>Native aortic valve</b>	Children (<18 years)	<b>23 (27%)</b>
	Unicuspid	<b>6 (7%)</b>
	Bicuspid	<b>61 (71%)</b>
	Tricuspid	<b>15 (17%)</b>
	Unspecified	<b>4 (5%)</b>
<b>Prior cardiac surgery</b>	Patients	<b>18 (21%)</b>
	Procedures	<b>20</b>
<b>Indication Ross procedure</b>	Regurgitation	<b>41 (48%)</b>
	Stenosis	<b>16 (19%)</b>
	Combined	<b>28 (33%)</b>
	Unspecified	<b>1 (1%)</b>
<b>Aetiology</b>	Congenital	<b>49 (57%)</b>
	Degenerative	<b>23 (27%)</b>
	Endocarditis	<b>4 (5%)</b>
	Rheumatic	<b>1 (1%)</b>
	Prosthesis mismatch	<b>1 (1%)</b>
	Prosthesis thrombosis	<b>1 (1%)</b>
	Cusp repair failure	<b>1 (1%)</b>
	Unspecified	<b>6 (7%)</b>
<b>Ross technique</b>	Root replacement	<b>73 (85%)</b>
	Inclusion cylinder	<b>10 (12%)</b>
	Sub coronary	<b>3 (3%)</b>
<b>RVOT graft type</b>	Homograft	<b>84 (98%)</b>
	Bioprosthesis	<b>2 (2%)</b>

\* Age at Ross procedure does not conform to a normal distribution. RVOT indicates right ventricular outflow tract.

Overall survival and freedom from reintervention after valve-sparing reoperation were analysed using the Kaplan-Meier method. Curves were truncated when the number of patients at risk dropped below 9 (<10% of the original population at risk). Ninety-five percent confidence intervals were calculated using log transformation of the cumulative hazard function.

With Cox regression, a univariable analysis of potential risk factors for reintervention after valve-sparing reoperation was performed. Variables included sex, bicuspid aortic valve yes/no, indication for initial Ross procedure (aortic regurgitation, aortic stenosis, combination), Ross technique (full root, inclusion cylinder, sub coronary), interval from the Ross procedure at time of valve-sparing reoperation, age at time of valve-sparing reoperation, isolated aortic regurgitation as indication for valve-sparing reoperation yes/no, prolapse yes/no, severe aortic regurgitation at the time of valve-sparing reoperation (grade  $\geq 3$ ) yes/no, valve-sparing autograft root replacement yes/no, reimplantation versus remodelling technique, annulus repair yes/no and isolated autograft valve repair yes/no. Pearson's correlation coefficient was used to assess correlations between variables included in the univariable analyses. A one-way ANOVA with Tukey's honestly significant difference post-hoc test was performed to assess possible differences in reintervention rates after valve-sparing reoperation between the three types of valve-sparing autograft root replacement techniques.

## Results

In the participating centres, 1783 Ross procedures were performed from 1997 to 2013. During this period, 87 patients (44.2%) received a valve-sparing reoperation after the Ross procedure out of a total of 197 patients who required at least one reoperation on the autograft. One patient was excluded from our study population due to intra-operative conversion to autograft valve replacement. An overview of patient and procedural characteristics at the time of the initial Ross procedure is provided in Table 1. An overview of the peri-operative details of the valve-sparing reoperation after the Ross procedure is provided in Table 2, while Table 3 provides details of autograft valve repair. At the time of the valve-sparing reoperation after the Ross procedure, median age of patients was 38.4 years (interquartile range 27.1-51.6 years).

### Early outcome

Following the valve-sparing reoperation after the Ross procedure, one patient died on day 9 post-operatively following cardiac arrest. With one death, 30-day mortality was 1.2% (binomial 95% confidence interval: 0.03% - 6.24%) .

One patient, who had isolated autograft valve repair, underwent reintervention after valve-sparing reoperation on day five post-operatively due to grade III autograft regurgitation. The autograft valve was replaced by a homograft valve. Bleeding complications occurred in three patients, requiring resternotomy in two. One patient suffered from a transient ischemic attack.

Median hospital stay was 7 days (interquartile range 6 to 9 days, range 4 to 17 days).

**TABLE 2** Characteristics of valve-sparing reoperation after Ross procedure

<b>Procedures</b>		<b>86</b>	
	Emergency	1 (1%)	
	Elective	79 (99%)	
<b>Time after Ross procedure</b>	Median	9.1	years
	Interquartile range	5.8 – 12.6	years
	Range	0.0 – 20.7	years
<b>Indication</b>	Aneurysm	36 (42%)	
	Regurgitation	16 (19%)	
	Combined	28 (33%)	
	RVOT graft stenosis	1 (1%)	
	Unspecified	5 (6%)	
<b>Aetiology</b>	Degenerative	72 (84%)	
	Endocarditis	6 (7%)	
	Acute dissection	1 (1%)	
	Unspecified	7 (8%)	
<b>Autograft root diameter * †</b>	Annulus	26.6 ± 4.9	mm
	Sinus	49.7 ± 5.0	mm
	STJ	47.0 ± 5.3	mm
	Ascending aorta	49.2 ± 4.9	mm
<b>Autograft regurgitation (N=79)</b>	None / trace	3 (4%)	
	Grade I	17 (22%)	
	Grade II	23 (29%)	
	Grade III	23 (29%)	
	Grade IV	13 (16%)	
<b>Annulus repair (N=80)</b>		57 (71%)	
	Circular annuloplasty ‡	40	
	Cabrol stitches	16	
	Unspecified	1	
<b>Valve-sparing autograft root replacement (N=81)</b>		70 (86%)	
	Reimplantation	37	
	Remodelling	17	
	Supra-coronary	16	
<b>STJ remodelling (N=74)</b>		20 (27%)	
<b>Cusp abnormalities (N=81) §</b>		33 (41%)	
	Prolapse	31	
	Fenestration	2	
	Perforation	3	
	Retraction	2	
	Calcification	1	



**TABLE 2** Characteristics of valve-sparing reoperation after Ross procedure (*Continued*)

<b>Autograft valve repair (N=79) §</b>	<b>34 (43%)</b>
Central plication	28
Suture free edge	10
Pericardial patch	2
<b>Perfusion time (N=66) *</b>	145.0 ± 60.3 minutes
<b>Cross-clamp time (N=66) *</b>	107.1 ± 46.2 minutes
<b>Circulatory arrest (N=54) *</b>	4 (7%)
	26.3 ± 35.0 minutes
<b>Concomitant surgery §</b>	<b>20 (23%)</b>
RVOT graft replacement	16
Hemi-arch replacement	3
ASD closure	1
VSD closure	1

For several variables, number of patients from which data was available is indicated by “(N)”. \*Values represent mean ± standard deviation. † Diameters provided only for patients with autograft root aneurysms without severe autograft valve regurgitation ‡ Includes 37 patients with aortic root reimplantation (David procedure). § Overlapping categories. RVOT indicates right ventricular outflow tract; STJ, sinotubular junction; ASD, atrial septal defect; VSD, ventricular septal defect.

**TABLE 3** Reinterventions after valve-sparing reoperation

<b>Total (N)</b>	<b>15</b>
<b>Indication</b>	<b>13 (86.7%)</b>
Autograft regurgitation	13 (86.7%)
Autograft stenosis	1 (6.7%)
Autograft root dilatation	1 (6.7%)
<b>Cusp abnormalities</b>	<b>8 (66.7%)</b>
Cusp prolapse	8 (66.7%)
Cusp retraction	4 (26.7%)
Combination	1 (6.7%)
Cusp calcifications	2 (13.3%)
<b>Procedure</b>	<b>10 (53.3%)</b>
Autograft valve repair	1 (6.7%)
Replacement with mechanical prosthesis	10 (53.3%)
Replacement with biological prosthesis	4 (26.7%)

### Late mortality

Follow-up following the valve-sparing reoperation after the Ross procedure was 95% complete, with a median duration of 4.3 years (interquartile range 2.4 to 6.3 years, range 54 days to 16.2 years, 343 patient years). There were 3 cancer-related deaths at 5.8, 7.5 and 10.0 years. Estimated freedom from all-cause mortality at eight years follow-up was 89% (95% confidence interval: 65%-97%).

## Reintervention after valve-sparing reoperation

Surgical reintervention after valve-sparing reoperation was performed in 15 patients (Table 3). Estimated freedom from reintervention was 76% at eight years follow-up (95% confidence interval: 57%-87%) (Figure 1). While most autograft cusps appeared thin and pliable at explantation, two patients presented with autograft cusp calcifications.

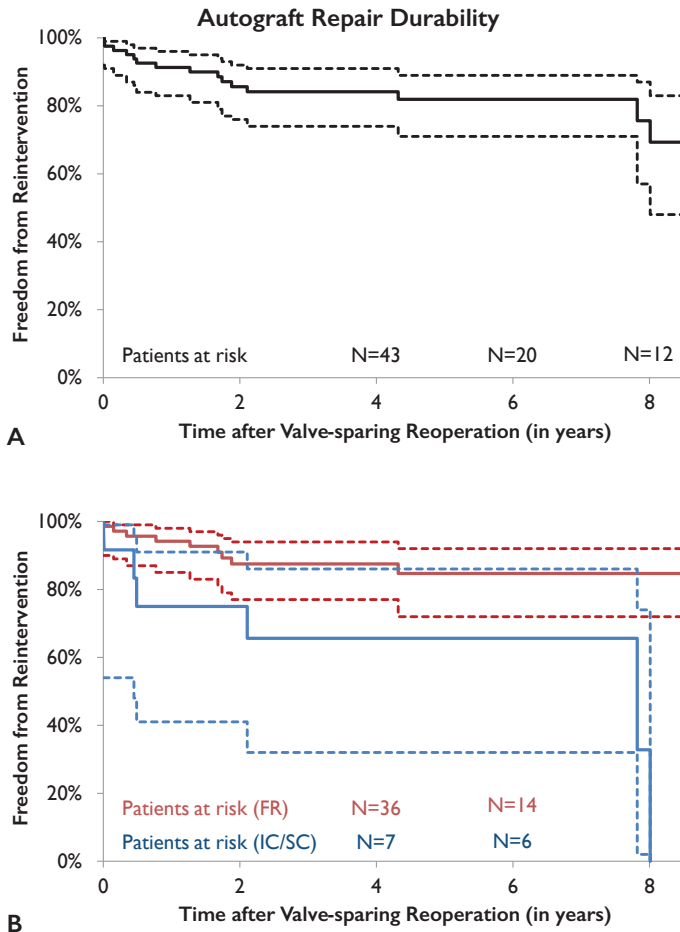
Univariable analysis revealed several variables that were potentially associated with the hazard of reintervention after valve-sparing reoperation (Table 4). Isolated autograft valve repair was associated with an increased hazard of reintervention. Estimated freedom from reintervention at eight years follow-up was 33% in patients with isolated autograft valve repair (7 out of 11 patients) compared to 85% in patients with valve-sparing autograft root replacement with or without valve repair (8 out of 70 patients). Reintervention rates after valve-sparing reoperation were not significantly different between patients who received valve-sparing autograft root replacement using the reimplantation (4 out of 37 patients), remodelling (3 out of 17 patients) or supra-coronary technique (1 out of 16 patients) ( $P=0.503$ ).

Since the low number of events precluded performing a multivariable analysis, we performed correlation analysis between the variables that were significant in the univariable analysis. Isolated autograft regurgitation as indication for valve-sparing reoperation after the Ross procedure was negatively correlated with use of the full root technique at the initial Ross procedure (coefficient  $-0.459$ ,  $P<0.001$ ) and valve-sparing autograft root replacement (coefficient  $-0.891$ ,  $P<0.001$ ). It was not correlated with age at the time of valve-sparing reoperation (coefficient  $-0.060$ ,  $P=0.594$ ).

**TABLE 4** Univariable analysis of the hazard of reinterventions after valve-sparing reoperation

Variable		Hazard ratio *	P-value
Ross technique	Full root	1.000	
	Inclusion cylinder	4.358 (1.454 – 13.064)	0.009
	Sub coronary	4.005 (0.497 – 32.286)	0.193
Age		0.944 (0.906 – 0.985)	0.007
Isolated aortic regurgitation †		5.021 (1.721 – 14.649)	0.003
Severe aortic regurgitation (grade $\geq 3$ ) ‡		3.736 (1.165 – 11.978)	0.027
Isolated autograft valve repair		5.041 (1.677 – 15.154)	0.004
Valve-sparing autograft root replacement		0.199 (0.070 – 0.565)	0.002

\*Hazard ratio with ninety-five percent confidence interval in brackets. † As indication for repair. ‡ At the time of valve-sparing reoperation after Ross procedure.



**FIGURE I** Kaplan-Meier curve of freedom from reintervention after valve-sparing reoperation (A) entire cohort and (B) cohort split according to operation technique used at the time of the Ross procedure. FR indicates full root technique; IC, inclusion cylinder technique; SC, sub coronary technique.

### Clinical status

At latest follow-up, 80% of patients were in NYHA class I, 12% in class II and 8% in class III. Ninety-five percent of patients were in sinus rhythm, 3% had a permanent pacemaker and 2% were diagnosed with atrial fibrillation. Oral anticoagulation was used by 10% of patients. Several patients experienced cardiac-related complications during follow-up including stroke (8%), heart failure (5%) and myocardial infarction (2%). Following valve-sparing reoperation after the Ross procedure, at least four women had a total of five successful pregnancies.

At latest follow-up, 63 patients were still alive and under active follow-up without having had a reintervention after valve-sparing reoperation. Autograft valve regurgitation was absent in 41% patients, grade I in 43%, grade II in 13% and grade III in 3% of patients.

## Discussion

This multicentre European study provides important information for surgeons on the characteristics and outcome following valve-sparing reoperations after the Ross procedure. It illustrates that the indication for surgery and the presentation of the patient at the time of valve-sparing reoperation varies widely. The majority of patients in our cohort underwent the initial Ross procedure as young adults. Therefore, a substantial proportion of patients presented with a bicuspid aortic valve. Somewhat surprisingly, the indication for the Ross procedure was isolated aortic regurgitation in almost half of the patients. The absence of aortic stenosis as indication in such a large proportion of patients might be explained in part by prior balloon valvotomy or surgical valvuloplasty in these patients. Another part of the explanation may be that patients in whom the indication for the Ross procedure is aortic stenosis have a lower risk of autograft-related complications.

In experienced hands, valve-sparing reoperation after the Ross procedure is safe with acceptable early morbidity and mortality. Low reported early mortality is especially striking considering that in 21% of patients the valve-sparing reoperation was their third or even fourth cardiac surgical procedure. After the valve-sparing reoperation, patients may again enjoy the claimed benefits of their autograft valve and avoid use of oral anticoagulation. This is superbly illustrated by the four women in our cohort who became pregnant after the valve-sparing reoperation. In our cohort, no cardiac-related deaths were observed during follow-up. This finding suggests that valve-sparing reoperations after the Ross procedure conserve the survival advantage observed following the Ross procedure.<sup>7</sup> However, the three cancer-related deaths resulted in a slightly lower estimated survival at 8 years compared to the age-matched general population in The Netherlands (89% versus 98%).<sup>8</sup>

Reintervention after valve-sparing reoperation is not uncommon. Interestingly, the majority of reinterventions were performed within the first two post-operative years. This may explain why the case reports on valve-sparing reoperations after the Ross procedure do not report failure, as follow-up in these reports rarely extends beyond a few months post-operatively.<sup>9,10</sup> It is important to note that the majority of patients who did not require a reintervention were in excellent clinical condition and presented with good autograft valve function at latest follow-up.

We have identified several factors related to characteristics of the patient and initial Ross procedure as well as autograft valve function at the time of the valve-sparing reoperation that are associated with reintervention. These findings may help to guide the decision-making process when a reoperation on the pulmonary autograft is necessary.

Interestingly, the technique used at the initial Ross procedure was associated with outcome following the valve-sparing reoperation after the Ross procedure. When compared to the full root technique, the inclusion cylinder technique was associated with an increased hazard of failure of the valve-sparing reoperation. Although a similar association in the sub coronary group was not statistically significant, this may be attributed to the limited number of patients in this group. We believe that the inclusion cylinder and sub coronary techniques may lead to distortion of the complex geometry of the autograft cusps. Over time, this may lead to cusp prolapse and other degenerative cusp changes in some patients. Not surprisingly, the majority of patients in whom the initial Ross procedure was performed according to the inclusion cylinder or sub coronary technique presented with isolated, and often severe, autograft regurgitation at the time of valve-sparing reoperation. Prolapse and degenerative cusp changes present at the time of valve-sparing reoperation after the Ross procedure may prevent durability of the valve-sparing reoperation. In addition, valve-sparing reoperations may be technically more challenging in patients following a Ross procedure with the inclusion cylinder or sub coronary technique due to scarring and possible reduced compliance of the autograft wall. A substantial proportion of these patients who required a reintervention after the valve-sparing reoperation presented with prolapse and/or retraction of one or more cusps at the time of reintervention. Of note, the two patients in whom cusp calcifications were reported at the time of autograft valve explantation had an inclusion cylinder Ross.

In contrast, use of the full root technique at the initial Ross procedure preserves the complex geometry of the autograft root. Following the full root technique, the predominant mechanism of failure is autograft root dilatation with generally no to only moderate autograft regurgitation. Degenerative cusp changes are expected to be limited. Supporting this theory is our finding that in patients in whom the full root technique was used, autograft root aneurysm was the indication for a valve-sparing autograft root replacement in the majority of patients. Interestingly, the interval between the initial Ross procedure and valve-sparing reoperation was longer when the indication for reoperation was autograft root aneurysm (10.7 years) compared to isolated autograft regurgitation (3.4 years).

Our findings are in accordance with two smaller cohort studies that showed an association between isolated autograft valve pathology and reintervention after valve-sparing reoperation.<sup>4,5</sup> In a case series with seven patients, the authors did not report any reintervention after a mean echocardiographic follow-up of 3.2 years.<sup>11</sup> Their excellent results may be explained in part by the absence of patients with isolated autograft regurgitation. In the literature, results following primary valve-sparing aortic root operations are excellent. De Kerchove *et al.* report a freedom from reoperation after primary valve-sparing aortic root operation at eight years of 90%, while Aicher *et*

*al.* report 96% at ten years.<sup>12,13</sup> These results are comparable to our reported freedom from reintervention of 85% at eight years in the subgroup of patients who received valve-sparing autograft root replacement.

Durable valve-sparing reoperations after the Ross procedure in patients with diseased autograft cusps may not be possible in some patients, especially when isolated autograft regurgitation is present, or may require careful reconsideration of the surgical approach. Several participating centres do not consider patients with leaflet calcifications, fenestrations or retraction suitable candidates for valve-sparing reoperations after the Ross procedure. In this light, some centres advocate the use of intra-operative measurements of the autograft cusps to guide the reoperation. While this approach may prove to be more reliable than eye-balling, no difference in outcome of autograft valve repair was observed in the current study between centres that use intra-operative measurements versus those that do not. In patients in whom a durable repair is unlikely, surgeons may consider the Bentall procedure with implantation of a mechanical or biological prosthesis.

### **Limitations**

The retrospective nature of this study resulted in limitations with respect to data collection as information on several variables was not available for all patients. This underscores the need for a prospective registry to assess (variables associated with) outcome following valve-sparing reoperations after the Ross procedure. This may be achieved in the recently initiated AVIATOR registry, a prospective international registry of patients undergoing surgery for ascending aorta aneurysm and/or isolated aortic regurgitation (<http://heartvalvesociety.org/working-groups.cgi>).

### **Conclusions**

Valve-sparing reoperations after the Ross procedure may be performed with limited early morbidity and mortality in the majority of patients. This approach allows patients the continued benefit of the advantages associated with a functioning autograft valve. However, reintervention after valve-sparing reoperation is a common finding in the first two post-operative years in patients with isolated and/or severe autograft regurgitation and warrants careful consideration of the surgical approach in these patients.

### **Acknowledgements**

We thank Corinne Coulon (Division of Cardiothoracic and Vascular Surgery, Université Catholique de Louvain, Cliniques Universitaires Saint-Luc, Brussels, Belgium) for her help with data collection.

## References

1. Stelzer P. The Ross procedure: state of the art 2011. *Semin Thorac Cardiovasc Surg* 2011;23:115-123.
2. Elkins RC, Lane MM, McCue C. Pulmonary autograft reoperation: incidence and management. *Ann Thorac Surg*. 1996;62:450-455.
3. David TE. Aortic Valve Sparing Operations: A Review. *Korean J Thorac Cardiovasc Surg* 2012;45:205-212.
4. Luciani GB, Lucchese G, De Rita F, Puppini G, Faggian G, Mazzucco A. Reparative surgery of the pulmonary autograft: experience with Ross reoperations. *Eur J Cardiothorac Surg*. 2012;41:1309-1314; discussion 1314-1315.
5. de Kerchove L, Boodhwani M, Etienne PY, Poncelet A, Glineur D, Noirhomme P, et al. Preservation of the pulmonary autograft after failure of the Ross procedure. *Eur J Cardiothorac Surg*. 2010;38:326-332.
6. Charitos EI, Takkenberg JJ, Hanke T, Gorski A, Botha C, Franke U, et al. Reoperations on the pulmonary autograft and pulmonary homograft after the Ross procedure: An update on the German Dutch Ross Registry. *J Thorac Cardiovasc Surg*. 2012;144:813-21; discussion 821-3.
7. El-Hamamsy I, Eryigit Z, Stevens LM, Sarang Z, George R, Clark L, et al. Long-term outcomes after autograft versus homograft aortic root replacement in adults with aortic valve disease: a randomised controlled trial. *Lancet*. 2010;376:524-531.
8. StatLine by Statistics Netherlands: <http://statline.cbs.nl/StatWeb/?LA=en>
9. Watanabe N, Saito S, Saito H, Kurosawa H. Valve-sparing aortic root replacement with repair of leaflet prolapse after Ross operation. *Interact Cardiovasc Thorac Surg*. 2007;6:89-91.
10. Goldstone AB, Woo YJ. Pulmonary autograft leaflet repair and valve sparing root replacement to correct late failure of the ross procedure. *J Card Surg*. 2013;28:496-499.
11. Brinkman WT, Herbert MA, Prince SL, Ryan C, Ryan WH. Redo autograft operations after the Ross procedure. *Ann Thorac Surg*. 2012;93:1477-1481; discussion 1481-1482.
12. de Kerchove L, Boodhwani M, Glineur D, Poncelet A, Verhelst R, Astarci P, et al. Effects of preoperative aortic insufficiency on outcome after aortic valve-sparing surgery. *Circulation*. 2009;120:S120-126.
13. Aicher D, Langer F, Lausberg H, Bierbach B, Schäfers HJ. Aortic root remodeling: ten-year experience with 274 patients. *J Thorac Cardiovasc Surg*. 2007;134:909-915.





# Chapter 5

## **Early Failure of Valve-sparing Autograft Root Replacement after Ross Operation**

**Aart Mookhoek, Jan L Robertus, Jos A Bekkers, Ad J J C Bogers**

*Submitted*

## **Abstract**

The Ross operation offers patients an aortic valve substitute with good hemodynamics and freedom from oral anticoagulation use. In patients requiring reoperation after the Ross operation, valve-sparing autograft root replacement may conserve advantages of the initial Ross operation. This case report describes a 24-year-old patient who underwent elective valve-sparing autograft root replacement according to David ten years after the Ross operation for severe autograft root dilatation with moderate to severe autograft regurgitation. Post-operative echocardiography revealed trivial aortic valve regurgitation. Two years after the reoperation, severe symptomatic autograft regurgitation and progressive reduction in left ventricular function was observed. Surgical inspection demonstrated thickened autograft leaflets with prolapse in two. Histological analysis showed features characteristic of autograft leaflets explanted at reoperation for autograft root dilatation. The prominent aortalis layer, consisting of poorly aligned elastin and collagen fibers, was a novel finding. We believe it may be associated with leaflet prolapse, as either cause or consequence. We advocate collection of pulmonary autograft leaflets explanted upon reintervention after valve-sparing autograft root replacement to help answer why prolapse occurs after valve-sparing reoperations.

## Introduction

The Ross operation offers patients an aortic valve substitute with good hemodynamics and freedom from oral anticoagulation use.<sup>1</sup> However, progressive dilatation of the autograft root, often accompanied by autograft regurgitation, is a major cause for reoperation in the second post-operative decade.<sup>2</sup> In patients requiring reoperation after the Ross operation, valve-sparing autograft root replacement may conserve several advantages of the initial Ross operation. This case report describes a patient requiring early reintervention after valve-sparing reoperation.

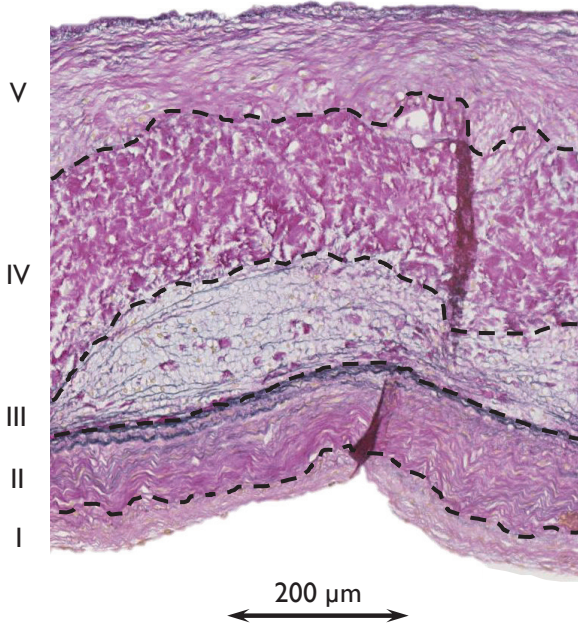
## Case report

The institutional review board of the Erasmus MC approved this study (MEC 2013-219) and the patient gave informed consent.

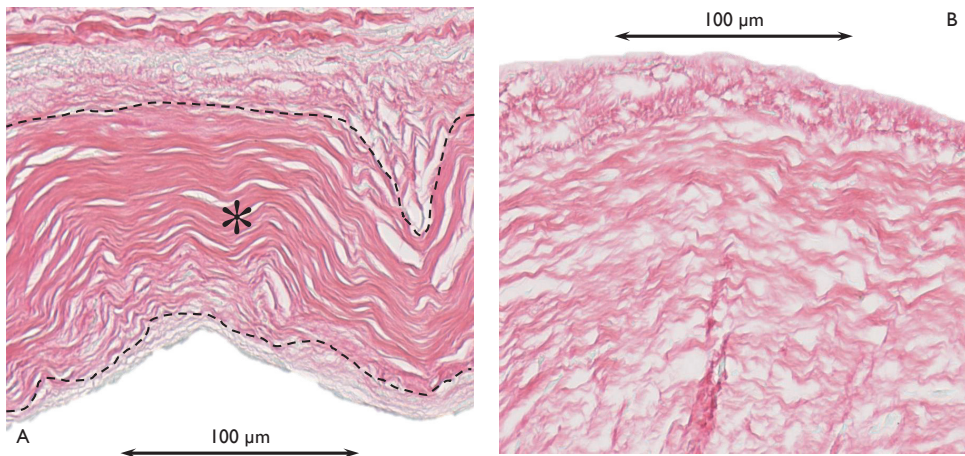
A 24-year-old woman underwent elective reintervention on the pulmonary autograft 12 years after the Ross operation. Indication for the initial Ross operation was progressive, symptomatic aortic stenosis and regurgitation in the presence of a bicuspid aortic valve. The pulmonary autograft was transplanted as a full root without external support. A pulmonary homograft was used to reconstruct the right ventricular outflow tract. Ten years after the Ross operation, with an autograft root diameter in excess of 45 mm, the patient became pregnant. Due to a perceived increased risk of autograft rupture, a primary caesarean section was performed at 35 weeks. No clinical adverse events occurred. The patient returned to the clinic six months later with complaints of progressive fatigue, dizziness and shortness of breath on exertion. Echocardiography revealed a severely dilated autograft root (56 mm) with moderate to severe autograft regurgitation. Surgery was indicated. Upon surgical inspection, the tricuspid autograft valve appeared symmetrical with thin, pliable leaflets. Therefore, a valve-sparing autograft root replacement according to David was performed without autograft valve repair. Post-operative echocardiography revealed trivial aortic valve regurgitation. Two years later, a diagnosis of severe symptomatic autograft regurgitation and progressive reduction in left ventricular function was made. Surgical inspection demonstrated thickened autograft leaflets with prolapse in two. The autograft leaflets were excised and a mechanical valve prosthesis was implanted.

Tissue remodeling has been demonstrated in explanted autograft leaflets obtained from patients with autograft root dilatation.<sup>3</sup> We had the opportunity to study the remodeling response in autograft leaflets two years after normalizing autograft root diameter. One explanted autograft leaflet was preserved in formalin and cut in half along the radial direction (from wall to free edge) to study the central belly region. The specimen was embedded in paraffin, sectioned at 4  $\mu\text{m}$  and stained to visualize collagen and elastin fibers. Leaflet thickness in the central belly region was 647  $\mu\text{m}$ . Five distinct layers of connective tissue could be identified (Figure 1). The cell-rich radialis layer consisted of densely-packed, well-aligned, radially oriented collagen fibers (Figure 2A). The fibrosa, the thickest layer (202  $\mu\text{m}$ ), contained mostly circumferentially oriented collagen fibers. The

prominent aortalis layer (181  $\mu\text{m}$ ) consisted of poorly aligned elastin and collagen fibers (Figure 2B).



**FIGURE 1** Radial cross-section through the central belly region stained with Verhoeff-Van Gieson. I denotes lamina ventricularis; II, radialis; III, spongiosa; IV, fibrosa; V, aortalis.



**FIGURE 2** Visualization of collagen fiber orientation with Sirius red staining in the lamina radialis (panel A) and aortalis (panel B). \* denotes the lamina radialis in panel A.

## Discussion

In this case report, we offer the detailed history of a patient in whom valve-sparing autograft root replacement required reintervention after only two years. While the patient history offers interesting insights, several studies have previously reported on reinterventions following valve-reoperation after the Ross operation.<sup>2,4</sup> This report offers valuable new information and raises important questions about the remodeling response of pulmonary autograft leaflets.

Although the autograft leaflets were thin and pliable at the valve-sparing reoperation, they were shown to be thickened only two years later at the time of the reintervention. Our histological analysis showed a preserved five-layer architecture typical of semilunar valves.<sup>5</sup> However, thickness and composition of the five layers did not resemble native pulmonary or aortic leaflets. High cellularity and collagen fiber deposition in the radialis layer were similar to the characteristic changes reported in autograft leaflets explanted at reoperation for autograft root dilatation.<sup>3</sup>

A novel finding is the presence of a prominent aortalis layer. This layer, not often described in literature, is present as a thin layer of fine elastic fibers in native pulmonary and aortic leaflets as well as in explanted autograft leaflets. We believe that macroscopic thickening of the leaflets presented in this case report is due to a substantial increase in aortalis layer thickness. We do not think this is active remodeling towards a native aortic phenotype. Given the orientation of collagen and elastin fibers, it is more likely to be associated with leaflet prolapse, as either cause or consequence.

## Conclusions

In this case report, we have presented the histological features of a prolapsed pulmonary autograft leaflet explanted two years after valve-sparing autograft root replacement. We advocate collection of pulmonary autograft leaflets explanted upon reintervention after valve-sparing autograft root replacement. Detailed histological analysis of these leaflets may help to answer why prolapse occurs after valve-sparing reoperations.

## References

1. Stelzer P. The Ross procedure: state of the art 2011. *Semin Thorac Cardiovasc Surg* 2011;23:115-23.
2. Luciani GB, Lucchese G, De Rita F, Puppini G, Faggian G, Mazzucco A. Reparative surgery of the pulmonary autograft: experience with Ross reoperations. *Eur J Cardiothorac Surg*. 2012;41:1309-14; discussion 1314-5.
3. Mookhoek A, de Heer E, Bogers AJ, Takkenberg JJ, Schoof PH. Pulmonary autograft valve explants show typical degeneration. *J Thorac Cardiovasc Surg*. 2010;139:1416-9.
4. de Kerchove L, Boodhwani M, Etienne PY, Poncelet A, Glineur D, Noirhomme P, et al. Preservation of the pulmonary autograft after failure of the Ross procedure. *Eur J Cardiothorac Surg*. 2010;38:326-32.
5. Misfeld M, Sievers HH. Heart valve macro- and microstructure. *Philos Trans R Soc Lond B Biol Sci*. 2007;362:1421-36.

# Chapter 6

## **Pulmonary Autograft Valve Explants Show Typical Degeneration**

**Aart Mookhoek, Emile de Heer, Ad J J C Bogers, Johanna J M Takkenberg, Paul H Schoof**

*J Thorac Cardiovasc Surg. 2010;139:1416-1419.*

## **Abstract**

### **Objectives**

To evaluate the microscopic characteristics of pulmonary autograft valve explants.

### **Methods**

Cell density and thickness of the autograft valve ventricularis were determined and compared with those of normal aortic and pulmonary valves (n=11). Cellular phenotype and extracellular matrix involvement were assessed with immunohistochemistry. Collagen three-dimensional architecture was studied by means of confocal microscopy.

### **Results**

The autograft valve exhibited characteristic thickening of the ventricularis as compared to the normal aortic and normal pulmonary valve (137 versus 77 (P= .058) versus 37  $\mu\text{m}$  (P= .002)). Its cell number was increased compared to the normal aortic and normal pulmonary valve (396 versus 230 (P= .02) versus 303 (P= .083)). Myofibroblasts and stressed endothelial cells, both present in pulmonary autografts, were absent in control valves. The exclusive presence of MMPI was an additional sign of extracellular matrix turn-over. Apoptosis, elastinolysis, cell proliferation, or senescence were not expressed. Dense fibrosis of the autograft ventricularis, with relatively well aligned collagen fibers was observed with confocal microscopy.

### **Conclusions**

Fibrous hyperplasia of the ventricularis and cellular and extracellular matrix characteristics of active remodelling were a consistent finding in pulmonary autograft valve explants. The observations suggest a primary valve related cause to be involved in pulmonary autograft valve failure.



## Introduction

Pulmonary autograft valve regurgitation and root dilatation have emerged as important complications of the Ross operation at short and midterm follow up (1-3). Valve regurgitation has generally been assumed to be secondary to root dilatation, although a primary valve related cause has never been excluded. In our previous study, fibrotic thickening of the autograft ventricularis was identified as a common feature (4). Now, we systematically studied eleven explanted autografts and eleven control valves to assess and quantify the histopathological characteristics to support any clinico-pathologic correlates.

## Methods

Pulmonary autografts (n=11) were obtained from adults reoperated for pulmonary autograft failure between 2003 and 2007 in the University Medical Centres of Rotterdam and Leiden (Table 1). Age matched heart valves (n=11) (aortic 5, pulmonary 6), obtained from the Heart Valve Bank of the Erasmus MC Rotterdam, served as controls.

TABLE 1 Clinical data of Ross patients and controls

	Autograft (n=11)	Control (n=11)
Age at operation (yrs)	24.4 (10.5 - 39.2)	NA
Age at explantation (yrs)	35.8 (23.6 - 47.8)	31.9 (19.7 - 49.7)
Interval (yrs)	11.2 (7.3 - 15.4)	NA
Male	9	7
Female	2	3
Bicuspid native valves	7	0
<i>Indication for reoperation</i>		
Aortic dilatation/aneurysm	11	NA
Aortic regurgitation	10	NA

NA = not applicable.

## Sample staining

Radial valve sections (4 µm) were cut from paraffin embedded leaflets and mounted on slides. Von Gieson staining was used to visualize elastin and collagen fibers and alcian blue staining to visualize glycosaminoglycans and nuclei. Sections were photographed using a Zeiss microscope (Zeiss, Oberkochen, Germany) with a Sony DXC 950p full-colour 3CCD camera (Sony Corp., Tokyo, Japan) and captured with KS-400 image analysis software version 3.0 (Zeiss, Oberkochen, Germany). Von Gieson stained sections were analysed using ImageJ version 1.37V to determine the thickness of the ventricularis and

total valve thickness. The mean number of nuclei was calculated in alcian blue stained sections by counting four different sample fields.

Immunohistochemical analysis using 13 different markers was performed to compare autograft valves (n=11) with control valves (n=11) (Table 2). In general, sections were deparaffinised, followed by antigen retrieval by boiling in 0.1 M citrate buffer, pH 6.0, blocked for endogenous peroxidases and incubated for one hour with the primary antibody. Next, sections were washed and incubated with an Envision horseradish-peroxidase conjugated secondary antibody (DAKO, Glostrup, Denmark). Subsequently, all slides were incubated with diaminobenzidine and analysed with KS-400 image analysis software to quantify staining percentage of the ventricularis.

**TABLE 2** Antibodies used in immunohistochemical analysis

Markers	Cellular aspects	Antigen retrieval	Primary antibody	Secondary antibody	Company
$\alpha$ -SMA	Myofibroblasts	-	1:400	Mouse	Sigma
Active caspase 3 *	Apoptosis	+	1:200	Rabbit	Cell signalling
Cathepsin K	Elastinolysis	+	1:1000	Rabbit	TNO
Cathepsin S	Elastinolysis	+	1:1000	Rabbit	TNO
CD31*	Endothelium	+	1:400	Mouse	DAKO
CD45	Inflammatory infiltrate	+	1:100	Mouse	DAKO
Desmin	Myofibroblasts	-	1:20	Mouse	LUMC
IL-6	Differentiation	+	1:500	Goat ‡	Biogenesis
Ki67	Proliferation	+	1:200	Mouse	DAKO
MMP1	Collagen breakdown	-	1:1000	Mouse	Chemicon
MMP9	Collagen breakdown	+	1:250	Rabbit	TNO
p <sup>16</sup> <sup>INK4a</sup> †	Senescence	+	1:800	Mouse	Neomarkers
TGF- $\beta$	Differentiation	+	1:500	Rabbit	LUMC

\* diaminobenzidine enhancement by incubation with  $\text{Cu}_2\text{SO}_4$  for 5 min, † antigen retrieval using Tris/EDTA, ‡ rabbit a goat + SABC.

## Confocal microscopy

Three-dimensional images were made from 20  $\mu\text{m}$  thick, paraffin embedded, Sirius red stained leaflets with an LSM510 confocal microscope with a C-Apochromat® 40x/1.2W Corr water immersion objective (Zeiss, Oberkochen, Germany).

## Statistical methods

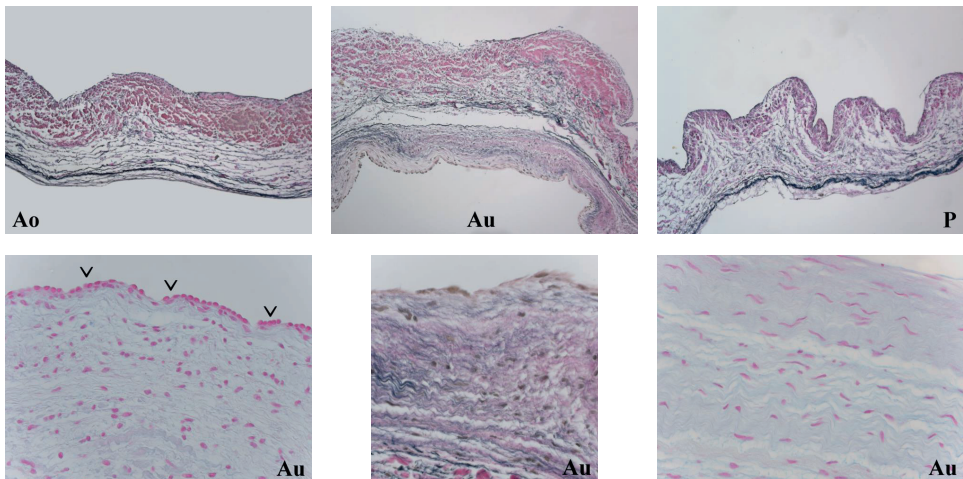
Continuous data, such as those obtained from histochemical analyses, were compared using the unpaired T-test. Discrete data, such as those obtained from the immunohistochemical analysis of desmin and  $\alpha$ -SMA, were analysed using the Fisher's exact test. All comparative

analyses were performed using SPSS 12.0.1 Windows (SPSS, Chicago, USA). P values < .05 were considered significant.

## Results

### Histochemical analysis

Autograft valves differed greatly from normal aortic and pulmonary valves (Figure 1) in their mean total thickness (372  $\mu\text{m}$  versus 474  $\mu\text{m}$  (normal aortic) and 292  $\mu\text{m}$  (normal pulmonary),  $P > .2$  and  $P = .067$  respectively). Thickness of the ventricularis of autograft valve (137  $\mu\text{m}$ ) was significantly more than normal than normal aortic (77  $\mu\text{m}$ ) or pulmonary valve (37  $\mu\text{m}$ ),  $P = .058$  and  $P = .002$  respectively. It comprised 36% of total autograft thickness, compared to normal aortic (17%) and pulmonary (12%) valve,  $P = .02$  and  $P < .001$  respectively. Number of cells per square mm in the ventricularis was 396 in autografts compared to normal aortic (230) and pulmonary (303) valves,  $P = .02$  and  $P = .083$  respectively. Matrix cell morphology was spindle shaped and cells lining the ventricularis surface appeared large and cubical.



**FIGURE 1** Morphological analysis shows a thickened autograft (Au) ventricularis compared to normal aortic (Ao) and pulmonary (P) valves (upper mid panel, original magnification  $\times 135$ ). Detailed photos of the autograft valves show cubical endothelium (lower left, V), collagen-rich extracellular matrix (lower mid) and high density of spindle shaped cells (lower right) (original magnification  $\times 540$ ).

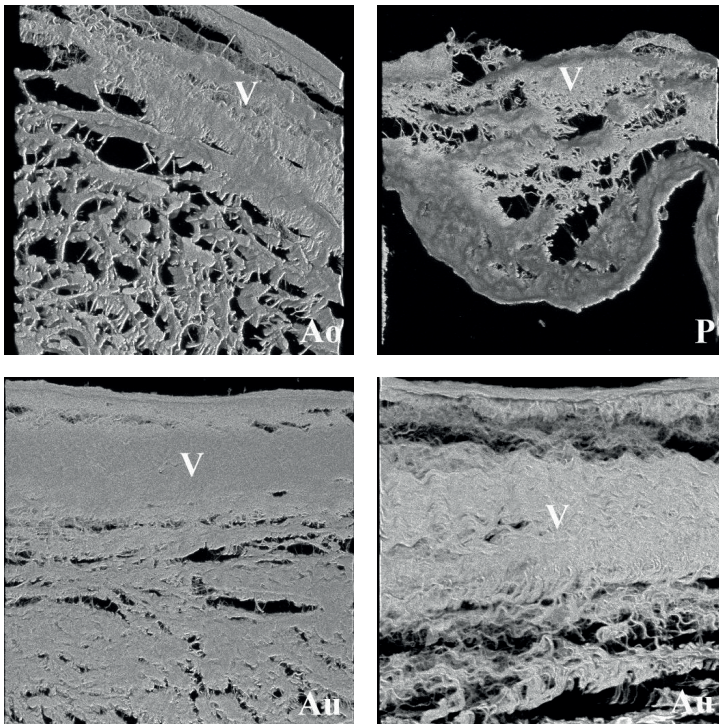
### Immunohistochemical analysis

The autograft ventricularis was lined by endothelial cells, as identified by CD31 staining. Autograft valves showed  $\alpha$ -SMA-positive cells and desmin-positive cells in 91% and 36%

of samples respectively, compared to 36% and 0% respectively in control samples,  $P = .024$  and  $P = .035$  respectively. The expression of these markers indicates a myofibroblast-like phenotype of the cells present in the extracellular matrix of the autograft ventricularis. In contrast to controls, the autograft ventricularis stained positive for IL-6, MMP1 and TGF- $\beta$ . A very low number of inflammatory cells were present in the ventricularis of both autograft and control samples, as identified by CD45 staining. Apoptosis, matrix degradation, cell proliferation or senescence markers were not expressed.

### Confocal microscopy

Collagen fiber density was more pronounced in the ventricularis of autograft valves compared to normal aortic and pulmonary valves (Figure 2). Moreover, these fibers showed a high degree of geometric organisation. Fiber alignment was typically in the radial direction (i.e. from wall to rim).



**FIGURE 2** Confocal images of valvular collagen structures show an increase in collagen density in pulmonary autograft valves (lower left) compared to normal aortic and pulmonary valves (upper panels) (original magnification  $\times 800$ ). Distinct radial orientation of the collagen fibers is shown at high magnification (lower right, original magnification  $\times 1600$ ) (V = ventricularis).

## Discussion

Pulmonary autograft valve explants consistently showed a thickened ventricularis. Its presence along the entire cusp as well as focal expression of fibroblast activator TGF-beta and IL-6, suggest this thickening is the result of a local adaptive response rather than fibrous overgrowth (pannus) as suggested by Rabkin-Aikawa *et al.* who observed similar thickening of the pulmonary autograft valve (5). In addition, we found that collagen fibres were abundant in this area and particularly well aligned, which may implicate that the architectural changes are a result of adaptive remodelling secondary to increased mechanical stress. Interestingly, the remodelling tissue marker MMP1 as well as the presence of numerous myofibroblasts were found in explants that functioned over 10 years in the systemic circulation. It suggests that the adaptation process in the explanted valves did not reach homeostasis. Such an ongoing process of remodelling may eventually be exhausted and lead to degeneration. Interestingly, we found the same changes in an explant from a patient who died of a non-valve related cause (not included in this study) (4) and comparable changes were found in pulmonary autografts of hearts from patients who needed a transplantation following the Ross operation (5). This suggests a common mode of adaptation that may occur to some extent in all autograft valves and therefore the relation with clinical valve failure is uncertain. However, speculating on a cause of valve failure, the presence of a thick fibrous layer is likely to negatively influence the delicate microdynamics of the valve, in particular its radial extensibility. Obviously, biaxial stress testing should be performed to substantiate this. We believe that the observed remodelled ventricularis is the result of beneficial adaptation, but may eventually play a role in failure of the pulmonary autograft valve.

## Conclusion

Fibrous hyperplasia of the ventricularis is a consistent finding in pulmonary autograft valve explants. Its cellular and extracellular matrix characteristics at explantation suggest it to be the result of sustained remodeling. The architectural changes may cause failure of the pulmonary autograft valve in the long term.

## Limitations

The valves used in this study were all acquired from failing autografts. This impedes the extrapolation of our results to autograft valves in general. To enable such an extrapolation, valves from failing autografts should ideally have been compared with valves from non failing autografts.

### **Future perspectives**

It would be useful to perform a similar study with explanted valves from patients who underwent a classic Ross operation using the subcoronary implantation technique or from roots supported with Dacron. Since these autografts are unaffected by progressive root dilatation, the valve's intrinsic tendency for failure can be more accurately studied. Detailed characterization of the collagen fibers in the ventricularis could provide additional information on the structure and quality of collagen.

## References

- 1 Luciani GB, Mazzucco A. Aortic root disease after the Ross procedure. *Curr Opin Cardiol* 2006; 21(6):555-560.
- 2 Klieverik LM, Takkenberg JJ, Bekkers JA, Roos-Hesselink JW, Witsenburg M, Bogers AJ. The Ross operation: a Trojan horse? *Eur Heart J* 2007.
- 3 Pasquali SK, Shera D, Wernovsky G, Cohen MS, Tabbutt S, Nicolson S et al. Midterm outcomes and predictors of reintervention after the Ross procedure in infants, children, and young adults. *J Thorac Cardiovasc Surg* 2007; 133(4):893-899.
- 4 Schoof PH, Takkenberg JJ, van Suylen RJ, Zondervan PE, Hazekamp MG, Dion RA et al. Degeneration of the pulmonary autograft: an explant study. *J Thorac Cardiovasc Surg* 2006; 132(6):1426-1432.
- 5 Rabkin-Aikawa E, Aikawa M, Farber M, Kratz JR, Garcia-Cardena G, Kouchoukos NT et al. Clinical pulmonary autograft valves: pathologic evidence of adaptive remodeling in the aortic site. *J Thorac Cardiovasc Surg* 2004; 128(4):552-561.





# Chapter 7

## **Biomechanics of Failed Pulmonary Autografts Compared to Normal Pulmonary Roots**

**Aart Mookhoek, Kapil Krishnan, Sam Chitsaz, Heide Kuang, Liang Ge,  
Paul H Schoof, Ad J J C Bogers, Johanna J M Takkenberg, Elaine E Tseng**

*Accepted (Ann Thorac Surg)*

## **Abstract**

### **Background**

Progressive dilatation of pulmonary autografts after the Ross operation may reflect inadequate remodeling of the native pulmonary root to adapt to systemic circulation. Understanding the biomechanics of autograft root dilatation may aid designing strategies to prevent dilatation. We have previously characterized normal human pulmonary root material properties; however, mechanical properties of failed autografts are unknown. In this study, failed autograft roots explanted during reoperation were acquired and their material properties determined.

### **Methods**

Failed pulmonary autograft specimens were obtained from patients undergoing reoperation after the Ross operation. Fresh human native pulmonary roots were obtained from the transplant donor network as controls. Biaxial stretch testing was performed to determine tissue mechanical properties. Tissue stiffness was determined at patient-specific physiologic stresses at pulmonary pressures.

### **Results**

Non-linear stress-strain response was present in both failed autografts and normal pulmonary roots. Explanted pulmonary autografts were less stiff than their native pulmonary root counterparts at 8mmHg ( $134\pm 42$  vs.  $175\pm 49$ kPa, respectively,  $p=0.086$ ) and 25mmHg ( $369\pm 105$  vs.  $919\pm 353$ kPa, respectively,  $p=0.006$ ). Autograft wall stiffness at both 8 and 25mmHg was not correlated with age at the Ross operation ( $p=0.898$  and  $p=0.813$ , respectively) or time in the systemic circulation ( $p=0.609$  and  $p=0.702$ , respectively).

### **Conclusions**

Failed pulmonary autografts retained non-linear response to mechanical loading typical of healthy human arterial tissue. Remodeling increased wall thickness but decreased wall stiffness in failed autografts. Increased compliance may explain progressive autograft root dilatation in autograft failures.

## Introduction

The Ross operation offers several advantages compared to other aortic valve replacement strategies(1). Excellent hemodynamics and freedom from oral anticoagulation led to adoption of Ross operation for young adults(2-5). Patients after Ross operation have a demonstrated life expectancy similar to the general population(1, 6, 7). However, enthusiasm among cardiologists and surgeons to apply this operation more widely in adults has been limited, due to technical complexity of the operation and autograft reoperation risk beyond the first decade(8-13). Late autograft dysfunction in the root replacement technique is primarily caused by progressive root dilatation, which may lead to aneurysm formation and valvular regurgitation, while autograft failure in the subcoronary technique is often due to leaflet dysfunction(9-15).

Progressive autograft dilatation likely reflects the inability of the native pulmonary root to adapt to demands of the systemic circulation. Histological analyses have offered insights into the remodeling response in failed explanted autografts(16-18). Loss and fragmentation of medial elastin fibers and increased adventitial collagen fiber deposition have been demonstrated(18). We hypothesized that these extracellular matrix changes were reflected as marked changes in tissue material properties. Study of the mechanical properties of failed autografts provides understanding of the autograft dilatation process as the biomechanical remodeling response upon exposure to systemic pressure. The goal of this study was to determine the material properties of failed explanted autograft roots compared to healthy native pulmonary roots.

## Materials and Methods

This study was approved by Institutional Review Boards of Erasmus University Medical Center and San Francisco Veterans Affairs Medical Center and exempted by Committee of Human Research at University of California San Francisco Medical Center.

### Sample Collection

Patients who required reoperation after Ross operation for aneurysm formation and autograft valvular regurgitation were recruited from Erasmus University Medical Center (Table 1). They consented to tissue collection of pulmonary autograft specimens. The original operation was performed using Ross full root replacement technique, leaving minimal amount of tissue distal to sinotubular junction (STJ) and without applying external support. Tissue specimens were excised proximal to the distal suture line, corresponding to STJ area. Specimens were frozen and stored at  $-80^{\circ}\text{C}$ . To compare autograft to native pulmonary roots, fresh human specimens were obtained from California Transplant Donor Network (CTDN, Oakland, CA, USA) unused donor hearts. CTDN specimens were taken

from subjects who consented for research and died of non-cardiac causes. Furthermore, CTDN patients chosen were as closely age-matched to the Ross explant patients as was feasible based on availability. Tissue samples were obtained from two regions: sinuses and 1 cm distal to STJ. Care was taken to preserve tissue alignment in circumferential and longitudinal directions. Mechanical testing for CTDN specimens was completed within 24 hours of cross-clamping; autograft specimens were thawed prior to stretching.

**TABLE 1** Characteristics of Study Population

	Ross patients	Control subjects
Total subjects	10	7
Gender	Male	3
	Female	4
Aortic valve	Bicuspid	0
	Tricuspid	7
Wall thickness (zero pressure)	2.2±0.2mm	1.4±0.2mm <sup>a</sup>
Diameter (zero pressure)	26.7±1.9mm	22.3±3.5mm <sup>b</sup>
Diameter (systemic pressure)	45.8±4.0mm	-
Diameter pulmonary artery at Ross operation (n=2)	25.0±0.0mm	-
Diameter aorta at Ross operation (n=8)	27.6±6.2mm	-
Age at Ross operation	26.7±11.1	
Age at explantation	39.7±10.9	50.9±11.3 <sup>c</sup>
Time in systemic circulation	13.0±2.1	-

<sup>a</sup>p=0.001, <sup>b</sup>p=0.055, <sup>c</sup>p=0.058

### Equibiaxial stretch testing

A custom-built planar biaxial stretching system was used to determine material properties. Details of biaxial tensile testing methods and analyses have been described previously(19). Specimen wall thickness was measured using digital caliper (model 500-754-10; Mitutoyo America Corporation, Aurora, IL, USA) by lightly sandwiching tissue between two glass slides. Three 5-0 silk sutures were anchored to each specimen edge using small, barbless fishhooks. These sutures were attached to four stretcher arms, aligning circumferential and longitudinal edges with the direction of deformation. Five black ceramic markers (250–355 μm; MO-SCI Corporation, Rolla, MO, USA) were placed on tissue surface, creating a grid in the specimen center. Specimen was floated in a water bath with Dulbecco's phosphate buffered saline without calcium and magnesium. Load cells (model 31/3672–02, 1000 g; Honeywell Sensotec Inc., Columbus, OH, USA) located on two orthogonal arms were zeroed. During extension, load cell data was amplified to determine force on specimen during deformation. Real-time displacement of marker beads was obtained using CCD camera placed over tissue surface (model TM 9701; 30fps, 0.1 pixels/mm; Pulnix

Inc., Sunnyvale, CA, USA). Images of tissue surface during deformation were digitized in MATLAB (version 7.0; MathWorks, Natick, MA, USA), and markers were identified based on their contrast to surrounding tissue. Coordinates of each marker were tracked through loading cycle, and their relative movement was used to calculate strains in the principal directions. Specimens were tested over a large strain range using equibiaxial displacement-controlled protocols. First, 10 preconditioning cycles of 10% stretch, using a triangular waveform at 0.5 Hz, were applied. Subsequently, each specimen was repeatedly cycled up to 55% peak strain.

### Constitutive Modeling

Explanted autograft and pulmonary roots were assumed to be incompressible and nonlinear hyperelastic materials. Stress was defined as measure of the average force acting per unit area of a surface within a deformable body in the deformed configuration. Planar forces ( $f$ ) measured by load cells during deformation were converted to Cauchy stresses ( $T$ ) in the principal directions, given by

$$T = \frac{f}{t l_L} \quad (1a)$$

$$T_{LL} = \frac{f_L}{t l} \quad (1b)$$

where  $t$  is tissue thickness and  $l = \frac{l}{l_0}$  represents the ratio of deformed length ( $l$ ) to resting tissue length after preconditioning ( $l_0$ ). Indices  $\theta$  and  $L$  represent circumferential and longitudinal directions, respectively. Components of Green strain ( $E$ ) were calculated using the following equations

$$E = \frac{1}{2} (l^2 - 1) \quad (2a)$$

$$E_{LL} = \frac{1}{2} (l_L^2 - 1) \quad (2b)$$

The material's response to stress can be described mathematically by a set of constitutive equations, derived from scalar strain energy function  $W$ . Mechanical data from the five regions were fit to two dimensional Fung strain energy function, given by

$$W = \frac{c}{2} (e^Q - 1) \quad (3)$$

$$Q = c (E^2 + 2c_L E_{LL} + c_{LL} E_{LL}^2)$$

Where  $c$  and  $c_q, c_{qL}, c_{LL}$  are coefficients to the Fung model. A nonlinear regression Levenberg-Marquardt least-squares algorithm in MATLAB (v7.0.1, Natick, MA) was used to fit experimentally obtained stresses to corresponding theoretically calculated stresses for explanted autograft and pulmonary roots. Cauchy stresses based on the model were given by

$$\begin{aligned} T &= {}^2 c e^{\varrho} (c E + c_L E_{LL}) \\ T_{LL} &= {}^2_L c e^{\varrho} (c_L E + c_{LL} E_{LL}) \end{aligned} \quad (4)$$

## Data analysis

Stiffness was defined as slope of the stress-strain curve at a given point. To investigate stiffness under physiologic conditions, stiffness was calculated at patient-specific physiologic stresses at pulmonary diastolic and systolic pressures (8 and 25 mmHg, respectively). For normal pulmonary roots, patient-specific physiologic stresses were determined from finite element (FE) modeling with LS-DYNA (Livermore Software Technology Corporation, Livermore, CA, USA), using a cylindrical model with tissue material properties from biaxial stretching, diameter and wall thickness at 0mmHg (unloaded diameter and wall thickness, respectively)(20). Simulations were run from 0mmHg to pulmonary pressures to determine patient-specific physiologic stresses. For explanted autografts, unloaded wall thickness but not diameter was known. Autograft diameter was measured pre-operatively using TTE at systemic pressure. FE simulations were run from 0mmHg to systemic pressure using unloaded wall thickness, autograft material properties from biaxial stretching, and iterative estimations of unloaded diameter until autograft diameter at systemic pressure matched measured diameter by TTE. After determining unloaded autograft diameter, FE simulations were run from 0mmHg to pulmonary pressures to determine patient-specific physiologic stresses.

Tissue stiffness for each normal pulmonary and explanted autograft root was then obtained at their respective physiologic stress based on slope of their respective stress-strain curves obtained from biaxial stretching. Occasionally, for a specific Ross patient, FE models could not determine physiologic stress when simulation results would not converge; in that situation, stiffness was calculated based on average physiologic stress for explanted autografts at pulmonary pressures. When tissue specimens were not stretched to desired stress level, stiffness was calculated from extrapolated curves based on Fung strain energy function fitted to raw data.

For statistical analysis, normal distribution of data was assessed using Shapiro-Wilk test. Differences between patients and control subjects in age at explantation, wall thickness, and stiffness were analyzed by independent-samples *t*-tests. Paired sample *t*-tests were used for additional stiffness analyses. Pearson's correlation coefficient was used to study autograft

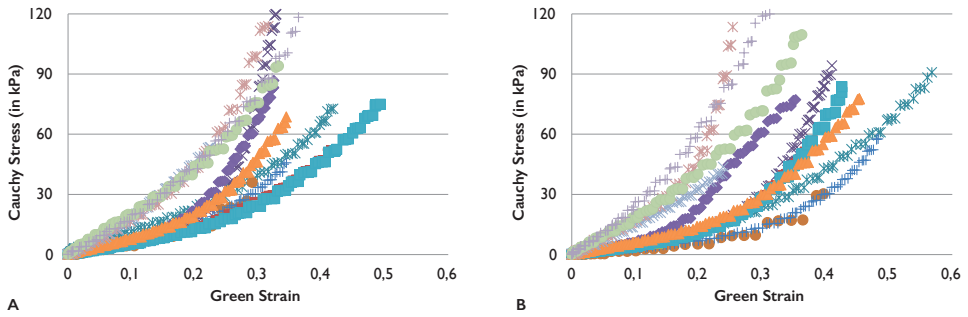
stiffness with respect to age at Ross operation and time in systemic circulation. Reported values are quoted as mean±standard deviation. Statistical analyses were performed using IBM SPSS (version 21.0; IBM, Somers, NY, USA).

## Results

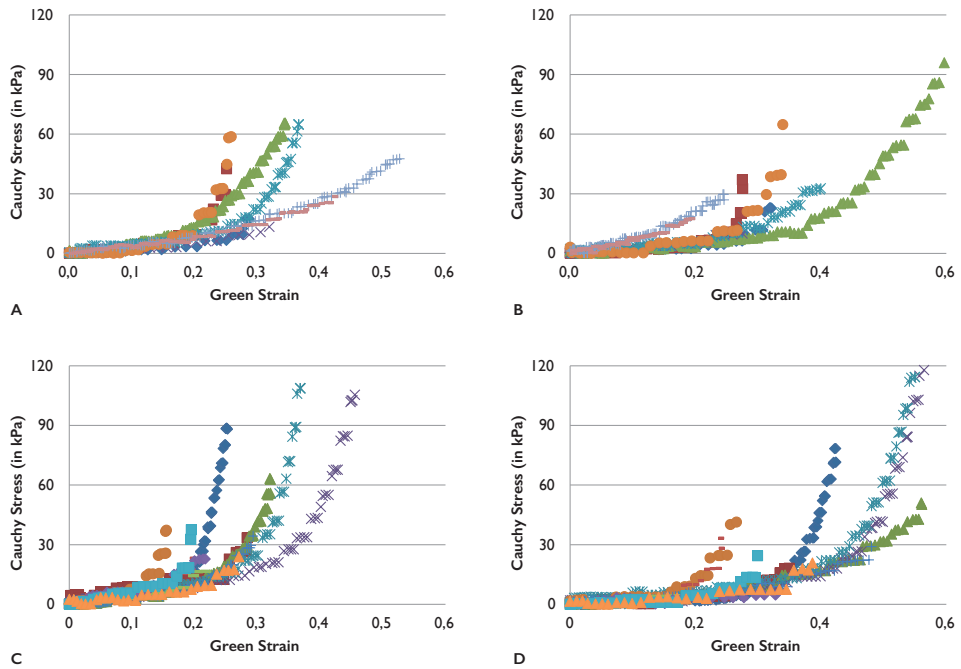
Patient demographics of explanted autografts and native pulmonary roots are shown (Table 1). None of the patients undergoing the Ross operation were noted to have preoperative pulmonary arterial hypertension. Average preoperative pulmonary artery systolic and diastolic pressures are  $21.8\pm 6.2$  and  $12.0\pm 4.2$  mmHg, respectively ( $n=4$ ). Notably, explanted autografts were significantly thicker than pulmonary roots. Average autograft time in the systemic circulation was 13 years. Raw stress-strain data obtained from equibiaxial stretch testing of autograft and native pulmonary roots is displayed as Cauchy stress–Green strain plots (Figures 1-2, respectively).

Non-linear stress-strain response was evident for both root types in both circumferential and longitudinal directions. FE analyses determined pressurized wall thickness, root diameter, and patient-specific physiologic stress at 8 and 25 mmHg (Table 2).

Stiffness (elastic moduli) was greater at systolic than diastolic pulmonary pressures for both explanted autografts and native pulmonary roots in both circumferential ( $p<0.001$ ) and longitudinal ( $p<0.001$ ) directions (Figure 3). Strikingly, explanted autografts were significantly less stiff than their native pulmonary root controls in both circumferential and longitudinal directions at 8 mmHg ( $p=0.086$  and  $p=0.043$ , respectively) and 25 mmHg ( $p=0.006$  and  $p=0.005$ , respectively). Wall stiffness in explanted autografts obtained from patients with bicuspid aortic valve (BAV) appeared greater compared to patients with tricuspid aortic valve (TAV) at 8 mmHg ( $145\pm 40$  vs  $91\pm 3$  kPa) and at 25 mmHg ( $397\pm 97$  vs.  $258\pm 49$  kPa). Anisotropy, directional dependence of material properties, exists when material properties differ in the circumferential vs longitudinal direction. In native pulmonary roots, anisotropy was present at 25 mmHg ( $p=0.016$ ), but not at 8 mmHg ( $p=0.188$ ). Anisotropy for native pulmonary roots showed greater stiffness in the longitudinal than circumferential direction. Explanted autografts displayed no differences in stiffness in the circumferential and longitudinal directions (isotropic responses to mechanical loading) at both 8 and 25 mmHg ( $p=0.400$  and  $p=0.924$ , respectively). Explanted autograft stiffness at both 8 and 25 mmHg was not correlated with patient age at the time of Ross operation ( $p=0.898$  and  $p=0.813$ , respectively) nor time in the systemic circulation ( $p=0.609$  and  $p=0.702$ , respectively).



**FIGURE 1** Stress-strain curves for explanted pulmonary autografts in circumferential (A) and longitudinal directions (B).



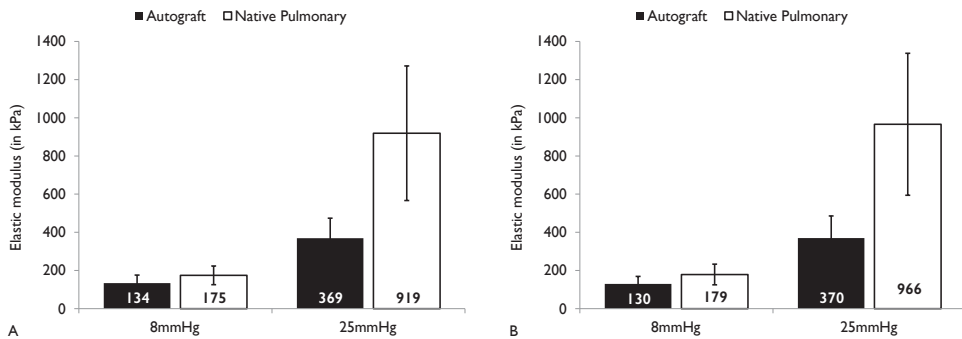
**FIGURE 2** Stress-strain curves for native pulmonary arteries (A, B) and pulmonary sinuses (C, D) in circumferential (A, C) and longitudinal directions (B, D).



**TABLE 2** Wall Thickness, Root Diameter, and Patient-Specific Physiologic Stress from FE Models

	8mmHg			25mmHg		
	Thickness (mm)	Diameter (mm)	Stress (kPa)	Thickness (mm)	Diameter (mm)	Stress (kPa)
Autograft	1.7±0.2	31.6±2.6	10.4±1.6	1.5±0.2	38.0±3.4	45.4±7.8
Pulmonary artery	1.0±0.2 <sup>a</sup>	26.9±1.1 <sup>c</sup>	15.4±3.9 <sup>e</sup>	0.9±0.1 <sup>b</sup>	32.2±1.8 <sup>d</sup>	73.7±9.9 <sup>f</sup>

Statistical analysis of differences between pulmonary autograft and native pulmonary root: wall thickness <sup>a</sup>p=0.002, <sup>b</sup>p=0.001; diameter <sup>c</sup>p=0.027, <sup>d</sup>p=0.035; physiologic stress <sup>e</sup>p=0.039, <sup>f</sup>p=0.004.

**FIGURE 3** Stiffness of explanted pulmonary autograft and native pulmonary roots at 8 and 25mmHg in circumferential (A) and longitudinal (B) directions.

## Comment

The collection of explanted autograft tissue at Erasmus University Medical Center permitted a unique and unprecedented opportunity to study the material properties of a series of failed pulmonary autografts. Our study provides interesting evidence of biomechanical remodeling in autografts which have been exposed to the systemic circulation for more than a decade. Wall stiffness was significantly less in explanted autografts compared to native pulmonary roots. This remodeling may explain why autografts that do not dilate immediately after the Ross operation, can fail by autograft dilatation a decade later. This finding is corroborated by operative descriptions of the autograft wall as delicate and pliable by surgeons during explantation.

## Histopathology

Arterial tissues are complex laminar structures in which responses to mechanical loading are principally determined by elastin fibers, collagens bundles and interstitial smooth muscle cells(21, 22). Although previous histological characterization of both failed and non-failing pulmonary autografts demonstrated viable interstitial and endothelial cells,

Schoof *et al.* also described marked fragmentation and loss of elastin fibers as well as adventitial fibrosis(17, 18). In this study, we provided evidence that these histological findings reflect a marked difference in material properties between explanted autografts and native pulmonary roots. At the relatively low stress levels of pulmonic circulation, arterial load-bearing is elastin-dominated. Loss and fragmentation of elastin fibers and increased collagen content due to adventitial fibrosis in explanted autografts might suggest increased wall stiffness. However, impaired collagen biosynthesis and post-translational modification may have greater effect on aneurysm formation than collagen quantity as previously shown in the aorta of patients with a bicuspid aortic valves(23).

### ***Pulmonary Biomechanics***

Our findings reflect the intrinsic material properties of autograft and native pulmonary artery tissues. Intrinsic values of wall stiffness were calculated independent of vessel wall thickness, diameter and geometry. This approach allows the direct study of biomechanical remodeling at the tissue level. While this approach provides interesting information on the remodeling response after the Ross operation, it does not directly reflect the *in vivo* mechanical behavior of the whole vessel. If a decrease in intrinsic wall stiffness would have been the only result of biomechanical remodeling after the Ross operation, we would see increased compliance *in vivo*. However, we have observed a complex interplay between the intrinsic material properties, vessel wall thickness, diameter and geometry.

Limited data is available on human autograft material properties. Carr-White *et al.*, reported increased autograft stiffness in one 14-year old patient whose autograft was explanted four months after initial Ross operation(24). The single sample, younger patient age, earlier time to explantation, and different biomechanical testing methods, makes direct comparison with our findings not possible. Increased stiffness could reflect time differences in mechanical remodeling, early vs late, or mechanical differences based on patient age, pathology, etc.

Lammers described pulmonary mechanics and vascular stiffness in pulmonary arterial hypertension (PAH) compared to native pulmonary artery(21, 25). In PAH, pulmonary vascular stiffness increases due to 1) vascular remodeling with changes in thickness, composition, and alignment of the extracellular matrix, primarily elastin and collagen, 2) vascular dilation which shifts stiffness from the elastin-dominated to collagen-dominated portion of the stress-strain curve, and 3) active contraction of arterial smooth muscle cells and myofibroblasts. PAH provides an interesting comparison to the Ross operation, which is an extreme form of PAH where the autograft is subjected instantaneously to systemic pressure, in contrast to PAH, where the increase in pulmonary pressure is more gradual and to a lower peak pressure. In sheep and bovine neonatal PAH studies, proximal pulmonary artery increased in wall stiffness despite an increase in wall thickness(25, 26).

Vascular remodeling showed increased collagen and decreased elastin contribution to the mechanical response. In sheep, increased adventitia with decreased media was present(26). These animal studies differed from our autograft study in several aspects: 1) induction of increased pulmonary pressure in animal models was sub-acute, 2) studies were in neonatal sheep and cow rather than our study in young adult humans, and 3) animal specimens were explanted from non-failing pulmonary roots acutely 7-15 days after inducing PAH. We previously demonstrated via FE modeling that upon exposure to systemic circulation, pulmonary autograft experienced significantly increased wall stress with resultant decreased distensibility and minimal change in diameter(20). Decreased distensibility was reflective of increased wall stiffness which prevented acute dilatation. We speculated that an early biomechanical response to increased wall stress is development of increased wall thickness as demonstrated in animal studies, to effectively reduce wall stress. Since our patients underwent autograft explant on average over a decade after Ross operation, our study suggests that late failure may occur due to further pathological remodeling which increased compliance, reduced wall stiffness with resultant autograft dilatation.

Vascular adaptation has been shown to be age-dependent(22). Although autograft remodeling response is probably more versatile in neonates than in adults, we did not observe a correlation between age and autograft stiffness in our young adult population. The age range of our patients was fairly narrow and sample size limited. Therefore, our study did not have sufficient power to answer whether age-dependent differences exist. Similarly, we found no correlation between autograft stiffness and duration of autograft exposure to systemic circulation. We had expected changes in material properties after Ross operation to be progressive, in parallel with changes in root diameter. However, material properties in failed autografts may represent a common failed state.

In our study, explanted autografts demonstrated increased compliance which may explain late dilatation. This surprising maladaptive biomechanical response to long-term exposure to systemic blood pressure supports the inclusion cylinder technique with native aorta or synthetic external support for stabilizing autograft root. Autograft can be stabilized by a cylindrical sleeve of synthetic reinforcement such as Dacron to prevent dilatation(27, 28). Dacron is significantly stiffer than autograft wall, thus it acts as an external barrier to prevent root dilatation. Yacoub's root replacement technique without support has been described to prevent late autograft dilatation—key features include implanting autograft at subannular level and cutting root 2-3mm above commissures to minimize pulmonary artery length(1). Our specimens were closer to STJ and may reflect dilatation from use of longer autograft length with inclusion of pulmonary artery. We have previously suggested that STJ/pulmonary artery should be excluded or reinforced as the material properties suggest a propensity for autograft dilatation(19, 20) and this study here also supports those conclusions.

## Study Limitations

We compared fresh native pulmonary roots with explanted autograft roots stored at  $-80^{\circ}\text{C}$ . Given the distance of our two institutions, Erasmus where autografts were harvested and UCSF where biaxial stretching was performed, it was not possible for fresh autograft explant analysis. Furthermore, Ross reoperation was rare and infrequent given decline in use of the technique, thus explanted autografts were stored in tissue bank. As such, access to explanted autograft specimens represented a unique opportunity to investigate failure of remodeling response to systemic blood pressure despite the limitations. Freezing has the potential to influence our stiffness results. Experimental studies of the effects of freezing and cryopreservation on elastic modulus measurements have mixed conclusions (29-32). Some studies demonstrated similar material properties for fresh and frozen arteries, while others showed differences. Interestingly, for those that demonstrated material property differences, stiffness was increased by the cryopreservation process rather than decreased (31, 32). Based on such findings, the decreased stiffness of explanted autografts compared to native pulmonary roots seen in our study likely reflects tissue remodeling rather than the effect of freezing.

Differences in characteristics between patients and controls were inevitable given the inherently limited supply of donor hearts from the transplant donor network. We did not receive any donor hearts from BAV patients. Currently, tissue mechanical properties have not been reported in the literature from pulmonary roots taken from patients with BAV. In our study, wall stiffness in explanted autografts from BAV patients appeared greater compared to patients with TAV. These results agree well with a recent echocardiographic study demonstrating increased pulmonary artery stiffness in BAV patients compared to TAV controls (33). As such, the decrease in autograft wall stiffness compared to native pulmonary artery we have reported most likely reflects the effect of autograft remodeling.

## Conclusions

More than a decade after initial exposure to the high pressure environment of systemic circulation, explanted autografts retained the non-linear response to mechanical loading typical of healthy human arteries. Remodeling increased wall thickness and reduced circumferential wall stress. Interestingly, wall stiffness in explanted autografts was reduced compared to native pulmonary roots, which explained progressive autograft root dilatation.

## Acknowledgements

We would like to thank Dr. A J Van den Bogaardt from Heart Valve Bank of Erasmus University Medical Center (Rotterdam, Netherlands) for his kind help and advice with both storage and handling of frozen explanted autograft tissue. We also thank CTDN for providing fresh normal human pulmonary roots.

## References

1. El-Hamamsy I, Poirier NC. What is the role of the ross procedure in today's armamentarium? *The Canadian journal of cardiology* 2013;29(12):1569-1576.
2. Stelzer P, Itagaki S, Varghese R, Chikwe J. Operative mortality and morbidity after the ross procedure: A 26- year learning curve. *J Heart Valve Dis* 2013;22(6):767-775.
3. David TE, David C, Woo A, Manlhiot C. The ross procedure: Outcomes at 20 years. *The Journal of thoracic and cardiovascular surgery* 2014;147(1):85-93.
4. Mastrobuoni S, de Kerchove L, Solari S et al. The ross procedure in young adults: Over 20 years of experience in our institution. *European journal of cardio-thoracic surgery : official journal of the European Association for Cardio-thoracic Surgery* 2015.
5. Sievers HH, Stierle U, Charitos EI et al. A multicentre evaluation of the autograft procedure for young patients undergoing aortic valve replacement: Update on the german ross registry. *European journal of cardio-thoracic surgery : official journal of the European Association for Cardio-thoracic Surgery* 2015.
6. Yacoub MH, El-Hamamsy I, Sievers HH et al. Under-use of the ross operation--a lost opportunity. *Lancet* 2014;384(9943):559-560.
7. El-Hamamsy I, Eryigit Z, Stevens LM et al. Long-term outcomes after autograft versus homograft aortic root replacement in adults with aortic valve disease: A randomised controlled trial. *Lancet* 2010;376(9740):524-531.
8. Takkenberg JJ, Klieverik LM, Schoof PH et al. The ross procedure: A systematic review and meta-analysis. *Circulation* 2009;119(2):222-228.
9. David TE. Reoperations after the ross procedure. *Circulation* 2010;122(12):1139-1140.
10. de Kerchove L, Boodhwani M, Etienne PY et al. Preservation of the pulmonary autograft after failure of the ross procedure. *European journal of cardio-thoracic surgery : official journal of the European Association for Cardio-thoracic Surgery* 2010;38(3):326-332.
11. Pettersson GB, Subramanian S, Flynn M et al. Reoperations after the ross procedure in adults: Towards autograft-sparing/ross reversal. *J Heart Valve Dis* 2011;20(4):425-432.
12. Charitos EI, Takkenberg JJ, Hanke T et al. Reoperations on the pulmonary autograft and pulmonary homograft after the ross procedure: An update on the german dutch ross registry. *The Journal of thoracic and cardiovascular surgery* 2012;144(4):813-821; discussion 821-813.
13. Luciani GB, Lucchese G, De Rita F, Puppini G, Faggian G, Mazzucco A. Reparative surgery of the pulmonary autograft: Experience with ross reoperations. *European journal of cardio-thoracic surgery : official journal of the European Association for Cardio-thoracic Surgery* 2012;41(6):1309-1314; discussion 1314-1305.
14. Stulak JM, Burkhart HM, Sundt TM, 3rd et al. Spectrum and outcome of reoperations after the ross procedure. *Circulation* 2010;122(12):1153-1158.
15. Mokhles MM, Rizopoulos D, Andrinopoulou ER et al. Autograft and pulmonary allograft performance in the second post-operative decade after the ross procedure: Insights from the rotterdam prospective cohort study. *European heart journal* 2012;33(17):2213-2224.
16. Mookhoek A, de Heer E, Bogers AJ, Takkenberg JJ, Schoof PH. Pulmonary autograft valve explants show typical degeneration. *The Journal of thoracic and cardiovascular surgery* 2010;139(6):1416-1419.

17. Rabkin-Aikawa E, Aikawa M, Farber M et al. Clinical pulmonary autograft valves: Pathologic evidence of adaptive remodeling in the aortic site. *The Journal of thoracic and cardiovascular surgery* 2004;128(4):552-561.
18. Schoof PH, Takkenberg JJ, van Suylen RJ et al. Degeneration of the pulmonary autograft: An explant study. *The Journal of thoracic and cardiovascular surgery* 2006;132(6):1426-1432.
19. Azadani AN, Chitsaz S, Matthews PB et al. Regional mechanical properties of human pulmonary root used for the ross operation. *J Heart Valve Dis* 2012;21(4):527-534.
20. Wisneski AD, Matthews PB, Azadani AN et al. Human pulmonary autograft wall stress at systemic pressures prior to remodeling after the ross procedure. *J Heart Valve Dis* 2014;23(3):377-384.
21. Hunter KS, Lammers SR, Shandas R. Pulmonary vascular stiffness: Measurement, modeling, and implications in normal and hypertensive pulmonary circulations. *Comprehensive Physiology* 2011;1(3):1413-1435.
22. Lammers S, Scott D, Hunter K, Tan W, Shandas R, Stenmark KR. Mechanics and function of the pulmonary vasculature: Implications for pulmonary vascular disease and right ventricular function. *Comprehensive Physiology* 2012;2(1):295-319.
23. Wagsater D, Paloschi V, Hanemaaijer R et al. Impaired collagen biosynthesis and cross-linking in aorta of patients with bicuspid aortic valve. *Journal of the American Heart Association* 2013;2(1):e000034.
24. Carr-White GS, Afoke A, Birks EJ et al. Aortic root characteristics of human pulmonary autografts. *Circulation* 2000;102(19 Suppl 3):III15-21.
25. Lammers SR, Kao PH, Qi HJ et al. Changes in the structure-function relationship of elastin and its impact on the proximal pulmonary arterial mechanics of hypertensive calves. *American journal of physiology Heart and circulatory physiology* 2008;295(4):H1451-1459.
26. Dodson RB, Morgan MR, Galambos C, Hunter KS, Abman SH. Chronic intrauterine pulmonary hypertension increases main pulmonary artery stiffness and adventitial remodeling in fetal sheep. *American journal of physiology Lung cellular and molecular physiology* 2014;307(11):L822-828.
27. Nappi F, Spadaccio C, Fouret P et al. An experimental model of the ross operation: Development of resorbable reinforcements for pulmonary autografts. *The Journal of thoracic and cardiovascular surgery* 2015.
28. Skillington PD, Mokhles MM, Takkenberg JJ et al. The ross procedure using autologous support of the pulmonary autograft: Techniques and late results. *The Journal of thoracic and cardiovascular surgery* 2015;149(2 Suppl):S46-52.
29. Chow MJ, Zhang Y. Changes in the mechanical and biochemical properties of aortic tissue due to cold storage. *The Journal of surgical research* 2011;171(2):434-442.
30. Schaar JA, de Korte CL, Mastik F, van der Steen AF. Effect of temperature increase and freezing on intravascular elastography. *Ultrasonics* 2002;40(1-8):879-881.
31. Hemmasizadeh A, Darvish K, Autieri M. Characterization of changes to the mechanical properties of arteries due to cold storage using nanoindentation tests. *Annals of biomedical engineering* 2012;40(7):1434-1442.
32. Venkatasubramanian RT, Grassl ED, Barocas VH, Lafontaine D, Bischof JC. Effects of freezing and cryopreservation on the mechanical properties of arteries. *Annals of biomedical engineering* 2006;34(5):823-832.
33. Celik M, Yuksel UC, Yalcinkaya E et al. Elasticity properties of pulmonary artery in patients with bicuspid aortic valve. *Echocardiography* 2014;31(6):759-764.

# Chapter 8

## **Biomechanics of Pulmonary Autografts Compared to Native Aortic Roots**

**Aart Mookhoek, Kapil Krishnan, Sam Chitsaz, Heide Kuang, Liang Ge,  
Paul H Schoof, Ad J J C Bogers, Johanna J M Takkenberg, Elaine E Tseng**

*Accepted (Ann Thorac Surg)*

## **Abstract**

### **Background**

Progressive autograft dilatation after Ross operation suggests that remodeling does not effectively reproduce native aortic root biomechanics. In the first of this two-part series, we compared autograft and pulmonary root mechanical properties at pulmonary pressures. The goal of this study was to compare mechanical properties of explanted pulmonary autografts to native aortic roots at systemic pressures.

### **Methods**

Autograft specimens were obtained from patients undergoing reoperation after Ross operation. For comparison, native aortic roots were obtained from unused donor hearts. Biaxial stretch testing was performed to determine vessel wall mechanical properties. Wall stiffness was determined at patient-specific physiologic stresses corresponding to systemic pressures (80 and 120mmHg) as well as hypertensive state (200mmHg).

### **Results**

Non-linear stress-strain curves were present for both failed autografts and native aortic roots. Explanted autografts were significantly more compliant than native aortic roots at 80mmHg ( $1527 \pm 676$  versus  $2993 \pm 1343$  kPa,  $p=0.011$ ), 120mmHg ( $2537 \pm 1183$  versus  $4931 \pm 2211$  kPa,  $p=0.013$ ) and 200mmHg ( $4788 \pm 2303$  versus  $9207 \pm 4159$  kPa,  $p=0.015$ ). Autograft wall stiffness at 80, 120 and 200mmHg was not correlated with age at time of Ross operation ( $p=0.666$ ,  $p=0.639$  and  $p=0.616$ , respectively) or time in the systemic circulation ( $p=0.635$ ,  $p=0.637$  and  $p=0.647$ , respectively).

### **Conclusions**

Failed pulmonary autografts retained non-linear response to mechanical loading typical of healthy arterial tissue. Despite similar wall thickness in autografts, wall stiffness was significantly reduced compared to native aortic roots. We demonstrated that biomechanical remodeling was inadequate to achieve native aortic mechanical properties, which may have resulted in progressive autograft root dilatation.



## Introduction

The Ross operation offers several advantages compared to conventional aortic valve replacement such as freedom from oral anticoagulation and good hemodynamics(1). In addition, Ross operation may restore life expectancy to that of the general population(2-4). However, recent guidelines only consider Ross operation when performed by experienced surgeons in young adults with contraindication to anticoagulation use(5). These guidelines weighed the advantages against technical complexity of the operation and risk of autograft reoperation(6-10). Late autograft dysfunction after the Ross operation using the full root technique was primarily due to progressive root dilatation leading to aneurysm formation and valvular regurgitation(6-11).

Progressive root dilatation likely reflects inability of the autograft to adapt to demands of the systemic circulation. Understanding the biomechanics of vascular remodeling in explanted autografts is important for designing strategies to prevent dilatation. We previously demonstrated that vascular remodeling in explanted autografts resulted in increased compliance in native pulmonary roots at pulmonary pressures(x). We hypothesize that pulmonary autografts explanted after progressive dilatation were also more compliant than native aortic root at systemic pressures. In this study, we compared wall biomechanical properties of explanted pulmonary autografts to healthy native aortic roots at patient-specific stresses corresponding to systemic pressures and systemic hypertension.

## Patients and Methods

This study was approved by the institutional review boards of Erasmus University Medical Center and San Francisco Veterans Affairs Medical Center and was exempted by Committee of Human Research at University of California San Francisco Medical Center.

### Sample Collection

Patients who required reoperation after a Ross operation performed between 1992 and 2000 at the Erasmus University Medical Center and consented for autograft specimen collection were recruited (Table 1). The Ross operation was performed using the root replacement technique without external support, leaving a minimal amount of tissue distal to the sinotubular junction (STJ). Specimens were excised proximal to the distal suture line, frozen, and stored at  $-80^{\circ}\text{C}$ .

Human native aortic roots were obtained from unused California Transplant Donor Network (CTDN, Oakland, CA, USA) donor hearts from age-matched subjects who consented for research and died of non-cardiac causes. Tissue samples were obtained from sinuses and at 1cm distal to STJ.

Care was taken to preserve tissue alignment in circumferential and longitudinal directions. Mechanical testing for CTDN specimens was completed within 24 hours of cross-clamping; autograft specimens were thawed prior to stretching.

**TABLE I** Patient Population

		Ross patients	Control subjects
Patients		10	6
Sex	Male	8	3
	Female	2	3
Native aortic valve	Bicuspid	8	0
	Tricuspid	2	6
Wall thickness (zero pressure)		2.2±0.2mm	1.7±0.3mm <sup>a</sup>
Diameter (zero pressure)		26.7±1.9mm	22.3±0.6mm <sup>b</sup>
Diameter (systemic pressure)		45.8±4.0mm	-
Diameter pulmonary artery at Ross operation (n=2)		25.0±0.0mm	-
Diameter aorta at Ross operation (n=8)		27.6±6.2mm	-
Age at Ross operation		26.7±11.1	-
Age at explantation		39.7±10.9	49.0±10.3 <sup>c</sup>
Time in systemic circulation		13.0±2.1	-

Ross patients compared with control subjects: <sup>a</sup>p=0.011, <sup>b</sup>p=0.009, <sup>c</sup>p=0.112.

### Equibiaxial stretch testing

Custom-built planar biaxial stretcher was used to determine material properties. Biaxial tensile testing methods were described previously(12). Specimen wall thickness was measured using digital caliper (model 500-754-10; Mitutoyo America Corporation, Aurora, IL, USA) by lightly sandwiching tissue between two glass slides. Three 5-0 silk sutures were anchored to each specimen edge using small, barbless fishhooks, and were attached to four stretcher arms, aligning circumferential and longitudinal edges with direction of deformation. Five black ceramic markers (250–355µm; MO-SCI Corporation, Rolla, MO, USA) were placed on tissue surface, creating grid in specimen center. Specimen was floated in a water bath with Dulbecco's phosphate buffered saline without calcium and magnesium. Load cells (model 31/3672-02, 1000 g; Honeywell Sensotec Inc., Columbus, OH, USA) located on two orthogonal arms were zeroed. During extension, load cell data was amplified to determine force on specimen during deformation. Real-time displacement of marker beads was obtained using CCD camera placed over tissue surface (model TM 9701; 30fps, 0.1 pixels/mm; Pulnix Inc., Sunnyvale, CA, USA). Images of tissue surface during deformation were digitized in MATLAB (version 7.0; MathWorks, Natick, MA, USA), and markers were identified based on their contrast to surrounding tissue. Coordinates of

each marker were tracked through loading cycle, and their relative movement was used to calculate strains in the principal directions. Specimens were tested over a large strain range using equibiaxial displacement-controlled protocols. First, 10 preconditioning cycles of 10% stretch, using triangular waveform at 0.5 Hz, were applied. Subsequently, each specimen was repeatedly cycled up to 55% peak strain.

## Data analysis

Constitutive modeling to calculate Cauchy stress and Green strain was performed as described previously(x). Wall stiffness was defined as slope of the stress-strain curve at a given point. To investigate stiffness under physiologic conditions, stiffness was calculated at patient-specific physiologic stresses at systemic pressures (80 and 120mmHg) and systemic hypertension (200mmHg). For native aortic roots, patient-specific physiologic stresses were determined from finite element (FE) modeling with LS-DYNA (Livermore Software Technology Corporation, Livermore, CA, USA), using a cylindrical model with mechanical properties obtained from biaxial stretching, unloaded root diameter and wall thickness at 0mmHg(13). Simulations were run from 0mmHg to systemic pressures and hypertensive pressures to determine respective patient-specific physiologic stresses. For explanted autografts, unloaded root diameter was calculated based on pre-operatively echocardiographic measurements. FE simulations were run from 0mmHg to systemic pressure using unloaded wall thickness, autograft material properties from biaxial stretching, and iterative estimations of unloaded diameter until autograft diameter at systemic pressure matched measured diameter by echocardiography. After determining unloaded autograft root diameter, FE simulations were run from 0mmHg to systemic pressures and hypertensive pressures to determine patient-specific physiologic stresses.

Wall stiffness was obtained at respective physiologic stresses based on slope of stress-strain curves obtained from biaxial stretching. For two Ross patients, when FE models failed to determine physiologic stress as simulation results would not converge, stiffness was calculated based on average physiologic stress for explanted autografts at the respective blood pressure.

For statistical analysis, normal distribution of data was assessed using Shapiro-Wilk test. Differences between patients and control subjects in age at explantation, wall thickness, and wall stiffness were analyzed by independent-samples *t*-tests. Paired sample *t*-tests were used for additional stiffness analyses. Pearson's correlation coefficient was used to study autograft stiffness with respect to age at Ross operation and time in systemic circulation. Reported values are quoted as mean  $\pm$  standard deviation. Statistical analyses were performed using IBM SPSS (version 21.0; IBM, Somers, NY, USA).

## Results

A total of 101 patients underwent the Ross operation between 1992 and 2000 at the Erasmus University Medical Center. As of January 1st 2015, 39 of those patients required a reoperation on the pulmonary autograft. Nine out of ten patients included in this study presented with congenital aortic stenosis at the Ross operation, one patient presented with aortic regurgitation based on single leaflet prolapse of a tricuspid aortic valve. None of the patients undergoing the Ross operation were noted to have preoperative pulmonary arterial hypertension. Average preoperative pulmonary artery systolic and diastolic pressures were  $21.8 \pm 6.2$  and  $12.0 \pm 4.2$  mmHg, respectively ( $n=4$ ).

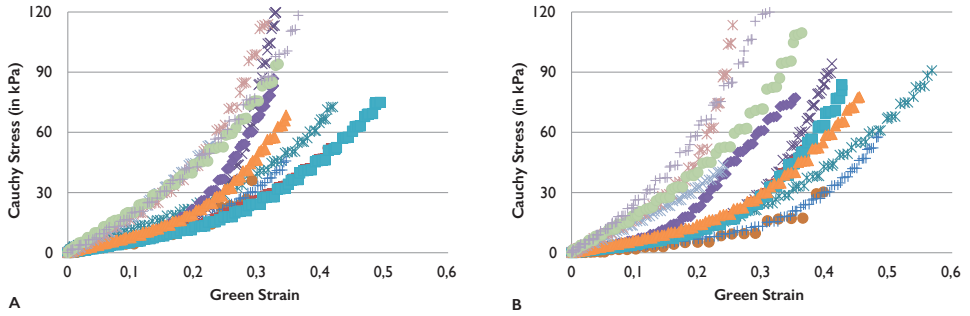
Raw stress-strain data obtained from equibiaxial stretch testing of explanted autografts and native aortic roots is displayed as Cauchy stress–Green strain plots (Figures 1 and 2, respectively).

Non-linear stress-strain response was evident for both root types in both circumferential and longitudinal directions. FE modeling allowed calculation of pressurized wall thickness, root diameter and patient-specific physiologic stress at 80, 120 and 200 mmHg (Table 2).

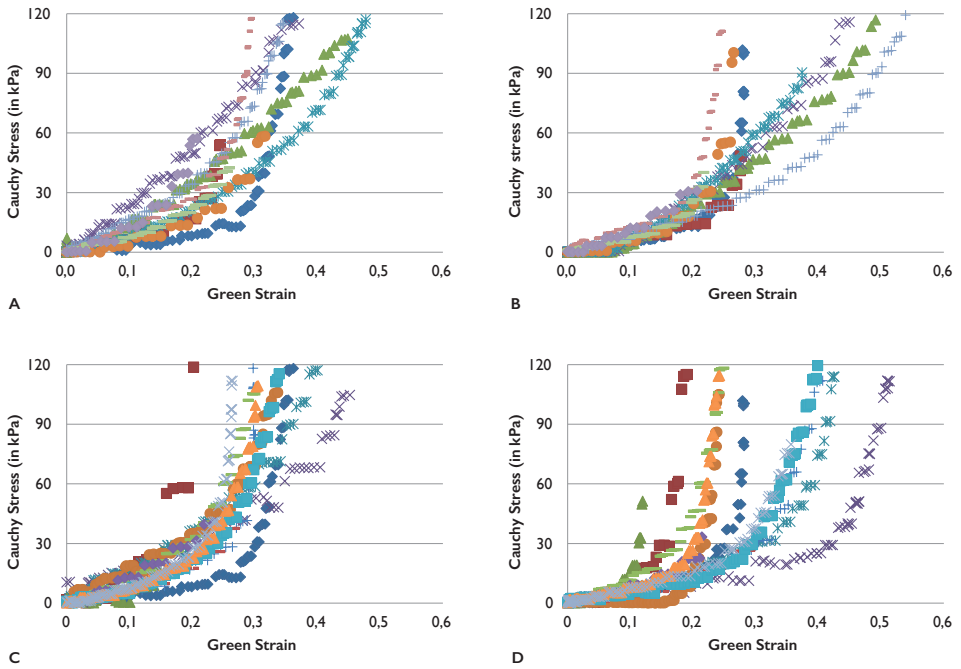
Wall stiffness was greater at 120 mmHg than 80 mmHg for both explanted autografts and native aortic roots in both circumferential ( $p < 0.001$  and  $p < 0.001$ , respectively) and longitudinal ( $p < 0.001$  and  $p < 0.001$ , respectively) directions. Stiffness was also greater at 200 mmHg than at 120 mmHg for both explanted autografts and native aortic roots in both circumferential ( $p < 0.001$  and  $p < 0.001$ , respectively) and longitudinal directions ( $p < 0.001$  and  $p < 0.001$ , respectively). Wall stiffness in explanted autografts was lower compared to native aortic roots in both circumferential and longitudinal directions at 80 mmHg ( $p = 0.011$  and  $p = 0.011$ , respectively), 120 mmHg ( $p = 0.013$  and  $p = 0.014$ , respectively) and 200 mmHg ( $p = 0.015$  and  $p = 0.016$ , respectively).

In native aortic roots, the response to mechanical loading was similar in the circumferential and longitudinal directions (isotropy) at 80, 120, and 200 mmHg ( $p = 0.437$ ,  $p = 0.595$  and  $p = 0.646$ , respectively). Explanted autografts also displayed isotropic responses at 80, 120 and 200 mmHg ( $p = 0.301$ ,  $p = 0.318$  and  $p = 0.170$ , respectively).

Autograft wall stiffness at 80, 120 and 200 mmHg was not correlated with patient age at time of original Ross operation ( $p = 0.666$ ,  $p = 0.639$  and  $p = 0.616$ , respectively) nor time in systemic circulation prior to explantation ( $p = 0.635$ ,  $p = 0.637$  and  $p = 0.647$ , respectively). Wall stiffness in explanted autografts obtained from patients with a bicuspid aortic valve (BAV) appeared greater compared to patients with a tricuspid aortic valve (TAV) at 80 mmHg ( $1632 \pm 711$  vs  $1107 \pm 363$  kPa), at 120 mmHg ( $2708 \pm 1253$  vs  $1855 \pm 659$  kPa) and at 200 mmHg ( $5104 \pm 2451$  vs  $3527 \pm 1311$  kPa).



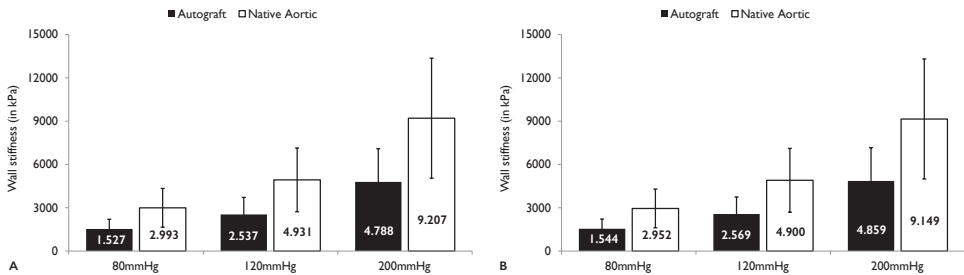
**FIGURE 1** Stress-strain curves for pulmonary autografts in circumferential (A) and longitudinal directions (B).



**FIGURE 2** Stress-strain curves for native ascending aorta (A, B) and aortic sinuses (C, D) in circumferential (A, C) and longitudinal directions (B, D).

**TABLE 2** FE Model Calculations of Patient-Specific Physiologic Stress

	80mmHg			120mmHg			200mmHg		
	Thickness mm	Diameter Mm	Stress kPa	Thickness mm	Diameter mm	Stress kPa	Thickness mm	Diameter mm	Stress kPa
Autograft	1.3±0.1	44.2±3.8	191.8±32.5	1.2±0.1	45.8±4.0	309.8±52.3	1.2±0.1	47.8±4.2	561.3±94.5
Aorta	1.2±0.2	35.0±2.5	173.5±34.9	1.2±0.2	36.2±2.5	276.8±56.2	1.1±0.2	37.3±2.6	494.3±101.3
	p=0.512	p=0.010	p=0.481	p=0.566	p=0.010	p=0.432	p=0.629	p=0.008	p=0.380

**FIGURE 3** Stiffness of pulmonary autografts and native aortic roots at 80, 120 and 200mmHg in circumferential (A) and longitudinal directions (B).

## Discussion

Availability of explanted pulmonary autograft specimens offered a unique opportunity to study the biomechanical consequences of remodeling after the Ross operation. In a previous study, altered biomechanical characteristics were shown in explanted autografts compared to native pulmonary roots at pulmonary pressures(x). In this study, we have demonstrated that autograft roots, explanted after progressive dilatation, did not remodel to biomechanically represent native aortic roots at systemic pressures. On the contrary, explanted autografts, which on average had been exposed to the systemic circulation for more than a decade, remodeled to become more compliant than age-matched native aortic roots.

Arterial tissues have complex laminar structures in which responses to mechanical loading are principally determined by collagen and elastin fibers(14, 15). At low stresses, arterial load-bearing is elastin-dominated and more compliant. At high stresses, load-bearing is collagen-dominated and stiffness increases. Finite element analysis of native pulmonary roots demonstrated a dramatic increase in maximal wall stress when an increase from pulmonary to systemic pressures was simulated(13). Using native pulmonary root geometry and biomechanical characteristics, a six fold increase in maximal wall stress was demonstrated between 25mmHg and 120mmHg. Based on these findings, release of the aortic cross-clamp during the Ross operation is expected to immediately shift the

response to mechanical loading of the pulmonary autograft to the collagen-dominated portion of the stress-strain curve. Moreover, the magnitude of stress increase may be the driving force for remodeling.

Interestingly, explanted autografts have been shown to display prominent deposition of collagen in the adventitia and loss as well as fragmentation of elastin fibers in the media compared to native aortic roots(16, 17).Therefore, one might expect an increase in autograft wall stiffness compared to native aortic roots. However, wall stiffness is influenced by more than collagen quantity alone. Load-bearing of collagen fibers is determined by collagen micro-architecture, such as the number and nature of cross-links(18). In the aortic wall of patients with a BAV, impaired collagen biosynthesis and post-translational modification appears to be associated with aneurysm formation (19). Our finding of decreased autograft wall stiffness may be explained by similar changes in collagen micro-architecture. This intriguing hypothesis should be subject to future studies.

To date, a single study has reported on the biomechanical properties of the autograft wall (20). Interestingly, the authors also reported lower autograft wall stiffness, compared to the native aortic root, in a specimen explanted four months after the Ross operation in a 14-year old patient. However, it is important to mention the limited sample size and time to explantation as well as differences in the methods used to obtain the biomechanical characteristics.

The absence of a correlation between wall stiffness and duration of autograft exposure to systemic the circulation may be explained by the limited range of exposure duration as well as limited sample size. The same may apply to the correlation between wall stiffness and patient age at the time of the original Ross operation. An interesting avenue for future studies may be to investigate whether these correlations are present in patients without progressive autograft root dilatation.

## Study Limitations

The main limitation of our study was that native aortic roots were analyzed fresh, while explanted autograft roots had to be frozen for transport to our facility in San Francisco and subsequently thawed prior to stretch testing. While freezing may be expected to influence wall stiffness measurements, experimental studies of the effects of freezing have shown mixed results in (21-24). Some studies reported similar biomechanical characteristics for fresh and frozen arteries, while others surprisingly demonstrated an increase in stiffness in the physiologic range after freezing(23, 24). As such, the differences in wall stiffness reported in our study likely reflect tissue remodeling.

Differences in characteristics between patients and controls were due to the limited supply of donor hearts from the transplant donor network. We did not receive any donor hearts from patients with a BAV. In our study, wall stiffness in explanted autografts from

BAV patients appeared greater compared to patients with a TAV. These results agree well with a recent echocardiographic study demonstrating increased pulmonary artery stiffness in BAV patients compared to TAV controls (25). Therefore, our finding of decreased autograft wall stiffness in explanted autograft compared to native aortic roots most likely reflects the effect of autograft remodeling.

### **Future perspectives**

The value of current prediction models used to determine when to operate on patients with autograft root dilatation are limited. Prediction of patient-specific evolution of autograft root dimensions as well as determination of the maximum diameter at which dissection risk is still acceptable would benefit patients. Our study improves our understanding of biomechanical remodeling in the setting of autograft dilatation and may act as a starting point for future studies. To arrive at a prediction models based on biomechanical characteristics, we aim to develop advanced imaging techniques to determine *in vivo* biomechanical characteristics and study changes over time in Ross patients.

### **Conclusions**

We have shown that in failed pulmonary autografts, explanted for aneurysmal dilatation more than a decade after the initial Ross operation, biomechanical remodeling resulted in increased compliance compared to the native aortic root. This finding may explain why progressive autograft root dilatation occurs late after the Ross operation.

### **Acknowledgements**

We would like to thank Dr. A J Van den Bogaerdt from Heart Valve Bank of Erasmus University Medical Center (Rotterdam, Netherlands) for his kind help and advice with both storage and handling of frozen pulmonary autograft tissue.



## References

1. El-Hamamsy I, Poirier NC. What is the role of the Ross procedure in today's armamentarium? *The Canadian journal of cardiology*. 2013;29(12):1569-76.
2. David TE, David C, Woo A, Manlhiot C. The Ross procedure: outcomes at 20 years. *The Journal of thoracic and cardiovascular surgery*. 2014;147(1):85-93.
3. El-Hamamsy I, Eryigit Z, Stevens LM, et al. Long-term outcomes after autograft versus homograft aortic root replacement in adults with aortic valve disease: a randomised controlled trial. *Lancet*. 2010;376(9740):524-31.
4. Sievers HH, Stierle U, Charitos EI, et al. A multicentre evaluation of the autograft procedure for young patients undergoing aortic valve replacement: update on the German Ross Registry dagger. *European journal of cardio-thoracic surgery : official journal of the European Association for Cardio-thoracic Surgery*. 2015.
5. Nishimura RA, Otto CM, Bonow RO, et al. 2014 AHA/ACC Guideline for the Management of Patients With Valvular Heart Disease: a report of the American College of Cardiology/American Heart Association Task Force on Practice Guidelines. *Circulation*. 2014;129(23):e521-643.
6. Charitos EI, Takkenberg JJ, Hanke T, et al. Reoperations on the pulmonary autograft and pulmonary homograft after the Ross procedure: An update on the German Dutch Ross Registry. *The Journal of thoracic and cardiovascular surgery*. 2012;144(4):813-21; discussion 21-3.
7. de Kerchove L, Boodhwani M, Etienne PY, et al. Preservation of the pulmonary autograft after failure of the Ross procedure. *European journal of cardio-thoracic surgery : official journal of the European Association for Cardio-thoracic Surgery*. 2010;38(3):326-32.
8. Luciani GB, Lucchese G, De Rita F, Puppini G, Faggian G, Mazzucco A. Reparative surgery of the pulmonary autograft: experience with Ross reoperations. *European journal of cardio-thoracic surgery : official journal of the European Association for Cardio-thoracic Surgery*. 2012;41(6):1309-14; discussion 14-5.
9. Stulak JM, Burkhart HM, Sundt TM, 3rd, et al. Spectrum and outcome of reoperations after the Ross procedure. *Circulation*. 2010;122(12):1153-8.
10. Takkenberg JJ, Klieverik LM, Schoof PH, et al. The Ross procedure: a systematic review and meta-analysis. *Circulation*. 2009;119(2):222-8.
11. Mokhles MM, Rizopoulos D, Andrinopoulou ER, et al. Autograft and pulmonary allograft performance in the second post-operative decade after the Ross procedure: insights from the Rotterdam Prospective Cohort Study. *European heart journal*. 2012;33(17):2213-24.
12. Azadani AN, Chitsaz S, Matthews PB, et al. Regional mechanical properties of human pulmonary root used for the Ross operation. *J Heart Valve Dis*. 2012;21(4):527-34.
13. Wisneski AD, Matthews PB, Azadani AN, et al. Human pulmonary autograft wall stress at systemic pressures prior to remodeling after the Ross procedure. *J Heart Valve Dis*. 2014;23(3):377-84.
14. Hunter KS, Lammers SR, Shandas R. Pulmonary vascular stiffness: measurement, modeling, and implications in normal and hypertensive pulmonary circulations. *Comprehensive Physiology*. 2011;1(3):1413-35.
15. Lammers S, Scott D, Hunter K, Tan W, Shandas R, Stenmark KR. Mechanics and function of the pulmonary vasculature: implications for pulmonary vascular disease and right ventricular function. *Comprehensive Physiology*. 2012;2(1):295-319.
16. Schoof PH, Takkenberg JJ, van Suylen RJ, et al. Degeneration of the pulmonary autograft: an explant study. *The Journal of thoracic and cardiovascular surgery*. 2006;132(6):1426-32.

17. Rabkin-Aikawa E, Aikawa M, Farber M, et al. Clinical pulmonary autograft valves: pathologic evidence of adaptive remodeling in the aortic site. *The Journal of thoracic and cardiovascular surgery*. 2004;128(4):552-61.
18. Lindeman JH, Ashcroft BA, Beenakker JW, et al. Distinct defects in collagen microarchitecture underlie vessel-wall failure in advanced abdominal aneurysms and aneurysms in Marfan syndrome. *Proceedings of the National Academy of Sciences of the United States of America*. 2010;107(2):862-5.
19. Wagsater D, Paloschi V, Hanemaaijer R, et al. Impaired collagen biosynthesis and cross-linking in aorta of patients with bicuspid aortic valve. *Journal of the American Heart Association*. 2013;2(1):e000034.
20. Carr-White GS, Afoke A, Birks EJ, et al. Aortic root characteristics of human pulmonary autografts. *Circulation*. 2000;102(19 Suppl 3):III15-21.
21. Chow MJ, Zhang Y. Changes in the mechanical and biochemical properties of aortic tissue due to cold storage. *The Journal of surgical research*. 2011;171(2):434-42.
22. Schaar JA, de Korte CL, Mastik F, van der Steen AF. Effect of temperature increase and freezing on intravascular elastography. *Ultrasonics*. 2002;40(1-8):879-81.
23. Hemmasizadeh A, Darvish K, Autieri M. Characterization of changes to the mechanical properties of arteries due to cold storage using nanoindentation tests. *Annals of biomedical engineering*. 2012;40(7):1434-42.
24. Venkatasubramanian RT, Grassl ED, Barocas VH, Lafontaine D, Bischof JC. Effects of freezing and cryopreservation on the mechanical properties of arteries. *Annals of biomedical engineering*. 2006;34(5):823-32.
25. Celik M, Yuksel UC, Yalcinkaya E et al. Elasticity properties of pulmonary artery in patients with bicuspid aortic valve. *Echocardiography* 2014;31(6):759-764.

# Chapter 9

## **Material Properties of Explanted Pulmonary Autograft Leaflets Compared to Native Aortic and Pulmonary Leaflets**

**Aart Mookhoek, Heide Kuang, Andrew D Wisneski, Ad J J C Bogers,  
Johanna J M Takkenberg, Elaine E Tseng, Paul H Schoof**

*Submitted*

## **Abstract**

### **Background**

Pulmonary autograft reoperation after the Ross operation is a concern. Surgeons advocate autograft valve preservation to restore the advantages associated with a functioning autograft valve. Long-term outcome after valve-sparing autograft reoperations is unknown. In this study, we compared the material properties of explanted pulmonary autograft leaflets with native aortic and pulmonary leaflets.

### **Methods**

Autograft leaflets from seven patients (86% male, mean age  $40 \pm 12$  years), explanted at reoperation  $12 \pm 3$  years after the Ross operation, were analyzed using equibiaxial stretch testing. For comparison, native aortic and pulmonary leaflets from human donor hearts were analyzed. Leaflet stiffness was calculated at a standardized stress level.

### **Results**

Stiffness of explanted pulmonary autograft leaflets did not differ from native pulmonary leaflets in both the circumferential ( $11273 \pm 3768$  versus  $9746 \pm 4370$  kPa,  $p=0.908$ ) and radial direction ( $11184 \pm 3209$  versus  $9726 \pm 4578$  kPa,  $p=0.926$ ). Stiffness of native aortic leaflets was higher than that of both autograft and native pulmonary leaflets in the circumferential ( $26866 \pm 7208$  kPa,  $p=0.001$  and  $p=0.002$  respectively) and radial direction ( $27979 \pm 8308$  kPa,  $p=0.001$  and  $p=0.002$  respectively).

### **Conclusions**

After more than a decade in the systemic circulation, pulmonary autograft leaflets retained material properties similar to native pulmonary leaflets. Despite changes to autograft root geometry and tissue structure shown in previous studies, equibiaxial stretch testing did not demonstrate mechanical remodeling. In our view, these findings do not preclude autograft valve preservation at reoperation after the Ross operation.

## Introduction

The Ross operation offers patients a living aortic valve substitute with good hemodynamics and freedom from oral anticoagulation use. In adult patients, reoperation due to progressive autograft root dilatation and/or autograft insufficiency is a concern, especially in the second post-operative decade.<sup>1</sup> The original reoperation strategy involved excision of all autograft material followed by a Bentall procedure.<sup>2</sup> Nowadays, surgeons advocate autograft leaflet preservation by performing valve-sparing autograft root replacement and/or autograft valve repair.<sup>3,4</sup> While this approach preserves some advantages of the Ross operation, long-term outcome of autograft leaflet preservation is not yet available.

Experimental studies may help to predict future events and long-term outcome. The structural integrity and biomechanical remodeling response of explanted pulmonary autograft leaflets may be assessed by exploring the material properties. Until recently, the Bentall procedure was the reoperation strategy of choice after the Ross operation in our center. Therefore, we have been able to collect a substantial number of pulmonary autograft leaflets at the Erasmus University Medical Center over the years.

In this study, equibiaxial stretch testing was used to determine the material properties of explanted pulmonary autograft leaflets and compare them with native aortic and pulmonary leaflets.

## Patients and Methods

This study was approved by the institutional review boards of the Erasmus University Medical Center and the San Francisco Veterans Affairs Medical Center and exempted by the Committee of Human Research at University of California at San Francisco Medical Center.

### Specimen Collection

Pulmonary autograft leaflets were obtained from consenting patients at the Erasmus University Medical Center. The initial Ross operation in these patients was performed using the full root replacement technique without applying external support. Leaflets were obtained when patients received a Bentall procedure for autograft root aneurysm and autograft valve insufficiency. Specimens were frozen and stored at  $-80^{\circ}\text{C}$ . To compare autograft leaflets to native aortic and pulmonary leaflets, fresh human specimens were obtained from unused California Transplant Donor Network (CTDN, Oakland, CA, USA) donor hearts. Inclusion of CTDN specimens was limited to donors who consented for research and died of non-cardiac causes.

A square specimen was excised from the central belly region of each leaflet, while care was taken to preserve tissue alignment in the circumferential and radial directions.

Mechanical testing for CTDN specimens was completed within 24 hours of cross-clamping, autograft specimens were thawed prior to stretching.

### **Equibiaxial stretch testing**

A custom-built planar biaxial stretching system was used to determine material properties. Details of biaxial tensile testing methods and analyses have been described previously [5]. Leaflet thickness was measured using a digital caliper (model 500-754-10; Mitutoyo America Corporation, Aurora, IL, USA). Three 5-0 silk sutures were anchored to each edge of the specimen using small, barbless fishhooks. These sutures were attached to four stretcher arms, aligning circumferential and radial edges with the direction of deformation. Five black ceramic markers (250–355  $\mu\text{m}$ ; MO-SCI Corporation, Rolla, MO, USA) were placed on the leaflet surface, creating a grid in the center of the specimen. The specimen was then floated in a water bath with Dulbecco's phosphate buffered saline without calcium and magnesium at room temperature. Load cells (model 31/3672-02, 1000 g; Honeywell Sensotec Inc., Columbus, OH, USA) located on two orthogonal arms were zeroed. During extension, load cell data was amplified to determine force on the specimen during deformation. Real-time displacement of marker beads was obtained using a CCD camera placed over the leaflet surface (model TM 9701; 30fps, 0.1 pixels/mm; Pulnix Inc., Sunnyvale, CA, USA). Images of the leaflet surface during deformation were digitized in MATLAB (version 7.0; MathWorks, Natick, MA, USA), and the markers were identified based on their contrast to the surrounding tissue. Coordinates of each marker were tracked through the loading cycle, and their relative movement was used to calculate Green strains in the principal directions. Specimens were tested over a large strain range using equibiaxial displacement-controlled protocols. First, 10 preconditioning cycles of 10% stretch, using a triangular waveform at 0.5 Hz, were applied. Subsequently, each specimen was repeatedly cycled up to 55% peak strain.

### **Data analysis**

Experimental stretch data was fitted to the two-dimensional Fung strain energy function. Leaflet stiffness was calculated by taking the first derivative of the stress-strain response at a fixed stress level of 277 kPa. This stress level represents physiologic stress in the native aortic root at 120 mmHg (data not shown). When specimens were not stretched to the desired stress level, stiffness was obtained from extrapolated curves based on the Fung strain energy function fitted to the raw data.

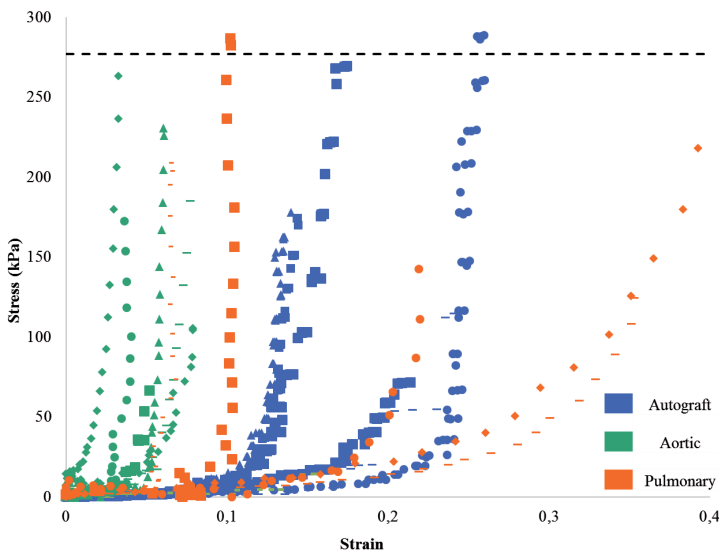
For statistical analysis, normal distribution of data was assessed using the Shapiro-Wilk test. Anisotropy, directional dependence of the material response to mechanical loading, was tested using paired-samples t-tests. A one-way ANOVA with Tukey's honestly significant

difference post-hoc test was performed to assess possible differences in leaflet stiffness between the three leaflet types. Reported values are quoted as mean  $\pm$  standard deviation. Statistical analyses were performed using IBM SPSS (version 23.0; IBM, Somers, NY, USA).

## Results

Pulmonary autograft leaflets were explanted in seven patients (86% male) at a mean age of  $40 \pm 12$  years. Indication for explantation, performed a mean of  $12 \pm 3$  years after the initial Ross operation, was a combination of autograft root aneurysm and autograft valve insufficiency in all patients. Native aortic leaflets were collected from five donor hearts, pulmonary leaflets from three.

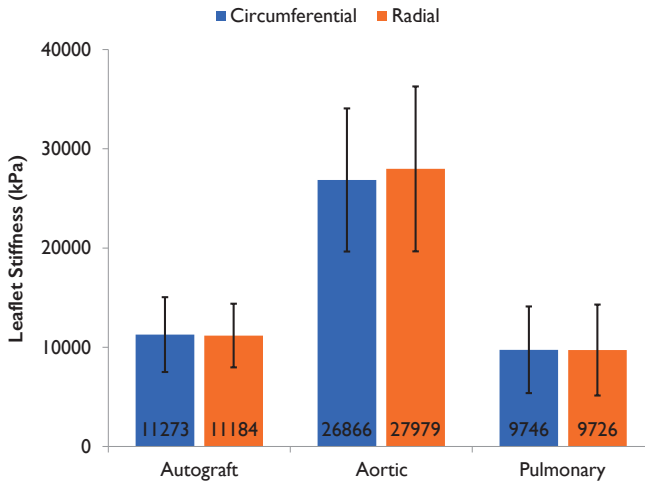
Raw stress-strain data obtained from equibiaxial stretch testing of autograft, native aortic and pulmonary leaflets is displayed as stress–strain plots in Figure 1. A non-linear stress-strain response was evident for all leaflet types in both circumferential and radial directions.



**FIGURE 1** Stress-strain plot of autograft, native aortic and pulmonary leaflets in the circumferential direction. When more than one leaflet was tested from a subject, results from each leaflet are displayed separately. Dashed line represents stress level at which leaflet stiffness was calculated.

The response to mechanical loading was isotropic in explanted pulmonary autograft leaflets ( $p=0.903$ ) as well as in native aortic ( $p=0.259$ ) and pulmonary leaflets ( $p=0.897$ ). The one-way ANOVA showed significant differences between the three leaflet types in

both circumferential and radial directions. As shown in Figure 2, mean stiffness of autograft leaflets was similar to native pulmonary leaflets in both the circumferential ( $p=0.908$ ) and radial direction ( $p=0.926$ ). Stiffness of native aortic leaflets was higher than that of autograft ( $p=0.001$ ) and native pulmonary ( $p=0.002$ ) leaflets in both directions.



**FIGURE 2** Overview of mean leaflet stiffness in both circumferential and radial direction. Error bars represent the standard deviation.

## Discussion

Leaflet stiffness was similar in explanted autograft and native pulmonary leaflets. Exposure to the high pressure environment of the systemic circulation for more than a decade did not induce biomechanical remodeling in autograft leaflets. Absence of biomechanical remodeling is remarkable given the histological changes in leaflets observed after the Ross operation [6]. Compared to native pulmonary leaflets, explanted autograft leaflets showed a significant increase in thickness. This increase was largely due to increased deposition of radially aligned collagen fibers on the ventricular aspect of the leaflets [6].

Semilunar valve leaflets consist of three distinct layers: the elastin-rich ventricularis, the spongiosa composed primarily of glycosaminoglycans and proteoglycans, and the fibrosa which is rich in collagen fibers [7]. Biomechanical properties of a leaflet are determined by the properties of each of the three leaflet layers combined [8, 9]. Interestingly, the ventricularis appears to contribute more than the fibrosa to the mechanical behavior in the radial direction [9]. In native aortic valve leaflets, both the fibrosa and ventricularis are considerably stiffer in the circumferential compared to the radial direction, resulting in marked anisotropy [8]. Increased deposition of radially aligned collagen fibers in the



ventricularis may explain the absence of anisotropy in autograft leaflets demonstrated in the present study.

An increase in leaflet thickness may intuitively be expected to result in an increase in leaflet stiffness. However, we calculated stiffness independent of leaflet thickness and geometry, to obtain intrinsic material properties. This approach allows the direct study of biomechanical remodeling at the tissue level. Native aortic leaflets were shown to be significantly stiffer than both native pulmonary and explanted autograft leaflets. This finding may be explained in part by a higher percentage of collagen fibers in native aortic leaflets. In addition to (relative) collagen quantity, differences in collagen biosynthesis and post-translational modification have an effect on intrinsic material properties [10].

Changes in intrinsic material properties do not directly reflect changes in the in vivo mechanical behavior of leaflets. Mechanical behavior is the result of a complex interplay between the intrinsic material properties, leaflet thickness and geometry, blood pressure and flow patterns. The combination of in vivo imaging and computer modelling are expected to offer more insights into the mechanical behavior of autograft leaflets [11].

Our study provides novel insights into the biomechanical characteristics of autograft leaflets explanted more than a decade after the initial Ross operation. Preservation of intrinsic material properties support the current practice of valve-sparing autograft root replacement or autograft leaflet repair when reoperation after the Ross operation becomes necessary. However, the implications of changes in both leaflet and root geometry after the reoperation remain unknown and subject of future study.

### Study Limitations

Autograft leaflet stiffness was studied in surgical specimens explanted for a combination of autograft root dilatation and valve insufficiency. Therefore, this study offers novel insights for surgeons who are confronted with patients requiring a reoperation after the Ross operation. However, our findings may not be extrapolated to patients in whom autograft function is not impaired.

We compared frozen autograft leaflets ( $-80^{\circ}\text{C}$ ) with fresh native aortic and pulmonary leaflets. A pilot study was conducted to study the possible influence of freezing on tissue material properties, which demonstrated similar elastic moduli in fresh and frozen ( $-80^{\circ}\text{C}$ ) human aortic wall specimens (data not shown). In addition, Schaar *et al.* demonstrated similar material properties for fresh and frozen ( $-80^{\circ}\text{C}$ ) human coronary, carotid and femoral arteries [12]. Although no data is available on the effect of freezing on semilunar valves, we feel confident our findings reflect absence of biomechanical remodeling in pulmonary autograft leaflets.

## **Conclusions**

After more than a decade in the systemic circulation, pulmonary autograft leaflets retained material properties similar to native pulmonary leaflets. Interestingly, stiffness in explanted pulmonary autograft leaflets was significantly lower than in native aortic leaflets. In our view, these findings do not preclude autograft valve preservation at reoperation after the Ross operation.

## **Acknowledgements**

We would like to thank Dr.A JVan den Bogaerdt from the Heart Valve Bank of the Erasmus University Medical Center (Rotterdam, The Netherlands) for his help and advice with both storage and handling of frozen pulmonary autograft tissue.

## References

1. Stelzer P. The Ross procedure: state of the art 2011. *Semin Thorac Cardiovasc Surg* 2011;23:115-123.
2. Elkins RC, Lane MM, McCue C. Pulmonary autograft reoperation: incidence and management. *Ann Thorac Surg*. 1996;62:450-455.
3. David TE. Aortic Valve Sparing Operations: A Review. *Korean J Thorac Cardiovasc Surg* 2012;45:205-212.
4. Luciani GB, Lucchese G, De Rita F, Puppini G, Faggian G, Mazzucco A. Reparative surgery of the pulmonary autograft: experience with Ross reoperations. *Eur J Cardiothorac Surg*. 2012;41:1309-1314; discussion 1314-1315.
5. Azadani AN, Chitsaz S, Matthews PB, Jaussaud N, Leung J, Wisneski A et al. Biomechanical comparison of human pulmonary and aortic roots. *Eur J Cardiothorac Surg*. 2012;41:1111-1116.
6. Mookhoek A, de Heer E, Bogers AJ, Takkenberg JJ, Schoof PH. Pulmonary autograft valve explants show typical degeneration. *J Thorac Cardiovasc Surg*. 2010;139:1416-1419.
7. Gross L, Kugel MA. Topographic anatomy and histology of the valves in the human heart. *Am J Pathol* 1931;7:445-473.
8. Vesely I, Noseworthy R. Micromechanics of the fibrosa and the ventricularis in aortic valve leaflets. *J Biomech*. 1992;25:101-113.
9. Stella JA, Sacks MS. On the biaxial mechanical properties of the layers of the aortic valve leaflet. *J Biomech Eng* 2007;129:757-766.
10. Wagsater D, Paloschi V, Hanemaaijer R et al. Impaired collagen biosynthesis and cross-linking in aorta of patients with bicuspid aortic valve. *Journal of the American Heart Association* 2013;2:e000034.
11. Soares AL, van Geemen D, van den Bogaardt AJ, et al. Mechanics of the pulmonary valve in the aortic position. *J Mech Behav Biomed Mater*. 2014;29:557-567.
12. Schaar JA, de Korte CL, Mastik F, van der Steen AF. Effect of temperature increase and freezing on intravascular elastography. *Ultrasonics*. 2002;40:879-881.



# Chapter 10

## **Mechanical characteristics of chronic autograft dissection after Ross procedure**

Aart Mookhoek, Heide Kuang, Elaine E. Tseng, Ad J. J. C. Bogers

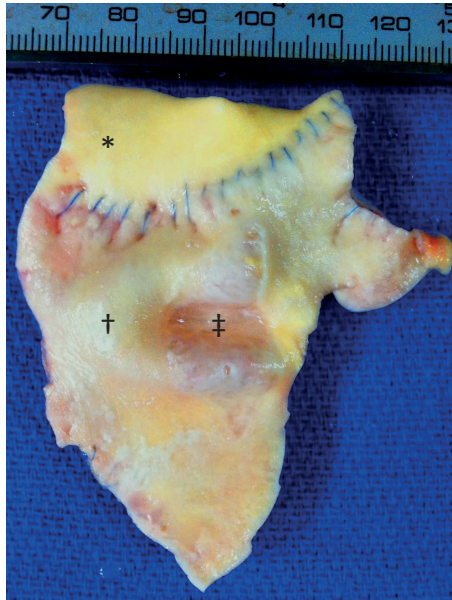
## **Abstract**

Progressive autograft root dilatation after a Ross procedure may lead to autograft dissection. In this case report, a 47-year-old man underwent autograft explantation 12 years after a Ross procedure. Inspection of the explanted autograft revealed a longitudinal intimal tear with medial denudation. Autograft material properties were analyzed by equibiaxial stretch testing and elastic modulus calculation. Interestingly, response to mechanical loading was different comparing dissected and non-dissected autograft sections. A seven-fold increase in wall stiffness was found in the dissected autograft section. Biomechanical characterization of the dissected and non-dissected vessel wall displays the versatility of the arterial remodeling response in autografts.

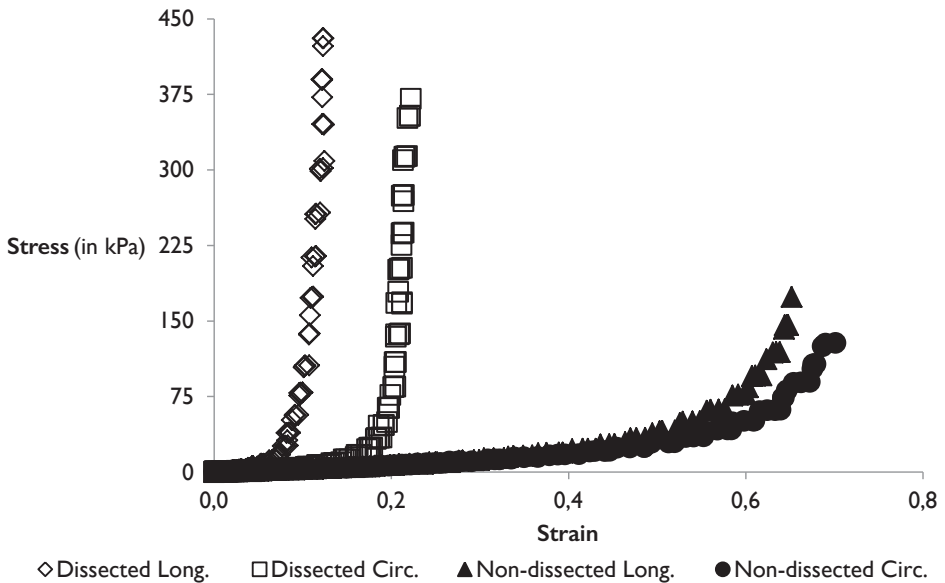
Young adults have several options when aortic valve replacement is indicated. One option, the Ross procedure, offers the prospect of an autologous valve with good hemodynamics and freedom from anticoagulation.<sup>1</sup> In a randomized controlled trial, the Ross procedure has been shown to result in a normal life expectancy.<sup>2</sup> A major drawback is progressive autograft root dilatation, especially after use of the full root technique. Progressive dilatation, often accompanied by aortic valve insufficiency, may necessitate reoperation. Moreover, focal dissection of the autograft root has been reported.<sup>3,4</sup> In this case report such a chronic autograft dissection is described with particular focus on autograft material properties.

A 47-year-old man with mildly impaired left ventricular function underwent elective reoperation on the pulmonary autograft twelve years after a Ross procedure with the full root technique. Indication for the initial Ross procedure was progressive aortic root dilatation and aortic valve insufficiency (AI) in the presence of a bicuspid aortic valve. Serial echocardiographic follow-up in the first seven years after the Ross procedure showed a gradually progressive diameter increase of the sinotubular junction (STJ) from 30 mm to 40 mm with trace AI. During the eighth post-operative year, echocardiography revealed a sudden increase in STJ diameter to 48 mm with grade I AI. While STJ diameter remained stable in subsequent years, AI increased to grade III in the 12<sup>th</sup> post-operative year. At echocardiographic assessment four months prior to reoperation, severe AI and dilatation of the pulmonary autograft (STJ 48 mm, distal to STJ 57 mm) was present in the absence of cardiac-related symptoms. At reoperation, the pulmonary autograft was replaced with a 27 mm St Jude composite mechanical aortic root prosthesis. The early post-operative period was complicated by two reinterventions for excess blood loss. After discharge, the patient remained in good clinical condition until he died suddenly 1.4 years later, 13.8 years after the initial Ross procedure. No autopsy was performed.

Inspection of the explant material revealed a longitudinal intimal tear near the distal anastomosis (Figure 1). The tear resulted in medial denudation over an area of roughly 3 × 1.5 cm. After explantation, tissue was frozen and stored. After thawing, we performed biomechanical characterization of the autograft tissue by equibiaxial stretch testing, as described previously.<sup>5</sup> The elastic modulus, a measure of wall stiffness calculated by taking the derivative of the stress-strain curve, was obtained at a fixed, literature-derived stress level.<sup>5</sup> We found that the response to mechanical loading was very different in the non-dissected compared to the dissected autograft section (Figure 2). Wall stiffness in the circumferential and longitudinal direction in the dissected autograft section (4655 and 4648 kPa, respectively) was increased more than seven-fold compared to the non-dissected autograft section (633 and 618 kPa, respectively).



**FIGURE 1** Photo of explanted autograft section  
 Scale in mm. Symbols indicate locations of sample collection. \* = Native aorta, † = Non-dissected autograft section, ‡ = Dissected autograft section.



**FIGURE 2** Stress-strain curve of the explanted autograft wall  
 Long. = Longitudinal, Circ. = Circumferential.



## Comment

In our patient, the dissecting lesion in the pulmonary autograft is thought to have occurred several years prior to explantation when STJ diameter suddenly increased from the seventh to the eighth post-operative year. The timing, absence of clinical symptoms and macroscopic characteristics were similar to previously published cases.<sup>3,4</sup>

Wall stiffness in the dissected autograft section was considerably higher than in the non-dissected section. Stiffness values in both sections were in the same order of magnitude as observed in freshly tested native aortic roots (906 to 1962 kPa).<sup>5</sup> The occurrence of dissection is associated with an increase in wall stiffness. However, the nature of our analysis does not allow us to determine whether increased wall stiffness was cause or consequence of the dissection event. If increased wall stiffness was consequence of the dissection, it may have prevented further dilatation at the STJ. At the same time, it may have increased the risk of a local rupture. The observations in our case study suggest that the pulmonary autograft root may show additional biomechanical remodeling at the site of dissection.

## References

1. Stelzer P. The Ross procedure: state of the art 2011. *Semin Thorac Cardiovasc Surg.* 2011;23:115-23.
2. El-Hamamsy I, Eryigit Z, Stevens LM, Sarang Z, George R, Clark L, et al. Long-term outcomes after autograft versus homograft aortic root replacement in adults with aortic valve disease: a randomised controlled trial. *Lancet.* 2010;376:524-31.
3. Klieverik LM, Takkenberg JJ, Elbers BC, Oei FB, van Herwerden LA, Bogers AJ. Dissection of a dilated autograft root. *J Thorac Cardiovasc Surg.* 2007;133:817-8.
4. Luciani GB, Favaro A, Viscardi F, Bertolini P, Mazzucco A. Valve-sparing root replacement for pulmonary autograft dissection late after the Ross operation. *J Thorac Cardiovasc Surg.* 2004;128:753-6.
5. Azadani AN, Chitsaz S, Matthews PB, Jaussaud N, Leung J, Wisneski A, et al. Biomechanical comparison of human pulmonary and aortic roots. *Eur J Cardiothorac Surg.* 2012;41:1111-6.

# Chapter II

## **General Discussion**



## Introduction

In this thesis, the aim was to provide a comprehensive overview of the consequences of long-term exposure of the native pulmonary root to the systemic circulation after the Ross operation. Three important questions were addressed. First, what is the outcome after the Ross operation when performed in neonates and infants? Second, is a valve-sparing reoperation a valuable approach in patients requiring reoperation after the Ross operation? Third, does pulmonary autograft remodelling result in an aortic phenotype? In this chapter, these questions are discussed in the wider context of aortic valve disease, clinical implications of our findings are explored and future perspectives are commented on.

### Ross Operation in Neonates and Infants

The incidence of early mortality after the Ross operation in neonates is high. In our cohort, almost half of the neonates died early after the Ross operation (**Chapter 2**). This disconcerting finding may be explained by the large proportion of neonates that were critically ill at the time of surgery and those who presented with multiple congenital heart defects requiring concomitant surgical intervention. However, several studies reporting on neonates with similar patient characteristics have shown lower incidences of early mortality [1-5]. Notably, our cohort includes patients from several centres that were among the first worldwide to receive a neonatal Ross operation [6]. The learning curve from those first operations in each of the included centres may have contributed to the relatively high incidence of early mortality in our cohort.

Coronary button reimplantation is a crucial step in the Ross operation. In neonates and infants, size difference between the native aortic and pulmonary root complicates assessment of where in the autograft to implant the coronary buttons. In **Chapter 2**, myocardial ischemia is reported in two patients who required a second pump run to change coronary button position. Several other cases of coronary flow obstruction have recently been reported in the literature, some with fatal consequences [1, 3]. Early mortality after the Ross operation in neonates and infants appeared, at least in some cases, to be associated with myocardial ischemia due to compromised coronary flow. Increased awareness of this specific problem is thought to further reduce early mortality in the near future.

In contrast to perioperative complication and early mortality rates, mid-term follow-up shows that the Ross operation offers neonates and infants good autograft valve function without the need for early reoperation, despite considerable somatic growth. Moreover, in **Chapter 3** we have shown a remarkable improvement over time of left ventricular function in neonates and infants after the Ross operation. Even in patients with severely impaired

preoperative left ventricular function, normal contractility may be restored over time. Improved left ventricular function may have contributed to the relatively low estimates of late mortality reported in the literature [3]. In our cohort, autograft root diameter Z-scores were high upon discharge from hospital after the Ross operation, reflecting the size difference between the native aortic and pulmonary root. However, an increase in Z-scores due to autograft root dilatation after first exposure to the pressures of the systemic circulation cannot be excluded. Interestingly, Z-scores remained stable in the first postoperative decade, supporting the observation of preserved autograft root growth potential [7]. Despite these changes in autograft root dimensions, autograft valve function in our cohort remained excellent. These results suggest that the Ross operation may effectively treat aortic valve disease in neonates and infants. However, follow-up duration in our cohort and those published previously is limited [1-5]. In addition, our results show a trend towards increased autograft root Z-scores in the second postoperative decade. If autograft root dilatation in neonates and infants progresses, reoperations on the pulmonary autograft may become necessary and limit autograft durability. Therefore, close follow-up is required to monitor both autograft dimensions and valve function.

High early mortality after the Ross operation has led one centre to advocate an alternative approach to surgical treatment of neonates with critical aortic stenosis [8]. They focus on postponement of the Ross operation to allow patients to grow and improve their clinical condition. However, the techniques that are suggested, such as leaflet repair, do not appear feasible in the majority of neonates [8]. In practice, the Ross operation continues to be the treatment of choice for aortic valve disease in these young patients. Therefore, in principle, every congenital heart surgery unit should offer the Ross operation. However, the operation is technically demanding and requires an experienced surgeon. One way to balance availability and expertise, is to limit both the number of congenital heart surgery units and the number of surgeons in each centre to perform the Ross operation.

### **Valve-sparing Reoperations after Ross Operation**

To prevent the complications associated with mechanical or bioprosthetic valve substitutes, valve-sparing techniques were developed to treat patients with native aortic valve regurgitation [9-11]. In patients with aortic valve stenosis (or regurgitation), the Ross operation is another surgical approach designed to avoid these complications [12]. Several advantages of the Ross operation may restore life expectancy of patients to the level of the general population [13, 14]. However, some patients may develop autograft regurgitation requiring reoperation after the Ross operation. In **Chapter 4**, our experience with valve-sparing reoperations after the Ross operation is presented. Valve-sparing autograft root replacement and autograft leaflet repair, in patients with autograft root dilatation or isolated autograft valve regurgitation respectively, preserved several

advantages of the Ross operation. Moreover, early morbidity and mortality associated with these reoperations are reassuringly low [15, 16].

In our cohort, high reintervention rates were shown early after the valve-sparing reoperation in patients who presented with isolated autograft valve regurgitation at the time of the reoperation. Detailed analysis of our cohort led to interesting insights into the mechanisms of failure after the Ross operation. Patients who were operated using the “root replacement” technique generally presented with autograft root dilatation relatively late after the initial Ross operation. A valve-sparing reoperation in these patients may be a durable approach as the diseased autograft wall is removed and restoration of normal root diameter eliminates autograft valve regurgitation by increasing coaptation surface. In contrast, patients who were operated using the “sub-coronary” or “inclusion cylinder” technique presented more often with isolated autograft leaflet prolapse relatively early after the initial Ross operation. Autograft leaflets in these patients may be diseased and, while leaflet repair may temporarily restore valve patency, the leaflets remain vulnerable to prolapse.

What causes leaflet prolapse after the Ross operation using the “sub-coronary” or “inclusion cylinder” technique? Why does leaflet prolapse not occur when using the “root replacement” technique? A case report describing leaflet prolapse after valve-sparing autograft root replacement in a patient who received the Ross operation with the “root replacement” technique reveals a possible answer (**Chapter 5**). Prolapse of two leaflets, thin and pliable at the time of the valve-sparing reoperation, occurred in the second postoperative year which may suggest an underlying technical complication. The complex geometry of the native aortic root may be crucial for valve function. The Ross operation using the “sub-coronary” or “inclusion cylinder” technique may change root geometry and thereby induce remodelling of autograft leaflets leading to prolapse. To test this hypothesis, one approach is to compare the histological characteristics of explanted autograft leaflets following the three different Ross operation techniques. In addition, biomechanical analysis and computer modelling may identify the factors that induce prolapse. These two approaches may offer surgeons valuable information for development of novel surgical strategies to prevent prolapse.

The choice of surgical treatment in patients who require a reoperation after the Ross operation should not be based solely on reoperation statistics. A patient may for instance accept a relatively high chance of an early reoperation when complications of a mechanical valve prosthesis can be avoided. Expected quality of life after surgery is important when different surgical strategies are possible, especially in young adults. In patients who received native aortic valve replacement, results have shown superior quality of life at long-term follow-up after implantation of a biological valve substitute compared to a mechanical valve substitute [17]. In addition, quality of life in patients who received aortic valve repair

or aortic valve replacement with a pulmonary autograft was superior compared to aortic valve replacement with a mechanical valve substitute [18]. Future studies will need to address quality of life following a reoperation after the Ross operation.

The results presented in **Chapter 4** should be shared by clinicians with their patients and will allow shared decision making by an informed patient and the clinician. However, guidelines will continue to be important in this setting. Based on our results, the guidelines should include that a valve-sparing reoperation after the Ross operation in patients that present with isolated autograft regurgitation should not be considered.

### **Autograft Remodelling**

Pulmonary autograft leaflets remained viable after transplantation into the systemic circulation (**Chapter 6**). Early after the Ross operation, an increase in the number of activated myofibroblasts and the activity of enzymes involved in matrix remodelling has been demonstrated in pulmonary autograft leaflets compared to native aortic and pulmonary leaflets [19]. Interestingly, these and other signs of stress on both the cellular and tissue level persist in explanted autografts to a certain degree for more than a decade after the Ross operation. The remodelling response, which increases leaflet thickness by deposition of collagen, fails to induce tissue homeostasis. This raises concern for the long-term durability of the autograft valve.

Remodelling of pulmonary autograft leaflets does not produce a phenotype similar to that of native aortic leaflets. Progressive autograft root dilatation may have prevented leaflet remodelling into an aortic phenotype. Native pulmonary leaflets have been shown to display reduced radial extensibility at systemic pressures, which may reduce coaptation surface [20]. In addition, root dilatation also decreases the coaptation surface and may have been the driving force for deposition of radially aligned collagen fibres on the ventricular aspect of the leaflets. However, similar histological changes have been observed in autograft leaflets obtained at heart transplantation or autopsy from patients without autograft root dilation [19]. Therefore, histological changes may simply reflect the limited range of remodelling responses available to adult pulmonary valve leaflets when exposed to the high pressure environment of the systemic circulation. Insights from future studies on the forces driving the remodelling response after the Ross operation may offer surgeons the information necessary to improve surgical technique. In addition, insights into the range of remodelling responses of autograft leaflets and their driving forces may offer scientists stepping stones towards development of tissue-engineered valves. One interesting avenue of research will be to examine native aortic valve leaflets explanted from patients with aortic root dilatation to determine whether histological changes similar to those observed in explanted pulmonary autograft leaflets can be observed.



Interestingly, the remodelling response did not affect leaflet stiffness, despite deposition of radially aligned collagen fibres in the ventricularis (**Chapter 9**). Biomechanical properties of a leaflet are determined by the properties of each of the three leaflet layers combined [21]. In native aortic valve leaflets, both the fibrosa and ventricularis are considerably stiffer in the circumferential compared to the radial direction, resulting in marked anisotropy [22]. The increase in radially aligned collagen fibres may explain the lack of anisotropy in autograft leaflets demonstrated in our study. However, based on the increased collagen deposition, overall leaflet stiffness was predicted to increase. Future histological and biomechanical analyses may offer an explanation for our apparently conflicting findings.

Wall stiffness of pulmonary autograft roots, explanted for root aneurysm on average more than a decade after the Ross operation, was decreased (**Chapter 7 and 8**). This decrease may have contributed to progressive autograft root dilatation. Several surgeons performing the Ross operation with the “full root” technique have reported autograft root dilatation immediately after removal of the aortic cross-clamp, a finding corroborated by *in vitro* studies [23]. The sudden increase in wall stress upon exposure to the high pressure environment of the systemic circulation may have resulted in both root dilatation and fragmentation (and eventual loss) of elastin fibres in the media [24]. These hemodynamic changes will have resulted in a shift on the stress-strain curve, whereby further dilatation was prevented by residual wall stiffness. Over time, increased collagen deposition in the ventricularis may have decreased wall stress and thereby contributed to a reduction of autograft root dissection and rupture risk. This combination of histological changes, decreased elastin and increased collagen, was expected to increase wall stiffness.

The quantity of extracellular matrix proteins, such as collagen and elastin fibres, is not the only factor determining tissue biomechanical properties. Impaired collagen biosynthesis and post-translational modifications may also contribute to aneurysm formation, as shown in the native aortic root of patients with a bicuspid aortic valve [25]. Future visualisation of the microarchitecture of collagen fibres may demonstrate whether similar changes explain the counterintuitive observation of decreased wall stiffness in pulmonary autograft wall specimens. A case report of a patient with clinically silent autograft dissection demonstrated that the remodelling response may also increase wall stiffness in pulmonary autografts (**Chapter 10**). While the occurrence of dissection was associated with an increase in wall stiffness, it was not possible to differentiate between cause and consequence. Dissection and subsequent increased wall stress through autograft root dilatation may have initiated an increase in wall stiffness to prevent progressive dilatation.

Given the differences in reoperation rates after a Ross operation with the “full root” technique between centres, surgical technique or post-operative management are expected to influence root remodelling [26]. Therefore, it is important to understand the remodelling response underlying a decrease in autograft wall stiffness. One approach

may be to study vascular remodelling in patients with pulmonary arterial hypertension. Interestingly, several centres have recently reported increased stiffness of the proximal pulmonary artery in patients with pulmonary arterial hypertension [27, 28]. Despite a more gradual increase in pressure, the remodelling response in an animal model of neonatal pulmonary arterial hypertension gave rise to similar histological changes to those observed in explanted pulmonary autografts [29]. Interestingly, wall stiffness in these animals was increased compared to the native pulmonary root.

### The Debate Revisited

Recent guidelines on management of valvular heart disease do not recommend use of the Ross operation in adults [30, 31]. The 2014 American guidelines state that the Ross operation should only be considered when performed by an experienced surgeon in young adults in whom oral anticoagulation use is not desirable [30]. In the 2012 European guidelines, the Ross operation was not even included in the guideline statements [31]. Interestingly, both guidelines refer to and criticize the only randomized controlled trial on the Ross operation [13].

In the single centre, single surgeon randomized controlled trial patients were randomized to receive the Ross operation or aortic valve replacement using a homograft. Long-term survival was similar in patients who received the Ross operation compared to an age-matched and sex-matched general population. Despite absence of strict in- and exclusion criteria, the cohort consisted primarily of young and relatively healthy patients with limited comorbidity. These patient characteristics may explain the excellent survival after the Ross operation. Survival in patients who received a homograft was inferior. However, use of homografts in the aortic position is rare nowadays with most young adults receiving a mechanical valve prosthesis. Performing a randomized controlled trial comparing the Ross operation with implantation of a mechanical valve prosthesis in a more diverse patient population will prove difficult. Improved patient education and introduction of shared decision making tools have led to increased patient awareness of the risks and benefits associated with the different prosthesis types [32]. Therefore, it may not be appropriate from an ethical point of view to ask patients, especially young adults, to undergo randomisation. In this light, it is even more remarkable that the American guidelines disregard the findings from the randomized controlled trial on the basis that these have not been replicated in other randomized controlled trials.

Current guidelines reflect the scientific climate; the majority of the cardiovascular community no longer considers the Ross operation when aortic valve replacement in adults is discussed [33]. Notably, in adults with congenital heart disease, who are often cared for by the same team responsible for paediatric patients, the Ross operation is still considered a valuable treatment option. The current climate of ranking surgeons and

surgical centres based on early outcome may dissuade cardiothoracic surgeons to learn this complex operation [34]. In addition, a cynic might argue that the decline in interest may be due to emergence of techniques that are more attractive commercially, such as transcatheter aortic valve implantation, or simply more novel, such as valve-sparing aortic root replacement. However, there are genuine concerns regarding the Ross operation that warrant discussion: the increasing hazard of reoperation on the pulmonary autograft in the second postoperative decade, technical complexity and the creation of double valve disease.

In the setting of a single centre single surgeon study, freedom from reoperation on the pulmonary autograft after the Ross operation using the “full root” technique was almost complete after a decade [13]. However, a large multicentre prospective cohort study recently reported substantially higher rates of reoperation [14]. The difference in reoperation rates between these two studies may to a certain extent reflect technical complexity. Low-volume centres contributing to registries will have less experience and expertise with the Ross operation and the relatively high reoperation rates from these centres may reflect institutional learning curves. This statement is a challenge to the community of surgeons with expertise on the Ross operation in adults. Mentorship of committed and talented young surgeons may improve long-term outcome after the Ross operation and perhaps allow more patients to benefit from this unique approach to aortic valve replacement.

The challenge now for the proponents of the Ross operation is to shift the debate from a focus on the negative (i.e. reoperation rates) to include discussion of the positive. Aicher *et al.* have shown a superior quality of life after the Ross operation compared with conventional mechanical valve replacement [18]. The Ross operation may offer a window for young adults to lead an active lifestyle and start a family at the cost of a possible reintervention later in life. The current guidelines on aortic valve replacement should be challenged by demanding a more evidence-based and balanced discussion of the Ross operation.

## Conclusions

The scientific findings presented in this thesis can be summarized in the form of several conclusions, which may impact clinical decision making and drive future research.

### *Ross operation in neonates and infants*

1. Coronary reimplantation is a critical step in an otherwise complex operation.
2. High early mortality in neonates is contrasted with remarkable improvement in left ventricular function of patients who survived the early postoperative period.

3. Autograft valve function remains excellent in the first decade despite, or perhaps thanks to, increasing autograft root dimensions.
4. Close echocardiographic follow-up of patients is warranted as findings suggest autograft root dilatation may occur in the second postoperative decade.

#### ***Valve-sparing reoperations after the Ross operation***

5. This approach is associated with limited early and late morbidity as well as mortality.
6. Reintervention after valve-sparing reoperation are frequent in patients who presented with isolated autograft valve regurgitation (i.e. without autograft root dilatation) at the time of reoperation.

#### ***Pulmonary autograft root remodelling***

7. Autograft leaflets show architectural changes that suggest changes in the mechanical forces acting upon the leaflets drive the remodelling response.
8. Autograft leaflet stiffness is similar to native pulmonary leaflets.
9. Wall stiffness in explanted autografts is decreased despite increased collagen deposition.

#### **The Future**

Answering the questions raised by the work presented in this thesis may prove challenging. In adults, the Ross operation is performed in a select patient population in a limited number of centres worldwide. In children, especially in neonates and infants, use of the Ross operation is more widespread. However, the relatively low incidence of congenital aortic stenosis requiring surgical intervention contributes to the problem of limited patient numbers available for scientific study. Introduction of a single, prospective global Ross registry would increase statistical power of follow-up studies and may act as a stepping stone towards formation of a global Ross community. In addition, uniform data reporting will result in more reliable data.

In parallel to strategies designed to increase data availability, ways to increase efficiency of data use should be explored further. This thesis is the result of a multidisciplinary approach to addressing questions regarding the Ross operation. Bringing together surgeons, cardiologists, epidemiologists, statisticians, pathologists and biomedical engineers greatly increases the speed at which the research field moves forward. This approach may also allow use of the same dataset or tissue sample for the study of multiple questions.

Using the biomechanical data presented in this thesis along with high-resolution CT imaging, three dimensional computer models of the autograft root can be constructed. Model simulations may predict the behaviour of the autograft root at different blood pressures and after different surgical interventions. Results from these simulations could

guide surgical decision making and innovation of surgical technique, and generate new hypotheses concerning pulmonary autograft remodelling. This avenue of research may ultimately lead to a better understanding of both autograft and native aortic root dilatation and increase power of existing prediction models designed to identify the optimal timing for intervention.

In this thesis, the use of complex statistical modelling to study the evolution over time of several important echocardiographic variables in patients who received the Ross operation as neonate or infant is explored. Novel statistical approaches are expected to reveal more information than ever before from datasets. However, clinicians should proceed with caution and be in the company of an expert when performing complex statistics. To ensure quick and correct implementation of these approaches into the clinical practice, it is crucial to educate clinicians on how to interpret the data obtained from complex statistical approaches. In turn, the ability of clinicians to explain scientific results to a patient is a prerequisite to allow the informed patient to participate in shared decision making.

The 1960's represent the pioneering era of aortic valve replacement. In the decades following this era, evolution of the techniques and approaches developed in the 1960's have greatly improved life expectancy and quality of life of patients with aortic valve disease. The pioneering spirit of the early days of aortic valve surgery appears to have been rekindled recently. Novel approaches such as transcatheter aortic valve implantation and valve-sparing aortic root implantation have revolutionized the field of aortic valve replacement. Moreover, results from studies on experimental techniques such as personalised external aortic root show promising results. Although these novel approaches may not offer patients a valve substitute for life, they may be integrated into a strategy for life with aortic valve disease. It can be assumed that the pioneering spirit shown by clinicians and scientists will continue to improve the lives of patients with aortic valve disease in the 21<sup>st</sup> century.

## References

1. Elder RW, Quaegebeur JM, Bacha EA, Chen JM, Bourlon F, Williams IA. Outcomes of the infant Ross procedure for congenital aortic stenosis followed into adolescence. *J Thorac Cardiovasc Surg.* 2013;145(6):1504-1511.
2. Lo Rito M, Davies B, Brawn WJ, Jones TJ, Khan N, Stickley J, et al. Comparison of the Ross/Ross-Konno aortic root in children before and after the age of 18 months. *Eur J Cardiothorac Surg.* 2014;46(3):450-457; discussion 457.
3. Maeda K, Rizal RE, Lavrsen M, Malhotra SP, Akram SA, Davies R, et al. Midterm results of the modified Ross/Konno procedure in neonates and infants. *Ann Thorac Surg.* 2012;94(1):156-162; discussion 162-153.
4. Shinkawa T, Bove EL, Hirsch JC, Devaney EJ, Ohye RG. Intermediate-term results of the Ross procedure in neonates and infants. *Ann Thorac Surg.* 2010;89(6):1827-1832; discussion 1832.
5. Woods RK, Pasquali SK, Jacobs ML, Austin EH, Jacobs JP, Krolikowski M, et al. Aortic valve replacement in neonates and infants: an analysis of the Society of Thoracic Surgeons Congenital Heart Surgery Database. *J Thorac Cardiovasc Surg.* 2012;144(5):1084-1089.
6. Ziemer G, Beierlein W, Salehi-Gilani S. Aortic root remodeling 13,5 years after neonatal Ross operation. *Thorac Cardiovasc Surg.* 2004;52(suppl.1):S46-47.
7. Elkins RC, Knott-Craig CJ, Ward KE, McCue C, Lane MM. Pulmonary autograft in children: realized growth potential. *Ann Thorac Surg.* 1994;57(6):1387-1393; discussion 1393-1384.
8. Konstantinov IE. Is Ross operation in neonates and infants justified? Aortic valve repair may postpone Ross operation. *Eur J Cardiothorac Surg.* 2015;47(5):e170-171.
9. David TE, Feindel CM. An aortic valve-sparing operation for patients with aortic incompetence and aneurysm of the ascending aorta. *J Thorac Cardiovasc Surg.* 1992;103(4):617-621; discussion 622.
10. Leyh RG, Schmidtke C, Bartels C, Sievers HH. Valve-sparing aortic root replacement (remodeling/reimplantation) in acute type A dissection. *Ann Thorac Surg.* 2000;70(1):21-24.
11. Yacoub MH, Gehle P, Chandrasekaran V, Birks EJ, Child A, Radley-Smith R. Late results of a valve-preserving operation in patients with aneurysms of the ascending aorta and root. *J Thorac Cardiovasc Surg.* 1998;115(5):1080-1090.
12. Ross DN. Replacement of aortic and mitral valves with a pulmonary autograft. *Lancet.* 1967;2(7523):956-958.
13. El-Hamamsy I, Eryigit Z, Stevens LM, Sarang Z, George R, Clark L, et al. Long-term outcomes after autograft versus homograft aortic root replacement in adults with aortic valve disease: a randomised controlled trial. *Lancet.* 2010;376(9740):524-531.
14. Sievers HH, Stierle U, Charitos EI, Takkenberg JJ, Horer J, Lange R, et al. A multicentre evaluation of the autograft procedure for young patients undergoing aortic valve replacement: update on the German Ross Registry. *Eur J Cardiothorac Surg.* 2015;49(1):212-218.
15. de Kerchove L, Boodhwani M, Etienne PY, Poncelet A, Glineur D, Noirhomme P, et al. Preservation of the pulmonary autograft after failure of the Ross procedure. *Eur J Cardiothorac Surg.* 2010;38(3):326-332.
16. Luciani GB, Lucchese G, De Rita F, Puppini G, Faggian G, Mazzucco A. Reparative surgery of the pulmonary autograft: experience with Ross reoperations. *Eur J Cardiothorac Surg.* 2012;41(6):1309-1314; discussion 1314-1305.
17. Ruel M, Kulik A, Lam BK, Rubens FD, Hendry PJ, Masters RG, et al. Long-term outcomes of valve replacement with modern prostheses in young adults. *Eur J Cardiothorac Surg.* 2005;27(3):425-433; discussion 433.

18. Aicher D, Holz A, Feldner S, Kollner V, Schafers HJ. Quality of life after aortic valve surgery: replacement versus reconstruction. *J Thorac Cardiovasc Surg.* 2011;142(2):e19-24.
19. Rabkin-Aikawa E, Aikawa M, Farber M, Kratz JR, Garcia-Cardena G, Kouchoukos NT, et al. Clinical pulmonary autograft valves: pathologic evidence of adaptive remodeling in the aortic site. *J Thorac Cardiovasc Surg.* 2004;128(4):552-561.
20. Soares AL, van Geemen D, van den Bogaerdt AJ, Oomens CW, Bouten CV, Baaijens FP. Mechanics of the pulmonary valve in the aortic position. *J Mech Behav Biomed Mater.* 2014;29:557-567.
21. Billiar KL, Sacks MS. Biaxial mechanical properties of the natural and glutaraldehyde treated aortic valve cusp--Part I: Experimental results. *J Biomech Eng.* 2000;122(1):23-30.
22. Vesely I, Noseworthy R. Micromechanics of the fibrosa and the ventricularis in aortic valve leaflets. *J Biomech.* 1992;25(1):101-113.
23. Okazaki Y, Takarabe K, Furukawa K, Higuchi S, Rikitake K, Ohtsubo S, et al. Distensibility of the pulmonary autograft under systemic pressure. *J Heart Valve Dis.* 2002;11(2):231-235.
24. Schoof PH, Takkenberg JJ, van Suylen RJ, Zondervan PE, Hazekamp MG, Dion RA, et al. Degeneration of the pulmonary autograft: an explant study. *J Thorac Cardiovasc Surg.* 2006;132(6):1426-1432.
25. Wagsater D, Paloschi V, Hanemaaijer R, Hultenby K, Bank RA, Franco-Cereceda A, et al. Impaired collagen biosynthesis and cross-linking in aorta of patients with bicuspid aortic valve. *J Am Heart Assoc.* 2013;2(1):e000034.
26. Takkenberg JJ, Klieverik LM, Schoof PH, van Suylen RJ, van Herwerden LA, Zondervan PE, et al. The Ross procedure: a systematic review and meta-analysis. *Circulation.* 2009;119(2):222-228.
27. Lau EM, Iyer N, Ilsar R, Bailey BP, Adams MR, Celermajer DS. Abnormal pulmonary artery stiffness in pulmonary arterial hypertension: in vivo study with intravascular ultrasound. *PLoS One.* 2012;7(3):e33331.
28. Shen JY, Cai ZY, Sun LY, Yang CD, He B. The Application of Intravascular Ultrasound to Evaluate Pulmonary Vascular Properties and Mortality in Patients with Pulmonary Arterial Hypertension. *J Am Soc Echocardiogr.* 2016;29(2):103-111.
29. Lammers SR, Kao PH, Qi HJ, Hunter K, Lanning C, Albietsz J, et al. Changes in the structure-function relationship of elastin and its impact on the proximal pulmonary arterial mechanics of hypertensive calves. *Am J Physiol Heart Circ Physiol.* 2008;295(4):H1451-1459.
30. Nishimura RA, Otto CM, Bonow RO, Carabello BA, Erwin JP, 3rd, Guyton RA, et al. 2014 AHA/ACC Guideline for the Management of Patients With Valvular Heart Disease: a report of the American College of Cardiology/American Heart Association Task Force on Practice Guidelines. *Circulation.* 2014;129(23):e521-643.
31. Vahanian A, Alfieri O, Andreotti F, Antunes MJ, Baron-Esquivias G, Baumgartner H, et al. Guidelines on the management of valvular heart disease (version 2012): the Joint Task Force on the Management of Valvular Heart Disease of the European Society of Cardiology (ESC) and the European Association for Cardio-Thoracic Surgery (EACTS). *Eur J Cardiothorac Surg.* 2012;42(4):S1-44.
32. Korteland NM, Bras FJ, van Hout FM, Kluijn J, Klautz RJ, Bogers AJ, et al. Prosthetic aortic valve selection: current patient experience, preferences and knowledge. *Open Heart.* 2015;2(1):e000237.
33. Yacoub MH, El-Hamamsy I, Sievers HH, Carabello BA, Bonow RO, Stelzer P, et al. Under-use of the Ross operation--a lost opportunity. *Lancet.* 2014;384(9943):559-560.
34. Treasure T, Hasan A, Yacoub M. Is there a risk in avoiding risk for younger patients with aortic valve disease? *BMJ.* 2011;342:d2466.





# Chapter 12

**Summary / Samenvatting / Portfolio / Publications**



## Summary

**Chapter 1**, the general introduction, describes the prevalence of aortic valve disease and the clinical consequences of aortic valve regurgitation and stenosis. Furthermore, it describes the evolution of surgical interventions to replace the aortic valve with a focus on the Ross operation. In this operation, the aortic valve is replaced by the pulmonary of the same patient, a donor valve replaces the pulmonary valve. Chapter 1 describes the debate on use of the Ross operation in adults. After identifying clinically relevant unanswered questions, the goals of the research are discussed.

**Chapters 2 and 3** describe the experience with the Ross operation in neonates and infants with a focus on the post-operative course.

**Chapter 2** describes the combined clinical experience of six centres from The Netherlands and Germany with the Ross operation in neonates and infants. The median age of the 76 patients was 85 days at the time of the operation. Early mortality, in 13 patients, occurred relatively more often in neonates and patients with congenital aortic arch defects. Function of the pulmonary autograft at the time of last follow-up was generally good and a reoperation was necessary in only 1 patient. Although the Ross operation in neonates and infants is a high-risk operation, it offers patients a durable aortic valve replacement.

**Chapter 3** studies the evolution of echocardiographic variables of patients who underwent the Ross operation as neonate or infant in The Netherlands and survived the peri-operative period. The median follow-up duration of the 42 patients was 3.2 years. The left ventricular function improved significantly over time with an increase of fractional shortening of 26% pre-operatively to 34% at the time of last follow-up. Dilatation of the pulmonary autograft root was only seen at the level of the sinotubular junction. The function of the autograft valve remained unchanged over time. The Ross operation offer neonates and infants a vital improvement of left ventricular function. Moreover, growth of the autograft root is mainly parallel to the growth of the patient with preservation of valve function.

**Chapters 4 and 5** describe the experience with valve-sparing reoperations after the Ross operation.

**Chapter 4** describes the combined experience of six European centres with valve-sparing reoperations after the Ross operation in 86 patients. During a median follow-up of 4.3 years 4 patients died, one of whom early after the reoperation. A reintervention after the valve-sparing reoperation was necessary in 15 patients, mainly due to prolapse or retraction of the valve leaflets. The reintervention hazard was higher in patients with isolated or severe autograft regurgitation at the time of the valve-sparing reoperation. Valve

function at last follow-up was predominantly good in the patients without reintervention. Valve-sparing reoperations after the Ross operation are characterized by a low operative risk and acceptable degree of reintervention. In patients with isolated or severe autograft regurgitation as indication for the reoperation surgical alternatives should be considered.

**Chapter 5** describes the case of a patient with a reintervention after valve-sparing reoperation. Ten years after the Ross operation a 22-year old woman underwent a valve-sparing autograft root replacement because of severe autograft root dilation and valve regurgitation. Two years later she presented with severe valve regurgitation based on prolapse of two leaflets. Histological analysis of the explanted leaflets showed changes which may be associated with prolapse of the leaflets.

**Chapter 6** discusses the histological characteristics of autograft leaflets and compares these with normal aortic and pulmonary valves. In 11 patients, the autograft valve was explanted on average 11.2 years after the Ross operation because of autograft root dilatation and valve regurgitation. The valve leaflets of the autograft were significantly thicker than the pulmonary valve (137 versus 37  $\mu\text{m}$ ). Increase of leaflet thickness was caused by deposition of radially aligned collagen fibres in the ventricularis. Matrix remodelling in the autograft valve is, based on the presence of myofibroblasts and the activity of matrix metalloproteinases, more than ten years after the Ross operation still an active process.

**Chapters 7 to 10** discuss the biomechanical characteristics of the explanted pulmonary autograft

**Chapter 7** compares wall stiffness of the autograft with the normal pulmonary root. Square vessel wall specimens of 10 patients were stretched using biaxial stretch testing. Stiffness was calculated at 8 and 25 mmHg. The autograft wall was significantly less stiff than the normal pulmonary root at 8 (134 versus 175 kPa) and 25 mmHg (369 versus 919 kPa). This finding may explain the occurrence of progressive autograft root dilatation.

**Chapter 8** compares wall stiffness of the autograft with the normal aorta. Square vessel wall specimens of 10 patients were stretched using biaxial stretch testing. Stiffness was calculated at 80, 120 and 200 mmHg. The autograft wall was significantly less stiff than the normal aortic root at 80 (1527 versus 2993 kPa), 120 (2537 versus 4931 kPa) and 200 mmHg (4788 versus 9207 kPa). The process of remodelling after the Ross operation did not provide the autograft with the biomechanical characteristics of the normal aorta.

**Chapter 9** compares the stiffness of the autograft valve with the normal aortic and pulmonary valve. Valve leaflets of seven patients were explanted on average 12 years after the Ross operation. Stiffness of the valve leaflets was determined using biaxial stretch testing and compared with normal aortic and pulmonary valves. Although stiffness in autograft leaflets was lower than in normal aortic leaflets (11273 versus 26866 kPa), there

was no difference with normal pulmonary leaflets (9746 kPa). Despite changes in the geometry and histology of the autograft root, no evidence for biomechanical remodelling was observed.

**Chapter 10** describes the case of a patient with an incidentally discovered dissection of the autograft. A 47-year old man underwent a reoperation 12 years after the Ross operation because of autograft root dilatation and valve regurgitation. After the explantation, a longitudinal tear in the intima of the autograft was observed. A biaxial stretch test showed that wall stiffness at the site of dissection was much higher than in the surrounding area. This case illustrates the versatility of the remodelling response in the autograft root.

**Chapter 11**, the general discussion, discusses three prominent questions regarding the Ross operation which this thesis has tried to answer. First, what is the outcome of the Ross operation in neonates and infants? Second, what is the value of valve-sparing reoperations after the Ross operation? Third, does remodelling cause the pulmonary autograft to adopt an aortic phenotype? Moreover, Chapter 11 contributes to the debate on the use of the Ross operation in adults and discusses the answers to the three questions this thesis has produced. The future of research on the Ross operation is seen with confidence.



## Nederlandse Samenvatting

**Hoofdstuk 1**, de algemene introductie, bespreekt de prevalentie van aortaklepziekten en de klinische gevolgen van aortaklepinsufficiëntie en stenose. Verder beschrijft het de evolutie van chirurgische interventies om de aortaklep te vervangen, met nadruk op de Ross operatie. In deze operatie wordt de aortaklep vervangen door de pulmonaalklep van dezelfde patiënt, een donorklep vervangt de pulmonaalklep. Hoofdstuk 1 bespreekt het debat over gebruik van de Ross operatie in volwassenen. Na inventarisatie van klinisch relevante onbeantwoorde vragen worden de doelen van het onderzoek besproken.

**Hoofdstukken 2 en 3** bespreken de ervaring met de Ross operatie in neonaten en zuigelingen met nadruk op het postoperatieve beloop.

**Hoofdstuk 2** beschrijft de verzamelde klinische ervaring van zes centra uit Nederland en Duitsland met de Ross operatie in neonaten en zuigelingen. De mediane leeftijd van de 76 patiënten was 85 dagen ten tijde van de operatie. Vroege sterfte, in 13 patiënten, trad relatief vaker op in neonaten en patiënten met congenitale aortaboog defecten. Functie van de pulmonale autograft ten tijde van het laatste klinische contact was overwegend goed en in slechts 1 patiënt was een reoperatie noodzakelijk. Hoewel de Ross operatie in neonaten en zuigelingen een hoog-risico operatie is, biedt het patiënten een duurzame aortaklep vervanging.

**Hoofdstuk 3** bestudeert de evolutie van echografische variabelen van patiënten die als neonaat of zuigeling de Ross operatie in Nederland hebben ondergaan en de perioperatieve periode hebben overleefd. De mediane follow-up duur van de 42 patiënten was 3,2 jaar. De linkerventrikelfunctie verbeterde significant over de tijd met een toename van fractionele verkorting van 26% preoperatief tot 34% ten tijde van het laatste klinische contact. Dilatatie van de autograftwortel werd alleen gezien ter hoogte van de sinotubulaire overgang. De functie van de autograftklep bleef onveranderd over de tijd. De Ross operatie biedt neonaten en zuigelingen een cruciale verbetering van de linkerventrikelfunctie. Verder is groei van de autograftwortel overwegend parallel aan de groei van de patiënt met behoud van klepfunctie.

**Hoofdstukken 4 en 5** beschrijven de ervaring met klepsparende reoperaties na de Ross operatie.

**Hoofdstuk 4** bespreekt de verzamelde ervaring van zes Europese centra met klepsparende reoperaties na de Ross operatie in 86 patiënten. Gedurende een mediane follow-up van 4,3 jaar overleden 4 patiënten, waarvan 1 kort na de reoperatie. Een reinterventie na de klepsparende reoperatie was noodzakelijk in 15 patiënten, overwegend door prolaps of retractie van de klepbladen. De reinterventie hazard was hoger in patiënten met geïsoleerde of ernstige autograft insufficiëntie ten tijde van de klepsparende

reoperatie. Klepfunctie ten tijde van het laatste klinische contact was overwegend goed in de patiënten zonder reïnterventie. Klepsparende reoperaties na de Ross operatie worden gekenmerkt door een laag operatief risico en acceptabele mate van reïnterventie. In patiënten met geïsoleerde of ernstige autograft insufficiëntie als indicatie voor de reoperatie moet nagedacht worden over chirurgische alternatieven.

**Hoofdstuk 5** beschrijft de casus van een patiënt met een reïnterventie na klepsparende reoperatie. Tien jaar na de Ross operatie onderging een 22-jarige vrouw een klepsparende autograftwortel vervanging vanwege ernstige autograftwortel dilatatie en klepinsufficiëntie. Twee jaar later presenteerde zij zich met ernstige klepinsufficiëntie op basis van prolaps van twee klepbladen. Histologische analyse van de geëxplanteerde klepbladen toonde veranderingen die mogelijk geassocieerd zijn met prolaps van de klepbladen.

**Hoofdstuk 6** bespreekt de histologische kenmerken van autograftkleppen en vergelijkt deze met normale aorta- en pulmonaalkleppen. In 11 patiënten werd de autograftklep gemiddeld 11,2 jaar na de Ross operatie geëxplanteerd vanwege autograft worteldilatatie en klepinsufficiëntie. De klepbladen van de autograft waren significant dikker dan de pulmonaalklep (137 versus 37  $\mu\text{m}$ ). Toename van klepdikte werd veroorzaakt door depositie van radiaal georiënteerde collageenvezels in de ventricularis. Matrix remodellering in de autograftklep is, gezien de aanwezigheid van myofibroblasten en activiteit van matrix-metalloproteïnasen, meer dan 10 jaar na de Ross operatie nog steeds een actief proces.

**Hoofdstukken 7 tot en met 10** bespreken de biomechanische eigenschappen van de geëxplanteerde pulmonale autograft.

**Hoofdstuk 7** vergelijkt de wandstijfheid van de autograft met de normale pulmonaalwortel. Vierkante fragmenten vaatwand van 10 patiënten werden middels biaxiale strekproeven uitgerekt. De stijfheid werd bij 8 en 25 mmHg berekend. De autograftwand was significant minder stijf dan de normale pulmonaalwortel bij 8 (134 versus 175 kPa) en 25 mmHg (369 versus 919 kPa). Deze bevinding kan het optreden van progressieve autograftwortel dilatatie mogelijk verklaren.

**Hoofdstuk 8** vergelijkt de wandstijfheid van de autograft met de normale aorta. Vierkante fragmenten vaatwand van 10 patiënten werden middels biaxiale strekproeven uitgerekt. De stijfheid werd bij 80, 120 en 200 mmHg berekend. De autograftwand was significant minder stijf dan de normale aortawortel bij 80 (1527 versus 2993 kPa), 120 (2537 versus 4931 kPa) en 200 mmHg (4788 versus 9207 kPa). Het proces van remodellieren na de Ross operatie heeft er niet toe geleid dat de autograft de biomechanische eigenschappen van de normale aorta heeft gekregen.

**Hoofdstuk 9** vergelijkt de stijfheid van de autograft klep met de normale aorta- en pulmonaalklep. Klepbladen van zeven patiënten werden gemiddeld 12 jaar na de Ross



operatie geëxplanteerd. De stijfheid van de klepbladen werd bepaald middels biaxiale sterkproeven en vergeleken met normale aorta- pulmonaalkleppen. Hoewel stijfheid in autograaftklepbladen lager was dan in normale aortaklepbladen (11273 versus 26866 kPa) was er geen verschil met normale pulmonaalkleppen (9746 kPa). Ondanks veranderingen in de geometrie en histologie van de autograaftwortel werd er geen bewijs voor biomechanische remodelering gevonden.

**Hoofdstuk 10** beschrijft de casus van een patiënt met een bij toeval ontdekte dissectie van de autograaft. Een 47-jarige man onderging een reoperatie 12 jaar na de Ross operatie vanwege autograaft worteldilatatie en klepinsufficiëntie. Er werd na explantatie een longitudinale scheur in de intima van de autograaft gezien. Een biaxiale strekproef toonde aan dat de wandstijfheid ter plaatse van de dissectie veel groter was dan in het gebied daaromheen. Deze casus illustreert het vermogen tot remodelering van de autograaftwortel.

**Hoofdstuk 11**, de algemene discussie, bespreekt drie voornamelijk vragen over de Ross operatie die dit proefschrift heeft getracht te beantwoorden. Ten eerste, wat is de uitkomst van de Ross operatie in neonaten en zuigelingen? Ten tweede, wat is de waarde van klepsparende reoperaties na de Ross operatie? Ten derde, zorgt remodelering ervoor dat de pulmonale autograaft een aortaal fenotype aanneemt? Verder draagt Hoofdstuk 11 bij aan het debat over het gebruik van de Ross operatie bij volwassenen en bespreekt het de antwoorden op de drie vragen die dit proefschrift heeft voortgebracht. De toekomst van het onderzoek naar de Ross operatie wordt met optimisme tegemoet gezien.



## PhD Portfolio

Name PhD student	Aart Mookhoek
Department	Cardio-thoracic Surgery
Research school	COEUR
PhD period	January 2012 – December 2014
Promotors	Prof. Dr. J.J.M. Takkenberg Prof. Dr. A.J.J.C. Bogers
Copromotor	Dr. P.H. Schoof

In-depth courses	year	ECTS
Arrhythmia Research Methodology (COEUR)	2012	1.5
Cardiovascular Clinical Epidemiology (COEUR)	2012	1.5
BROK course	2012	1
Atherosclerotic & Aneurysmal Disease (COEUR)	2012	1.5
Cardiovascular Imaging and Diagnostics (COEUR)	2013	1.5
Integriteit in Wetenschappelijk Onderzoek	2013	2
Congenital Heart Disease (COEUR)	2013	1.5
Functionele en Toegepaste Cardiale Anatomie (ERCATHAN)	2013	0.3
Vascular Biology (NHS)	2013	2

Symposia and Meetings	year	ECTS
Symposium Congenital Cardiology “Focus on Echo”	2012	0.3
The cardiovascular system in women (COEUR)	2012	0.4
Scientific meetings Department of Surgery (UCSF)	2012	2
Scientific meetings Department of Cardio-thoracic Surgery (Erasmus MC)	2012 - 2014	2
Biostatistics and Cardio-thoracic Surgery (COEUR)	2013	0.4
COEUR debate on Cardiovascular Controversies (COEUR)	2014	0.4

Presentations	year	ECTS
3 <sup>rd</sup> Annual Bio Mechanical Conference at Stanford	2012	0.6
5 <sup>th</sup> Ross Summit	2012	0.6
8 <sup>th</sup> International Symposium on Biomechanics in Vascular Biology and Cardiovascular Disease	2013	0.6

7 <sup>th</sup> Biennial Meeting of the Society for Heart Valve Disease	2013	1.2
Valves in the Heart of the Big Apple VIII	2014	1.2
9 <sup>th</sup> International Research Symposium on Marfan Syndrome and Related Disorders	2014	0.3
<b>International conferences</b>	<b>year</b>	<b>ECTS</b>
92 <sup>nd</sup> Annual Meeting of American Association for Thoracic Surgery	2012	1.5
3 <sup>rd</sup> Annual Bio Mechanical Conference at Stanford	2012	0.3
5 <sup>th</sup> Ross Summit	2012	0.6
Optics in Cardiology	2013	0.6
8 <sup>th</sup> International Symposium on Biomechanics in Vascular Biology and Cardiovascular Disease	2013	0.6
7 <sup>th</sup> Biennial Meeting of the Society for Heart Valve Disease	2013	1.2
Valves in the Heart of the Big Apple VIII	2014	0.6
9 <sup>th</sup> International Research Symposium on Marfan Syndrome and Related Disorders	2014	0.6
<b>Teaching</b>	<b>year</b>	<b>ECTS</b>
Supervision of research project undergraduate student (UCSF)	2012	0.4
Supervision of research project graduate student (UCSF)	2012	0.4
Tutor 1 <sup>st</sup> medical students	2013	1
Supervision systematic review two groups 2 <sup>nd</sup> year medical students	2013	0.3
Supervision research project 3 <sup>rd</sup> medical student	2014	0.3
Lecture Minor “Congenital Heart Defects”	2014	0.3
Supervision systematic review Minor “Congenital Heart Defects”	2014	0.3
Coordination of departmental journal club	2014	0.5
	<b>Total ECTS</b>	<b>32</b>

## List of Publications

- Mookhoek A**, de Heer E, Bogers AJ, Takkenberg JJ, Schoof PH. Pulmonary autograft valve explants show typical degeneration. *J Thorac Cardiovasc Surg.* 2010;139:1416-1419.
- Chitsaz S, Wenk JF, Ge L, Wisneski A, **Mookhoek A**, Ratcliffe MB, Guccione JM, Tseng EE. Material properties of CorCap passive cardiac support device. *Ann Thorac Surg.* 2013;95:148-154.
- Azadani AN, Chitsaz S, Mannion A, **Mookhoek A**, Wisneski A, Guccione JM, Hope MD, Ge L, Tseng EE. Biomechanical properties of human ascending thoracic aortic aneurysms. *Ann Thorac Surg.* 2013;96:50-58.
- Wisneski AD, Matthews PB, Azadani AN, **Mookhoek A**, Chitsaz S, Guccione JM, Ge L, Tseng EE. Human pulmonary autograft wall stress at systemic pressures prior to remodeling after the Ross procedure. *J Heart Valve Dis.* 2014;23:377-384.
- Self MW, **Mookhoek A**, Tjalma N, Roelfsema PR. Contextual effects on perceived contrast: figure-ground assignment and orientation contrast. *J Vis.* 2015;15(2):2.
- Wisneski AD, **Mookhoek A**, Chitsaz S, Hope MD, Guccione JM, Ge L, Tseng EE. Patient-specific finite element analysis of ascending thoracic aortic aneurysm. *J Heart Valve Dis.* 2014;23:765-772.
- Arabkhani B, **Mookhoek A**, Di Centa I, Lansac E, Bekkers JA, De Lind Van Wijngaarden R, Bogers AJ, Takkenberg JJ. Reported Outcome After Valve-Sparing Aortic Root Replacement for Aortic Root Aneurysm: A Systematic Review and Meta-Analysis. *Ann Thorac Surg.* 2015; 4975:932-937.
- Mookhoek A**, de Kerchove L, El Khoury G, Weimar T, Luciani GB, Mazzucco A, Bogers AJ, Aicher D, Schäfers HJ, Charitos EI, Stierle U, Takkenberg JJ. European multicenter experience with valve-sparing reoperations after the Ross procedure. *J Thorac Cardiovasc Surg.* 2015;5223:1490-1497.
- Mookhoek A**, Charitos EI, Hazekamp MG, Bogers AJ, Hörer J, Lange R, Hetzer R, Sachweh JS, Riso A, Stierle U, Takkenberg JJ, Schoof PH. Ross Procedure in Neonates and Infants: A European Multicenter Experience. *Ann Thorac Surg.* 2015;100:2278-84.
- Mookhoek A**, Korteland NM, Arabkhani B, Di Centa I, Lansac E, Bekkers JA, Bogers AJ, Takkenberg JJ. Bentall Procedure: A Systematic Review and Meta-Analysis. *Ann Thorac Surg.* 2016; S0003-4975(15)01762-2.



**Dankwoord**





Dit proefschrift is het resultaat van jarenlang samenwerken met geweldige collega's en onmisbare steun van mijn ouders en goede vrienden. Graag wil ik een aantal mensen in het bijzonder bedanken.

Mijn promotor prof. dr. Takkenberg. Beste Hanneke, ongeveer 10 jaar geleden stapte ik als tweedejaars student vol zenuwen jouw kamer binnen om hartkleppen op te halen voor mijn eerste onderzoeksproject. Zenuwen hebben inmiddels plaatsgemaakt voor diep respect. Bedankt voor de vele kansen die je me door de jaren heen hebt geboden en de begeleiding tijdens mijn promotietraject en het schrijven van dit proefschrift. Van jou heb ik geleerd wat echte passie voor de wetenschap betekent en hoe aanstekelijk dat kan zijn. Ik heb in het bijzonder genoten van onze discussies, zowel op jouw kamer als op congres, over de wetenschap in al haar facetten en over het onderwijs binnen COEUR.

Mijn promotor prof. dr. Bogers. Beste prof. Bogers, ik wil u hartelijk danken voor het vertrouwen dat u mij gegeven heeft door mij als promovendus op de afdeling te verwelkomen. Ik heb respect voor uw kritische blik en heb veel van u geleerd over het schrijven van wetenschappelijke artikelen. Bedankt ook voor de vrijheid die u mij heeft gegeven en de tijd die u heeft genomen om samen oplossingen te zoeken voor problemen met enkele complexe projecten.

Mijn copromotor dr. Schoof. Beste Paul, ontzettend bedankt voor een bijzondere samenwerking die 10 jaar geleden begon in Leiden. Ik ben dankbaar dat u mij vanaf het begin het gevoel heeft gegeven samen onderzoek te doen. Een mooi voorbeeld is de NVT waar u mij, naïef gekleed in overhemd met korte mouwen, als tweedejaars student mee naar toe nam. Ik heb veel respect voor de rust die u uitstraalt en de manier waarop u kliniek en wetenschap combineert. U heeft altijd veel interesse getoond in mijn carrière en ik wil u bedanken voor de goede gesprekken, de adviezen en uw steun.

Beste leden van de kleine commissie, prof. dr. Hazekamp, prof. dr. Helbing en prof. dr. Van Kemenade, hartelijk dank voor uw bereidheid mijn proefschrift te lezen en te beoordelen. Beste prof. dr. Bloemena, prof. dr. Niessen, dr. Wentzel en dr. Witsenburg, hartelijk dank dat u plaats wilt nemen in de grote commissie. Ik kijk ernaar uit om met u allen van gedachten te wisselen over de inhoud van mijn proefschrift.

Dear dr. Tseng, thank you for the generous invitation to work at your lab on our joint project. It was a privilege learning from you and your team and I thank you for the patience you showed to someone with no background in biomechanical engineering. I enjoyed the weekly lab meetings and cherish my send-off at the Cliff House.

Graag wil ik alle collega's bedanken met wie ik het genoeg heb gehad om de afgelopen jaren mee samen te werken. Een aantal mensen wil ik in het bijzonder bedanken. Bardia, Jonathan en Nelleke, ik heb met plezier samen met jullie gewerkt aan onze systematische reviews! Dr. Rebel, bedankt voor het samen opzetten van een complexe studie. Beste dr. Bökenkamp, hartelijk dank voor de vele uren samen doorgebracht met het beoordelen van echobeelden. Of course, a huge thank you to all my international collaborators who have worked hard to make our multicentre efforts a success. Beste Annet, Erna, Liesbeth en Usha, bedankt voor jullie hulp en ondersteuning!

Lieve kamergenoten en mede-promovendi Bardia, Elrozy, Gerdien, Jonathan, Mostafa, Nelleke, Sahar en Simone, bedankt voor jullie collegialiteit en de vele, te lange lunches in de stad. Het is goed om te zien dat een aantal van jullie al gepromoveerd zijn en een aantal mij snel zullen volgen!

Dear Andrew, Heidi and Sam, thank you for making me feel at home in the lab. Sam, your help and advice the first weeks in the lab was truly invaluable. Dear Andrew and Heidi, I enjoyed sharing the lab with you over the summer. I still miss your boxed cheese plates whenever I go for a long walk!

Mijn opleiders in het VU medisch centrum prof. dr. Bloemena en prof. dr. Van der Valk en mentor prof. dr. De Jong. Beste Elisabeth, Paul en Daphne, dank voor jullie vertrouwen in mij. Ik ben trots dat ik onder jullie hoede de opleiding tot patholoog mag volgen. Bedankt voor de mogelijkheid die jullie aangereikt hebben om tijdens mijn opleiding twee maanden vrij te maken om dit proefschrift te voltooien.

Beste collega's in het VU medisch centrum, ik ben dankbaar om met zulke geweldige collega's te mogen werken. In het bijzonder wil ik mijn collega-AIOS Anna-Lena, Annefleure, Clifton, David, Emma, Emma, Eriëne, Evita, Evert-Jan, Jolanda, Kimberly, Maartje, Mariëlle, Mathilda, Max, Mehrdad, Sara en Shaimaa bedanken. Ik voel me echt thuis op de afdeling en dat komt door jullie!

Thank you to Asia, Emelie, Luke and Pierre for discovering San Francisco together, for eating and drinking, for hiking, for being great friends! Dear Sophie, thank you for letting me live in your house, where I felt at home with you and the cats.

Dear Arianna, do you think I could defend my thesis over Skype? I am still happy we said goodbye in a Manhattan hotel and not at a Sicilian airport.

Graag wil ik mijn vrienden bedanken voor jullie begrip en interesse. In het bijzonder wil ik Emma, Justin en Jeroen bedanken voor hun vriendschap en de vele samen gemaakte reizen. Oscar, bedankt voor de tijd samen aan de Burgermeester Reigerstraat! En Noortje, bedankt voor de gezelligheid op weg naar het Erasmus MC.

Beste Emma en Johan, mijn paranimfen, ik ben erg blij en trots dat jullie naast mij staan op deze bijzondere en belangrijke dag. Dank voor jullie steun!

Dearest Violeta, falling in love is such an amazing feeling!

De laatste woorden zijn voor mijn ouders die mij met veel liefde en toewijding hebben opgevoed en mij nog steeds zoveel leren. Lieve ouders, bedankt voor jullie grenzeloze steun! Jullie hebben ervoor gezorgd dat ik zelden zorgen heb gekend. Het afgelopen jaar hebben jullie je veelvuldig en hardop afgevraagd of ik mijn proefschrift nog af ging maken. Het is dan ook mede dankzij jullie dat ik straks vol trots mijn proefschrift in jullie bijzijn zal verdedigen.



## About the author



Aart Mookhoek was born on October 10<sup>th</sup>, 1985 in Beverwijk (The Netherlands). After graduating from grammar school, he started his academic career at Leiden University (The Netherlands) in 2003. Fascinated by the inner workings of the human body, he completed a bachelor's and master's degree in biomedical sciences. During his time in Leiden, he took advantage of the opportunities to study abroad by spending a semester at the Karolinska Institute (Sweden) and the National University of Singapore (Singapore).

Exposure to clinical research and inspiring hours spent in the operating room at the Leiden University Medical Center (The Netherlands) persuaded him to pursue a career in medicine. In 2008, he enrolled in the Selective Utrecht Medical Master, SUMMA in short, at the University of Utrecht (The Netherlands), a four year fast-track medical school designed to stimulate students to pursue a career as both clinician and scientist. During his final year, Aart completed a clinical rotation in adult congenital heart disease at the Royal Brompton Hospital (United Kingdom) and performed a research project concerning the biomechanical properties of explanted pulmonary autografts at the Department of Surgery at the University of California San Francisco (United States) under the supervision of Elaine Tseng.

After graduating from medical school in 2012, Aart moved to the Erasmus Medical Center (The Netherlands) for the PhD project which resulted in the thesis you are now reading. This move was instigated by a wish to finish a research project which he started to work on while still a bachelor student in Leiden. As of January 2015, Aart is in training to become a clinical pathologist at the VU Medical Center (The Netherlands).

