



**REDEFINING THE BOUNDARIES OF DRUG-ELUTING
STENT UTILIZATION: FROM IN-STENT RESTENOSIS TO
ACUTE MYOCARDIAL INFARCTION**

Francesco Saia

REDEFINING THE BOUNDARIES OF
DRUG-ELUTING STENT UTILIZATION:
FROM IN-STENT RESTENOSIS TO ACUTE
MYOCARDIAL INFARCTION

Francesco Saia

ISBN 90-77595-59-7

Front cover: **Fabrizio Chella**

Layout & Print: Optima Grafische Communicatie, Rotterdam

All rights reserved. No part of this thesis may be reproduced, stored in a retrieval system of any nature, or transmitted in any form by any means, electronic, mechanical, photocopying, recording or otherwise, included a complete or partial transcription without the permission of the author.

© Francesco Saia 2004

REDEFINING THE BOUNDARIES OF
DRUG-ELUTING STENT UTILIZATION:
FROM IN-STENT RESTENOSIS TO
ACUTE MYOCARDIAL INFARCTION

HET OPNIEUW VASTSTELLEN VAN DE MOGELIJKHEDEN
VAN DE DRUG-ELUTING STENT: VAN IN-STENT RESTENOSIS
TOT ACUUT MYOCARD INFARCT

Thesis

to obtain the degree of Doctor from the
Erasmus University Rotterdam
by command of the
Rector Magnificus
Prof.dr. S.W.J. Lamberts

and according to the decision of the Doctorate Board
The public defence shall be held on

Wednesday, 22 September 2004 at 11:45

by

Francesco Saia
born in Pescara, Italy

DOCTORAL COMMITTEE

Promotors:

Prof.dr. P.W.J.C. Serruys

Prof.dr. P.J. de Feijter

OTHER MEMBERS

Prof.dr. D.J.G.M. Duncker

Prof.dr. J.R.T.C. Roelandt

Prof.dr. A. Branzi

Financial support by the Netherlands Heart Foundation for the publication of this thesis is gratefully acknowledged.

The generous sponsoring by Cordis, a Johnson & Johnson Company, is gratefully acknowledged.

A Barbara

TABLE OF CONTENTS

Chapter 1	Introduction and overview of the thesis F Saia	9
PART 1	Drug-eluting stents to treat in-stent restenosis	
Chapter 2	Routine Sirolimus-Eluting Stent Implantation for Unselected In-Stent Restenosis: Insights From the Rapamycin Eluting Stent Evaluated at Rotterdam Cardiology Hospital (RESEARCH) Registry F Saia, PA Lemos, CA Arampatzis, A Hoye, M Degertekin, K Tanabe, G Sianos, PC Smits, WJ van der Giessen, PJ de Feyter, RT van Domburg, PW Serruys <i>Heart, in press</i>	17
Chapter 3	Clinical outcomes for sirolimus-eluting stent implantation and vascular brachytherapy for the treatment of in-stent restenosis F Saia, PA Lemos, A Hoye, G Sianos, CA Arampatzis, PJ de Feyter, WJ van der Giessen, PC Smits, RT van Domburg, PW Serruys <i>Catheter Cardiovasc Interv. 2004;62:283-8.</i>	31
Chapter 4	Effectiveness of Sirolimus-Eluting Stent Implantation for Recurrent In-Stent Restenosis After Brachytherapy F Saia, PA Lemos, G Sianos, M Degertekin, CH Lee, CA Arampatzis, A Hoye, K Tanabe, E Regar, WJ van der Giessen, PC Smits, P de Feyter, J Ligthart, RT van Domburg, PW Serruys <i>Am J Cardiol 2003;92:200-203.</i>	45
PART 2	Unrestricted utilization of drug-eluting stents	
Chapter 5	Incidence of Thrombotic Stent Occlusion During the first 3 Months After Sirolimus-Eluting Stent Implantation in 500 Consecutive Patients Treated in the “Real World” E Regar, PA Lemos, F Saia, M Degertekin, K Tanabe, CH Lee, CA Arampatzis, A Hoye, G Sianos, P de Feyter, WJ van der Giessen, PC Smits, RT van Domburg, PW Serruys <i>Am J Cardiol 2004;93:1271–1275.</i>	51
Chapter 6	Unrestricted Utilization of Sirolimus-Eluting Stents Compared to Conventional Bare Stent Implantation in the “Real World”. The Rapamycin-Eluting Stent Evaluated At Rotterdam Cardiology Hospital (RESEARCH) registry PA Lemos, PW Serruys, RT van Domburg, F Saia, CA Arampatzis, A Hoye, M Degertekin, K Tanabe, J Daemen, TKK Liu, E McFadden, G Sianos, SH Hofma, PC Smits, WJ van der Giessen, P de Feyter <i>Circulation 2004;109:190-195.</i>	59

Chapter 7	Clinical and Angiographic Outcomes After Over-Dilatation of Undersized Sirolimus-Eluting Stents With Largely Oversized Balloons. An Observational Study F Saia, PA Lemos, CA Arampatzis, A Hoye, E McFadden, G Sianos, PC Smits, WJ van der Giessen, PJ de Feyter, RT van Domburg, PW Serruys <i>Cath Cardiovasc Interv</i> 2004;61:455-460.	67
Chapter 8	Coronary Restenosis After Sirolimus-Eluting Stent Implantation. Morphological Description and Mechanistic Analysis From a Consecutive Series of Cases PA Lemos, F Saia, JMR Ligthart, CA Arampatzis, G Sianos, K Tanabe, A Hoye, M Degertekin, J Daemen, E McFadden, S Hofma, PC Smits, P de Feyter, WJ van der Giessen, RT van Domburg, PW Serruys <i>Circulation</i> 2003;108:257-260.	75
PART 3	Sirolimus-eluting stent implantation in patients with acute myocardial infarction	
Chapter 9	Sirolimus-Eluting Stent Implantation in ST-Elevation Acute Myocardial Infarction. A Clinical and Angiographic Study F Saia, PA Lemos, CH Lee, CA Arampatzis, A Hoye, M Degertekin, K Tanabe, G Sianos, PC Smits, E McFadden, SH Hofma, WJ van der Giessen, PJ de Feyter, RT van Domburg, PW Serruys <i>Circulation</i> 2003;108:1927-1929.	81
Chapter 10	Short- and Long-Term Clinical Benefit of Sirolimus-Eluting Stents Compared to Conventional Bare Stents for Patients With Acute Myocardial Infarction PA Lemos, F Saia, SH Hofma, J Daemen, ATL Ong, CA Arampatzis, A Hoye, E McFadden, G Sianos, PC Smits, WJ van der Giessen, P de Feyter, RT van Domburg, PW Serruys <i>J Am Coll Cardiol</i> 2004;43:704-708.	87
Chapter 11	Summary and conclusions F Saia	95
Samevatting en Conclusies		100
Acknowledgements		103
Curriculum Vitae		107
List of Publications		108



CHAPTER 1

Introduction and Overview of the Thesis

Author: Francesco Saia.

GENERAL INTRODUCTION AND OUTLINE OF THE THESIS

Percutaneous Coronary Interventions

Percutaneous coronary angioplasty was first introduced by Andreas Gruentzig in 1977 as a non surgical method for coronary artery revascularization. Although initially restricted to stable patients with single, discrete, concentric, noncalcified stenoses, percutaneous revascularization is now routinely applied to patients with multivessel disease, multiple lesions, complex lesions, acute coronary syndromes, and left ventricular dysfunction. Refinement of the equipment used to perform angioplasty and utilization of adjunctive periprocedural medications, together with time and growing experience played a major role in the explosive growth and popularity of percutaneous coronary interventions (PCI). The most important advancement in the field of percutaneous coronary interventions was the introduction of coronary stents, which reduce both the acute risk of major complications and the incidence of restenosis.^{1,2} With modern techniques, procedural success > 90% is readily achieved, and the risk of sudden arterial occlusion and subsequent myocardial infarction is very low.³ Long-term survival has been shown to be not different from that achieved with bypass surgery, therefore in many countries percutaneous coronary interventions have become the preferred strategy for coronary revascularization.

Restenosis

Restenosis, defined as the vessel lumen renarrowing following a successful percutaneous coronary intervention, represents the principal limitation to the long-term outcome of coronary angioplasty. Restenosis is a pathobiological process caused by the arterial healing response after vessel injury, and is due to varying degrees of elastic recoil,⁴ vascular remodeling,⁵ and neointimal hyperplasia.⁶ The only widely accepted means of reducing restenosis is the coronary stent, which virtually eliminates vessel elastic recoil and negative remodeling following balloon dilatation.⁶ However, the efficacy of this purely “mechanical” approach to the prevention of restenosis has been hampered by the development of a new iatrogenic disease: in-stent restenosis, which is predominantly due to neointima formation. In-stent restenosis has been reported to occur in 10 to 50% of the patients in several series,⁷ depending upon a number of clinical, angiographic, and procedural variables. Furthermore, treatment of ISR is frequently a challenging clinical problem, with recurrent restenosis being reported in up to 80% of the patients in the most complex cases.⁸

The development of neointimal tissue is thought to relate to a combination of coagulation cascade activation, platelet deposition, organization of thrombus, growth factor stimulation, and is due mainly to smooth muscle cell proliferation and migration, and excessive extracellular matrix production.⁹ Smooth muscle cell proliferation has therefore become the main target in the effort to prevent or reduce in-stent restenosis.

DRUG-ELUTING STENTS

Stent-based local drug delivery (drug-eluting stents) is a percutaneous technique that has been developed to prevent neointimal proliferation.¹⁰ Stents represent an ideal platform for local drug delivery because of their permanent scaffolding properties. In addition, they may represent drug reservoirs as medications are released to the vessel wall from various coatings at different time intervals. The drugs which have been tested can be classified according to the mechanism of

action as immunosuppressive, antiproliferative, antiinflammatory, antithrombotic. Some agents, such as sirolimus, may affect multiple targets.¹¹ Recently, sirolimus- and paclitaxel-eluting stent implantation has been proven to markedly reduce the incidence of angiographic restenosis and repeat revascularization when compared to bare metal stents in selected patients,¹²⁻¹⁵ raising considerable enthusiasm in the scientific community.

Immediately after market approval in Europe and FDA approval in the USA, drug-eluting stents have triggered a major debate regarding their correct utilization. Evidence-based medicine, cost-effectiveness ratio, and necessity to complete scientific evaluation in every subset of patients and lesions, have resulted in different strategies between different countries and different hospitals.¹⁶⁻¹⁸

The present doctoral research project started after sirolimus-eluting stents (CypherTM, Cordis Europe, Johnson and Johnson, Roden, NL) were commercialised in Europe. The Thoraxcenter, Erasmus University of Rotterdam, had played a pivotal role in the First in Men (FIM)^{19,20} and in the RANdomized study with the sirolimus-eluting Bx VELOCITY balloon-expandable stent in the treatment of patients with de novo native coronary artery Lesions (RAVEL)¹² trials, being among the pioneers of drug-eluting stents development. The dilemma about drug-eluting stent utilization was subsequently turned into a scientific research program aimed to evaluate the impact in clinical practice of routine drug-eluting stent implantation, without any clinical and anatomical restriction, the Rapamycin Eluting Stents Evaluated At Rotterdam Cardiology Hospital (RESEARCH) registry.¹⁸ Most of the studies which compose this thesis were performed in this setting.

In-Stent Restenosis and Acute Myocardial Infarction: the Past and the Future

In-stent restenosis (ISR) and acute myocardial infarction (AMI) could be seen as two “boundaries” of drug-eluting stents utilization because of many different reasons.

From a clinical point of view, ISR more often lead to chronic ischemic coronary disease/stable angina, whilst AMI is the most dramatic of the acute coronary syndromes.

Pathophysiology of these two conditions is also extremely different: exaggerated neointimal hyperplasia following stent implantation is responsible of ISR, whilst atherosclerotic plaque rupture/erosion with superimposition of a flow-limiting thrombus is the predominant cause of AMI.²¹ The biological substrate and target of the intervention is therefore clearly different.

In-stent restenosis and acute myocardial infarction are boundaries for drug-eluting stent utilization also from a “strategic” point of view. In fact, many institutions are carefully selecting patients to be treated with drug-eluting stents, limiting DES implantation to a few specific indication, and treatment of ISR on a bare stent was one of the first indications proposed. At the other extreme of the spectrum of possible treatment strategies, there are institutions with a broad and liberal utilization of DES, including patients with AMI.

Furthermore, percutaneous treatment of ISR and AMI might delineate a peculiar temporal, historical perspective. In-stent restenosis is presently considered the Achilles’s heel of interventional cardiology.²² If the results of DES utilization in selected populations were confirmed in the daily practice, in-stent restenosis rate could be reduced to a single digit number and even more reduced should be the necessity of repeat revascularization. Since restenosis following DES implantation seems to be predominantly focal, ISR as a major limitation of PCI might become just history of the past.^{23,24} On the other hand, percutaneous angioplasty has been recently indicated as the preferred therapeutic option to obtain culprit vessel recanalization during acute myocardial infarction, at least when it can be performed within 90 min after the first

medical contact. In the last few years, a tremendous interest has been focused on catheter-based reperfusion therapy for myocardial infarction, involving health system organization, financial resorts, and research for new devices and peri-procedural medications.²⁵ Thus, giving a glance into the future of catheterization laboratories, we could hypothesize that treatment of acute myocardial infarction will become more and more relevant.

Drug-Eluting Stents to Treat In-stent Restenosis

Prevention of in-stent restenosis is undoubtedly the major frontier of interventional cardiology, and drug-eluting stent implantation represents the most promising strategy. However, the implementation of drug-eluting stents in clinical practice has been limited mainly by cost issues and, to a lesser extent, by the reluctance in transferring the positive results of RCTs to the real-world. Moreover, to date limited data are available for DES utilization in some high-risk patients and lesions. Bare metal stents are still the most used devices in the catheterization laboratory, and development of in-stent restenosis is still a major problem. Vascular brachytherapy is the only percutaneous treatment proven to be effective to treat in-stent restenosis in randomized trials.²⁶⁻³⁰ However, its utilization is limited by complex logistic requirements and the necessity of highly trained operators. Drug-eluting stents have been proposed as an alternative to vascular brachytherapy, because of the potent inhibitory effect on development of neointimal hyperplasia.³¹⁻³³ In the first part of this thesis, we analysed the preliminary results of this new strategy.

Unrestricted Utilization Of Drug-Eluting Stents

The second part of this doctoral research is focused on the evaluation of unrestricted utilization of drug-eluting stents to prevent in-stent restenosis. Specifically, we analyzed safety, effectiveness and caveats of sirolimus-eluting stent implantation as the default strategy to accomplish percutaneous coronary interventions at our catheterization laboratory, without any clinical or anatomical restriction.

Drug-Eluting Stents For ST-Elevation Acute Myocardial Infarction

Patients presenting with acute myocardial infarction form a peculiar cohort of patients undergoing percutaneous coronary interventions, because of the high-risk of periprocedural and mid-term complications.

We investigated the clinical and angiographic results of sirolimus-eluting stent implantation in patients with ST-elevation acute myocardial infarction. The results of our researches are described in Part 3 of this thesis.

REFERENCES

1. Serruys PW, de Jaegere P, Kiemeneij F, Macaya C, Rutsch W, Heyndrickx G, Emanuelsson H, Marco J, Legrand V, Materne P, et al. A comparison of balloon-expandable-stent implantation with balloon angioplasty in patients with coronary artery disease. Benestent Study Group. *N Engl J Med* 1994;331:489-95.
2. Fischman DL, Leon MB, Baim DS, Schatz RA, Savage MP, Penn I, Detre K, Veltri L, Ricci D, Nobuyoshi M, et al. A randomized comparison of coronary-stent placement and balloon angioplasty in the treatment of coronary artery disease. Stent Restenosis Study Investigators. *N Engl J Med* 1994;331:496-501.
3. Smith SC, Jr., Dove JT, Jacobs AK, Kennedy JW, Kereiakes D, Kern MJ, Kuntz RE, Popma JJ, Schaff HV, Williams DO, Gibbons RJ, Alpert JP, Eagle KA, Faxon DP, Fuster V, Gardner TJ, Gregoratos G, Russell RO. ACC/AHA guidelines of percutaneous coronary interventions (revision of the 1993 PTCA guidelines)--executive summary. A report of the American College of Cardiology/American Heart Association Task Force on Practice Guidelines (committee to revise the 1993 guidelines for percutaneous transluminal coronary angioplasty). *J Am Coll Cardiol* 2001;37:2215-39.
4. Rensing BJ, Hermans WR, Beatt KJ, Laarman GJ, Suryapranata H, van den Brand M, de Feyter PJ, Serruys PW. Quantitative angiographic assessment of elastic recoil after percutaneous transluminal coronary angioplasty. *Am J Cardiol* 1990;66:1039-44.
5. Mintz GS, Popma JJ, Pichard AD, Kent KM, Satler LF, Wong C, Hong MK, Kovach JA, Leon MB. Arterial remodeling after coronary angioplasty: a serial intravascular ultrasound study. *Circulation* 1996;94:35-43.
6. Hoffmann R, Mintz GS, Dussallant GR, Popma JJ, Pichard AD, Satler LF, Kent KM, Griffin J, Leon MB. Patterns and mechanisms of in-stent restenosis. A serial intravascular ultrasound study. *Circulation* 1996;94:1247-54.
7. Lowe HC, Oesterle SN, Khachigian LM. Coronary in-stent restenosis: current status and future strategies. *J Am Coll Cardiol* 2002;39:183-93.
8. Mehran R, Dangas G, Abizaid AS, Mintz GS, Lansky AJ, Satler LF, Pichard AD, Kent KM, Stone GW, Leon MB. Angiographic patterns of in-stent restenosis: classification and implications for long-term outcome. *Circulation* 1999;100:1872-8.
9. Virmani R, Liistro F, Stankovic G, Di Mario C, Montorfano M, Farb A, Kolodgie FD, Colombo A. Mechanism of late in-stent restenosis after implantation of a paclitaxel derivate-eluting polymer stent system in humans. *Circulation* 2002;106:2649-51.
10. Sousa JE, Serruys PW, Costa MA. New frontiers in cardiology: drug-eluting stents: Part I. *Circulation* 2003;107:2274-9.
11. Serruys PW, Regar E, Carter AJ. Rapamycin eluting stent: the onset of a new era in interventional cardiology. *Heart* 2002;87:305-7.
12. Morice MC, Serruys PW, Sousa JE, Fajadet J, Ban Hayashi E, Perin M, Colombo A, Schuler G, Barragan P, Guagliumi G, Molnar F, Falotico R. A randomized comparison of a sirolimus-eluting stent with a standard stent for coronary revascularization. *N Engl J Med* 2002;346:1773-80.
13. Moses JW, Leon MB, Popma JJ, Fitzgerald PJ, Holmes DR, O'Shaughnessy C, Caputo RP, Kereiakes DJ, Williams DO, Teirstein PS, Jaeger JL, Kuntz RE. Sirolimus-eluting stents versus standard stents in patients with stenosis in a native coronary artery. *N Engl J Med* 2003;349:1315-23.
14. Schofer J, Schluter M, Gershlick AH, Wijns W, Garcia E, Schampaert E, Breithardt G. Sirolimus-eluting stents for treatment of patients with long atherosclerotic lesions in small coronary arteries: double-blind, randomised controlled trial (E-SIRIUS). *Lancet* 2003;362:1093-9.
15. Colombo A, Drzewiecki J, Banning A, Grube E, Hauptmann K, Silber S, Dudek D, Fort S, Schiele F, Zmudka K, Guagliumi G, Russell ME. Randomized study to assess the effectiveness of slow- and moderate-release polymer-based paclitaxel-eluting stents for coronary artery lesions. *Circulation* 2003;108:788-94.
16. Lemos PA, Serruys PW, Sousa JE. Drug-eluting stents: cost versus clinical benefit. *Circulation* 2003;107:3003-7.

17. O'Neill WW, Leon MB. Drug-eluting stents: costs versus clinical benefit. *Circulation* 2003;107:3008-11.
18. Lemos PA, Lee C, Degertekin M, Saia F, Tanabe K, Arampatzis CA, Hoye A, van Duuren M, Sianos G, Smits PC, de Feyter P, van der Giessen WJ, van Domburg RT, Serruys PW. Early outcome after sirolimus-eluting stent implantation in patients with acute coronary syndromes. Insights from the Rapamycin-Eluting Stent Evaluated At Rotterdam Cardiology Hospital (RESEARCH) registry. *J Am Coll Cardiol* 2003;41:2093-9.
19. Rensing BJ, Vos J, Smits PC, Foley DP, van den Brand MJ, van der Giessen WJ, de Feijter PJ, Serruys PW. Coronary restenosis elimination with a sirolimus eluting stent: first European human experience with 6-month angiographic and intravascular ultrasonic follow-up. *Eur Heart J* 2001;22:2125-30.
20. Sousa JE, Costa MA, Abizaid A, Abizaid AS, Feres F, Pinto IM, Seixas AC, Staico R, Mattos LA, Sousa AG, Falotico R, Jaeger J, Popma JJ, Serruys PW. Lack of Neointimal Proliferation After Implantation of Sirolimus-Coated Stents in Human Coronary Arteries : A Quantitative Coronary Angiography and Three-Dimensional Intravascular Ultrasound Study. *Circulation* 2001;103:192-195.
21. Davies MJ, Thomas AC. Plaque fissuring--the cause of acute myocardial infarction, sudden ischaemic death, and crescendo angina. *Br Heart J* 1985;53:363-73.
22. Beyar R, Roguin A. The sirolimus coated stent: will the Achilles heel of interventional cardiology finally be cured? *Eur Heart J* 2001;22:2054-7.
23. Colombo A, Orlic D, Stankovic G, Corvaja N, Spanos V, Montorfano M, Liistro F, Carlino M, Airoldi F, Chieffo A, Di Mario C. Preliminary observations regarding angiographic pattern of restenosis after rapamycin-eluting stent implantation. *Circulation* 2003;107:2178-80.
24. Lemos PA, Saia F, Ligthart JM, Arampatzis CA, Sianos G, Tanabe K, Degertekin M, Daemen J, McFadden E, Hofma S, Smits PC, De Feyter P, Van Der Giessen WJ, Van Domburg RT, Serruys PW. Coronary Restenosis After Sirolimus-Eluting Stent Implantation. Morphological Description and Mechanistic Analysis From a Consecutive Series of Cases. *Circulation* 2003.
25. Topol EJ. Current status and future prospects for acute myocardial infarction therapy. *Circulation* 2003;108:1116-13.
26. Leon MB, Teirstein PS, Moses JW, Tripuraneni P, Lansky AJ, Jani S, Wong SC, Fish D, Ellis S, Holmes DR, Kerieakes D, Kuntz RE. Localized intracoronary gamma-radiation therapy to inhibit the recurrence of restenosis after stenting. *N Engl J Med* 2001;344:250-6.
27. Verin V, Popowski Y, de Bruyne B, Baumgart D, Sauerwein W, Lins M, Kovacs G, Thomas M, Calman F, Disco C, Serruys PW, Wijns W. Endoluminal beta-radiation therapy for the prevention of coronary restenosis after balloon angioplasty. The Dose-Finding Study Group. *N Engl J Med* 2001;344:243-9.
28. Waksman R, Bhargava B, White L, Chan RC, Mehran R, Lansky AJ, Mintz GS, Satler LF, Pichard AD, Leon MB, Kent KK. Intracoronary beta-radiation therapy inhibits recurrence of in-stent restenosis. *Circulation* 2000;101:1895-8.
29. Teirstein PS, Massullo V, Jani S, Popma JJ, Mintz GS, Russo RJ, Schatz RA, Guarneri EM, Steuterman S, Morris NB, Leon MB, Tripuraneni P. Catheter-based radiotherapy to inhibit restenosis after coronary stenting. *N Engl J Med* 1997;336:1697-703.
30. Waksman R, White RL, Chan RC, Bass BG, Geirlach L, Mintz GS, Satler LF, Mehran R, Serruys PW, Lansky AJ, Fitzgerald P, Bhargava B, Kent KM, Pichard AD, Leon MB. Intracoronary gamma-radiation therapy after angioplasty inhibits recurrence in patients with in-stent restenosis. *Circulation* 2000;101:2165-71.
31. Sousa JE, Costa MA, Abizaid A, Sousa AG, Feres F, Mattos LA, Centemero M, Maldonado G, Abizaid AS, Pinto I, Falotico R, Jaeger J, Popma JJ, Serruys PW. Sirolimus-eluting stent for the treatment of in-stent restenosis: a quantitative coronary angiography and three-dimensional intravascular ultrasound study. *Circulation* 2003;107:24-7.
32. Degertekin M, Saia F, Lemos PA, Arampatzis CA, Serruys PW. Sirolimus-eluting stents for the treatment of in-stent restenosis. *Minerva Cardioangiol* 2003;51:475-84.
33. Tanabe K, Serruys PW, Grube E, Smits PC, Selbach G, van der Giessen WJ, Staberock M, de Feyter P, Muller R, Regar E, Degertekin M, Ligthart JM, Disco C, Backx B, Russell ME. TAXUS III Trial: in-stent restenosis treated with stent-based delivery of paclitaxel incorporated in a slow-release polymer formulation. *Circulation* 2003;107:559-64.

PART 1

DRUG-ELUTING STENTS TO TREAT IN-STENT RESTENOSIS

CHAPTER 2

Routine Sirolimus-Eluting Stent Implantation
for Unselected In-Stent Restenosis:
Insights From the Rapamycin Eluting Stent
Evaluated at Rotterdam Cardiology Hospital
(RESEARCH) Registry

Authors: Francesco Saia, Pedro A. Lemos,
Chourmouziou A. Arampatzis, Angela Hoye,
Muzaffer Degertekin, Kengo Tanabe, Georgios
Sianos, Pieter C. Smits, Willem J. van der Giessen,
Pim J. de Feyter, Ron T. van Domburg, Patrick W.
Serruys.

Heart, in press

CHAPTER 2

Routine Sirolimus-Eluting Stent Implantation for Unselected In-Stent Restenosis: Insights From the Rapamycin Eluting Stent Evaluated at Rotterdam Cardiology Hospital (RESEARCH) Registry

Francesco Saia, MD, Pedro A. Lemos, MD, Chourmouziou A. Arampatzis, MD, Angela Hoye, MB ChB, MRCP, Muzaffer Degertekin, MD, Kengo Tanabe, MD, Georgios Sianos, MD, Pieter C. Smits, MD, PhD, Wim J. van der Giessen, MD, PhD, Pim J. de Feyter, MD, PhD, Ron T. van Domburg, PhD, Patrick W. Serruys, MD, PhD.

Department of Invasive Cardiology, Thoraxcenter, Erasmus University Medical Center, Rotterdam, The Netherlands

Address for correspondence:

Prof. Patrick W. Serruys
Erasmus MC, Thoraxcenter
Kamer Bd 404
Dr. Molewaterplein 40
3015 GD Rotterdam, The Netherlands
Tel: 0031.10.4635260
Fax: 0031.10.4369154
e-mail: p.w.j.c.serruys@erasmusmc.nl

Running head: Sirolimus-eluting stents for ISR

Total word count: 4021

There is no conflict of interest for any of the authors.

ABSTRACT

Objective: To assess the effectiveness of routine sirolimus-eluting stent (SES) implantation for unselected patients with in-stent restenosis (ISR), and to provide preliminary information about the angiographic outcome for different lesion subgroups and for different ISR patterns.

Design: Prospective, single-center registry.

Setting: Tertiary referral centre.

Patients: We evaluated 44 consecutive patients (53 lesions) without previous brachytherapy that were treated with SES for in-stent restenosis at our institution. Routine angiographic follow-up was obtained at 6 months and the incidence of major adverse cardiac events was evaluated.

Results: At baseline, 42% of the lesions were focal, 21% diffuse, 26% proliferative, and 11% total occlusions. Small vessel size (reference diameter <2.5mm) was present in 49%, long lesions (>20mm) in 30%, treatment of bypass grafts in 13%, and bifurcation stenting in 18%. At follow-up, post-SES restenosis was observed in 14.6%. No restenosis was observed in focal lesions. For more complex lesions, restenosis rates ranged 20-25%. At 1-year follow-up, the incidence of death was 0%, myocardial infarction 4.7%, and target lesion revascularisation 16.3%. Target lesion revascularisation due to restenosis was performed in 11.6%.

Conclusions: Routine sirolimus-eluting stent implantation is highly effective for focal in-stent restenosis and appears to be a promising strategy for more complex patterns of restenosis.

Keywords: sirolimus, eluting-stent, in-stent restenosis

INTRODUCTION

Despite major advances in the field of percutaneous coronary interventions (PCI), long-term outcome is still limited by the occurrence of in-stent restenosis (ISR), which has been reported to occur in 10 to 50% of the patients in several series.[1] Furthermore, treatment of ISR is frequently a challenging clinical problem, with recurrent restenosis being reported in up to 80% in the most complex cases.[2] Currently, vascular brachytherapy is the only strategy proven to be more effective for the treatment of ISR than other conventional approaches.[3][4][5][6][7] However, post-brachytherapy recurrent restenosis has been reported to occur in 17% to 32% of patients at 1 year.[3][4][5][6][7] Moreover, despite the relative improvement in outcomes, brachytherapy has not been extensively adopted as routine therapy in many centers, mostly due to logistic and technical limitations.

Sirolimus-eluting stents (SES) have been shown in randomized trials to virtually abolish in-stent restenosis in selected patients with *de novo* lesions.[8][9] Moreover, prolonged (up to 2 years) inhibition of the proliferative response has been documented in two series of patients with non-complex lesions.[10][11] Due to the potent antiproliferative and antimigratory effects of the drug on vascular smooth muscle cells and the clinical efficacy demonstrated for *de novo* lesions, SES implantation has been recently tested in two preliminary studies to treat in-stent restenosis.[12][13] In one study with 25 relatively non-complex cases, zero recurrent binary restenosis was observed after SES.[13] In the other study, among 16 patients with more complex lesions, repeat in-stent restenosis was observed in 20% of cases.[12] However, due to the limited number of patients in both reports, the outcome in patients with complex lesion morphology, a condition commonly seen in daily practice, is currently unclear.

In the present study, we evaluated the clinical and angiographic outcomes of 44 consecutive patients treated with routine SES implantation for in-stent restenosis with a broad range of morphological lesion patterns.

METHODS

Patient population

Since the 16th of April 2002, SES implantation has been adopted as the default strategy for all patients undergoing PCI at our institution, as part of the RESEARCH (Rapamycin-Eluting Stents Evaluated At Rotterdam Cardiology Hospital) Registry.[14] Forty-four consecutive patients without previous brachytherapy were treated for in-stent restenosis during a 6-month enrolment period and comprise the present study population. No patient with in-stent restenosis was treated in the same period exclusively with other percutaneous devices (e.g. bare metal stents, cutting balloon) or with brachytherapy and therefore excluded from this report. The study protocol was approved by the hospital ethics committee and is in accordance with the principles of Good Clinical Practice for Trials of Medicinal Products in the European Community and the Declaration of Helsinki. Written informed consent was given by every patient.

Procedure

The CYPHER™ sirolimus-eluting stent (Cordis Europa NV, Roden, NL) was utilized in all patients. The stents were available in lengths of 8, 18 or 33mm and in diameters of 2.25, 2.5, 2.75 and 3.0mm. All procedures were performed according to standard techniques and the final interventional strategy was left to the operator's discretion. Complete lesion coverage was recommended, as well as a small region of overlap of adjacent stents when treating lesions that required more than one stent. Periprocedural adjunctive medications were left to the discretion of the operator. All patients were pre-treated with aspirin and clopidogrel. Aspirin was maintained lifelong and at least 3 months of clopidogrel treatment was recommended thereafter.

Definitions and Follow-up

Restenotic lesions were angiographically classified by two independent operators according to Mehran classification as: 1) focal (<10 mm), 2) diffuse, 3) proliferative, or 4) total occlusion.[2] A procedure was considered successful when residual stenosis was < 30% by quantitative coronary analysis (QCA) with TIMI flow 3. All patients were requested to undergo an elective repeat angiogram after 6 months following a successful procedure. Post-SES binary restenosis at follow-up was defined as >50% diameter stenosis occurring in the segment inside the SES or within 5-mm segment proximal or distal to the stent. Late luminal loss was calculated as the difference between the minimal luminal diameter (MLD) immediately after the procedure and the MLD at six months.

Patients were prospectively followed-up to evaluate the incidence of major adverse cardiovascular events (MACE), defined as death, myocardial infarction or target lesion revascularisation (TLR). Target lesion revascularisation (TLR) was defined as any surgical or percutaneous re-intervention motivated by a significant luminal narrowing within the stent or in the 5-mm distal or proximal persistent segments.

Statistical analysis

Discrete variables are reported as counts and relative percentages and compared with Fisher's exact test. Continuous variables are expressed as mean \pm standard deviation and compared with the Student *T* test. A *p* value < 0.05 was considered to be significant. All tests were two-tailed. Analyses were performed with SPSS version 8.0 statistical package (SPSS Inc. Chicago, IL, USA).

RESULTS

Baseline and procedural data

Baseline clinical characteristics of the 44 patients with ISR are shown in table 1. Diabetes was present in 25% of the patients. Clinical presentation was an acute coronary syndrome in 27% of cases. A quarter of the patients had previous recurrent episodes of ISR. According to the Mehran classification, 42% of the lesions were class I, 21% class II, 26% class III, and 11% class IV (table 2). Small vessel size (reference diameter < 2.5 mm) was present in 49%, long lesions (>20mm) in 30%, treatment of bypass grafts in 13%, and bifurcation stenting in 18%. The patients received on average 2.0 ± 1.4 stents, with a mean stent length per lesion of 28 ± 20 mm (range 8-84 mm). Direct stenting was performed in 13 lesions (24.5%). Seven lesions (13.2%) were pre-dilated with a cutting balloon. Endovascular ultrasound was used in 25% of

the procedures for stent sizing or to optimize the result. The procedure was successful in 43 patients (97.7%). One patient underwent emergency bypass surgery due to intimal dissection and acute vessel occlusion during the procedure.

Angiographic results

The pre-procedure, post-procedure and follow-up quantitative angiographic data are shown in table 3. Representative sequences of angiograms from two patients are shown in figure 1. Mean reference diameter was 2.64 ± 0.56 mm and mean lesion length was 17.5 ± 12.1 mm. Angiographic follow-up was obtained in 33 patients (77% of patients with successful index procedure) with 41 lesions (79%). Late loss was 0.17 ± 0.76 mm. Cumulative distribution curves of angiographic late loss (figure 2) show that the vast majority of the lesions (79%) had a late loss between -0.5 and $+0.5$ mm. Overall, post-SES binary restenosis was observed in 14.6% of the lesions. Table 4 shows the frequency of post-SES restenosis for some subgroups. No restenosis was observed in Mehran class I lesions; class II, III and IV lesions had post-SES restenosis in 22%, 25% and 20%, respectively ($p=NS$). In 5 out of 6 cases with post-SES restenosis the restenosis was focal or multifocal. For patients with post-SES restenosis, the average lesion length decreased from 31.7 ± 15.3 mm at baseline to 10.0 ± 4.8 mm at follow-up ($p=0.01$). One patient presented post-SES with silent total occlusion. Post-SES restenotic lesions were located within the SES in 5 lesions and at the proximal edge in the remaining 1. In two patients, post-SES restenosis occurred in an uncovered region injured during the procedure (gap between two SES implanted to treat two separate lesions in one patient and stent discontinuity by ultrasound examination due to possible stent fracture in another case).[15] Marked SES undersizing (stent diameter 2.7mm; vessel diameter 5.7mm) was found in another patient with post-SES restenosis.

The patients that developed post-SES restenosis had baseline clinical characteristics similar to the others. However, the lesions who developed binary restenosis were considerably longer (29.1 ± 15.0 mm vs 16.1 ± 11.0 , $p=0.01$), were treated with more stents (2.2 ± 0.7 vs 1.5 ± 0.7 , $p=0.04$), and the stented segment was longer (average stent length per lesion: 49.0 ± 30.0 mm vs 25.5 ± 16.3 mm, $p<0.01$) compared to lesions who presented less than 50% diameter stenosis at follow-up.

Clinical Follow-up

Complete clinical follow-up was available for 43 patients (98%). After 1 year, the cumulative incidence of MACE was 20.9%. There were no deaths, 2 patients had non-Q-wave myocardial infarction (4.7%), of which 1 peri-procedural and 1 after 7 months, and 7 patients (16.3%) underwent TLR (including the patient who underwent emergency CABG). Target lesion revascularisation due to restenosis was performed in 5 patients (11.6%). One additional target lesion revascularisation was performed 5 days after the index procedure in a patient with recurrent angina and intravascular ultrasound evidence of incomplete right coronary artery ostium coverage. All repeat revascularisations were within 7 months follow-up. There were no documented episodes of early or late stent thromboses. It is worth noting that patients who refused to undergo angiographic re-evaluation had no adverse events during follow-up.

DISCUSSION

The major finding of the present study is that routine sirolimus-eluting stent implantation for in-stent restenosis is safe and associated with low recurrence rates in a broad range of clinical and anatomical settings.

The present series comprises patients and lesions commonly not included in previous reports,[12][13] [16] such as very long lesions, chronic total occlusions, small vessels, bypass grafts, and bifurcations. In fact, the majority of patients in our consecutive series, representative of the everyday practice, presented at least one of the aforementioned characteristics. Despite the unselected nature of this population, clinical and angiographic outcomes appear superior to previous results for conventional approaches.[2] [18][19][20][21] Indeed, our findings compare favorably with those reported for vascular brachytherapy, which has been advocated as the treatment of choice for complex in-stent restenosis.[3][4][5][6][7] Moreover, SES implantation does not deviate from practice with conventional bare stents, and avoids most of the technical and logistical limitations that have hampered a more widespread use of brachytherapy.

The outcomes of patients with in-stent restenosis after repeat treatment have been reported to be closely related to the baseline lesion morphology.[2] A progressive increase in risk profile occurs from lesions with a focal pattern to lesions with a more diffuse appearance and total occlusions.[2] Accordingly, in our series, SES was associated with a remarkably low incidence of recurrent restenosis in focal lesions. Indeed, all cases of repeat restenosis occurred in patients with more complex baseline characteristics. However, no clear differences in the rates of repeat restenosis were noted among higher risk categories (i.e Mehran classes II, III, and IV), in whom the rates of repeat restenosis have been reported to be 35, 50 and 85%, respectively, with conventional therapy. Thus, it is possible that SES implantation may reduce the prognostic value of the lesion pattern of in-stent restenoses for non-focal ISR, although the limited number of our observations does not allow a definitive conclusion. Conversely, our data suggest that lesion length may still have an impact on recurrent restenosis. Recently, sirolimus-eluting stents have been consistently shown to reduce neointimal proliferation in ISR as effectively as in *de novo* lesions.[21] Instead of reflecting an intrinsic drug resistance, repeat restenosis in complex lesions may actually be more closely related to local mechanical conditions that impair the therapeutic effect of the device (p.e. incomplete coverage of balloon-injured areas of neointimal hyperplasia, under-expanded stents). In fact, a possible technical reason for failure was documented in 3 of 6 cases (50%) of recurrent restenosis in our series, although the significance of these findings remains elusive. Two recent reports have confirmed these observations in a larger number of patients treated with sirolimus-eluting stents. [22][23]

This study evaluates a relatively limited number of patients and lesions. However, this is the largest series of patients described to date (table 5). Moreover, to the best of our knowledge, this is the first study to assess the impact of sirolimus-eluting stent implantation in a broad range of different anatomical subsets of in-stent restenosis.

The rate of angiographic follow-up (79% of all lesions), although similar to other studies that enrolled patients with recurrent ISR, [3] [6][7] is not very high and could not represent the true binary restenosis for the entire cohort. This could be explained by the considerable number of recurrent restenosis and previous procedures suffered by some patients, therefore not willing to undergo 6-month angiography in the absence of symptoms. This was indirectly confirmed by the clinical follow-up of the patients who refused the angiographic control, who were all asymptomatic. Patients with failed brachytherapy were not included in the current report.

We have recently shown that recurrent in-stent restenosis following vascular brachytherapy may exhibit a peculiar and different biological and clinical response to sirolimus-eluting stent implantation,[24] therefore representing a potentially confounding factor if analyzed conjointly with patients without prior local irradiation.

CONCLUSIONS

Routine utilization of sirolimus-eluting stent implantation to treat in-stent restenosis appeared safe and effective in an unselected series of cases of in-stent restenosis, especially in patients with focal lesions. Sirolimus-eluting stent implantation also seems to be a promising strategy for complex in-stent restenosis. Further analysis with larger series and more prolonged follow-up, as well as a direct comparison with brachytherapy in a randomized fashion are needed to clarify the role of sirolimus-eluting stents in this context.

SOURCES OF FUNDING: This study was supported by health care funds allotted by Erasmus Medical Center (Erasmus University), Rotterdam, The Netherlands, and by an institutional research grant from Cordis Corporation, a Johnson & Johnson Company, Miami Lakes, FL, USA. Cordis Corporation did not have any role in the collection, management, and analysis of the data.

ACKNOWLEDGEMENTS

The authors would like to thank Dr. Brian Firth for his critical review of the manuscript.

REFERENCES

1. Lowe HC, Oesterle SN, Khachigian LM. Coronary in-stent restenosis: current status and future strategies. *J Am Coll Cardiol* 2002;**39**:183-193.
2. Mehran R, Dangas G, Abizaid AS, et al. Angiographic patterns of in-stent restenosis: classification and implications for long-term outcome. *Circulation* 1999;**100**:1872-1878.
3. Leon MB, Teirstein PS, Moses JW, et al. Localized intracoronary gamma-radiation therapy to inhibit the recurrence of restenosis after stenting. *N Engl J Med* 2001;**344**:250-256.
4. Teirstein PS, Massullo V, Jani S, et al. Catheter-based radiotherapy to inhibit restenosis after coronary stenting. *N Engl J Med* 1997;**336**:1697-1703.
5. Waksman R, White RL, Chan RC, et al. Intracoronary gamma-radiation therapy after angioplasty inhibits recurrence in patients with in-stent restenosis. *Circulation* 2000;**101**:2165-2171.
6. Waksman R, Bhargava B, White L, et al. Intracoronary beta-radiation therapy inhibits recurrence of in-stent restenosis. *Circulation* 2000;**101**:1895-1898.
7. Waksman R, Raizner AE, Yeung AC, Lansky AJ, Vandertie L, on behalf of the INHIBIT investigators. Use of localised intracoronary β radiation in the treatment of in-stent restenosis: the INHIBIT randomised controlled trial. *Lancet* 2002;**359**:551-557.
8. Morice MC, Serruys PW, Sousa JE, et al. A randomized comparison of a sirolimus-eluting stent with a standard stent for coronary revascularisation. *N Engl J Med* 2002;**346**:1773-1780.
9. Moses JW, Leon MB, Popma JJ, et al. Angiographic and Clinical Outcomes after a Sirolimus-Eluting Stent Compared to a Standard Stent in Patients with Native Coronary Artery Stenoses. *N Engl J Med* 2003; *in press*
10. Degertekin M, Serruys PW, Foley DP, et al. Persistent inhibition of neointimal hyperplasia after sirolimus-eluting stent implantation: long-term (up to 2 years) clinical, angiographic, and intravascular ultrasound follow-up. *Circulation* 2002;**106**:1610-1613.
11. Sousa JE, Costa MA, Sousa AG, et al. Two-year angiographic and intravascular ultrasound follow-up after implantation of sirolimus-eluting stents in human coronary arteries. *Circulation* 2003;**107**:381-383.
12. Degertekin M, Regar E, Tanabe K, et al. Sirolimus-eluting stent for treatment of complex in-stent restenosis. The first clinical experience. *J Am Coll Cardiol* 2003;**41**:184-189.
13. Sousa JE, Costa MA, Abizaid A, et al. Sirolimus-eluting stent for the treatment of in-stent restenosis: a quantitative coronary angiography and three-dimensional intravascular ultrasound study. *Circulation* 2003;**107**:24-27.
14. Lemos PA, Lee CH, Degertekin M, et al. Early outcome after sirolimus-eluting stent implantation in patients with acute coronary syndromes. Insights from the Rapamycin-Eluting Stent Evaluated At Rotterdam Cardiology Hospital (RESEARCH) Registry. *J Am Coll Cardiol* 2003;**41**:2093-9.
15. Sianos G, Hofma S, Ligthart J, et al. Stent fracture in the drug-eluting stent era. *Catheter Cardiovasc Interv* 2003; *in press*
16. Tanabe K, Serruys PW, Grube E, et al. TAXUS III trial. In-stent restenosis treated with stent-based delivery of paclitaxel incorporated in a slow-release polymer formulation. *Circulation* 2003;**107**:559-564.
17. Adamian M, Colombo A, Briguori C, et al. Cutting balloon angioplasty for the treatment of in-stent restenosis: a matched comparison with rotational atherectomy, additional stent implantation and balloon angioplasty. *J Am Coll Cardiol* 2001;**38**:672-679.
18. Alfonso F, Cequier A, Zueco J, et al. Stenting the stent: initial results and long-term clinical and angiographic outcome of coronary stenting for patients with in-stent restenosis. *Am J Cardiol* 2000;**85**:327-332.
19. Giri S, Ito S, Lansky AJ, et al. Clinical and angiographic outcome in the laser angioplasty for restenotic stents (LARS) multicenter registry. *Catheter Cardiovasc Interv* 2001;**52**:24-34.
20. vom Dahl J, Dietz U, Haager PK, et al. Rotational atherectomy does not reduce recurrent in-stent restenosis: results of the angioplasty versus rotational atherectomy for treatment of diffuse in-stent restenosis trial (ARTIST). *Circulation* 2002;**105**:583-588.

Chapter 2

21. Degertekin M, Lemos PA, Lee CH, et al. Comparative efficacy of sirolimus eluting stent for treatment of in-stent restenosis versus de novo coronary lesions. An intravascular ultrasound study. *Eur Heart J* 2003; *in press*.
22. Colombo A, Orlic D, Stankovic G, et al. Preliminary observations regarding angiographic pattern of restenosis after rapamycin-eluting stent implantation. *Circulation* 2003;**107**:2178-2180
23. Lemos PA, Saia F, Ligthart JM, et al. Coronary restenosis after sirolimus-eluting stent implantation: morphological description and mechanistic analysis from a consecutive series of cases. *Circulation* 2003;**108**:257-260.
24. Saia F, Lemos PA, Sianos G, et al. Effectiveness of sirolimus-eluting stent implantation for recurrent in-stent restenosis after brachytherapy. *Am J Cardiol* 2003;**92**:200-203

FIGURE LEGEND

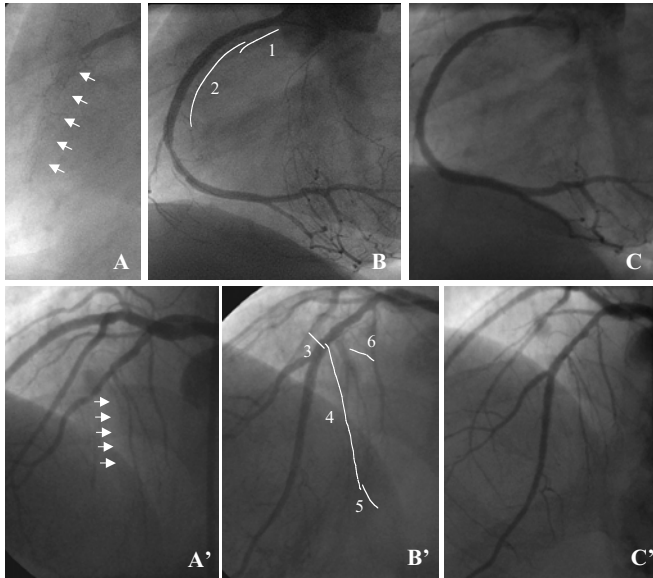


Figure 1. Sirolimus-eluting stent implantation for total occlusion due to in-stent restenosis: representative sequences of angiograms from two patients. Patient 1. A. Diagnostic angiogram showing total occlusion of the proximal right coronary artery due to ISR (arrows). B. Final result after implantation of two overlapping SES, 3x18 mm proximal (1), and 3x33 mm distal (2). Some minimal residual stenosis is visible at the distal stent edge. C. Six-month angiographic follow-up showing persistence of the good result obtained previously. Patient 2. A'. Diagnostic angiogram showing in-stent restenosis giving total occlusion of the mid part of the left anterior descending artery (LAD) (arrows), immediately after the origin of the second diagonal branch. B'. Final result after implantation of three overlapping SES in the LAD, 2.75x8 mm proximal (3), 2.5x33 mm in the middle (4), and 2.25x8 mm distal (5). Bifurcation stenting was necessary to preserve the second diagonal (6, SES 2.25x8 mm). C'. Six-month angiographic follow-up showing persistence of the good result in both vessels.

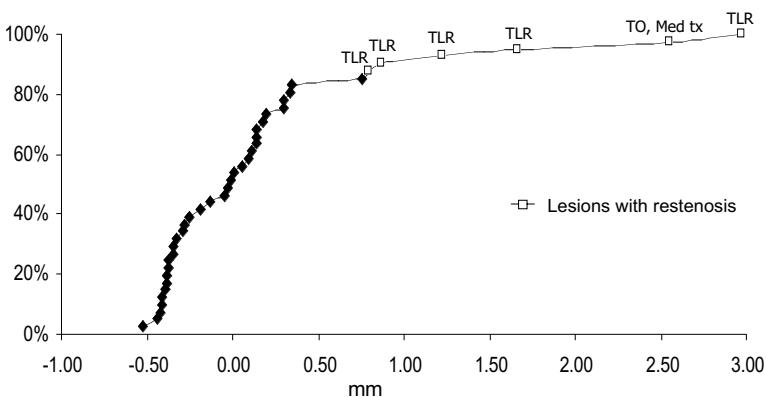


Figure 2. Cumulative distribution of late loss at angiographic follow-up. Lesions with binary restenosis are indicated by empty squares. Clinical outcome of each restenotic lesion is reported corresponding to the respective late loss value. This curve resembles a bimodal distribution and suggests that the failures cases might share unique features.

TABLES

Table 1. Baseline patient characteristics

Patients	44
Age, years±SD	63±13
Men	73%
Risk Factors	
Current smoker	27%
Hypercholesterolemia*	68%
Systemic hypertension	48%
Diabetes mellitus	25%
Family history of coronary heart disease	43%
Clinical Presentation	
Silent ischemia	9%
Stable angina pectoris	64%
Unstable angina pectoris	25%
Acute myocardial infarction	2%
Multivessel coronary disease	50%
Previous myocardial infarction	52%
Previous coronary bypass	23%
Recurrent episodes of in-stent restenosis (>1)	25%

*Total cholesterol > 200mg/dl and/or on lipid lowering treatment

Table 2. Angiographic and procedural characteristics

Lesions	53
Target coronary artery	
Left anterior descending	49%
Left circumflex artery	11%
Right coronary artery	26%
Left main	2%
Saphenous vein graft	9%
Left internal mammary artery	2%
Mehran class	
I (Focal)	42%
II (Diffuse)	21%
III (Proliferative)	26%
IV (Total occlusion)	11%
Small vessel size*	49%
Bifurcation stenting†	18%
Multivessel stenting†	25%
Glycoprotein IIb/IIIa inhibitor†	9%
Stent length per lesion, mm	28 ± 20
Stents per patient, n	2.0 ± 1.4

*pre-procedure reference diameter ≤ 2.5 mm

†percentages relative to the number of patients

Table 3. Quantitative angiographic analysis at baseline, post-procedure and follow-up*.

	Pre-procedure	Post-procedure	Follow-up
Reference diameter, mm	2.64±0.56	2.73±0.54	2.83±0.50
Minimum lumen diameter, mm	0.90±0.55	2.33±0.59	2.20±0.81
Diameter stenosis, %	66±19	16±15	23±25
Lesion length, mm	17.5±12.1	-	-
Acute gain, mm	-	1.42±0.70	-
Late loss, mm	-	-	0.17±0.76
Late loss excluding occlusions, mm	-	-	0.11±0.67
Binary post-SES restenosis†, %			14.6

SES=sirolimus-eluting stent

*related to 41 lesions with angiographic follow-up

†including one total re-occlusion

Table 4. Binary post-SES restenosis in subgroups*

	Post-SES restenosis
Total population (n=41)	14.6 %
Diabetics (n=8)	25.0 %
Small vessel size (n=20) †	10.0 %
Vein grafts (n=5)	20.0 %
Lesion length > 20mm (n=14)	28.6 %
Bifurcating stents‡ (n=7)	14.3 %
Mehran class ²	
Type I (n=15)	0
Type II (n=9)	22.2 %
Type III (n=12)	25.0 %
Type IV (n=5)	20.0 %

Between brackets are reported the numbers of lesions with angiographic follow-up

* related to 41 lesions with angiographic follow-up

† pre-procedure reference diameter ≤ 2.5 mm

‡ this datum refers only to the in-stent restenosis lesions; in these series, there was no case of restenosis in the side-branches treated for de novo lesions.

Table 5. Eluting-stents implantation for in-stent restenosis: angiographic results of the principal studies.

	TAXUS-III ¹⁶	FIM – Rotterdam ¹²	FIM - São Paulo ¹³	ISR post-brachytherapy ²⁴	R E S E A R C H Registry
Drug	Paclitaxel	Sirolimus	Sirolimus	Sirolimus	Sirolimus
Patients	28	16	25	12	44
Inclusion criteria	- Single lesion - native coronary artery - Vessel size 3.0 - 3.5 mm	- Single lesion - native coronary artery - Vessel size 2.5 - 3.5 mm	- Single lesion - native coronary artery - Vessel size 2.5 - 3.5 mm	- Previous brachytherapy	- All clinical and anatomical conditions
Exclusion criteria	- Acute myocardial infarction - Lesion > 30 mm in length - Total occlusion - LVEF<30% - renal dysfunction	- Saphenous vein graft	- Previous brachytherapy - Lesion > 36 mm in length - Total occlusion		- Previous brachytherapy
Reference diameter	2.75±1.20	2.68±0.33	2.78±0.30	2.83±0.48	2.64±0.56
Lesion length	13.6 ± 6.4	18.4 ± 13.1	13.6 ± 7.65	-	17.5 ± 12.1
Stent length	22 ± 8	28 ± 18	22 ± 7	34 ± 30	28 ± 20
Time of follow-up	6 months	6 months	4 months	6 months	6 months
Late loss*	0.54 ± 0.51 [†]	0.26 ± 0.67	-0.05±0.30	0.68 ± 1.2	0.17 ± 0.76
Binary restenosis*	16.0%	20.0%	0%	40.0%	14.6%

* in-stent plus 5-mm segment proximal and distal to the stent
[†]in-stent only

PART 1

DRUG-ELUTING STENTS TO TREAT IN-STENT RESTENOSIS

CHAPTER 3

Clinical Outcomes for Sirolimus-Eluting Stent Implantation and Vascular Brachytherapy for the Treatment of In-Stent Restenosis

Authors: Francesco Saia, Pedro A. Lemos, Angela Hoye, Georgios Sianos, Chourmouzos A Arampatzis, Pim J. de Feyter, Willem J. van der Giessen, Pieter C. Smits, Ron T. van Domburg, Patrick W. Serruys.

Catheter Cardiovasc Interv. 2004;62:283-8.

CHAPTER 3

Clinical outcomes for sirolimus-eluting stent implantation and vascular brachytherapy for the treatment of in-stent restenosis

Francesco Saia, MD, Pedro A. Lemos, MD, Angela Hoye, MB, ChB, MRCP, Georgios Sianos, MD, PhD, Chourmouzos A. Arampatzis, MD, Pim J. de Feyter, MD, PhD, Willem J. van der Giessen, MD, PhD, Pieter C. Smits, MD, PhD, Ron T. van Domburg, PhD, Patrick W. Serruys, MD, PhD

Erasmus University Medical Center, Thoraxcenter, Rotterdam, The Netherlands

Address for correspondence:

Prof. Patrick W. Serruys
Erasmus MC, Thoraxcenter, Kamer Bd 404
Dr. Molewaterplein 40
3015 GD Rotterdam, The Netherlands
Tel: 0031.10.4635260 Fax: 0031.10.4369154
e-mail: p.w.j.c.serruys@erasmusmc.nl

Short title: Sirolimus eluting-stent vs brachytherapy for ISR

Word count: 4357

ABSTRACT

Purpose: To compare the mid-term clinical outcome of sirolimus-eluting stent (SES) implantation and vascular brachytherapy (VBT) for in-stent restenosis (ISR).

Methods: We assessed the 9-month occurrence of major adverse cardiac events (MACE) in 44 consecutive patients with ISR treated with SES implantation, and 43 consecutive patients treated with VBT in the period immediately prior.

Results: Baseline clinical and angiographic characteristics of the two groups were similar. During follow-up, 3 patients (7%) died in the VBT group and 0 in the SES group. The incidence of myocardial infarction was 2.3% in both groups. Target lesion revascularization was performed in 11.6% of the VBT patients and 16.3% of the SES patients ($p=NS$). The 9-month MACE-free survival was similar in both groups (79.1% VBT vs 81.5% SES; $p=0.8$ by log rank).

Conclusions: The result of this non-randomized study suggests that sirolimus-eluting stent implantation is at least as effective as vascular brachytherapy in the treatment of in-stent restenosis.

Keywords: sirolimus, eluting-stent, in-stent restenosis

INTRODUCTION

In-stent restenosis (ISR) represents the major limitation of coronary stenting (1). Treatment of ISR with conventional strategies is limited by the high rate of recurrence, which gradually increase from focal lesions to proliferative patterns and total occlusions (2).

The “mechanical” approach to treat ISR, with utilization of additional stents or debulking devices, has failed to show substantial benefits (3-6). Vascular brachytherapy (VBT), by targeting the “biological” component of neointimal proliferation, is the only strategy proven to be effective in randomized trials (7-11). However, its utilization is limited by complex logistic requirements and the necessity of highly trained operators. Moreover, recurrent restenosis still occurs in approximately one third of the patients treated with vascular brachytherapy (7-11).

Sirolimus- (12-13) and paclitaxel-eluting stents (14) have been shown in randomized trials to strongly suppress the development of neointimal hyperplasia in selected *de novo* lesions compared to bare stents. Also, promising results have been recently reported with drug-eluting stents for the treatment of in-stent restenosis, especially for patients with less complex forms of restenosis (15-17). A relatively low incidence of repeat restenosis has been shown after drug-eluting stent implantation in these preliminary series of cases. However, to date, the clinical efficacy of this new therapeutic approach has not been compared to conventional percutaneous techniques or to the “gold standard” vascular brachytherapy.

In this study we therefore aimed to comparatively evaluate the outcomes of patients with in-stent restenosis treated with sirolimus-eluting stent implantation or with catheter-based brachytherapy.

METHODS

Patient population

Since the 16th of April 2002, we have adopted a policy of sirolimus-eluting stent implantation for all patients undergoing percutaneous coronary interventions at our institution, as previously described elsewhere (18). In the first six months enrollment, 44 consecutive patients with in-stent restenosis and no previous brachytherapy at the same site were treated with SES implantation (SES group). A comparison group was composed by 43 patients treated with vascular brachytherapy (group VBT) in the months immediately prior, between 1st January 2001 and 15th of April 2002. This time period was selected to approximately match the number of patients with brachytherapy with the number of patients treated with sirolimus-eluting stent. All patients treated with both modalities were included in the present report. Informed, written consent was obtained from all patients.

Procedures

All patients were pre-treated with aspirin (at least 75 mg/d) and clopidogrel (75 mg/d or 300 mg bolus). During the procedure weight-adjusted heparin was administered to achieve an activated clotting time of >300 sec. Vascular brachytherapy was performed in all patients with catheter-delivered beta-radiation. Two systems were used during the study period: Betacath™ (Novoste,

Norcross, GA), and Galileo™ (Guidant corporation, Santa Clara, CA, USA), which have been described in detail elsewhere (11, 19). Operators were strongly advised to avoid implantation of new stents (20), and to avoid insufficient radiation dose delivery to injured areas (geographic miss) (21). Clopidogrel prescription was decided on an individual patient basis by the attending interventional cardiologist according to current practice guidelines. In the SES group, restenotic lesions were treated with implantation of the Cypher™ sirolimus-eluting stent (Cordis Europa NV, Roden, NL). Complete lesion coverage by this stent was recommended. In case additional stents were needed, care was taken to avoid gaps between adjacent stents. The final treatment strategy and device utilization other than SES were left to the operator's discretion. At least 3 months of clopidogrel treatment was prescribed thereafter. In both study periods, periprocedural adjunctive medications were left to the discretion of the operator.

Definitions and follow-up

ISR was defined as a significant stenosis within a previous stented segment on visual assessment, together with objective evidence of ischemia. The lesions were angiographically classified according to Mehran et al. (2) by two independent operators. The primary composite endpoint was the incidence of major adverse cardiovascular events (MACE) during 9 months of follow-up, defined as death, myocardial infarction or target lesion revascularization (either percutaneous or surgical). The diagnosis of myocardial infarction was based on an increased level of creatine kinase to more than twice the upper limit of normal with an increased level of creatine kinase-MB isoform. Target lesion revascularization (TLR) was defined, for the patients in the brachytherapy group, as any surgical or percutaneous re-intervention due to restenosis within the irradiated segment or the 5mm proximal or distal segments, and for the patients in the SES group as any revascularization in the stent and in the 5 mm proximal and distal segments. Target vessel revascularization (TVR) was defined as any re-intervention driven by lesions located in the treated vessel beyond the target lesion limits. Survival status at follow-up was assessed by written inquires to the Municipal Civil Registries. Repeat revascularization procedures and episodes of acute myocardial infarction were prospectively collected in the hospital data base. For patients admitted to peripheral hospitals in the acute phase, the diagnosis of myocardial infarction was confirmed by the referring physician based on the same criteria. All re-interventions were prospectively collected in a dedicated electronic database.

Statistical methods

Discrete variables were presented as count and relative percentages and compared with Fisher exact tests or Chi-square. Continuous variables were presented as mean and standard deviations and compared with Student *t* test. Event-free survivals were calculated according to the Kaplan-Meier method and compared by the log-rank test. All tests were two-tailed, and a *p* value <0.05 was considered as significant.

RESULTS

Baseline characteristics

The baseline characteristics of the two groups were similar (table 1). Specifically, no difference was observed in the incidence of diabetes (26% VBT vs 25% SES; *p*=0.1), previous myocardial infarction (47% VBT vs 52% SES; *p*=0.6), previous coronary artery bypass graft (CABG) surgery

(21% VBT vs 23% SES; $p=0.8$), or multivessel disease (47% VBT vs 50% SES; $p=0.7$). The majority of the patients in both groups had stable angina at hospital admission (79% VBT vs 73% SES; $p=0.5$). Almost all patients in the VBT group had single-lesion brachytherapy, except by one patient with 2 lesions treated. In the SES group, 53 ISR lesions were treated (1.2 ± 0.5 lesion per patient). In the SES group there were more lesions classified as Mehran type I (23% VBT vs 42% SES; $p=0.05$), whilst type II was more common in the VBT group (43% VBT vs 21% SES; $p=0.02$). However, both treatment groups had similar numbers of lesions with non-complex (Mehran Type I/II: 66% VBT vs 63% SES) or complex (Mehran Type III/IV: 34% VBT vs 37% SES; $p=0.7$ for all) morphologies. Quantitative coronary analysis did not show significant differences in baseline lesions' characteristics between the two groups (table 2). Average lesion length was 15.7 ± 10.4 mm in the VBT group and 17.5 ± 12.1 mm in the SES group ($p=0.4$). As expected, post-procedure minimal lumen diameter was bigger (1.84 ± 0.41 mm VBT vs 2.33 ± 0.59 mm SES; $p=0.0008$) and diameter stenosis smaller (28 ± 12 % VBT vs 16 ± 15 % SES; $p=0.004$) in the SES group.

In the VBT group average irradiated length was 48 ± 12 mm, and average radiation dose administered was 23 ± 2 Gy. A new stent was implanted in 27% of the VBT patients. In the SES group each patient received on average 2.0 ± 1.4 stents, with a mean stent length of 28 ± 20 mm per lesion. In the VBT group periprocedural glycoprotein IIb/IIIa inhibitors utilization was more common (33% vs 9%; $p=0.007$), and clopidogrel prescription longer (7.5 ± 5.5 months vs 5.9 ± 2.6 months; $p=0.005$).

Clinical outcome

Complete information at follow-up was available in 100% of VBT patients and 97.7% of SES patients (1 patient moved abroad and was lost to follow-up). During nine months of follow-up, 3 patients (7%) died in the VBT group and 0 in the SES group ($p=0.08$ by log rank)(table 3). They were all thought to be cardiac deaths: one patient with previous CABG operation developed severe hypotension after balloon angioplasty and irradiation of the right coronary artery and died 2 days after the procedure; two patients had a sudden death 3 months after treatment of a lesion in the proximal left anterior descending while still on combined antiplatelet treatment (one of them had a new stent implanted during the brachytherapy procedure). Subacute stent thrombosis could not be ruled out in these last 2 cases. A definite diagnosis of acute MI was made in 1 patient in each group. Target lesion revascularization was performed in 5 patients (11.6%) in the VBT group, and 7 patients (16.3%) in the SES group ($p=NS$). In the VBT group these recurrent restenosis were treated with 2 CABG operations, 1 balloon angioplasty, 1 stent implantation, and 1 sirolimus-eluting stent implantation. In the SES group 1 patient underwent emergency CABG surgery for vessel dissection and acute occlusion during treatment of a lesion in the proximal left circumflex artery, and the remaining 6 TLRs were accomplished percutaneously (3 with additional SES implantation, 3 with taxol-eluting stent implantation). Overall, the MACE-free survival at 9 months was similar in both groups (79.1% VBT vs 81.5% SES; $p=0.8$ by log rank) (figure 1).

DISCUSSION

Vascular brachytherapy has been rightly considered the gold-standard treatment for in-stent restenosis, at the least for more complex cases, after several randomized trials have shown

its superiority over other conventional approaches (7-11). Despite these favorable results, brachytherapy has not been widely utilized, being still currently restricted, at least in Europe, to a limited number of centers. Complex logistic and technical requirements, as well as lack of reimbursement in some countries, have limited a more generalized utilization of brachytherapy. Furthermore, the identification of possible shortcomings such as geographical miss (21) and delayed re-endothelialization, which is associated with an increased risk of subacute thrombosis especially when a new stent is implanted (22), have made mandatory a specific training for the operators involved in brachytherapy procedures.

In the present study, treatment of in-stent restenosis with sirolimus-eluting stents was associated with similar clinical results at 9 months compared to vascular brachytherapy. These findings are of potential major interest. Routine utilization of sirolimus-eluting stent implantation does not deviate from the standard practice with conventional bare stents. Indeed, no additional requirements are needed to readily apply this new therapy at any catheterization laboratory.

Widespread utilization of drug-eluting stents is expected to change the current scenario, by reducing ISR to a minority of patients. (12,23) Moreover, recurrent restenosis after drug-eluting stent implantation presents peculiar characteristics, such as predominantly focal pattern, (24,25) which could improve its response to the various percutaneous treatments. However, despite the enthusiasm raised by the publication of the first clinical studies, drug-eluting stent penetration in common practice is still limited by cost restraints (26), and ISR remains the major limitation of PCI. In this early drug-eluting stents era, "provisional" SES utilization in case of bare stent failure is appealing and, based on the results of the present study and two prior reports (15,16), seems to be a feasible and effective strategy.

In the evaluation of our results, two additional pieces of information should be taken into account. Although not statistically significant, a slightly higher rate of TLR was observed in the SES group. However, in this group routine angiographic follow-up was scheduled by protocol, and performed in 77% of the patients, while only a minority of patients in the VBT group underwent elective angiography (30%). We have previously shown that angiographic follow-up have a negative impact on clinical outcome due to more repeat revascularization procedures ("oculostenotic reflex") (27). Furthermore, a late "catch-up" phenomenon (continuous increasing of angiographic late-loss after 6 months) has been reported for VBT (28,29), while data regarding SES for both de novo (30) and ISR (16) lesions suggest that the early results are predictive of the long-term findings. On the other hand, although not statistically significant, we observed an increased mortality in the brachytherapy group (VBT: 7%; SES: 0%; $p=0.08$), suggesting once again the possibility of serious adverse events related to the prolonged endothelial damage after vessel irradiation.

Study limitations

Our study presents a number of limitations that suggest some caution when interpreting the results. First of all, the two groups were not randomized, and were treated in different time periods. Moreover, while the SES group was composed of a consecutive series of patients, the patients undergoing VBT group were selected by the operators based on clinical and morphological consideration. Accordingly, more patients in the SES group presented Mehran type I lesions (23% VBT vs 42% SES), because in the VBT phase most of these patients underwent percutaneous re-intervention with conventional techniques. However, we cannot ignore the fact that baseline clinical characteristics of the 2 cohorts of patients were remarkably similar. Additionally, if we consider together lesions of Mehran class I and II, the difference among

the two groups disappears (66% VBT vs 63% SES; $p=0.7$). This was indirectly confirmed by the lack of difference in lesion length between the two groups. Other imbalances were observed in procedural characteristics and peri-procedural medications. The higher rate of glycoprotein IIb/IIIa inhibitors in the VBT-treated patients, and the longer clopidogrel prescription in the same group, could have generated a clinical advantage, especially in those with acute coronary syndromes (31,32). More lesions were treated per patient in the SES group; while on one side this strategy could favour recurrent restenosis and repeat revascularizations, especially in patients with angiographic follow-up, on the other side a possible positive impact of a more complete revascularization on clinical outcome cannot be ruled out.

Another limitation is represented by the low number of patients in both groups. It should be noticed, however, that the present study is, to the best of our knowledge, the first comparison between VBT and SES in the treatment of ISR, and in this setting the study which included the higher number of patients treated with SES reported so far (15,16). Moreover, the first randomized trial comparing vascular brachytherapy with conventional balloon dilatation included only 55 patients (8).

CONCLUSIONS

In this study, routine sirolimus-eluting stent implantation to treat in-stent restenosis appeared at least as effective as vascular brachytherapy in the treatment of in-stent restenosis, with the advantage of simpler logistic and technical requirements. Further prospective, randomized investigation with larger study population and longer follow-up are mandatory to confirm these findings.

REFERENCES

1. Lowe HC, Oesterle SN, Khachigian LM. Coronary in-stent restenosis: current status and future strategies. *J Am Coll Cardiol* 2002;39:183-193.
2. Mehran R, Dangas G, Abizaid AS, Mintz GS, Lansky AJ, Satler LF, Pichard AD, Kent KM, Stone GW, Leon MB. Angiographic patterns of in-stent restenosis: classification and implications for long-term outcome. *Circulation* 1999;100:1872-1878.
3. Adamian M, Colombo A, Briguori C, Nishida T, Marsico F, Di Mario C, Albiero R, Moussa I, Moses JW. Cutting balloon angioplasty for the treatment of in-stent restenosis: a matched comparison with rotational atherectomy, additional stent implantation and balloon angioplasty. *J Am Coll Cardiol* 2001;38:672-679.
4. Giri S, Ito S, Lansky AJ, Mehran R, Margolis J, Gilmore P, Garratt KN, Cummins F, Moses J, Rentrop P, Oesterle S, Power J, Kent KM, Satler LF, Pichard AD, Wu H, Greenberg A, Bucher TA, Kerker W, Abizaid AS, Saucedo J, Leon MB, Popma JJ. Clinical and angiographic outcome in the laser angioplasty for restenotic stents (LARS) multicenter registry. *Catheter Cardiovasc Interv* 2001;52:24-34.
5. vom Dahl J, Dietz U, Haager PK, Silber S, Niccoli L, Buettner HJ, Schiele F, Thomas M, Commeau P, Ramsdale DR, Garcia E, Hamm CW, Hoffmann R, Reineke T, Klues HG. Rotational atherectomy does not reduce recurrent in-stent restenosis: results of the angioplasty versus rotational atherectomy for treatment of diffuse in-stent restenosis trial (ARTIST). *Circulation* 2002;105:583-588.
6. Alfonso F, Cequier A, Zueco J, Moris C, Suarez CP, Colman T, Esplugas E, Perez-Vizcayno MJ, Fernandez C, Macaya C. Stenting the stent: initial results and long-term clinical and angiographic outcome of coronary stenting for patients with in-stent restenosis. *Am J Cardiol* 2000;85:327-332.
7. Leon MB, Teirstein PS, Moses JW, Tripuraneni P, Lansky AJ, Jani S, Wong SC, Fish D, Ellis S, Holmes DR, Kerieakes D, Kuntz RE. Localized intracoronary gamma-radiation therapy to inhibit the recurrence of restenosis after stenting. *N Engl J Med* 2001;344:250-256.
8. Teirstein PS, Massullo V, Jani S, Popma JJ, Mintz GS, Russo RJ, Schatz RA, Guarneri EM, Steuterman S, Morris NB, Leon MB, Tripuraneni P. Catheter-based radiotherapy to inhibit restenosis after coronary stenting. *N Engl J Med* 1997;336:1697-1703.
9. Waksman R, White RL, Chan RC, Bass BG, Geirlach L, Mintz GS, Satler LF, Mehran R, Serruys PW, Lansky AJ, Fitzgerald P, Bhargava B, Kent KM, Pichard AD, Leon MB. Intracoronary gamma-radiation therapy after angioplasty inhibits recurrence in patients with in-stent restenosis. *Circulation* 2000;101:2165-2171.
10. Waksman R, Bhargava B, White L, Chan RC, Mehran R, Lansky AJ, Mintz GS, Satler LF, Pichard AD, Leon MB, Kent KK. Intracoronary beta-radiation therapy inhibits recurrence of in-stent restenosis. *Circulation* 2000;101:1895-1898.
11. Raizner AE, Oesterle SN, Waksman R, Serruys PW, Colombo A, Lim YL, Yeung AC, van der Giessen WJ, Vandertie L, Chiu JK, White LR, Fitzgerald PJ, Kaluza GL, Ali NM. Inhibition of restenosis with beta-emitting radiotherapy: Report of the Proliferation Reduction with Vascular Energy Trial (PREVENT). *Circulation* 2000;102:951-958.
12. Morice MC, Serruys PW, Sousa JE, Fajadet J, Ban Hayashi E, Perin M, Colombo A, Schuler G, Barragan P, Guagliumi G, Molnar F, Falotico R. A randomized comparison of a sirolimus-eluting stent with a standard stent for coronary revascularization. *N Engl J Med* 2002;346:1773-1780.
13. Moses JW, Leon MB, Popma JJ, Fitzgerald PJ, Holmes DR, O'Shaughnessy C et al. for the SIRIUS investigators. Angiographic and clinical outcomes after a sirolimus-eluting stent compared to a standard stent in patients with native coronary artery stenoses. *N Engl J Med* 2003; 349:1315-1323.
14. Colombo A, Drzewiecki J, Banning A, Grube E, Hauptmann K, Silber S, Dudek D, Fort S, Schiele F, Zmudka K, Guagliumi G, Russell ME, for the TAXUS II Study Group. Randomized Study to Assess the Effectiveness of Slow- and Moderate-Release Polymer-Based Paclitaxel-Eluting Stents for Coronary Artery Lesions. *Circulation* 2003;108:788-794.

15. Degertekin M, Regar E, Tanabe K, Smits PC, van der Giessen WJ, Carlier SG, de Feyter P, Vos J, Foley DP, Ligthart JM, Popma JJ, Serruys PW. Sirolimus-eluting stent for treatment of complex in-stent restenosis. The first clinical experience. *J Am Coll Cardiol* 2003;41:184-189.
16. Sousa JE, Costa MA, Abizaid A, Sousa AG, Feres F, Mattos LA, Centemero M, Maldonado G, Abizaid AS, Pinto I, Falotico R, Jaeger J, Popma JJ, Serruys PW. Sirolimus-eluting stent for the treatment of in-stent restenosis: a quantitative coronary angiography and three-dimensional intravascular ultrasound study. *Circulation* 2003;107:24-27.
17. Tanabe K, Serruys PW, Grube E, Smits PC, Selbach G, van der Giessen WJ, Staberock M, de Feyter P, Müller R, Regar E, Degertekin M, Ligthart JMR, Disco C, Backx B, Russell ME. TAXUS III Trial. In-Stent Restenosis Treated With Stent-Based Delivery of Paclitaxel Incorporated in a Slow-Release Polymer Formulation. *Circulation* 2003;107:559-64.
18. Lemos PA, Lee C, Degertekin M, Saia F, Tanabe K, Arampatzis CA, Hoye A, van Duuren M, Sianos G, Smits PC, de Feyter P, van der Giessen WJ, van Domburg RT, Serruys PW. Early outcome after sirolimus-eluting stent implantation in patients with acute coronary syndromes. Insights from the Rapamycin-Eluting Stent Evaluated At Rotterdam Cardiology Hospital (RESEARCH) registry. *J Am Coll Cardiol* 2003;41:2093-2099.
19. King SB, 3rd, Williams DO, Chougule P, Klein JL, Waksman R, Hilstead R, Macdonald J, Anderberg K, Crocker IR. Endovascular beta-radiation to reduce restenosis after coronary balloon angioplasty: results of the beta energy restenosis trial (BERT). *Circulation* 1998;97:2025-2030.
20. Waksman R, Bhargava B, Mintz GS, Mehran R, Lansky AJ, Satler LF, Pichard AD, Kent KM, Leon MB. Late total occlusion after intracoronary brachytherapy for patients with in-stent restenosis. *J Am Coll Cardiol* 2000;36:65-68.
21. Sabate M, Costa MA, Kozuma K, Kay IP, van der Giessen WJ, Coen VL, Ligthart JM, Serrano P, Levendag PC, Serruys PW. Geographic miss: a cause of treatment failure in radio-oncology applied to intracoronary radiation therapy. *Circulation* 2000;101:2467-2471.
22. Costa MA, Sabate M, van der Giessen WJ, Kay IP, Cervinka P, Ligthart JM, Serrano P, Coen VL, Levendag PC, Serruys PW. Late coronary occlusion after intracoronary brachytherapy. *Circulation* 1999;100:789-792.
23. Grube E, Silber S, Hauptmann KE, Mueller R, Buellesfeld L, Gerckens U, Russell ME. TAXUS I: six- and twelve-month results from a randomized, double-blind trial on a slow-release paclitaxel-eluting stent for de novo coronary lesions. *Circulation* 2003;107:38-42.
24. Colombo A, Orlic D, Stankovic G, Corvaja N, Spanos V, Montorfano M, Liistro F, Carlino M, Airoldi F, Chieffo A, Di Mario C. Preliminary observations regarding angiographic pattern of restenosis after rapamycin-eluting stent implantation. *Circulation* 2003;107:2178-2180.
25. Lemos PA, Saia F, Ligthart JM, Arampatzis CA, Sianos G, Tanabe K, Hoye A, Degertekin M, Daemen J, McFadden E, Hofma S, Smits PC, De Feyter P, Van Der Giessen WJ, Van Domburg RT, Serruys PW. Coronary Restenosis After Sirolimus-Eluting Stent Implantation. Morphological Description and Mechanistic Analysis From a Consecutive Series of Cases. *Circulation* 2003.
26. Lemos PA, Serruys PW, Sousa JE. Drug-eluting stents: cost versus clinical benefit. *Circulation* 2003;107:3003-3007.
27. Ruygrok PN, Melkert R, Morel MA, Ormiston JA, Bar FW, Fernandez-Aviles F, Suryapranata H, Dawkins KD, Hanet C, Serruys PW. Does angiography six months after coronary intervention influence management and outcome? Benestent II Investigators. *J Am Coll Cardiol* 1999;34:1507-1511.
28. Teirstein PS, Massullo V, Jani S, Popma JJ, Russo RJ, Schatz RA, Guarneri EM, Steuterman S, Sirkin K, Cloutier DA, Leon MB, Tripuraneni P. Three-year clinical and angiographic follow-up after intracoronary radiation : results of a randomized clinical trial. *Circulation* 2000;101:360-365.
29. Kay IP, Wardeh AJ, Kozuma K, Foley DP, Knook AH, Thury A, Sianos G, van der Giessen WJ, Levendag PC, Serruys PW. Radioactive stents delay but do not prevent in-stent neointimal hyperplasia. *Circulation* 2001;103:14-17.

30. Degertekin M, Serruys PW, Foley DP, Tanabe K, Regar E, Vos J, Smits PC, van der Giessen WJ, van den Brand M, de Feyter P, Popma JJ. Persistent inhibition of neointimal hyperplasia after sirolimus-eluting stent implantation: long-term (up to 2 years) clinical, angiographic, and intravascular ultrasound follow-up. *Circulation* 2002;106:1610-1613.
31. Lincoff AM, Califf RM, Topol EJ. Platelet glycoprotein IIb/IIIa receptor blockade in coronary artery disease. *J Am Coll Cardiol* 2000;35:1103-1115.
32. Yusuf S, Zhao F, Mehta SR, Chrolavicius S, Tognoni G, Fox KK. Effects of clopidogrel in addition to aspirin in patients with acute coronary syndromes without ST-segment elevation. *N Engl J Med* 2001;345:494-502.

Figure 1. Kaplan-Meier curves of survival-free from major adverse cardiac events (MACE) in the brachytherapy (VBT) and in the sirolimus-eluting stent (SES) groups.

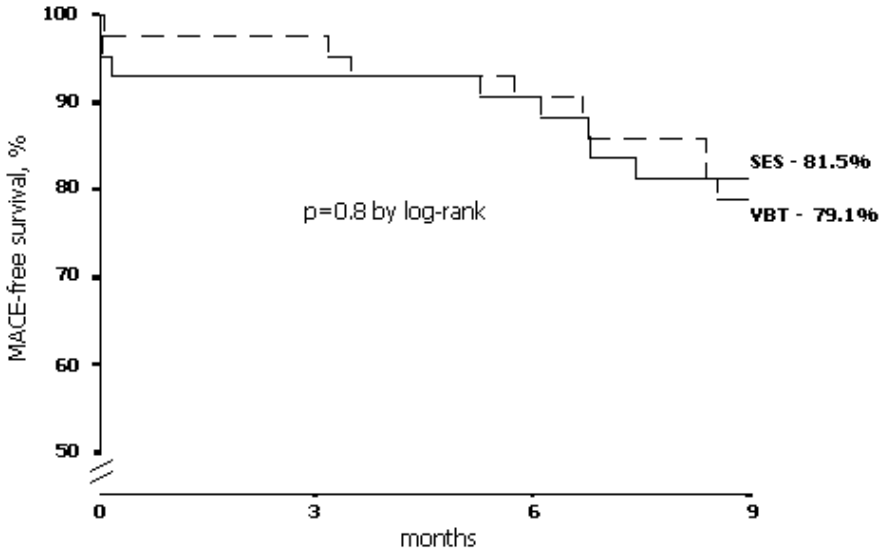


Table 1. Baseline clinical characteristics and demographics of the two study cohorts.

	VBT (n. 43)	SES (n. 44)	p value
Age, y	61±10	63±13	ns
Males, n (%)	31 (73)	32 (73)	ns
Diabetes Mellitus, n (%)	11 (26)	11 (25)	ns
Hypertension, n (%)	13 (30)	21 (48)	ns
Hypercholesterolemia, n (%)	26 (60)	30 (68)	ns
Previous MI, n (%)	20 (47)	23 (52)	ns
Previous CABG, n (%)	9 (21)	10 (23)	ns
Multivessel disease, n (%)	20 (47)	22 (50)	ns
Clinical presentation, n (%)			ns
Stable Angina	34 (79)	32 (73)	
ACS	9 (21)	12 (27)	
Number of ISR lesions treated	44	53	-
ISR lesions treated per patient	1.0 ± 0.2	1.2 ± 0.5	0.02
Target Vessel, n (%)			ns
LAD	16 (36)	26 (49)	
LCX	9 (20)	6 (11)	
RCA	15 (34)	14 (26)	
LM	1 (2)	1 (2)	
Bypass grafts	3 (7)	6 (11)	
Mehran classification, n (%)			
Type I	10 (23)	22 (42)	0.05
Type II	19 (43)	11 (21)	0.02
Type III	10 (23)	14 (26)	ns
Type IV	5 (11)	6 (11)	ns
Multivessel procedure, n (%)	9 (21)	11 (25)	ns
Procedural success*, n (%)	42 (98)	43 (98)	ns
IIb/IIIa inhibitors, n (%)	14 (33)	4 (9)	0.007
Clopidogrel prescription, mo	7.5 ± 5.5	5.9 ± 2.6	0.005

ACS=Acute Coronary syndromes; CABG=Coronary Artery Bypass Graft; LAD=left anterior descending artery; LCX=left circumflex artery; MI=Myocardial Infarction; RCA=right coronary artery; LM=left main stem; TL=Target Lesion

*as judged by the operator, in the absence of in-hospital complications.

Table 2. Quantitative coronary analysis at baseline

	VBT (n. 44)	SES (n. 53)	p value
Pre-procedure			
Reference diameter, mm	2.44 ± 0.45	2.64 ± 0.56	ns
MLD, mm	0.74 ± 0.52	0.90 ± 0.55	ns
Diameter stenosis, %	69 ± 20	66 ± 19	ns
Lesion length, mm	15.7 ± 10.4	17.5 ± 12.1	ns
Post-procedure			
Reference diameter, mm	2.61 ± 0.51	2.73 ± 0.54	ns
MLD, mm	1.84 ± 0.41	2.33 ± 0.59	0.0008
Diameter stenosis, %	28 ± 12	16 ± 15	0.004

MLD = Minimal Lumen Diameter

Table 3. Nine-month clinical outcome

	VBT (n. 43)	SES (n. 44)
All MACE, %	20.9	18.6
Death, %	7.0	0
Myocardial infarction, %	2.3	2.3
Target Lesion Revascularization, %	11.6	16.3
Target Vessel Revascularization, %	4.7	4.7
Coronary bypass graft, %	7.0	2.3
Percutaneous coronary intervention, %	9.3	18.6

MACE=Major Adverse Cardiovascular Events

PART 1

DRUG-ELUTING STENTS TO TREAT IN-STENT RESTENOSIS

CHAPTER 4

Effectiveness of Sirolimus-Eluting Stent
Implantation for Recurrent In-Stent Restenosis
After Brachytherapy

Authors: Francesco Saia, Pedro A. Lemos,
Georgios Sianos, Muzaffer Degertekin, Chi-Hang
Lee, Chourmouziou A. Arampatzis, Angela Hoyer,
Kengo Tanabe, Evelyn Regar, Willem J. van der
Giessen, Pieter C. Smits, Pim de Feyter, Jurgen
Ligthart, Ron T. van Domburg, Patrick W. Serruys.

Am J Cardiol 2003; 92:200-203

Effectiveness of Sirolimus-Eluting Stent Implantation for Recurrent In-Stent Restenosis After Brachytherapy

Francesco Saia, MD, Pedro A. Lemos, MD, Georgios Sianos, MD, Muzaffer Degertekin, MD, Chi-Hang Lee, MD, Chourmouzios A. Arampatzis, MD, Angela Hoye, MD, Kengo Tanabe, MD, Evelyn Regar, MD, PhD, Willem J. van der Giessen, MD, PhD, Pieter C. Smits, MD, PhD, Pim de Feyter, MD, PhD, Jurghen Ligthart, MSc, Ron T. van Domburg, MSc, PhD, and Patrick W. Serruys, MD, PhD

Coronary vascular brachytherapy is, to date, the only effective treatment available for complex in-stent restenosis (ISR).¹ However, its efficacy is hampered by late restenosis,² late thrombosis,^{3,4} edge effect,⁵ geographic miss,⁶ and delayed healing.³ Moreover, the fate of the patients after "failed" brachytherapy is uncertain, as well as the result of the various percutaneous treatments employed thereafter. Sirolimus is a macrolide antibiotic produced by *Streptomyces hygroscopicus* with immunosuppressive effects; it is approved for the prevention of renal transplant rejection.⁷ The main effect of sirolimus is the interruption of G1 to S cell cycle progression mediated by its binding to a cytosolic receptor (FK506 protein binding protein 12) and a cascade of subsequent actions. Importantly, sirolimus inhibits proliferation and migration of vascular smooth muscle cells, a key element in the development of restenosis after percutaneous coronary interventions (PCIs). Recently, stent-based local sirolimus delivery has been shown to strongly suppress neointimal hyperplasia and prevent restenosis in de novo lesions followed up for 2 years.^{8,9} The revolutionary results obtained with drug-eluting stents have encouraged the assessment of their efficacy in more complex clinical and morphologic subsets. The first human experience evaluating the sirolimus-eluting stent (SES) for the treatment of ISR has been recently reported; it showed this strategy to be highly effective.¹⁰ We describe here the first series of patients treated with SESs for recurrent ISR after brachytherapy.

•••

The patients described in this report consist of 2 cohorts treated during separate time periods. The first cohort was treated between March 2001 and June 2001, as part of a pilot study on SESs for treatment of ISR. Since April 2002, shortly after European Community market approval, SES implantation has been adopted as the default strategy in all patients treated with PCI at our institution, irrespective of clinical presentation and coronary morphology. These latter patients have been included in the RESEARCH Registry (Rapamycin-Eluting Stent Evaluated At Rotterdam Cardiology Hospitals) and will be followed up

for 1 year.¹¹ The only exclusion criteria were unavailability of an adequately sized SES at the time of the procedure and enrollment in another revascularization protocol (SESs were available in diameters from 2.25 to 3.0 mm and lengths of 8, 18, and 33 mm). All patients treated with SES after "failed" brachytherapy were scheduled for 6-month angiography.

ISR was defined as >50% diameter stenosis by quantitative coronary angiography within a previously stented vessel segment and classified as proposed by Mehran et al.¹² Treatment strategy and device utilization other than stenting was left to the physician's discretion. The procedure was considered successful when residual stenosis <30% by quantitative coronary angiography was achieved together with Thrombolysis In Myocardial Infarction (TIMI) flow grade 2 to 3. The study stent utilized was the sirolimus-eluting Cypher (Cordis Europa NV, Johnson & Johnson, Roden, The Netherlands), which contains a 140 µg sirolimus/cm² metal surface area in a slow release formulation (>28 days). Pretreatment with clopidogrel for 48 hours or a 300-mg loading dose was required. During the procedure, intravenous heparin was given to maintain an activated clotting time >300 seconds. After the procedure, all patients received aspirin indefinitely (>75 mg/day) and clopidogrel (75 mg/day) for at least 2 months. Clinical status information was collected at follow-up visits or by telephone contact with the patient or referring physician. Data are presented as number and relative percentage or mean ± SD. Median and range have been reported when deemed necessary for a better description.

From the beginning of the study until August 15, 2002, 12 consecutive patients (both cohorts) underwent PCI with SES implantation for recurrent ISR after local radiation therapy. All of them presented with angina pectoris and/or myocardial ischemia as documented by stress test or thallium scan. Coronary brachytherapy had been previously performed in 11 patients with catheter-based local irradiation (10 beta, 1 gamma) and in 1 patient with phosphorus-32 radioactive stent implantation.

Baseline clinical and angiographic characteristics are listed in Tables 1 and 2, respectively.

Nine patients (75%) had had more than 1 previous episode of restenosis. Average time from the preceding percutaneous reintervention was 24 months (range 111 to 1,678 days, median 719).

Remarkably, 9 patients (75%) presented with a

From Erasmus MC, Thoraxcenter, Rotterdam, The Netherlands. Dr. Serruys' address is: Erasmus MC, Thoraxcenter, Bld404, Dr. Molewaterplein 40, 3015 GD Rotterdam, The Netherlands. E-mail: p.w.j.c.serruys@erasmusmc.nl. Manuscript received January 16, 2003; revised manuscript received and accepted April 14, 2003.

Patients	12
Age (yrs)	62 ± 11
Men	9 (75%)
Current smoker	4 (33%)
Hypercholesterolemia*	11 (92%)
Systemic hypertension	6 (50%)
Diabetes mellitus	3 (25%)
Family history of coronary heart disease	4 (33%)
Stable angina pectoris	7 (58%)
Unstable angina pectoris	4 (33%)
Acute myocardial infarction	1 (8%)
Multivessel coronary disease	10 (83%)
Previous myocardial infarction	9 (75%)
Previous coronary bypass	4 (33%)
Time from last target lesion revascularization (d)	111–1,678 (719)
Time from brachytherapy (d)	111–1,968 (792)
Episodes of ISR	
>1	9 (75%)
>2	5 (42%)

*Total cholesterol >200mg/dl and/or receiving lipid lowering treatment. Values expressed as mean ± SD, range (median), or as number of patients (%).

Variable	
Target coronary artery	
Left anterior descending	2 (17%)
Left circumflex artery	5 (42%)
Right	4 (33%)
Left main	1 (8%)
Quantitative coronary analysis, before procedure	
Reference diameter (mm)	2.83 ± 0.48
Minimum lumen diameter (mm)	0.67 ± 0.76
Diameter stenosis (%)	77 ± 25
Quantitative coronary analysis, after procedure	
Reference diameter (mm)	2.76 ± 0.38
Minimum lumen diameter (mm)	2.38 ± 0.45
Diameter stenosis (%)	13 ± 11
Acute gain (mm)	1.71 ± 0.58
Late loss (mm)	0.68 ± 1.20
Multivessel coronary procedure	3 (25%)
Other devices utilized	
Cutting balloon	3 (33%)
Cross Safe*	1 (8%)

Values expressed as mean ± SD or number (%).
*Intraluminal Therapeutics Inc., Carlsbad, California.

proliferative pattern of restenosis, 5 of whom (42%) had a totally occluded target vessel. The occlusion dated more than 3 months in 4 patients.

Overall, we implanted 18 SESs (average 1.5/patient). Mean stent length was 33.9 ± 30.1 mm (range 8 to 92; median 18), and mean stent diameter was 2.88 ± 0.33 mm. Multivessel PCI was performed in 3 patients (25%).

Angiographic success was obtained in 11 of 12 patients (92%). The remaining patient showed a 34% residual stenosis during quantitative coronary angiography and stent underexpansion despite very high-pressure inflation (24 atm). Individual clinical outcomes are listed in Table 3. With the obvious exception of the single patient presenting with acute

Patient	Target Coronary Artery	BT	Mehram Class	No. of ISR	Clopidogrel (mo)	In-Hospital MACE	Follow-Up (mo)	Follow-Up MACE (time)	Clinical Status Follow-Up	Angiographic Control (time [%DS])
1	Right	Beta	II	3	6	0	9.5	Death (9.5 mo)	Death	4 mo (7%)
2	Right	Beta	IB	2	8	0	12	0	Asymptomatic	4 mo (1.5%)
3	Right	Beta	II	2	2	0	14	0	Asymptomatic	6 mo (1.3%)
4	Right	Gamma	IV	4	1	0	7	0	Asymptomatic	7 mo (2.5%)
5	Left circumflex	Beta	IV	1	6	0	19	0	Asymptomatic	4 mo (1.00%)
6	Left circumflex	Beta	IV	2	1	0	5	TLR (5 mo)	Stable angina	5 mo (7.1%)
7	Left circumflex	Beta	III	3	2	0	6	0	Asymptomatic	Asymptomatic
8	Left circumflex	Beta	IB	3	3	0	7	TLR* (7 mo)	Asymptomatic	7 mo (1.7%)
9	Left circumflex	Beta	III	1	6	0	8	TLR (6 mo)	Stable angina	6 mo (98%)
10	Left main/circumflex	Beta	IC	2	1	0	5	Non-TLR (5 mo)	Stable angina	5 mo (1.3%)
11	Left anterior descending	³² P Rx Stent	IV	1	6	0	4	0	Asymptomatic	Asymptomatic
12	Left anterior descending	Beta	IV	3	1	0	5	TLR (5 mo)	Stable angina	5 mo (62%)

*Distal to the index lesion due to atherosclerotic disease progression.
BT = Brachytherapy; L = left; MACE = major adverse cardiovascular event; ³²P Rx Stent = phosphorus-32 radioactive stent; TLR = target lesion revascularization; TVR = target vessel revascularization; %DS = percent diameter stenosis by quantitative coronary analysis.

myocardial infarction, no postprocedural cardiac enzyme elevation was observed, and all the patients were discharged home free from events.

Average follow-up was 8.5 ± 4.5 months. Ten patients (83%) underwent angiography between 4 and 7 months after the procedure. Two patients who refused angiographic follow-up were asymptomatic after 4 and 6 months. One patient died after 9.5 months because of congestive heart failure, shortly after hospital admission for acute pulmonary edema. He was 79 years old, with a history of 2 coronary artery bypass graft operations and 2 PCIs. Left ventricular dysfunction and end-stage congestive heart failure were diagnosed before the last coronary angioplasty. During the 4-month follow-up, no intravascular ultrasound evidence of neointimal hyperplasia was found.

Recurrent ISR after SES implantation was found in 4 out of 10 patients who underwent angiography during follow-up (40%). One of them, in whom complete stent expansion could not be achieved at index procedure, was found to have silent reocclusion after 4 months. No further treatment was performed, and at 19 months the patient remained asymptomatic. Two other patients, both diabetics, presented with stable angina (Canadian Cardiovascular Society class 3) and ISR that required target lesion revascularization. In 1 of them, intravascular ultrasound showed a clearly underexpanded stent with a very small minimal in-stent diameter (1.3 mm). In the fourth case, a very focal restenosis (<5 mm) was diagnosed by elective angiography 5 months after the procedure. Originally, the patient had been treated with 4 SESs (overall length 92 mm) for chronic total occlusion of the left anterior descending artery (ISR). Intravascular ultrasound examination confirmed the absence of neointimal hyperplasia in the remaining portion of the stents. The patient was asymptomatic, but percutaneous revascularization was performed based on intravascular ultrasound findings.

Another patient had recurrent angina 4 months after the procedure. Angiography showed minimal in-stent hyperplasia in the region of interest, whereas a severe lesion due to ISR requiring percutaneous treatment was found in a different vessel.

One of the lesions treated with an SES during the index procedure was composed of echolucent tissue ("black hole").¹³ Interestingly enough, the intravascular ultrasound examination at follow-up showed a reappearance of this tissue, although it did not significantly affect the lumen area.

• • •

SESs have been recently shown to strongly prevent the development of neointimal hyperplasia after stenting. The first randomized clinical trial reported an exceptional 0% binary restenosis rate.⁸ Whether a similar result is obtainable in different clinical situations and for more complex coronary lesion subsets is the subject of extensive investigation. Preliminary results for their use in the treatment of ISR are positive, although less impressive than in de novo lesions.¹⁰

In the present investigation, we sought to assess the safety and outcome of SES implantation in patients

with recurrent ISR after brachytherapy. The strategy evaluated is safe and is believed to be clinically effective, considering the complex population under investigation. The 0% incidence of in-hospital events as well as the absence of subacute stent thrombosis is noteworthy because the average stent length was remarkably high, and these patients are likely to have endothelial dysfunction. The only death that occurred is highly unlikely to be related to either the procedure or to the stent, but rather to the severely compromised left ventricular function. Nevertheless, our report raises a series of unresolved issues. The antiproliferative effect of sirolimus after brachytherapy seems to be strongly reduced compared with other situations. The 40% incidence of restenosis in our population is noteworthy. Diabetes mellitus, a well-known risk factor for restenosis, may also represent a predisposing factor for failure in this setting. However, in 2 cases, technical causes of failure (stent underexpansion) could be implicated, and in a third patient, a very focal neointimal growth was observed compared with the very long baseline lesion and total stent length. The optimal duration of combined antiplatelet therapy is unclear. In this series there was a striking variety in the duration of clopidogrel prescribed after the procedure due to decisions made on an individual patient basis. Currently, we prescribe combined antiplatelet therapy for 12 months or lifelong after very long stent implantation, but this approach deserves further evaluation.

Our investigation presents a few limitations. First, we do not have a control population. Whether a conventional approach would have provided comparable results cannot be inferred from our data. Second, the present series of patients is quite heterogeneous; this is not surprising given the "real world" setting. The time elapsed from the last target vessel revascularization was considerably different among patients. The underlying physiopathologic process of late (around 2 years) recurrent restenosis after brachytherapy and subsequent response to treatment is not known (whether it is neointimal tissue or late atherosclerotic progression is unclear). Moreover, the incidence of black hole may be higher than suspected, and the biologic properties of this tissue may be responsible for a blunted response to antiproliferative drugs. Last, but not least, the number of patients in our investigation was low, and larger studies with extended follow-up are warranted to draw definitive conclusions.

In this investigation, 12 patients were treated with sirolimus-stent implantation for recurrent ISR after failed brachytherapy. The strategy evaluated was safe and is believed to be clinically effective, although our data suggest a different attenuated efficacy of sirolimus in preventing neointimal growth in this setting compared with the treatment of de novo lesions.

1. Lowe HC, Oesterle SN, Khachigian LM. Coronary in-stent restenosis: current status and future strategies. *J Am Coll Cardiol* 2002;39:183–193.
2. Kay IP, Wardeh AJ, Kozuma K, Foley DP, Knook AH, Thury A, Sianos G, van der Giessen WJ, Levendag PC, Serruys PW. Radioactive stents delay but do not prevent in-stent neointimal hyperplasia. *Circulation* 2001;103:14–17.
3. Costa MA, Sabat M, van der Giessen WJ, Kay IP, Cervinka P, Ligthart JM, Serrano P, Coen VL, Levendag PC, Serruys PW. Late coronary occlusion after intracoronary brachytherapy. *Circulation* 1999;100:789–792.
4. Waksman R, Bhargava B, Mintz GS, Mehran R, Lansky AJ, Satler LF, Pichard AD, Kent KM, Leon MB. Late total occlusion after intracoronary brachytherapy for patients with in-stent restenosis. *J Am Coll Cardiol* 2000;36:65–68.
5. Albiero R, Nishida T, Adamian M, Amato A, Vaghetti M, Corvaja N, Di Mario C, Colombo A. Edge restenosis after implantation of high activity (32)P radioactive beta-emitting stents. *Circulation* 2000;101:2454–2457.
6. Sabate M, Costa MA, Kozuma K, Kay IP, van der Giessen WJ, Coen VL, Ligthart JM, Serrano P, Levendag PC, Serruys PW. Geographic miss: a cause of treatment failure in radio-oncology applied to intracoronary radiation therapy. *Circulation* 2000;101:2467–2471.
7. Serruys PW, Regar E, Carter AJ. Rapamycin eluting stent: the onset of a new era in interventional cardiology. *Heart* 2002;87:305–307.
8. Morice MC, Serruys PW, Sousa JE, Fajadet J, Ban Hayashi E, Perin M, Colombo A, Schuler G, Barragan P, Guagliumi G, Molnar F, Falotico R. A randomized comparison of a sirolimus-eluting stent with a standard stent for coronary revascularization. *N Engl J Med* 2002;346:1773–1780.
9. Degerteekin M, Serruys PW, Foley DP, Tanabe K, Regar E, Vos J, Smits PC, van der Giessen WJ, van den Brand M, de Feyter P, Popma JJ. Persistent inhibition of neointimal hyperplasia after sirolimus-eluting stent implantation: long-term (up to 2 years) clinical, angiographic, and intravascular ultrasound follow-up. *Circulation* 2002;106:1610–1613.
10. Degerteekin M, Regar E, Tanabe K, Smits P, van der Giessen WJ, Carlier S, de Feyter P, Vos J, Foley D, Ligthart J, Popma J, Serruys PW. Sirolimus-eluting stent for treatment of complex in-stent restenosis: the first clinical experience. *J Am Coll Cardiol* 2003;41:184–189.
11. Lemos PA, Lee CH, Degerteekin M, Saia F, Tanabe K, Arampatzis CA, Hoyer A, van Duuren M, Sianos G, Smits PC, et al. Early outcome after sirolimus-eluting stent implantation in patients with acute coronary syndromes. Insights from the Rapamycin-Eluting Stent Evaluated At Rotterdam Cardiology Hospital (RESEARCH) Registry. *J Am Coll Cardiol* 2003;41:2093–2099.
12. Mehran R, Dangas G, Abizaid AS, Mintz GS, Lansky AJ, Satler LF, Pichard AD, Kent KM, Stone GW, Leon MB. Angiographic patterns of in-stent restenosis: classification and implications for long-term outcome. *Circulation* 1999;100:1872–1878.
13. Castagna MT, Mintz GS, Weissman N, Maehara A, Finet G, Waksman R. “Black hole.” Echolucent restenotic tissue after brachytherapy. *Circulation* 2001;103:778.

PART 2

UNRESTRICTED UTILIZATION OF DRUG-ELUTING STENTS

CHAPTER 5

Incidence of Thrombotic Stent Occlusion
During the first 3 Months After Sirolimus-
Eluting Stent Implantation in 500 Consecutive
Patients Treated in the Real World

Authors: Evelyn Regar, Pedro A. Lemos,
Francesco Saia, Muzaffer Degertekin, Kengo
Tanabe, Chi-Hang Lee, Chourmouzos A.
Arampatzis, Angela Hoye, Georgios Sianos, Pim
de Feyter, Willem J. van der Giessen, Pieter C.
Smits, Ron T. van Domburg, Patrick W. Serruys.

Am J Cardiol. 2004;93:1271-5

Incidence of Thrombotic Stent Occlusion During the First Three Months After Sirolimus-Eluting Stent Implantation in 500 Consecutive Patients

Evelyn Regar, MD, PhD, Pedro A. Lemos, MD, Francesco Saia, MD, Muzaffer Degertekin, MD, Kengo Tanabe, MD, Chi-Hang Lee, MBBS, MRCP, Chourmouzos A. Arampatzis, MD, Angela Hoye, MB, ChB, Georgios Sianos, MD, Pim de Feyter, MD, PhD, Willem J. van der Giessen, MD, PhD, Peter C. Smits, MD, PhD, Ron T. van Domburg, PhD, and Patrick W. Serruys, MD, PhD

Sirolimus-eluting stents have been used in our institution for all percutaneous interventions, without clinical or anatomic exclusion criteria, as part of the Rapamycin-Eluting Stent Evaluated At Rotterdam Cardiology Hospital registry. We analyzed the incidence of (sub)acute stent thrombosis after sirolimus-eluting stent implantation in an unselected population of 510 consecutive patients. At 3-month follow-up, (sub)acute stent thrombosis was diagnosed in 2 patients (0.4%) 6 hours and 11 days after the procedure, respectively. These cases occurred in diabetic women with complex coronary lesions. Intravascular ultrasound examination showed inadequate stent expansion and uncovered distal dissection as possible mechanical explanations for the thrombosis. ©2004 by Excerpta Medica, Inc.

(Am J Cardiol 2004;93:1271-1275)

Sirolium-eluting stents (SESs) have proved to significantly decrease restenosis in selected patients with relatively simple lesions.¹ This late benefit was accomplished without compromising the well-established low incidence of short-term complications with currently available bare stents. Specifically, in these studies, SESs have been associated with a low incidence of stent thrombosis, a condition largely reported to carry high risks of morbidity and mortality.² However, these results cannot be directly extrapolated to patients with more complex profiles, such as those commonly treated in daily practice. After bare-metal stent implantation, the incidence of sudden stent thrombosis has been shown to increase in patients with acute coronary syndromes, long stents, small vessels, long-term total occlusion, and in those who require multivessel intervention.³ We therefore investigated the incidence of (sub)acute stent thrombosis (SAT) occurring in the first 3 months after the procedure in an unselected cohort of consecutive patients treated with SES implantation in our institution.

From the Department of Cardiology, Thoraxcenter, Erasmus Medical Center Rotterdam, Rotterdam, The Netherlands. Dr. Serruys' address is: Department of Cardiology, Thoraxcenter, Room Bd 418, Erasmus Medical Center Rotterdam, Dr. Molewaterplein 40, 3015 GD Rotterdam, The Netherlands. E-mail: p.w.j.c.serruys@erasmusmc.nl. Manuscript received June 27, 2003; revised manuscript received and accepted January 29, 2004.

Since April 16, 2002, the SES (Cypher, Cordis Corp., Johnson & Johnson, Warren, New Jersey) has been used as the device of choice for all percutaneous coronary interventions performed in our institution as part of the Rapamycin-Eluting Stent Evaluated At Rotterdam Cardiology Hospitals registry. The study design has been described elsewhere.⁴ In brief, this is a single-center registry with the main purpose of evaluating the effectiveness of SES implantation in patients treated in the "real world." Therefore, SES has been used in virtually all clinical situations and lesion morphologies with no specific contraindications.

All procedures were performed according to standard techniques, and the final interventional strategy was left to the discretion of the operators. At the initiation of this study, SESs were available in diameters from 2.25 to 3.00 mm and lengths of 8, 18, and 33 mm. Glycoprotein IIb/IIIa inhibitors were given at the discretion of the operator, including situations associated with high risk for SAT, such as acute coronary syndromes, long stents, small vessels, long-term total occlusion, and need for multivessel intervention. All patients were on life-long aspirin administration and received a loading dose of clopidogrel (300 mg), which was maintained for ≥ 3 months (75 mg/day).

Clinical follow-up at 3 months was performed by scheduled visits at the outpatient clinic or by direct contact (telephone or regular mail). Recordings of all repeat interventions (surgical and percutaneous) and rehospitalizations were prospectively collected in a dedicated database. Survival status at 30 days was assessed by written inquiries to the municipal civil registries. The local ethical committee approved the study, and written informed consent was obtained from all patients.

Thrombotic stent occlusion was documented angiographically as a complete occlusion (Thrombolysis In Myocardial Infarction [TIMI] flow 0 or 1) or as a flow-limiting thrombus (TIMI flow 1 or 2) of a successfully treated artery (TIMI flow 3 immediately after stent placement and percent in-lesion diameter stenosis $< 30\%$). Acute occlusion was defined to occur at < 24 hours, subacute occlusion was defined to occur at > 24 hours to < 30 days after the study procedure, and late occlusion was defined to occur > 30 days after the index procedure. Discrete variables were pre-

TABLE 1 Baseline and Procedural Characteristics (n = 510)

	Men (n = 359)	Women (n = 151)
Age (yrs)	60.5 ± 11.9	63.3 ± 10.9
Diabetes mellitus	16.0%	23.7%
Current smoker	39.3%	32.6%
Systemic hypertension	40.9%	59.0%
Previous myocardial infarction	34.8%	22.8%
Previous percutaneous coronary intervention	26.5%	20.3%
Previous coronary bypass	10.1%	10.7%
No. of coronary arteries narrowed >50%		
1	45.8%	45.9%
2	31.7%	25.7%
3	22.5%	28.4%
Stable angina pectoris	52.1%	51.7%
Unstable angina pectoris	31.5%	33.1%
Acute myocardial infarction	16.7%	13.9%
Glycoprotein IIb/IIIa inhibitors	27.9%	21.3%
Treated coronary artery*		
Left main stem	3.7%	3.3%
Left anterior descending	57.4%	57.0%
Left circumflex	36.5%	29.8%
Right	34.3%	41.1%
Multivessel SES implantation	25.3%	23.2%
No. of SESs per procedure	2.1 ± 1.3 stents	2.1 ± 1.2 stents
Total length of the implanted stents (range)	38.0 ± 26.9 mm/patient (8–152 mm)	37.9 ± 26.5 mm/patient (8–184 mm)
Adjacent stented length >36 mm	17.5%	17.2%
Small-diameter stent (2.5 or 2.25 mm)	36.5%	33.9%
Postdilatation performed	56.6%	51.0%
Intravascular ultrasound use	20.6%	20.5%
Maximum pressure	17.2 ± 2.6 atm	17.2 ± 2.8 atm
Reference diameter	2.70 ± 0.49 mm	2.70 ± 0.54 mm
Minimal lumen diameter before SES	0.75 ± 0.45 mm	0.71 ± 0.45 mm
Diameter of stenosis before SES	71 ± 17%	71 ± 18%
Minimal lumen diameter after SES	2.31 ± 0.49 mm	2.35 ± 0.46 mm
Diameter of stenosis after SES	15 ± 12%	14 ± 9%

*Not mutually exclusive—in patients with multivessel disease, several arteries were treated.

sented as counts and percentages, and continuous variables were expressed as mean ± 1 SD

Between April 16 and September 17, 2002, 510 consecutive patients (842 lesions) were treated with 1,093 SESs (2.1 ± 1.3 SESs per patient). Baseline characteristics are listed in Table 1. Overall, 15.7% of patients had acute myocardial infarction and 32.4% had unstable angina at admission. Multivessel stent implantation was performed in 25%, nominally small-diameter stents (2.5 or 2.25 mm) were implanted in 25.7%, and a long-stented segment (>36 mm) was recorded in 17.5%. Glycoprotein IIb/IIIa inhibitors were used in 24% of cases.

Clinical 3-month follow-up information was obtained in all patients. During the first 3 months after the procedure, 2 patients (0.4%) developed SAT (Figures 1 and 2). These patients were receiving aspirin and clopidogrel at the time of the event.

• • •

In the present study, SAT occurred in 2 of 510 consecutive unselected patients treated with SESs. The 0.4% incidence of SAT at 3 months observed in our series is low and comparable to that reported for conventional bare-metal stents.^{2,5} The patients with stent thrombosis were women with diabetes and complex coronary lesions. Intravascular ultrasound examination showed that mechanical factors may have predisposed these patients to these complications

(inadequate stent expansion and uncovered distal dissection). This is correlated with recent findings in a large series of bare-metal stents.⁶ SAT was found to be related mainly to inadequate postprocedure lumen dimensions or to procedure-related abnormal lesion morphologies (dissection, thrombus, or tissue prolapse). Stents in the left anterior descending artery have been implicated more often than stents in other vessels in stent thrombosis, but in that cohort the diameters of the left anterior descending artery were smaller than those in the right coronary artery.⁷

Although diabetes is a well-established predictor of adverse outcome,⁸ the effect of gender is controversial. In recent studies comparing the outcome for women and men after with bare-metal stent implantation, a higher event rate,⁹ a lower event rate,¹⁰ or similar event rates¹¹ have been reported in women versus men.

Combined oral antiplatelet therapy¹² and systematic high-pressure stent implantation¹³ have decreased the incidence of thrombotic occlusion after conventional coronary stenting.¹⁴ Because SESs have virtually the same physical properties as bare-metal stents, we used a similar approach to accomplish optimum SES deployment. In our series, the average implantation pressure was 17 atm, and balloon postdilatation was performed in approximately half the cases. All

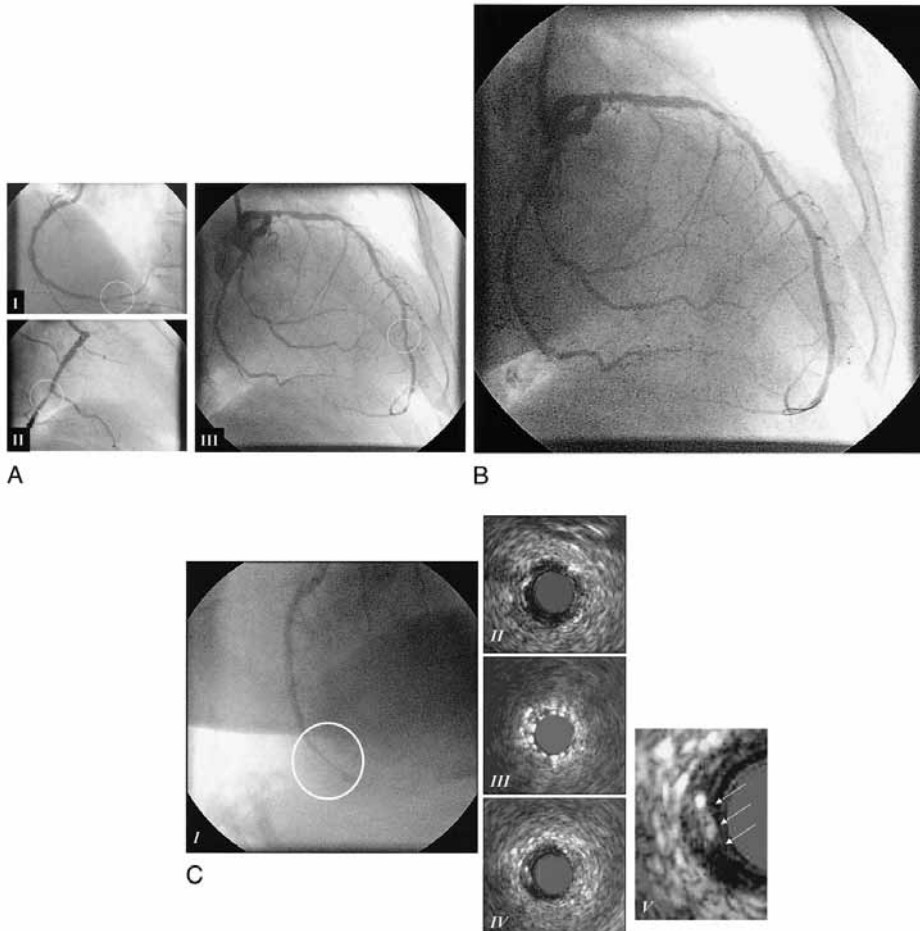
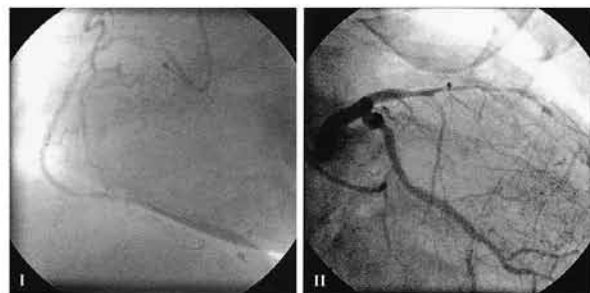


FIGURE 1. (A) Preintervention. Lesions in the distal (I) and middle (II) right coronary arteries (III). Lesions in the distal left anterior descending artery (lesion length 6.91 mm; reference diameter 2.63 mm, minimal lumen diameter 1.58 mm) and the apical left anterior descending artery (lesion length 9.82 mm, reference diameter 1.71 mm, minimal lumen diameter 0.89 mm). (B) After SES implantation in the distal left anterior descending artery (SES 3.0/8 and 2.25/18 mm at 12 atm, reference diameter 2.51 mm, minimal lumen diameter 2.58 mm) and the apical left anterior descending artery (SES 2.25/8 mm at 10 atm, reference diameter 1.95 mm, minimal lumen diameter 1.75 mm). (C) (I) Coronary angiography 6 hours after the index procedure shows total occlusion of the SES in the apical left anterior descending artery (apart from the stents in the distal left anterior descending artery). Intravascular ultrasound scans show underexpansion of the apical stent (III) (minimal stent area 2.00 mm²) compared with the proximal (II) (lumen area 3.81 mm²) and distal (IV) (lumen area 3.10 mm²) references and a distal edge dissection (V, arrows) that was not visible on the angiogram at the time of the index procedure.

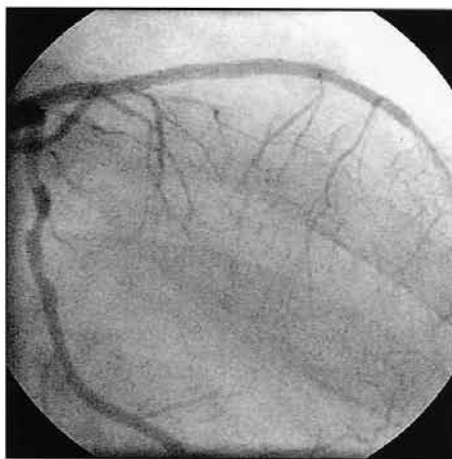patients were maintained under dual antiplatelet treatment.

Previous studies have suggested that sirolimus can significantly enhance agonist-induced platelet aggregation¹⁵ and impair endothelial function.¹⁶ Animal models have shown focal remnants of residual fibrin deposition adjacent to the struts, which may reflect a delay in arterial repair or impaired fibrin degradation

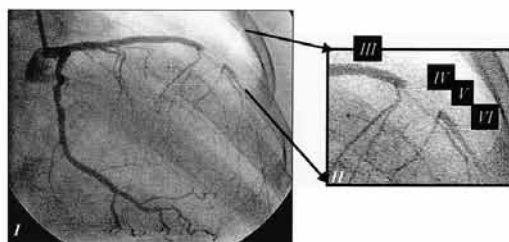
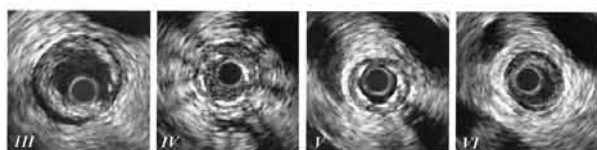
secondary to the local effects of the drug.¹⁷ However, although these features may increase the risk of thrombotic complications, our findings suggest a minimal risk of SAT after SES implantation, even in patients with well-known risk factors for short-term thrombotic complications. Although similar SAT rates have been reported in clinical trials with SES,¹ the present report allowed a comprehensive evaluation of



A



B



C

FIGURE 2. (A) Preintervention angiogram showing spontaneous recanalization of the right coronary artery (I) and chronic total occlusion of the left anterior descending artery (II). The left anterior descending artery is visualized by simultaneous contrast injection into the left and right coronary arteries (left anterior descending artery is filled by collateral flow from the right coronary artery). (B) Result after recanalization of the left anterior descending artery and implantation of 2 SESs (3.0/33 mm and 2.5/33 mm reference diameter 2.59 mm; minimal lumen diameter 1.79 mm). (C) (I, II) Coronary angiograms 11 days after the index procedure show occlusion of the distal left anterior descending artery. Intravascular ultrasound scans show speckled echolucent material within the lumen (IV) and an underexpansion of the stent (V) (minimal stent area 2.27 mm²) compared with the proximal reference (III) (gap between 2 stents; lumen area 8.55 mm²) and the distal reference (VI) (lumen area 2.54 mm²).

the risk of SAT in a large range of clinical settings, including patients not commonly enrolled in randomized studies.

1. Morice MC, Serruys PW, Sousa JE, Fajadet J, Ban Hayashi E, Perin M, Colombo A, Schuler G, Barragan P, Guagliumi G, et al. A randomized comparison of a sirolimus-eluting stent with a standard stent for coronary revascularization. *N Engl J Med* 2002;346:1773–1780.
2. Cutlip D, Baim DS, Ho KK, Popma JJ, Lansky AJ, Cohen DJ, Carozza JP Jr, Chauhan MS, Rodriguez O, Kuntz RE. Stent thrombosis in the modern era: a pooled analysis of multicenter coronary stent clinical trials. *Circulation* 2001;103:1967–1971.
3. Reynolds MR, Rinaldi MJ, Pinto DS, Cohen DJ. Current clinical characteristics and economic impact of subacute stent thrombosis. *J Invasive Cardiol* 2002;14:364–368.
4. Lemos P, Lee CH, Degertekin M, Saia F, Tanabe K, Arampatzis C, Hoye A, van Duuren M, Stianos G, Smits P, et al. Early outcome after sirolimus eluting stent implantation in patients with acute coronary syndromes. Insights from the Rapamycin Eluting Stent Evaluated at Rotterdam Cardiology Hospital (RESEARCH) Registry. *J Am Coll Cardiol* 2003;41:2093–2099.
5. Moussa I, Oetgen M, Roubin G, Colombo A, Wang X, Iyer S, Maida R, Collins M, Kreps E, Moses JW. Effectiveness of clopidogrel and aspirin versus ticlopidine and aspirin in preventing stent thrombosis after coronary stent implantation. *Circulation* 1999;99:2364–2366.
6. Cheneau E, Leborgne L, Mintz GS, Kotani J-I, Pichard AD, Sattler LF, Canos DC, Castagna M, Weissman NJ, Waksman R. Predictors of subacute stent thrombosis: results of a systematic intravascular ultrasound study. *Circulation* 2003;108:43–47.
7. Werner G, Gastmann O, Ferrari M, Schuenemann S, Knies A, Diedrichl, Kreuzer H. Risk factors for acute and subacute stent thrombosis after high-pressure stent implantation: a study by intracoronary ultrasound. *Am Heart J* 1998;135:300–309.
8. van Domburg RT, Foley DP, de Jaegere P, de Feyter P, van den Brand M, van der Giessen W, Hamburger J, Serruys PW. Long term outcome after coronary stent implantation: a 10 year single centre experience of 1000 patients. *Heart* 1999;82:27–34.
9. Watanabe CT, Maynard C, Ritchie JL. Comparison

of short-term outcomes following coronary artery stenting in men versus women. *Am J Cardiol* 2001;88:848–852.

10. Mehilli J, Kastrati A, Bollwein H, Dibra A, Schulhen H, Dirschinger J, Schomig A. Gender and restenosis after coronary artery stenting. *Eur Heart J* 2003;24:1523–1530.

11. Moriel M, Feld S, Almagor Y, Balkin J, Klutstein M, Meerkin D, Rosenmann D, Winkler H, Tzivoni D. Results of coronary artery stenting in women versus men: a single center experience. *Isr Med Assoc J* 2003;5:398–402.

12. Karrison GJ, Morice MC, Benveniste E, Bunouf P, Aubry P, Cattan S, Chevalier B, Commeau P, Cribier A, Eiferman C, et al. Intracoronary stent implantation without ultrasound guidance and with replacement of conventional anticoagulation by antiplatelet therapy. 30-Day clinical outcome of the French multicenter registry. *Circulation* 1996;94:1519–1527.

13. Nakamura S, Hall P, Gaglione A, Tiecco F, Di Maggio M, Maiello L, Martini G, Colombo A. High pressure assisted coronary stent implantation accomplished without intravascular ultrasound guidance and subsequent anticoagulation. *J Am Coll Cardiol* 1997;29:21–27.

14. Serruys PW, de Jaegere P, Kiemeneij F, Macaya C, Rutsch W, Heyndrickx G, Emanuelsson H, Marco J, Legrand V, Materne P, et al, for the Benestent Study Group. A comparison of balloon-expandable-stent implantation with balloon angioplasty in patients with coronary artery disease. *N Engl J Med* 1994;331:489–495.

15. Babinska A, Markell MS, Salifu MO, Akoad M, Ehrlich YH, Kornecki E. Enhancement of human platelet aggregation and secretion induced by rapamycin. *Nephrol Dial Transplant* 1998;13:3153–3159.

16. Jeanmart H, Perrault LP, Carrier M, Cartier R, Nickner C. Comparative study of CSA and FK506 versus newer immunosuppressive drugs MMF and rapamycin on coronary endothelial function in vitro. *J Heart Lung Transplant* 2001;20:235.

17. Suzuki T, Kopia G, Hayashi S-I, Bailey LR, Llanos G, Wilensky R, Klugherz BD, Papandreou G, Narayan P, Leon MB, et al. Stent-based delivery of sirolimus reduces neointimal formation in a porcine coronary model. *Circulation* 2001;104:1188–1193.

PART 2

UNRESTRICTED UTILIZATION OF DRUG-ELUTING STENTS

CHAPTER 6

Unrestricted Utilization of Sirolimus-Eluting Stents Compared to Conventional Bare Stent Implantation in the Real World .
The Rapamycin-Eluting Stent Evaluated At Rotterdam Cardiology Hospital (RESEARCH) registry

Authors: Pedro A Lemos, Patrick W Serruys, Ron T van Domburg, Francesco Saia, Chourmouzos A Arampatzis, Angela Hoye, Muzaffer Degertekin, Kengo Tanabe, Joost Daemen, Tommy KK Liu, Eugene McFadden, Georgios Sianos, Sjoerd H Hofma, Pieter C Smits, Willem J van der Giessen, Pim de Feyter.

Circulation 2004;109:190-195

Unrestricted Utilization of Sirolimus-Eluting Stents Compared With Conventional Bare Stent Implantation in the “Real World”

The Rapamycin-Eluting Stent Evaluated At Rotterdam Cardiology Hospital (RESEARCH) Registry

Pedro A. Lemos, MD; Patrick W. Serruys, MD, PhD; Ron T. van Domburg, PhD; Francesco Saia, MD; Chourmouziou A. Arampatzis, MD; Angela Hoye, MBChB, MRCP; Muzaffer Degertekin, MD; Kengo Tanabe, MD; Joost Daemen; Tommy K.K. Liu; Eugene McFadden, MBChB, FRCPI; Georgios Sianos, MD, PhD; Sjoerd H. Hofma, MD; Pieter C. Smits, MD, PhD; Willem J. van der Giessen, MD, PhD; Pim J. de Feyter, MD, PhD

Background—The effectiveness of sirolimus-eluting stents in unselected patients treated in the daily practice is currently unknown.

Methods and Results—Sirolimus-eluting stent implantation has been used as the default strategy for all percutaneous procedures in our hospital as part of the Rapamycin-Eluting Stent Evaluated At Rotterdam Cardiology Hospital (RESEARCH) registry. Consecutive patients with de novo lesions (n=508) treated exclusively with sirolimus-eluting stents (SES group) were compared with 450 patients who received bare stents in the period just before (pre-SES group). Patients in the SES group more frequently had multivessel disease, more type C lesions, received more stents, and had more bifurcation stenting. At 1 year, the cumulative rate of major adverse cardiac events (death, myocardial infarction, or target vessel revascularization) was 9.7% in the SES group and 14.8% in the pre-SES group (hazard ratio [HR], 0.62 [95% CI, 0.44 to 0.89]; $P=0.008$). The 1-year risk of clinically driven target vessel revascularization in the SES group and in the pre-SES group was 3.7% versus 10.9%, respectively (HR, 0.35 [95% CI, 0.21 to 0.57]; $P<0.001$).

Conclusions—Unrestricted utilization of sirolimus-eluting stents in the “real world” is safe and effective in reducing both repeat revascularization and major adverse cardiac events at 1 year compared with bare stent implantation. (*Circulation*. 2004;109:190-195.)

Key Words: stents ■ angioplasty ■ revascularization ■ restenosis

In-stent restenosis has long been recognized as the main limitation of coronary stenting, with rates of as high as 50% in more complex subsets. Recently, sirolimus-eluting stent (SES) implantation has been proven to markedly reduce the incidence of angiographic restenosis and repeat revascularization in selected patients.¹⁻³ In the First-In-Man study, no cases of restenosis were detected in a series of 45 patients, with persistent neointimal inhibition demonstrated up to 2 years.⁴ These findings have been further confirmed in randomized trials comparing SES with conventional bare stents.^{2,3} In the RAndomized study with the sirolimus-eluting Bx VELOCITY balloon-expandable stent in the treatment of patients with de novo native coronary artery Lesions (RAVEL),² there were no cases of binary angiographic restenosis in patients treated with SES implantation. Similarly, in the SIRIUS-eluting Bx velocity balloon expand-

able stent trial (SIRIUS),³ restenosis occurred in 9% of cases in the SES group compared with 36% of patients treated with conventional stents ($P<0.001$).

See p 140

Based on these findings, since the first half of 2002, SES have progressively received clinical approval by official regulatory agencies and are currently available for routine use in Europe, Asia, South America, and more recently the United States. However, all clinical trials completed so far have included elective patients with relatively noncomplex lesions. The effects of SES implantation in complex, unselected patients, such as those treated in daily practice, remains largely unknown. Notably, the occurrence of restenosis in a small but relevant proportion of patients in the SIRIUS trial occurred mainly in patients with diabetes, small

Received July 28, 2003; revision received October 2, 2003; accepted October 6, 2003.

From Erasmus Medical Center, Thoraxcenter, Rotterdam, The Netherlands.

Correspondence to Prof P.W. Serruys, MD, PhD, Thoraxcenter, Bd-406, Dr Molewaterplein 40, 3015-GD Rotterdam, The Netherlands. E-mail p.w.j.c.serruys@erasmusmc.nl

© 2004 American Heart Association, Inc.

Circulation is available at <http://www.circulationaha.org>

DOI: 10.1161/01.CIR.0000109138.84579.FA

vessels, and long lesions,³ characteristics frequently found in most series. Moreover, restenosis after SES implantation has been recently shown to occur in association with procedures with increased complexity.⁵ The present study was therefore conducted to investigate the impact of SES on the outcomes of patients treated in the “real world” of interventional cardiology, as compared with a strategy using conventional bare stent implantation.

Methods

Study Design and Patient Population

The study protocol of the Rapamycin-Eluting Stent Evaluated At Rotterdam Cardiology Hospital (RESEARCH) has been described elsewhere.⁶ Briefly, the RESEARCH is a single-center registry conducted with the main purpose of evaluating the safety and efficacy of SES implantation for patients treated in daily practice. To include a patient population representative of the “real world,” we have adopted since April 16, 2002, a policy of using SES (Cypher; Johnson & Johnson-Cordis unit, Cordis Europa NV) as the default strategy for every percutaneous coronary intervention.

In the first 6 months enrollment, a total of 508 patients with de novo lesions were treated exclusively with SES and were included in the present report (SES group) (72% of the 710 patients treated with stents during the period). Patients treated with bare stents and SES in the same procedure (66 patients) and those treated only with bare stents (136 patients) were not included in the present report. At the initiation of the RESEARCH registry, SES were available in lengths of 8, 18, and 33 mm and diameters from 2.25 to 3.00 mm, but postdilatation with larger balloons was allowed (0.5-mm larger balloons were used in 55% of cases in which a 3.0-mm SES was used). However, unavailability of an appropriate SES size was still the reason for nonutilization of SES in 77% of cases. Moreover, 5% of cases were included in the other study and were not enrolled in the RESEARCH. In the remaining patients not included, SES were not used for a variety of reasons, predominantly operator’s personal choice.

Patients treated solely with SES were compared with a group of consecutive patients treated with bare stents for de novo lesions in the preceding 6 months (pre-SES group). To better match the vessel sizes treated in the two study groups, patients receiving bare metal stents larger than 3.5-mm were excluded from this analysis ($n = 176$). This cutoff value (instead of 3.0-mm diameter stents) was chosen because of the postdilatation policy applied in the SES group, which extended the use of SES to patients with 3.5-mm vessels by visual estimation. In addition, patients treated with bare stents smaller than 2.25 mm were not included ($n = 30$). In total, 450 consecutive patients thereby comprise the pre-SES group (69% of all patients with de novo lesions treated with stents during the period). The present study population was consequently composed of a total of 958 patients divided into two sequential cohorts, primarily distinguished by the interventional strategy applied (bare stent or SES implantation, respectively). This protocol was approved by the hospital ethics committee and is in accordance with the Declaration of Helsinki. Written informed consent was obtained from every patient.

Procedures and Postintervention Medications

All interventions were performed according to current standard guidelines,⁷ and the final interventional strategy was entirely left to the discretion of the operator. Angiographic success was defined as residual stenosis $< 30\%$ by visual analysis in the presence of TIMI 3 grade flow. Periprocedural glycoprotein IIb/IIIa inhibitors and anti-thrombotic medications were used according to the operator’s decision. All patients were advised to maintain lifelong aspirin. At least 1-month clopidogrel treatment (75 mg/d) was recommended for patients treated in the pre-SES phase. For patients treated with SES, clopidogrel was prescribed for at least 3 months, unless one of the following was present (in which case clopidogrel was maintained for

at least 6 months): multiple SES implantation (> 3 stents), total stented length > 36 mm, chronic total occlusion, and bifurcations.

End Point Definitions and Clinical Follow-Up

The primary outcome was the occurrence of major adverse cardiac events, defined as (1) death, (2) nonfatal myocardial infarction, or (3) target vessel revascularization. Myocardial infarction was diagnosed by a rise in the creatine kinase level to more than twice the upper normal limit with an increased creatine kinase-MB. Target lesion revascularization was defined as a repeat intervention (surgical or percutaneous) to treat a luminal stenosis within the stent or in the 5-mm distal or proximal segments adjacent to the stent. Target vessel revascularization was defined as a reintervention driven by any lesion located in the same epicardial vessel. Thrombotic stent occlusion was angiographically documented as a complete occlusion (TIMI flow 0 or 1) or a flow-limiting thrombus (TIMI flow 1 or 2) of a previously successfully treated artery.

Information about the in-hospital outcomes was obtained from an electronic clinical database for patients maintained in our institution and by review of the hospital records for those discharged to referring hospitals (patients were referred from a total of 14 local hospitals). Postdischarge survival status was obtained from the Municipal Civil Registries. All repeat interventions (surgical and percutaneous) and rehospitalizations were prospectively collected during the follow-up. Questionnaires with information about anginal status and medication usage were sent to all living patients. The referring physicians and institutions were contacted whenever necessary for additional information.

During follow-up, coronary angiography was obtained as clinically indicated by symptoms or documentation of myocardial ischemia. Additionally, late angiographic evaluation was eventually obtained from “complex” patients in the SES group, typically with SES implanted in bifurcations, left main coronary, chronic total occlusions, very small vessels, long stented length (> 36 mm), and acute myocardial infarction (in total, 38% patients in the SES group had angiographic follow-up between 6 and 8 months). No angiographic re-study was performed in the pre-SES group. Because of the well-known effect of angiographic reevaluation in increasing the incidence of repeat revascularization,⁸ all reinterventions were retrospectively adjudicated and classified as clinically driven or non-clinically driven by a group of clinicians not involved in the treatment of the particular patient analyzed. Clinically driven repeat revascularization was defined as any intervention motivated by a significant luminal stenosis ($> 50\%$ diameter stenosis) in the presence of anginal symptoms and/or proven myocardial ischemia in the target vessel territory by noninvasive testing.

Statistical Analysis

Continuous variables were presented as mean \pm SD and were compared by means of the Student unpaired t test. Categorical variables were presented as counts and percentages and compared by means of the Fisher exact test. All statistical tests were 2-tailed. The cumulative incidence of adverse events was estimated according to the Kaplan-Meier method, and Cox proportional hazards models were used to assess risk reduction of adverse events. Patients lost to follow-up were considered at risk until the date of last contact, at which point they were censored. Multivariate analyses were performed to identify independent predictors of adverse events, using all clinical, angiographic, and procedural variables included in Tables 1 and 2.

Results

Baseline and Procedural Characteristics

Baseline and procedural characteristics are shown in Table 1 and Table 2. Overall, approximately half of the patients in both groups were admitted with acute coronary syndromes, and diabetes was present in 16% of cases. Patients treated with SES had significantly more multivessel disease, more

TABLE 1. Baseline Characteristics of Patients Treated With Conventional Bare Stents Before Introduction of SES (Pre-SES Group) and Patients Treated Exclusively With SES Implantation (SES Group)

	Pre-SES Group (n=450)	SES Group (n=508)	P
Male, %	72	68	0.4
Age, y±SD	61±11	61±11	0.7
Diabetes, %	15	18	0.3
Non-insulin-dependent, %	11	12	0.7
Insulin-dependent, %	4	6	0.2
Hypertension, %	48	41	0.2
Hypercholesterolemia, %	55	56	1.0
Current smoking, %	34	31	0.3
Previous myocardial infarction, %	40	30	<0.01
Previous angioplasty, %	18	19	0.8
Previous coronary bypass surgery, %	8	9	0.5
Single-vessel disease, %	52	46	0.05
Multivessel disease, %	48	54	0.05
Clinical presentation	0.7
Stable angina, %	48	45	...
Unstable angina, %	35	37	...
Acute myocardial infarction, %	18	18	...
Cardiogenic shock, %*	12	10	0.7

*Relative to patients with acute myocardial infarction.

type C lesions, more bifurcation stenting, more segments stented, and more stents used. Also, in the SES group, long stents and stents with smaller diameters were more frequently used. Periprocedural administration of glycoprotein IIb/IIIa inhibitors was more frequent in the pre-SES phase (33% versus 19%; $P<0.01$). The angiographic success rate was similar in both groups.

Clinical Outcomes

Complete follow-up information was available for 99.1% of patients (mean follow-up period, 405 days). There were no significant differences between the SES group and the pre-SES group in the incidence of major adverse cardiac events during the first month (3.0% versus 4.2% respectively; $P=0.3$) (Table 3). Target vessel revascularization at 30 days was 1.0% (n=5) in the SES group and 2.2% (n=10) in the pre-SES group ($P=0.2$), which included emergency bypass surgery in 2 patients (0.4%) in the SES group and in 2 cases (0.4%) in the pre-SES group ($P=1.0$) and early “redo” target vessel revascularization (eg, residual dissection or compromised side branch in patients with continuing symptoms) in 1 patient (0.2%) in the SES group and in 1 patient (0.2%) in the pre-SES group ($P=1.0$). In the remaining cases, 30-day repeat intervention was performed for angiographically documented stent thrombosis in 2 patients (0.4%) in the SES group and in 7 patients (1.6%) in the pre-SES group ($P=0.1$). No further thrombotic stent occlusion was observed in the late follow-up.

At 1 year, the cumulative incidence of death and death or myocardial infarction was similar between both groups (Fig-

TABLE 2. Angiographic and Procedural Characteristics of Patients Treated With Conventional Bare Stents Before Introduction of SES (Pre-SES Group) and Patients Treated Exclusively With SES Implantation (SES Group)

	Pre-SES Group (n=450)	SES Group (n=508)	P
Treated vessel			
Left anterior descending, %	59	59	0.8
Left circumflex, %	33	32	0.7
Right coronary artery, %	34	39	0.2
Left main coronary, %	2	3	0.6
Bypass graft, %	2	3	0.2
Lesion type			
Type A, %	20	22	0.4
Type B1, %	32	31	0.7
Type B2, %	50	49	0.8
Type C, %	30	43	<0.01
Glycoprotein IIb/IIIa inhibitor, %	33	19	<0.01
Clopidogrel prescription, months±SD	2.9±2.0	4.0±2.0	<0.01
Bifurcation stenting, %	8	16	<0.01
No. of stented segments±SD	1.8±0.9	2.0±1.0	<0.01
No. of implanted stents±SD	1.9±1.2	2.1±1.4	<0.01
Individual stent length ≥33 mm, %	10	35	<0.01
Total stented length per patient, mm±SD	30.1±19.6	38.7±28.7	<0.01
Nominal stent diameter ≤2.5 mm, %	23	36	<0.01
Postdilatation with a balloon ≥0.5 mm larger, %	19	55	<0.01
Angiographic success of all lesions, %	97	97	1.0

ure 1, A and B). Patients treated with SES had significantly less death, myocardial infarction, or target lesion revascularization at 1 year than patients treated in the pre-SES phase (8.8% versus 12.6%, respectively; hazard ratio [HR] 0.66

TABLE 3. Thirty-Day Outcomes of Patients Treated With Conventional Bare Stents Before Introduction of SES (Pre-SES Group) and Patients Treated Exclusively With SES Implantation (SES Group)

	Pre-SES Group (n=450)	SES Group (n=508)	P*
Death, %	2.0	1.6	0.6
Nonfatal myocardial infarction, %	1.6	0.8	0.4
Target lesion revascularization, %	1.8	1.0	0.4
Target vessel revascularization, %†	2.2	1.0	0.2
Any event, %	4.2	3.0	0.3
Stent thrombosis, %‡	1.6	0.4	0.1

*By Fisher exact test.

†Includes target lesion revascularization.

‡Angiographically documented stent thrombosis requiring repeat intervention.

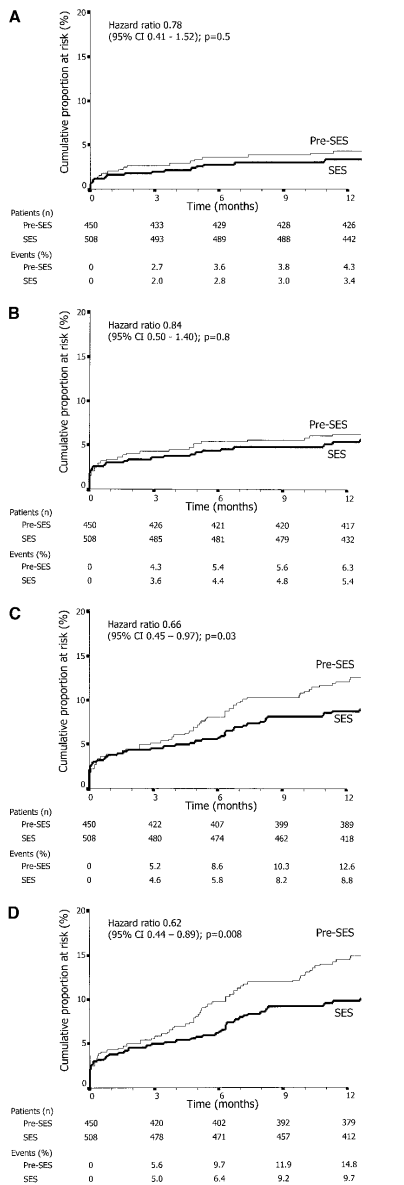


Figure 1. One-year adverse events in patients treated with bare stents before the introduction of SES (pre-SES group) and in patients treated exclusively with SES implantation (SES group). A, Cumulative risk of death; B, death or myocardial infarction; C, death, myocardial infarction, or target lesion revascularization; and D, death, myocardial infarction, or target vessel revascularization.

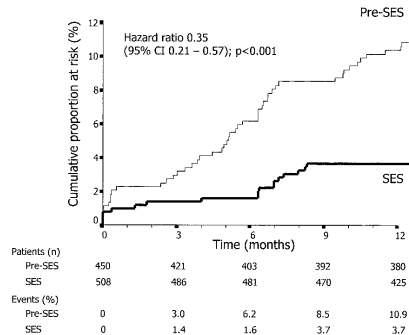


Figure 2. One-year cumulative risk of clinically driven target vessel revascularization in patients treated with bare stents before introduction of SES (pre-SES group) and in patients treated exclusively with SES implantation (SES group).

[95% CI, 0.45 to 0.97]; $P=0.03$) (Figure 1C). Similarly, the 1-year cumulative risk of major adverse cardiac events (death, myocardial infarction, or target vessel revascularization) was significantly reduced in the SES group (9.7% versus 14.8% in the pre-SES group; HR, 0.62 [95% CI, 0.44 to 0.89]; $P=0.008$). The difference in outcomes between both groups was mainly due to a decrease in the need for target vessel revascularization in the SES group (5.1% versus 10.9% in the pre-SES group; HR, 0.49 [95% CI, 0.29 to 0.82]; $P=0.007$). Specifically, treatment with SES was associated with a marked reduction in clinically driven repeat interventions at 1 year (3.7% versus 10.9% in the pre-SES group; HR, 0.35 [95% CI, 0.21 to 0.57]; $P<0.001$) (Figure 2).

Predictors of Adverse Events

The impact of SES implantation on the risk of subsequent clinically driven target vessel revascularization in specific subsets is shown in Figure 3. SES implantation was associated with a risk reduction that ranged from 28% to 79% across the subgroups evaluated. However, the benefit of SES did not reach statistical significance in women (HR, 0.59 [95% CI, 0.24 to 1.45]; $P=0.25$) and diabetics (HR, 0.72 [95% CI, 0.30 to 1.77]; $P=0.50$). Patients treated with bifurcation stenting (HR, 0.38 [95% CI, 0.13 to 1.13]; $P=0.08$) and patients receiving 33-mm or longer stents (HR, 0.41 [95% CI, 0.16 to 1.03]; $P=0.06$) presented a strong trend to have better outcomes with SES implantation. In the other subgroups, SES use significantly decreased the need of repeat intervention (Figure 3). Importantly, the postdilation strategy applied in the present study did not influence the clinical benefit of SES implantation. The magnitude of the risk reduction was similar between patients treated with postdilation (HR, 0.28 [95% CI, 0.13 to 0.62]; $P=0.002$) or without postdilation (HR, 0.35 [95% CI, 0.18 to 0.70]; $P=0.003$) procedures.

Multivariate Cox proportional hazards analysis identified SES utilization to be independently associated with a reduced risk of adverse clinical events (Table 4). After adjustment for other independent variables, SES significantly decreased the

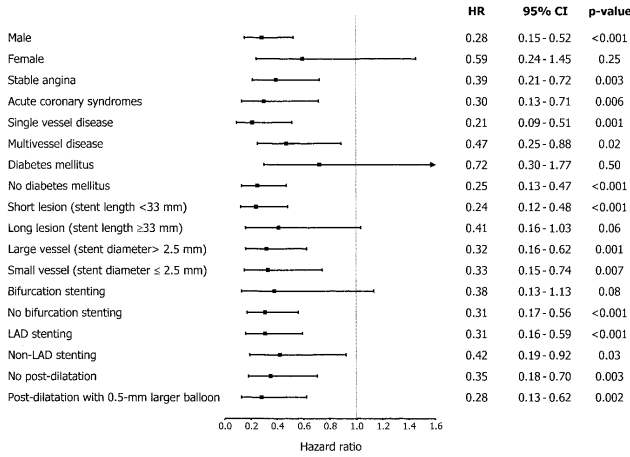


Figure 3. Hazard ratio of 1-year clinically driven target vessel revascularization (Cox proportional hazards models) in subgroups of patients according to baseline and procedural characteristics.

risk of clinically driven target vessel revascularization (adjusted HR, 0.33 [95% CI, 0.20 to 0.56]; $P < 0.01$) and the risk of major adverse cardiac events (adjusted HR, 0.55 [95% CI, 0.38 to 0.80]; $P < 0.01$).

Discussion

SES implantation has been shown to markedly decrease the incidence of in-stent restenosis in the context of randomized trials.^{2,3} However, these studies have enrolled relatively noncomplex patient populations referred for elective intervention. As a consequence, the findings from these studies cannot be directly extrapolated to many patients treated in the everyday practice, where complex, nonelective cases are the rule rather than the exception. In the present study, SES implantation was associated with a reduction in the rates of repeat revascularization and major adverse cardiac events at 1 year in a consecutive, unselected cohort of patients. SES

implantation resulted in a relative reduction of 51% in the overall rate of target vessel revascularization and of 65% in the rate of clinically driven target vessel revascularization.

Our series compared a strategy of unrestricted usage of SES with conventional approaches that used bare stents in the pre-SES era. Although the two study groups were consecutively included over a total period of only 1 year, some important differences were noted in the interventional strategy applied. Patients in the SES phase were treated with a less restrictive interventional approach, with a significant increase in the number and length of stents implanted, number of coronary segments dilated, bifurcation stenting, and decrease in the diameter of the stents. Possibly, this change in practice may reflect the early recognition by the operators that the acute results, even in this complex population, were maintained in the medium term. Also, it may reflect an attempt to accomplish more complete lesion coverage and ensure uniform drug delivery over the entire diseased segment, since stent discontinuity and edge injury have been recently shown by our group to be associated with post-SES restenosis.⁵ Moreover, the higher complex profile of patients treated with SES (eg, high rates of multivessel disease, type C lesions, bifurcations) may translate a change in the decision-making process promoted by the availability of SES in our institution. Although both study groups differed in some baseline and procedural characteristics, which may somewhat limit an unbiased comparison between them, it is worth noting that most if not all differences would be traditionally expected to increase the incidence of late complications in the SES-treated patients. Nevertheless, the treatment effect of SES was significantly higher than bare stents, remaining virtually unaffected after adjustment for procedural characteristics.

The reduction of adverse events after SES implantation in our series is lower than that observed in the RAVEL trial, in which no binary angiographic restenosis was diagnosed.² The present findings more closely resemble those seen in the SIRIUS trial (75% reduction in clinically driven target lesion

TABLE 4. Multivariate Predictors of Adverse Events (Cox Proportional Hazards Model)

	HR	95% CI	P
Major adverse cardiac events*			
SES utilization	0.55	0.38-0.80	<0.01
Cardiogenic shock	4.73	2.31-9.70	<0.01
Diabetes mellitus	1.62	1.09-2.43	0.02
Left main stenting	2.93	1.48-5.82	<0.01
Utilization of at least one 33-mm-long stent	1.54	1.02-2.33	0.04
Clinically driven target vessel revascularization			
SES utilization	0.33	0.20-0.56	<0.01
Acute coronary syndromes†	0.51	0.32-0.80	<0.01
No. of stented segments	1.25	1.01-1.55	0.04
Diabetes mellitus	1.81	1.10-2.99	0.02

*Major adverse cardiac events: death, myocardial infarction, or target vessel revascularization.

†Unstable angina or acute myocardial infarction at admission.

revascularization), in which patients with higher risk profiles were included.³ Compared with the RAVEL study, the relative decline in effectiveness in the SIRIUS trial and in the RESEARCH study may have been related to the complexity of the procedures included. Although SES implantation markedly reduced the risk of subsequent revascularization in most subsets, the benefit of the new treatment did not reach statistical significance in some subgroups in our series. Indeed, the presence of diabetes and treatment of long lesions were shown to independently increase the incidence of complications. These findings highlight the need of further analyses with larger numbers of patients to fully estimate the clinical impact of SES in these patients. Also, whether the outcomes of higher-risk subgroups can be improved with refinements in the procedural techniques remains to be established.

Importantly, the reduction of late complications was accomplished without any increase in unexpected sudden events. Our results extend the findings observed in an early report⁶ and show that SES implantation in complex patients is safe, with no increase in acute device-related adverse events. The incidence (0.4%) and timing (within the first month) of documented thrombotic stent occlusion in the SES group was compatible with the current results with conventional bare metal stents. The utilization of IIb/IIIa inhibitors and clopidogrel differed between both study groups. However, these differences did not significantly influence the clinical outcome in our study. Nevertheless, it should be noted that these agents were not uniformly used across the various patient subsets, being mainly used in cases at a higher risk of complications, which may have blunted the overall positive effect of these drugs.

Although restenotic lesions have been shown to be amenable to treatment by SES,^{9,10} the treatment of de novo lesions may be considered as the main field of application of the new device. In this regard, this study was conducted to evaluate the use of SES as a prophylactic strategy in preventing rather than treating in-stent restenosis in the “real world.”

Some patients were not treated with the SES during the time period of the study. However, in most instances, this was due to unavailability of large-diameter SES. As large vessels have been shown to present a lower risk of restenosis,³ it is quite possible that the noninclusion of patients with larger vessels may have resulted in an underestimation of the overall treatment effect in the present report. The present study is a single-center experience from a tertiary referral center and lacks the obvious advantages of a multicenter, multinational randomized study. Furthermore, it is unlikely that a random-

ized study will be conducted in the context in which this study was performed, with virtually no exclusion criteria.

Conclusions

This study demonstrates that unrestricted utilization of SES in the “real world” is safe and effective in reducing the need of further revascularization and the incidence of major adverse cardiac events after 1 year, as compared with patients treated with bare stent implantation in the period immediately before.

Acknowledgments

This study was supported by the Erasmus Medical Center, Erasmus University, Rotterdam, The Netherlands, and by an unrestricted institutional grant from Cordis, a Johnson & Johnson Company, Miami Lakes, Fla.

References

1. Sousa JE, Costa MA, Abizaid AC, et al. Sustained suppression of neointimal proliferation by sirolimus-eluting stents: one-year angiographic and intravascular ultrasound follow-up. *Circulation*. 2001;104:2007–2011.
2. Morice MC, Serruys PW, Sousa JE, et al. A randomized comparison of a sirolimus-eluting stent with a standard stent for coronary revascularization. *N Engl J Med*. 2002;346:1773–1780.
3. Moses JW, Leon MB, Popma JJ, et al. Sirolimus-eluting stents versus standard stents in patients with stenosis in a native coronary artery. *N Engl J Med*. 2003;349:1315–1323.
4. Degertekin M, Serruys PW, Foley DP, et al. Persistent inhibition of neointimal hyperplasia after sirolimus-eluting stent implantation: long-term (up to 2 years) clinical, angiographic, and intravascular ultrasound follow-up. *Circulation*. 2002;106:1610–1613.
5. Lemos PA, Saia F, Lighthart JMR, et al. Coronary restenosis after sirolimus-eluting stent implantation: morphological description and mechanistic analysis from a consecutive series of cases. *Circulation*. 2003;108:257–260.
6. Lemos PA, Lee C, Degertekin M, et al. Early outcome after sirolimus-eluting stent implantation in patients with acute coronary syndromes: insights from the Rapamycin-Eluting Stent Evaluated At Rotterdam Cardiology Hospital (RESEARCH) registry. *J Am Coll Cardiol*. 2003;41:2093–2099.
7. Smith SC Jr, Dove JT, Jacobs AK, et al. ACC/AHA guidelines of percutaneous coronary interventions (revision of the 1993 PTCA guidelines: a report of the American College of Cardiology/American Heart Association Task Force on Practice Guidelines (committee to revise the 1993 guidelines for percutaneous transluminal coronary angioplasty). *J Am Coll Cardiol*. 2001;37:2239i–ixvii.
8. Ruygrok PN, Melkert R, Morel MA, et al. Does angiography six months after coronary intervention influence management and outcome? Benestent II Investigators. *J Am Coll Cardiol*. 1999;34:1507–1511.
9. Degertekin M, Regar E, Tanabe K, et al. Sirolimus-eluting stent for treatment of complex in-stent restenosis: the first clinical experience. *J Am Coll Cardiol*. 2003;41:184–189.
10. Sousa JE, Costa MA, Abizaid A, et al. Sirolimus-eluting stent for the treatment of in-stent restenosis: a quantitative coronary angiography and three-dimensional intravascular ultrasound study. *Circulation*. 2003;107:24–27.

PART 2

UNRESTRICTED UTILIZATION OF DRUG-ELUTING STENTS

CHAPTER 7

Clinical and Angiographic Outcomes
After Over-Dilatation of Undersized
Sirolimus-Eluting Stents With Largely
Oversized Balloons.
An Observational Study

Authors: Francesco Saia, Pedro A. Lemos,
Chourmouziotis A. Arampatzis, Angela Hoye,
Eugene McFadden, Georgios Sianos, Pieter C.
Smits, Wim J. van der Giessen, Pim J. de Feyter,
Ron T. van Domburg, Patrick W. Serruys.

Cath Cardiovasc Interv 2004;61:455-460

CORONARY ARTERY DISEASE

Original Studies

Clinical and Angiographic Outcomes After Overdilatation of Undersized Sirolimus-Eluting Stents With Largely Oversized Balloons: An Observational Study

Francesco Saia, MD, Pedro A. Lemos, MD, Chourmouziou A. Arampatzis, MD, Angela Hoye, Eugene McFadden, Georgios Sianos, MD, Pieter C. Smits, MD, PhD, Willem J. van der Giessen, MD, PhD, Pim J. de Feyter, MD, PhD, Ron T. van Domburg, PhD, and Patrick W. Serruys,* MD, PhD

The purpose of this study was to assess the safety and effectiveness of sirolimus-eluting stent (SES) postdilatation with largely oversized balloons. We evaluated the clinical outcome of 68 consecutive patients enrolled in the Rapamycin-Eluting Stent Evaluated at Rotterdam Cardiology Hospital (RESEARCH) registry who underwent percutaneous coronary intervention with SES implantation and further postdilatation with balloons > 1 mm larger than the stent nominal size. Angiographic follow-up was either scheduled for selected subgroups or clinically driven. Overall, 75 lesions were treated. The procedure was successful in 98.5% of the cases. One patient (1.5%) underwent emergency coronary bypass surgery for acute vessel occlusion. During 10.1 ± 1.7 months of follow-up, three patients (4.5%) died, one (1.5%) had acute myocardial infarction, and four (6%) had target vessel revascularization. At angiographic follow-up, loss index was 0.13 ± 0.34 and restenosis rate was 7.7%. Although not routinely recommended in every patient, SES postdilatation with largely oversized balloons appears a safe and effective strategy for selected patients. *Catheter Cardiovasc Interv* 2004;61:455–460. © 2004 Wiley-Liss, Inc.

Key words: angioplasty; stent; sirolimus

INTRODUCTION

Stent-based local drug delivery is a relatively new concept developed to prevent neointima hyperplasia growth and restenosis following coronary angioplasty and stenting [1]. While the stent, with its mechanical properties, prevents elastic recoil and negative vessel remodeling, the drug bound on its surface exerts an inhibitory action toward smooth muscle cell proliferation and migration, the most important determinants of in-stent restenosis (ISR).

Sirolimus-eluting stents (SESs) have been shown in randomized trials to virtually abolish in-stent restenosis in selected patients with de novo lesions [2]. The revolutionary results obtained in the first studies have encouraged, in a few pioneer centers, the routine utilization of these new devices, with the double aim of giving the best treatment available to all patients and, at the same time, assessing the efficacy of SESs in more complex clinical

subsets of patients and lesions, such as those found in the daily practice [3].

Several intravascular ultrasound (IVUS) studies have shown that optimal stent deployment was rarely achieved with angiographically guided angioplasty alone [4–6]. The major effect of these studies was the introduction of routine high-pressure stenting [5,7]. Moreover, stent postdilatation with larger balloons has become common

Erasmus MC, Thoraxcenter, Rotterdam, The Netherlands

*Correspondence to: Dr. Patrick W. Serruys, Erasmus MC, Thoraxcenter, Kamer Bd 404, Dr. Molewaterplein 40, 3015 GD Rotterdam, The Netherlands. E-mail: p.w.j.c.serruys@erasmusmc.nl

Received 28 August 2003; Revision accepted 26 November 2003

DOI 10.1002/ccd.20001

Published online in Wiley InterScience (www.interscience.wiley.com).

practice after the documentation of the frequent mismatch between the angiographic and the real vessel diameter [8–10], and the very low incidence of in-stent restenosis observed in the MUSIC study with IVUS-guided stent deployment [11]. The choice to postdilate a stent depends on many factors: operator's habit, attempt to improve suboptimal angiographic results, IVUS-guided stenting. In the AVID study, which evaluated the effects of IVUS-guided stent, additional balloon dilatation based on IVUS findings was performed in 43% of the patients [12]. Similarly, in the CRUISE study, after IVUS examination, the operators decided to use oversized balloons in 34% of the patients [13]. This strategy has been proven to be safe with bare stents and was not reported to hamper the efficacy of drug-eluting stents in the RAVEL trial [2], where it was allowed in order to achieve a less than 20% residual in-stent diameter stenosis.

In daily practice, based on angiographic or intravascular ultrasound findings, extreme overdilatation with balloon > 1 mm larger than the stent nominal size might be required in selected cases to achieve a good procedural result. Moreover, temporary limited availability of properly sized stents could be related to local laboratory's or manufacturers' problems. In the SES, sirolimus is blended in a 5 μ m thick layer of nonerodable polymer. Appropriate drug delivery depends on the polymer integrity and on the proper spatial distribution of the stent struts. Extreme postdilatation of the stent could impair the effectiveness of SES in different ways: by enhancing tissue proliferation in response to greater vessel injury [14], by altering the mechanical properties of the stent, by disrupting the polymer coating, and by increasing the distance between the stent struts, therefore reducing local drug distribution.

In the present study, we evaluated the clinical and angiographic outcomes of 68 patients treated with SES implantation in which a postdilatation with largely oversized balloons was performed.

MATERIALS AND METHODS

Patient Population

SES implantation was adopted as the default strategy for all patients undergoing PCI at our institution as part of the Rapamycin-Eluting Stents Evaluated at Rotterdam Cardiology Hospital (RESEARCH) registry [3]. The SES was available in limited lengths (8, 18, and 33 mm) and diameters (2.25, 2.5, 2.75, and 3.0 mm). In a 4-month period from June to October 2002, 68 consecutive patients underwent SES implantation and further postdilatation with balloons > 1 mm larger than the stent nominal size and comprise the present study population.

Procedure

All procedures were performed according to standard techniques, and the final interventional strategy, as well as periprocedural adjunctive medications and intravascular ultrasound utilization, was left to the operator's discretion. All patients were pretreated with aspirin and clopidogrel. Aspirin was maintained lifelong and at least 3 months of clopidogrel treatment was recommended thereafter. Prolonged clopidogrel prescription (6 months) was recommended for patients treated with SES and at least one of the following characteristics: multiple SES (> 3 stents), total stented length > 36 mm, chronic total occlusion, bifurcations, and in-stent restenosis. The study protocol was approved by the institutional ethics committee and written informed consent was obtained from all patients.

Definitions and Follow-Up

A procedure was considered successful when residual stenosis was < 30% by quantitative coronary analysis together with TIMI flow 3. During follow-up, coronary angiograms were obtained as clinically indicated by symptoms or positive ischemic tests. In addition, follow-up angiograms were scheduled for patients with SES implantation to treat in-stent restenosis, bifurcations, left main, chronic total occlusions, very small vessels (SES diameter 2.25 mm), long stent length (> 36 mm), and acute myocardial infarction. Post-SES binary restenosis at follow-up was defined as > 50% diameter stenosis occurring in the segment inside the SES or within 5 mm segment proximal or distal to the stent. Acute gain was defined as the difference between minimal luminal diameter (MLD) post- and preprocedure. Late loss was calculated as the difference between the MLD immediately after the procedure and the MLD at 6 months. Loss index was defined as the ratio between late loss and acute gain. The incidence of major adverse cardiovascular events (MACEs), defined as death, myocardial infarction, or target vessel revascularization (TVR), was evaluated. A definite diagnosis of MI required an increase in the creatine kinase level to more than twice the upper normal limit with an increased level of creatine kinase-MB.

Target lesion revascularization (TLR) was defined as any surgical or percutaneous reintervention motivated by a significant luminal narrowing within the stent or in the 5 mm distal or proximal persistent segments. TVR was defined as any reintervention driven by lesions located in the treated vessel even beyond the target lesion limits.

Statistical Analysis

Discrete variables are reported as counts and relative percentages. Continuous variables are expressed as mean \pm standard deviation.

TABLE I. Baseline Patient Characteristics

Patients, n	68
Age, years	60 ± 10
Male	45 (66.2%)
Risk factors	
Current smoker	24 (35.3%)
Hypercholesterolemia ^a	40 (58.8%)
Systemic hypertension	22 (32.4%)
Diabetes mellitus	10 (14.7%)
Family history of coronary heart disease	32 (47.1%)
Clinical presentation	
Silent ischemia	3 (4.4%)
Stable angina pectoris	30 (44.1%)
Unstable angina pectoris	19 (27.9%)
Acute myocardial infarction	16 (23.5%)
Multivessel coronary disease	38 (55.9%)
Previous myocardial infarction	21 (30.1%)
Previous coronary bypass	9 (13.2%)
Previous percutaneous coronary intervention	17 (25%)

^aTotal cholesterol > 200 mg/dl and/or on lipid-lowering treatment.

RESULTS

Baseline and Procedural Data

Baseline clinical characteristics of the 68 patients are shown in Table I. Around 15% of the patients had diabetes mellitus and 56% multivessel coronary disease. Notably, 23.5% of the patients presented acute myocardial infarction. Overall, 75 lesions were treated with 101 sirolimus-eluting stents, with an average stent length per lesion of 26.9 ± 18.0 mm. Among the lesions, seven (9.3%) were in the left main and nine (12%) in a saphenous vein graft. Chronic total occlusions (> 3 months) accounted for 24% of the procedures. Nominal stent diameter was 3.0 mm in 98 cases, 2.75 mm in 2, and 2.5 in 1. Further stent postdilatation was performed with a 4.0 mm balloon in 70 lesions and with 4.5 mm balloon in the remaining 5. Average inflation pressure was 15.9 ± 3.6 atm. Nominal balloon-to-artery ratio was 1.31 ± 0.29. IVUS was used in 21 patients (30.8%). In 85.3% of the cases, the SES was implanted to treat a de novo lesion, in 9.3% to treat in-stent restenosis, and in 4% to treat a guiding catheter-induced vessel dissection (Table II). Glycoprotein IIb/IIIa inhibitors were used in 38.2% of the patients. The procedure was successful in 67 patients (98.5%). One patient developed diffuse distal vessel dissection after postdilatation of the 3 × 18 mm SES with a 4 × 15 mm balloon, inflated up to 12 atm, and underwent successful emergency CABG.

Clinical Follow-Up

Clinical follow-up was available for 67 patients (98.5%). During an average follow-up of 10.1 ± 1.7 months, three (4.5%) patients died, one (1.5%) had acute myocardial infarction, and four (6%) had a TVR, of which three were TLR (4.5%). Overall MACE rate was

TABLE II. Angiographic and Procedural Characteristics

Lesions, n	75
Target coronary artery	
Left anterior descending	21 (28.0%)
Left circumflex artery	6 (8.0%)
Right coronary artery	32 (42.7%)
Left main	7 (9.3%)
Saphenous vein graft	9 (12.0%)
Lesion type	
De novo	64 (85.3%)
In-stent restenosis	7 (9.3%)
Early reintervention	1 (1.3%)
Guiding catheter injury/dissection	3 (4.0%)
Lesion type (AHA/ACC classification)	
Type A	4 (5.3%)
Type B1	18 (24.0%)
Type B2	29 (38.7%)
Type C	24 (32.0%)
Thrombus-containing lesions	16 (21.3%)
Moderate/severe calcifications	9 (12.0%)
Ostial lesions	23 (30.7%)
Bifurcation stenting	4 (5.2%)
Chronic total occlusions	18 (24%)
Glycoprotein IIb/IIIa inhibitors ^a	26 (38.2%)
Stent per lesion, n	1.35 ± 0.65
Stents length per lesion, mm	26.9 ± 18.0

^aPercentage relative to the number of patients (68).

12.0%. One patient was admitted with acute large infero-posterior myocardial infarction and cardiogenic shock, which was irreversible despite positioning of intra-aortic balloon pump. A second patient died 5 months after the procedure because of end-stage renal failure. The cause of death of the third patient, who died 141 days after the revascularization procedure, is unknown: he was 75 years old, diabetic, with three-vessel disease and moderate aortic valve stenosis, and had received an SES in the proximal right coronary artery. One patient had a small periprocedural myocardial infarction (CK max = 346 UI/L; MB = 73 UI/L). The angioplasty was performed in a saphenous vein graft, which was totally occluded due to in-stent restenosis. Among the four target vessel reinterventions, only one was motivated by restenosis. The remaining were one case of emergency bypass surgery, already described, one early (5 days) percutaneous reintervention caused by incomplete ostial coverage of the right coronary artery during the index procedure, and one case of in-stent redilatation driven by IVUS diagnosis of stent undersizing despite the absence of angiographic restenosis (the patient was symptomatic and presented angiographic restenosis in another lesion located distally in the same vessel, a saphenous vein graft). There were no documented episodes of early or late stent thromboses.

Angiographic Results

Angiographic follow-up was obtained in 34 patients for 39 lesions after 210 ± 29 days (range, 156–309

TABLE III. Paired Quantitative Angiographic Analysis at Baseline, Postprocedure, and Follow-Up for Patients With Angiographic Follow-Up

	Preprocedure	Postprocedure	Follow-up
Reference diameter, mm	3.18 ± 0.63	3.36 ± 0.40	3.43 ± 0.46
Minimum lumen diameter, mm	0.68 ± 0.62	2.88 ± 0.42	2.66 ± 0.77
Diameter stenosis, %	77 ± 22	14 ± 9	20 ± 21
Lesion length, mm	20.1 ± 14.1		
Acute gain, mm		2.22 ± 0.73	
Late loss, ^a mm			0.24 ± 0.61
Loss index			0.13 ± 0.34
Binary post-SES restenosis, %			7.7%

^aIncluding one total reocclusion.

days). As previously specified, the reasons for repeat catheterization were elective follow-up because the patient was included in selected subgroups in 32 cases (72.7% of the 44 patients scheduled for 6-month angiography) and clinically driven recatheterization in 2 patients. At baseline, mean reference diameter was 3.21 ± 0.58 mm, MLD 0.86 ± 0.61 mm, percent diameter stenosis $72\% \pm 21\%$, and lesion length 17.9 ± 11.5 mm. Paired quantitative coronary analysis for patients with angiographic follow-up is shown in Table III. Late loss was 0.24 ± 0.61 mm, with 76% of the cases in the range between -0.5 and 0.5 mm. Loss index was 0.13 ± 0.34 . Overall, post-SES binary restenosis was observed in three lesions (7.7%): two were proximal edge restenosis, and in one patient the vessel was occluded approximately 30 mm proximally to the target lesion.

DISCUSSION

In the present study, we show that postdilatation of sirolimus-eluting stents with largely oversized balloons is relatively safe and associated with good angiographic results.

IVUS studies have demonstrated that incomplete stent deployment may occur in a considerable number of patients even with high-pressure techniques [6,15]. Optimal stent expansion plays a key role in the prevention of stent thrombosis [4]. Moreover, previous studies have shown that residual percent diameter stenosis after stent implantation is directly related to the development of restenosis [16,17]. Similarly, in-stent minimal lumen cross-sectional area measured by IVUS is inversely related to restenosis [18]. All together, these findings provide the rationale to pursue optimal stent expansion. This outcome is often achieved by performing stent postdilatation with balloons oversized with respect to the nominal stent size. Overdilatation with balloons > 0.25 mm larger has been shown to improve lumen gain and possibly reduce the need for target vessel revascularization, without increasing complications [9,10,19]. However, in one study, IVUS examination revealed that even with this strategy,

no stent reached its nominal size [19]. Thus, it is commonly believed that postdilatation with balloons up to 0.5 mm larger than the stent nominal size can be safely accomplished in most of the cases. Conversely, dilatation with balloons > 0.5 mm larger than the stent nominal size is a rare procedure. In clinical practice, this extreme postdilatation is performed in selected patients, commonly when the operator has the perception, based on angiographic or IVUS findings, that the stent implanted is markedly undersized relatively to the vessel diameter. In other situations, this choice could be driven, in a bailout procedure, by unavailability of the proper size of stents. In both cases, this strategy should be regarded as an extreme solution, not free from potential complications. Possible stent structure distortion and disruption must be taken into account, as well as the chance of extensive intimal dissection and vessel wall rupture. When the same strategy is applied with drug-eluting stents, further possible shortcomings should be considered. In fact, the success of drug-eluting stents depends critically on the achievement of the appropriate local drug concentration, which warrants potent antiproliferative effects and preserved vascular healing. The elution profile and release kinetics of the drug depend on the biological properties of the drug and of the coating matrix [1]. Apart from the potential mechanical damages to the stent, excessive SES postdilatation could impair their antiproliferative properties by damaging the polymer coating. Moreover, by increasing the distance between the drug-carrying stent struts, overdilatation could decrease local sirolimus concentration to a suboptimal or ineffective level. The results of the present study suggest that these potential risks do not have an evident impact on the favorable clinical and angiographic outcome of SES, although some negative influence cannot be ruled out in single cases [20]. In our series, extreme SES postdilatation was not associated with a high rate of acute complication, although one patient had to be referred for emergency coronary surgery. The clinical outcome at mid-term follow-up was favorable, and the 12% incidence of MACEs appears very satisfactory if we consider

TABLE IV. Angiographic Measurements Compared to the MUSIC Study

	MUSIC	SES overdilatated
Reference diameter pre, mm	3.09 ± 0.49	3.18 ± 0.63
Reference diameter post, mm	3.40 ± 0.54	3.36 ± 0.40
Reference diameter at 6 months, mm	3.04 ± 0.51	3.43 ± 0.46
Minimum lumen diameter pre, mm	1.13 ± 0.34	0.68 ± 0.62
Minimum lumen diameter post, mm	2.90 ± 0.36	2.88 ± 0.42
Minimum lumen diameter at 6 months, mm	2.12 ± 0.67	2.66 ± 0.77
Diameter stenosis pre, %	63 ± 10	77 ± 22
Diameter stenosis post, %	15 ± 6	14 ± 9
Diameter stenosis at 6 months, %	30 ± 17	20 ± 21
Nominal balloon:artery ratio	1.20 ± 0.15	1.31 ± 0.29
Maximal inflation pressure	15.8 ± 3.33	15.9 ± 3.6
Acute gain, mm	1.79 ± 0.39	2.22 ± 0.73
Late loss, mm	0.78 ± 0.56	0.24 ± 0.61
Loss index	0.45 ± 0.33	0.13 ± 0.34

the unselected nature of the population analyzed, which included 24% of the patients with acute myocardial infarction. Notably, 9% of the lesions treated were in the left main and 12% in a saphenous vein graft. Moreover, at angiographic follow-up, restenosis was observed in a very limited number of patients. Although only 50% of the patients underwent repeat catheterization, the selection criteria of these patients (complex lesions and symptomatic patients) would have been expected to increase the chance of finding restenotic lesions, thus indirectly confirming the very positive results obtained. Remarkably, almost one-fourth of the lesions were chronic total occlusions, condition traditionally associated with higher restenosis rates [21,22]. Indeed, the loss index of the present series (0.13 ± 0.34) compares favorably with the historical series of the BENESTENT trial (0.46 ± 1.39), the BENESTENT II Pilot study (0.41 ± 1.18), and the MUSIC study (0.45 ± 0.33) using bare stents (Table IV) [11].

In conclusion, angiographically or intravascular-guided postdilatation of SES with largely oversized balloons could be considered an extreme solution for stent undersizing. Although careful case-by-case evaluation in these situations is necessary, this strategy appears relatively safe and does not seem to impair the effectiveness of sirolimus-eluting stents.

REFERENCES

- Sousa JE, Serruys PW, Costa MA. New frontiers in cardiology: I, drug-eluting stents. *Circulation* 2003;107:2274–2279.
- Morice MC, Serruys PW, Sousa JE, Fajadet J, Ban Hayashi E, Perin M, Colombo A, Schuler G, Barragan P, Guagliumi G, Molnar F, Falotico R. A randomized comparison of a sirolimus-eluting stent with a standard stent for coronary revascularization. *N Engl J Med* 2002;346:1773–1780.

- Lemos PA, Lee C, Degertekin M, Saia F, Tanabe K, Arampatzis CA, Hoye A, van Duuren M, Sianos G, Smits PC, de Feyter P, van der Giessen WJ, van Domburg RT, Serruys PW. Early outcome after sirolimus-eluting stent implantation in patients with acute coronary syndromes: insights from the Rapamycin-Eluting Stent Evaluated at Rotterdam Cardiology Hospital (RESEARCH) registry. *J Am Coll Cardiol* 2003;41:2093–2099.
- Colombo A, Hall P, Nakamura S, Almagor Y, Maiello L, Martini G, Gaglione A, Goldberg SL, Tobis JM. Intracoronary stenting without anticoagulation accomplished with intravascular ultrasound guidance. *Circulation* 1995;91:1676–1688.
- Gorge G, Haude M, Ge J, Voegelé E, Gerber T, Rupprecht HJ, Meyer J, Erbel R. Intravascular ultrasound after low and high inflation pressure coronary artery stent implantation. *J Am Coll Cardiol* 1995;26:725–730.
- Nakamura S, Colombo A, Gaglione A, Almagor Y, Goldberg SL, Maiello L, Finci L, Tobis JM. Intracoronary ultrasound observations during stent implantation. *Circulation* 1994;89:2026–2034.
- Stone GW, St Goar FG, Hodgson JM, Fitzgerald PJ, Alderman EL, Yock PG, Coverdale J, Sheehan H, Linnemeier TJ. Analysis of the relation between stent implantation pressure and expansion: Optimal Stent Implantation (OSTI) investigators. *Am J Cardiol* 1999;83:1397–1400.
- Glagov S, Weisenberg E, Zarins CK, Stankunavicius R, Kolletis GJ. Compensatory enlargement of human atherosclerotic coronary arteries. *N Engl J Med* 1987;316:1371–1375.
- Stone GW, Hodgson JM, St Goar FG, Frey A, Mudra H, Sheehan H, Linnemeier TJ. Improved procedural results of coronary angioplasty with intravascular ultrasound-guided balloon sizing: the CLOUT pilot trial. *Circulation* 1997;95:2044–2052.
- Schroeder S, Baumbach A, Haase KK, Oberhoff M, Marholdt H, Herdeg C, Athanasiadis A, Karsch KR. Reduction of restenosis by vessel size adapted percutaneous transluminal coronary angioplasty using intravascular ultrasound. *Am J Cardiol* 1999;83:875–879.
- de Jaegere P, Mudra H, Figulla H, Almagor Y, Doucet S, Penn I, Colombo A, Hamm C, Bartorelli A, Rothmann M, Nobuyoshi M, Yamaguchi T, Voudris V, Di Mario C, Makovski S, Hausmann D, Rowe S, Rabinovich S, Sunamura M, van Es GA. Intravascular ultrasound-guided optimized stent deployment: immediate and 6 months clinical and angiographic results from the Multicenter Ultrasound Stenting in Coronaries study (MUSIC study). *Eur Heart J* 1998;19:1214–1223.
- Russo RJ, Attubato MJ, Davidson CJ, et al. Angiography versus intravascular ultrasound-directed stent placement: final results from AVID. *Circulation* 1999;100(Suppl 1):I234.
- Fitzgerald PJ, Oshima A, Hayase M, Metz JA, Bailey SR, Baim DS, Cleman MW, Deusch E, Diver DJ, Leon MB, Moses JW, Oesterle SN, Overlie PA, Pepine CJ, Safian RD, Shani J, Simonson CA, Smalling RW, Teirstein PS, Zidar JP, Yeung AC, Kuntz RE, Yock PG, for the CRUISE investigators. Final results of the Can Routine Ultrasound Influence Stent Expansion (CRUISE) study. *Circulation* 2000;102:523–530.
- Hoffmann R, Mintz GS, Mehran R, Kent KM, Pichard AD, Satler LF, Leon MB. Tissue proliferation within and surrounding Palmaz-Schatz stents is dependent on the aggressiveness of stent implantation technique. *Am J Cardiol* 1999;83:1170–1174.
- Bermejo J, Botas J, Garcia E, Elizaga J, Osende J, Soriano J, Abeytua M, Delcan JL. Mechanisms of residual lumen stenosis after high-pressure stent implantation: a quantitative coronary angiography and intravascular ultrasound study. *Circulation* 1998; 98:112–118.

16. Serruys PW, Kay IP, Disco C, Deshpande NV, de Feyter PJ. Periprocedural quantitative coronary angiography after Palmaz-Schatz stent implantation predicts the restenosis rate at six months: results of a meta-analysis of the BENESTENT I, BENESTENT II Pilot, BENESTENT II and MUSIC trials. *J Am Coll Cardiol* 1999;34:1067-1074.
17. Serruys PW, Deshpande NV. Is there MUSIC in IVUS guided stenting? is this MUSIC going to be a MUST? *Eur Heart J* 1998;19:1122-1124.
18. de Feyter PJ, Kay P, Disco C, Serruys PW. Reference chart derived from post-stent-implantation intravascular ultrasound predictors of 6-month expected restenosis on quantitative coronary angiography. *Circulation* 1999;100:1777-1783.
19. Johansson B, Allared M, Borgencrantz B, Brorson L, Geijer H, Kellerth T, Olsson H, Ragnarsson A, Skoglund H, Wennerblom B. Standardized angiographically guided over-dilatation of stents using high pressure technique optimize results without increasing risks. *J Invas Cardiol* 2002;14:221-226.
20. Lemos PA, Saia F, Ligthart JM, Arampatzis CA, Sianos G, Tanabe K, Hoye A, Degertekin M, Daemen J, McFadden E, Hofma S, Smits PC, De Feyter P, Van Der Giessen WJ, Van Domburg RT, Serruys PW. Coronary restenosis after sirolimus-eluting stent implantation: morphological description and mechanistic analysis from a consecutive series of cases. *Circulation* 2003;108:257-260.
21. Violaris G, Melkert R, Serruys PW. Long-term luminal renarrowing after successful elective coronary angioplasty of total occlusions. A quantitative angiographic analysis. *Circulation* 1995;91:2140-2150.
22. Berger PB, Holmes DR, Ohman EM, O'Hanesian MA, Murphy JG, Schwartz RS, Serruys PW, Faxon DP, for the MARCATOR investigators. Restenosis, reocclusion and adverse cardiovascular events after successful balloon angioplasty of occluded versus nonoccluded coronary arteries: results from the Multicenter American Research Trial With Cilazapril After Angioplasty to Prevent Transluminal Coronary Obstruction and Restenosis (MARCATOR). *J Am Coll Cardiol* 1996;27:1-7.

PART 2

UNRESTRICTED UTILIZATION OF DRUG-ELUTING STENTS

CHAPTER 8

Coronary Restenosis After Sirolimus-Eluting Stent Implantation. Morphological Description and Mechanistic Analysis From a Consecutive Series of Cases

Authors: Pedro A. Lemos, Francesco Saia, Jurgen M.R. Ligthart, Chourmouzios A. Arampatzis, Georgios Sianos, Kengo Tanabe, Angela Hoye, Muzaffer Degertekin, Joost Daemen, Eugene McFadden, Sjoerd Hofma, Pieter C. Smits, Pim de Feyter, Willem J. van der Giessen, Ron T. van Domburg, Patrick W. Serruys.

Circulation 2003; 108:257-260

Brief Rapid Communications

Coronary Restenosis After Sirolimus-Eluting Stent Implantation

Morphological Description and Mechanistic Analysis From a Consecutive Series of Cases

Pedro A. Lemos, MD; Francesco Saia, MD; Jurgen M.R. Ligthart, BSc;
 Chourmouziou A. Arampatzis, MD; Georgios Sianos, MD; Kengo Tanabe, MD;
 Angela Hoye, MBChB, MRCP; Muzaffer Degertekin, MD; Joost Daemen; Eugene McFadden, MB;
 Sjoerd Hofma, MD; Pieter C. Smits, MD, PhD; Pim de Feyter, MD, PhD;
 Willem J. van der Giessen, MD, PhD; Ron T. van Domburg, PhD; Patrick W. Serruys, MD, PhD

Background—We describe the clinical and morphological patterns of restenosis after sirolimus-eluting stent (SES) implantation.

Methods and Results—From 121 patients with coronary angiography obtained >30 days after SES implantation, restenosis (diameter stenosis >50%) was identified in 19 patients and 20 lesions (located at the proximal 5-mm segment in 30% or within the stent in 70%). Residual dissection after the procedure or balloon trauma outside the stent was identified in 83% of the proximal edge lesions. Lesions within the stent were focal, and stent discontinuity was identified in some lesions evaluated by intravascular ultrasound.

Conclusions—Sirolimus-eluting stent edge restenosis is frequently associated with local trauma outside the stent. In-stent restenosis occurs as a localized lesion, commonly associated with a discontinuity in stent coverage. Local conditions instead of intrinsic drug-resistance to sirolimus are likely to play a major role in post-SES restenosis. (*Circulation*. 2003; 108:257-260.)

Key Words: restenosis ■ stents ■ angioplasty

Sirolimus-eluting stents (SES) have been reported to reduce restenosis by inhibiting neointimal growth,¹ though post-SES restenosis may still occur in some cases.² Currently, the clinical and morphological features of restenosis after SES implantation are unknown. In this study, we describe a consecutive series of patients with angiographic restenosis after SES implantation.

See p 248

Methods

Since April 2002, SES (Cypher; Cordis Europa NV) have been used as the device of choice for percutaneous coronary intervention in our institution, as part of the *Rapamycin-Eluting Stent Evaluated At Rotterdam Cardiology Hospital* (RESEARCH) registry,³ a single-center registry designed to evaluate the impact of SES implantation in the "realworld." During follow-up, coronary angiograms were obtained as clinically indicated by symptoms or positive ischemic tests. In addition, follow-up angiograms were obtained at 6±1 month for "complex" patients, typically with SES implantation to treat in-stent restenosis, bifurcations, left main, chronic total occlusions, very small vessels (SES diameter 2.25 mm), long stented length

(>36 mm), and acute myocardial infarction. Intravascular ultrasound (IVUS) was performed at the discretion of the operator. The study protocol was approved by the institutional ethics committee, and written informed consent was obtained from all patients.

Binary restenosis was defined by diameter stenosis >50% and classified as (1) in-stent, if inside the stent, or (2) edge restenosis, if located within the 5-mm segments distal or proximal to the stent margins. Restenosis at an ostial location was classified as in-stent, unless clearly located outside the limits of the SES, in which case it was classified as edge restenosis. Discrete variables were presented as counts and percentages. Continuous variables were presented as mean±SD and compared by Student's *t* test.

Results

To date, 192 patients with at least one of the aforementioned "complex" characteristics have completed ≥7 months from the index procedure. A coronary angiogram performed >30 days after the angioplasty was obtained in 121 patients (221 lesions). Among these, post-SES restenosis was identified in 19 patients and 20 lesions (Table). IVUS was available at follow-up for 11 patients with restenosis (58%). In total, 6 lesions (30%) were located at the proximal edge and 14 were

Received March 25, 2003; de novo received May 2, 2003; revision received June 3, 2003; accepted June 5, 2003.

From Erasmus Medical Center, Thoraxcenter, Rotterdam, the Netherlands.

Correspondence to Prof P.W. Serruys, MD, PhD, Thoraxcenter, Bd-406, Dr Molewaterplein 40, 3015-GD Rotterdam, The Netherlands. E-mail p.w.j.c.serruys@erasmusmc.nl

© 2003 American Heart Association, Inc.

Patients With Restenosis After Sirolimus-Eluting Stent Implantation: Clinical, Procedural, and Morphological Characteristics

Patient No.	1	2	3	4	5	6	7	8	9	10	11	12	13	14	15	16	17	18	19	Total	
Age, y	63	77	52	66	70	78	77	58	69	43	58	50	52	50	46	72	45	48	61	56 ±11	
Gender	M	M	M	M	M	F	M	M	F	M	M	M	M	M	M	M	M	M	M	M	89% (men)
Diabetes	0	+	0	0	0	0	0	+	+	+	0	+	+	0	0	0	+	0	0	37%	
Symptoms/ischemia at follow-up	0	+	+	0	+	+	0	0	+	+	0	0	+	+	0	+	+	+	0	58%	
Lesions treated	1	1	3	1	3	3	2	3	2	3	2	3	2	1	2	6	1	1	2	42	
Lesions with restenosis	1	1	1	1	1	2	1	1	1	1	1	1	1	1	1	1	1	1	1	20 (48%)	
Vessel	LAD	LAD	LAD	DG	SVG	LAD	LCx	RCA	RPL	LCx	DG	DG	LAD	RCA	LAD	RCA	SVG	LCx	RCA	DG	...
Procedural, angiographic, and IVUS findings																					
Treatment of previous in-stent restenosis	0	0	0	0	0	0	0	0	0	+	0	0	0	0	+	0	+	+	+	0	25%
Moderate/severe calcification	0	+	0	+	0	+	+	0	0	0	0	+	0	0	0	0	0	0	0	0	25%
CTO	0	0	0	0	+	+	0	0	0	0	0	0	+	+	+	0	0	+	+	0	35%
Trauma outside the stent/residual dissection	+	+	+	+	+	0	83%†
Residual edge lesion‡	0	0	+	+	0	0	33%†
After dilation with balloon ≥0.5 mm larger	+	0	+	0	+	0	0	0	0	+	0	0	0	0	+	+	+	0	+	+	45%
Bifurcation stenting	0	0	+\$	0	0	+\$	0	0		0			0	+\$	0	0	0	0	0	+	35%
Ostial	0	0	0	+	0	0	+	0	+	0	+	+	0	0	0	0	0	0	0	+	30%
Stented length >33 mm	0	0	+	0	+	0	0	+	0	0	0	0	0	+	+	+	0	+	+	0	40%
2.25-mm diameter SES	0	0	0	+	0	0	0	0	0	0	+	0	0	0	0	0	0	+	0	0	15%
Stent fracture or gap between stents¶	0	0	0	NA	NA	NA	NA	NA	NA	NA	NA	NA	0	+	0	+	0	0	+	+	50%#
Stent underexpansion at restenosis site¶	0	0	0	NA	NA	NA	NA	NA	NA	NA	NA	+	0	0	0	+	0	0	0	0	25%#
No. of any above (+ diabetes)	2	3	5	5	4	3	2	1	3	3	4	2	3	5	4	3	3	5	5	4	Range 1–5
Post-SES restenosis characteristics																					
Location	prox	prox	prox	prox	prox	prox	in-st	in-st	in-st	in-st	in-st	in-st	in-st	in-st	in-st	in-st	in-st	in-st	in-st	in-st	
Total occlusion	0	0	0	0	+	+	0	0	0	0	0	0	0	0	0	0	0	0	0	0	10%
Focal lesion (length <10 mm)	+	+	+	0	0	0	+	+	+	+	0	0	+	+	+	+	+	+	+	+	86%††

CTO indicates chronic total occlusion; DG, diagonal; IVUS, intravascular ultrasound; in-st, in-stent restenosis; LAD, left anterior descending; LCx, left circumflex artery; NA, IVUS not available; prox, proximal edge restenosis; RCA, right coronary artery; RPL, right posterolateral branch; SES, sirolimus-eluting stent; SVG, saphenous vein graft; +, present; and 0, absent.

*After brachytherapy.

†Relative to proximal edge restenosis.

‡Angiographic diameter stenosis >30% or IVUS plaque burden >50%.

§Main vessel restenosis.

||Side branch restenosis.

¶Diagnosed by IVUS.

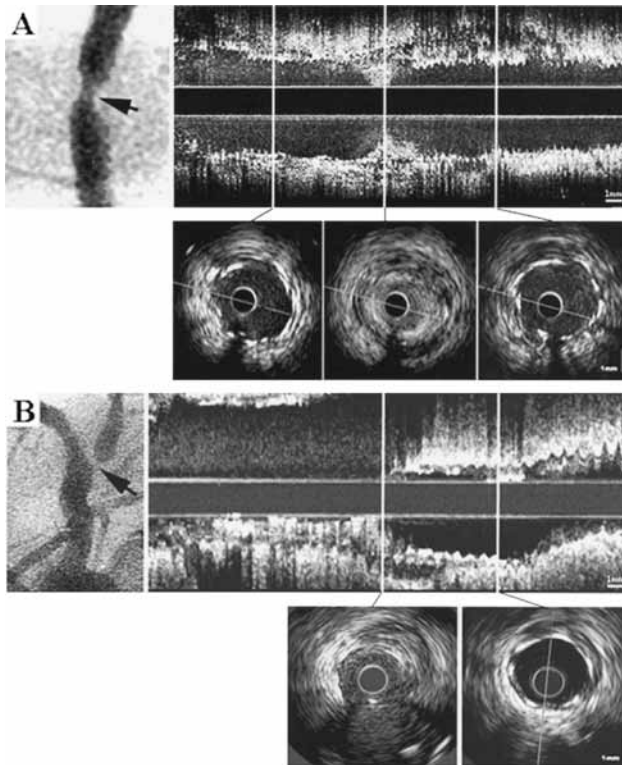
#Relative to the No. of in-stent restenoses with available IVUS.

**More than 1 "focal" site.

††Relative to the No. of in-stent restenoses.

in-stent (70%). Local injury outside the stent was observed in 5 cases of edge restenosis (83%), as evidenced by the presence of angiographic or IVUS residual dissection after the procedure (patients 1, 3, and 4), by balloon dilation at a

nonstented area in a patient with extensive manipulation before and after implantation of 4 stents for acute occlusion (patient 2), or by balloon postdilation outside the stent (patient 5).



Focal restenosis at a gap between stents. A, Short restenosis (angiogram, arrowhead) was noted at site where no stent struts were visualized on IVUS examination (IVUS cross section, mid). Stent coverage was complete at proximal and distal segments, with no neointimal tissue present (IVUS cross sections left and right, respectively). Longitudinal IVUS reconstruction showed localized pattern of restenosis. B, Ostial restenosis (angiogram, arrowhead) was associated with incomplete coverage by SES (IVUS cross section left and longitudinal reconstruction). Distal segment presented no neointimal proliferation inside the stent (IVUS cross section right and longitudinal reconstruction).

Among the 14 in-stent lesions, 12 (86%) were focal (restenosis length <10 mm)⁴ and presented a peculiar angiographic pattern manifested by a very localized stenotic site bordered by segments without evidence of lumen compromise (Figure, A). Stenosis length decreased from 19.1 ± 19.1 mm at baseline to 7.6 ± 5.6 mm at follow-up ($P=0.046$). The ratio of restenosis length/stent length was 0.3 ± 0.2 . A gap between stents or stent fracture at the site of the restenosis was detected by IVUS in 4 patients at follow-up. A gap was diagnosed by the absence of stent struts in at least one IVUS cross section in the examination of the region between two stents (patients 13, 18, and 19); a stent fracture was diagnosed by the nonvisualization of struts within the stent (patients 15 and 18). One patient presented both stent gap and fracture in separate sites (patient 18). In this patient, no IVUS was performed at the index procedure (IVUS was done only at follow-up). In the other patient with stent fracture (patient 15), the stent discontinuity was not evident after the procedure, being only detected at the follow-up. In all cases, the stent gap or fracture could not be noticed angiographically and measured <1 mm in length by IVUS (Figure, A).

Among the 6 ostial lesions (30%), the ostium was not covered by the stent at angiographic inspection in 1 case

(classified as proximal edge restenosis). The remaining 5 lesions appeared to be fully covered by the stent on angiography. IVUS was available for only one of these cases. In this patient, although angiographically unnoticed, a short area at the ostium was observed to be uncovered by SES (Figure, B). Among the 6 ostial lesions, 4 were located in the side branch of bifurcation stenting treatment, all treated with “T”stent technique (stent in the side branch implanted with its proximal border located at the ostium of the branch; stent in the main vessel implanted encompassing the side branch ostium, thereby creating a “T” configuration).⁵

Discussion

In $\approx 90\%$ of patients with in-stent restenosis after SES implantation, the lesion was very localized and bordered by segments with no evidence of neointima. The effect of the drug in the nonrestenotic portions indicates that an intrinsic resistance to sirolimus was unlikely in most of our patients. Among lesions evaluated by IVUS, stent discontinuity was identified in 36% of cases (and in 50% of restenosis located inside the stent), suggesting that a decrease in local drug availability may have contributed to the development of restenosis in these cases. Accordingly,

our findings suggest that incomplete lesion coverage by the SES also may influence the occurrence of restenosis at the stent borders and at ostial sites. We may speculate that although no clinical data are currently available, techniques that ensure complete vessel scaffolding could constitute an alternative for SES implantation at bifurcations.⁶ Edge restenosis occurred more frequently in the proximal than in the distal stent border. Whether this finding is associated with a more effective drug effect in the outflow stent border remains to be clarified. In addition, 37% of our cases were diabetics. It may be hypothesized that the presence of diabetes mellitus may lead to a higher predisposition to post-SES restenosis.

The current study presents several limitations. Angiographic follow-up was available for complex patients or for those with recurrent symptoms, therefore precluding an evaluation of the total restenosis rate for the global treated population. Moreover, the lack of IVUS limits a more detailed description of the mechanisms involved in the occurrence of post-SES restenosis in some patients.

Conclusions

Restenosis after sirolimus-eluting stent placement occurs within or adjacent to the stent. Edge restenosis is fre-

quently associated with local trauma outside the stented segment. In-stent restenosis occurs as a very localized lesion, associated with complex anatomy (especially ostial lesions), stent discontinuity, or diabetes. A systemic drug resistance to sirolimus seemed to be unlikely in most patients.

References

1. Morice MC, Serruys PW, Sousa JE, et al. A randomized comparison of a sirolimus-eluting stent with a standard stent for coronary revascularization. *N Engl J Med.* 2002;346:1773–1780.
2. Degertekin M, Regar E, Tanabe K, et al. Sirolimus-eluting stent for treatment of complex in-stent restenosis: the first clinical experience. *J Am Coll Cardiol.* 2003;41:184–189.
3. Lemos PA, Lee CH, Degertekin M, et al. Early Outcome after Sirolimus-Eluting Stent Implantation in Patients with Acute Coronary Syndromes: insights from the Rapamycin-Eluting Stent Evaluated At Rotterdam Cardiology Hospital (RESEARCH) registry. *J Am Coll Cardiol.* 2003;41:2093–2099.
4. Mehran R, Dangas G, Abizaid AS, et al. Angiographic patterns of in-stent restenosis: classification and implications for long-term outcome. *Circulation.* 1999;100:1872–1878.
5. Sheiban I, Albiero R, Marsico F, et al. Immediate and long-term results of “ T”stenting for bifurcation coronary lesions. *Am J Cardiol.* 2000;85:1141–1144, A9.
6. Chevalier B, Glatt B, Royer T, et al. Placement of coronary stents in bifurcation lesions by the “ culotte” technique. *Am J Cardiol.* 1998;82:943–949.

PART 3

SIROLIMUS-ELUTING STENT IMPLANTATION IN PATIENTS WITH ACUTE MYOCARDIAL INFARCTION

CHAPTER 9

Sirolimus-Eluting Stent Implantation in
ST-Elevation Acute Myocardial Infarction.
A Clinical and Angiographic Study

Authors: Francesco Saia, Pedro A. Lemos,
Chi-Hang Lee, Chourmouziou A. Arampatzis,
Angela Hoye, Muzaffer Degertekin,
Kengo Tanabe, Georgios Sianos, Pieter C. Smits,
Eugene McFadden, Sjoerd H. Hofma,
Willem J. van der Giessen, Pim J. de Feyter,
Ron T. van Domburg, Patrick W. Serruys.

Circulation 2003;108:1927-1929

Sirolimus-Eluting Stent Implantation in ST-Elevation Acute Myocardial Infarction

A Clinical and Angiographic Study

Francesco Saia, MD; Pedro A. Lemos, MD; Chi-Hang Lee, MD; Chourmouzos A. Arampatzis, MD; Angela Hoye, MB ChB, MRCP; Muzaffer Degertekin, MD; Kengo Tanabe, MD; Georgios Sianos, MD, PhD; Pieter C. Smits, MD, PhD; Eugene McFadden, MB ChB, MRCP; Sjoerd H. Hofma, MD; Willem J. van der Giessen, MD, PhD; Pim J. de Feyter, MD, PhD; Ron T. van Domburg, PhD; Patrick W. Serruys, MD, PhD

Background—Sirolimus-eluting stents (SES) have recently been proven to reduce restenosis and reintervention compared with bare stents. Safety and effectiveness of SES in acute myocardial infarction remain unknown.

Methods and Results—Since April 16, 2002, a policy of routine SES implantation has been instituted in our hospital, with no clinical or anatomic restrictions, as part of the RESEARCH (Rapamycin-Eluting Stent Evaluated At Rotterdam Cardiology Hospital) registry. During 6 months of enrollment, 96 patients with ST-elevation acute myocardial infarction underwent percutaneous recanalization and SES implantation; these patients comprise the study population. The incidence of major adverse cardiac events (death, nonfatal myocardial infarction, reintervention) was evaluated. Six-month angiographic follow-up was scheduled per protocol. At baseline, diabetes mellitus was present in 12.5% and multivessel disease in 46.9%. Primary angioplasty was performed in 89 patients (92.7%). Infarct location was anterior in 41 (42.7%) of the cases, and 12 patients (12.5%) had cardiogenic shock. Postprocedural TIMI-3 flow was achieved in 93.3% of the cases. In-hospital mortality was 6.2%. One patient (1.1%) had reinfarction and target lesion reintervention the first day as a result of distal dissection and acute vessel occlusion. During follow-up (mean follow-up of 218 ± 75 days), 1 patient died (1.1%), no patient had recurrent myocardial infarction, and there were no additional reinterventions. No early or late stent thromboses were documented. At angiographic follow-up (70%), late loss was -0.04 ± 0.25 , and no patient presented angiographic restenosis.

Conclusions—In this study, sirolimus-eluting stent implantation for patients with ST-elevation acute myocardial infarction was safe without documented angiographic restenosis at 6 months. (*Circulation*. 2003;108:1927-1929.)

Key Words: myocardial infarction ■ drugs ■ stents ■ restenosis

Routine stent implantation has been shown to have a better procedural success rate and clinical outcome than balloon angioplasty in patients presenting with acute myocardial infarction (AMI).¹ However, in-stent restenosis and vessel reocclusion remain significant clinical problems limiting the long-term success of percutaneous treatment.^{1,2}

Sirolimus-eluting stents (SES) have been proven to virtually abolish in-stent restenosis in elective patients with relatively simple lesions,³ with persistent neointimal growth inhibition up to 2 years.⁴ Recently, we have demonstrated that the 30-day outcomes of SES implantation for patients with acute coronary syndromes were similar to those of a control population treated with bare stents.⁵ Nevertheless, no specific information is presently available regarding the safety of these new devices in patients with AMI. Furthermore, the long-term clinical efficacy of SES for AMI is unknown. The

rationale of the present study is therefore to evaluate the short- and midterm clinical and angiographic outcomes of SES implantation in a consecutive series of patients treated during the acute phase of AMI.

Methods

Patient Population

Since April 16, 2002, SES implantation (Cypher; Johnson & Johnson, Cordis Europa NV, Roden, the Netherlands) has been instituted as the default strategy for all percutaneous coronary interventions performed at our institution as part of the Rapamycin-Eluting Stent Evaluated At Rotterdam Cardiology Hospital (RESEARCH) registry, which has been described elsewhere.⁵ All clinical situations and lesion morphologies were considered eligible. After 6 months of enrollment, 96 consecutive patients within 12 hours of an episode of AMI underwent mechanical reperfusion of the infarct-related artery

Received June 30, 2003; revision received September 2, 2003; accepted September 2, 2003.

From the Department of Interventional Cardiology, Thoraxcenter, Erasmus Medical Center, Rotterdam, the Netherlands.

Correspondence to Prof. Patrick W. Serruys, MD, PhD, Thoraxcenter, Bd-406, Dr. Molewaterplein 40,3015-GD Rotterdam, The Netherlands. E-mail p.w.j.c.serruys@erasmusmc.nl

© 2003 American Heart Association, Inc.

Circulation is available at <http://www.circulationaha.org>

DOI: 10.1161/01.CIR.0000096053.87580.CD

with SES implantation; these patients comprise the present study population.

Procedure

Except for SES utilization, all procedures were performed according to standard techniques, and the final interventional strategy was left to the discretion of the operator. Weight-adjusted heparin was administered to achieve an activated clotting time of >300 seconds, or 200 to 250 seconds when platelet glycoprotein IIb/IIIa inhibitor was used. Postprocedural antiplatelet regimen consisted of lifelong aspirin use and 75 mg clopidogrel per day for 3 months. Prolonged clopidogrel prescription (6 months) was recommended for patients with at least one of the following characteristics: multiple SES (>3 stents), total stent length >36 mm, bifurcations, or in-stent restenosis. The local ethics committee approved the study protocol, and informed consent was obtained from all patients.

Definitions and Follow-Up

Patients were evaluated for the occurrence of death, reinfarction (clinical symptoms or new electrocardiographic changes, associated with re-elevation of the creatine kinase and creatine kinase MB levels of >1.5 times the previous value if within 48 hours, >3 times the upper normal limit if after 48 hours),² and target lesion revascularization (surgical or percutaneous reintervention motivated by a significant stenosis located within the stent or in the 5-mm segments proximal or distal to the stent). Information regarding repeat interventions was prospectively collected in the local database. Survival status was assessed by written inquiries to the Civil Registry. Questionnaires to assess clinical status were sent to all living patients. The patient, referring physician, and peripheral hospitals were directly approached whenever necessary for additional information.

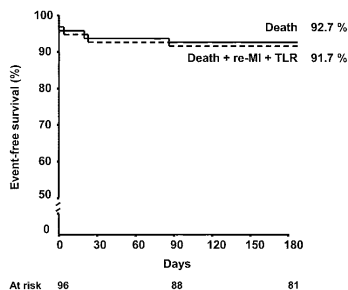
To evaluate the incidence of restenosis after SES implantation for AMI, angiographic follow-up was scheduled at 6 months for all living patients. Binary restenosis was defined as a stenosis diameter >50% within the stent or in the 5-mm segments proximal or distal to the stent. Late loss was defined as the difference between the minimal luminal diameter immediately after the procedure and at follow-up.

Statistical Analysis

Continuous variables are expressed as mean \pm SD. Discrete variables are presented as count and percentages. Event-free survival curves were estimated according to the Kaplan-Meier method. Patients lost to follow-up were considered at risk until the date of last contact, at which point they were censored.

Results

At baseline, mean age was 57 ± 12 years. Twelve patients (12.5%) had diabetes mellitus, 10 (10.4%) had had a previous myocardial infarction, and 45 (46.9%) presented multivessel disease. Six patients (6.2%) had prior coronary angioplasty, and 1 (1%) had prior coronary bypass surgery. Mean creatine kinase level was 2685 ± 2869 IU/L. Average time from the onset of symptoms to the beginning of the procedure was 3.6 ± 2.9 hours. Primary angioplasty was performed in 89 patients (92.7%) and rescue angioplasty after failed thrombolysis in the remaining 7 (7.3%). Cardiogenic shock was diagnosed in 12 patients (12.5%). Periprocedural glycoprotein IIb/IIIa inhibitor (abciximab) was used in 45 patients (46.9%). Infarct location was anterior in 41 cases (42.7%). Overall, 104 culprit lesions were identified (in 8 patients, we found 2 different lesions anatomically and clinically related to the development of the AMI). The lesions were located in the left main in 2 cases (1.9%), the left anterior descending in 51 (49.0%), the left circumflex in 10 (9.6%), and the right



Kaplan-Meier curves for survival, and survival free from myocardial infarction (MI) and target lesion revascularization (TLR). The almost complete overlap of the curves, motivated by the very low incidence of recurrent myocardial infarction and reinterventions, is evident.

coronary in 41 (39.4%). Before the procedure, TIMI flow 0 to 1 was present in 60.6% of the cases. Postprocedural TIMI-3 flow was achieved in 93.3%. Clopidogrel was prescribed for 3 months in 54% of patients and for 6 months in the remaining cases.

Complete follow-up was available for 99% of the patients at 218 ± 75 days. A total of 6 deaths occurred during the index hospitalization (6.2%). In 1 case, death occurred as a result of brain death in a patient with prolonged out-of-hospital resuscitation. The other 5 cases were all admitted in cardiogenic shock; 3 of them died the same day of the procedure as a result of progressive hemodynamic deterioration. The other 2 patients died of overwhelming sepsis at days 23 and 86 after a prolonged, stormy course. One additional death (1.1%) resulting from heart failure occurred during follow-up, shortly after hospital discharge, in a 77-year-old patient with 3-vessel disease, who was admitted with a large inferoposterior myocardial infarction and cardiogenic shock. In none of these cases, death occurred as an unexpected, sudden episode that could be attributable to stent thrombosis. Target lesion reintervention was necessary in 1 patient (1.1%) the same day as the procedure as a result of distal dissection, acute vessel occlusion, and reinfarction. There were no further cases of reinfarction or repeat intervention after discharge (Figure). Also, no early or late stent thromboses were documented.

Six-month angiographic follow-up was obtained in 62 patients (70%). The angiographic outcomes are shown in the Table. Late loss was -0.04 ± 0.25 mm, and there were no cases of binary restenosis.

Discussion

The present study is the first report on SES implantation for patients with ST-elevation AMI. The main finding is that, in these patients, SES implantation appears highly effective in preventing neointimal proliferation and restenosis, with results similar to those observed in a randomized trial for relatively simple lesions.³

Primary percutaneous coronary intervention has been demonstrated to be more effective than thrombolytic therapy for the treatment of AMI.⁶ However, although consistently re-

Quantitative Coronary Analysis in Patients With AMI Treated With Sirolimus-Eluting Stents

	Before Procedure	After Procedure	Follow-Up*
Reference diameter, mm	2.73±0.59	2.80±0.47	3.04±0.49
Minimum lumen diameter, mm	0.34±0.50	2.54±1.31	2.59±0.42
Diameter stenosis, %	86±21	14±12	15±11
Lesion length, mm	16.90±9.93
Late loss, mm	-0.04±0.25
Binary restenosis, %	0

*Values related to 62 patients with 6-month angiographic follow-up.

duced by stent utilization, recurrent ischemia, restenosis, and reocclusion of the infarct-related artery occur in sizable proportions, increasing clinical events and healthcare costs. In the Stent PAMI (Stent Primary Angioplasty for Myocardial Infarction) trial, 6-month restenosis and target vessel revascularization rates were 20.3% and 7.7%, respectively.² In the CADILLAC (Controlled Abciximab and Device Investigation to Lower Late Angioplasty Complications) trial, the corresponding values were 22.2% and 8.9%, and reocclusion of the infarct-related artery 5.7%.¹ In this context, the absence of restenosis and reinterventions by SES as found in our study could further improve clinical outcomes, although this hypothesis should be tested in dedicated randomized trials.

Previous preclinical laboratory data suggested that sirolimus could decrease endothelial function in vitro,⁷ enhance agonist-induced platelet aggregation,⁸ and delay vascular healing.⁹ Altogether, these features can potentially increase the risk of thrombotic complications and adversely affect the outcome after SES implantation, especially in very susceptible patients such as those treated during the acute phase of myocardial infarction. However, the clinical significance of these preliminary findings remains elusive. Indeed, we recently demonstrated the safety of SES for patients with acute coronary syndromes, although AMI at presentation was still associated with an increased risk of adverse events at follow-up.⁵ The present study, with the very low event rate and the absence of episodes of acute and subacute thrombosis, confirms the safety of SES utilization, specifically in patients with AMI.

In this prospective, single-center registry of SES implantation in AMI, all the limitations inherent to this particular study design apply, and the patient number was relatively small. Notably, however, given the unrestricted inclusion criteria, this cohort of patients accurately reflects the daily practice in the "real world" of interventional cardiology, and therefore the results are extended to virtually all patients with AMI as a result of occlusion of native coronary vessels.

Conclusions

Routine SES implantation during mechanical reperfusion of AMI is safe and associated with no evidence of late luminal loss and restenosis at 6 months. Larger studies are necessary to confirm these findings and to evaluate the impact of SES implantation on clinical events for patients with AMI.

Acknowledgments

This study was supported by health care funds allotted by Erasmus Medical Center (Erasmus University), Rotterdam, the Netherlands, and by an institutional research grant from Cordis Corporation, a Johnson & Johnson Company, Miami Lakes, Fla.

References

1. Stone GW, Grines CL, Cox DA, et al. Comparison of angioplasty with stenting, with or without abciximab, in acute myocardial infarction. *N Engl J Med.* 2002;346:957-966.
2. Grines CL, Cox DA, Stone GW, et al. Coronary angioplasty with or without stent implantation for acute myocardial infarction. Stent Primary Angioplasty in Myocardial Infarction Study Group. *N Engl J Med.* 1999; 341:1949-1956.
3. Morice MC, Serruys PW, Sousa JE, et al. A randomized comparison of a sirolimus-eluting stent with a standard stent for coronary revascularization. *N Engl J Med.* 2002;346:1773-1780.
4. Degertekin M, Serruys PW, Foley DP, et al. Persistent inhibition of neointimal hyperplasia after sirolimus-eluting stent implantation: long-term (up to 2 years) clinical, angiographic, and intravascular ultrasound follow-up. *Circulation.* 2002;106:1610-1613.
5. Lemos PA, Lee C, Degertekin M, et al. Early outcome after sirolimus-eluting stent implantation in patients with acute coronary syndromes. Insights from the Rapamycin-Eluting Stent Evaluated At Rotterdam Cardiology Hospital (RESEARCH) registry. *J Am Coll Cardiol.* 2003;41: 2093-2099.
6. Grines CL, Serruys P, O'Neill WW. Fibrinolytic therapy. Is it a treatment of the past? *Circulation.* 2003;107:2358-2342.
7. Jeanmart H, Malo O, Carrier M, et al. Comparative study of cyclosporine and tacrolimus vs newer immunosuppressants mycophenolate mofetil and rapamycin on coronary endothelial function. *J Heart Lung Transplant.* 2002;21:990-998.
8. Babinska A, Markell MS, Salifu MO, et al. Enhancement of human platelet aggregation and secretion induced by rapamycin. *Nephrol Dial Transplant.* 1998;13:3153-3159.
9. Virmani R, Farb A, Kolodgie FD. Histopathologic alterations after endovascular radiation and antiproliferative stents: similarities and differences. *Herz.* 2002;27:1-6.

PART 3

SIROLIMUS-ELUTING STENT IMPLANTATION IN PATIENTS WITH ACUTE MYOCARDIAL INFARCTION

CHAPTER 10

Short- and Long-Term Clinical Benefit of Sirolimus-Eluting Stents Compared to Conventional Bare Stents for Patients With Acute Myocardial Infarction

Authors: Pedro A. Lemos, Francesco Saia, Sjoerd H. Hofma, Joost Daemen, Andrew T. Ong, Chourmouzos A. Arampatzis, Angela Hoye, Eugene McFadden, Georgios Sianos, Pieter C. Smits, Willem J. van der Giessen, Pim de Feyter, Ron T. van Domburg, Patrick W. Serruys.

Circulation 2003;108:1927-1929

EXPRESS PUBLICATION

Short- and Long-Term Clinical Benefit of Sirolimus-Eluting Stents Compared to Conventional Bare Stents for Patients With Acute Myocardial Infarction

Pedro A. Lemos, MD, Francesco Saia, MD, Sjoerd H. Hofma, MD, Joost Daemen, Andrew T. L. Ong, MBBS FRACP, Chourmouzos A. Arampatzis, MD, Angela Hoye, MBChB, MRCP, Eugene McFadden, MBChB, FRCPI, FACC, Georgios Sianos, MD, PhD, Pieter C. Smits, MD, PhD, Willem J. van der Giessen, MD, PhD, Pim de Feyter, MD, PhD, FACC, Ron T. van Domburg, PhD, Patrick W. Serruys, MD, PhD, FACC

Rotterdam, The Netherlands

OBJECTIVES	This study investigated the clinical outcomes of patients with ST-segment elevation myocardial infarction (MI) treated with sirolimus-eluting stents (SESs) or with conventional bare stents.
BACKGROUND	The clinical impact of SES implantation for patients with ST-segment elevation MI is currently unknown.
METHODS	Primary angioplasty was performed with SESs in 186 consecutive patients with acute MI who were compared with 183 patients treated with bare stents. The incidence of death, reinfarction, and repeat revascularization was assessed at 30 and 300 days.
RESULTS	Postprocedure vessel patency, enzymatic release, and the incidence of short-term adverse events were similar in both the sirolimus and the bare stents (30-day rate of death, reinfarction, or repeat revascularization: 7.5% vs. 10.4%, respectively; $p = 0.4$). Stent thrombosis was not diagnosed in any patient in the sirolimus group and occurred in 1.6% of patients treated with bare stents ($p = 0.1$). At 300 days, treatment with SESs significantly reduced the incidence of combined adverse events (9.4% vs. 17%; hazard ratio [HR] 0.52 [95% confidence interval (CI) 0.30 to 0.92]; $p = 0.02$), mainly due to a marked reduction in the risk of repeat intervention (1.1% vs. 8.2%; HR 0.21 [95% CI 0.06 to 0.74]; $p = 0.01$).
CONCLUSIONS	Compared to conventional bare stents, the SESs were not associated with an increased risk of stent thrombosis and were effective in reducing the incidence of adverse events at 300 days in unselected patients with ST-segment elevation acute MI referred for primary angioplasty. (J Am Coll Cardiol 2004;43:704–8) © 2004 by the American College of Cardiology Foundation

Routine stent implantation has been advocated for patients with acute myocardial infarction (MI) referred for primary angioplasty, with superior results compared to balloon dilation (1–3). However, the late clinical efficacy is still hampered by the occurrence of in-stent restenosis and the need for repeat intervention.

Sirolimus-eluting stents (SESs) have proven to be effective in reducing late restenosis compared to conventional stenting in elective patients (4–6). We have recently shown in a relatively small consecutive series of cases that SES implantation in patients with acute MI was safe and associated with an extremely low (zero) incidence of angiographic restenosis at six months (7). However, the clinical benefit of SESs in comparison to conventional stent implantation remains currently unknown. Therefore, we evaluated the long-term clinical outcomes of a large series of

patients with acute MI treated with primary angioplasty utilizing either SESs or conventional metal stents.

METHODS

Since April 2002, SES implantation (Cypher, Johnson & Johnson-Cordis unit, Cordis Europa NV, Roden, The Netherlands) has been utilized as the strategy of choice for patients treated with percutaneous intervention in our institution (8). Up until January 2003, a total of 186 consecutive patients with ST-segment elevation acute MI have been treated with primary angioplasty utilizing exclusively SESs and were included in the present report. The first 89 patients of the present series were included in an angiographic substudy, of which the results have been reported previously (7). A control group for comparison was composed of 183 consecutive patients with ST-segment elevation acute MI treated with conventional bare stents in the period immediately before the introduction of SESs. The following bare metal stents were used: BX Sonic or BX Velocity in 53% (Cordis, Johnson & Johnson, Warren, New Jersey); Multi-Link Penta in 22% (Guidant Corp., Santa

From the Erasmus Medical Center, Thoraxcenter, Rotterdam, Netherlands. Supported by the Erasmus Medical Center, Rotterdam, The Netherlands, and by an unrestricted institutional grant from Cordis, a Johnson & Johnson Company, Miami Lakes, Florida.

Manuscript received November 4, 2003; revised manuscript received November 20, 2003, accepted November 24, 2003.

Abbreviations and Acronyms

CI	= confidence interval
CK	= creatine kinase
HR	= hazard ratio
MI	= myocardial infarction
SES	= sirolimus-eluting stent
TIMI	= Thrombolysis In Myocardial Infarction

Clara, California); Multi-Link Tetra in 6% (Guidant Corp.); R-Stent in 6% (Orbus Medical Technologies, Fort Lauderdale, Florida), and other stents in 12%. In both study phases, all patients were enrolled regardless of the clinical or anatomical presentation, including patients admitted with cardiogenic shock (defined as persistent systolic blood pressure <90 mm Hg, or the need of vasopressors or intra-aortic balloon pumping required to maintain blood pressure >90 mm Hg with evidence of end-organ failure and elevated left ventricular filling pressures). Therefore, the total study population comprised all 369 consecutive patients with ST-segment elevation acute MI undergoing primary angioplasty with either bare stents or SESs in the two study phases, respectively. Patients with angioplasty after failed thrombolytic therapy were excluded from the present analysis. This study protocol was approved by the local ethics committee, and written informed consent was given by every patient.

The final interventional strategy, as well as the utilization of periprocedural glycoprotein IIb/IIIa inhibitors and anti-thrombotic medications, was entirely left to the discretion of the operator. Baseline and postprocedure anterograde flow were evaluated off-line according to the Thrombolysis In Myocardial Infarction (TIMI) criteria (9) by cardiologists blinded to both the stent group and to the clinical outcomes. Clopidogrel was recommended for at least one month in the control group. In the SES group, clopidogrel was prescribed for three months, unless one of the following was present (in which case clopidogrel was maintained for at least six months): multiple SES implantation (>3 stents), total stented length >36 mm, bifurcation stenting, and in-stent restenosis.

Patients were prospectively followed for the occurrence of major adverse cardiac events: 1) all-cause death, 2) nonfatal MI, or 3) target vessel revascularization. Reinfarction was diagnosed by recurrent symptoms and/or new electrocardiographic changes in association with re-elevation of the creatine kinase (CK) and CK-MB levels of >1.5 times the previous value, if within 48 h, or >3 times the upper normal limit, if after 48 h from the index infarction (1,7). Target vessel revascularization was defined as a repeat intervention (surgical or percutaneous) driven by any lesion located in the same epicardial vessel treated at the index procedure. Thrombotic stent occlusion was angiographically documented as a complete occlusion (TIMI flow grade 0 or 1) or a flow-limiting thrombus (TIMI flow grade 1 or 2) of a previously successfully treated artery. Routine angiographic

follow-up was obtained only for patients treated with SESs enrolled during the first six months; results of this subanalysis have been previously reported (7).

Continuous variables were presented as mean \pm standard deviation, and were compared using the Student unpaired *t* test. Categorical variables were presented as counts and percentages and compared with the Fisher exact test. Survival free of adverse events was estimated using the Kaplan-Meier method and differences between curves were evaluated by the log-rank test. Cox proportional hazards survival models were used to assess risk reduction. Multivariate analyses were performed to identify independent predictors of long-term major adverse cardiac events. Baseline and procedural characteristics associated with the incidence of adverse events at univariate analysis (*p* value for selection ≤ 0.2) were tested for their multivariate predictive value (tested variables: SES utilization, diabetes, cardiogenic shock, multivessel disease, culprit vessel, pre-procedure TIMI flow, postprocedure TIMI flow, current smoking). The final model was built by backward stepwise variable selection with an entry and exit criteria set at the *p* = 0.05 and *p* = 0.1 levels, respectively.

RESULTS

Baseline characteristics were similar between both study groups, except by an older age and a lower incidence of previous MI in the sirolimus group (Table 1). Procedural characteristics differed between both groups in terms of the utilization of glycoprotein IIb/IIIa inhibitors (sirolimus: 37% vs. bare stents: 56%; *p* < 0.01) and the number of stents implanted (sirolimus: 1.9 ± 1.2 vs. bare stents: 1.7 ± 1.0 ; *p* = 0.03). As defined by the study protocol, the duration of clopidogrel prescription was longer for patients with sirolimus stents (Table 1).

No significant differences existed in the 30-day outcomes between patients treated with sirolimus or bare stents (Table 2). Stent thrombosis was diagnosed in three patients (1.6%) treated with bare stents and was not detected in the SES group (*p* = 0.1) (Table 2).

At 300 days, no differences were noted between both study groups in the incidence of death and death or reinfarction (Table 2). However, the incidence of 300-day major adverse events was significantly lower in the sirolimus stent group compared to the bare stent group (9.4% vs. 17%, respectively; hazard ratio [HR] 0.52 [95% confidence interval (CI) 0.30 to 0.92]; *p* = 0.02) (Table 2, Fig. 1), mainly due to a marked reduction in the risk of repeat intervention (1.1% vs. 8.2%, respectively; HR 0.21 [95% CI 0.06 to 0.74]; *p* = 0.01). A multivariate analysis was performed to adjust for baseline and procedural imbalances between the study groups (Table 3). Sirolimus-eluting stent utilization was identified as an independent predictor of 300-day death, reinfarction, or repeat revascularization (HR 0.53 [95% CI 0.29 to 0.95]; *p* = 0.03).

Table 1. Baseline and Procedural Characteristics of Patients Treated With Bare Stents or SES Implantation

	Bare Stents (n = 183)	SES (n = 186)	p Value
Male (%)	79	75	0.4
Age, yrs ± SD	57 ± 12	60 ± 12	0.04
Diabetes (%)	12	11	0.9
Current smoking (%)	47	46	0.8
Previous myocardial infarction (%)	24	14	0.03
Previous angioplasty (%)	9	7	0.4
Previous bypass surgery (%)	3	2	0.3
Coronary disease			0.3
Single-vessel (%)	48	55	
Double-vessel (%)	29	27	
Triple-vessel (%)	24	18	
Cardiogenic shock (%)	10	13	0.3
Time from symptom onset to angioplasty, h ± SD	3.0 ± 2.7	3.2 ± 1.9	0.6
Infarct-related vessel			0.3
Right coronary artery (%)	30	37	
Left anterior descending (%)	57	53	
Left circumflex artery (%)	10	8	
Left main coronary artery (%)	1	2	
Bypass graft (%)	2	—	
TIMI flow baseline			0.7
Grade 0/I (%)	73	73	
Grade II (%)	15	17	
Grade III (%)	13	10	
TIMI flow after angioplasty			0.5
Grade 0/I (%)	4	2	
Grade II (%)	17	15	
Grade III (%)	79	83	
Number of stents ± SD	1.7 ± 1.0	1.9 ± 1.2	0.03
Glycoprotein IIb/IIIa inhibitor (%)	56	37	<0.01
Clopidogrel prescription, months ± SD	2.1 ± 1.5	3.7 ± 2.1	<0.01
Peak CK, IU/l ± SD*	3,957 ± 5,135	3,126 ± 3,126	0.1
Peak CK-MB, IU/l ± SD†	319 ± 230	296 ± 255	0.5

*Upper limit of normal 199 IU/l. †Upper limit of normal 23 IU/l.
CK = creatine kinase; SD = standard deviation; SES = sirolimus-eluting stents; TIMI = Thrombolysis In Myocardial Infarction.

DISCUSSION

The main finding of the present study was that SES implantation was effective in reducing the incidence of adverse events at 300 days in unselected patients with ST-segment elevation acute MI, compared to conventional

bare stenting. Furthermore, the risk of subacute thrombosis within the first 30 days did not appear higher compared with bare metal stents. Sirolimus-eluting stents were asso-

Table 2. Kaplan-Meier Estimates of Adverse Events at 30 Days and at 300 Days

	Bare Stents (n = 183)	SES (n = 186)	p Value
30-Day outcomes			
Death (%)	5.5	5.9	1.0
Death or nonfatal reinfarction (%)	7.1	6.5	0.8
Target vessel revascularization (%)	4.4	1.1	0.1
Any event (%)	10.4	7.5	0.4
Stent thrombosis (%)*	1.6	0	0.1
300-Day outcomes			
Death (%)	8.2	8.3	0.8
Death or nonfatal reinfarction (%)	10.4	8.8	0.5
Target vessel revascularization (%)	8.2	1.1	<0.01
Any event (%)	17.0	9.4	0.02

*Angiographically documented stent thrombosis.
SES = sirolimus-eluting stents.

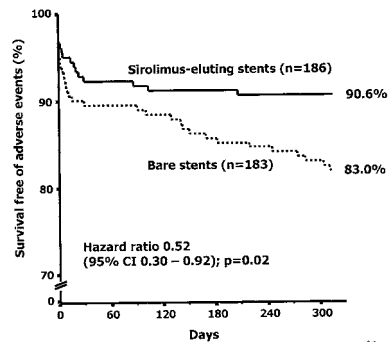


Figure 1. Survival free of reinfarction or target vessel revascularization in the sirolimus-eluting stent and conventional stent groups. CI = confidence interval.

Table 3. Multivariate Predictors of 300-Day Major Adverse Cardiac Events

	Hazard Ratio	95% Confidence Interval	p Value
SES utilization	0.53	0.29–0.95	0.03
Cardiogenic shock	3.31	1.72–6.34	<0.01
Culprit vessel left main coronary	6.05	1.60–22.87	<0.01
Culprit vessel left anterior descending	2.02	1.10–3.71	0.02
Postprocedure TIMI flow grade			<0.01
Grade 0/I (reference)	1.00	—	
Grade II	0.29	0.11–0.76	
Grade III	0.17	0.07–0.40	
Current smoking	0.57	0.31–1.02	0.06

SES = sirolimus-eluting stents; TIMI = Thrombolysis In Myocardial Infarction.

ciated with a relative reduction of 48% in the risk of death, reinfarction, or repeat intervention and a relative reduction of 79% in the risk of repeat intervention at 300 days.

In our series, reperfusion treatment with SESs was associated with similar rates of vessel patency, enzymatic release, and 30-day complications compared to bare stents. The death rate and the incidence of death or reinfarction were similar in both study groups, but somewhat higher than those reported in randomized trials with selected patients (1,2). These findings most probably reflect the unrestricted inclusion criteria of our series (10), which frequently enrolled patients not included in randomized studies, as, for instance, cardiogenic shock, multivessel disease, and unprotected left main lesions. Importantly, stent thrombosis has not been identified in any patient treated with sirolimus stents and occurred in three controls (1.6%), with no statistical difference between the groups. Although the incidence of stent thrombosis in the bare stent group was at a somewhat higher range, our results in this group were not discrepant from historical series with conventional stents (1,2,11–13).

Coronary stenting for the treatment of acute MI has been limited by the need of late repeat intervention, which has been reported to occur in approximately 9% of cases at six months, ranging from 3.6% to 22.7% (1–3). The incidence of repeat intervention after conventional stenting in our series (8.2%) was in line with these previous figures. Conversely, patients treated with SES implantation clearly had a reduced risk of reintervention at 10 months. Of note, between 30 days and 10 months, no additional patient was referred for repeat revascularization, which is consistent with the lack of angiographic restenosis after sirolimus stent implantation, as previously shown in a subset of patients from the present population (7).

The peri- and postprocedural antiplatelet therapeutic scheme differed between patients treated with either bare or sirolimus stents in our series. Patients in the sirolimus group received fewer glycoprotein IIb/IIIa inhibitors but had a longer clopidogrel prescription time. However, none of these characteristics were identified as independent predic-

tors influencing the outcomes of patients. The impact of clopidogrel and glycoprotein IIb/IIIa inhibitors on the long-term clinical outcomes of patients with ST-segment elevation acute MI remains to be established (2,14,15).

Conclusions. Sirolimus-eluting stent implantation for unselected patients with ST-segment elevation acute MI was associated with similar procedural and 30-day outcomes compared to bare stents, but markedly reduced the risk of major adverse events and repeat intervention at 10 months. By providing effective mechanical reperfusion with similar results to the current therapeutic standard, and decreasing the incidence of late complications, SESs appeared as an attractive approach for patients admitted with acute MI. The promising results of the present study warrant further confirmation in the context of a randomized trial.

Reprint requests and correspondence: Dr. Patrick W. Serruys, Thoraxcenter, Bd–406, Dr. Molewaterplein 40, 3015-GD Rotterdam, The Netherlands. E-mail: p.w.j.c.serruys@erasmusmc.nl.

REFERENCES

- Grines CL, Cox DA, Stone GW, et al. Stent Primary Angioplasty in Myocardial Infarction Study Group. Coronary angioplasty with or without stent implantation for acute myocardial infarction. *N Engl J Med* 1999;341:1949–56.
- Stone GW, Grines CL, Cox DA, et al. Comparison of angioplasty with stenting, with or without abiximab, in acute myocardial infarction. *N Engl J Med* 2002;346:957–66.
- Zhu MM, Feit A, Chadow H, Alam M, Kwan T, Clark LT. Primary stent implantation compared with primary balloon angioplasty for acute myocardial infarction: a meta-analysis of randomized clinical trials. *Am J Cardiol* 2001;88:297–301.
- Moses JW, Leon MB, Popma JJ, et al. Sirolimus-eluting stents versus standard stents in patients with stenosis in a native coronary artery. *N Engl J Med* 2003;349:1315–23.
- Morice MC, Serruys PW, Sousa JE, et al. A randomized comparison of a sirolimus-eluting stent with a standard stent for coronary revascularization. *N Engl J Med* 2002;346:1773–80.
- Schofer J, Schluter M, Gershlick AH, et al. Sirolimus-eluting stents for treatment of patients with long atherosclerotic lesions in small coronary arteries: double-blind, randomised controlled trial (E-SIRIUS). *Lancet* 2003;362:1093–9.
- Saia F, Lemos PA, Lee CH, et al. Sirolimus-eluting stent implantation in ST-elevation acute myocardial infarction: a clinical and angiographic study. *Circulation* 2003;108:1927–9.
- Lemos PA, Lee C, Degertekin M, et al. Early outcome after sirolimus-eluting stent implantation in patients with acute coronary syndromes. Insights from the Rapamycin-Eluting Stent Evaluated At Rotterdam Cardiology Hospital (RESEARCH) registry. *J Am Coll Cardiol* 2003;41:2093–9.
- TIMI Study Group. The Thrombolysis In Myocardial Infarction (TIMI) trial. Phase I findings. *N Engl J Med* 1985;312:932–6.
- Zahn R, Schiele R, Schneider S, et al. Decreasing hospital mortality between 1994 and 1998 in patients with acute myocardial infarction treated with primary angioplasty but not in patients treated with intravenous thrombolysis. Results from the pooled data of the Maximal Individual Therapy in Acute Myocardial Infarction (MITRA) Registry and the Myocardial Infarction Registry (MIR). *J Am Coll Cardiol* 2000;36:2064–71.
- Cutlip DE, Baim DS, Ho KK, et al. Stent thrombosis in the modern era: a pooled analysis of multicenter coronary stent clinical trials. *Circulation* 2001;103:1967–71.

Short- and Long-Term Clinical Benefit of Sirolimus-Eluting Stents

12. Moussa I, Oetgen M, Roubin G, et al. Effectiveness of clopidogrel and aspirin versus ticlopidine and aspirin in preventing stent thrombosis after coronary stent implantation. *Circulation* 1999;99:2364–6.
13. Serruys PW, Unger F, Sousa JE, et al. Comparison of coronary artery bypass surgery and stenting for the treatment of multivessel disease. *N Engl J Med* 2001;344:1117–24.
14. Eisenberg MJ, Jamal S. Glycoprotein IIb/IIIa inhibition in the setting of acute ST-segment elevation myocardial infarction. *J Am Coll Cardiol* 2003;42:1–6.
15. Tcheng JE, Kandzari DE, Grines CL, et al. Benefits and risks of abciximab use in primary angioplasty for acute myocardial infarction: the Controlled Abciximab and Device Investigation to Lower Late Angioplasty Complications (CADILLAC) trial. *Circulation* 2003; 108:1316–23.



CHAPTER 11

Summary and Conclusions

SUMMARY AND CONCLUSIONS

Drug-eluting stents (DES) represent a new breakthrough biotechnology which combines coronary stent implantation and local drug-delivery. Sirolimus and paclitaxel-eluting stents have been shown in randomised trials to prevent local neointimal formation and to dramatically reduce restenosis as compared with conventional bare metal stents.

However, thus far the implementation of DES in clinical practice has been limited by cost issues and to some reluctance in transferring the positive results of randomised trials to the real-world scenario without the support of scientific evidence of efficacy.

Therefore, to test whether broadening the indications for drug-eluting stent utilization in daily practice is safe and effective, we assessed the outcomes of sirolimus-eluting stent implantation in clinical conditions and in coronary lesions generally excluded from randomised trials.

DRUG-ELUTING STENTS TO TREAT IN-STENT RESTENOSIS

To date, in-stent restenosis (ISR) still represents the major limitation of percutaneous coronary intervention, even if the development of drug-eluting stents is giving rise to the reasonable hope that neointimal hyperplasia growth and luminal renarrowing following coronary stent implantation could be very efficiently prevented.

Treatment of ISR is frequently a challenging clinical problem, with recurrent restenosis being reported in up to 80% in the most complex cases. Vascular brachytherapy (VBT), by targeting the "biological" component of neointimal proliferation, is the only strategy proven to be effective in randomized trials. However, its utilization is limited by complex logistic requirements and the necessity of highly trained operators.

Sirolimus-eluting (SES) implantation for the treatment of in-stent restenosis was tested in two preliminary studies with a very limited number of patients. Therefore we evaluated the clinical and angiographic outcomes of 44 consecutive patients treated with routine SES implantation for in-stent restenosis in a broad range of morphological lesion patterns, as commonly seen in daily practice. We showed that routine sirolimus-eluting stent implantation was highly effective for focal in-stent restenosis and appeared to be a promising strategy for more complex patterns of restenosis. When compared to patients with similar clinical characteristics and lesion patterns treated with vascular brachytherapy, SES implantation appeared to be at least as effective at 9 months clinical follow-up.

We reported also the first experience of SES implantation to treat patients with recurrent in-stent restenosis following failed brachytherapy. We concluded that SES implantation in these patients is safe and clinically effective, although they clearly represent a peculiar subset of patients in which SES are less effective in preventing neointimal hyperplasia, for reasons that would require further investigations.

UNRESTRICTED UTILIZATION OF DRUG-ELUTING STENTS

The second part of this thesis is focused on the evaluation of the impact of SES on the outcomes of patients treated in the “real world” of interventional cardiology, as compared with a strategy using conventional bare stent implantation. Therefore, we adopted SES implantation as the default strategy to accomplish percutaneous coronary interventions at our institution, without any contraindication (with the exception of unavailability of properly sized devices). The outcome was compared with that of patients treated with bare metal stent implantation in the period immediately before SES commercialisation. We proved that unrestricted utilization of SES in the “real world” is safe, through a preliminary analysis of the incidence of mid-term thrombotic stent occlusion, and is effective in reducing the need of further revascularization and the incidence of major adverse cardiac events after 1 year.

To be routinely used, a new stent should be safe in all procedural conditions. Direct stenting, overlapping stents, post-dilatation, and others are fields that deserve specific investigation. In daily practice, post-deployment dilatation of the stent with oversized balloons on the basis of angiographic or intravascular ultrasound findings is quite common. Although not recommended, extreme over-dilatation with balloon >1mm larger than the stent nominal size might be required in selected cases to achieve a good procedural result. With available drug-eluting stents, appropriate drug delivery depends on the polymer integrity and on the proper spatial distribution of the stent struts. Post-dilatation of the stent could impair the effectiveness of SES in different ways: by enhancing tissue proliferation in response to greater vessel injury, by altering the mechanical properties of the stent, by disrupting the polymer coating, and by increasing the distance between the stent struts. Therefore, we assessed the outcomes of patients treated with SES implantation in which a post-dilatation with largely oversized balloons was performed, and showed that this strategy is safe and apparently does not compromise SES efficacy.

Finally, we described the clinical and morphological patterns of restenosis after sirolimus-eluting stent implantation, and we observed that edge restenosis is frequently associated with local trauma outside the stent, whilst in-stent restenosis occurs as a localized lesion, commonly associated with a discontinuity in the stent coverage or local conditions rather than intrinsic drug-resistance to sirolimus.

DRUG-ELUTING STENTS FOR ST-ELEVATION ACUTE MYOCARDIAL INFARCTION

Routine stent implantation has been advocated for patients with acute myocardial infarction referred for primary angioplasty, with superior results compared to balloon dilatation. In the third part of this thesis, results of the first experience of sirolimus-eluting stents implantation in patients with acute myocardial infarction are reported. In this subset, SES appeared safe and associated with an extremely low (zero) incidence of angiographic restenosis at 6 months. Moreover, this strategy achieved similar procedural and 30-days outcomes compared to bare stents, but markedly reduced the risk of major adverse events and repeat intervention at 10 months.

A GLIMPSE INTO THE FUTURE

As already pointed out, widespread utilization of drug-eluting stents in clinical practice has been limited by cost issues and, to a lesser extent, by the fact that available data referred to a limited number of patients, with selected low-risk clinical conditions and lesions. However, the body of evidence for a dramatic reduction of in-stent restenosis with drug-eluting stents is sharply increasing to include large number of patients with all clinical and anatomical conditions. Therefore, we might speculate that drug-eluting stents will slowly subside bare metal stents, being the initially higher costs of presumably ephemeral nature.

It appears now clear that complete abolition of in-stent restenosis, as hypothesized after publication of the RAVEL trial results, was merely a dream. Although strongly reduced and apparently presenting with a favourable focal pattern, in-stent restenosis following drug-eluting stent implantation will deserve some attention to select appropriate treatment and outcomes.

The drug-eluting stent era has just begun. A large number of new drugs and coatings are under investigations and will slowly appear in the market. As our understanding of the interaction between these drugs, the vessel wall and the patients will increase, we might be able to develop tailored stents for different clinical conditions and lesions (for example, with increased amount of the drug or prolonged release for patients at very high-risk for restenosis).

The complex balance between drug antiproliferative effect and vessel wall healing after the intervention, could be improved with new stent coatings, and some are already under development.

In the near future, the concept of stent drug elution might be further expanded. In fact, some manufacturers have developed new stents which can be loaded with different drugs, in variable amounts, which can be released with different kinetics, and with a differentially directed elution (toward the vessel wall or the blood stream). Primary angioplasty for acute myocardial infarction might well represent the ideal field of application of such a stent, with an antiproliferative drug directed toward the vessel wall to take care of restenosis, and a specific drug released downstream to improve microvascular reperfusion or to promote myocardial tissue repair.

Finally, biodegradable stents are under investigation. The possible combination between a biodegradable stent platform and a specific drug is very appealing. It might be routinely used, and it might also represent a tool to treat atherosclerotic lesions which are not obstructive but that are recognised by appropriate means (under development as well) to be "vulnerable", i.e. associated with increased risk to originate acute coronary events.

SAMENVATTING EN CONCLUSIES

Gecoate stents vertegenwoordigen een nieuwe baanbrekende biotechnologie die coronaire stent implantatie combineert met lokale geneesmiddeltherapie. Gerandomiseerde studies hebben bewezen dat sirolimus- en paclitaxel gecoate stents neointima formatie kunnen voorkomen en restenose drastisch kunnen verminderen in vergelijking tot de conventionele stents.

Tot nog toe werd het gebruik van gecoate stents in de hedendaagse praktijk beperkt door hogere kosten en door enige terughoudendheid in het overbrengen van de positieve resultaten van gerandomiseerde studies in een scenario dat dichterbij de dagelijkse praktijk ligt, zonder de steun van wetenschappelijke bewijzen en efficiëntie.

Om te testen of het verbreden van het indicatiegebied voor gecoate stents in de dagelijkse praktijk veilig en effectief is, beoordeelden wij de resultaten van het gebruik van sirolimus gecoate stent implantatie in klinische situaties die normaal geëxcludeerd zouden zijn in gerandomiseerde studies.

GECOATE STENTS TER BEHANDELING VAN IN-STENT RESTENOSE

Tot nu toe is in-stent restenose (ISR) nog steeds de grootste beperking van percutane coronaire interventies, ondanks het feit dat de ontwikkeling van gecoate stents reële hoop geeft dat neointima hyperplasie en vernauwing van het vaatlumen na coronaire stent implantatie zeer effectief tegengegaan zou kunnen worden.

Behandeling van ISR is regelmatig een uitdagend klinisch probleem, met terugkerende restenose percentages oplopend tot 80% in de meest complexe gevallen. Vasculaire brachytherapie (VBT), die de “biologische” component van neointima proliferatie tegengaat, is de enige strategie die in gerandomiseerde studies effectief is gebleken. Het gebruik hiervan wordt echter beperkt door de behoefte aan een complexe organisatie met betrekking tot formele goedkeuringen en hoog opgeleide operateurs.

Sirolimus gecoate stent implantatie voor de behandeling van in-stent restenose is onderzocht in twee voorafgaande studies met een zeer beperkt aantal patiënten. Daarom hebben wij het klinische en angiografische resultaat van 44 opeenvolgende patiënten die behandeld zijn met een routine sirolimus gecoate stent implantatie voor in-stent restenose beoordeeld in een breed gebied van laesiepatronen zoals frequent gezien in de dagelijkse praktijk. Wij konden aantonen dat routine sirolimus gecoate stent implantatie zeer effectief was in het behandelen van focale in-stent restenose en deze behandeling bleek een veelbelovende strategie voor complexe vormen van restenose. Wanneer vergeleken met patiënten met dezelfde klinische presentatie en laesies behandeld met brachytherapie, bleek sirolimus gecoate stent implantatie zeker zo effectief na 9 maanden van klinische follow-up.

Ook publiceerden wij de eerste ervaringen van behandeling van patiënten met terugkerende in-stent restenose na niet succesvolle brachytherapie behandeld met sirolimus gecoate stents.

Concluderend kunnen wij zeggen dat het gebruik van sirolimus gecoate stents in deze patiënten veilig en klinisch effectief is, ook al representeren zij een zeer specifieke groep van patiënten waarin het gebruik van de sirolimus gecoate stents minder effectief is in het tegengaan van neointima hyperplasie. Naar de oorzaak hiervan zal dan ook nog verder onderzoek verricht moeten worden.

ONBEPERKT GEBRUIK VAN GECOATE STENTS

Het tweede gedeelte van dit proefschrift richt zich op het beoordelen van het gebruik van sirolimus gecoate stents in een patiëntenpopulatie uit de dagelijkse praktijk van de interventiecardiologie vergeleken met het gebruik van conventionele stents. Om deze reden hebben we in onze instelling de sirolimus gecoate stent als standaard behandeling voor alle percutane coronaire interventies gebruikt, zonder enige contra-indicaties, met uitzondering van het in bepaalde gevallen niet beschikbaar zijn van stents in de juiste maat. De resultaten van dit beleid hebben we vergeleken met de resultaten van de behandeling van patiënten waarin conventionele stents gebruikt waren, in een periode vlak voor de introductie van de sirolimus gecoate stents. We hebben bewezen dat onbeperkt gebruik van de sirolimus gecoate stent in de dagelijkse praktijk veilig is, door een voorafgaande analyse van de incidentie van trombotische stent occlusie op middenlangetermijn, en dat de sirolimus gecoate stent effectief is in het terugbrengen van de behoefte aan latere revascularisatie en cardiale events 1 jaar na follow-up.

Om als routine behandeling gebruikt te kunnen worden, moet een nieuwe stent in alle klinische situaties veilig zijn. Direct stenten, overlappende stents, na-dilatatie en anderen, zijn gebieden waarop specifiek onderzoek verricht zal moeten worden. In de dagelijkse praktijk is dilatatie na ontplooiing van de stent met ballonnen met een diameter groter dan die van de stent op basis van angiografische of intravasculaire echore resultaten vrij gewoon geworden. Ondanks het niet aanbevolen worden hiervan kan extreme over-dilatatie met ballonnen groter dan 1mm boven de nominale grootte van de stent in specifieke gevallen noodzakelijk zijn om een goed behandelingsresultaat te krijgen. Met de beschikbaarheid over gecoate stents, hangt gepaste medicijn afgifte af van de zuiverheid van de polymeer en van de afstand waarop de stentdraden van elkaar liggen. Nadilatatie zou de effectiviteit van de sirolimus gecoate stents op verschillende manieren nadelig kunnen beïnvloeden: door weefselproliferatie te bevorderen als gevolg van grotere beschadigingen van de vaatwand, door de mechanische eigenschappen van de stent te beïnvloeden, door het beschadigen van de polymeer coating en door het vergroten van de afstand tussen de stentdraden. Daarom beoordeelden wij de resultaten van de behandeling van patiënten met sirolimus gecoate stents waarin nadilatatie met te grote ballonnen was gedaan en toonden aan dat deze behandelingsstrategie veilig is en de efficiëntie van de sirolimus gecoate stent niet nadelig beïnvloed.

Tot slot beschreven wij de klinische en morfologische vormen van restenose na sirolimus gecoate stent implantatie en zagen we dat randrestenose frequent geassocieerd is met trauma buiten de stent, daar waar in-stent restenose vooral voorkomt als een locale laesie en vaak geassocieerd is met een discontinuïteit in de bedekking door de stent of de plaatselijke vaatwandtoestand, eerder dan door ongevoeligheid voor sirolimus.

GECOATE STENTS VOOR ACUTE MYOCARD INFARCTEN MET ST-ELEVATIE

Het gebruik van stents in de behandeling van patiënten met een acuut myocard infarct verwezen voor primaire angioplastiek heeft inmiddels de voorkeur gekregen boven de ballon dilatatie vanwege de betere resultaten. In het derde gedeelte van dit proefschrift zijn de eerste resultaten beschreven van de behandeling van acute myocard infarct patiënten met sirolimus gecoate stents. In deze patiëntenpopulatie heeft de sirolimus gecoate stent bewezen veilig te zijn en een extreem lage (nul) incidentie van angiografische restenose te geven na 6 maanden van

follow-up. Hierboven gaf deze strategie dezelfde procedurele resultaten als de conventionele stentbehandeling na 30 dagen van follow-up maar met een duidelijk lager risico op negatieve gebeurtenissen en herinterventies na 10 maanden van follow-up.

EEN BLIK IN DE TOEKOMST

Zoals reeds besproken wordt het grootschalig gebruik van gecoate stents in de klinische praktijk beperkt door kostenkwesaties en in mindere mate door het feit dat de beschikbare data verwijst naar een beperkt aantal patiënten met een beperking betreft klinische risico's en laesies.

Maar, met een sterke toename van bewijs voor de drastische reductie van in-stent restenose met gecoate stents lijkt het mogelijk om een groter aantal patiënten te includeren zonder beperkingen met betrekking tot klinische en anatomische presentatie. Om deze reden mogen we speculeren dat gecoate stents langzaam de conventionele stents zullen vervangen ondanks de aanvankelijk hogere kosten van waarschijnlijk voorbijgaande aard.

Het lijkt nu duidelijk dat een "volledige" verdwijning van in-stent restenose, zoals geopperd na publicatie van de RAVEL studie resultaten enkel een droom was. Ondanks sterk verminderd en zich blijkbaar presenterend met een gunstig plaatselijk focus zal in-stent restenose na het gebruik van de gecoate stents verdere aandacht vergen om te kiezen voor een gepaste behandeling en resultaten.

Het tijdperk van de gecoate stent is pas begonnen. Er wordt onderzoek gedaan naar een groot aantal nieuwe geneesmiddelen en coatings (bijvoorbeeld, stents met een hogere medicijnload of verlengde afgifte hiervan voor patiënten met een hoger risico op restenose).

De complexe balans tussen medicijn geïnduceerde antiproliferatieve effecten en vaatwand genezing na behandeling zou kunnen worden verbeterd met nieuwe stent coatings en sommige zijn zeker in ontwikkeling.

In de nabije toekomst zal het idee van medicijnafgifte vanuit de stent verder uitgewerkt worden. Sommige producenten hebben zelfs al nieuwe stents ontwikkeld die verschillende soorten geneesmiddelen kunnen dragen, in verschillende dosis die kunnen worden afgegeven met andere kinetische eigenschappen en met een anders gereguleerde afgifte (naar de vaatwand of in de richting van de bloedstroom). Primaire angioplastiek voor acute myocard infarcten zou zich kunnen presenteren als het ideale gebied voor het gebruik van zulke stents, met een antiproliferatief geneesmiddel gericht tegen de vaatwand om restenose tegen te gaan en een meer specifiek middel met een afgifte in de richting van de bloedstroom om microvasculaire reperfusie te bevorderen of om genezing van het door een myocard infarct aangetast weefsel te bevorderen.

Tot slot wordt er onderzoek verricht naar bioresorbeerbare stents en de mogelijke combinatie van een bioresorbeerbare stent met een specifiek geneesmiddel lijkt zeer aantrekkelijk. Het zou als routinebehandeling gebruikt kunnen gaan worden en het zou ook een manier kunnen gaan vertegenwoordigen om atherosclerotische laesies te behandelen die niet obstructief zijn maar die erkend worden hiervoor "gevoelig" te zijn (ook in onderzoek), wat wil zeggen: laesies geassocieerd met een hoger risico coronaire events.

ACKNOWLEDGEMENTS

I have to admit that my adventure at the Thoraxcenter did not have a very good start. After sending the application form it took 6 months to have the first reply: another application form. After other 2-3 months without any feed-back, I decided to give a telephone call. Anja, Professor Serruys' secretary, after 2 minutes of conversation: "[...] Dr. Saia, are you really sure that you want to come here now? You can barely speak english!". Me: "...yes, mmh.. no, mmh...but.. mmh..I can speak english...mmh...enough..." and finally and bravely I was able to put a few words together to defend my position. First "flash" meeting with Prof. de Feyter, Paris, EuroPCR 2002. Running from a room to another. "When would you like to come?" "July, Professor". "Good. You have to talk to Patrick for the interview, but I think it's ok. Sorry, I have to hurry up for another session now. See you in Rotterdam". First meeting with Prof. Serruys: "Saia, Saia....., yes, in French there is a similar word that means dull!" (sic!). At that time, I could not even imagine the incredible amount of human and professional experience that my adventure at the Thoraxcenter was going to bring to me in the forthcoming future.

The first person that I have to thank is Pedro Lemos. Pedrinho, you believed in the possibility to write this thesis before I did believe it, and you convinced me that it was possible when it appeared too difficult. Thanks for sharing with me many nice dinners, talks about music and poems, Italy and Brasil, football and skying. And pasta, and oil, and families, and everything... Thanks for having taught to me so many things. And thanks for your friendship, that I am sure will go on. Knowing you and Francine was one of the best things that could have happened to me. Obrigado!

Akis Arampatzis, the big Greek. It took a few months to understand that this apparently very serious man was actually an incredible nice and friendly person. A great expert in food and wine, and a living guide on Rotterdam by night. The only fellow able to speak Dutch, and to scare people in the night just saying "Mag ik...?". Akis, thanks for the funny time that we have together, and for sharing with me important discussions about life...

Muzaffer Degertekin, Muza. Hard worker and fine scientist. But also a peerless talent in social life. Difficult to find in Rotterdam when he was not in Z building, my guide to "bella vita" in international meeting's venues.

I would need another thesis to explain how special was to work with each one of the other fellows. Angela Hoye. Angela, thanks for your help with your "barbarian" language (it's the only alibi that I have to suffer so much with english), and for your explanations about spag-bol. Evelyn Regar, fine interventional cardiologist and researcher, but charming and elegant lady as well. Thanks for explaining me how to become like James Bond, and to understand that italians are caotic but sometime also inventive and pleasant. Kengo Tanabe, I will always remember your politeness and...the sachè at the Japanese restaurant. Ronald Lee, we spent together only a few months, but enough to appreciate your Chinese courtesy. Thanks for leading me around in the Thoraxcenter and for introducing me to the other fellows when I arrived. And thanks to the "newcomers", Andrew Ong, Carlos van Mieghem, Jiro Aoki, Gaston Rodriguez, Marco Valgimigli, with whom I had the privilege to work only for a limited time, but enough to understand that they are going to constitute another nice group of fellows. Good luck for your time at the Thoraxcenter and for your life!

If the fellows are the "brothers", the people that were sharing with me the job, the experience, the social life, Prof. Serruys is the "father" of this family. Dear Professor, the words are really limited to express my heartfelt gratitude to you. Working with you was an unforgettable and

Acknowledgements

marvellous journey in the past and the future of interventional cardiology. You do not need many words to teach. Your experience comes out from every single action you do, your knowledge from the way you lead the research, your genius from every idea, suggestion, intuition, your uniqueness from the enthusiasm of a young fellow blended in a pioneer and artificer of interventional cardiology. In this light, your teachings are much more than a mere transmission of information, but rather hints to achieve deep understanding and keen discernment of things, and guidelines for a successful professional life. Grazie Professore, I will try to keep these things always with me.

The other promotor of this thesis is Prof. Pim de Feyter. Dear Professor Pim, I arrived in a moment in which you were focusing much of your interest and time in the coronary MSCT scan. Despite this, I could day by day appreciate your wiseness in the catheterization laboratory, your capacity for sound judgment of research works, your nice sense of humor, and your unique style and elegance in interpersonal relationships. Among other things, I will always remember when me and Pedro helped you preparing the Meeting Highlights for EuroPCR 2003. You acknowledged us in the main arena for that, and that was the best, and unexpected, reward for us.

If I had the chance to follow a research program at the Thoraxcenter, I have to thank also Prof. Branzi, the Director of the Institute of Cardiology of the University of Bologna, the institution from where I come from. He has always encouraged and supported with enthusiasm this kind of initiatives, and he asked to be periodically informed about my studies in Rotterdam. Dear Professor, thank you very much because during my staying in Rotterdam I always could feel your approval for the things I was doing, and the closeness of the Institute of Cardiology. And thank you very much for having accepted to be a member of the Doctoral Committee. I consider this a great honour for me. For the same reason I would like to thank Prof. Antonio Colombo and Prof. Felix Zijlstra, because their prestigious presence in the Plenary Doctoral Committee represents for me an exceptional privilege.

I have to thank also my colleagues from the Catheterization Laboratory at the Institute of Cardiology in Bologna. Dr. Antonio Marzocchi, the Head of the lab, who addressed me to Interventional Cardiology. I will always remember the day in which, in the elevator of the hospital, you asked me simply and plainly: "Would you like to become an Interventional Cardiologist and to work with us?". That was a major turnpoint in my life. He is sharing with us his special clinical experience and expertise in the field, and is often reminding us that the patient's health comes always first. Thanks also for the invaluable and spontaneous help in finding financial support for the printing of this thesis. Thanks to Drs. Cinzia Marrozzini, Paolo Ortolani, and Tullio Palmerini, who began teaching me how to perform catheterizations and PCIs a few years ago and are still providing me with tips and tricks to constantly improve, and to my colleague Matteo Aquilina. Their friendship is for me of profound value. And I wish also to thank Dr. Giancarlo Piovaccari, who is now leading the Cardiology Department in Rimini, for his precious teachings in the first period of my training.

A special acknowledgement is for Johannes Schaar. He led me in the "23rd floor" and in the "marvellous world" of the vulnerable plaque, giving me a different perspective of Interventional Cardiology. The "23rd floor" is the reign of engineers, physics, technicians, and selected clinicians, wisely and nicely directed by Prof. Ton van der Steen. Going to the "23rd floor" was always pleasant, both from a scientific point of view and for the nice company of Johannes and Frits Mastik. Dear Johannes, I have really appreciated working with you, and I hope there will

be other chances in the future. Thanks also for the dinners at your place, which I never had the chance to return, and for the kind help that you gave me when I went back to Italy.

Another special thanks is for Ron van Domburg. He has been always kind and helpful to me, and spontaneously offered me his generous help to complete this thesis. Together with his skills as a statistician, and his tolerance with a real beginner like myself, I could also appreciate his nice company in a few recreational moments.

It has been very nice to work and collaborate with all the seniors in the cath lab of the Thorax. Thanks to Pieter Smits and Wim van der Giessen who never lost the chance to give me valuable suggestions, to George Sianos for always encouraging me to be determinate and resolute, to Sjoerd Hofma for helping me understanding the Dutch people. And many thanks to Eugene McFadden, that despite his unpretentious, discreet and gentle character, is a very skilled operator in the catheterization laboratory, and an excellent clinical investigator. Eugene, thanks for the very enjoyable dinners we had together, in the search for good food and wines.

Many thanks also to Filippo Cademartiri and Nico Mollet, both very friendly and kind persons. Thanks for asking me to participate in a few studies with coronary MSCT scan, and for the enjoyable company when we had the chance to go out together. I will especially remember the night...outside the Talia club!

Paul Cummins and Arno Ruiter, research nurses, engines of research. Thanks both for your help. Paul, thanks also for your hints about Rotterdam life, and for the football games,but not for the pictures of me with my "ridiculous" green bathrobe after the match!

I would like to thank all the technicians of the cath lab, who where helpful so many times. With them I shared a long time collecting data in the lab, and I was very impressed by the high professionalism of each one of them in different fields. They were always very tolerant with my continuous questions, and we had many nice conversations. Emile, John, Gio, Anne Marie, Jurgen, Ben, thank you!

Thanks also to all the nurses, especially Marjo, Janine, Samantha, Elza and Marijke. I always appreciated your work, and your smiles were often very encouraging for me.

A special thank is for the secretaries. Anja, for being always so perfect and reliable, and very kind with me. Edith, for her sincere spiritual support. Titia, Mieke, Jolanda, and Marijke, always ready to help. Titia, your daily "buongiorno" was always very pleasant to me. Elles, thanks for being always so nice and gentle.

An important contribution to this thesis came from Joost Daemen. Dear Joost, I appreciated very much your work in the RESEARCH program. I wish you the best for your future, because I have rarely seen students so reliable, clever and cultured as you are. *Grazie mille*.

Only occasional but extremely interesting and profitable was for me the collaboration with Heleen van Beusekom and her staff, in the Experimental Cardiology department led by Prof. Dunkers. Dear Heleen, thanks a lot for having introduced me to this unexplored world. And thanks again to Wim van der Giessen, who represents the link between the cath lab and this department.

In the 5th floor, the headquarter of Thoraxcenter, I had the pleasure to meet Dr.J. Willem de Jong, who speaks italian and offered me his friendly help since the beginning, Annet Louw, that I will never thank enough for her priceless help in preparing all the documents for this thesis, Sarah Fransen, and Wil Barthelemy. Thanks everybody!

A special place in the Thoraxcenter is the office of Jan Tuin, where you can listen his excellent music while working. And you can assist to Jan's and Paula's "miracles" with pictures and film processing.

Acknowledgements

I consider a privilege having worked many days in Cardialysis. Many thanks to Marie-Angèle Morel, Gerrit-Anne van Es, Dick Goedhart, and Clemens Disco.

When I first arrived in Rotterdam, I felt very lonely. I was lucky to meet soon a lot of people who later on became my “new family”. David, Diana, Valentina, Marta, Beni, Carlos, Paula, Simone, Fabrizio, Amandine, Isa, Maria, Eva, Pasquale, Raimondo, Giannis, Luis, Juan Luis, Pepe, Natalia, Fran, Andrea, Laura, Vera, Wolfgang, Fady, Nicoline, Edgar, Rafa, Arturo, Tato, Kris, Ana, Joao, Martin, Serginho, Jan, Olatz, Manuela....they are too many to list, but I will always remember their smiles and the time together.

A very special thank is for my friend Elena Biagini. She arrived at the Thoraxcenter a few months after me. Elena, even if we did not spend much time together in the Netherlands, thanks for being always there when I needed a friend. And thanks to Vittoria and Eleni, your colleagues in the Echo department.

I cannot forget to thank my friends Armando e Anna, who visited me in Rotterdam and who were always giving me their support. And who did not forget me during this period. I missed you a lot, ...and the dinners at your place too!

And thanks also to Anna Chiara, Nevio and Simona. You probably do not know, but with keeping my mood happy you have been very important and helpful during these last months, while I was completing the preparation of the thesis.

At the end, I need to thank my family, because they are my real strength. Cari papà e mamma, Roberto, Maria e nonna Draghiza, sappiate che voi siete la mia principale fonte di energia. Non finirò mai di ringraziarvi per l'amore con cui mi avete educato, sostenuto, incoraggiato, affiancato, criticato, entusiasmato e...è difficile fermarsi. Vi voglio un mondo di bene. Grazie di tutto. E grazie agli zii e cugini che mi hanno chiamato e che sono venuti a trovarmi. Vi sento sempre molto vicino.

Barbara, per te le parole sono del tutto insufficienti. Sai che ti ho portato con me in ogni istante, e che non ce l'avrei mai fatta se tu mi avessi fatto sentire anche solo per un momento quanto stavi soffrendo la mia assenza. Tutto questo è per te, per i sorrisi che mi hai regalato e per quelli che ti ho tolto, per le parole che mi hai detto e per quelle che non mi hai detto, per il solo fatto che esisti e riempi di musica la mia vita.

CURRICULUM VITAE

Francesco Saia was born in Pescara, Italy, on March 29th 1971. In 1989 he obtained the General Certificate of Scientific Education at Liceo Scientifico Statale "G. Galilei" in Pescara. He obtained his Degree in Medicine and Surgery *Summa cum laude* in 1995 at the University of Bologna. He completed the School of Specialization in Cardiology in 2000 at the University of Bologna, *Summa cum laude*. He obtained the Doctorate in Pathophysiology of Heart Failure at the University of Bologna on May 2004. From October 1997 to February 1998 he worked as Research Fellow in Cardiology at the Royal Brompton Hospital in London, under the tutorship of Dr. Kim Fox. In 1998-1999 he completed the Military Service as a Medical Officer of the Italian Army. During that period, he qualified as Military Doctor of the Aviation Group. From July to September 1999, he participated to the humanitarian mission in Albany and Kosovo as Director of the Medical Service in Farke, Tirana. In 2000-2002 he completed his residency in Interventional Cardiology at the Catheterization Laboratory of the Institute of Cardiology, University of Bologna. In 2002-2003 he worked as Research Fellow at the Thoraxcenter, Erasmus Medical Center, University of Rotterdam, under the supervision of Prof. Patrick W. Serruys and Prof. Pim J de Feyter. He is presently working as Interventional Cardiologist at the Catheterization Laboratory of the Institute of Cardiology, University of Bologna.

Francesco Saia is a member of the Italian and of the European Society of Cardiology (ESC) since 1998, and of the Italian Society of Invasive Cardiology since 2003.

LIST OF PUBLICATIONS

Articles

1. Mollet NR, Cademartiri F, Nieman K, [Saia F](#), Lemos PA, McFadden EP, Pattynama PM, Serruys PW, Krestin GP, De Feyter PJ. Multislice spiral computed tomography coronary angiography in patients with stable angina pectoris. *J Am Coll Cardiol* 2004;43:2265-70.
2. Schaar JA, Regar E, Mastik F, McFadden EP, [Saia F](#), Disco C, de Korte CL, de Feyter PJ, van der Steen AF, Serruys PW. Incidence of high-strain patterns in human coronary arteries: assessment with three-dimensional intravascular palpography and correlation with clinical presentation. *Circulation* 2004;109:2716-9.
3. Regar E, Lemos PA, [Saia F](#), Degertekin M, Tanabe K, Lee CH, Arampatzis CA, Hoyer A, Sianos G, de Feyter P, van der Giessen WJ, Smits PC, van Domburg RT, Serruys PW. Incidence of thrombotic stent occlusion during the first three months after sirolimus-eluting stent implantation in 500 consecutive patients. *Am J Cardiol* 2004;93:1271-5.
4. Hoyer A, Tanabe K, Lemos PA, Aoki J, [Saia F](#), Arampatzis C, Degertekin M, Hofma SH, Sianos G, McFadden E, van der Giessen WJ, Smits PC, de Feyter PJ, van Domburg RT, Serruys PW. Significant reduction in restenosis after the use of sirolimus-eluting stents in the treatment of chronic total occlusions. *J Am Coll Cardiol* 2004;43:1954-8.
5. Hoyer A, Lemos PA, Arampatzis CA, [Saia F](#), Tanabe K, Degertekin M, Hofma S, McFadden E, Sianos G, Smits PC, van der Giessen WJ, de Feyter P, van Domburg RT, Serruys PW. Effectiveness of the sirolimus-eluting stent in the treatment of saphenous vein graft disease. *J Invasive Cardiol* 2004;16:230-3.
6. Hoyer A, Lemos PA, Arampatzis CA, [Saia F](#), Tanabe K, Degertekin M, Hofma S, McFadden E, Sianos G, Smits PC, van der Giessen WJ, de Feyter P, van Domburg RT, Serruys PW. Effectiveness of the sirolimus-eluting stent in the treatment of patients with a prior history of coronary artery bypass graft surgery. *Coron Artery Dis* 2004;15:171-5.
7. Lemos PA, Hoyer A, Goedhart D, Arampatzis CA, [Saia F](#), van der Giessen WJ, McFadden E, Sianos G, Smits PC, Hofma SH, de Feyter PJ, van Domburg RT, Serruys PW. Clinical, angiographic, and procedural predictors of angiographic restenosis after sirolimus-eluting stent implantation in complex patients: an evaluation from the Rapamycin-Eluting Stent Evaluated At Rotterdam Cardiology Hospital (RESEARCH) study. *Circulation* 2004;109:1366-70.
8. Lemos PA, Arampatzis CA, [Saia F](#), Hoyer A, Degertekin M, Tanabe K, Lee CH, Cummins P, Smits PC, McFadden E, Sianos G, de Feyter P, van der Giessen WJ, van Domburg RT, Serruys PW. Treatment of very small vessels with 2.25-mm diameter sirolimus-eluting stents (from the RESEARCH registry). *Am J Cardiol* 2004;93:633-6.
9. Degertekin M, Arampatzis CA, Lemos PA, [Saia F](#), Hoyer A, Daemen J, Tanabe K, Lee CH, Hofma SJ, Sianos G, McFadden E, van der Giessen W, Smits PC, de Feyter PJ, van Domburg RT, Serruys PW. Very long sirolimus-eluting stent implantation for de novo coronary lesions. *Am J Cardiol* 2004;93:826-9.
10. Ballantyne CM, Riegger G, Moore N, [Saia F](#), Serruys PW. Fluvastatin reduces cardiac mortality in patients with coronary heart disease. *Cardiovasc Drugs Ther* 2004;18:67-75.
11. [Saia F](#), Lemos PA, Arampatzis CA, Hoyer A, McFadden E, Sianos G, Smits PC, van der Giessen WJ, de Feyter PJ, van Domburg RT, Serruys PW. Clinical and angiographic outcomes after over-dilatation of undersized sirolimus-eluting stents with largely oversized balloons. *Catheter Cardiovasc Interv* 2004;61:455-60.
12. Lemos PA, [Saia F](#), Hofma SH, Daemen J, Ong ATL, Arampatzis CA, Hoyer A, McFadden E, Sianos G, Smits PC, van der Giessen WJ, de Feyter P, van Domburg RT, Serruys PW. Short- and Long-Term Clinical Benefit of Sirolimus- Eluting Stents Compared to Conventional Bare Stents for Patients With Acute Myocardial Infarction. *J Am Coll Cardiol* 2004;43:704-8.
13. Ortolani P, Marzocchi A, Marrozzini C, Palmerini T, Aquilina M, Corliano L, [Saia F](#), Taglieri N, Sbarzaglia P, Bacchi Reggiani ML, Branzi A. Clinical relevance of homocysteine levels in patients receiving coronary stenting for unstable angina. *Ital Heart J* 2004;5:189-96.
14. Arampatzis CA, Hoyer A, Lemos PA, [Saia F](#), Tanabe K, Degertekin M, Sianos G, Smits PC, van der Giessen WJ, McFadden E, van Domburg R, de Feyter P, Serruys PW. Elective

- sirolimus-eluting stent implantation for multivessel disease involving significant LAD stenosis. One-year clinical outcomes of 99 consecutive patients. The Rotterdam experience. *Cath and Cardiovasc Interv* 2004; in press.
15. Arampatzis CA, Lemos PA, Hoyer A, [Saia F](#), Tanabe K, van der Giessen WJ, Smits PC, McFadden E, de Feyter P, Serruys PW. Elective sirolimus-eluting stent implantation for left main coronary artery disease. 6-month angiographic follow-up and 1 year clinical outcome. *Cath and Cardiovasc Interv* 2004; in press.
 16. [Saia F](#), Sianos G, Hoyer A, Lemos PA, Van Der Giessen WJ, De Feyter P, Van Domburg RT, Serruys PW. Long-term outcome of percutaneous coronary interventions following failed Beta-brachytherapy. *J Invasive Cardiol* 2004;16:60-4.
 17. [Saia F](#), de Feyter P, Serruys PW, Lemos PA, Arampatzis CA, Hendrickx GR, Delarche N, Goedhart D, Lesaffre E, Branzi A. Effect of fluvastatin on long-term outcome after coronary revascularization with stent implantation. *Am J Cardiol* 2004;93:92-5.
 18. Sianos G, Hofma S, Ligthart JM, [Saia F](#), Hoyer A, Lemos PA, Serruys PW. Stent fracture and restenosis in the drug-eluting stent era. *Catheter Cardiovasc Interv* 2004;61:111-6.
 19. Lemos PA, Serruys PW, van Domburg RT, [Saia F](#), Arampatzis CA, Hoyer A, Degertekin M, Tanabe K, Daemen J, Liu TK, McFadden E, Sianos G, Hofma SH, Smits PC, van der Giessen WJ, de Feyter PJ. Unrestricted utilization of sirolimus-eluting stents compared with conventional bare stent implantation in the "real world": the Rapamycin-Eluting Stent Evaluated At Rotterdam Cardiology Hospital (RESEARCH) registry. *Circulation* 2004;109:190-5.
 20. [Saia F](#), Lemos PA, Lee CH, Arampatzis CA, Hoyer A, Degertekin M, Tanabe K, Sianos G, Smits PC, McFadden E, Hofma SH, van der Giessen WJ, de Feyter PJ, van Domburg RT, Serruys PW. Sirolimus-eluting stent implantation in ST-elevation acute myocardial infarction: a clinical and angiographic study. *Circulation* 2003;108:1927-9.
 21. Van Domburg RT, [Saia F](#), Lemos PA. Coronary artery bypass surgery and percutaneous transluminal coronary angioplasty in patients with multivessel disease. *Minerva Cardioangiol* 2003;51:599-608.
 22. Degertekin M, [Saia F](#), Lemos PA, Arampatzis CA, Serruys PW. Sirolimus-eluting stents for the treatment of in-stent restenosis. *Minerva Cardioangiol* 2003;51:475-84.
 23. Arampatzis CA, Lemos PA, Tanabe K, Hoyer A, Degertekin M, [Saia F](#), Lee CH, Ruiters A, McFadden E, Sianos G, Smits PC, van der Giessen WJ, de Feyter P, van Domburg R, Serruys PW. Effectiveness of sirolimus-eluting stent for treatment of left main coronary artery disease. *Am J Cardiol* 2003;92:327-9.
 24. Lemos PA, [Saia F](#), Ligthart JM, Arampatzis CA, Sianos G, Tanabe K, Hoyer A, Degertekin M, Daemen J, McFadden E, Hofma S, Smits PC, de Feyter P, van der Giessen WJ, van Domburg RT, Serruys PW. Coronary restenosis after sirolimus-eluting stent implantation: morphological description and mechanistic analysis from a consecutive series of cases. *Circulation* 2003;108:257-60.
 25. [Saia F](#), Lemos PA, Sianos G, Degertekin M, Lee CH, Arampatzis CA, Hoyer A, Tanabe K, Regar E, van der Giessen WJ, Smits PC, de Feyter P, Ligthart J, van Domburg RT, Serruys PW. Effectiveness of sirolimus-eluting stent implantation for recurrent in-stent restenosis after brachytherapy. *Am J Cardiol* 2003;92:200-3.
 26. Lemos PA, Lee CH, Degertekin M, [Saia F](#), Tanabe K, Arampatzis CA, Hoyer A, van Duuren M, Sianos G, Smits PC, de Feyter P, van der Giessen WJ, van Domburg RT, Serruys PW. Early outcome after sirolimus-eluting stent implantation in patients with acute coronary syndromes: insights from the Rapamycin-Eluting Stent Evaluated At Rotterdam Cardiology Hospital (RESEARCH) registry. *J Am Coll Cardiol* 2003;41:2093-9.
 27. Ortolani P, Marzocchi A, Marrozzini C, Palmerini T, [Saia F](#), Aquilina M, Corliano L, Campese G, Sbarzaglia P, Branzi A. Ultrasound-assisted stent implantation in small size coronary arteries: a pilot study. *Ital Heart J* 2001;2:372-8.
 28. Chua TP, [Saia F](#), Bhardwaj V, Wright C, Clarke D, Hennessy M, Fox KM. Are there gender differences in patients presenting with unstable angina? *Int J Cardiol* 2000;72:281-6.
 29. Marzocchi A, Ortolani P, Piovaccari G, Marrozzini C, Palmerini T, Marinucci L, [Saia F](#), Bacchi-Reggiani ML, Branzi A, Magnani B. Long-term follow-up of stent implantation versus stent-like angioplasty in unstable angina. *Cardiologia* 1999;44:261-8.

List of Publications

30. Marzocchi A, Ortolani P, Piovaccari G, Marrozzini C, Nobile G, Palmerini T, Marinucci L, Saia F, Bacchi Reggiani ML, Branzi A, Magnani B. Coronary stenting for unstable angina: predictors of 30-day and long-term clinical outcome. *Coron Artery Dis* 1999;10:81-8.
31. Saia F, Chua TP, Fox KM. The management of hypercholesterolaemia in patients with coronary artery disease referred for coronary angiography. *Int J Cardiol* 1998;67:247-9.
32. Mulcahy D, Gunning M, Knight C, Patel D, Davies M, Underwood R, Sutton G, Clarke D, Wright C, Saia F, Fox K. Long-term (5 year) effects of transient (silent) ischaemia on left ventricular systolic function in stable angina. Clinical and radionuclide study. *Eur Heart J* 1998;19:1342-7.
33. Saia F, Branzi A. Coronary heart disease in women. *Brit J Cardiol*; vol. 5 n. 7 Jul 1998: 382-387.

Abstracts

1. Saia F, Lemos PA, Hoyer A, Sianos G, Arampatzis CA, van der Giessen WJ, Smits PC, van Domburg RT, de Feyter PJ, Serruys PW. Similar Clinical Outcomes for Sirolimus-Eluting Stent Implantation and Coronary Brachytherapy for the Treatment of In-Stent Restenosis. *J Am Coll Cardiol* 2004;43[suppl A];90A.
2. Schaar JA, Regar E, Saia F, de Korte CL, Mastik F, van der Steen AF, Serruys PW. Incidence of Vulnerable Plaques in Humans: Assessment With 3-D Intravascular Palpography. *J Am Coll Cardiol* 2004;43[suppl A];307A.
3. Mollet NR, Cademartiri F, Nieman K, Saia F, Lemos PA, McFadden EP, Krestin GP, de Feyter PJ. Multislice Spiral Computed Tomography Coronary Angiography of the Entire Coronary Tree. *J Am Coll Cardiol* 2004;43[suppl A];329A.
4. Ong ATL, Lemos PA, Hoyer A, Arampatzis CA, Saia F, Aoki J, van Mieghem C, Hofma SH, Smits PC, van der Giessen WJ, Sianos G, McFadden E, Feyter P, Serruys PW. Safety and Feasibility of Paclitaxel-Eluting Stents in the Treatment of ST-Elevation Acute Myocardial Infarction. *J Am Coll Cardiol* 2004;43[suppl A];251A.
5. Ong ATL, Lemos PA, Hoyer A, Arampatzis CA, Saia F, Aoki J, van Mieghem C, Hofma SH, Smits PC, van der Giessen WJ, Sianos G, McFadden E, Feyter P, Serruys PW. Comparative Incidence of Angiographically Proven Early Stent Thrombosis in Unselected Sirolimus- and Paclitaxel-Eluting Stent Populations. *J Am Coll Cardiol* 2004;43[suppl A];98A.
6. Lemos PA, Arampatzis CA, Hoyer A, Daemen J, Saia F, Ong ATL, Sianos G, Aoki J, Smits PC, van der Giessen WJ, de Feyter P, McFadden E, Hofma SH, van Domburg RT, Serruys PW. Restenosis After Sirolimus-Eluting Stent Implantation: Long-Term Evaluation Following Repeat Percutaneous Intervention. *J Am Coll Cardiol* 2004;43[suppl A];71A.
7. Hoyer A, Lemos PA, Tanabe K, Arampatzis C, Saia F, Aoki J, Degertekin M, Ong ATL, van Mieghem C, Hofma SH, Sianos G, Smits PC, van der Giessen W, McFadden E, de Feyter P, Serruys PW. Low Repeat Revascularization Rates Following Drug-Eluting Stent Implantation in De Novo Bifurcation Lesions. *J Am Coll Cardiol* 2004;43[suppl A];36A.
8. Saia F, Lemos PA, Lee CH, Arampatzis CA, Hoyer A, Tanabe K, Degertekin M, Smits PC, Sianos G, van der Giessen WJ, McFadden E, Hofma S, de Feyter P, van Domburg RT, Serruys PW. Comparison between sirolimus-eluting stents and conventional interventional strategies for patients with acute myocardial infarction – Results from the RESEARCH registry. *Circulation* 2003; 108 (17 [Suppl]): IV-409.
9. Lemos PA, Saia F, Arampatzis CA, Hoyer A, Tanabe K, Degertekin M, Sianos G, Smits PC, van der Giessen WJ, de Feyter P, McFadden E, Hofma S, van Domburg RT, Serruys PW. Unrestricted Utilization of Sirolimus-Eluting Stent Implantation in the “Real World” Reduces Events Compared with Previous Strategies Using Conventional Bare Stents – A Study of 1200 Consecutive Patients from the RESEARCH registry. *Circulation* 2003; 108 (17 [Suppl]): IV-532.
10. Saia F, Lemos P, Arampatzis C, Hoyer A, Degertekin M, Tanabe K, Cummins P, Smits P, Sianos G, Van der Giessen W, McFadden E, Hofma S, de Feyter P, van Domburg R, Serruys P. Sirolimus-eluting stent implantation in daily practice: 9-months results from the Rapamycin-

- Eluting Stent Evaluated At Rotterdam Cardiology Hospital (RESEARCH) Registry. *Ital Heart J* 2003; 4 [suppl 6]; 153S.
11. [Saia F](#), Lemos P, Arampatzis CA, Hoyer A, Tanabe K, Degertekin M, Ruiters A, McFadden E, Van der Giessen W, Smits P, Sianos G, de Feyter P, van Domburg R, Serruys P. Low incidence of adverse cardiac events in patients with diabetes mellitus treated with sirolimus-eluting stents in the "real world". *Ital Heart J* 2003; 4 [suppl 6]; 153S.
 12. [Saia F](#), Lemos P, Arampatzis C, Hoyer A, Degertekin M, Tanabe K, Cummins P, Smits P, Sianos G, Van der Giessen W, McFadden E, Hofma S, de Feyter P, van Domburg R, Serruys P. Safety and effectiveness of sirolimus-eluting stent implantation in patients with acute myocardial infarction. Results from the RESEARCH Registry. *Ital Heart J* 2003; 4 [suppl 6]; 186S.
 13. Aquilina M, Ortolani P, Marzocchi A, Marrozzini C, Palmerini T, Sbarzaglia P, Taglieri N, [Saia F](#), Branzi A. Efficacia della brachiterapia endocoronarica beta (P32) nel trattamento della ristenosi di lesioni ad elevato rischio. *Ital Heart J* 2003; 4 [suppl 6]; 69S.
 14. [Saia F](#), Branzi A, Hendrickx G, Suryapranata H, Cequier A, Specchia G, Delarche N, Goedeheart D, de Feyter P, Serruys PW. Early fluvastatin treatment reduces the long-term incidence of major adverse cardiovascular events following successful first percutaneous coronary intervention with or without the use of stent: the Lescol Intervention Prevention Study. *J Am Coll Cardiol* 2003; 41 [suppl]; 227A.
 15. [Saia F](#), Lemos PA, Degertekin M, Regar E, Arampatzis CA, Lee CH, Tanabe K, de Feyter P, Van der Giessen WJ, Sianos G, Smits P, van Domburg RT, Serruys PW. Sirolimus-eluting stents for treatment of in-stent restenosis in the real world: preliminary results from the Rapamycin-Eluting Stent Evaluated At Rotterdam Cardiology Hospital (RESEARCH) Registry. *J Am Coll Cardiol* 2003; 41 [suppl]; 53A.
 16. Regar E, Lemos PA, Lee CH, Tanabe K, [Saia F](#), Degertekin M, Arampatzis CA, de Feyter P, van der Giessen WJ, Sianos G, Smits P, van Domburg RT, Serruys PW. Subacute stent thrombosis after sirolimus-eluting stent implantation in daily practice: results from the Rapamycin-Eluting Stent Evaluated At Rotterdam Cardiology Hospital (RESEARCH) Registry. *J Am Coll Cardiol* 2003; 41 [suppl]; 23A.
 17. Tanabe K, Lemos PA, Lee CH, Degertekin M, Regar E, Arampatzis CA, van Domburg RT, de Feyter P, Van der Giessen WJ, Sianos G, Smits P, Cummins P, Ruiters A, [Saia F](#), Serruys PW. Impact of sirolimus-eluting-stents on the outcome of patients with bifurcation. *J Am Coll Cardiol* 2003; 41 [suppl]; 12A.
 18. [Saia F](#), Lemos PA, Degertekin M, Lee CH, Smits PC, De Feyter P, Van Domburg R, Serruys PW. Sirolimus-eluting stents for treatment of in-stent restenosis in the real world: results from the rapamycin-eluting stent evaluated at Rotterdam Cardiology Hospital (RESEARCH) Registry. *Eur Heart J Vol 24, Abstr. Suppl. August/September 2003*; 142.
 19. [Saia F](#), Degertekin M, Tanabe K, Lemos P, Arampatzis CA, Sianos G, Smits PC, Serruys PW. Sirolimus-eluting stents to treat recurrent in-stent restenosis after brachytherapy. *Eur Heart J Vol 24, Abstr. Suppl. August/September 2003*; 143.
 20. Degertekin M, [Saia F](#), Lemos PA, Lee CH, De Feyter P, Sianos G, Van Domburg RT, Serruys PW. Efficacy of sirolimus-eluting stent implantation in long (>36mm) stented segments. A RESEARCH substudy. *Eur Heart J Vol 24, Abstr. Suppl. August/September 2003*; 714.
 21. Schaar JA, Regar E, Mastik F, [Saia F](#), De Korte CL, De Feyter PJ, Van der Steen AFW, Serruys PW. Incidence of vulnerable plaques in humans: assessment with intravascular palpography. *Eur Heart J Vol 24, Abstr. Suppl. August/September 2003*; 419.
 22. Hoyer A, Sianos G, [Saia F](#), Serruys PW. Long-term outcome after intracoronary beta radiation therapy. *Eur Heart J Vol 24, Abstr. Suppl. August/September 2003*; 422.
 23. Regar E, Lemos PA, [Saia F](#), Tanabe K, Degertekin M, Arampatzis CA, Van Domburg R, Serruys PW. Low incidence of subacute stent thrombosis after sirolimus-eluting stent implantation in daily practice - results from the rapamycin eluting stent evaluated at Rotterdam hospital (RESEARCH) registry. *Eur Heart J Vol 24, Abstr. Suppl. August/September 2003*; 430.

24. Hoyer A, Saia F, Degertekin M, Lemos PA, Arampatzis CA, Tanabe K, Lee CH, Sianos G, Smits PC, van der Giessen W, de Feyter P, Serruys PW, van Domburg RT. Sirolimus-eluting stent implantation for restenosis following brachytherapy. *Heart* 2003, in press.
25. Hoyer A, Lemos P, Regar E, Saia F, Degertekin M, Arampatzis C, Tanabe K, Lee C, van Domburg R, Sianos G, Smits PC, van der Giessen W, de Feyter P, Serruys PW. Very low incidence of acute and subacute thrombosis following sirolimus-eluting stent implantation in a large series of consecutive patients – insights from the Rapamycin-Eluting Stent Evaluated At Rotterdam Cardiology Hospital (RESEARCH) Registry. *Heart* 2003, in press.
26. Saia F, Lemos PA, Lee CH, Tanabe K, Degertekin M, Regar E, Cummins P, Ruiter A, de Feyter P, van der Giessen WJ, Sianos G, Smits P, van Domburg RT, Serruys PW. Sirolimus-eluting stents in clinical practice. Preliminary results from the Rapamycin-Eluting Stent Evaluated At Rotterdam Cardiology Hospital (RESEARCH) Registry. *Emodinamica* 2002, *Atti del XXIV Congresso Nazionale del Gruppo Italiano di Studi Emodinamici e Cardiologia interventistica (GISE)*; Verona, 23-27 Ottobre 2002.
27. Ortolani P, Marzocchi A, Marrozzini C, Saia F, Sbarzaglia P, Aquilina M, Corlianò L, Camplese G, Branzi A. Impianto elettivo, IVUS-guidato, di Bestent nei rami coronarici di piccolo calibro. Dati preliminari dello studio SVIASI. *Ital Heart J* 2000; 1 [suppl 6]: 40S.
28. Piovaccari G, Ortolani P, Marzocchi A, Marrozzini C, Palmerini T, Nobile G, Marinucci L, Saia F, Branzi A, Magnani B. Unplanned stenting for suboptimal result after conventional coronary angioplasty. [Impianto di stent non elettivo per risultato subottimale dopo angioplastica coronarica convenzionale]. Abstract P38; 20 Years of PTCA 1977-1997; Zurich, Switzerland 15-17 September 1997.
29. Ortolani P, Marzocchi A, Piovaccari G, Marrozzini C, Palmerini T, Nobile G, Marinucci L, Saia F, Branzi A, Magnani B. Results of coronary stenting for unstable angina. [Risultati dell'utilizzo di stent coronarico nell'angina instabile]. Abstract P39; 20 Years of PTCA 1977-1997; Zurich, Switzerland 15-17 September 1997.
30. Marrozzini C, Marzocchi A, Piovaccari G, Ortolani P, Nobile G, Palmerini T, Marinucci L, Saia F, Belletti G, Branzi A, Magnani B. Risultati dell'angioplastica coronarica nell'angina instabile: confronto tra procedura tradizionale ed impianto di stent. Comunicazione C2; XIX Congresso Nazionale del Gruppo Italiano di Studi Emodinamici e Cardiologia interventistica (GISE); Bologna, Palazzo dei Congressi 9-11 Ottobre 1997.
31. Ortolani P, Marzocchi A, Piovaccari G, Marrozzini C, Nobile G, Palmerini T, Marinucci L, Saia F, Belletti G, Branzi A, Magnani B. Impianto di stent nell'angina pectoris instabile: fattori predittori a breve e a lungo termine. Comunicazione C3; XIX Congresso Nazionale del Gruppo Italiano di Studi Emodinamici e Cardiologia interventistica (GISE); Bologna, Palazzo dei Congressi 9-11 Ottobre 1997.
32. Ortolani P, Marzocchi A, Piovaccari G, Marrozzini C, Nobile G, Palmerini T, Marinucci L, Saia F, Belletti G, Branzi A, Magnani B. Impianto di stent nell'angina pectoris instabile: confronto tra terapia antiaggregante combinata e terapia anticoagulante. Comunicazione C5; XIX Congresso Nazionale del Gruppo Italiano di Studi Emodinamici e Cardiologia interventistica (GISE); Bologna, Palazzo dei Congressi 9-11 Ottobre 1997.
33. Ortolani P, Marzocchi A, Piovaccari G, Marrozzini C, Palmerini T, Marinucci L, Saia F, Tortorici GF, Belletti G, Di Marco M, Camplese G, Branzi A, Magnani B. PTCA "stent-like" vs stent nei pazienti con angina instabile. Risultati a lungo termine. *G It Cardiol*, Vol 28, Suppl 2, 1998:64 (C230).

Book Chapters

1. DIAGNOSIS OF VULNERABLE PLAQUES IN THE CARDIAC CATHETERIZATION LABORATORY. Johannes A Schaar, Evelyn Regar, Francesco Saia, Chourmouzos A. Arampatzis, Angela Hoye, Fritz Mastik, Rob Krams, Cornelis J Slager, Frank J Gijzen, Jolanda J Wentzel, Pim J de Feyter, Anton FW van der Steen and Patrick W Serruys. Da Waksman-Serruys, **Handbook of vulnerable plaque**, in press.
2. NEW INTRACORONARY DIAGNOSTIC METHODS. E. Regar, J.A. Schaar, F. Saia, P. Lemos, P.A. Magnin, P.J. de Feyter, P. Smits, P.W. Serruys. **EURO-PCR Book Course 2003**; Cap. 7. Paris, 2003.
3. DRUG-ELUTING STENTS. Pedro A Lemos, Sjoerd H Hofma, Evelyn Regar, Francesco Saia, Patrick W Serruys. **EURO-PCR Book Course 2004**; Cap. 15. Paris, 2004.
4. BILANCI BENEFICI/RISCHI DELL'ANGIOPLASTICA CORONARIA NELL'ULTRA SETTANTENNE. Antonio Marzocchi, Paolo Ortolani, Giancarlo Piovaccari, Cinzia Marrozzini, Matteo Aquilina, Lucia Marinucci, Francesco Saia, Angelo Branzi, Bruno Magnani. **Cardiologia 1998**, ed. C. De Vita- A. Moreo. 32° convegno internazionale del dipartimento cardiologico e cardiocirurgico A. De Gasperis. Milano 1998.

Financial support for the publication of this thesis was generously provided by:

- Cordis, a Johnson & Johnson Company
- Guidant Italia
- Netherlands Heart Foundation

