

# A Systematic Review and Meta-analysis on Omentoplasty for the Management of Abdominoperineal Defects in Patients Treated for Cancer

Robin D. Blok, MD,\*† Jan A. W. Hagemans, MD,‡ Charlotte E. L. Klaver, MD,\* Joke Hellinga, MD,§  
Boudewijn van Etten, MD, PhD,¶ Jacobus W. A. Burger, MD, PhD,‡|| Cornelis Verhoef, MD, PhD,‡  
Roel Hompes, MD,\* Wilhelmus A. Bemelman, MD, PhD,\* and Pieter J. Tanis, MD, PhD\*

**Objective:** The objective of this systematic review and meta-analysis was to examine the effects of omentoplasty on pelviperineal morbidity following abdominoperineal resection (APR) in patients with cancer.

**Background:** Recent studies have questioned the use of omentoplasty for the prevention of perineal wound complications.

**Methods:** A systematic review of published literature since 2000 on the use of omentoplasty during APR for cancer was undertaken. The authors were requested to share their source patient data. Meta-analyses were conducted using a random-effects model.

**Results:** Fourteen studies comprising 1894 patients (n = 839 omentoplasty) were included. The majority had APR for rectal cancer (87%). Omentoplasty was not significantly associated with the risk of presacral abscess formation in the overall population (RR 1.11; 95% CI 0.79–1.56), nor in planned subgroup analysis (n = 758) of APR with primary perineal closure for nonlocally advanced rectal cancer (RR 1.06; 95% CI 0.68–1.64). No overall differences were found for complicated perineal wound healing within 30 days (RR 1.30; 95% CI 0.92–1.82), chronic perineal sinus (RR 1.08; 95% CI 0.53–2.20), and pelviperineal complication necessitating reoperation (RR 1.06; 95% CI 0.80–1.42) as well. An increased risk of developing a perineal hernia was found for patients submitted to omentoplasty (RR 1.85; 95% CI 1.26–2.72). Complications related to the omentoplasty were reported in 4.6% (95% CI 2.5%–8.6%).

**Conclusions:** This meta-analysis revealed no beneficial effect of omentoplasty on presacral abscess formation and perineal wound healing after APR, while it increases the likelihood of developing a perineal hernia. These findings do not support the routine use of omentoplasty in APR for cancer.

**Keywords:** abdominoperineal resection, omentoplasty, perineal hernia, perineal wound healing, presacral abscess, surgical oncology

(*Ann Surg* 2020;271:654–662)

The pelvic wound bed after abdominoperineal resection (APR) carries a high risk of morbidity.<sup>1–3</sup> This is likely related to the contaminated operative field and dead space formation with fluid accumulation, and may be further increased by extended resections and compromised perfusion postradiotherapy. A randomized controlled trial showed that perineal complications within 1 year after APR with primary perineal closure may occur in up to 48%.<sup>4</sup> Patients frequently develop perineal wound dehiscence and infection, and often endure delayed healing. Secondary wound healing can take several months and may eventually result in a chronic perineal sinus.<sup>5</sup> Furthermore, patients may develop perineal pain and sitting problems, as well as a perineal hernia.<sup>6,7</sup>

To improve perineal wound healing after APR, various reconstructive methods have been proposed. These include the use of a

From the \*Department of Surgery, Amsterdam UMC, University of Amsterdam, Amsterdam, The Netherlands; †LEXOR, Center for Experimental and Molecular Medicine, Onco Institute, Cancer Center Amsterdam, Amsterdam UMC, University of Amsterdam, Amsterdam, The Netherlands; ‡Department of Surgical Oncology, Erasmus Medical Center, Cancer Institute, Rotterdam, The Netherlands; §Department of Plastic Surgery, University Medical Center Groningen, University of Groningen, Groningen, The Netherlands; ¶Department of Surgery, University Medical Center Groningen, University of Groningen, Groningen, The Netherlands; and ||Department of Surgery, Catharina Hospital Eindhoven, Eindhoven, The Netherlands.

Study concept and design: R.D.B., J.A.W.H., and P.J.T.

Acquisition of data: R.D.B., J.A.W.H., C.E.L.K., and J.H.

Analysis and interpretation of data: R.D.B., J.A.W.H., B.E., J.W.A.B., C.V., R.H., W.A.B., and P.J.T.

Writing manuscript: R.D.B. and J.A.W.H.

Revising it critically: C.E.L.K., J.H., B.E., J.W.A.B., C.V., R.H., W.A.B., and P.J.T.

All authors approved the final version.

PubMed citable collaborators:

Netherlands

-G.D. Musters, MD, PhD, Department of Surgery, Amsterdam UMC, University of Amsterdam, Amsterdam, the Netherlands.

France

-S. Kirzin, MD, PhD, Department of Colorectal Surgery, Purpan University Hospital, Toulouse, France.

-F. Dumont, MD, Department of Surgical Oncology, ICO René Gauducheau Cancer Center, Saint-Herblain, France

Germany

-J. Hardt, MD, PhD, Department of Surgery, Universitätsmedizin Mannheim, Medical Faculty Mannheim, University Heidelberg, Mannheim, Germany.

United Kingdom

-H.J.S. Jones, MD, Department of Colorectal Surgery, Oxford University Hospitals NHS Foundation Trust, Oxford, United Kingdom.

-Pelican LOREC Group

Sweden

-M. Abraham-Nordling, MD, PhD, Associate Professor of Surgery, Department of Molecular Medicine and Surgery, Karolinska Institutet, Stockholm, Sweden.

-N. Baloch, MD, Department of Molecular Medicine and Surgery, Karolinska Institutet, Stockholm, Sweden.

-P.J. Nilsson, MD, PhD, Department of Molecular Medicine and Surgery, Karolinska Institutet, Stockholm, Sweden.

-C. Nordenvall, MD, PhD, Department of Molecular Medicine and Surgery, Karolinska Institutet, Stockholm, Sweden.

United States of America

-A.T. Hawkins, MD, Assistant Professor of Surgery, Vanderbilt University Medical Center, Division of General Surgery, Section of Colon & Rectal Surgery, Nashville, Tennessee, United States of America.

The authors report no conflicts of interest.

Supplemental digital content is available for this article. Direct URL citations appear in the printed text and are provided in the HTML and PDF versions of this article on the journal's Web site ([www.annalsofsurgery.com](http://www.annalsofsurgery.com)).

Reprints: Dr. Pieter J. Tanis, MD, PhD, Surgeon, Department of Surgery, Amsterdam UMC, AMC, Post box 22660, 1100 DD, Amsterdam, The Netherlands. E-mail: P.J.Tanis@amc.nl.

Copyright © 2020 Wolters Kluwer Health, Inc. All rights reserved.

ISSN: 0003-4932/20/27104-0654

DOI: 10.1097/SLA.0000000000003266

biological mesh and several tissue flaps, such as a pedicled omentoplasty (OP) or a vertical rectus abdominis muscle flap (VRAM),<sup>8–10</sup> The flaps serve to obliterate the often noncollapsible defect with healthy and well perfused tissue, which has been associated with reduced abscess formation and improved wound healing.<sup>11,12</sup>

The omentum is supposedly an ideal option to prevent dead space formation after APR. It has a rich blood supply, expresses anti-inflammatory cytokines, often provides for abundant bulk, and appears relatively easy to release.<sup>13–16</sup> Many surgeons therefore perform an OP as part of the APR procedure. In a recent nationwide study with variability in practice of applying OP, no improvement in perineal wound healing was observed, and the OP particularly seemed to increase the risk of perineal herniation.<sup>6</sup> These results challenge the value of OP for closure of the pelvic defect after APR. Therefore, the aim of this systematic review and meta-analysis was to assess the effects of OP following APR on pelviperineal morbidity and related problems in patients treated for cancer in the published literature since 2000.

## METHODS

The study protocol was prospectively registered at PROSPERO (registration number: CRD42017073573) and followed Preferred Reporting Items for Systematic Reviews and Meta-analysis (PRISMA) guidance.<sup>17</sup>

### Search

The literature was systematically reviewed by searching in the PubMed-library for studies published between January 2000 and March 2017. The search was limited to publication since 2000 to limit the influence of historical changes in surgical and perioperative care, which better ties in to current practices. The search was rerun in June 2018 (Supplementary Digital Content 1, <http://links.lww.com/SLA/B624>). The search strategy only included terms relating to or describing neoplasms, surgical outcome, and APR. Since most studies do not explicitly mention the use of OP in the title or abstract, this was not included as a search term. Additional articles were manually selected from the reference lists of the retrieved papers.

### Eligibility

Original studies including patients undergoing APR for cancer and reporting on use of OP and perineal wound outcome were potentially eligible. Articles were restricted to the English language. Exclusion criteria were studies with no original data, individual case reports (<10 patients with OP), studies that did not report on at least 1 predefined outcome of interest, and studies that exclusively pertained to pelvic exenteration or benign disease.

### Outcome Parameters

The primary endpoint was incidence of presacral abscess formation, as this was expected to be most consistently reported. Secondary endpoints were the rate of overall pelviperineal wound complications within 30 days, 1 year, and the total study period, wound healing time, specific pelviperineal morbidity (ie, wound dehiscence, superficial wound infection, hemorrhage, perineal sinus), ileus (overall, and proportion requiring reoperation), perineal hernia (not specified), OP-related morbidity, operative time, and surgical perineal reintervention. Pelviperineal complication included any pelvic or perineal wound event (including perineal hernia), and surgical perineal reintervention any pelvic or perineal wound-related reoperation (including hernia repair). Perineal infection was categorized into superficial wound infection (including perineal abscess), and deep wound infection (ie, presacral abscess). Perineal hemorrhage included active perineal bleeding or hematoma (regardless of

need for reintervention). There was no definition given for presacral abscess, perineal sinus, and perineal hernia. Perineal hernia was based on the reporting of the source studies, and could vary from asymptomatic incidental computed tomography finding to symptomatic perineal bulge requiring surgical repair.

### Data Collection and Extraction

Two independent reviewers (R.D.B. and C.E.L.K.) scanned all abstracts identified by the search and cross-referencing. Full texts were retrieved for all studies that potentially met the inclusion criteria. Two reviewers (R.D.B. and J.A.W.H.) further independently reviewed the eligibility of these studies in full text. Any disagreement on the eligibility of particular studies was resolved through consensus discussion with a third reviewer (P.J.T.). Papers not meeting the inclusion criteria were excluded and listed with reason for omission (Fig. 1). All authors were contacted on 3 separate occasions to share either the source individual patient data or aggregate data, reported separately for OP and non-OP.

Data extraction included general study information, participant demographics, operative details, perineal wound outcome, length of follow-up, and information for assessment of the risk of bias. Any disagreement was solved by consensus discussion, if necessary with a third reviewer (P.J.T.). In case of missing data, the study authors were contacted to request additional information.

The received source patient data was preferably used, and may slightly differ from the original publication. If this was not available, data from the original publication was used. The cohort of Musters et al<sup>5</sup> was updated using original patient files. From the initial 104 patients of the *BIOPEX study*, 99 were entered in the analyses because of missing outcome data due to study exclusions.<sup>4</sup>

### Assessment of Risk of Bias in Included Studies

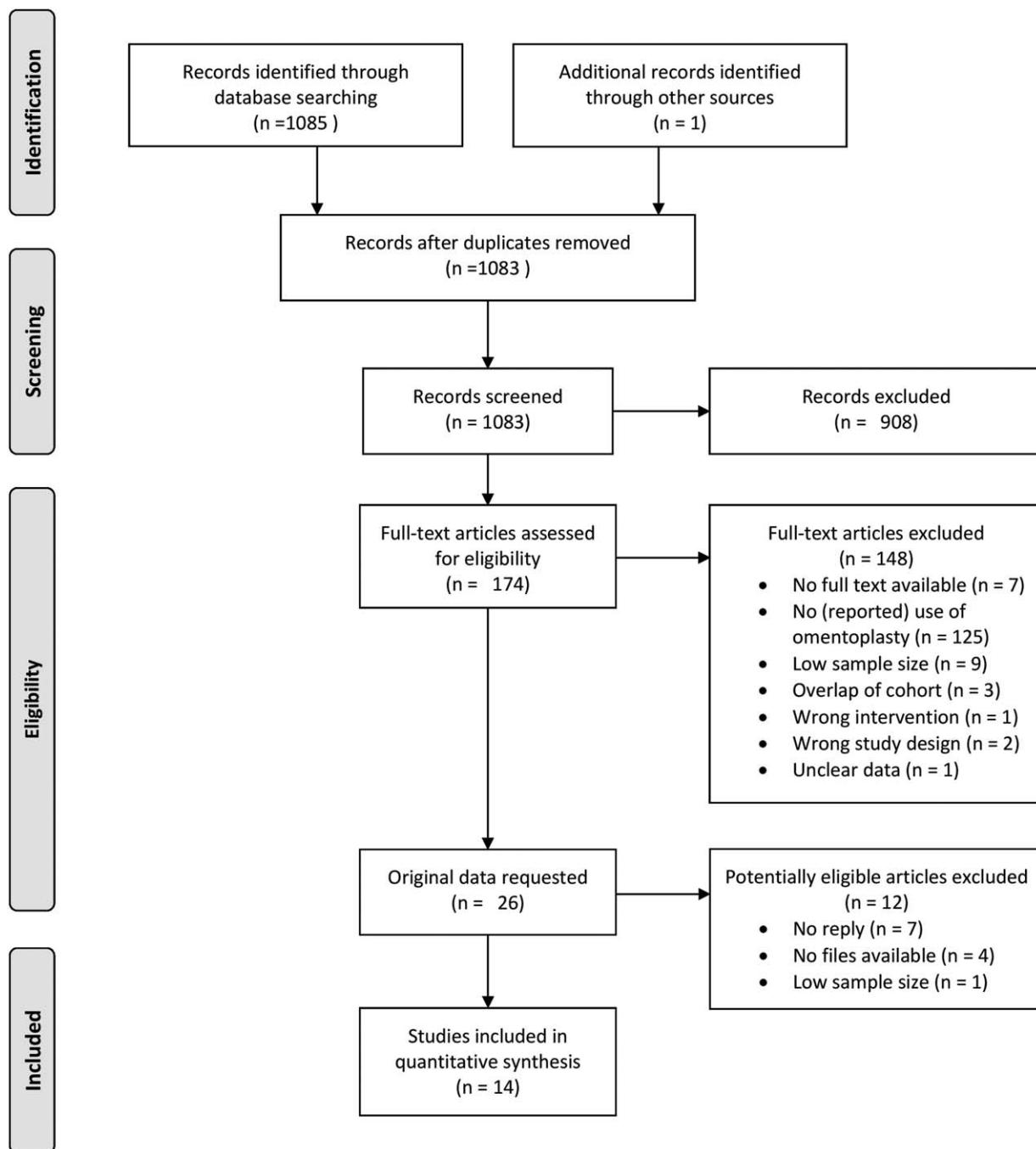
Two reviewers (R.D.B. and J.A.W.H.) independently assessed the risk of bias in the included studies using the Newcastle-Ottawa Scale for nonrandomized studies.<sup>18,19</sup>

### Data Synthesis

All outcome measures were quantitatively summarized. If at least 3 comparative studies ( $\geq 10$  cases in both groups) provided data on a study parameter, data were pooled in meta-analysis using Review Manager (RevMan 5; Cochrane Collaboration). Studies without a control (<10 cases of non-OP) were pooled in proportional meta-analysis using RStudio (version 3.5.1). Pooled estimates of effect were calculated along with corresponding 95% confidence interval (CI), using a random-effects model. The method as proposed by Wan et al<sup>20</sup> was used to approximate the estimation of the sample mean and standard deviation in case the median and interquartile range was given. Dichotomous data were summarized by risk ratios (RR), and continuous data were presented as mean differences. Heterogeneity between studies was perceived considerable when  $I^2 \geq 75\%$ .<sup>21</sup> Two-sided  $P$  values  $< 0.05$  were considered statistically significant. Funnel plots were generated to assess for publication bias. The evidence along with the quality of the data was summarized in a GRADE summary of findings table.

### Analysis of Subgroups

To decrease potential bias introduced by diverse indication and surgical methods, a planned subgroup analysis was performed for patients who underwent APR with primary perineal closure for nonlocally advanced rectal cancer. The additional exclusion criteria for the purpose of this subgroup analysis were reconstructions using a mesh and/or flap, other pelvic malignancies, pT4 stage, and adjacent organ resection. We also performed a planned subgroup analysis only in patients who received preoperative radiotherapy.



**FIGURE 1.** PRISMA flow diagram depicting the search strategy and study selection process. PRISMA indicates preferred reporting items for systematic reviews and meta-analysis.

## RESULTS

### Literature Search and Selection

The results of the literature search are displayed in Figure 1. After deduplication, the combined search yielded 1081 articles, of which 26 were identified as potentially eligible. After contacting the authors, individual patient data were provided in six<sup>4–6,22–24</sup> and aggregate data in four.<sup>25–28</sup> An additional of 4 studies with full text of the original paper only were included.<sup>9,10,29,30</sup> Eleven studies without

separate data for OP,<sup>31–41</sup> and 1 study that eventually appeared to have included only 1 patient with OP<sup>42</sup> were excluded.

### Study Characteristics

General study descriptions are demonstrated in Table 1. Eleven studies had a control group (ie,  $\geq 10$  cases of non-OP).<sup>2,4,6,9,10,22–24,26,28,30</sup> The quality of the included studies was moderate to good (range 5–9; Supplementary Table 2; Supplemental Digital Content 2, <http://links.lww.com/SLA/B624>). The 14

**TABLE 1.** Study Descriptions of the Included Studies

Study (Author)	Year	Country	Design	Quality*	Disease	Patients (n = 1894)	OP (n = 839)	Non-OP (n = 1055)
De Broux et al	2005	France	Retrospective cohort study	5	Rectal cancer	92	92	0
Lefevre et al	2009	France	Retrospective cohort study	7	Anal cancer	95	52	43
Hultman et al	2010	USA	Retrospective cohort study	5	Rectal cancer and anal cancer	70	29	41
Kirzin et al	2010	France	Retrospective cohort study	6	Rectal cancer	109	19	90
Oida et al	2012	Japan	Retrospective cohort study	8	Rectal cancer	45	20	25
Dumont et al	2012	France	Retrospective cohort study	6	Rectal cancer, anal cancer, and other	132	101	31
Hawkins et al	2014	USA	Retrospective cohort study	8	Rectal cancer	251	109	142
Musters et al	2014	Netherlands	Retrospective cohort study	9	Rectal cancer	128	50	78
Hardt et al	2016	Germany	Retrospective cohort study	6	Anal cancer	17	16	1
Hellinga et al	2016	Netherlands	Retrospective cohort study	5	Rectal cancer, anal cancer, and other	24	20	4
Jones et al	2017	United Kingdom	Prospective cohort study	6	Rectal cancer and anal cancer	266	42	224
Musters et al	2017	Netherlands	Prospective cohort study <sup>a</sup>	9	Rectal cancer	99	61	38
Blok et al	2018	Netherlands	Retrospective cross-sectional cohort study	9	Rectal cancer	477	172	305
Baloch et al	2018	Sweden	Retrospective cohort study	8	Rectal cancer, anal cancer, and other	89	56	33

\*Newcastle-Ottawa Quality Assessment Scale; a, randomized controlled trial of biomesh versus primary perineal closure, in which omentoplasty was at the discretion of the operating surgeon.

included studies covered a total of 1894 patients, of whom 839 underwent OP.

Pooled baseline characteristics of the 2 groups are demonstrated in Table 2. The indication for APR was predominantly rectal cancer (87.2%). The number of patients receiving neo-adjuvant

radiotherapy was 82.5% in the OP group and 74.4% in the non-OP group. Similar proportions of adjacent organ resection were performed (21.4% vs 18.2%) with slightly less additional reconstructive procedures in the OP group (17.8% vs 27.5%). Median operative time was median 19 minutes longer for APR with OP, but not

**TABLE 2.** Pooled Baseline Characteristics of Study Population With (OP) and Without Omentoplasty (Non-OP)

	All Patients (n = 1894)		Nonlocally Advanced Rectal Cancer and Primary Perineal Closure (n = 758)*	
	OP (n = 839)	Non-OP (n = 1055)	OP (n = 281)	Non-OP (n = 477)
Age				
Years (median [IQR])	64.3 [61.9–66.6]	64.0 [61.7–66.2]	64.9 [62.5–67.3]	66.2 [64.2–68.1]
Sex				
Male	438 (52%)	659 (62%)	204 (73%)	321 (67%)
Female	280 (33%)	355 (34%)	77 (27%)	156 (33%)
NR	121 (14%)	178 (17%)	0 (0%)	0 (0%)
Disease				
Rectal cancer	693 (83%)	959 (91%)	281 (100%)	477 (100%)
Anal cancer	99 (12%)	52 (5%)	0 (0%)	0 (0%)
Other malignant disease	18 (2%)	3 (0%)	0 (0%)	0 (0%)
NR	29 (3%)	66 (6%)	0 (0%)	0 (0%)
Neoadjuvant therapy				
None	104 (12%)	174 (16%)	18 (6%)	50 (10%)
Short course RTx (25 Gy)	93 (11%)	114 (11%)	86 (31%)	168 (35%)
Long course RTx (40–60 Gy)	78 (9%)	34 (3%)	15 (5%)	22 (5%)
CRTx	319 (38%)	360 (34%)	147 (52%)	220 (46%)
NR	245 (29%)	373 (35%)	0 (0%)	0 (0%)
Type of resection				
APR	594 (71%)	793 (75%)	281 (100%)	477 (100%)
APR with MVR	154 (18%)	175 (17%)	0 (0%)	0 (0%)
Total pelvic exenteration	8 (1%)	1 (0%)	0 (0%)	0 (0%)
NR	83 (10%)	86 (8%)	0 (0%)	0 (0%)
Perineal closure				
Primary suturing	690 (82%)	765 (73%)	281 (100%)	477 (100%)
Muscle flap reconstruction	42 (5%)	127 (12%)	0 (0%)	0 (0%)
Mesh closure	107 (13%)	163 (15%)	0 (0%)	0 (0%)
NR	0 (0%)	0 (0%)	0 (0%)	0 (0%)
Follow-up time				
Mo [Median (IQR)]	36.6 [24.6–48.6]	36.6 [22.7–50.5]	37.9 [19.3–56.5]	36.8 [19.6–53.8]

Percentages might not add up due to rounding.

CRTx indicates chemoradiotherapy; IQR, interquartile range; MVR, multivisceral resection; NR, not reported; RTx, radiotherapy.

**TABLE 3.** GRADE Summary of Findings Table of the Effects of Omentoplasty for Filling of the Pelvic Cavity Following Abdominoperineal Resection

Patient population: Patients who underwent abdominoperineal resection for malignant disease  
 Intervention: Omentoplasty  
 Comparison: No omentoplasty

Outcomes	Relative Effect	95% CI	I <sup>2</sup>	No. of Participants (Studies)	Quality of the Evidence (GRADE)
Complicated wound healing < 30 d	RR 1.30	0.92–1.82	74%	853 (5)	⊕⊕⊕⊕ High
Any complicated wound healing < follow-up	RR 1.09	0.83–1.44	69%	1033 (9)	⊕⊕⊕⊕ High
Superficial perineal infection	RR 0.85	0.45–1.62	78%	1100 (8)	⊕⊕⊕⊖ Moderate
Presacral abscess	RR 1.11	0.79–1.56	0%	1596 (9)	⊕⊕⊕⊕ High
Perineal dehiscence	RR 1.21	0.96–1.53	54%	1621 (9)	⊕⊕⊕⊖ Moderate
Perineal hemorrhage	RR 1.39	0.29–6.58	25%	307 (3)	⊕⊕⊖⊖ Low
Persistent perineal sinus	RR 1.08	0.53–2.20	56%	1370 (8)	⊕⊕⊕⊖ Moderate
Perineal hernia	RR 1.85	1.26–2.72	0%	1584 (9)	⊕⊕⊕⊖ Moderate
Ileus	RR 0.90	0.62–1.31	0%	789 (6)	⊕⊕⊕⊖ Moderate
Reoperation for pelviperineal complication	RR 1.06	0.80–1.42	0%	1401 (9)	⊕⊕⊕⊕ High

GRADE Working Group grades of evidence.  
 High quality: further research is very unlikely to change our confidence in the estimate effect.  
 Moderate quality: further research is likely to have an important impact on our confidence in the estimate of effect and may change the estimate.  
 Low quality: further research is very likely to have an important impact on our confidence in the estimate of effect and is likely to change the estimate.  
 Very low quality: we are very uncertain about the estimate.  
 CI indicates confidence interval; I<sup>2</sup>, test for heterogeneity; RR, risk ratio.

significantly different from the non-OP group. Median follow-up duration of the included studies ranged from 12 to 62 months (overall weighted mean 36.6 mo). Supplementary Table 3 (Supplemental Digital Content 3, <http://links.lww.com/SLA/B624>) shows the baseline characteristics and operative details for each of the included studies.

**Study Endpoints**

Supplementary Table 4 (Supplemental Digital Content 4, <http://links.lww.com/SLA/B624>) shows the outcomes for each of the included studies. The main findings of the study are summarized in Table 3. Visual inspection of the funnel plots for the main outcomes of interest did not suggest presence of significant publication bias (Supplementary Figure 1; Supplemental Digital Content 5, <http://links.lww.com/SLA/B624>).

**Presacral Abscess**

Twelve studies recorded the incidence of presacral abscess formation.<sup>4–6,10,22–29</sup> The overall weighted mean proportion of presacral abscess formation following OP was 8.7% (95% CI 6.1%–12.3%). Considering 9 comparative studies,<sup>4–6,10,22–24,26,28</sup> presacral abscesses similarly occurred after OP and non-OP (RR 1.11; 95% CI 0.79–1.56; I<sup>2</sup> = 0%) (Fig. 2A). The risk of presacral abscess was also similar in the predefined subgroup of APR with primary perineal closure for nonlocally advanced rectal cancer (RR 1.06; 95% CI 0.68–1.64; I<sup>2</sup> = 0%) (Fig. 2B).<sup>4–6,23,24</sup> Similarly, there was no reduced risk of developing presacral abscesses after OP when only analyzing the patients who have been treated with preoperative radiotherapy (RR 0.94; 95% CI 0.61–1.45; I<sup>2</sup> = 0%).<sup>2,4,6,23,24</sup>

**Perineal Wound Healing**

Eight studies recorded the primary perineal wound healing.<sup>2,4,24–29</sup> The overall weighted mean cumulative proportion of complicated wound healing at 30 days following OP was 50.6% (95% CI 35.5%–65.6%). In 5 comparative studies,<sup>2,4,24,26,28</sup> the rate of complicated wound healing within 30 days was not significantly different after OP and non-OP (RR 1.30; 95% CI 0.92–1.82; I<sup>2</sup> = 74%). In subgroup analysis of APR with primary perineal closure for nonlocally advanced disease, the association of OP with 30-day

wound complications remained nonsignificant (RR 1.28; 95% CI 0.64–2.56; I<sup>2</sup> = 73%).<sup>2,4,24</sup> There was no reduced risk of pelviperineal morbidity within 1 year (RR 1.18; 95% CI 0.80–1.74; I<sup>2</sup> = 80%)<sup>2,4,22,24,28</sup> or within the total study period (RR 1.09; 95% CI 0.83–1.44; I<sup>2</sup> = 69%)<sup>2,4,9,10,22–24,28,30</sup> for patients submitted to OP.

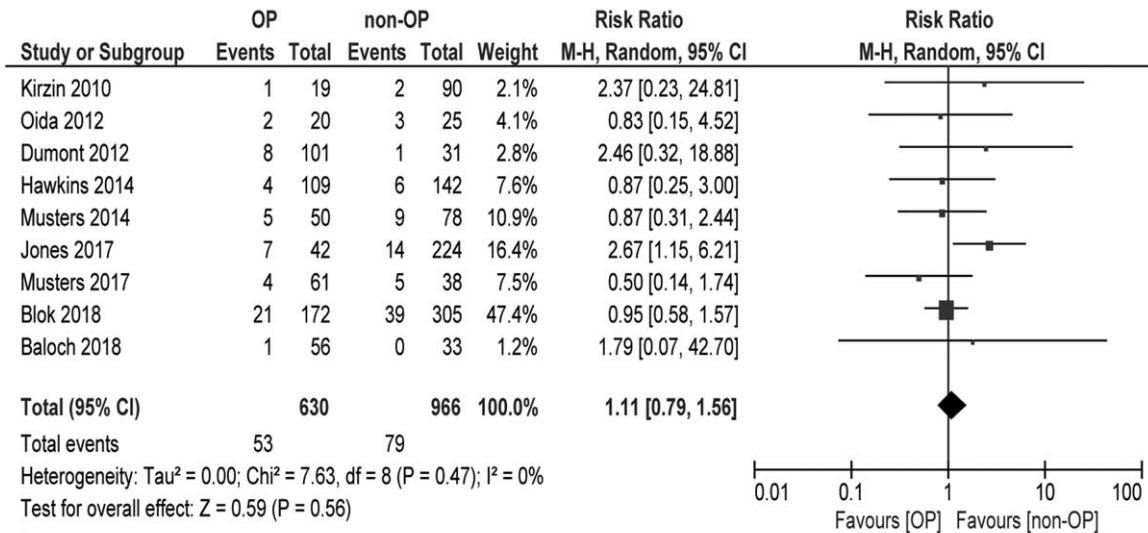
Time to complete healing was not uniformly reported with regard to patient population (eg, all patients or only those with dehiscence) and measuring unit (eg, days or weeks) (Supplementary Table 4; Supplemental Digital Content 4, <http://links.lww.com/SLA/B624>). The included studies demonstrated no significant difference in time to achieve perineal wound healing in terms of mean number of days (mean differences 24 d in favor of non-OP; 95% CI minus 11 to 59; I<sup>2</sup> = 80%),<sup>23,24,26,30</sup> or the proportion of patients in whom the perineal wound was healed within 3 months (RR 1.01; 95% CI 0.92–1.10; I<sup>2</sup> = 0%).<sup>4,6,22,23</sup>

**Specific Pelviperineal Complications**

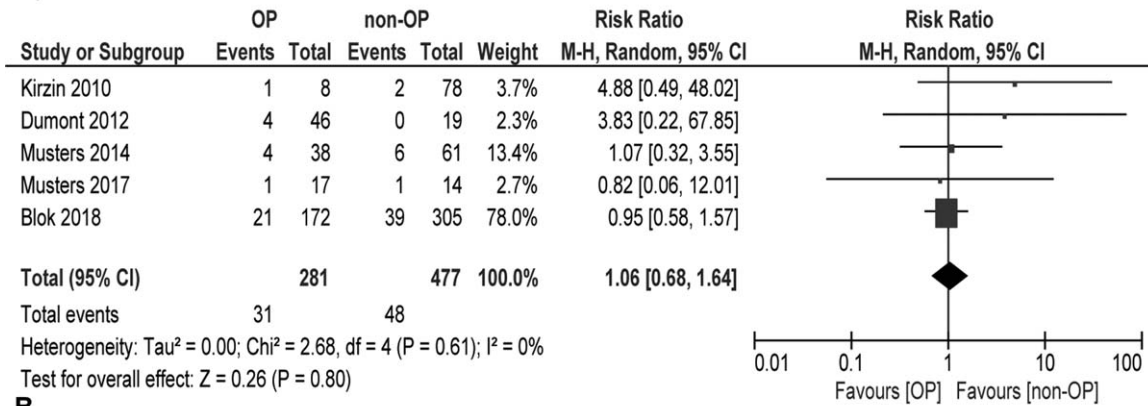
The pooled proportions of specific pelviperineal complications following OP are demonstrated in Supplementary Figure 2 (Supplemental Digital Content 6, <http://links.lww.com/SLA/B624>). After OP, the overall weighted mean incidence of wound dehiscence was 32.2% (95% CI 22.6%–43.5%),<sup>2,4,6,9,22–24,26–29</sup> which was 20.0% (95% CI 11.4%–32.9%) for superficial perineal infection,<sup>2,4,9,10,23–29</sup> 4.1% (95% CI 1.6%–10.5%) for hemorrhage,<sup>2,9,24</sup> and 8.0% (95% CI 5.1%–12.4%) for perineal sinus.<sup>2,4,6,9,22–24,28,29</sup> There were no statistically significant differences among patients with and without OP in terms of perineal wound dehiscence (RR 1.21; 95% CI 0.96–1.53; I<sup>2</sup> = 54%),<sup>2,4,6,9,22–24,26,28</sup> superficial perineal infection (RR 0.85; 95% CI 0.45–1.62; I<sup>2</sup> = 78%),<sup>2,4,9,10,23,24,26,28</sup> pelviperineal hemorrhage (RR 1.39; 95% CI 0.29–6.58; I<sup>2</sup> = 25%),<sup>2,9,24</sup> or chronic perineal sinus (RR 1.08; 95% CI 0.53–2.20; I<sup>2</sup> = 56%)<sup>2,4,6,9,22–24,28</sup> (Supplementary Figure 3, Supplemental Digital Content 7, <http://links.lww.com/SLA/B624>).

**Ileus**

Twelve studies recorded the incidence of ileus.<sup>2,4,6,9,10,23–29</sup> In the OP group, the overall weighted mean proportion of ileus was 7.8% (95% CI 4.2%–14.2%),<sup>2,4,9,10,23–26,29</sup> and 3.8% (95% CI 2.3%–6.2%) required reoperation for ileus.<sup>2,4,6,25,27–29</sup> Considering



**A**



**B**

**FIGURE 2.** Meta-analyses comparing presacral abscess formation between patients with and without omentoplasty in (A) all patients who underwent APR for malignancy, and (B) patients who underwent APR with primary perineal closure for nonlocally advanced rectal cancer.

8 comparative studies, overall incidence of ileus was not significantly different with or without OP (RR 0.90; 95% CI 0.62–1.31; I<sup>2</sup> = 0%),<sup>2,4,9,23,24,26</sup> nor the proportion of ileus requiring reoperation (RR 1.19; 95% CI 0.58–2.44; I<sup>2</sup> = 0%).<sup>2,4,6,28</sup>

**Perineal Hernia**

Twelve studies evaluated the incidence of perineal hernia.<sup>2,4,6,9,22,24–30</sup> The overall weighted mean proportion of perineal hernia was 8.9% (95% CI 5.7–13.7%) in those undergoing OP. Nine comparative studies recorded the incidence of perineal hernia.<sup>2,4,6,9,22,24,26,28,30</sup> The risk of perineal hernia was significantly increased in those submitted to OP compared with non-OP (RR 1.85; 95% CI 1.26–2.72; I<sup>2</sup> = 0%) (Fig. 3A). This association remained similar in those who underwent APR with primary perineal closure for nonlocally advanced disease (RR 1.83; 95% CI 1.17–2.87; I<sup>2</sup> = 0%) (Fig. 3B).<sup>2,4,6,24</sup>

**Omental Flap Complications**

Among 8 studies, the weighted mean proportion of OP-related complications was 4.6% (95% CI 2.5%–8.6%).<sup>2,4,9,10,25,27–29</sup> Specific complications of the OP included signs of inflammation of the

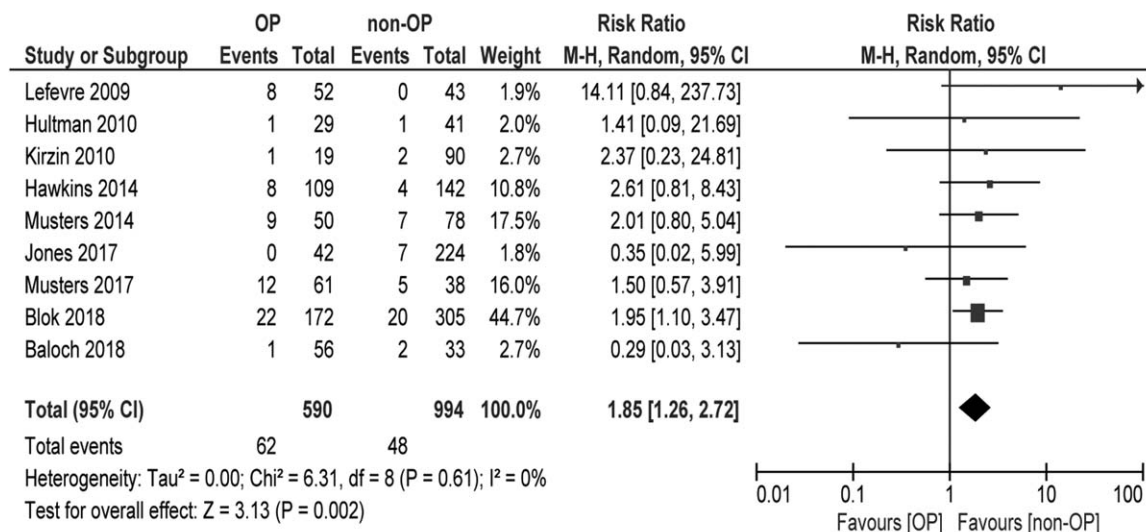
omentum (n = 1), partial omental necrosis (n = 1), total omental infarction (n = 1), perineal dehiscence with omental protrusion due to necrosis of the OP (n = 4), hemorrhagic shock due to bleeding of the gastro-epiploic artery (n = 1), and internal herniation of small bowel underneath the OP (n = 1).

**Surgical Reintervention**

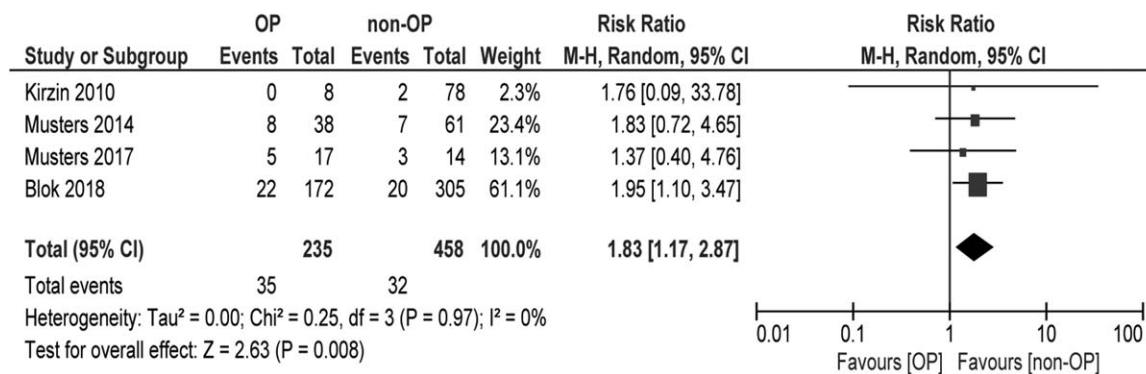
In 12 studies on OP, the overall weighted mean proportion of pelviperineal complications necessitating surgery (including hernia repair) was 12.6% (95% CI 9.0%–17.4%).<sup>2,4,6,9,10,22,23,25,27–30</sup> without significant difference between OP and non-OP (RR 1.06; 95% CI 0.80–1.42; I<sup>2</sup> = 0%).<sup>2,4,6,9,10,22,23,28,30</sup> Hernia repair tended to be more frequent in the OP group (RR 1.71; 95% CI 0.87–3.35; I<sup>2</sup> = 0%).<sup>2,4,6,28</sup> Problems related to the OP itself were reason for reoperation in 3.8% (95% CI 1.9%–7.6%).<sup>2,4,9,25,27,28</sup>

**DISCUSSION**

In the current literature review with mainly source patient data, we found no evidence to suggest that OP reduces pelviperineal abscess formation, nor that OP enhances perineal wound healing



**A**



**B**

**FIGURE 3.** Meta-analyses comparing perineal hernia development between patients with and without omentoplasty in (A) all patients who underwent APR for malignancy, and (B) patients who underwent APR with primary perineal closure for nonlocally advanced rectal cancer.

considering any other endpoint, or that OP reduces the risk of small bowel obstruction. Similarly, no beneficial effect of OP was found in planned subgroup analysis of patients who underwent APR with primary perineal closure for nonlocally advanced cancer, thereby likely reducing the risk of allocation bias. Furthermore, OP itself is associated with a small risk of complications and appears to be associated with perineal herniation.

The absence of any beneficial effects of OP as found in the present meta-analysis is in contrast to literature on autologous tissue flaps for perineal wound closure following APR.<sup>11,43</sup> In particular, the use of a VRAM flap is well established.<sup>8,30,44</sup> However, studies directly comparing muscle flaps and OP are scarce. A retrospective single institutional study by Lefevre et al<sup>30</sup>—which was included in the present review—found that VRAM flap closure was associated with less perineal morbidity, reduced healing time, and no perineal herniation (0% vs 15.4%; *P* = 0.0072) if compared with primary layered closure with OP. There are several potential explanations as to why OP is not associated with such favorable outcomes. Probably, the omentum is more likely to leave residual dead space, especially with thin patients. Furthermore, OP might have less robust blood supply after full mobilization, and compromised perfusion of an OP

is sometimes difficult to recognize intraoperatively. An OP with partial necrosis of the most distal parts, which are subsequently placed in the perineal wound, will likely counterbalance any beneficial effect in other patients. But in our opinion, the most crucial difference between OP and VRAM flap reconstruction is the filling of anal dead space. The muscle, fascia, subcutaneous fat, and skin of a VRAM flap are perfectly suited for the reconstruction of the pelvic floor and perineal defect, while an OP only consists of loose fatty tissue that does not provide any strength. OP mainly fills the presacral space, but the excised anal canal and sphincter complex seems to be the critical wound bed. The small bowel can fill the presacral space in the absence of an OP, as will occur after VRAM flap reconstruction.

Incidence of perineal hernia was around 10%, and is likely to even be an underestimation of the true incidence because of the retrospective design of most included studies. In meta-analysis, perineal hernia correlated significantly with the use of OP. This finding has recently been demonstrated in a nationwide study,<sup>6</sup> but was felt to be counterintuitive by some surgeons, and probably best explained by wider resections in the OP group. But this phenomenon may also be explained by the properties of an OP. As previously

mentioned, the fatty and nonfibrous omentum is not providing any strength to the neo-pelvic floor, and even puts continuous pressure on the perineal skin in a standing position. It is understandable that, in case of a bulky OP with a long vascular pedicle, such redundant bulk of fat is more likely to descend below the level of the pelvic floor than a few loops of small bowel that are often restricted by a certain mesenteric length. The omental fat is certainly more likely to result in perineal bulging than VRAM flap closure where muscle and fascia is added to the neo-pelvic floor.<sup>30</sup>

Two systematic reviews on the value of OP after APR have been published previously, both in contradiction with the current meta-analysis.<sup>45,46</sup> Compared with the review of Nilsson<sup>46</sup> only 1 study<sup>29</sup> is overlapping, and only three<sup>9,10,29</sup> out of 14 studies are overlapping with the review by Killeen et al.<sup>45</sup> Most of the older studies that were included in both previous reviews concern a small sample size and diversity regarding patient population and surgical methods, with only few comparative series. In addition, the rather historical studies have restricted generalizability, especially considering the less frequent use of preoperative radiotherapy. Strengths of the current review are restricted inclusion of publication since 2000, more comparative studies, and the use of primary source patient data, even if the original publication was not intended to study the effect of OP. Furthermore, benign pathology such as IBD was excluded, in contrast to the previous reviews. This resulted in more homogeneous patient populations with higher internal and external validity than previous systematic reviews published on the subject.<sup>45,46</sup> These methodological issues may explain the contradictory findings.

The main limitation of our study is the potential for a certain degree of allocation bias. In the absence of randomized controlled trials, it could be that surgeons selectively applied OP in those with a larger empty space after resection, and therefore an a priori greater risk of wound complications and hernia. To reduce potential confounding, a subgroup analysis was performed by excluding extended resections and additional reconstructive procedures. Even then, however, the potential for allocation bias cannot be excluded. A second limitation is that the definition of outcome variables in the source studies may be variable. In particular, the lack of a clear definition for presacral abscess and perineal hernia (ie, symptomatic perineal bulge or asymptomatic radiological finding) could potentially have influenced our results. However, reporting of perineal hernia was predominantly based on retrospective analysis of patient records, most likely not including small and asymptomatic radiological hernias. Also, total number of events was used for meta-analysis of perineal hernia, not properly taking into account the development of perineal hernia over time and differences among studies regarding duration of follow-up.

Based on the available literature, OP does not seem indicated for decreasing perineal wound complications after APR for cancer, nor does biological mesh closure.<sup>4</sup> Tissue transfer seems to have the greatest potential, but high-quality studies comparing muscle flap closure to other methods of perineal wound closure are warranted. Although VRAM flap closure has been effectively used in selective populations,<sup>8</sup> there remains the issue of donor and recipient site morbidity.<sup>43,47</sup> A smaller flap without donor site problems such as the perineal turnover flap<sup>48</sup> seems attractive. We are currently evaluating the effectiveness of a modified gluteal turnover flap<sup>49</sup> for routine use after APR, and we consider larger fascio-cutaneous gluteal or VRAM flaps only for the wider perineal defects with a high risk of sinus formation.

## CONCLUSIONS

In this systematic review and meta-analysis, that is reflecting current surgical practice of patients who are submitted to APR for malignant disease, we found no evidence to support the use of an OP

for reducing pelviperineal morbidity. Additionally, use of OP has an added risk of OP associated complications, and seems to be associated with the long-term likelihood of developing perineal hernia.

## ACKNOWLEDGMENTS

The authors thank Faridi S. van Etten (clinical librarian) for her help with developing the search strategy. The authors also appreciate the assistance of Susan van Dieren (clinical epidemiologist), who aided in the statistics of the study. Further, the authors greatly appreciate the efforts of multiple authors who provided additional information and discussed their data with us.

## REFERENCES

- Anderin C, Martling A, Lagergren J, et al. Short-term outcome after gluteus maximus myocutaneous flap reconstruction of the pelvic floor following extra-levator abdominoperineal excision of the rectum. *Colorectal Dis.* 2012;14:1060–1064.
- Musters GD, Buskens CJ, Bemelman WA, et al. Perineal wound healing after abdominoperineal resection for rectal cancer: a systematic review and meta-analysis. *Dis Colon Rectum.* 2014;57:1129–1139.
- Bullard KM, Trudel JL, Baxter NN, et al. Primary perineal wound closure after preoperative radiotherapy and abdominoperineal resection has a high incidence of wound failure. *Dis Colon Rectum.* 2005;48:438–443.
- Musters GD, Klaver CEL, Bosker RJI, et al. Biological mesh closure of the pelvic floor after extralevator abdominoperineal resection for rectal cancer: a multicenter randomized controlled trial (the BIOPEX-study). *Ann Surg.* 2017;265:1074–1081.
- Musters GD, Sloothaak DA, Roodbeen S, et al. Perineal wound healing after abdominoperineal resection for rectal cancer: a two-centre experience in the era of intensified oncological treatment. *Int J Colorectal Dis.* 2014;29:1151–1157.
- Blok RD, Musters GD, Borstlap WAA, et al. Snapshot study on the value of omentoplasty in abdominoperineal resection with primary perineal closure for rectal cancer. *Ann Surg Oncol.* 2018;25:729–736.
- Sayers AE, Patel RK, Hunter IA. Perineal hernia formation following extra-levator abdominoperineal excision. *Colorectal Dis.* 2015;17:351–355.
- Spasojevic M, Mariathasan AB, Goscinski M, et al. Vertical rectus abdominis musculocutaneous flap repair improves perineal wound healing after abdominoperineal resection for irradiated locally advanced rectal cancer. *Ann Surg Oncol.* 2018;25:1357–1365.
- Hultman CS, Sherrill MA, Halvorson EG, et al. Utility of the omentum in pelvic floor reconstruction following resection of anorectal malignancy: patient selection, technical caveats, and clinical outcomes. *Ann Plast Surg.* 2010;64:559–562.
- Oida T, Kawasaki A, Mimatsu K, et al. Omental packing with continuous suction drainage following abdominoperineal resection. *Hepatogastroenterology.* 2012;59:380–383.
- Devulapalli C, Jia Wei AT, DiBiaggio JR, et al. Primary versus flap closure of perineal defects following oncologic resection: a systematic review and meta-analysis. *Plast Reconstr Surg.* 2016;137:1602–1613.
- Butler CE, Gundeslioglu AO, Rodriguez-Bigas MA. Outcomes of immediate vertical rectus abdominis myocutaneous flap reconstruction for irradiated abdominoperineal resection defects. *J Am Coll Surg.* 2008;206:694–703.
- Van Vugt E, Van Rijthoven EA, Kamperdijk EW, et al. Omental milky spots in the local immune response in the peritoneal cavity of rats. *Anat Rec.* 1996;244:235–245.
- Chandra A, Srivastava RK, Kashyap MP, et al. The anti-inflammatory and antibacterial basis of human omental defense: selective expression of cytokines and antimicrobial peptides. *PLoS One.* 2011;6:e20446.
- Meza-Perez S, Randall TD. Immunological functions of the omentum. *Trends Immunol.* 2017;38:526–536.
- Settembre N, Labrousse M, Magnan PE, et al. Surgical anatomy of the right gastro-omental artery: a study on 100 cadaver dissections. *Surg Radiol Anat.* 2018;40:415–422.
- Moher D, Liberati A, Tetzlaff J, et al. Preferred reporting items for systematic reviews and meta-analyses: the PRISMA statement. *Int J Surg.* 2010;8:336–341.
- Higgins JP, Altman DG, Gotzsche PC, et al. The Cochrane Collaboration's tool for assessing risk of bias in randomised trials. *BMJ.* 2011;343:d5928.
- Wells GA SB, O'Connell D, Peterson J, et al. The Newcastle-Ottawa Scale (NOS) for assessing the quality of nonrandomised studies in meta-analyses. Available at: [http://www.ohri.ca/programs/clinical\\_epidemiology/oxford.asp](http://www.ohri.ca/programs/clinical_epidemiology/oxford.asp) Accessed February 23, 2017.



20. Wan X, Wang W, Liu J, et al. Estimating the sample mean and standard deviation from the sample size, median, range and/or interquartile range. *BMC Med Res Methodol*. 2014;14:135.
21. Higgins JP, Thompson SG, Deeks JJ, et al. Measuring inconsistency in meta-analyses. *BMJ*. 2003;327:557–560.
22. Baloch N, Nilsson PJ, Nordenvall C, et al. Perineal wound closure using biological mesh following extralevator abdominoperineal excision. *Dig Surg*. 2018;1–8. doi: 10.1159/000489134. [Epub ahead of print].
23. Dumont F, Souadka A, Goere D, et al. Impact of perineal pseudocontinent colostomy on perineal wound healing after abdominoperineal resection. *J Surg Oncol*. 2012;105:628–631.
24. Kirzin S, Lazorthes F, Nouaille de Gorce H, et al. Benefits of perineal colostomy on perineal morbidity after abdominoperineal resection. *Dis Colon Rectum*. 2010;53:1265–1271.
25. Hardt J, Mai S, Weiss C, et al. Abdominoperineal resection and perineal wound healing in recurrent, persistent, or primary anal carcinoma. *Int J Colorectal Dis*. 2016;31:1197–1203.
26. Hawkins AT, Berger DL, Shellito PC, et al. Wound dehiscence after abdominoperineal resection for low rectal cancer is associated with decreased survival. *Dis Colon Rectum*. 2014;57:143–150.
27. Hellinga J, Khoe PC, van Etten B, et al. Fasciocutaneous lotus petal flap for perineal wound reconstruction after extralevator abdominoperineal excision: application for reconstruction of the pelvic floor and creation of a neovagina. *Ann Surg Oncol*. 2016;23:4073–4079.
28. Jones H, Moran B, Crane S, et al. The LOREC APE registry: operative technique, oncological outcome and perineal wound healing after abdominoperineal excision. *Colorectal Dis*. 2017;19:172–180.
29. De Broux E, Parc Y, Rondelli F, et al. Sutured perineal omentoplasty after abdominoperineal resection for adenocarcinoma of the lower rectum. *Dis Colon Rectum*. 2005;48:476–481.
30. Lefevre JH, Parc Y, Kerneis S, et al. Abdomino-perineal resection for anal cancer: impact of a vertical rectus abdominis myocutaneous flap on survival, recurrence, morbidity, and wound healing. *Ann Surg*. 2009;250:707–711.
31. Ghouti L, Houvenaeghel G, Moutardier V, et al. Salvage abdominoperineal resection after failure of conservative treatment in anal epidermoid cancer. *Dis Colon Rectum*. 2005;48:16–22.
32. Lefevre JH, Corte H, Tiret E, et al. Abdominoperineal resection for squamous cell anal carcinoma: survival and risk factors for recurrence. *Ann Surg Oncol*. 2012;19:4186–4192.
33. Mariani P, Ghanneme A, De la Rochefordiere A, et al. Abdominoperineal resection for anal cancer. *Dis Colon Rectum*. 2008;51:1495–1501.
34. Melton GB, Paty PB, Boland PJ, et al. Sacral resection for recurrent rectal cancer: analysis of morbidity and treatment results. *Dis Colon Rectum*. 2006;49:1099–1107.
35. Stelzner S, Hellmich G, Sims A, et al. Long-term outcome of extralevator abdominoperineal excision (ELAPE) for low rectal cancer. *Int J Colorectal Dis*. 2016;31:1729–1737.
36. Walma MS, Burbach JP, Verheijen PM, et al. Vacuum-assisted closure therapy for infected perineal wounds after abdominoperineal resection. A retrospective cohort study. *Int J Surg*. 2016;26:18–24.
37. Welsch T, Mategakis V, Contin P, et al. Results of extralevator abdominoperineal resection for low rectal cancer including quality of life and long-term wound complications. *Int J Colorectal Dis*. 2013;28:503–510.
38. Bell SW, Dehni N, Chaouat M, et al. Primary rectus abdominis myocutaneous flap for repair of perineal and vaginal defects after extended abdominoperineal resection. *Br J Surg*. 2005;92:482–486.
39. Dalton RS, Smart NJ, Edwards TJ, et al. Short-term outcomes of the prone perineal approach for extra-levator abdomino-perineal excision (eAPE). *Surgeon*. 2012;10:342–346.
40. Ferenschild FT, Vermaas M, Hofer SO, et al. Salvage abdominoperineal resection and perineal wound healing in local recurrent or persistent anal cancer. *World J Surg*. 2005;29:1452–1457.
41. Peacock O, Simpson JA, Tou SI, et al. Outcomes after biological mesh reconstruction of the pelvic floor following extra-levator abdominoperineal excision of rectum (APER). *Tech Coloproctol*. 2014;18:571–577.
42. Habr-Gama A, Sao Juliao GP, Mattacheo A, et al. Extralevator abdominal perineal excision versus standard abdominal perineal excision: impact on quality of the resected specimen and postoperative morbidity. *World J Surg*. 2017;41:2160–2167.
43. Yang XY, Wei MT, Yang XT, et al. Primary vs myocutaneous flap closure of perineal defects following abdominoperineal resection for colorectal disease: a systematic review and meta-analysis. *Colorectal Dis*. 2018;21:138–155.
44. Johnstone MS. Vertical rectus abdominis myocutaneous versus alternative flaps for perineal repair after abdominoperineal excision of the rectum in the era of laparoscopic surgery. *Ann Plast Surg*. 2017;79:101–106.
45. Killeen S, Devaney A, Mannion M, et al. Omental pedicle flaps following proctectomy: a systematic review. *Colorectal Dis*. 2013;15:e634–e645.
46. Nilsson PJ. Omentoplasty in abdominoperineal resection: a review of the literature using a systematic approach. *Dis Colon Rectum*. 2006;49:1354–1361.
47. Foster JD, Tou S, Curtis NJ, et al. Closure of the perineal defect after abdominoperineal excision for rectal adenocarcinoma—ACPGBI Position Statement. *Colorectal Dis*. 2018;20(suppl 5):5–23.
48. Chasapi M, Maher M, Mitchell P, et al. The perineal turnover perforator flap: a new and simple technique for perineal reconstruction after extralevator abdominoperineal excision. *Ann Plast Surg*. 2018;80:395–399.
49. Blok RD, Lapid O, Bemelman WA, et al. Gluteal transposition flap without donor site scar for closing a perineal defect after abdominoperineal resection. *Tech Coloproctol*. 2016;21:155–157.