

Short Communication

Cite this article: Sarink MJ, Koelewijn R, Slingerland BCGC, Tielens AGM, van Genderen PJJ, van Hellemond JJ (2019). Performance of the commercially available SERION ELISA classic *Echinococcus* IgG test for the detection of cystic echinococcosis in clinical practice. *Journal of Helminthology* **93**, 636–639. <https://doi.org/10.1017/S0022149X18000536>

Received: 5 March 2018
Accepted: 8 June 2018
First published online: 28 June 2018

Key words:

cystic echinococcosis; diagnosis; *Echinococcus granulosus*; ELISA; serology

Author for correspondence:

J.J. van Hellemond, Fax.: + 31 10 703 3875,
E-mail: j.vanhellemond@erasmusmc.nl

Performance of the commercially available SERION ELISA classic *Echinococcus* IgG test for the detection of cystic echinococcosis in clinical practice

M.J. Sarink¹, R. Koelewijn¹, B.C.G.C. Slingerland¹, A.G.M. Tielens^{1,2},
P.J.J. van Genderen³ and J.J. van Hellemond¹

¹Department of Medical Microbiology and Infectious Diseases, Erasmus University Medical Center, 's Gravendijkwal 230, Rotterdam, the Netherlands; ²Department of Biochemistry and Cell Biology, Faculty of Veterinary Medicine, Utrecht University, Utrecht, the Netherlands and ³Harbor Hospital and Institute of Tropical Diseases, Haringvliet 2, Rotterdam, the Netherlands

Abstract

Diagnosis of cystic echinococcosis (CE) is at present mainly based on imaging techniques. Serology has a complementary role, partly due to the small number of standardized and commercially available assays. Therefore we examined the clinical performance of the SERION ELISA classic *Echinococcus* IgG test. Using 10 U/ml as a cut-off point, and serum samples from 50 CE patients and 105 healthy controls, the sensitivity and specificity were 98.0% and 96.2%, respectively. If patients with other infectious diseases were used as negative controls, the specificity decreased to 76.9%, which causes poor positive predictive values. However, if results between 10 and 15 U/ml are classified as indecisive, the specificity of positive results (≥ 15 U/ml) increased to 92.5% without greatly affecting the sensitivity (92.0%). Using this approach in combination with imaging studies, the SERION ELISA classic *Echinococcus* IgG test can be a useful aid in the diagnosis of CE.

Introduction

Cystic echinococcosis (CE) is a severe zoonotic disease caused by the cestode species *Echinococcus granulosus*, which affects livestock, wildlife and humans. The burden of CE is estimated to cause up to 1 million disability-adjusted life years and an annual loss of up to USD 2 billion in livestock production (Budke *et al.*, 2006; Torgerson *et al.*, 2015). When eggs of *E. granulosus* are ingested by humans or another intermediate host, oncospheres hatch and penetrate the intestinal mucosa. Migration to internal organs such as the liver follows, where subsequently a fluid-filled cyst develops (Eckert *et al.*, 2001). In general, only large cysts are able to induce clinical symptoms in humans. As a consequence, most human CE cases are found incidentally during imaging examinations made for other reasons or during community screenings in endemic regions (Ammann and Eckert, 1996; Del Carpio *et al.*, 2012).

Imaging modalities, including ultrasonography (US), CT and MRI, are important for the diagnosis of CE, which is standardized by the World Health Organization Informal Working Group on Echinococcosis in the classification of CE cysts (WHO Informal Working Group, 2003). Classification, staging, identification of possible complications and treatment response are often evaluated with the use of these imaging techniques (Polat *et al.*, 2003). Determination of specific antibodies against *E. granulosus* has only a complementary role in the diagnosis of CE, because all serology tests for CE have an implicit low specificity due to cross-reactions with a plethora of diseases (Brunetti *et al.*, 2010). However, serology can provide valuable information if imaging studies are inconclusive (Brunetti *et al.*, 2010). Furthermore, serological response in human disease has been linked to CE-cyst stage, as patients with CE1 and CE4–CE5 cysts tend to be seronegative in a high percentage of cases, whereas patients with CE2 and CE3 cysts are often seropositive (Lissandrin *et al.*, 2016).

Most available serological methods to detect CE lack standardization, which prevents their use as a robust diagnostic tool for CE (Manzano-Roman *et al.*, 2015). Furthermore, the quality of commercially available ELISAs has been studied infrequently and results are rather variable, as the reported sensitivity (Se) and specificity (Sp) of these ELISAs varied from 69.5–93.14% and 76.0–98.42%, respectively (Kalantari *et al.*, 2010; Marinova *et al.*, 2011; Tamarozzi *et al.*, 2013, 2016; Tamer *et al.*, 2015; Pagnozzi *et al.*, 2016). Additionally, most studies on commercial ELISAs for detection of CE have focused on healthy controls and a wide range of infectious disease controls (Kalantari *et al.*, 2010; Marinova *et al.*, 2011; Tamer *et al.*, 2015), hepatic

© Cambridge University Press 2018. This is an Open Access article, distributed under the terms of the Creative Commons Attribution licence (<http://creativecommons.org/licenses/by/4.0/>), which permits unrestricted re-use, distribution, and reproduction in any medium, provided the original work is properly cited.

cyst controls (Tamarozzi *et al.*, 2016), or comparison with locally developed ELISAs (Tamarozzi *et al.*, 2013; Pagnozzi *et al.*, 2016). In these studies, cross-reactivity with helminth infections has been described, but not studied extensively. In order to extend the knowledge on both the clinical performance of commercially available serological assays to detect CE, and infectious diseases that cause cross-reactivity in these serological assays, we examined the SERION ELISA *classic* Echinococcus IgG test.

Materials and methods

Serum samples

The present study included serum samples from 50 patients with CE that presented at the Harbor Hospital in Rotterdam, The Netherlands. The diagnosis of CE was proven either by microscopic analysis of obtained cyst fluid ($n = 8$) or by characteristic abnormalities in diagnostic imaging (ultra-sound echography, CT-scan and/or MRI-scan) in combination with the demonstration of specific antibodies against *Echinococcus* spp. ($n = 42$). The presence of specific antibodies against *Echinococcus* species was demonstrated by two or more of the following tests: indirect haemagglutination (IHA, Fumouze, France), ELISA using *E. granulosus* cyst fluid antigen, IgG1 and IgG4 Western blot, immunoelectrophoresis (IE) or complement binding reaction tests (CBR) (supplementary table S1). Apart from the commercially available indirect haemagglutination assay (van Doorn *et al.*, 2007), all other assays were in-house developed tests by the Dutch referral centre for echinococcosis, the National Institute for Public Health and the Environment (Bilthoven, the Netherlands). Based on these imaging and serological results in combination with clinical follow-up, the final diagnosis of CE was made by a multidisciplinary team of clinicians, including infectious disease, surgery, parasitology and radiology specialists.

Serum samples from 105 healthy German blood donors were used as healthy controls, and sera from 173 patients were included to test for cross-reactivity. The latter group included samples from patients with several helminthiases (ascariasis, hookworm infection, larva migrans infection, schistosomiasis, strongyloidiasis, toxocarasis and trichuriasis), bacterial infections (campylobacteriosis, rickettsiosis, salmonellosis, shigellosis, shiga toxin-producing *Escherichia coli* (STEC) infection, syphilis, typhoid fever) and other infectious diseases (dengue fever, *P. falciparum*).

SERION ELISA *classic* Echinococcus IgG test

The CE-marked SERION ELISA *classic* Echinococcus IgG test was performed manually according to the manufacturer's instructions (Institut Virion/Serion GmbH, Würzburg). The antigen is based on cyst fluid of *Echinococcus granulosus*. SERION ELISA *classic* Echinococcus IgG is a qualitative and quantitative immunoassay for detection of human antibodies directed against *Echinococcus granulosus* and *Echinococcus multilocularis*. This study, however, investigated only the clinical performance for the detection of *E. granulosus* specific antibodies.

All serum samples were examined in duplicate. Optical density (OD) signals were converted to IgG antibody concentrations (U/ml) by a non-linear function. The quantification is based on the 4PL method, which optimizes accuracy and precision over the maximal usable calibration range. Lot-specific 4 PL standard curves for each SERION ELISA immunoassay are established and four parameters are depicted on the control certificate. Test

level is adjusted by implementing a correction factor, and the use of a single test-specific calibrator compensates for inter-assay variations (1-Point Calibration). *Echinococcus* specific IgG concentration results were processed in Graphpad 7.0.

Results and discussion

Sensitivity and specificity of SERION ELISA *classic* Echinococcus IgG test

Forty-nine of the 50 serum samples from CE patients yielded a result above the strict diagnostic threshold of 10.0 U/ml. Of the 105 tested samples of the healthy controls, four samples tested positive using this cut-off. Sensitivity and specificity calculated with these groups were 98.0% and 96.2%, respectively (table 1). Outcomes of our other serological tests are presented in supplementary table S1. Our results suggest that the SERION ELISA *classic* Echinococcus IgG test performs adequately, with characteristics at least comparable to other serological methods for CE (Se 69.5–93.14% , Sp 76.0–98.42%) (Kalantari *et al.*, 2010; Marinova *et al.*, 2011; Tamarozzi *et al.*, 2013, 2016; Tamer *et al.*, 2015; Pagnozzi *et al.*, 2016).

Cross-reactivity

In clinical practice, the reference population is one with a variety of possible infectious diseases, with its inherent risk of cross-reactivity. For this reason an additional control group of patients with infectious diseases other than CE was introduced. When this group was used as a negative control, the specificity of the assay decreased to 76.9% if the cut-off of 10.0 U/ml was used (table 1). Cross-reactivity was seen in 23.1% of the sera of the infectious diseases control group. When the infectious diseases were divided into subgroups, cross-reactivity was shown in 34.1% of the patients with helminthiases, whereas cross-reactivity was found in 7.8% of the tested sera of patients with bacterial infections. In particular, high cross-reactivity was present in sera from patients with strongyloidiasis, with positive SERION ELISA *classic* Echinococcus IgG test results in 11 out of 12 patients (91.7%). This high percentage of cross-reactivity in patients with helminth infections was also reported in other studies that evaluated an ELISA for the detection of CE (Brunetti *et al.*, 2010; Marinova *et al.*, 2011; Tamer *et al.*, 2015). It is possible that the high cross-reactivity may be partially due to actual, but so far unnoticed, CE infections in patients allocated within the other helminth infections group, as regions where CE is endemic overlap with regions where other helminth infections are endemic.

The prevalence of CE varies widely between geographical areas, with very low prevalence in northern and central European countries and high endemicity in areas of southern and eastern Europe (Grosso *et al.*, 2012). If a test with a specificity of 76.9% in a clinical control group is used, the positive predictive value (PPV) of this test will be poor (Torgerson and Deplazes, 2009). However, when an additional classification is made to distinguish indecisive results, the specificity, and with it the PPV, can be improved (see below).

Classification of indecisive results

Most sera with cross-reacting antibodies were only weakly positive, with levels just above 10.0 U/ml (fig. 1). Therefore, when an additional classification was applied, marking test results

Table 1. Sensitivity and specificity of the SERION ELISA *classic* Echinococcus IgG test according to respective control groups. CE, Cystic echinococcosis; Pos, Positive; Neg, Negative; Indec, Indecisive; Co, Cut-off.

| | Patients with CE | | Control samples | | | |
|-------------------------------|------------------|-----------------|------------------|-----------------|-----------------------------|-----------------|
| | No. of samples | Sensitivity (%) | Healthy controls | | Infectious disease controls | |
| | No. of samples | Sensitivity (%) | No. of samples | Specificity (%) | No. of samples | Specificity (%) |
| Pos (Co \geq 10.0) | 49 | 98.0 | 4 | | 40 | |
| Neg (Co < 10.0) | 1 | | 101 | 96.2 | 133 | 76.9 |
| Pos (Co \geq 15.0) | 46 | 92.0 | 3 | | 13 | |
| Indec (10.0 \leq Co < 15.0) | 3 | | 1 | | 27 | |
| Neg (Co < 10.0) | 1 | | 101 | 97.1 | 133 | 92.5 |

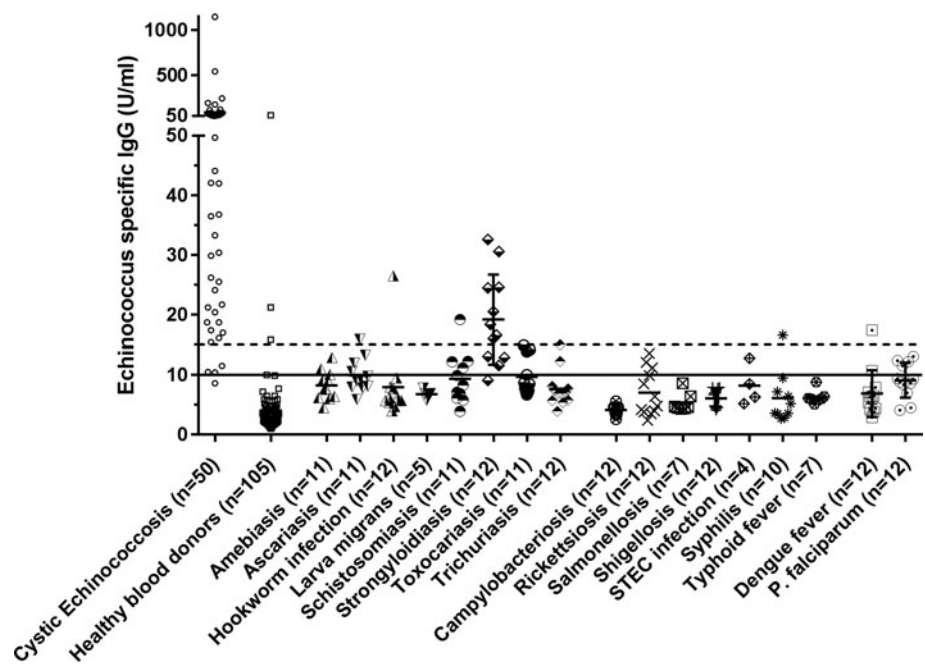


Fig. 1. Concentrations of *Echinococcus* specific IgG in the various study groups. Each marker represents the average of one serum sample tested in duplicate. The solid line at 10 U/ml represents the lower cut-off value. The dashed line at 15 U/ml represents the higher cut-off value. The indecisive zone is situated between the solid and the dashed lines.

between 10 and 15 U/ml as indecisive, this improved the specificity of the test. When healthy blood donors were used as negative controls, the sensitivity and specificity of positive test results (≥ 15 U/ml) were 92.0% and 97.1%, respectively. When the other infectious diseases were used as negative controls, with the same threshold of 15 U/mL, specificity increased from 76.9% (with a cut-off of 10 U/ml) to 92.5%, with a sensitivity of 92.0%. A substantial number of serum samples from the infectious diseases control group that were deemed positive with the strict cut-off of 10 U/ml were reallocated to the indecisive section ($n = 26$; 65.0%), whereas only a few samples from patients with CE were reallocated ($n = 3$; 6.1%). This improvement in specificity has a positive effect on the PPV of the test, which is especially important when the prevalence of a disease is very low. Therefore, the use of an indecisive section will improve test properties considerably when used in areas with a low prevalence of CE, such as northern and western Europe. Although the test properties of the SERION ELISA *classic* Echinococcosis IgG are adequate, it is always essential to

perform imaging studies, as this improves the PPV substantially (Torgerson and Deplazes, 2009).

Limitations

One constraint of our study is that the definitive diagnosis of CE for the majority of cases was made by a multidisciplinary team of experts based on clinical findings, imaging and serology, whereas other studies used microscopic verification. However, the combination of clinical findings, imaging, serology and expert opinion is currently the standard to diagnose CE, and clinical follow-up did not reveal misdiagnosis in any of the cases included in this study.

Clinical interpretation

In conclusion, our results demonstrated that the SERION ELISA *classic* Echinococcus IgG test possesses characteristics comparable to other serological methods and can be used in clinical practice to aid in diagnosing CE. In low-prevalence settings we recommend

the following cut-off values for interpretation: negative (<10 U/ml), indecisive (≥ 10 and <15 U/ml) and positive (≥ 15 U/ml). Clinical interpretation of this test, as well as all other serological methods for CE, should always be performed in combination with imaging studies, as false-negative serology results are often obtained for patients with fully calcified cysts (Lissandrin *et al.*, 2016) and false-positive serology results can be caused by other (helminth) infections (Tamarozzi *et al.*, 2013; Pagnozzi *et al.*, 2016).

Supplementary material. To view supplementary material for this article, please visit <https://doi.org/10.1017/S0022149X18000536>

Acknowledgements. We thank Titia Kortbeek (MD, National Institute for Public Health and the Environment, Bilthoven, the Netherlands) for providing technical and interpretation details of the serological methods employed by the Dutch referral centre for echinococcosis to which the patient sera were sent at the time of clinical presentation.

Financial support. This study was supported by Institut Virion\Serion GmbH through supplying the test kits for evaluation, and financial compensation for the labour involved in evaluation of cross-reactivity with other infectious diseases. Institut Virion\Serion GmbH had no role in analysis and interpretation of data, in the writing of the report, or in the decision to submit the article for publication.

Conflict of interest. None.

Ethical standards. Ethical clearance for the storage and use of residual serum samples for scientific purposes was granted by the Medical Ethics Review Board of the Erasmus University Medical Center Rotterdam, the Netherlands (MEC 2012-047 and MEC-2015-306).

References

- Ammann RW and Eckert J** (1996) Cestodes. Echinococcus. *Gastroenterology Clinics of North America* **25**, 655–689.
- Brunetti E et al.** (2010) Expert consensus for the diagnosis and treatment of cystic and alveolar echinococcosis in humans. *Acta Tropica* **114**, 1–16.
- Budke CM, Deplazes P and Torgerson PR** (2006) Global socioeconomic impact of cystic echinococcosis. *Emerging Infectious Diseases* **12**, 296–303.
- Del Carpio M et al.** (2012) Early diagnosis, treatment and follow-up of cystic echinococcosis in remote rural areas in Patagonia: impact of ultrasound training of non-specialists. *PLoS Neglected Tropical Diseases* **6**, e1444.
- Eckert J et al.** (2001) *WHO/OIE Manual on Echinococcosis in Humans and Animals: A Public Health Problem of Global Concern*. World Organisation for Animal Health (Office International des Epizooties), Paris, France, and World Health Organization, Geneva, Switzerland.
- Grosso G et al.** (2012) Worldwide epidemiology of liver hydatidosis including the Mediterranean area. *World Journal of Gastroenterology* **18**, 1425–1437.
- Kalantari E et al.** (2010) Application of recombinant *Echinococcus granulosus* antigen B to ELISA kits for diagnosing hydatidosis. *Parasitology Research* **106**, 847–851.
- Lissandrin R et al.** (2016) Factors influencing the serological response in hepatic *Echinococcus granulosus* infection. *The American Journal of Tropical Medicine and Hygiene* **94**, 166–171.
- Manzano-Roman R et al.** (2015) Serological diagnosis and follow-up of human cystic echinococcosis: a new hope for the future? *BioMed Research International* **2015**, 428205.
- Marinova I et al.** (2011) Quantitative assessment of serum-specific IgE in the diagnosis of human cystic echinococcosis. *Parasite Immunology* **33**, 371–376.
- Pagnozzi D et al.** (2016) Diagnostic accuracy of antigen 5-based ELISAs for human cystic echinococcosis. *PLoS Neglected Tropical Diseases* **10**, e0004585.
- Polat P et al.** (2003) Hydatid disease from head to toe. *RadioGraphics* **23**, 475–494.
- Tamarozzi F et al.** (2013) Recombinant AgB8/1 ELISA test vs. commercially available IgG ELISA test in the diagnosis of cystic echinococcosis. *Parasite Immunology* **35**, 433–440.
- Tamarozzi F et al.** (2016) Comparison of the diagnostic accuracy of three rapid tests for the serodiagnosis of hepatic cystic echinococcosis in humans. *PLoS Neglected Tropical Diseases* **10**, e0004444.
- Tamer GS et al.** (2015) Evaluation of immunochromatographic test for the detection of antibodies against *Echinococcus granulosus*. *Medical Science Monitor* **21**, 1219–1222.
- Torgerson PR and Deplazes P** (2009) Echinococcosis: diagnosis and diagnostic interpretation in population studies. *Trends in Parasitology* **25**, 164–170.
- Torgerson PR et al.** (2015) World Health Organization estimates of the global and regional disease burden of 11 foodborne parasitic diseases, 2010: a data synthesis. *PLoS Medicine* **12**, e1001920.
- van Doorn HR et al.** (2007) Reliable serodiagnosis of imported cystic echinococcosis with a commercial indirect hemagglutination assay. *Diagnostic Microbiology and Infectious Disease* **57**, 409–412.
- WHO Informal Working Group** (2003) International classification of ultrasound images in cystic echinococcosis for application in clinical and field epidemiological settings. *Acta Tropica* **85**, 253–261.