

Circulation

JOURNAL OF THE AMERICAN HEART ASSOCIATION



TAXUS III Trial: In-Stent Restenosis Treated With Stent-Based Delivery of Paclitaxel Incorporated in a Slow-Release Polymer Formulation

Kengo Tanabe, Patrick W. Serruys, Eberhard Grube, Pieter C. Smits, Guido Selbach, Willem J. van der Giessen, Manfred Staberock, Pim de Feyter, Ralf Müller, Evelyn Regar, Muzaffer Degertekin, Jurgen M.R. Ligthart, Clemens Disco, Bianca Backx and Mary E. Russell

Circulation 2003;107;559-564; originally published online Jan 13, 2003;

DOI: 10.1161/01.CIR.0000048184.96491.8A

Circulation is published by the American Heart Association, 7272 Greenville Avenue, Dallas, TX 72514

Copyright © 2003 American Heart Association. All rights reserved. Print ISSN: 0009-7322. Online ISSN: 1524-4539

The online version of this article, along with updated information and services, is located on the World Wide Web at:

<http://circ.ahajournals.org/cgi/content/full/107/4/559>

Subscriptions: Information about subscribing to *Circulation* is online at
<http://circ.ahajournals.org/subscriptions/>

Permissions: Permissions & Rights Desk, Lippincott Williams & Wilkins, 351 West Camden Street, Baltimore, MD 21202-2436. Phone 410-5280-4050. Fax: 410-528-8550. Email:
journalpermissions@lww.com

Reprints: Information about reprints can be found online at
<http://www.lww.com/static/html/reprints.html>

TAXUS III Trial

In-Stent Restenosis Treated With Stent-Based Delivery of Paclitaxel Incorporated in a Slow-Release Polymer Formulation

Kengo Tanabe, MD; Patrick W. Serruys, MD, PhD; Eberhard Grube, MD; Pieter C. Smits, MD, PhD; Guido Selbach, MD; Willem J. van der Giessen, MD, PhD; Manfred Staberock, MD; Pim de Feyter, MD, PhD; Ralf Müller, MD; Evelyn Regar, MD; Muzaffer Degertekin, MD; Jurgen M.R. Ligthart, MSc; Clemens Disco, MSc; Bianca Backx, PhD; Mary E. Russell, MD

Background—The first clinical study of paclitaxel-eluting stent for de novo lesions showed promising results. We performed the TAXUS III trial to evaluate the feasibility and safety of paclitaxel-eluting stent for the treatment of in-stent restenosis (ISR).

Methods and Results—The TAXUS III trial was a single-arm, 2-center study that enrolled 28 patients with ISR meeting the criteria of lesion length ≤ 30 mm, 50% to 99% diameter stenosis, and vessel diameter 3.0 to 3.5 mm. They were treated with one or more TAXUS NIRx paclitaxel-eluting stents. Twenty-five patients completed the angiographic follow-up at 6 months, and 17 of these underwent intravascular ultrasound (IVUS) examination. No subacute stent thrombosis occurred up to 12 months, but there was one late chronic total occlusion, and additional 3 patients showed angiographic restenosis. The mean late loss was 0.54 mm, with neointimal hyperplasia volume of 20.3 mm³. The major adverse cardiac event rate was 29% (8 patients; 1 non-Q-wave myocardial infarction, 1 coronary artery bypass grafting, and 6 target lesion revascularization [TLR]). Of the patients with TLR, 1 had restenosis in a bare stent implanted for edge dissection and 2 had restenosis in a gap between 2 paclitaxel-eluting stents. Two patients without angiographic restenosis underwent TLR as a result of the IVUS assessment at follow-up (1 incomplete apposition and 1 insufficient expansion of the stent).

Conclusions—Paclitaxel-eluting stent implantation is considered safe and potentially efficacious in the treatment of ISR. IVUS guidance to ensure good stent deployment with complete coverage of target lesion may reduce reintervention. (*Circulation*. 2003;107:559-564.)

Key Words: stents ■ restenosis ■ drugs

The development of coronary stents has revolutionized the field of interventional cardiology by reducing the incidence of restenosis after balloon angioplasty.^{1,2} With the widespread clinical use of coronary stents, in-stent restenosis (ISR) has become the most challenging problem.³ Previous pharmacological and mechanical approaches have shown disappointing results in eliminating this iatrogenic disease. Presently, intravascular brachytherapy is the only treatment for ISR proven to be effective in clinical randomized trials.⁴⁻⁶ Brachytherapy requires special handling and is hampered by potential issues such as edge restenosis,^{7,8} late thrombosis,⁹ geographical miss,¹⁰ late stent malapposition,¹¹ persisting dissection,^{12,13} and positive vascular remodeling after treatment.^{14,15}

Stent-based local drug delivery is expected to cause a revolutionary change in the field of percutaneous interven-

tion, with recent clinical trials of paclitaxel or sirolimus-eluting stents demonstrating promising results in the treatment of de novo lesions.¹⁶⁻¹⁹ Paclitaxel is a microtubule inhibitor presently used to treat several kinds of cancer, most commonly breast and ovarian. Microtubular dynamics regulate many of the inflammatory and profibrotic steps implicated in the restenotic cascade. This agent has been reported to reduce vascular cell proliferation and migration in vitro and in vivo.²⁰⁻²³ In accordance with these experimental results, paclitaxel-eluting stents for de novo lesions showed no restenosis in the TAXUS I feasibility trial.¹⁶ However, it has not been established whether this is applicable to a more complex patient group, such as patients with ISR. The TAXUS III trial is a single-arm, 2-center study aiming to evaluate the feasibility and safety of this eluting stent for the treatment of ISR.

Received July 29, 2002; revision received October 22, 2002; accepted October 22, 2002.

From the Division of Cardiology (K.T., P.W.S., P.C.S., W.J.G., P.F., E.R., M.D., J.M.R.L.), Thoraxcenter, Erasmus MC, Rotterdam, the Netherlands; Department of Cardiology/Angiology (E.G., G.S., M.S., R.M.), Heart Center Siegburg, Siegburg, Germany; Cardialysis BV (C.D., B.B.), Rotterdam, the Netherlands; and Boston Scientific Corporation (M.E.R.), Natick, Mass.

Correspondence to P.W. Serruys, MD, PhD; Thoraxcenter, Bd 408, Erasmus MC, Dr Molewaterplein 40, 3015GD, Rotterdam, the Netherlands. E-mail serruys@card.azr.nl

© 2003 American Heart Association, Inc.

Circulation is available at <http://www.circulationaha.org>

DOI: 10.1161/01.CIR.0000048184.96491.8A

Methods

Patient Selection

Patients were eligible if they had ISR of a native coronary artery with objective evidence of ischemia. Angiographic inclusion criteria were lesion length ≤ 30 mm, 50% to 99% diameter stenosis, and vessel diameter between 3.0 and 3.5 mm. Patients were excluded if they had an acute myocardial infarction, left ventricular ejection fraction $< 30\%$, stroke within the last 6 months, a renal dysfunction (serum creatinine > 1.7 $\mu\text{g}/100$ mL), or a contraindication to aspirin, clopidogrel, or ticlopidine. Between May 2001 and August 2001, patients were enrolled in two centers (Thoraxcenter, Rotterdam, the Netherlands, and Heart Center Siegburg, Siegburg, Germany). All patients gave written informed consent. The study was reviewed and approved by both institutions' ethics review committees.

Procedure

The stent used in the study was the TAXUS NIRx paclitaxel-eluting stent (Boston Scientific Corporation), with a total load of 1.0 $\mu\text{g}/\text{mm}^2$ of paclitaxel incorporated into a slow-release copolymer carrier system that gives biphasic release. The initial release is over the first 48 hours followed by slow release over the next 10 days. All stents were 15 mm long and 3.0 or 3.5 mm in diameter. Balloon predilatation was performed followed by NIRx paclitaxel-eluting stent implantation using conventional techniques. Postdilatation was performed if necessary. Periprocedural intravenous heparin was given to maintain an activated clotting time ≥ 250 seconds, and all patients received aspirin (at least 75 mg) and clopidogrel (300 mg loading dose followed by 75 mg once daily for 6 months).

Follow-Up

Clinical information was collected 6 and 12 months after procedure. Angiographic and intravascular ultrasound (IVUS) follow-ups were performed at the 6-month visit. Major adverse cardiac events (MACEs) were defined as death, myocardial infarction (MI), target-vessel repeat percutaneous coronary intervention, or coronary artery bypass grafting (CABG). MI was defined as Q-wave MI (development of new pathological Q waves in 2 or more leads with CK-MB levels elevated above normal) or non-Q-wave MI (elevation of CK levels to > 2 times upper normal limit with CK-MB levels elevated above normal).

Angiographic Analysis

Coronary angiograms were obtained in multiple views after intracoronary nitrate. ISR was classified according to a modified Mehran classification.³ Three coronary segments underwent quantitative angiography: in-stent, proximal edge, and distal edge segment. The in-stent analysis encompassed the entire length of all stents used during the procedure. The proximal and distal edge segments included up to 5 mm on either side of the in-stent segment. Quantitative coronary angiographic analysis was performed by an independent core laboratory (Cardialysis, Rotterdam, the Netherlands).²⁴ The reference vessel diameter, minimal lumen diameter (MLD), and percent diameter stenosis were measured before procedure, after procedure, and at follow-up. Late loss was calculated as the difference between the MLD after procedure and that at follow-up. The target lesion was defined as the in-stent segment plus the proximal and distal edge segments. Angiographic restenosis was defined as $> 50\%$ diameter stenosis within the target lesion.

IVUS Analysis

IVUS images were acquired after procedure and at 6-month follow-up using automated pull-back at 0.5 mm/s following intracoronary nitrate.²⁵ The total coronary analysis segment beginning 5 mm distal to and extending 5 mm proximal to the study stent was examined. A computer-based contour detection program was used for automated 3D reconstruction of the segments from up to 200 cross-sectional images. Lumen, stent boundaries, and external elastic membrane were detected using a minimum cost algorithm, and volumetric quantification was performed.^{26,27} Percent volume ob-

TABLE 1. Baseline Clinical Characteristics

Patients	28
Age, y	63.2 \pm 10.5
Male sex	19 (67.9)
Diabetes mellitus	4* (14.3)
Hypertension	18 (64.3)
Hypercholesterolemia	20 (71.4)
Family history	5 (17.9)
Current smoker	2 (7.1)
Unstable angina pectoris	2 (7.1)
Multivessel disease	7 (25)
Previous MI	16 (57.1)
Previous CABG	5 (17.9)

Values are presented as numbers (relative percentages) or mean \pm SD.

*In 1 patient, the information on diabetes mellitus was unknown.

struction was calculated as neointimal volume/stent volume $\times 100$. The quantitative ultrasound analysis was performed by the same independent core laboratory.

Statistical Analysis

Continuous variables are expressed as mean \pm SD. Comparisons between postprocedure and 6-month follow-up measurements were performed with a 2-tailed paired *t* test. $P < 0.05$ was considered statistically significant.

Results

Baseline Clinical and Lesion Characteristics

Twenty-eight patients with 28 target lesions were included. The patients' baseline clinical and lesion characteristics are summarized in Tables 1 and 2, respectively. The incidence of diabetes, previous MI, and previous CABG are in keeping with the higher risk population of ISR.³ Diffuse ISR pattern

TABLE 2. Lesion Characteristics

No. of target lesions	28
Treated vessel	
Left anterior descending	10 (35.7)
Left circumflex	6 (21.4)
Right coronary artery	11 (39.3)
Left main	1 (3.6)
Type of ISR, Mehran classification	
IA, gap	0 (0)
IB, margin	3 (10.7)
IC, focal body	6 (21.4)
ID, multifocal	1 (3.6)
II, diffuse intrastent	13 (46.4)
III, proliferative	4 (14.3)
IV, total occlusion	1 (3.6)
Lesion length, mm	13.61 \pm 6.36
No. of implanted paclitaxel-eluting stents	
1 Stent per lesion	15 (53.6)
2 Stents per lesion	13 (46.4)

Values are presented as numbers (relative percentages) or mean \pm SD.

TABLE 3. Cumulative Clinical Outcome

	30 Days	6 Months	12 Months
Death	0	0	0
Q-wave MI	0	0	0
Non-Q-wave MI	1 (3.6)	1 (3.6)	1 (3.6)
CABG	0	1 (3.6)	1 (3.6)
Target vessel revascularization	0	6 (21.4)	6 (21.4)

Values are presented as numbers (relative percentages).

was present in 64% of target lesions. Thirteen lesions (46%) were treated with 2 paclitaxel-eluting stents.

Clinical Outcome

Table 3 summarizes MACE up to 12 months after procedure. No subacute stent thrombosis occurred, and no deaths were reported. There was 100% technical success in deploying the study stents; however, 1 patient had postprocedural non-Q-wave MI, yielding a 30-day MACE rate of 4%.

During the 6-month follow-up, an additional 7 patients had a MACE, for a 6-month rate of 29%. One patient underwent CABG attributable to progression of left main and ostial left circumflex lesions, which were at a distance from the target lesion. The remaining 6 patients underwent percutaneous target lesion revascularization (TLR). For 3 of these patients, the indication for TLR was angiographic restenosis. In the remaining 3 patients, 1 without angiographic restenosis had TLR because of anginal symptoms in the presence of a small MLD (1.33 mm). IVUS findings at follow-up triggered 2 additional interventions in the absence of angiographic restenosis. One showed incomplete stent apposition, the other showed insufficient stent expansion, and neither showed neointimal hyperplasia (percent volume obstruction, 0%). It was unknown whether the incomplete apposition was already present at baseline, because no IVUS assessment was performed after procedure. Between 6 and 12 months, no additional MACE was reported.

Angiographic and IVUS Outcome

Of 28 patients, 25 (89%) underwent 6-month follow-up angiography. Binary angiographic restenosis was documented in 4 patients (16%). One of these patients had target vessel total occlusion. Two paclitaxel-eluting stents had been implanted to treat ISR of a covered stent, which had been used to treat ISR of a gold-coated stent. Additional intervention was not undertaken, because the patient had no anginal symptoms.

Of the remaining 3 patients, 1 had restenosis in a bare metal stent implanted because of a dissection at the distal edge of the paclitaxel-eluting stent. Two patients had restenosis in a gap between 2 paclitaxel-eluting stents, as evident on IVUS (Figure 1). Minimal neointimal hyperplasia is seen in the segments with double contours of stent struts; however, where there is a single layer of stent struts, ie, a gap between the paclitaxel-eluting stents, occlusive neointimal tissue is evident. Hence, of the 4 with binary restenosis, 3 occurred within a region with no local delivery of paclitaxel.

The quantitative coronary angiographic data are summarized in Table 4. The mean reference vessel diameter was

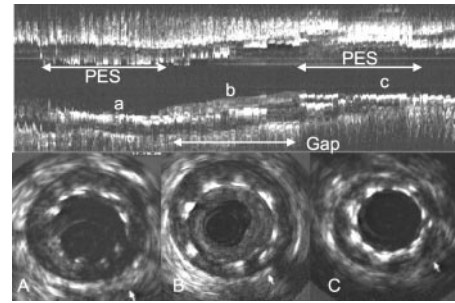


Figure 1. The IVUS images at follow-up of a patient who showed restenosis in a gap between the 2 paclitaxel-eluting stents (PES). Minimal neointimal hyperplasia was observed within the PES (A and C), whereas neointimal hyperplasia was noted in a gap (B). The cross-sectional views (A, B, and C) correspond to the a, b, and c sections of the longitudinal views.

2.75 mm. Figure 2 shows the cumulative distribution curve of MLD in the in-stent segment. The MLD at follow-up (1.84 mm) was significantly lower than that after procedure (2.40 mm). Diameter stenosis at follow-up was 30.8%, with an average in-stent late loss of 0.54 mm. Late loss of the proximal and distal edges were 0.20 and 0.11 mm, respectively, without angiographic restenosis.

Seventeen patients underwent IVUS examination at follow-up. The neointimal hyperplasia volume amounted to $20.3 \pm 23.1 \text{ mm}^3$ with the stent volume of $172.1 \pm 85.4 \text{ mm}^3$. In addition, serial analysis ($n=14$ pairs) of the total vessel volume after procedure ($411.2 \pm 332.9 \text{ mm}^3$) versus follow-up ($435.8 \pm 217.5 \text{ mm}^3$) showed no statistically significant change, suggesting that paclitaxel-eluting stent does not cause positive or negative vessel remodeling. No late acquired incomplete stent apposition was detected by serial IVUS investigation.

Subgroup Analysis

We performed subgroup analysis to estimate the treatment effect within stented segments directly exposed to local paclitaxel delivery by excluding the 3 patients who showed restenosis in a bare stent or a gap between 2 paclitaxel-eluting stents, as tabulated in Table 4. In this subgroup, the late loss and restenosis rate was 0.47 mm and 4.5%, respectively.

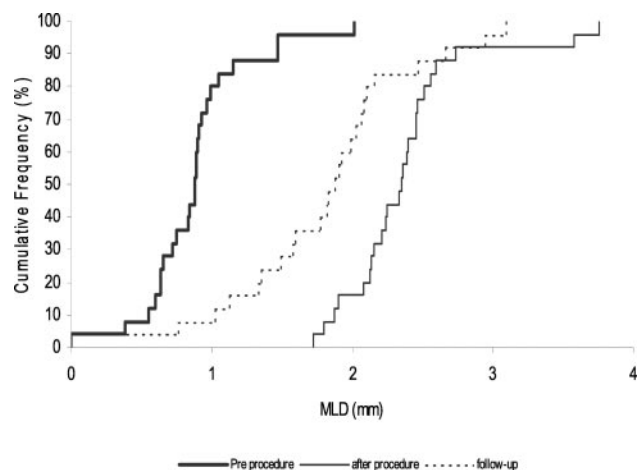


Figure 2. The cumulative distribution curve of the MLD.

TABLE 4. QCA Data

	n	Proximal Edge, All Patients	In Stent, All Patients	Distal Edge, All Patients	n	In Stent, Subgroup*
Reference diameter						
Before procedure, mm	28	NA	2.75±1.20	NA	25	2.84±1.25
After procedure, mm	28	3.08±0.40	2.91±0.43	2.81±0.43	25	2.91±0.45
6-Month follow-up, mm	25	2.86±0.43†	2.67±0.42†	2.54±0.43†	22	2.64±0.45†
Minimal lumen diameter						
Before procedure, mm	28	NA	0.87±0.38	NA	25	0.90±0.39
After procedure, mm	28	2.67±0.54	2.40±0.44	2.27±0.47	25	2.41±0.46
6-Month follow-up, mm	25	2.45±0.54†	1.84±0.63†	2.17±0.49	22	1.93±0.61†
Percent diameter stenosis						
Before procedure, mm	28	NA	67.3±11.3	NA	25	67.1±11.8
After procedure, mm	28	13.9±9.4	17.4±7.6	19.3±11.0	25	16.9±7.6
6-Month follow-up, mm	25	14.3±10.5	30.8±20.5†	14.8±9.5	22	26.9±18.6†
Late loss, mm	25	0.20±0.40	0.54±0.51	0.11±0.33	22	0.47±0.48

*The subgroup is the group that excludes the patients who showed angiographic restenosis in a bare metal stent or a gap between the paclitaxel-eluting stents.

† $P<0.05$ vs after procedure.

Figure 3 shows the results of subgroup analysis between patients with single stent ($n=13$) and those with 2 stents ($n=12$). Post-hoc statistical analysis showed a significantly smaller MLD and larger diameter stenosis at follow-up for the 2-stent group ($P<0.01$). Post-hoc statistical analysis of IVUS data at follow-up reveal that percent volume obstruction in the single-stent group ($n=10$; length, 15.4 ± 2.8 mm) was $12.4\pm 15.7\%$ for a stent volume of 111.9 ± 27.9 mm³, whereas percent volume obstruction in the 2-stent group ($n=7$, length 29.4 ± 3.0 mm) was $10.1\pm 8.2\%$ for a stent volume of 258.1 ± 60.3 mm³. In this latter group, the analysis included only 1 of the 4 patients who had angiographic restenosis.

Discussion

In the present study, we report the first clinical experience with the TAXUS NIRx paclitaxel-eluting stent for the treatment of ISR. The major findings of the TAXUS III trial are as follows. First, this polymer-based paclitaxel-eluting stent is feasible and safe for the treatment of ISR with no subacute

stent thrombosis. Second, late loss (0.54 mm) is seemingly diminished compared with historical controls. Third, angiographic restenosis rate is 16%; however, when present, it tends to occur in a gap between 2 paclitaxel-eluting stents. Fourth, the TLR rate of 21.4% (6 of 28 patients) is promising given that 3 were not performed according to predefined angiographic criteria.

Safety Consideration

At up to 12 months of clinical follow-up, there has been no late subacute stent thrombosis in our patient population, although clopidogrel was discontinued at 6 months. There was 1 patient with silent total occlusion who had preexisting in-stent restenosis in gold-coated and covered stent sandwich subsequently treated with the study stents. However, the mechanism of this occlusion is difficult to decipher, because the effect of paclitaxel on the adjacent covered stent sandwich is unknown and the covered stent precluded the IVUS assessment with respect to the detection of either a gap or an overlap. The promising safety data in our study contrasts with

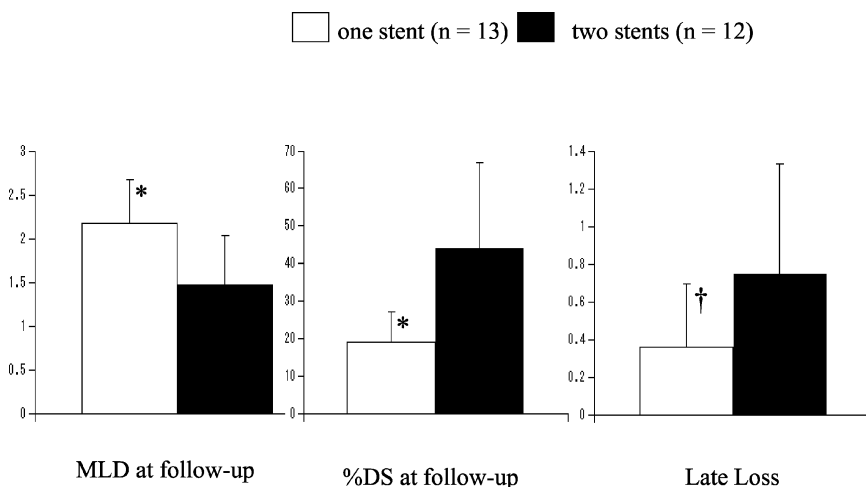


Figure 3. Post-hoc analysis between single stent and 2 stents of angiographic parameters (MLD at follow-up, percent diameter stenosis (DS) at follow-up, and late loss). It has to be emphasized that the 2 stent group include 1 total occlusion, 2 gaps between the stents, and 1 bare-stent restenosis. * $P<0.01$ vs 2 stents by unpaired t test; † $P=0.054$ versus 2 stents.

the high incidence of late subacute stent thrombosis in the randomized Score trial, evaluating de novo lesions with the QuaDS stent that used 4 or 5 polymer sleeves to deliver high concentrations (800 $\mu\text{g}/\text{sleeve}$) of paclitaxel derivative.²⁸ The enrollment of the Score trial was prematurely stopped because of a major imbalance in MACE between the study and control groups associated with stent thrombosis. Previous animal studies showed that paclitaxel may delay the healing process in a dose-dependent manner,²⁹ and stent thrombosis is likely the result of incomplete healing and reendothelialization. Additional preclinical and clinical data will give insight as to whether the dose of paclitaxel (1.0 $\mu\text{g}/\text{mm}^2$ [loaded drug/stent surface area]) used in this trial will maintain the promising safety margin.

Efficacy of the TAXUS NIRx Paclitaxel-Eluting Stent for Treatment of In-Stent Restenosis

Previous reports using bare metal stent for treatment of ISR showed a late loss of 0.9 to 1.4 mm.^{30–32} The overall late loss (0.54 mm) in our study was more favorable, even though it underestimates the treatment effect. If the 2 patients with restenosis attributable to a gap between 2 paclitaxel-eluting stents and the patient with restenosis in a bare stent are excluded, the adjusted late loss is 0.47 mm. In addition, the late loss in the single-stent group was 0.36 mm (Figure 3). These values are close to the loss of 0.35 mm (placebo group, 0.70 mm) observed in the TAXUS I trial on de novo coronary lesions treated with the same slow-release formulation. Furthermore, the neointimal volume from the TAXUS III patients with 1 NIRx stent was 15.6 mm³, comparable to 14.8 mm³ in the TAXUS I patients treated with one NIRx stent. These two values are both lower than the value of 21.6 mm³ seen in the TAXUS I uncoated bare stent group. Taken together, these data suggest that paclitaxel on the NIRx seems to attenuate neointimal formation for ISR as well as de novo lesions.

Restenosis at the Gap

In 2 patients, IVUS identified a gap between 2 eluting stents that led to restenosis. Our hypothesis is that barotrauma from balloon inflation in an area of preexisting in-stent neointima may have triggered the local exuberant hyperplasia in the gap where the concentration of paclitaxel is insufficient to prevent neointimal hyperplasia. Accordingly, we speculate that paclitaxel does not diffuse substantially from the edge of the stent to have biological effect in the gap. Therefore, when treating ISR with the paclitaxel-eluting stents, covering the entire length of the previously implanted stents and providing a margin at either side may reduce TLR associated with restenosis near the drug-treated segments. With this in mind, IVUS guidance may be useful, and the advent of longer-eluting stents will be advantageous.

TLR Without Angiographic Restenosis

The TLR rate of this trial has been artificially inflated by reinterventions because of ultrasound or angiographic findings not always clinically driven or justified by predefined angiographic criteria. In this trial, 3 of 6 TLRs had diameter stenosis <50%. Two of these patients underwent TLR as a

result of IVUS findings at follow-up. In one, there was an incomplete apposition at follow-up without postprocedural assessment. In the other patient, the stent was considered at follow-up to be insufficiently expanded, although the mean lumen area of the stent was 4.41 mm² without neointimal hyperplasia. The third patient had anginal symptoms despite a diameter stenosis of 32.5% and underwent TLR in an attempt to increase the MLD (1.33 mm) and reference diameter (1.96 mm). In this trial, the incidence of TLR may underestimate the clinical benefit related to the inhibition of neointimal hyperplasia resulting from the drug elution.

Study Limitations

The limitations of this study are its small sample size and single-arm open-label design without randomization. The angiographic follow-up rate was acceptable, although a higher IVUS follow-up rate may have provided more information on neointimal hyperplasia. Ongoing clinical follow-up will provide insight on long-term outcomes in this challenging population.

Conclusion

Paclitaxel-eluting stent implantation is considered safe and potentially efficacious in the treatment of ISR. The IVUS guidance to ensure good stent deployment with complete coverage of target lesion may reduce reintervention.

Acknowledgments

The authors appreciate the efforts of the catheterization laboratory staff and would like to thank Dr A. Hoyer, E. van Remortel, P. Cummins, and J. Hansen for their continuous support.

References

1. Serruys PW, de Jaegere P, Kiemeneij F, et al. A comparison of balloon-expandable-stent implantation with balloon angioplasty in patients with coronary artery disease: Benestent Study Group. *N Engl J Med*. 1994; 331:489–495.
2. Fischman DL, Leon MB, Baim DS, et al. A randomized comparison of coronary-stent placement and balloon angioplasty in the treatment of coronary artery disease: Stent Restenosis Study Investigators. *N Engl J Med*. 1994;331:496–501.
3. El-Omar MM, Dangas G, Iakovou I, et al. Update on in-stent restenosis. *Curr Intervent Cardiol Rep*. 2001;3:296–305.
4. Waksman R, White RL, Chan RC, et al. Intracoronary gamma-radiation therapy after angioplasty inhibits recurrence in patients with in-stent restenosis. *Circulation*. 2000;101:2165–2171.
5. Teirstein PS, Massullo V, Jani S, et al. Three-year clinical and angiographic follow-up after intracoronary radiation: results of a randomized clinical trial. *Circulation*. 2000;101:360–365.
6. Leon MB, Teirstein PS, Moses JW, et al. Localized intracoronary gamma-radiation therapy to inhibit the recurrence of restenosis after stenting. *N Engl J Med*. 2001;344:250–256.
7. Albiero R, Nishida T, Adamian M, et al. Edge restenosis after implantation of high activity (32)P radioactive β -emitting stents. *Circulation*. 2000;101:2454–2457.
8. Wardeh AJ, Knook AH, Kay IP, et al. Clinical and angiographical follow-up after implantation of a 6–12 microCi radioactive stent in patients with coronary artery disease. *Eur Heart J*. 2001;22:669–675.
9. Costa MA, Sabat M, van der Giessen WJ, et al. Late coronary occlusion after intracoronary brachytherapy. *Circulation*. 1999;100:789–792.
10. Sabate M, Costa MA, Kozuma K, et al. Geographic miss: a cause of treatment failure in radio-oncology applied to intracoronary radiation therapy. *Circulation*. 2000;101:2467–2471.
11. Kozuma K, Costa MA, Sabate M, et al. Late stent malapposition occurring after intracoronary β -irradiation detected by intravascular ultrasound. *J Invasive Cardiol*. 1999;11:651–655.

12. Meerkin D, Tardif JC, Crocker IR, et al. Effects of intracoronary β -radiation therapy after coronary angioplasty: an intravascular ultrasound study. *Circulation*. 1999;99:1660–1665.
13. Kay IP, Sabate M, Van Langenhove G, et al. Outcome from balloon induced coronary artery dissection after intracoronary β radiation. *Heart*. 2000;83:332–337.
14. Sabate M, Serruys PW, van der Giessen WJ, et al. Geometric vascular remodeling after balloon angioplasty and β -radiation therapy: a three-dimensional intravascular ultrasound study. *Circulation*. 1999;100:1182–1188.
15. Kay IP, Sabate M, Costa MA, et al. Positive geometric vascular remodeling is seen after catheter-based radiation followed by conventional stent implantation but not after radioactive stent implantation. *Circulation*. 2000;102:1434–1439.
16. Grube E, Siber MS, Hauptmann KE, et al. Prospective, randomized, double-blind comparison of NIRx stents coated with paclitaxel in a polymer carrier in de-novo coronary lesions compared with uncoated controls. *Circulation*. 2001;104(suppl):II-463.
17. Rensing BJ, Vos J, Smits PC, et al. Coronary restenosis elimination with a sirolimus eluting stent: first European human experience with 6-month angiographic and intravascular ultrasonic follow-up. *Eur Heart J*. 2001;22:2125–2130.
18. Sousa JE, Costa MA, Abizaid AC, et al. Sustained suppression of neo-intimal proliferation by sirolimus-eluting stents: one-year angiographic and intravascular ultrasound follow-up. *Circulation*. 2001;104:2007–2011.
19. Morice MC, Serruys PW, Sousa JE, et al. A randomized comparison of a sirolimus-eluting stent with a standard stent for coronary revascularization. *N Engl J Med*. 2002;346:1773–1780.
20. Sollott SJ, Cheng L, Pauly RR, et al. Taxol inhibits neointimal smooth muscle cell accumulation after angioplasty in the rat. *J Clin Invest*. 1995;95:1869–1876.
21. Axel DI, Kunert W, Goggelmann C, et al. Paclitaxel inhibits arterial smooth muscle cell proliferation and migration in vitro and in vivo using local drug delivery. *Circulation*. 1997;96:636–645.
22. Herdeg C, Oberhoff M, Baumbach A, et al. Local paclitaxel delivery for the prevention of restenosis: biological effects and efficacy in vivo. *J Am Coll Cardiol*. 2000;35:1969–1976.
23. Drachman DE, Edelman ER, Seifert P, et al. Neointimal thickening after stent delivery of paclitaxel: change in composition and arrest of growth over six months. *J Am Coll Cardiol*. 2000;36:2325–2332.
24. Serruys PW, Foley DP, de Feyter. *Quantitative Coronary Angiography in Clinical Practice*. Philadelphia, Pa: Kluwer Academic Publishers; 1994.
25. Mintz GS, Nissen SE, Anderson WD, et al. Standard for the acquisition, measurement, and reporting of intravascular ultrasound studies: a report of the American College of Cardiology Task Force on Clinical Expert Consensus Documents. *J Am Coll Cardiol*. 2001;37:1478–1492.
26. Li W, von Birgelen C, Hartlooper A, et al. Semi-automated contour detection for volumetric quantification of intracoronary ultrasound. In: *Computers in Cardiology*. Washington: IEEE Computer Society Press; 1994:277–280.
27. von Birgelen C, Di Mario C, Li W, et al. Morphometric analysis in three-dimensional intracoronary ultrasound: an in vitro and in vivo study performed with a novel system for the contour detection of lumen and plaque. *Am Heart J*. 1996;132:516–527.
28. Liistro F, Colombo A. Late acute thrombosis after paclitaxel eluting stent implantation. *Heart*. 2001;86:262–264.
29. Farb A, Heller PF, Shroff S, et al. Pathological analysis of local delivery of paclitaxel via a polymer-coated stent. *Circulation*. 2001;104:473–479.
30. Adamian M, Colombo A, Briguori C, et al. Cutting balloon angioplasty for the treatment of in-stent restenosis: a matched comparison with rotational atherectomy, additional stent implantation and balloon angioplasty. *J Am Coll Cardiol*. 2001;38:672–679.
31. Elezi S, Kastrati A, Hadamitzky M, et al. Clinical and angiographic follow-up after balloon angioplasty with provisional stenting for coronary in-stent restenosis. *Cathet Cardiovasc Intervent*. 1999;48:151–156.
32. Alfonso F, Cequier A, Zueco J, et al. Stenting the stent: initial results and long-term clinical and angiographic outcome of coronary stenting for patients with in-stent restenosis. *Am J Cardiol*. 2000;85:327–332.