



OPEN ACCESS

Spontaneous subdiaphragmatic bar migration after pectus excavatum treatment

Alexander Hamming ¹, Hendt Versteegh,² J Marco Schnater ²

¹Neurosurgery, HMC Westeinde, Den Haag, The Netherlands
²Paediatric Surgery, Sophia Children's Hospital Erasmus Medical Center, Rotterdam, The Netherlands

Correspondence to

Dr J Marco Schnater;
j.schnater@erasmusmc.nl

Accepted 9 December 2022

SUMMARY

A case of an adolescent boy with persistent thoracic symptoms and recurrence of pectus excavatum (after previous treatment with the Nuss procedure) is presented. During thoracoscopic revision, subdiaphragmatic migration of the implant was noted. The bar was removed without damage to the intra-abdominal organs or other complications, and a new bar was placed and stabilised. Revision showed successful correction of the thorax, and the boy had no thoracic symptoms.

BACKGROUND

The Nuss procedure is the most applied surgical treatment of pectus excavatum (PE). It was developed by Donald Nuss in 1987 and implemented as primary treatment in the late 1990s.¹ This minimally invasive surgery achieves improvement of thoracic anatomy, aesthetics and cardiopulmonary function.^{1,2} However, early and late complications of the Nuss procedure often occur. Complications may be seen intraoperatively (eg, haemothorax, pericardial perforation, arrhythmias) or postoperatively (eg, bar displacement, pleural effusion, pneumothorax, wound infections, pericardial effusion).¹ Bar displacement is one of the most prevalent complications.¹ Three types of bar displacement can be distinguished: lateral sliding, flipping or posterior disruption. Displacement is mostly seen within 30 days after initial placement,³ although it can occur at any point during follow-up. Fortunately, due to the introduction of stabilisers and fixation techniques, the incidence has decreased over the years from 15% to 3%–7%.⁴

In this report, we present a patient with an abdominal location of a bar due to the extraordinary occurrence of subdiaphragmatic migration following the Nuss procedure.

CASE PRESENTATION

The patient is an adolescent boy with a history of mild scoliosis and epilepsy, without any seizures or medication in the 7 years prior to surgery. To remedy cosmetic problems of PE, he underwent a thoracoscopic-guided Nuss procedure. During the procedure, no unexpected events occurred and the patient completed his admission without complications. Perioperative images showed a good intrathoracic placement of the Nuss bar. One month after surgery, he presented with thoracic pain, which was interpreted as persistent postoperative pain. Physical examination and a thoracic X-ray showed no abnormalities and an unaltered position of the Nuss

bar. Eight months after surgery, he presented with position-dependent discomfort and a recurrence of the PE, for which bar revision was indicated. During surgery, subdiaphragmatic and intra-abdominal migration of the bar were seen. Subsequently, the bar was removed, and a new bar was placed intrathoracically.

INITIAL NUSS BAR PLACEMENT

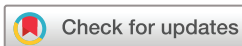The initial bar placement by video-assisted thoracoscopy (VATS) was done under both general and epidural anaesthesia, with the patient placed in supine position. The bar was measured and bent to fit size. An incision was made on both sides of the thorax, followed by submuscular tunnelling. A 5 mm trocar was introduced in the anterior section of the axillary region on the right side, followed by insufflation of carbon dioxide and tunnelling under thoracoscopic vision. A precordial tunnel from side to side was created. A silicon tube was secured to the tunnel, after which the previously bent bar was pulled back through the precordial tunnel (figure 1). The bar turned with good result, and haemodynamic changes were not noted. A fixation plate was introduced on the left side, on which the lateral part of the bar was bent to prevent slip-off of the plate. Haemostasis of the precordial tunnel and operative wounds was achieved. The wounds were closed in layers. The procedure was carried out without any complications and with minimal blood loss. The patient was discharged on postoperative day 3.

INVESTIGATIONS

The first postoperative X-ray showed a good position of the bar (figure 2). When thoracic symptoms persisted, a second X-ray was performed, which was initially described as showing no abnormalities (figure 3). A second reading, however, did show caudal displacement and potential rotation of the bar with the right hemidiaphragm projecting over the bar.

TREATMENT

The revision by VATS was carried out under both general and epidural anaesthesia, with the patient placed in supine position. Incisions were made at the same level as during the previous surgery and scar tissue was excised. Subsequently, the bar and fixation plate on the left side were mobilised. Led by palpable movement, localisation of the bar was attempted on the right side without any success. A 5 mm trocar was introduced in the frontal axillary region on the right side, followed by creating



© BMJ Publishing Group Limited 2022. Re-use permitted under CC BY-NC. No commercial re-use. See rights and permissions. Published by BMJ.

To cite: Hamming A, Versteegh H, Schnater JM. *BMJ Case Rep* 2022;**15**:e251757. doi:10.1136/bcr-2022-251757

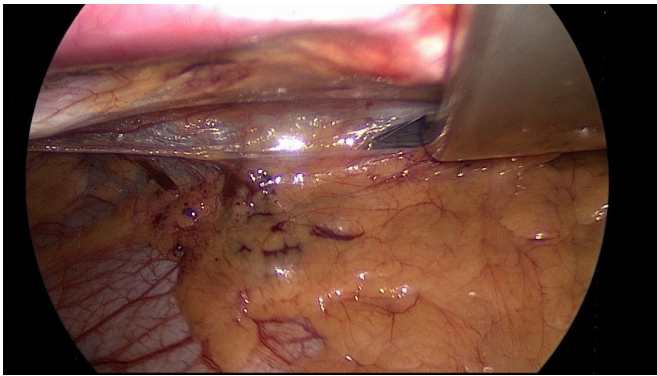


Figure 1 Intraoperative view of first bar placement.

thoracoscopic vision. Under direct vision, the bar could not be identified on the right side of the thorax. Migration to the subdiaphragmatic region appeared to have occurred, as movement of the bar was seen below the diaphragm. There were no signs of damage to the diaphragm or surrounding tissues (figure 4). The left thoracic incision site was extended, and the Nuss bar was manually removed through the left side, without any haemodynamic changes. A precordial tunnel from side to side was created again. A silicon tube was secured to the tunnelling instrument,

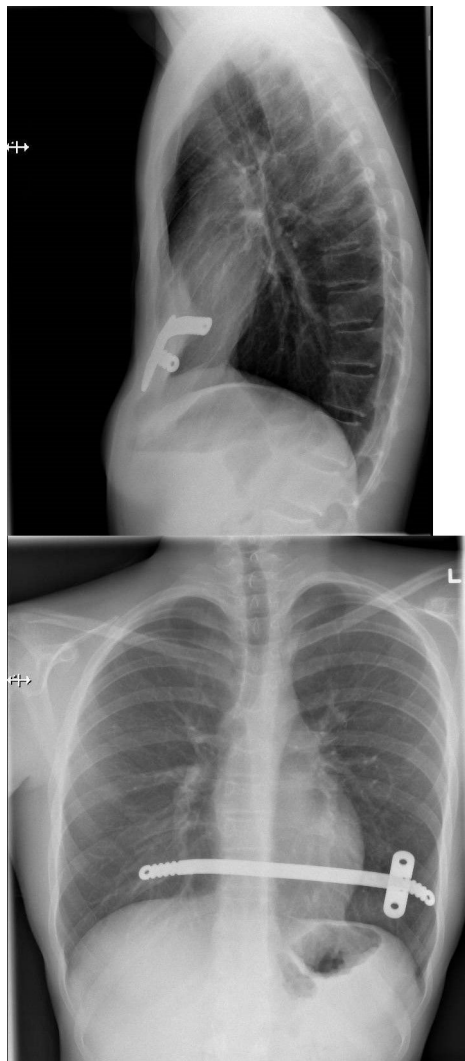


Figure 2 Postoperative X-thorax after first bar placement.

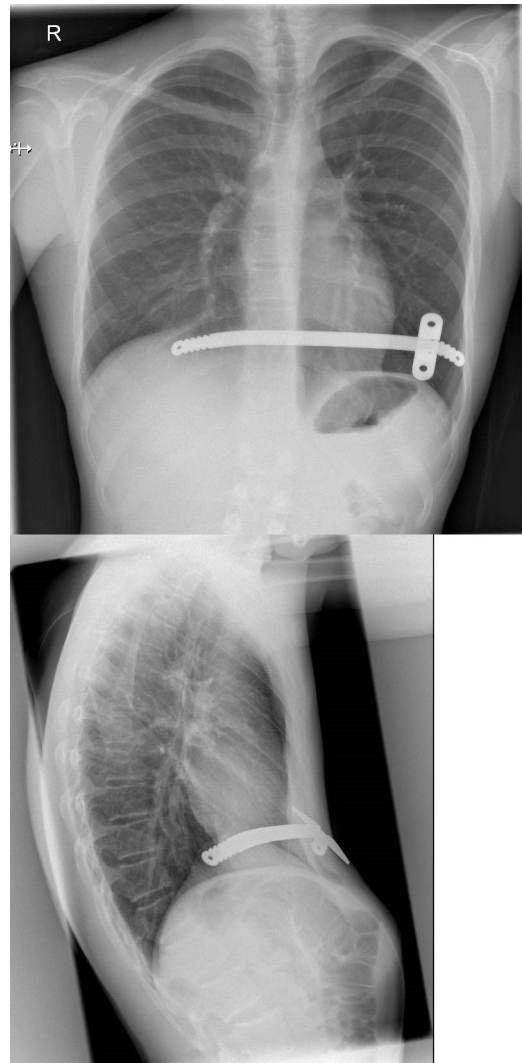


Figure 3 Follow-up X-thorax.

after which the newly bent bar was retracted through the precordial tunnel. The bar turned with good result and without any haemodynamic changes. A fixation plate was introduced; this time on the right side, on which the lateral part of the bar was bent to prevent slip-off of the plate. Haemostasis of the precordial tunnel and operative wounds was achieved. The wounds were closed in layers. The operation was carried out without

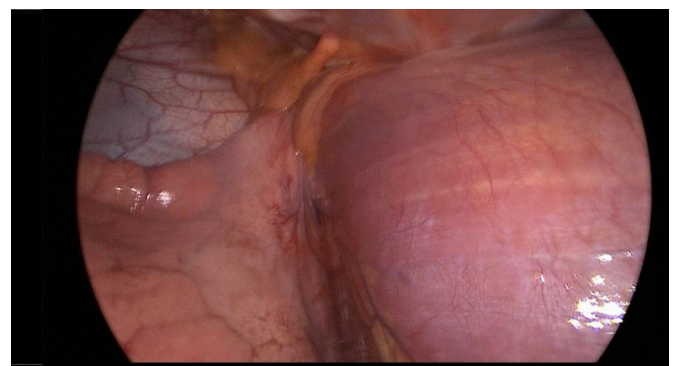


Figure 4 Intraoperative view of absent intrathoracic bar with intact diaphragm.

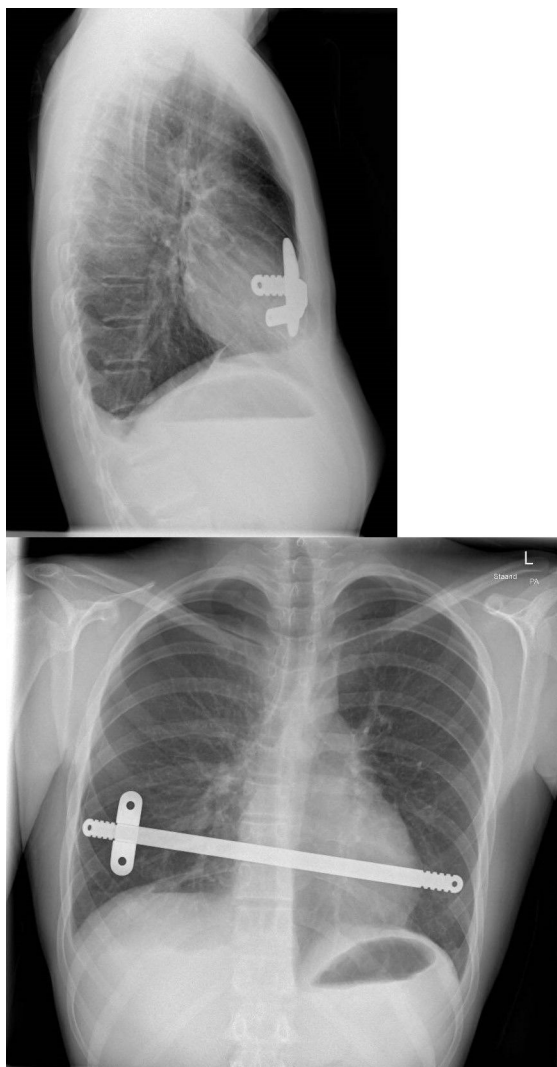


Figure 5 Postoperative X-thorax after bar revision.

any complications and with minimal blood loss. The patient was discharged on postoperative day 3.

OUTCOME AND FOLLOW-UP

The postoperative course was without complications. Five days after the revision procedure, adequate correction of anatomy and appearance of the thorax were seen. The patient had no thoracic symptoms and was pleased with the result. The X-ray showed an adequate position of the bar (figure 5).

DISCUSSION

Extrathoracic or intra-abdominal migration of a Nuss bar is a rare event, in contrast to intrathoracic bar displacement, which occurs rather frequently.

Several cases have been reported with different types of bar displacement and only a few with intra-abdominal migration. Simon *et al* have reported an intra-abdominal migration of a bar into the stomach in a man in his 20s.⁵ Tahmassebi *et al* reported a case of a man in late adolescence, in which VATS failed to view an intrathoracic bar.⁶ By instrumental palpation, subdiaphragmatic position of the bar was concluded. Via an incision in the diaphragm, the bar was successfully removed without complications.

Moreover, Tahmassebi *et al* present 12 other bar migration cases from literature, in most of which the aetiology remained unclear. Migration sites included peritoneum, ascending aorta, left ventricle of the heart and liver.⁶

Among other types of displacement, Hoel *et al* reported a life-threatening laceration of the ascending aorta in a young boy 2 months after a Nuss procedure. A cardiac tamponade was the consequence of this laceration, which was relieved by immediate needle aspiration from the pericardium and subsequent median sternotomy for removal of the bar.⁷ Furthermore, Yang *et al* presented a similar case in which displacement of the bar caused cardiac tamponade 6 months after the Nuss procedure.⁸

Kanegaonkar and Dussek presented a case report of three bar migration cases. One case was a patient in early adolescence who at the age of 2 years had received a lower lobectomy for an unresolving lobar consolidation. Because of sternal depression, the patient underwent resection of the costal cartilages from the third rib downwards and a partial transverse sternotomy followed by a bar placement. During elective bar removal after 2 years, a part of the bar was seen buried into newly formed bone of the sixth rib. The other two cases presented by Kanegaonkar and Dussek concerned bar migration into the thoracic cavity. One was observed during elective bar removal, the other was seen on CT after a failed attempt to remove the bar because it could not be located during surgery.⁹

While bar displacement may occur in 3%–7% of cases, bar migration is a rather extraordinary occurrence with an unknown prevalence. It could be defined as passage of foreign material through organs or tissues without any damage to those organs or tissues.⁶ In our case, indeed, damage to the diaphragm was seen neither during the initial procedure nor during the second procedure. Several mechanisms have been proposed that could cause such migration events, including cardiac and lung activity, patient rotation activities, narrow thickness of the bar and unilateral fixation of the bar where the movement of the contralateral side is not limited. Furthermore, in the case of bar migration to the subdiaphragmatic region, self-healing of the diaphragm could conceal the extra-thoracic position of the bar during surgery.

If migration of a Nuss bar is suspected, thorough examination through X-rays and, if necessary, CT scans are advocated to be the first course of action. Furthermore, an ultrasound could confirm whether the bar is located above or below the diaphragm. In addition, MRI could assess if the bar has penetrated diaphragmatic structures. When bar migration or displacement of the bar is highly suspected, but not seen on imaging techniques, a second look through thoroscopic surgery is indicated.

When intra-abdominal migration is seen on additional imaging, a revision through endoscopic surgery is necessary to safely remove the bar. Furthermore, VATS or laparoscopy may be insufficient to locate and remove the migrated bar, such as in the case described by Tahmassebi *et al*. In such circumstances, an open approach through laparotomy may be the best option for correct and safe removal of the Nuss bar.⁶

Nevertheless, novel methods have been proposed for reducing the risk of bar migration or displacement. For instance, Tam *et al* recently presented the ZipFix stabilisation method in 20 patients without any recurrence or bar displacement, by using a biocompatible cable-tie implant.¹⁰ However, these methods are yet to be further studied for their success rates.

In conclusion, bar migration following the Nuss procedure is a rare occurrence with an unknown aetiology. On occurrence or suspicion of bar migration, cautious action through

Case report

X-ray, CT scan and VATS is essential. New methods that could reduce the risk of bar migration or displacement are yet to be studied.

Learning points

- ▶ Extrathoracic or intra-abdominal migration of a Nuss bar is a rare but potential appearance.
- ▶ The aetiology of this type of migration is unknown.
- ▶ Low-threshold X-thorax, CT of the thorax and possibly revision are essential when new thoracic symptoms present in patients with a Nuss bar.

Contributors AH—writing of the case report and submission of documents. HV—direct supervision and cowriting of the case report, providing images/figures. JMS—supervision and approval for submission.

Funding The authors have not declared a specific grant for this research from any funding agency in the public, commercial or not-for-profit sectors.

Competing interests None declared.

Patient consent for publication Obtained.

Provenance and peer review Not commissioned; externally peer reviewed.

Open access This is an open access article distributed in accordance with the Creative Commons Attribution Non Commercial (CC BY-NC 4.0) license, which permits others to distribute, remix, adapt, build upon this work non-commercially, and license their derivative works on different terms, provided the original work is properly cited and the use is non-commercial. See: <http://creativecommons.org/licenses/by-nc/4.0/>.

Case reports provide a valuable learning resource for the scientific community and can indicate areas of interest for future research. They should not be used in isolation to guide treatment choices or public health policy.

ORCID iDs

Alexander Hamming <http://orcid.org/0000-0002-9062-5412>

J Marco Schnater <http://orcid.org/0000-0003-4910-8293>

REFERENCES

- 1 Garzi A, Prestipino M, Rubino MS, *et al*. Complications of the "Nuss Procedure" In Pectus Excavatum. *Transl Med UniSa* 2020;22:24–7.
- 2 Pilegaard HK. Short Nuss bar procedure. *Ann Cardiothorac Surg* 2016;5:513–8.
- 3 Park HJ, Lee SY, Lee CS. Complications associated with the Nuss procedure: analysis of risk factors and suggested measures for prevention of complications. *J Pediatr Surg* 2004;39:391–5.
- 4 Tedde ML, Campos JRMde, Das-Neves-Pereira J-C, *et al*. The search for stability: bar displacement in three series of pectus excavatum patients treated with the Nuss technique. *Clinics* 2011;66:1743–6.
- 5 Simon N, Kolvekar S, Khosravi A. Extra-thoracic migration of the Nuss bar in corrective surgery for pectus excavatum: a very rare late complication. *J Surg Case Rep* 2020;2020:rjaa388.
- 6 Tahmassebi R, Ashrafian H, Salih C, *et al*. Intra-abdominal pectus bar migration—a rare clinical entity: case report. *J Cardiothorac Surg* 2008;3:39.
- 7 Hoel TN, Rein KA, Svennevig JL. A life-threatening complication of the Nuss procedure for pectus excavatum. *Ann Thorac Surg* 2006;81:370–2.
- 8 Yang M-H, Cheng Y-L, Tsai C-S, *et al*. Delayed cardiac tamponade after the Nuss procedure for pectus excavatum: a case report and simple management. *Heart Surg Forum* 2008;11:E129–31.
- 9 Kanegaonkar RG, Dussek JE. Removal of migrating pectus bars by video-assisted thoracoscopy. *Eur J Cardiothorac Surg* 2001;19:713–5.
- 10 Tam JKC, Leow L, Yong KJ, *et al*. Novel Nuss bar fixation using ZipFix for pectus excavatum. *Heart Lung Circ* 2022;31:1443–9506.

Copyright 2022 BMJ Publishing Group. All rights reserved. For permission to reuse any of this content visit <https://www.bmj.com/company/products-services/rights-and-licensing/permissions/>
BMJ Case Report Fellows may re-use this article for personal use and teaching without any further permission.

Become a Fellow of BMJ Case Reports today and you can:

- ▶ Submit as many cases as you like
- ▶ Enjoy fast sympathetic peer review and rapid publication of accepted articles
- ▶ Access all the published articles
- ▶ Re-use any of the published material for personal use and teaching without further permission

Customer Service

If you have any further queries about your subscription, please contact our customer services team on +44 (0) 207111 1105 or via email at support@bmj.com.

Visit casereports.bmj.com for more articles like this and to become a Fellow