











## ORIGINAL ARTICLE

# Joint status of patients with nonsevere hemophilia A

Anne-Fleur Zwagemaker<sup>1</sup>  | Fabienne R. Kloosterman<sup>1</sup>  | Robert Hemke<sup>2</sup>  |  
 Samantha C. Gouw<sup>1,3</sup>  | Michiel Coppens<sup>4</sup>  | Lorenzo G. R. Romano<sup>5</sup>  |  
 Marieke J. H. A. Kruijff<sup>5</sup>  | Marjon H. Cnossen<sup>6</sup>  | Frank W. G. Leebeek<sup>5</sup>  |  
 Barbara A. Hutten<sup>7</sup>  | Mario Maas<sup>2</sup>  | Karin Fijnvandraat<sup>1,8</sup> 

<sup>1</sup>Pediatric Hematology, Amsterdam UMC, University of Amsterdam, Emma Children's Hospital, Amsterdam, The Netherlands

<sup>2</sup>Department of Radiology and Nuclear Medicine, Amsterdam University Medical Centers, University of Amsterdam, Amsterdam Movement Sciences, Amsterdam, The Netherlands

<sup>3</sup>Department of Clinical Epidemiology, Leiden University Medical Center, Leiden, The Netherlands

<sup>4</sup>Department of Vascular Medicine, Amsterdam University Medical Centers, Amsterdam, the Netherlands

<sup>5</sup>Department of Hematology, Erasmus MC, Erasmus University Medical Center, Rotterdam, The Netherlands

<sup>6</sup>Department of Pediatric Hematology, Erasmus MC Sophia Children's Hospital, Erasmus University Medical Center, Rotterdam, The Netherlands

<sup>7</sup>Department of Epidemiology and Data Science, Amsterdam Cardiovascular Sciences, Amsterdam University Medical Centers, University of Amsterdam, Amsterdam, The Netherlands

<sup>8</sup>Department of Molecular Cellular Hemostasis, Sanquin Research and Landsteiner Laboratory, Amsterdam, The Netherlands

## Correspondence

Karin Fijnvandraat, Department of Pediatric Hematology, Emma Children's Hospital, Room H7-266 Amsterdam UMC, Meibergdreef 9, 1105 AZ, Amsterdam, The Netherlands.  
 Email: c.j.fijnvandraat@amsterdamumc.nl

## Funding information

Bayer, Grant/Award Number: Hemophilia Outcomes Research Award 2015; Novo Nordisk; CSL Behring, Grant/Award Number: Prof. Heimburger Award 2016

## Abstract

**Background:** Joint bleeding in hemophilia may eventually lead to joint damage. In non-severe hemophilia, joint bleeds occur infrequently. Currently, knowledge on the joint status of patients with nonsevere hemophilia using objective imaging is limited.

**Objective:** To investigate the joint status in patients with nonsevere hemophilia A.

**Methods:** This cross-sectional study included patients with nonsevere hemophilia A aged 24–55 years. Joint status was assessed by magnetic resonance imaging (MRI) of the elbows, knees, and ankles and International Prophylaxis Study Group (IPSG) scores were calculated. Lifetime joint bleeding history was collected from medical files. The contribution of factors to joint outcome was explored using multivariable linear regression analysis.

**Results:** In total, 51 patients were included, of whom 19 (37%) had moderate and 32 (63%) had mild hemophilia. Patients had a median age of 43 years (interquartile range [IQR] 32–50), a median factor VIII activity of 10 IU/dl (IQR 4–16) and a median annual joint bleeding rate (AJBR) of 0.0 (IQR 0.0–0.2). Soft-tissue changes (IPSG subscore > 0) in the elbows, knees, and ankles were present in 19%, 71%, and 71% of patients, respectively. Osteochondral changes (IPSG subscore > 0) in the elbows, knees, and ankles were present in 0%, 20%, and 35% of patients, respectively. In 14% of bleed-free

Manuscript handled by: David Lillicrap

Final decision: David Lillicrap, 11 February 2021

This is an open access article under the terms of the Creative Commons Attribution-NonCommercial-NoDerivs License, which permits use and distribution in any medium, provided the original work is properly cited, the use is non-commercial and no modifications or adaptations are made.

© 2022 The Authors. Journal of Thrombosis and Haemostasis published by Wiley Periodicals LLC on behalf of International Society on Thrombosis and Haemostasis.

joints, hemosiderin depositions were observed. Age and AJBRs were most strongly associated with the IPSP score.

**Conclusion:** This study demonstrates that a substantial proportion of adults with non-severe hemophilia has joint changes on MRI despite low joint bleeding rates.

#### KEYWORDS

hemarthrosis, hemophilia A, joint diseases, joints, magnetic resonance imaging

## 1 | INTRODUCTION

Hemophilia A is an X-linked inherited coagulation disorder that is caused by a deficiency in functional clotting factor VIII (FVIII). The severity of disease is based on the residual FVIII activity and classified into a severe (<1 IU/dl), moderate (1–5 IU/dl), and mild form (>5–<40 IU/dl).<sup>1</sup> Patients with severe hemophilia may experience spontaneous bleeds, whereas patients with moderate and mild (non-severe) hemophilia generally suffer from bleeds provoked by trauma.

In hemophilia, joint bleeding is considered the hallmark of disease and typically affects the elbows, knees, and ankles.<sup>2,3</sup> Intra-articular blood induces several processes characterized by iron accumulation, synovial proliferation, and angiogenesis that may progress into chronic synovitis or osteochondral damage.<sup>4,5</sup> Such late-stage hemophilic arthropathy is a severe complication associated with pain, disability, and impaired quality of life.<sup>2,6</sup> Although significant arthropathy is predominantly observed in patients with severe hemophilia, previous research has also reported joint problems in patients with nonsevere hemophilia.<sup>7–10</sup>

Different modalities exist to assess joint status in hemophilia. For evaluation of clinical function, one of the assessments is the Haemophilia Joint Health Score (HJHS).<sup>11</sup> For imaging of the joints, conventional radiography has traditionally been the standard in hemophilia, although a drawback is the insensitivity to early joint abnormalities. Ultrasound is noninvasive and can accurately visualize the synovium but has limited ability to assess the central joint areas. Magnetic resonance imaging (MRI) enables improved visualization because soft-tissue changes are visible in all areas and is therefore considered the most sensitive method for detecting early joint alterations.<sup>12,13</sup>

MRI studies in severe hemophilia that reported joint abnormalities in patients without a history of overt joint bleeding suggest that even subclinical bleeds may result in joint deterioration.<sup>14,15</sup> Furthermore, some patients exhibited structural damage in spite of a limited number of experienced clinical joint bleeds.<sup>14,16</sup> These findings raise concerns that patients with a history of sporadic or even no clinical joint bleeds may be at risk for development of joint damage, calling for more intensive monitoring or treatment to halt further progression.

Because most research has focused on severe hemophilia, knowledge on the extent of joint damage in patients with non-severe hemophilia is limited. Moreover, such data could also be relevant for severe patients with treatment targets within the nonsevere range. Because no previous MRI studies have been conducted in this

### Essentials

- Patients with non-severe hemophilia A (HA) generally experience no or sporadic joint bleeds.
- Joint status was assessed with magnetic resonance imaging (MRI) in adults with non-severe HA.
- In ankles, soft tissue changes were seen in 71% and osteochondral changes in 35% patients.
- Hemosiderin depositions were detected in 14% of joints without a history of joint bleeding.

population, objective imaging studies in the evaluation of joints in patients with nonsevere hemophilia are urgently required.

Therefore, the primary aim of this study is to investigate the joint status in patients with nonsevere hemophilia A using MRI of elbows, knees and ankles. The secondary aim of this study is to explore factors contributing most strongly to observed joint changes.

## 2 | METHODS

### 2.1 | Design and setting

The DYNAMO study is a multicenter international cohort study evaluating the bleeding phenotype of patients with nonsevere hemophilia. For the present cross-sectional study, a subset of patients was recruited from two Dutch hemophilia treatment centers located at the Amsterdam University Medical Center (Amsterdam UMC) and the Erasmus University Medical Center Rotterdam (Erasmus MC). Eligible patients were invited for study participation on a random basis until our target of 50 participants was reached. Enrollment took place from September 2019 to October 2020. The study was approved by the institutional review boards of the participating centers and registered in advance on clinicaltrials.gov (NCT03623295). Written informed consent was obtained from all included patients.

### 2.2 | Participants

Male patients with nonsevere hemophilia A (FVIII activity 2–35 IU/dl) aged 24–55 years were eligible for inclusion. The FVIII activity

range was set to ensure that only true nonsevere patients were investigated with less influence of one-off outliers in FVIII measurements. The lower age limit was set to ensure that findings are not influenced by physiological growth and the upper limit to ensure that all participants had lifetime access to cryoprecipitate or factor concentrate. Exclusion criteria were the presence of another coagulation disorder, participation in a trial with an investigational product, use of anticoagulant or antiplatelet agents, a history of inhibitory antibodies to FVIII, contraindications for MRI, and presence of a hemophilia-unrelated comorbidity that could affect joint status, such as inflammatory joint diseases.

## 2.3 | Study outcomes

The primary outcome of the study was joint status as assessed by MRI of elbows, knees, and ankles scored with the International Prophylaxis Study Group (IPSG) score. Soft-tissue changes and osteochondral changes were defined as >0 point on the corresponding subscore. The secondary outcome of the study was the exploration of potential contributing factors of observed joint changes.

## 2.4 | Data collection

### 2.4.1 | Imaging

MRI examinations were conducted on a 3Tesla MR scanner (Ingenia; Omega, Philips Medical Systems) at the Amsterdam UMC during a single study visit. Patients were first placed in a feet-first supine position for scanning of both knees and ankles with a large anterior coil. The sequences acquired for knees and ankles were sagittal T1-weighted turbo spin echo images and sagittal and coronal T2\*-weighted fast gradient echo images. The elbows were scanned with the elbow joint placed in the middle of the coil. The sequences acquired for elbows were sagittal T1-weighted turbo spin echo images and sagittal and transversal T2\*-weighted fast gradient echo images. The first 10 MRI scans were scored in consensus by two board-certified musculoskeletal radiologists (R.H. and M.M.) with 9 and 21 years of experience in musculoskeletal MRI, respectively. Because the initial images were assessed similarly by the two radiologists, subsequent images were scored by one musculoskeletal radiologist (R.H.). All MRI scans were evaluated blinded to patient characteristics and scored according to the IPSG score and an MRI atlas for hemophilic arthropathy.<sup>17,18</sup> The IPSG score consists of a soft-tissue component (effusion/hemarthrosis, synovial hypertrophy, hemosiderin deposition) with a maximum of 9 points per joint and an osteochondral component (surface erosions, cysts, cartilage degradation) with a maximum of 8 points per joint. Higher scores are associated with more abnormalities. As a result, the maximum score is 17 points per joint and 102 points when all 6 joints are evaluated. Because lower cutoff values for the surface measurements of effusion and synovial hypertrophy are lacking in literature, these were

defined as 0.50 cm<sup>2</sup> for knees and as 0.25 cm<sup>2</sup> for ankles and elbows in accordance with previous work by Foppen et al.<sup>19</sup>

### 2.4.2 | Clinical function

The clinical function of joints was assessed at the same day of the MRI examinations and scored according to the HJHS version 2.1 by two physicians (A.Z. and F.K.) trained in advance by physiotherapists with expertise in the field of hemophilia. The HJHS assesses swelling, muscle atrophy, crepitus on motion, range of motion, joint pain, strength, and gait. As a result, the maximum scores are 20 points per joint and 124 points in total (including gait score). The presence of an abnormal HJHS subscore was defined as >1 point per joint. This cutoff was chosen based on the interquartile ranges of the HJHS in healthy males.<sup>20</sup>

### 2.4.3 | Retrospective clinical data

The following data were collected from medical files: demographics, lifetime lowest FVIII activity, body mass index (BMI), history of joint surgery, treatment regimen, and information on all lifetime joint bleeding events including cause and treatment of bleeds. BMI was calculated from the highest measured weight and height in the past 10 years. Joint bleeding events were defined as bleeds that occurred in elbows, wrists, shoulders, knees, hips, or ankles and classified as such by the treating physician. Annual joint bleeding rates (AJBRs) were derived for the duration from the period 1 January 2009 until the study visit and calculated as: (total number of joint bleeding episodes during follow-up / follow-up in months) × 12. Further definitions are described in the supplemental materials.

### 2.4.4 | Patient-reported data

All patients completed an online questionnaire on the day of the study visit and were asked to provide details on all physical exercises they perform in a typical 7-day period for more than 15 min. A total activity score was calculated based on the Godin Leisure-Time Exercise Questionnaire and classified into sedentary, moderately active, and active.<sup>21</sup> More information on the Godin Leisure-Time Exercise Questionnaire can be found in the supplemental materials.

## 2.5 | Statistical analysis

Continuous data were presented as medians and interquartile range (IQR) and categorical data as frequencies and/or percentages. Differences between moderate and mild hemophilia severity was assessed for IPSG and HJHS scores using Mann-Whitney *U* tests; prevalence ratios were given for the presence of osteochondral damage. Subgroup analyses were performed

for observed IPSP items categorized for age  $\leq 40$  and  $>40$  years. Associations between contributing factors and IPSP scores were explored through scatterplots and univariable linear regression analyses. The following variables were evaluated: age, FVIII activity, moderate vs. mild hemophilia, AJBR, cumulative number of lifetime joint bleeds, history of a joint bleed, BMI, and activity score. Patients with an incomplete lifetime joint bleed history were removed from analyses that required data on cumulative lifetime joint bleeds. Multivariable linear regression analyses were performed with the variables age, FVIII activity, AJBR, BMI, and activity score. These variables were selected based on the results of the univariable analyses and clinical relevance. We applied stepwise backward elimination and variables were removed if  $p > .20$ . All statistical analyses were performed for the total scores and on joint level. Sensitivity analyses for the regression analyses were performed for IPSP score without effusion. The analyses were performed using SPSS 25 (IBM SPSS Statistics, Chicago, IL, USA).

## 2.6 | Data sharing statement

For original data, please contact [c.j.fijnvandraat@amsterdamumc.nl](mailto:c.j.fijnvandraat@amsterdamumc.nl).

## 3 | RESULTS

In total, 161 patients were eligible for study recruitment. After random recruitment of 51 patients, the study population target was reached. The 110 nonparticipants did not differ in age and FVIII levels in comparison with the 51 participants. MRIs were evaluated of 96 elbows (48 patients), 102 knees (51 patients), and 101 ankles (51 patients). One ankle joint was unevaluable because of a spontaneous arthrodesis and in three patients elbow scanning was not performed because of claustrophobia.

### 3.1 | Clinical characteristics

The 51 included patients had a median age of 43 years (IQR 32–50) and a median FVIII activity of 10 IU/dl (IQR 4–16). Additional patient characteristics are summarized in Table 1 for patients with moderate ( $n = 19$ ) and mild hemophilia ( $n = 32$ ) separately. Patients with moderate hemophilia had lower activity scores but were of similar age when compared with patients with mild hemophilia. The proportion of patients who had experienced a bleed in an elbow, knee, or ankle was 20%, 53%, and 57%, respectively. A larger proportion of patients with moderate hemophilia experienced bleeds in the elbow, knee, and ankle in comparison to patients with mild hemophilia (47% vs. 3%; 74% vs. 41%; and 74% vs. 47%, respectively). In 110 of 247 (45%) reported joint bleeds, a cause was known, in which 24% ( $n = 26$ ) was spontaneous, 66% ( $n = 73$ ) trauma-induced, and 10% ( $n = 11$ ) activity-related.

### 3.2 | Joint outcome

The median IPSP score was 4 (IQR 2–9) in the total cohort. Soft-tissue changes in the elbows, knees, and ankles were present in 19%, 71%, and 71% of patients, respectively. When effusion was omitted from the calculation, the remaining soft-tissue items hemosiderin and synovial hypertrophy were present in elbows, knees, and ankles in 15%, 3%, and 53% of patients, respectively. Osteochondral changes in the elbows, knees, and ankles were present in 0%, 20%, and 35% of patients, respectively. Figure 1 presents the IPSP scores per joint per item for the total cohort. When present, abnormalities were seen bilaterally in 33% of elbows, 76% of knees, and in 44% of ankles. For patients with moderate and mild hemophilia, the median IPSP-scores were 7 (IQR 2–12) and 4 (IQR 2–7), respectively ( $p = .132$ ). In the knees, osteochondral changes were observed in 16% of patients with moderate hemophilia and in 22% of patients with mild hemophilia (prevalence ratio 0.7; 95% confidence interval [CI], 0.2–2.5). In the ankles, osteochondral changes were seen more frequently as 47% and 28% of patients with moderate and mild hemophilia had these changes (prevalence ratio 1.7; 95% CI, 0.8–3.5). Osteochondral changes were observed in ankles of both patients aged  $\leq 40$  and  $>40$  years but were only observed in the knees in patients aged  $>40$  years (Table S3).

The median HJHS score was 3 (IQR 2–7) in the total cohort, 7 (IQR 4–11) in patients with moderate, and 2 (IQR 1–4) in patients with mild hemophilia ( $p < .001$ ). Figure 2 presents the HJHS scores per item for the total cohort. The most frequently scored items in knees and ankles were crepitus on motion (67% and 14%), flexion loss (15% and 11%), and extension loss (8% and 13%). The HJHS subscore in joints with osteochondral changes on MRI was abnormal in 47% of knees and in 46% of ankles.

### 3.3 | Exploration of risk factors on joint outcome

Scatterplots between potential risk factors and the total IPSP score are presented in Figure 3. In the multivariable analyses, age and AJBR were significantly associated with the total IPSP score (Table 2). For each year of age, the total IPSP score increased by 0.22 (95% CI, 0.08–0.36). Additionally, an increase of 1.0 in AJBR led to an increase in 10.94 (95% CI, 5.92–15.97) of the IPSP score. For the knees, mainly age and AJBR were associated with exhibited joint changes. For the ankles, age, FVIII activity, and AJBR were associated with joint status. Sensitivity analyses for the IPSP score without effusion yielded similar associations. The complete list of all univariable analyses (including elbows) and sensitivity analyses are presented in the supplemental materials.

### 3.4 | Joint outcome according to joint bleeding history

The lifetime clinical joint bleed history was known for 229 of 299 evaluated joints. The MRI findings of 149 joints (65%) with

	Moderate hemophilia <i>n</i> = 19	Mild hemophilia <i>n</i> = 32	Total cohort <i>n</i> = 51
Age, y	43 (38–50)	42 (29–50)	43 (32–50)
FVIII activity, IU/dl	4 (2–4)	14 (10–18)	10 (4–16)
Treatment regimen			
Full prophylaxis	1 (5)	0 (0)	1 (2)
Intermittent prophylaxis	2 (11)	0 (0)	2 (4)
On demand	16 (84)	32 (100)	48 (94)
BMI, kg/m <sup>2</sup>	28 (24–30)	25 (24–28)	26 (24–28)
Activity score (GLTEQ)			
Sedentary	7 (37)	6 (19)	13 (26)
Moderately active	5 (26)	4 (13)	9 (17)
Active	7 (37)	22 (69)	29 (57)
History of joint surgery <sup>a</sup>	3 (16)	0 (0)	3 (6)
Joint bleeding history			
Zero joint bleeds <sup>b</sup>			
Any joint	1 (5)	10 (31)	11 (22)
Elbows	3 (16)	26 (81)	29 (57)
Knees	2 (11)	17 (53)	19 (37)
Ankles	2 (11)	14 (44)	16 (31)
Lifetime cumulative joint bleeds <sup>c</sup>			
Any joint	12 (5–23)	1 (0–2)	2 (0–7)
Elbows	1 (0–2)	0 (0–0)	0 (0–0)
Knees	5 (1–7)	0 (0–1)	0 (0–2)
Ankles	5 (1–9)	0 (0–1)	1 (0–2)
AJBR <sup>d</sup>	0.2 (0.0–0.4)	0.0 (0.0–0.1)	0.0 (0.0–0.2)

Note: Values are given in medians and interquartile ranges (IQR) or *n* (%).

Abbreviations: AJBR, annual joint bleeding rate; BMI, body mass index; F, factor; GLTEQ, Godin Leisure-Time Exercise Questionnaire.

<sup>a</sup>In two patients debridement of an ankle, in one patient meniscus surgery of a knee.

<sup>b</sup>Unknown in 12 patients (seven moderate, five mild) for specific data on elbows. Unknown in five patients (three moderate, two mild) for specific data on knees. Unknown in six patients (three moderate, three mild) for specific data on ankles.

<sup>c</sup>Unknown in 16 patients (10 moderate, six mild) for specific data on any joint and ankles. Unknown in 15 patients (10 moderate, five mild) for specific data on elbows and knees.

<sup>d</sup>Median follow-up in all 51 included patients was 11 years (IQR 11–12).

a negative and 80 (35%) joints with a positive lifetime history of joint bleeding are presented in Table 3. In the 149 bleed-free joints, hemosiderin depositions were observed in 21 (14%) joints and osteochondral changes were detected in 13 (9%) joints. In the 80 joints in which bleeding occurred, hemosiderin depositions were seen in 19 (24%) and osteochondral changes in 23 (29%) joints. Joints with hemosiderin deposits had more recently suffered from a bleed than joints without hemosiderin (median 4 [IQR 3–8] and 16 [IQR 5–23] years ago, respectively). Focusing on joint abnormalities in bleed-free joints at an individual patient level, 17 patients demonstrated soft-tissue or osteochondral abnormalities (effusion excluded) in a bleed-free joint. These patients had a median age of 49 years (IQR 37–52), a median factor level of 15 IU/dl (IQR 10–20), and 15 had mild hemophilia (88%).

Figure 4 presents examples of MRI examinations of joints with no history of bleeds.

## 4 | DISCUSSION

In this cross-sectional study, we explored the joint status in 51 patients with nonsevere hemophilia A aged 24–55 years. Despite a low frequency of joint bleeds, a substantial proportion of this population presented joint changes on MRI, the ankles being most affected. This is consistent with previous MRI studies in severe hemophilia that also reported worse joint outcome for ankles compared with knees and elbows.<sup>14,15,22,23</sup> In our explorative analysis, age and joint bleeding rates were significantly associated with deterioration of

TABLE 1 Demographic and clinical patient characteristics

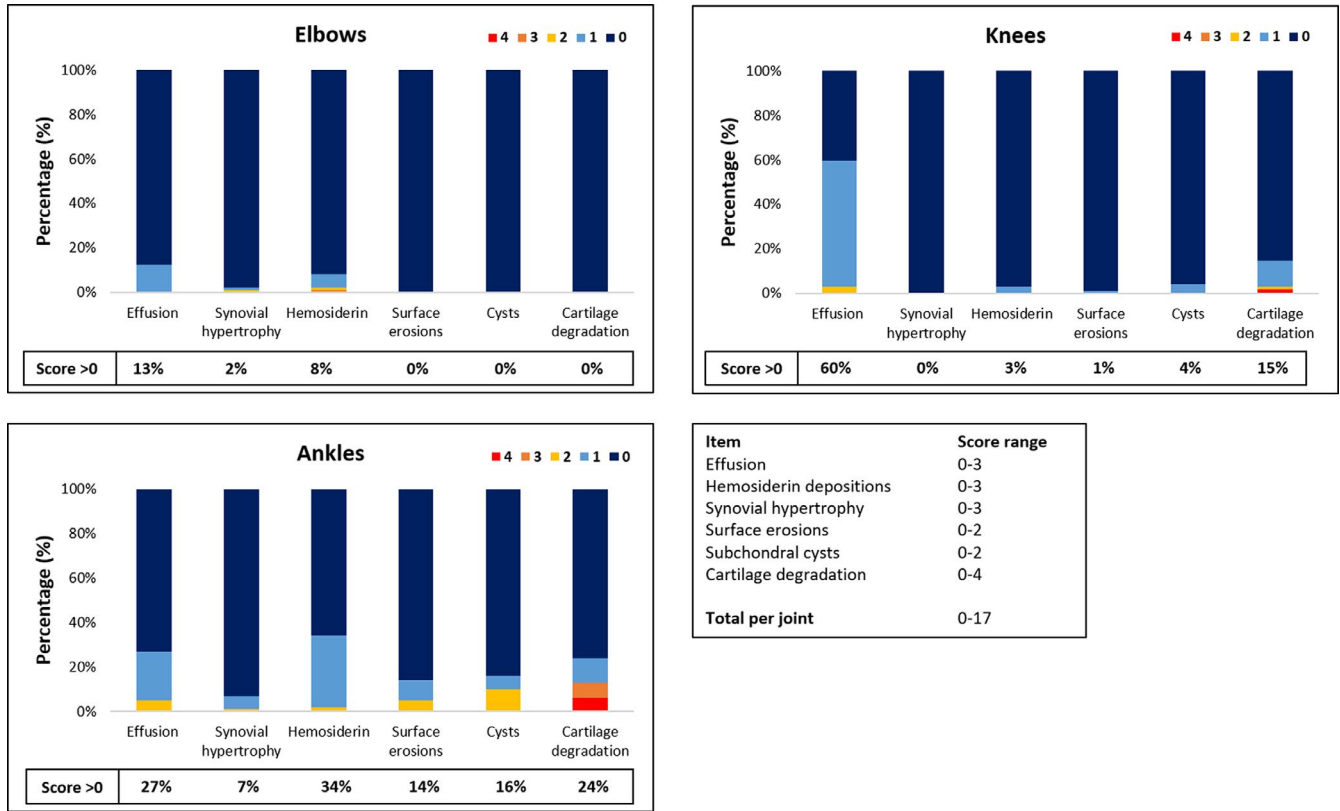


FIGURE 1 IPSG scores per item for evaluated elbows ( $n = 96$ ), knees ( $n = 102$ ), and ankles ( $n = 101$ ). The potential ranges in scores per item are shown in the lower right of the figure. The percentages in the box represent the proportion of joints with an IPGS score  $>0$  for the corresponding item. IPGS, International Prophylaxis Study Group.

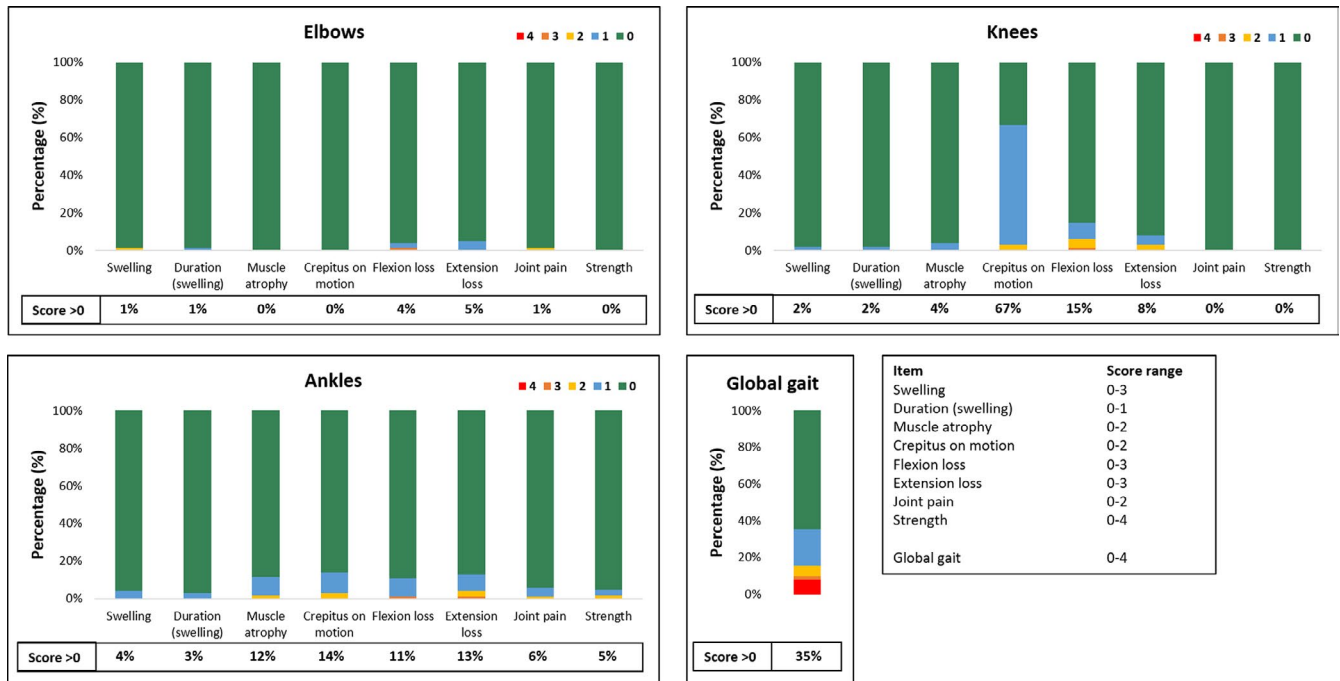
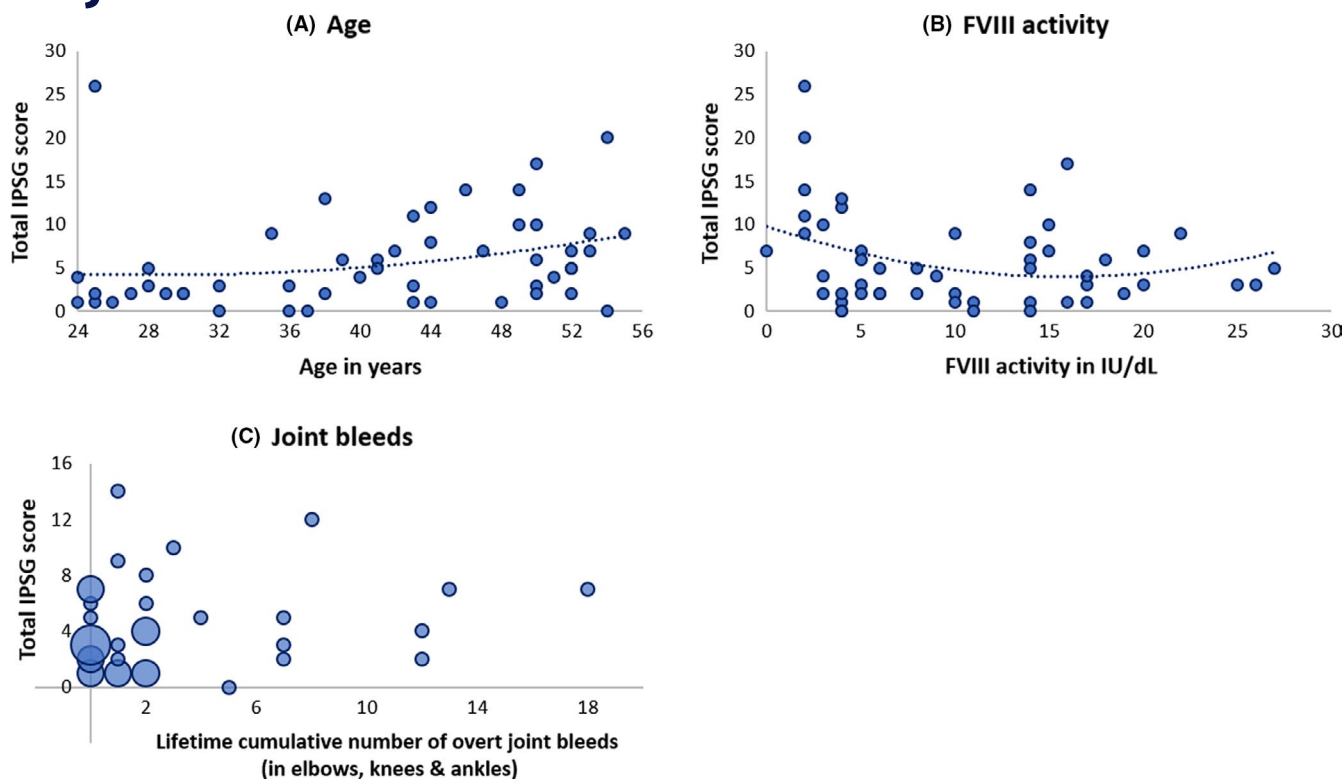


FIGURE 2 HJHS scores per item for evaluated elbows ( $n = 102$ ), knees ( $n = 102$ ), and ankles ( $n = 102$ ). The global gait score is presented for all patients ( $n = 51$ ). The potential ranges in scores per item are shown in the lower right of the figure. The percentages in the box represent the proportion of joints (or patients for global gait score) with an IPGS score  $>0$  for the corresponding item. HJHS, Haemophilia Joint Health Score; IPGS, International Prophylaxis Study Group.





**FIGURE 3** Scatterplots of the total IPSG score against (A) age, (B) FVIII activity, and (C) lifetime cumulative number of overt joint bleeds. A polynomial line of fit is shown. In panel C, the size of the circles correspond to the proportion of patients and one outlier (case with 57 joint bleeds and an IPSG score of 26) was removed to allow more detailed scaling. IPSG, International Prophylaxis Study Group.

**TABLE 2** Univariable and multivariable linear regression analyses for total IPSG score and IPSG subscores for knees and ankles

Variables	Univariable			Multivariable		
	$\beta$	95% CI	<i>p</i>	$\beta$	95% CI	<i>p</i>
<b>Total</b>						
Age (y)	0.14	-0.01-0.30	0.072	0.22	0.08-0.36	0.002
FVIII activity (IU/dl)	-0.17	-0.38-0.05	0.125	-	-	-
AJBR (elbows, knees, and ankles)	8.85	3.56-14.15	0.002	10.94	5.92-15.97	<0.001
BMI (kg/m <sup>2</sup> )	0.14	-0.26-0.54	0.489	-	-	-
Activity score (GLTEQ)	-0.01	-0.05-0.05	0.855	-	-	-
<b>Knees</b>						
Age (y)	0.08	0.03-0.13	0.002	0.10	0.05-0.15	<0.001
FVIII activity (IU/dl)	0.04	-0.03-0.12	0.248	0.05	-0.03-0.12	0.200
AJBR (knees)	2.66	-3.24-8.57	0.369	4.47	-1.53-10.47	0.140
BMI (kg/m <sup>2</sup> )	0.10	-0.03-0.23	0.131	-	-	-
Activity score (GLTEQ)	0.01	-0.01-0.02	0.478	0.01	-0.00-0.03	0.106
<b>Ankles</b>						
Age (y)	0.08	-0.06-0.22	0.265	0.13	0.00-0.25	0.047
FVIII activity (IU/dl)	-0.18	-0.38-0.01	0.058	-0.13	-0.31-0.05	0.153
AJBR (ankles)	21.20	7.96-34.43	0.002	21.42	8.06-34.78	0.002
BMI (kg/m <sup>2</sup> )	0.07	-0.28-0.43	0.684	-	-	-
Activity score (GLEQ)	-0.01	-0.05-0.04	0.780	-	-	-

Note: The 95% confidence intervals (CIs) for the unstandardized coefficients  $\beta$  are shown.

Abbreviations: AJBR, annual joint bleeding rate; BMI, body mass index; GLTEQ, Godin Leisure-Time Exercise Questionnaire.

TABLE 3 Joint outcome according to lifetime joint bleed history

Positive lifetime joint bleed history	Left elbow <i>n</i> = 4	Right elbow <i>n</i> = 7	Left knee <i>n</i> = 16	Right knee <i>n</i> = 19	Left ankle <i>n</i> = 15	Right ankle <i>n</i> = 19	Total <i>n</i> = 80
IPSG total scores >0							
Soft-tissue score	1 (25)	2 (29)	7 (44)	12 (63)	11 (73)	8 (42)	41 (51)
Osteochondral score	0 (0)	0 (0)	4 (25)	4 (21)	7 (47)	8 (42)	23 (29)
Total score	1 (25)	2 (29)	9 (56)	14 (74)	11 (73)	9 (47)	46 (58)
IPSG subitem scores >0							
Effusion	1 (25)	2 (29)	7 (44)	12 (63)	6 (40)	3 (16)	31 (39)
Synovial hypertrophy	1 (25)	1 (14)	0 (0)	0 (0)	1 (7)	2 (11)	5 (6)
Hemosiderin depositions	1 (25)	1 (14)	1 (6)	1 (5)	8 (53)	7 (37)	19 (24)
Surface erosions	0 (0)	0 (0)	1 (6)	0 (0)	3 (20)	6 (32)	10 (13)
Subchondral cysts	0 (0)	0 (0)	1 (6)	1 (5)	3 (20)	7 (37)	12 (15)
Cartilage degradation	0 (0)	0 (0)	4 (25)	4 (21)	7 (47)	7 (37)	22 (28)
Negative lifetime joint bleed history	Left elbow <i>n</i> = 32	Right elbow <i>n</i> = 28	Left knee <i>n</i> = 25	Right knee <i>n</i> = 22	Left ankle <i>n</i> = 21	Right ankle <i>n</i> = 21	Total <i>n</i> = 149
IPSG total scores >0							
Soft-tissue score	2 (6)	6 (21)	16 (64)	15 (68)	10 (48)	12 (57)	61 (41)
Osteochondral score	0 (0)	0 (0)	3 (12)	4 (18)	4 (19)	2 (10)	13 (9)
Total score	2 (6)	6 (21)	16 (64)	15 (68)	11 (52)	12 (57)	62 (42)
IPSG subitem scores >0							
Effusion	2 (6)	6 (21)	16 (64)	15 (68)	5 (23)	7 (33)	51 (34)
Synovial hypertrophy	0 (0)	0 (0)	0 (0)	0 (0)	3 (14)	0 (0)	3 (2)
Hemosiderin depositions	1 (3)	5 (18)	0 (0)	1 (5)	7 (33)	7 (33)	21 (14)
Surface erosions	0 (0)	0 (0)	0 (0)	0 (0)	2 (10)	0 (0)	2 (1)
Subchondral cysts	0 (0)	0 (0)	0 (0)	2 (9)	3 (14)	0 (0)	5 (3)
Cartilage degradation	0 (0)	0 (0)	3 (12)	4 (18)	3 (14)	2 (10)	12 (8)

Note: Values are given in *n* (%). MRI findings are presented for the 80 and 149 joints with a positive and negative lifetime joint bleed history, respectively.

Abbreviation: IPSG, International Prophylaxis Study Group.

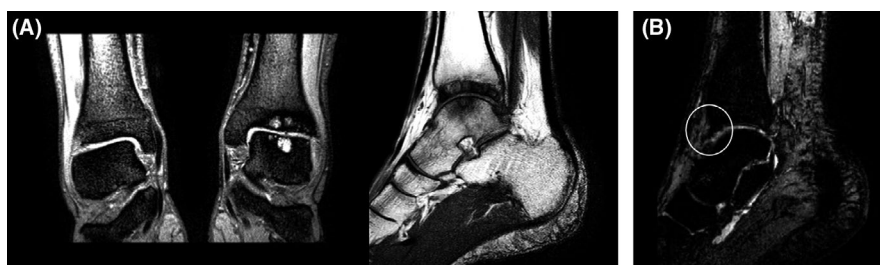

FIGURE 4 MRI examinations of joints with no history of bleeds. (A) A 44-year-old patient with a FVIII activity of 4.3 IU/dl. Despite no history of joint bleeds in the left ankle, MRI of this joint shows multiple subchondral cysts and severe osteochondral damage. (B) A 49-year-old patient with a FVIII activity of 14.8 IU/dl and a history of zero joint bleeds in the ankles. MRI of the left ankle shows a small hemosiderin deposition (circle). F, factor; IPSG, International Prophylaxis Study Group; MRI, magnetic resonance imaging.

MRI scores. Despite this association, we did observe considerable discrepancies between clinically evident joint bleeds and joint abnormalities. Some patients with a history of numerous bleeds had unaffected joints, whereas patients with zero overt joint bleeds demonstrated soft-tissue and osteochondral changes. In previous

studies, it has been hypothesized that subclinical bleeds may account for unnoticed joint deterioration as weak correlations were reported between the number of overt joint bleeds and changes as detected by MRI.<sup>14,15</sup> This is in line with our study because hemosiderin depositions were present in 14% of joints without documented



joint bleeds. Consequently, it remains a challenge to determine which patients are likely to develop joint damage.

#### 4.1 | Joint status in nonsevere hemophilia

Because this is the first MRI study of the joints in nonsevere hemophilia, no comparative MRI data are currently available. For clinical function, we demonstrated that the median total HJHS scores were 3 (IQR 2–7) in the total cohort and 7 (IQR 4–11) in patients with moderate hemophilia. The latter results are slightly higher compared with the findings of a study among Nordic patients with moderate hemophilia, which showed a median HJHS score of 4 (IQR 1–10). This may be explained by a difference in age because these patients were younger with a median age of 28 years (IQR 13–52) compared with 43 years (IQR 38–50) for the patients with moderate hemophilia in the present study.<sup>24</sup> In addition, a higher proportion of their study population received prophylaxis (38% vs. 16%), which may have contributed to the lower scores observed. Similar to their study, the most frequent findings were crepitus on motion and flexion and extension loss.<sup>25</sup> Other recent work detected arthropathy in 37% of patients with mild hemophilia using HJHS and ultrasound, in which age and baseline factor levels were reported as risk factors for presence of arthropathy.<sup>26</sup>

Previous studies on MRI of the joints in hemophilia have focused on patients with severe hemophilia. The occurrence of iron accumulation in the joint can lead to a range of pathological processes, including inflammation and synovial proliferation. Consequently, the joint becomes more vulnerable to repeated bleeding.<sup>6</sup> This process is revealed on MRI by synovial hypertrophy and hemosiderin deposition. In our population, hemosiderin depositions were seen in 8% of elbows, 3% of knees, and 34% of ankles. The relevance of these findings were highlighted by Foppen and colleagues; they showed that synovial hypertrophy, with concurrent hemosiderin in 88%, was predictive for future bleeding and that all abnormal IPSPG findings except for joint effusion were associated with development of radiographic joint changes.<sup>19</sup> It is of interest that in the present study, in 76% of joints with a positive history of hemarthrosis no hemosiderin depositions were observed. The bleeds in these joints occurred a median of 16 years before study participation. This confirms the observations of an earlier study that did not detect hemosiderin in joints with a bleed that occurred more than 3 years ago.<sup>23</sup> Altogether, these data suggest that hemosiderin may disappear over time and hemosiderin depositions reflect relatively recent bleeds, and that some of these patients may be at increased risk for joint deterioration.

Will the MRI findings of our study result in functional joint problems? This needs further follow-up of our study population, but some indication can be found in data from surveys. In a recent national survey in the Netherlands, 24% of nonsevere hemophilia patients reported an orthopedic surgery in the past and 10% specifically underwent joint replacement.<sup>27</sup> This incidence is higher than in the general population because the prevalence of a hip or knee joint replacement was 5% in males aged 60+ years.<sup>28</sup> These data are also in line with a Swedish study that demonstrated an increased incidence of

arthropathy diagnosis among individuals with mild hemophilia compared with the general population.<sup>9</sup> Another study showed that 16 of 34 (47%) adults with nonsevere hemophilia A reported joint pain and 17 of 33 patients (52%) had ankle arthropathy on x-ray.<sup>10</sup> These observations suggest that some of the joint changes could lead to subsequent joint impairment later in life.

#### 4.2 | Joint status in the general population

Comparison of our results with data from a healthy population may provide insight into the clinical relevance of the observed findings. Unfortunately, there is a paucity of studies using similar hemophilia-specific scoring tools in healthy males. Only one study group evaluated the HJHS and additive MRI score in a cohort of 30 healthy men.<sup>20</sup> The participants had a median HJHS score of 0 (range 0–3) and all had a MRI score of 0. However, these healthy men were aged 18–26 years and therefore substantially younger than our study cohort aged 24–55 years. Furthermore, joint effusion was not part of the MRI score used. There is debate on the relative importance of this item, as a previous study demonstrated similar to even higher positive effusion scores in healthy active men compared with hemophilia patients.<sup>29</sup> Also in our study, effusion was often present in knees and to a lesser extent in ankles. However, soft-tissue changes other than effusion were still detected in ankles in 53% of all patients.

In the general population, previous MRI studies in asymptomatic adults revealed that knee abnormalities are relatively common and progressively increase with age. In a systematic review, the estimated prevalence of cartilage defects on MRI was 11% and 43% in adults aged <40 and ≥40 years, respectively. Furthermore, the prevalence of subchondral cysts ranged from 0% to 24%.<sup>30</sup> For ankles, few MRI studies have been conducted in asymptomatic joints. One previous study in middle-aged healthy individuals demonstrated that cartilage loss and subchondral cysts were both present in 1.5% of ankle joints, which implies that such lesions are overall uncommon.<sup>31</sup> Articular hemosiderin has been described in individuals without hemophilia, although rarely and to our knowledge only in case reports.<sup>32–34</sup> Based on these data, we hypothesize that the majority of the MRI abnormalities found in the ankles of our study population are truly signs of hemophilia-related changes, whereas observed knee lesions may reflect normal age-related joint degeneration to a greater extent. This is in line with the low prevalence of ankle osteoarthritis and the high prevalence of knee osteoarthritis in the general population.<sup>35,36</sup> The low frequency of primary joint degeneration of ankles in the general population was also confirmed by a study investigating donor joints, reporting no ankle degeneration in absence of abnormalities in the knees.<sup>37</sup> Moreover, our hypothesis is supported by our finding that 34% of ankles had hemosiderin deposits compared with 3% of knees. In addition, we found that in patients aged ≤40 years osteochondral changes were observed in ankles but not in knees. And finally, the association between AJBR and ankle scores was much stronger in comparison to knee scores ( $\beta$  21.42 with 95% CI, 8.06–34.78 vs.  $\beta$  4.47 with 95% CI, –1.53 to 10.47).

### 4.3 | Strengths and limitations

This is the first study with a specific focus on joint assessment using MRI in nonsevere hemophilia. All investigations were performed by the same investigators during one study visit, thereby limiting potential inter-reader variability or differences associated with another setting. Another key strength in our study is that we performed MRI of the elbows, knees, and ankles and therefore were able to give a complete overview of the joint status. For the patients included, all lifetime joint bleeds were collected from the medical files, irrespective of treatment provided for bleeds. Although it is unlikely that clinically evident joint bleeds were missed by this approach, we acknowledge the limitations of retrospective data collection and that small unrecognized bleeds or bleeds that were treated with desmopressin at home and not reported to the treatment center could have been overlooked. For our analyses on joints with a positive and negative lifetime bleeding history, only joints were included where this information was clearly stated in the medical files. Despite our efforts, the exact number of lifetime cumulative joint bleeds was lacking for approximately one-third of the study population, which hampered further analyses into cumulative bleeds and joint outcome.

Because we included a subset of 51 patients of 161 patients that were eligible for inclusion, it could be possible that a selection of patients with joint problems were more willing to participate. We found that the distributions of age and FVIII level were similar across participants and nonparticipants. In addition, the median AJBR was 0 (IQR 0.0–0.2) in our study population, which suggests that our findings are overall representative for patients with low joint bleeding rates.

Another limitation is that seven joints could not be evaluated for the IPSP score because of unevaluable MRI scans. To enable calculation of the median MRI scores, we assumed a score of 0 points for these joints. Additionally, as MRIs were conducted without contrast, the degree of synovial hypertrophy may have been underrated,<sup>38</sup> resulting in an underestimation of the reported joint scores.

Because of the relatively small sample size, our multivariable linear regression analysis was explorative and demonstrated which variables contributed most strongly to joint outcome within our study population. Variables with a weak effect on the IPSP score may therefore not have remained associated in the final model. Hence, causal relationships between determinants and joint outcome need to be investigated in more depth within a larger prospective study.

### 4.4 | Clinical implications

Our observations suggest that more intensive monitoring of joint health and preventive treatment strategies are warranted, particularly for patients with moderate hemophilia. In the mild hemophilia population that generally receives on-demand therapy, pragmatic

approaches may include adequate counseling and highlighting the importance to alert the treatment center in case of joint complaints. Especially in this patient group, which rarely experiences bleeding events, minor joint bleeds may not be recognized as such and unfortunately remain untreated. Our data also suggest that joint status should remain an important outcome measure in studies evaluating the effects of nonreplacement therapies in patients with severe hemophilia. These patients are converted to a nonsevere phenotype with an estimated FVIII level equivalent to >10 IU/dl.<sup>39</sup>

Because the ankles were most frequently and structurally affected, we propose that these joints should be the primary focus for monitoring, in line with previous advice for patients with severe hemophilia.<sup>22</sup> In this regard, promising non-invasive methods such as point-of-care ultrasound may be valuable to visualize ankle joints at routine check-ups.<sup>40</sup> Ultrasound may also be used for follow-up to evaluate progression of joint abnormalities. Previous ultrasound evaluation in patients with moderate hemophilia reported subclinical pathology in 5% of joints with an excellent clinical function (HJHS of 0), supporting the value of this modality for low-threshold joint evaluation in this population.<sup>25</sup> MRI may be more suitable for a comprehensive evaluation of problematic joints. However, the effects of intensified monitoring and responsiveness to subsequent therapy in case of observed joint changes are yet to be established. Future studies are needed to further elucidate the clinical relevance and long-term outcomes of these joint changes in nonsevere hemophilia patients and the potential benefits of regular monitoring, counseling, and other preventive measures. In addition, future investigations into IPSP scores including healthy controls aged >28 years are ultimately needed to obtain reference values and put observations in hemophilia patients in perspective.

In conclusion, the results of our study show that a substantial proportion of patients with nonsevere hemophilia A exhibits joint changes on MRI despite low joint bleed rates. This suggests that more awareness of joint health in this population is needed.

### ACKNOWLEDGMENTS

The authors thank Sandra van den Berg and Raschel van Luijk (Amsterdam UMC, Amsterdam, the Netherlands) for their technical support and help in conducting the MRI scans. In addition, the authors thank Cees Nooij and Wypke de Boer for their training on assessment of the Haemophilia Joint Health Score.

This work was supported by grants from Novo Nordisk, CSL Behring (Prof. Heimburger Award 2016) and Bayer (Outcomes Research Award of the Bayer Hemophilia Awards Program 2015). The funding sponsors had no role in the design and conduct of the study; collection, management, analysis, and interpretation of the data; and preparation, review, and approval of the manuscript.

### CONFLICT OF INTERESTS

S. C. G. has received an unrestricted research grant from Sobi. M. C. has received financial support for research from Bayer, CSL Behring, Daiichi Sankyo, Portola/Alexion, Roche, Sanquin Blood Supply, and UniQure and consultancy or lecturing fees from Bayer, CSL Behring,

Medcon International, MEDtalks, Novo Nordisk, Pfizer, and Sobi. L.G. R. R. received the Sobi Young Investigators Award 2020 and a travel grant from Sobi (2019). M. J. H. A. K. has received unrestricted financial support for research from Bayer, Daiichi Sankyo, and Sobi and lecturing fees from Bayer en Roche, all payments to the institute. M. H. C. has received investigator-initiated research and travel grants as well as speaker fees over the years from the Netherlands Organisation for Scientific Research (NWO), the Netherlands Organization for Health Research and Development (ZonMw), the Dutch "Innovatiefonds Zorgverzekeraars", Baxter/Baxalta/Shire/Takeda, Pfizer, Bayer Schering Pharma, CSL Behring, Sobi Biogen, Novo Nordisk, Novartis, and Nordic Pharma, and has served as a steering board member for Roche, Bayer, and Novartis. All grants, awards and fees go to the Erasmus MC. F. W. G. L. received unrestricted research grants from CSL Behring, Shire/Takeda, SOBI, and uniQure. He is a consultant for CSL Behring, Takeda, Biomarin, and uniQure, of which the fees go to the University. He received travel support from SOBI. He is DSMB member of a study sponsored by Roche. The institution of K. F. has received unrestricted research grants from Sobi, Pfizer, CSL Behring, and Novo Nordisk and her institution received consultancy fees from Grifols, Takeda, Novo Nordisk, and Roche. A. Z., F. R. K., R. H., B. A. H., and M. M. have no potential conflicts of interest.

## AUTHOR CONTRIBUTIONS

Anne-Fleur Zwagemaker and Fabienne R. Kloosterman collected, cleaned, analyzed, and interpreted the data. Anne-Fleur Zwagemaker wrote the manuscript. Karin Fijnvandraat designed the study. Robert Hemke and Mario Maas designed the MRI scanning protocol and scored the MRI scans. Samantha C. Gouw, Michiel Coppens, Lorenzo G. R. Romano, Marieke J. H. A. Kruij, Marjon H. Cnossen, Frank W. G. Leebeek, and Karin Fijnvandraat collected data or supervised data collection. Barbara A. Hutten provided statistical advice. All authors reviewed this work and approved the final version of the manuscript.

## ORCID

Anne-Fleur Zwagemaker  <https://orcid.org/0000-0002-8848-1229>  
 Fabienne R. Kloosterman  <https://orcid.org/0000-0003-4988-1462>  
 Robert Hemke  <https://orcid.org/0000-0002-0826-302X>  
 Samantha C. Gouw  <https://orcid.org/0000-0002-1957-4122>  
 Michiel Coppens  <https://orcid.org/0000-0001-6891-9062>  
 Lorenzo G. R. Romano  <https://orcid.org/0000-0003-0348-658X>  
 Marieke J. H. A. Kruij  <https://orcid.org/0000-0002-0265-4871>  
 Marjon H. Cnossen  <https://orcid.org/0000-0003-1557-2995>  
 Frank W. G. Leebeek  <https://orcid.org/0000-0001-5677-1371>  
 Barbara A. Hutten  <https://orcid.org/0000-0002-9243-0037>  
 Mario Maas  <https://orcid.org/0000-0001-6785-5167>  
 Karin Fijnvandraat  <https://orcid.org/0000-0003-0904-4360>

## REFERENCES

- White GC 2nd, Rosendaal F, Aledort LM, Lusher JM, Rothschild C, Ingerslev J. Definitions in hemophilia. Recommendation of the scientific subcommittee on factor VIII and factor IX of the scientific and standardization committee of the International Society on Thrombosis and Haemostasis. *Thromb Haemost.* 2001;85(3):560.
- Srivastava A, Santagostino E, Dougall A, et al. WFH Guidelines for the management of hemophilia. *Haemophilia.* 2020;26(Suppl 6):1-158.
- Lobet S, Hermans C, Lambert C. Optimal management of hemophilic arthropathy and hematomas. *J Blood Med.* 2014;5:207-218.
- Gualtierotti R, Solimeno LP, Peyvandi F. Hemophilic arthropathy: current knowledge and future perspectives. *J Thromb Haemost.* 2021;19(9):2112-2121.
- van Vulpen LFD, Mastbergen SC, Lafeber F, Schutgens REG. Differential effects of bleeds on the development of arthropathy - basic and applied issues. *Haemophilia.* 2017;23(4):521-527.
- van Vulpen LFD, Holstein K, Martinoli C. Joint disease in haemophilia: pathophysiology, pain and imaging. *Haemophilia.* 2018;24(Suppl 6):44-49.
- Di Minno M, Ambrosino P, Franchini M, Coppola A, Di Minno G. Arthropathy in patients with moderate hemophilia a: a systematic review of the literature. *Semin Thromb Hemost.* 2013;39(7):723-731.
- Plug I, van der Bom JG, Peters M, et al. Thirty years of hemophilia treatment in the Netherlands, 1972-2001. *Blood.* 2004;104(12):3494-3500.
- Osooli M, Lövdahl S, Steen Carlsson K, et al. Comparative burden of arthropathy in mild haemophilia: a register-based study in Sweden. *Haemophilia.* 2017;23(2):e79-e86.
- Ling M, Heysen JP, Duncan EM, Rodgers SE, Lloyd JV. High incidence of ankle arthropathy in mild and moderate haemophilia A. *Thromb Haemost.* 2011;105(2):261-268.
- Hilliard P, Funk S, Zourikian N, et al. Hemophilia joint health score reliability study. *Haemophilia.* 2006;12(5):518-525.
- Foppen W, Fischer K, van der Schaaf IC. Imaging of hemophilic arthropathy: awareness of pitfalls and need for standardization. *Haemophilia.* 2017;23(5):645-647.
- Doria AS. State-of-the-art imaging techniques for the evaluation of hemophilic arthropathy: present and future. *Haemophilia.* 2010;16(Suppl 5):107-114.
- Manco-Johnson MJ, Abshire TC, Shapiro AD, et al. Prophylaxis versus episodic treatment to prevent joint disease in boys with severe hemophilia. *N Engl J Med.* 2007;357(6):535-544.
- Kraft J, Blanchette V, Babyn P, et al. Magnetic resonance imaging and joint outcomes in boys with severe hemophilia A treated with tailored primary prophylaxis in Canada. *J Thromb Haemost.* 2012;10(12):2494-2502.
- Fischer K, van der Bom JG, Mauser-Bunschoten EP, et al. The effects of postponing prophylactic treatment on long-term outcome in patients with severe hemophilia. *Blood.* 2002;99(7):2337-2341.
- Lundin B, Manco-Johnson ML, Ignas DM, et al. An MRI scale for assessment of hemophilic arthropathy from the International Prophylaxis Study Group. *Haemophilia.* 2012;18(6):962-970.
- Nuss R, Kilcoyne R. *The MRI Atlas of Hemophilic Arthropathy.* Professional Publishing Group, Ltd; 2002.
- Foppen W, van der Schaaf IC, Beek FJA, Mali W, Fischer K. MRI predicts 5-year joint bleeding and development of arthropathy on radiographs in hemophilia. *Blood Adv.* 2020;4(1):113-121.
- Sluiter D, Foppen W, de Kleijn P, Fischer K. Haemophilia Joint Health Score in healthy adults playing sports. *Haemophilia.* 2014;20(2):282-286.
- Godin G. The Godin-Shephard leisure-time physical activity questionnaire. *Health Fitness J Canada.* 2011;4(1):18-22.
- Oldenburg J, Zimmermann R, Katsarou O, et al. Controlled, cross-sectional MRI evaluation of joint status in severe haemophilia A patients treated with prophylaxis vs. on demand. *Haemophilia.* 2015;21(2):171-179.
- Den Uijl IE, De Schepper AM, Camerlinck M, Grobbee DE, Fischer K. Magnetic resonance imaging in teenagers and young adults with limited hemophilic arthropathy: baseline results from a prospective study. *Haemophilia.* 2011;17(6):926-930.

24. Måseide RJ, Berntorp E, Astermark J, et al. Joint health and treatment modalities in Nordic patients with moderate haemophilia A and B - the MoHem study. *Haemophilia*. 2020;26(5):891-897.
25. Måseide RJ, Berntorp E, Astermark J, et al. Haemophilia early arthropathy detection with ultrasound and haemophilia joint health score in the moderate haemophilia (MoHem) study. *Haemophilia*. 2021;27(2):e253-e259.
26. De la Corte-Rodriguez H, Rodriguez-Merchan EC, Alvarez-Roman MT, Martin-Salces M, Rivas-Pollmar I, Jimenez-Yuste V. Arthropathy in people with mild haemophilia: exploring risk factors. *Thromb Res*. 2022;211:19-26.
27. Hassan S, van Balen EC, Smit C, et al. Health- and treatment outcomes of patients with hemophilia in the Netherlands, 1972-2019. *J Thromb Haemost*. 2021;19(10):2394-2406.
28. Steel N, Melzer D, Gardener E, McWilliams B. Need for and receipt of hip and knee replacement—a national population survey. *Rheumatology (Oxford)*. 2006;45(11):1437-1441.
29. Foppen W, van der Schaaf IC, Witkamp TD, Fischer K. Is joint effusion on MRI specific for haemophilia? *Haemophilia*. 2014;20(4):582-586.
30. Culvenor AG, Øiestad BE, Hart HF, Stefanik JJ, Guermazi A, Crossley KM. Prevalence of knee osteoarthritis features on magnetic resonance imaging in asymptomatic uninjured adults: a systematic review and meta-analysis. *Br J Sports Med*. 2019;53(20):1268-1278.
31. van Putte-Katier N, van Ochten JM, van Middelkoop M, Bierma-Zeinstra SM, Oei EH. Magnetic resonance imaging abnormalities after lateral ankle trauma in injured and contralateral ankles. *Eur J Radiol*. 2015;84(12):2586-2592.
32. Khasawneh RA, Mohaidat ZM, Gharaibeh MM, Hdeeb A. Post-traumatic hemosiderotic synovitis of the knee mimicking pigmented villonodular synovitis on magnetic resonance imaging (MRI) in a child: a case report. *Am J Case Rep*. 2021;22:e931992.
33. Jayalakshmi V, Chikhale NP, Mishra A, Cherian S. Nonhemophilic hemosiderotic synovitis of the knee: a case report and review of literature. *Indian J Pathol Microbiol*. 2014;57(3):473-475.
34. Bartlett J, Lidder SS, Bucknill AT. Haemosiderotic synovitis secondary to anticoagulant use: an unusual mechanism of failure of a unicompartmental knee replacement. *Case Rep Orthop*. 2019;2019:3959278.
35. Zhang JF, Song LH, Wei JN, et al. Prevalence of and risk factors for the occurrence of symptomatic osteoarthritis in rural regions of Shanxi Province. *China. Int J Rheum Dis*. 2016;19(8):781-789.
36. Huch K, Kuettner KE, Dieppe P. Osteoarthritis in ankle and knee joints. *Semin Arthritis Rheum*. 1997;26(4):667-674.
37. Muehleman C, Margulis A, Bae WC, Masuda K. Relationship between knee and ankle degeneration in a population of organ donors. *BMC Med*. 2010;8:48.
38. Soliman M, Daruge P, Dertkigil SSJ, et al. Imaging of haemophilic arthropathy in growing joints: pitfalls in ultrasound and MRI. *Haemophilia*. 2017;23(5):660-672.
39. Kizilocak H, Marquez-Casas E, Malvar J, Carmona R, Young G. Determining the approximate factor VIII level of patients with severe haemophilia A on emicizumab using in vivo global haemostasis assays. *Haemophilia*. 2021;27(5):730-735.
40. Ligocki CC, Abadeh A, Wang KC, Adams-Webber T, Blanchette VS, Doria AS. A systematic review of ultrasound imaging as a tool for evaluating haemophilic arthropathy in children and adults. *Haemophilia*. 2017;23(4):598-612.

### SUPPORTING INFORMATION

Additional supporting information may be found in the online version of the article at the publisher's website.

**How to cite this article:** Zwagemaker A-F, Kloosterman FR, Hemke R, et al. Joint status of patients with nonsevere hemophilia A. *J Thromb Haemost*. 2022;20:1126-1137. doi:[10.1111/jth.15676](https://doi.org/10.1111/jth.15676)