

High Median Nerve Paralysis: Is the Hand of Benediction or Preacher's Hand A Correct Sign?

Liron S. Duraku, MD, PhD*
 Ton A.R. Schreuders, PhD†
 Dominic M. Power, MD‡
 Vaikunthan Rajaratnam, MD§
 Tahseen Chaudhry, MD‡
 Caroline A. Hundepool, MD,
 PhD†
 Jelle M. Zuidam, MD, PhD†

Background: High median nerve injuries are commonly presented in textbooks as adopting the typical posture of hand of benediction or preacher's hand. This study aimed to show that the hand of benediction or preacher's hand is incorrectly associated with a high median nerve paralysis.

Methods: A retrospective review of four cases with a high median nerve injury is presented. Diagnosis of a high median nerve injury was performed by means of intraoperative findings, electrodiagnostic studies, or ultrasound imaging. None of the patients presented in this study had a hand of benediction on physical examination despite the presence of a high median nerve lesion.

Results: All four patients with high median nerve injuries showed a similar hand posture when attempting to make a fist. Firstly, the index finger still flexed at the metacarpophalangeal joint because of the ulnar innervated interossei muscles. Secondly the thumb is completely abducted at the carpometacarpal joint and extended at the interphalangeal joint. Lastly, middle finger flexion is possible due to dual innervation of its flexor digitorum profundus by the ulnar nerve as well as due to the quadriga phenomenon.

Conclusions: The clinical appearance of a high median nerve palsy is different from the classical hand of benediction or preacher's hand posture pointing finger. We have shown that this incorrect association can result in delayed referral of patients with high median nerve injuries. (*Plast Reconstr Surg Glob Open* 2022;10:e4598; doi: 10.1097/GOX.0000000000004598; Published online 28 October 2022.)

INTRODUCTION

Delayed referral of traumatic peripheral nerve injuries to specialized care increases the chance of more significant loss of quality of life, neuropathic pain, more functional impairment, and a larger socioeconomic impact of predominantly young patients.^{1,2} Only 9% of nerve injuries are diagnosed at the emergency department, and 39% after hospital discharge³ with delayed diagnosis

precluding early operative management.⁴⁻⁶ Early diagnosis and prompt treatment is crucial for optimal outcomes in peripheral nerve injuries.^{7,8}

The median nerve accounts for 37% of all nerve injuries.³ Median nerve lesions are divided into high and low injuries⁹ sometimes referred to as proximal and distal lesions. Low median nerve lesions are distal to the innervation of the extrinsic flexor muscles of the forearm. Therefore, only the intrinsic muscles of the thumb and the two radial lumbricals are paralyzed and sensation to the volar side of thumb, index, and middle finger. High median nerve lesions are proximal to the origin of the anterior interosseus nerve when all the intrinsic plus extrinsic muscles are paralyzed⁹ (Fig. 1).

Historically, the clinical appearance of this high median nerve lesion has been described as a hand with an abducted thumb, with the index and middle fingers in an extended position (Fig. 2). In the majority of books and articles, this is called the hand of benediction or preacher's hand, referring to the hand of Saint Peter.¹⁰ Adding to the confusion even more, some authors report the hand of benediction due to chronic ulnar neuropathy or ulnar nerve lesion.¹⁰ This condition can also lead to what also

From the *Department of Plastic and Reconstructive Surgery and Hand Surgery, Amsterdam UMC, Amsterdam, the Netherlands; †Department of Plastic and Reconstructive Surgery and Hand Surgery, Erasmus MC, University Medical Center, Rotterdam, the Netherlands; ‡Birmingham Hand and Peripheral Nerve Centre, Queen Elisabeth Hospital, University of Birmingham, UK; and §Department of Orthopaedic Surgery, Khoo Teck Puat Hospital, Singapore.

Received for publication March 12, 2022; accepted August 23, 2022.

Copyright © 2022 The Authors. Published by Wolters Kluwer Health, Inc. on behalf of The American Society of Plastic Surgeons. This is an open-access article distributed under the terms of the Creative Commons Attribution-Non Commercial-No Derivatives License 4.0 (CCBY-NC-ND), where it is permissible to download and share the work provided it is properly cited. The work cannot be changed in any way or used commercially without permission from the journal.

DOI: 10.1097/GOX.0000000000004598

Disclosure: The authors have no financial interest to declare in relation to the content of this article.

might look like a preacher’s hand although this is when the patient is asked to extend the finger, not to flex the fingers. The classical hand of benediction or preacher’s hand for high median nerve lesion is a confusing and incorrect assignation. Firstly, in attempting to flex the fingers, the metacarpophalangeal (MCP) joints of the fingers are flexed due the action of the intrinsic muscles. Secondly, only the index finger is extended at both proximal interphalangeal (PIP) and distal interphalangeal (DIP) joints. The middle finger is flexed because of the connections between the flexor digitorum profundus (FDP) of the ring (quadriga phenomena) and middle finger and because of dual innervation of the ulnar nerve.¹¹ The confusion mentioned above could account for missed diagnosis of high median nerve lesions and, therefore, delayed referral to a nerve specialist for proper and early planning and management of the injury.

We present four cases of a high median nerve lesions that were missed or experienced a delayed referral because of the association with the hand of benediction or preacher’s hand. The aim of this article is to clear the confusion about this sign, based on four cases. We also review the historical basis of the hand of benediction and preacher’s sign and the pathophysiological mechanisms of deformity secondary to motor paralysis in the hand.

METHODS

Following the institutional review board requirements, the four case reports were retrospectively collected. All cases were diagnosed with a complete high median nerve injury, defined as an injury proximal to the PT. The nerve injury was later diagnosed by physical examination and additional studies of nerve conduction study, EMG and/or ultrasound. Charts were reviewed for demographic information, mechanism of injury, physical exam, referral date, and reason for delayed referral.

RESULTS

Patient characteristics and operations are presented in Table 1. Patient one is a 63-year-old woman who was treated for a mass near the biceps tendon. The mass was surgically

Takeaways

Question: Can the preacher’s or benediction hand be used for diagnosing high median nerve injury?

Findings: This study shows that the hand of benediction or preacher’s hand is incorrectly associated with a high median nerve lesion.

Meaning: Hand of benediction or preacher’s is an incorrect sign for high median nerve injury and thorough physical examination is paramount for diagnosis, appropriate referral, and treatment.

removed in a rural hospital. Directly postoperatively she complained of numbness in the thumb and index finger. The physical examination at that time describes “the patient could make a fist and the classical hand of benediction or preacher’s hand was not observed.” Therefore, the loss of sensation was assumed to be neuropraxia of the median nerve. Later on, she complained about loss of opposition and loss of strength of tip pinch, and she had no improvement in sensation. Therefore, she was referred with a delay of approximately 10 months. On physical examination she had complete loss of sensation of the median nerve area, loss of palmar abduction and opposition of the thumb strength, and loss of function of the flexor pollicis longus (FPL) and FDP of the index finger. The posture of her hand showed no sign of a hand of benediction; however when she was asked to make a fist, her thumb remained in adduction with an extended IP joint and her index finger was flexed at the MCP joint and DIP joint showed moderate flexion (Fig. 3A, B). She was treated more than a year after the first surgery with tendon transfers because late nerve reconstruction was considered less reliable in an older patient. Median nerve was not explored, and therefore no intraoperative stimulation was performed. She underwent FDP II side-to-side, extensor indicis proprius (EIP) to opposition and brachioradialis (BR) to FPL tendon transfer. These restored good hand function and allowed continuation of her daily activities.

Patient two is a 69-year-old woman who had an excision of a schwannoma of the median nerve at the level of the

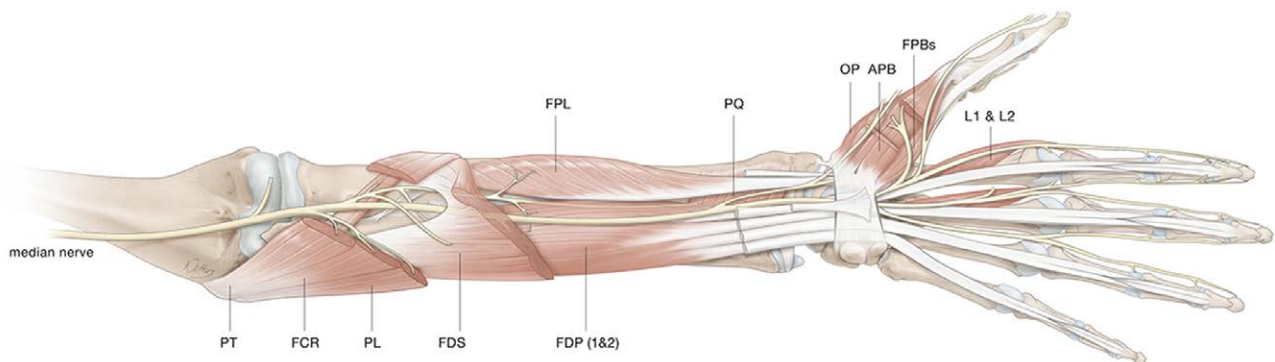


Fig. 1. Median nerve innervated muscles. Pronator teres (PT), Flexor carpi radialis (FCR), Palmaris longus (PL), Flexor digitorum superficialis (FDS), Flexor digitorum profundus index and middle (FDP), Flexor pollicis longus (FPL), Pronator quadratus (PQ), Abductor pollicis brevis (ABP), Opponens pollicis (OP), superficial head Flexor pollicis brevis (FPBs), first and second lumbrical muscle (LM).

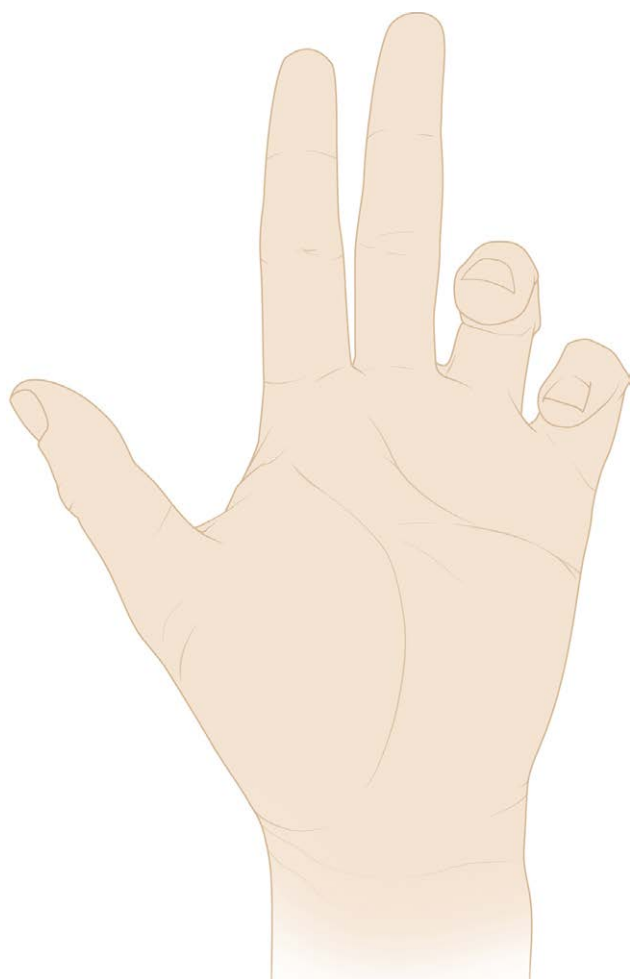


Fig. 2. Benediction or preacher’s hand for high median nerve palsy, which is depicted in many books and articles. Extension of the thumb, index, and middle finger and flexion of the ring and pinky when making a fist.

elbow, proximal to the PT. After the surgery, she developed loss of sensation of the volar side of thumb, index, and middle finger. This loss of sensation was assigned to neuropraxia of the median nerve. According to the surgeon, the median nerve was intact, as there was no hand of benediction or preacher’s hand. As sensation did not recover over time and function further decreased, she was referred a year post surgery. Physical examination revealed a high median nerve lesion, which was supported

by the electrodiagnostic studies, which also showed complete transection of the median nerve without reinnervation. However, when making a fist, she could flex the MCP joint of the index finger and flex the middle finger completely (Fig. 3C, D). At that time, she did not want any reconstructive surgery and unfortunately died 2 years later of another malignant tumor.

Patient three is a 37-year-old man who sustained a multiple gunshot injury in the upper arm and was seen in our emergency department by our own hand surgery team. Therefore, the patient did not have a delay in referral. Physical examination revealed a loss of function of the FPL and FDP of the second digit and loss of sensation over the volar aspect of the thumb and index finger. When the patient was asked to flex the fingers and thumb, there was no hand of benediction; rather, there was an index pointing finger gesture. The injury was recognized as possible injury to the median nerve. Electrodiagnostic testing revealed a prolonged conduction velocity at the APB with positive sharp waves and reduced motor action potentials. Other nerves did not undergo electrophysiological examination because during physical examination there was no suspicion of other nerve injuries. During the following weeks, the strength and range of movement of thumb and index finger gradually improved. Similarly, the sensation in the median nerve innervated skin returned.

Lastly, patient four, a 23-year-old man, fell through a glass window and was seen in the first aid department. Upon physical examination, the surgeon noticed that all fingers could be flexed and concluded that there was no median nerve problem (Fig. 3G). Because of language problems, the patient did not fully understand the sensory testing, and the on-call surgeon decided to wait and referred the patient to the plastic hand surgeons four months later.

The plastic hand surgeons diagnosed a median nerve lesion on physical examination and decided to explore the nerve. No electrodiagnostic studies were performed in this case because this would not change the plan of exploring the nerve. Intraoperatively, near the elbow proximally to the PT, the median nerve was completely transected, and after debridement there was a gap of 8 cm. The median nerve was reconstructed with a sural nerve graft of 24 cm, which was used as a cable graft for primarily sensation. Additionally, tendon transfers were performed for index finger function FDP II side-to-side, BR to FPL, and EIP for opposition. The patient had a good recovery and returned to his previous occupation.

Table 1. Patient Characteristics

#	Gender	Age	Injury	Level of Injury	Follow-up	Surgery
1	Woman	63	Excision of “mass” near biceps tendon, which appeared to be the median nerve	Elbow	4 years No initial recovery	FDP II side-to side, EIP for opposition, BR to FPL
2	Woman	69	Excision schwannoma	Elbow	2 years No initial recovery	No surgery
3	Man	37	Gun shot injury	Upper arm	8 months Full recovery	No surgery
4	Man	23	Broken window glass, fell on elbow	Upper arm	6 years No initial recovery	Median nerve reconstruction with sural nerve graft FDP II side-to side, EIP for opposition, BR to FPL

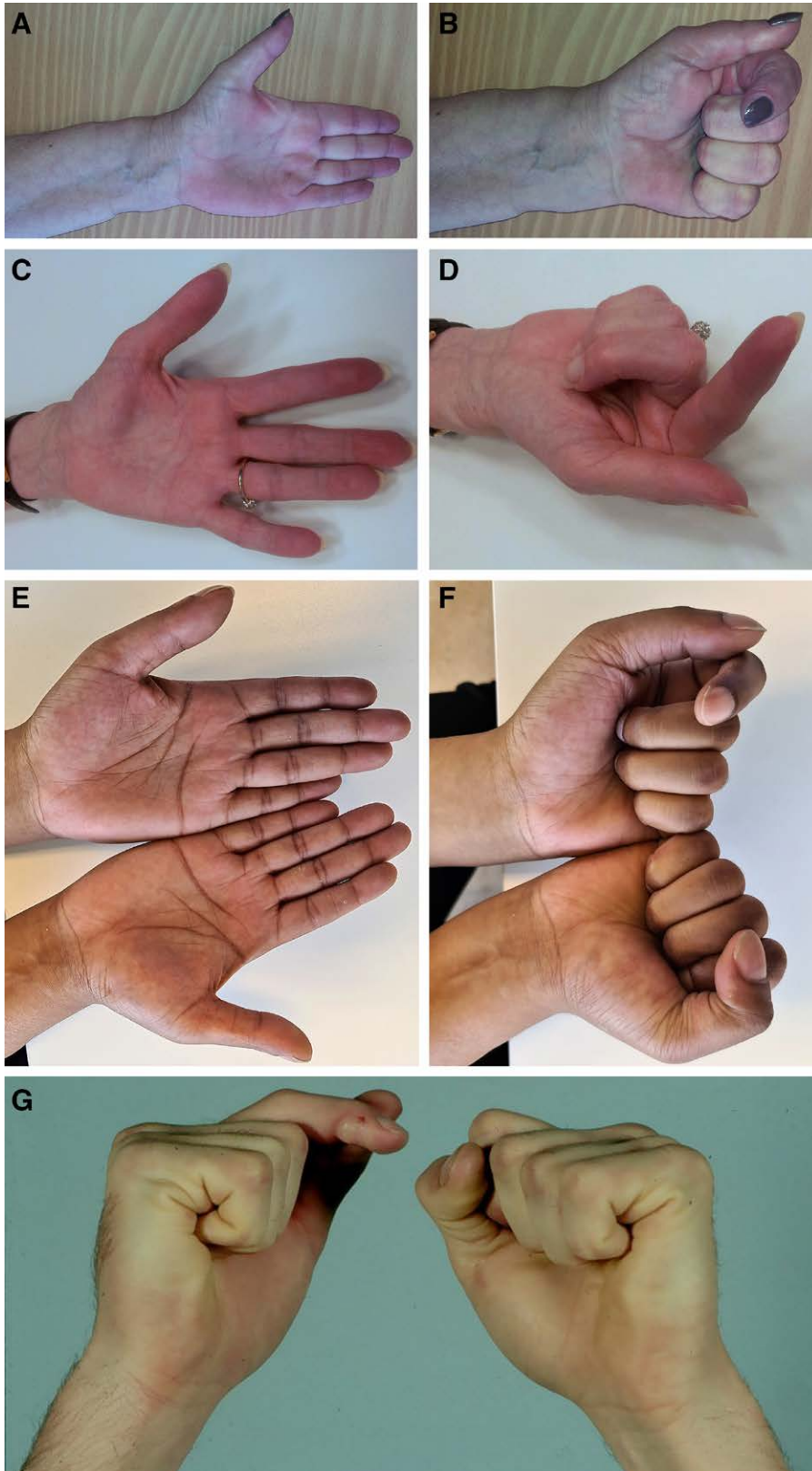


Fig. 3. Four case reports. Patient one shows a hand in active extension (A) and when making a fist (B). The thumb is in adduction, index finger MCP flexion with partial DIP flexion and complete flexion of the middle finger. Similar findings in patient two (C, D), three (E, F), and four (G, where both hands are shown when making a fist).

DISCUSSION

In this article, we describe four cases of high median nerve injury in patients who did not have the pathognomonic hand of benediction at the time of injury but had persistent or transient damage to the median nerve. In the literature, the term “hand of benediction” or “preacher’s hand” has been used to describe the abnormal posture of the hand when the patient is asked to make a fist: the fourth and fifth finger flex actively, while the thumb, index, and middle finger remain extended in the MCP joint, PIP joint, and DIP joint. This position resembles the hand during a blessing. Saint Peter, the first Pope, was probably the model for the hand of benediction, an iconic image that has since assumed a more generalized use in Christian art.¹⁰ Making a blessing with an open hand would have been the desired position because it represents greetings and peaceful intentions, which to date is still used by the Pope and preachers. However, this position is not present when the patient has a high median nerve palsy and is asked to make a fist.

The median nerve, which arises from the lateral and medial cords from the brachial plexus (C5-T1), provides predominately extrinsic flexors of the lower arm and hand, with the first being the PT and a small portion of the intrinsic muscles. The detailed innervation of the median nerve is shown in [Figure 1](#). Patients with a high median nerve palsy show an absent flexion in the DIP and

PIP joints of the index finger, and flexion at the MCP joint is still possible. The anatomical basis for this is that the ulnar nerve innervated palmar interossei flex the finger in the MCP joint. The middle finger is still able to flex at the DIP joint as a result of the connections between the FDP muscles and tendon, which create the so called quadriga phenomenon, or alternatively due to dual or variant innervation via the ulnar nerve. The thumb is paralyzed in terms of flexion (FPL) of the IP joint, palmar abduction, and opposition (thenar muscles).⁹ This position therefore resembles more the posture of a pointing finger rather than a hand of benediction ([Fig. 4A, B](#)).

In the literature, these findings are well reported. For instance, Bertelli et al showed, in a case series of 11 patients with a high median nerve injury, that all patients had an M5 and complete flexion of the middle finger.¹² Additionally, other studies showed, in solitary anterior interosseous nerve palsy for example, a consistent flexion of the middle finger.^{13,14} Soldado et al showed in their study that the ulnar nerve consistently innervated the FDP of the middle finger by intraoperative electrical stimulation.¹¹ The FDP of the middle finger is not the only muscle that receives a double innervation. For example, the brachialis muscle receives double innervation from the musculocutaneous and radial nerve for its medial and lateral part respectively.^{15,16} There are several reports that show that the muscle belly of the

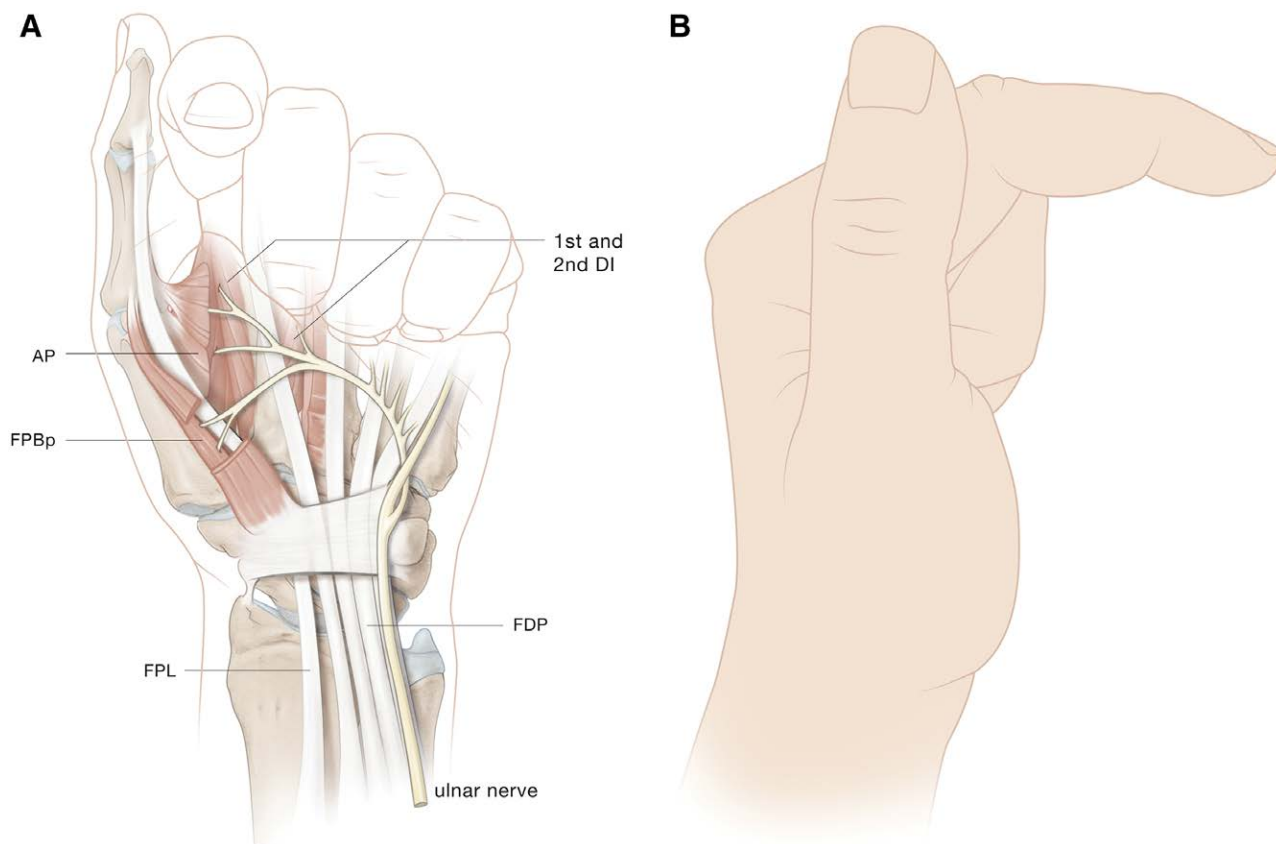


Fig. 4. High median nerve palsy pathomechanics. A, Thumb is in adduction and opposition due to ulnar innervated adductor pollicis and deep head of flexor pollicis brevis. Index finger is flexed in MCP joint due to intact interosseous muscles and minimal flexion in IP joint is seen. Lastly, the middle finger is in complete flexion. B, Medial view of posture hand in a high median nerve palsy.

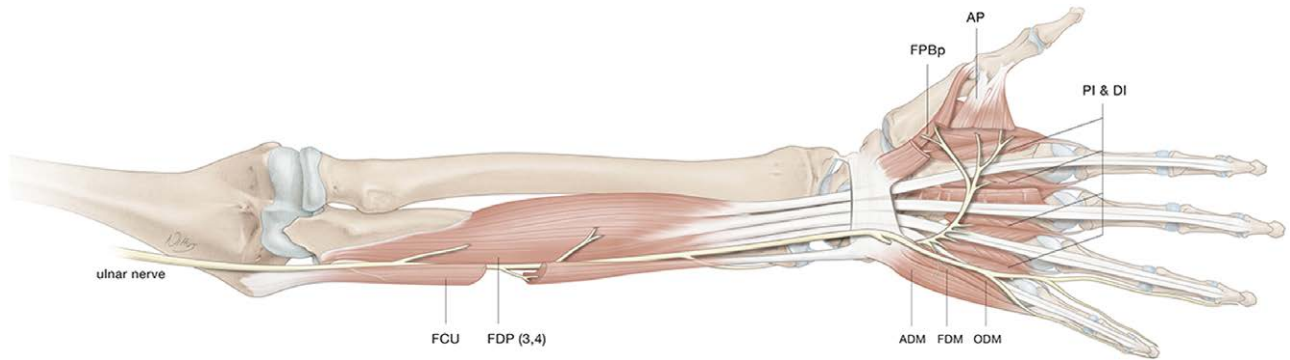


Fig. 5. Ulnar nerve innervated muscles. Flexor carpi ulnaris (FCU), Flexor digitorum profundus middle, ring and small (FDP), Palmaris brevis (PB), Abductor digiti minimi (ADM), Flexor digiti minimi (FDM), Opponens digiti minimi (ODM), Palmar and Dorsal interosseous (IO), III and IV lumbrical muscles (LM), Adductor pollicis (AP), deep head Flexor pollicis brevis (FPBd).

FDP to the middle finger has dual innervation from the median and ulnar nerve and together with intertendinous connections, flexion of the middle finger is still possible with a high median nerve injury.^{11,12}

Also, several reports show that the palmar abduction function of the thumb is still functionally preserved in up to 70% of patients with a low median nerve injury and that opposition transfer was necessary in only 14% of reported cases.^{17,18} The anatomical basis for these findings is the deep head innervation of the FPB by the ulnar nerve and, in one-third of the cases, dual innervation of the superficial head of the FPB.¹⁹ In the classical hand of benediction for a median nerve injury, the thumb is also in abduction; however, because of the ulnar innervated adductor pollicis (Fig. 5), when making a fist the thumb is completely adducted and IP extension is evident (Fig. 6). Additionally, it has been postulated that the APL and EPL, which are muscles innervated by the radial nerve, also play a role in abduction of the thumb,¹² which, together with the FPB, still preserves some limited function in the thumb.

To complicate things even more, in the literature, the papal benediction sign is sometimes attributed to an ulnar nerve palsy. Due to ulnar nerve injury or compression, a claw hand deformity is present, involving the ulnar two digits and accentuated by active extension of the fingers by the patient. Here, the ring and little finger are “clawed” with hyperextension of the MCP and show an inability to fully extend the IP joints (Figs. 5 and 6). It is worth mentioning that clawing is in the vast majority apparent in low ulnar lesions, distal to the innervation of the FDP of the fourth and fifth digits. This is due to the loss of function in the interosseous and third and fourth lumbrical muscles, which normally aid the EDC to fully extend the IP joints. Additionally, in lower ulnar palsy, the innervated strong FDPs are unopposed and cause flexion in the IP joints, which does not happen in the same extent when the FDPs are also paralyzed in a high ulnar (proximal to FDP innervation) nerve lesion. This specific posture (benediction sign) has also been attributed to other non-nerve related pathologies like Dupuytren disease.²⁰

When examining the clinical picture of median and ulnar nerve injuries, one must also consider nerve interconnections between the median and ulnar nerve (Fig. 7). The

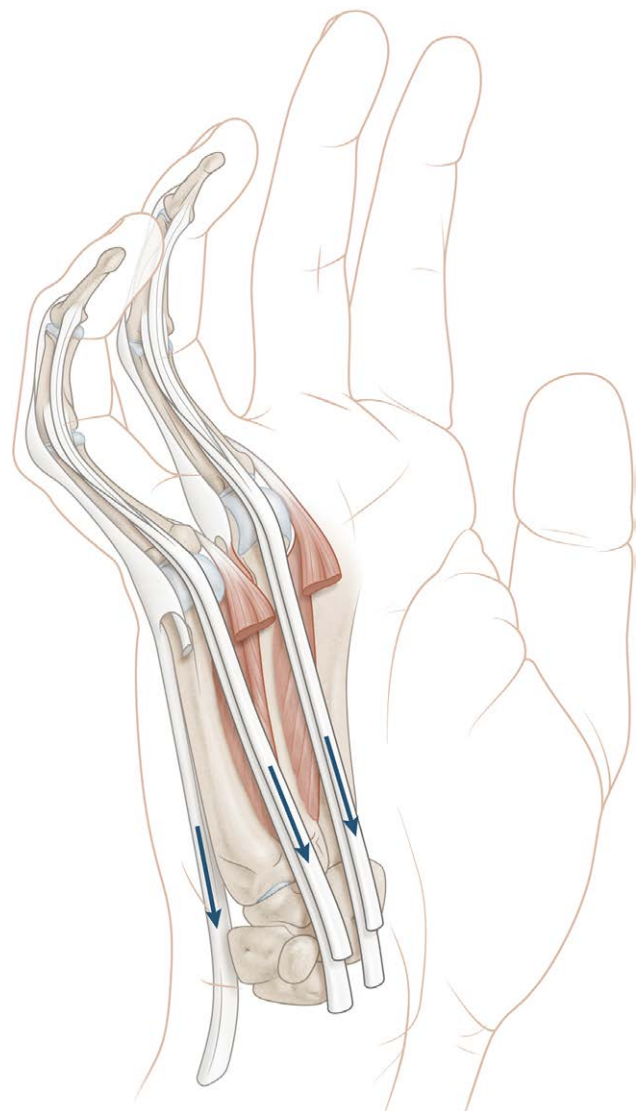


Fig. 6. Claw hand for distal ulnar nerve injury or chronic compression. Loss of intrinsic muscle action which leads to loss of isolated MCP flexion and, consequently, hyperextension due to unopposed action of the EDC. Moreover, due to strong FDP and FDS, this leads to unopposed flexion of the PIP and DIP.



Fig. 7. Interconnection nerves. 1. Martin-Gruber anastomosis (MGA), 2. Marinacci anastomosis (MA), 3. Riche-Cannieu anastomosis (RCA), 4. Berrettini anastomosis (BA).

Martin-Gruber anastomosis (MGA) is a connection between the median nerve proximally in the forearm to the ulnar nerve more distally (Fig. 7).²¹ It has been postulated that the prevalence of the MGA is around 19.5%, with important clinical implications.²² For example, in severe carpal tunnel syndrome patients with an MGA, there may be partial or total sparing of thenar muscles, which may result in retained thumb motor function. Secondly, the Marinacci anastomosis (MA) is a reverse MGA, with a nerve connection between the ulnar nerve proximally and median nerve distally. The MA has been reported in up to 4% of patients, although this may be an underestimate.²³ Instances of high median nerve injuries with an MA may not result in significant dysfunction in the median innervated intrinsic muscles in the hand. Thirdly, the Riche-Cannieu anastomosis, which is a connection between the recurrent branch of the median nerve and the deep branch of the ulnar nerve, has a prevalence of 55.5% to 80%.^{22,24} Reports show that Riche-Cannieu anastomosis in patients with a complete median nerve lesion results in misinterpretation of the clinical diagnosis in 60% to 82% of cases.^{21,25} Lastly, the most prevalent nerve interconnection is the Berrettini anastomosis (BA), with a prevalence of up to 80%. In the BA, there is connection between the common digital nerves of the ulnar and median nerves.²¹ The BA is a purely sensory connection, which may manifest with some sensory sparing of the middle and ring fingers after median nerve injury. The classical picture of volar radial sided sensory innervation from the median nerve has been shown to be inaccurate by Bertelli et al and is postulated to be a result of interconnections between the median and ulnar nerve.¹²

It is important that the use of this pathognomonic nomenclature of hand of benediction or preacher's sign should be abandoned because it adds no value to the medical documentation. Clinicians are best advised to describe the motor grade of each specific muscle involved for nerve palsies. This will potentially allow a correct diagnosis to be made as early as possible, ideally within an appropriate timeframe for anatomical reconstruction of the primary nerve injury. For example in patient four, because of the delay of several months the median nerve is retracted and scarred, which after debridement left a nerve gap of 8 cm. This defect needed to be grafted with an autograft sural nerve, with two anastomoses, which has a suboptimal

result, graft length, timing of repair, and possible donor site comorbidities. Limitations in the current study are the small case series and limited electrodiagnostic studies because of the retrospective nature of the study.

In conclusion, in this study we show that the hand of benediction or preacher's hand is ambiguous and has no anatomical basis for it to be considered a pathognomonic sign of a high median nerve injury. Its popularity in the medical literature and among educators continues to fuel the reasons of missed and delayed diagnosis and suboptimal treatment. Attention to detail in the motor assessment of the intrinsic and extrinsic muscle of the hand is the foundation of a thorough clinical examination to ensure accurate diagnosis of peripheral nerve injuries.

J. Michiel Zuidam, MD, PhD

Department of Plastic and Reconstructive Surgery and Hand Surgery Erasmus MC, University Medical Center Rotterdam, The Netherlands
E-mail: j.zuidam@erasmusmc.nl

REFERENCES

1. Novak CB, Anastakis DJ, Beaton DE, et al. Relationships among pain disability, pain intensity, illness intrusiveness, and upper extremity disability in patients with traumatic peripheral nerve injury. *J Hand Surg Am.* 2010;35:1633–1639.
2. Chemnitz A, Dahlin LB, Carlsson IK. Consequences and adaptation in daily life – patients' experiences three decades after a nerve injury sustained in adolescence. *Bmc Musculoskelet Di.* 2013;14:252.
3. Padovano WM, Dengler J, Patterson MM, et al. Incidence of nerve injury after extremity trauma in the United States. *Hand (N Y).* 2020;17:615–623.
4. Taylor CA, Braza D, Rice JB, et al. The incidence of peripheral nerve injury in extremity trauma. *Am J Phys Med Rehabil.* 2008;87:381–385.
5. Dolan RT, Butler JS, Hynes DE, et al. The nerve to delay: the impact of delayed referrals in the management of traumatic brachial plexus injuries in the Republic of Ireland. *J Plast Reconstr Aesthet Surg.* 2012;65:1127–1129.
6. Zhang D, Dyer GSM, Garg R. Delayed referral for adult traumatic brachial plexus injuries. *J Hand Surg Am.* 2021;46:929.e1–929.e7.
7. Moore AM, Franco M, Tung TH. Motor and sensory nerve transfers in the forearm and hand. *Plast Reconstr Surg.* 2014;134:721–730.
8. Griffin JW, Hogan MV, Chhabra AB, et al. Peripheral nerve repair and reconstruction. *J Bone Joint Surg Am.* 2013;95:2144–2151.

9. Ko JW, Mirarchi AJ. Late reconstruction of median nerve palsy. *Orthop Clin North Am.* 2012;43:449–457.
10. Futterman B. Analysis of the papal benediction sign: the ulnar neuropathy of St. Peter. *Clin Anat.* 2015;28:696–701.
11. Soldado F, Ghizoni MF, Bertelli JA. The ulnar nerve consistently drives flexion of the middle finger. *J Hand Surg Eur Vol.* 2014;39:211–212.
12. Bertelli JA, Soldado F, Lehn VLM, Ghizoni MF. Reappraisal of clinical deficits following high median nerve injuries. *J Hand Surg.* 2016;41:13–19.
13. Ulrich D, Piatkowski A, Pallua N. Anterior interosseous nerve syndrome: retrospective analysis of 14 patients. *Arch Orthop Trauma Surg.* 2011;131:1561–1565.
14. Kodama N, Ando K, Takemura Y, et al. Treatment of spontaneous anterior interosseous nerve palsy. *J Neurosurg.* 2020;132:1243–1248.
15. Mahakkanukrauh P, Somsarp V. Dual innervation of the brachialis muscle. *Clin Anat.* 2002;15:206–209.
16. Hwang K, Bang SJ, Chung SH. Innervation of the flexor digitorum profundus: a systematic review. *Plast Surg (Oakv).* 2018;26:120–125.
17. Boatright JR, Kiebzak GM. The effects of low median nerve block on thumb abduction strength. *J Hand Surg Am.* 1997;22:849–852.
18. Jensen EG. Restoration of opposition of the thumb. *Hand.* 1978;10:161–167.
19. Caetano EB, Nakamichi YDC, Alves de Andrade R, et al. Flexor pollicis brevis muscle. anatomical study and clinical implications. *Open Orthop J.* 2017;11:1321–1329.
20. Elliot D. The early history of Dupuytren's disease. *Hand Clin.* 1999;15:1–19.
21. Smith JL, Siddiqui SA, Ebraheim NA. Comprehensive summary of anastomoses between the median and ulnar nerves in the forearm and hand. *J Hand Microsurg.* 2019;11:1–5.
22. Roy J, Henry BM, PEkala PA, et al. Median and ulnar nerve anastomoses in the upper limb: a meta-analysis. *Muscle Nerve.* 2016;54:36–47.
23. Meenakshi-Sundaram S, Sundar B, Arunkumar MJ. Marinacci communication: an electrophysiological study. *Clin Neurophysiol.* 2003;114:2334–2337.
24. Harness D, Sekeles E. The double anastomotic innervation of thenar muscles. *J Anat.* 1971;109(Pt 3):461–466.
25. Bölükbaşı O, Turgut M, Akyol A. Ulnar to median nerve anastomosis in the palm (Riches-Cannieu anastomosis). *Neurosurg Rev.* 1999;22:138–139.