

Encapsulated eumycetoma caused by *Biatriospora mackinnonii*

Daniela Arteaga^a, Andrés Tirado-Sánchez^a, Denisse Vázquez-González^a, Luis-Miguel Moreno^b, Wendy van de Sande^{c,*}, Alexandro Bonifaz^a

^a Dermatology Department, Hospital General de México Dr. Eduardo Liceaga, Mexico City, 06720, Mexico

^b Dermatopathology Department, Hospital General de México Dr. Eduardo Liceaga, Mexico City, 06720, Mexico

^c Department of Medical Microbiology and Infectious Diseases, Erasmus MC University Medical Center Rotterdam, Rotterdam, 3015, the Netherlands

ARTICLE INFO

Keywords:

Encapsulated eumycetoma
Biatriospora mackinnonii
Subcutaneous mycosis
Implantation mycoses

ABSTRACT

Eumycetoma is a chronic infection due to filamentous fungi. Herein, we report a case of eumycetoma presenting as a subcutaneous encapsulated lesion on the right leg with no previous traumatic implantation. From microscopic morphological characteristics and molecular analysis, the pathogenic fungal species were identified as *Biatriospora mackinnonii*. Surgical excision of the entire lesion was performed to reduce the fungal load and improve antifungal therapy response.

1. Introduction

Mycetoma is a chronic, progressively destructive disease of the subcutaneous tissues recognized by the World Health Organization (WHO) as a neglected tropical disease with a significant worldwide burden [1]. Based on the etiology, it is divided into two groups: eumycetoma, caused by true filamentous fungi, and actinomycetoma, due to aerobic filamentous actinomycetes [2]. Herein, we report a case of subcutaneous encapsulated eumycetoma due to *Biatriospora mackinnonii* (formerly *Nigrograna mackinnonii*).

2. Case

A previously healthy 44-year-old farmer from southeastern Mexico presented with a 30-year history of a slowly growing nodule over his right leg with seropurulent discharge and scarring, leading to malleolus deformity. The patient had no medical history of previous trauma. Direct examination in potassium hydroxide preparation revealed black grains with thick branching hyphae, concluding a diagnosis of eumycetoma. We started itraconazole at 400 mg/daily for two years with a reduction in the lesion size without isolation of the infectious agent. The patient discontinued treatment and restarted two years after the appearance of a well-circumscribed nodule in the distal third of his right leg. Ultrasonography revealed hypochoic and multiple small-centered hyperechoic areas, matching eumycetoma (Fig. 1).

Wide local excision was necessary to remove the complete

encapsulated lesion to reduce the fungal load and improve antifungal therapy response (Fig. 2) (Fig. 3).

Skin biopsy showed granulomatous inflammation with black fungal grains (Fig. 4).

The fungus was identified as *B. mackinnonii* based on colony morphology, microscopic appearance, and molecular identification was done by rDNA internal transcribed spacer region (ITS) was amplified using primers ITS1 and ITS4, and the large ribosomal subunit (LSU) was amplified using primers LRoR and LR5. Treatment with itraconazole 400 mg/daily continued without relapse.

3. Discussion

Eumycetoma is a chronic implantation mycosis characterized by granulomatous infiltrates of the skin and the subcutaneous tissues. In Mexico, eumycetoma cases are rarely found and are caused by black fungi, representing only 5.39% of cases [3]. *Madurella mycetomatis* is the most typical organism among the etiological agents, followed by *Madurella pseudomycetomatis*, *Trematosphaeria grisea*, and *Biatriospora mackinnonii* [2]. *B. mackinnonii* is a known eumycetoma-causative agent in Latin America; four cases have been reported in Mexico [4]. This implantation mycosis develops slow-growing subcutaneous swelling and nodules, progressing to suppurative lesions and multiple draining sinus tracts that discharge black grains [5–7].

According to the natural habitat of this fungus in the soil, we can hypothesize that rural activities may expose the patients to repeated skin

* Corresponding author.

E-mail address: a_bonifaz@yahoo.com.mx (W. van de Sande).

<https://doi.org/10.1016/j.mmcr.2022.08.002>

Received 23 June 2022; Received in revised form 21 August 2022; Accepted 28 August 2022

Available online 13 September 2022

2211-7539/© 2022 Published by Elsevier B.V. on behalf of International Society for Human and Animal Mycology. This is an open access article under the CC BY-NC-ND license (<http://creativecommons.org/licenses/by-nc-nd/4.0/>).

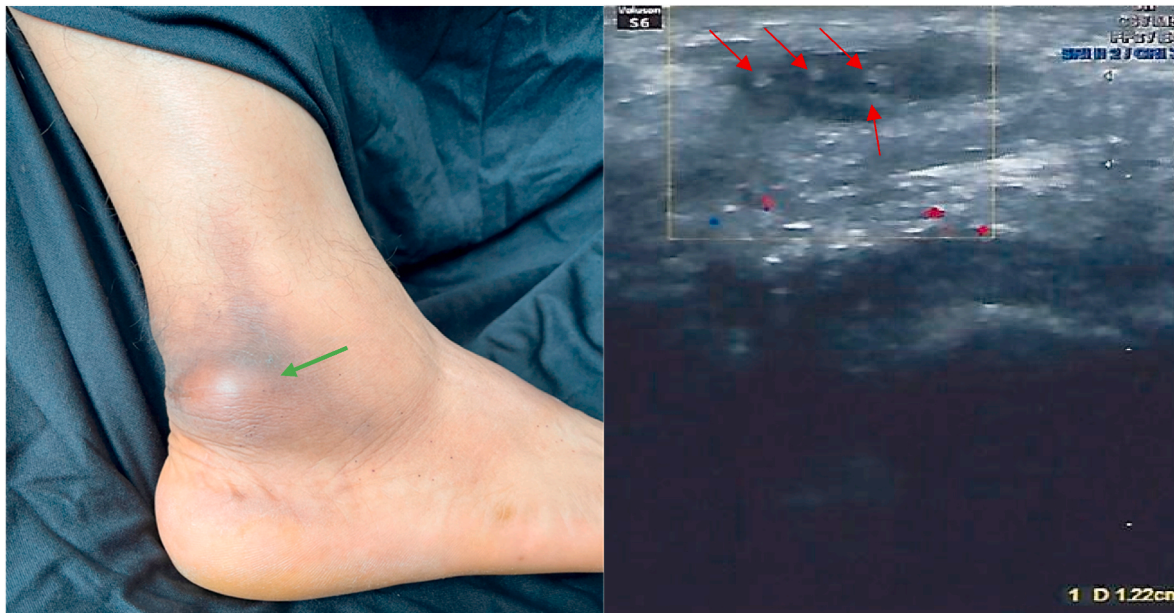

Fig. 1. Left: well-circumscribed nodule in the distal third of the right leg (green arrow). Right: hypoechoic area with multiple small-centered hyperechoic lesions (red arrows) corresponding with eumycetoma grains. (For interpretation of the references to colour in this figure legend, the reader is referred to the Web version of this article.)

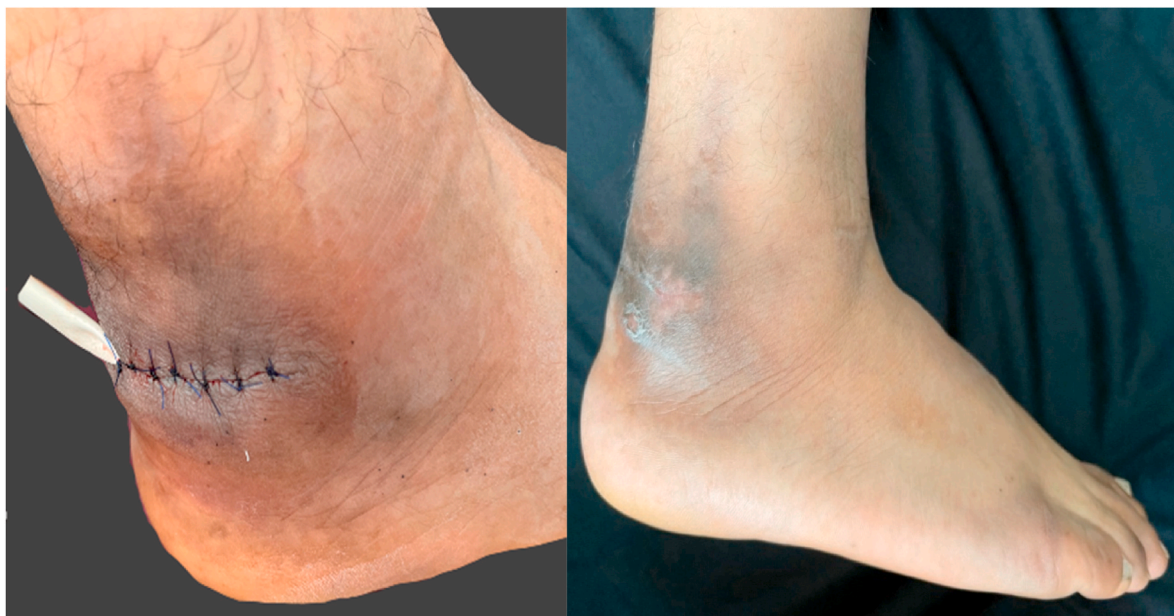


Fig. 2. Left: Removal of the encapsulated lesion. Right: no lesion recurrence was observed after three months.

trauma, triggering subcutaneous mycosis. Over 75% of patients have a lesion in the lower extremity, most commonly in the foot (70%), followed by the hand (sites exposed to traumatic skin wounds). Since the incubation period varies from 3 months to 9 years before the first medical evaluation, patients may forget the initial trauma, as in our case [1,2].

Diagnosis of mycetoma must include the following classic clinical triad: 1) painless firm subcutaneous nodule, 2) multiple sinus formation, and 3) grain-containing purulent or seropurulent discharge [2]. Direct clinical and microscopic examinations, and culture, are low-cost specific diagnostic tools; culture is the gold standard for species identification [1]. However, in the present case, due to chronic disease, the infection presented as an encapsulated lesion and an absence of grain-containing

discharge; this is rarely seen in eumycetoma.

Newer techniques, including fine-needle aspiration cytological examination and imaging, mainly cutaneous ultrasound and magnetic resonance imaging (MRI), are used to overcome diagnostic difficulties, playing an essential role in early diagnosis [8].

The “Dot in circle” sign is definite for mycetoma, consisting of single or multiple hypoechoic, thick-walled cavities with no acoustic enhancement. The grains often appear as sharp hyperechoic lesions [9]. High-intensity “circles” on MRI correlate with granulomatous infiltrates; central low signal “dots” correspond to the fungal grains, and the peripheral rim of hypointensity zones refers to the fibrous matrix [10]. These MRI findings correlate with ultrasonography (USG) [11].

Eumycetoma requires long-term medical therapy; however, the

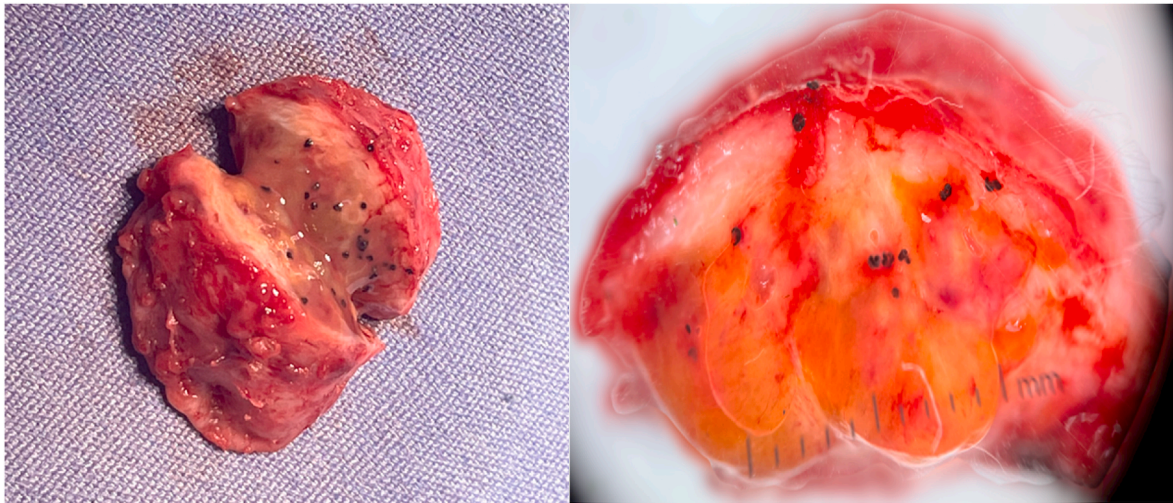


Fig. 3. Left: macroscopic view of the encapsulated lesion where large black grains can be seen. Right: detailed picture of the black grains (dermoscopy, 10x).

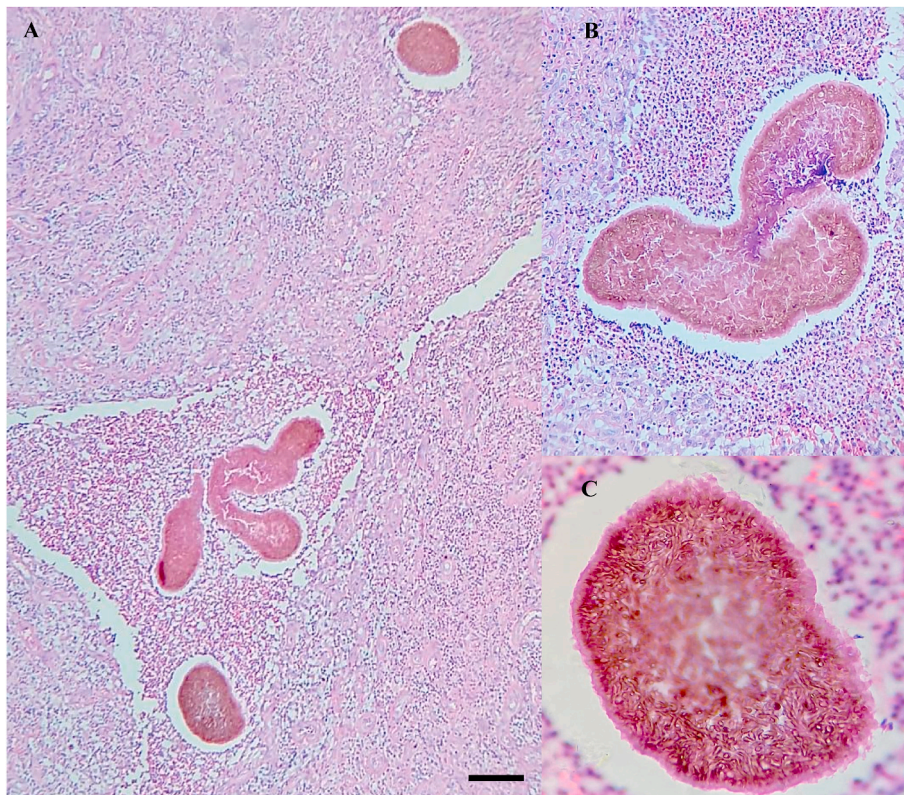


Fig. 4. A: suppurative granulomatous inflammatory infiltrates with neutrophils, lymphocytes, and histiocytes. B: large multilobed grains with thin Splendore – Hoeppli phenomenon. C: clusters of radially branched brown hyphae (HE, 100x). (For interpretation of the references to colour in this figure legend, the reader is referred to the Web version of this article.)

treatment is not entirely successful, showing low cure rates (26%) [2]. Low minimum inhibitory concentrations (MIC) for amphotericin B and azoles are often observed in *B. mackinnonii*; moreover, MIC for azoles is three to four-fold dilutions higher than *M. mycetomatis* [12]; therefore, treatment duration often ranges between six months to three years, then surgical intervention is usually needed. Wide local surgical excision is the treatment of choice for non-responding eumycetoma and small, well-localized lesions, allowing better response to medical therapy [13, 14]. However, postoperative recurrence rates occurred in up to 50% of cases [15].

In conclusion, we present a case of eumycetoma due to

B. mackinnonii, Latin America's one of the most common eumycetoma agent. The diagnosis was based on culture, specific radiologic signs, histopathological examination, and molecular analysis. Surgical intervention is recommended for eumycetoma but not for actinomycetoma. In this case, the surgical intervention improved clinical and mycological outcomes.

Funding source

There are none.

Declaration of competing interest

The authors have no conflicts of interest to disclose.

Acknowledgments

There are none.

References

- [1] P. Agarwal, V. Relhan, K. Mahajan, V. Garg, Mycetoma: an update, *Indian J. Dermatol.* 62 (4) (2017) 332.
- [2] W. van de Sande, E. Maghoub, A. Fahal, M. Goodfellow, O. Welsh, E. Zijlstra, The mycetoma knowledge gap: identification of research priorities, *PLoS Neglected Trop. Dis.* 8 (3) (2014), e2667.
- [3] A. Bonifaz, A. Tirado, L. Calderón, A. Saúl, J. Araiza, M. Hernández, et al., Mycetoma: experience of 482 cases in a single center in Mexico, *PLoS Neglected Trop. Dis.* 8 (8) (2014), e3102.
- [4] S. Ahmed, G. González, A. Tirado, L. Moreno, S. de Hoog, A. Bonifaz, *Nigrograna mackinnonii*, not *Trematosphaeria grisea* (syn., *Madurella grisea*), is the main agent of black grain eumycetoma in Latin America, *J. Clin. Microbiol.* 56 (3) (2018).
- [5] S. Ahmed, G. De Hoog, W. van de Sande, Fungi causing eumycotic mycetoma, in: K. C. Carroll, M.L. Pfaller MA Landry, et al. (Eds.), *Manual of Clinical Microbiology*, twelfth ed., ASM Press, Washington, DC, 2019, pp. 2261–2277.
- [6] D. Emery, D. Denning, The global distribution of actinomycetoma and eumycetoma, *PLoS Neglected Trop. Dis.* 14 (9) (2020), e0008397.
- [7] A. Ahmed, W. van Leeuwen, A. Fahal, W. van de Sande, H. Verbrugh, A. van Belkum, Mycetoma caused by *Madurella mycetomatis*: a neglected infectious burden, *Lancet Infect. Dis.* 4 (9) (2004) 566–574.
- [8] E. Siddig, N. Mhmoud, S. Bakhiet, O. Abdallah, S. Mekki, N. El Dawi, et al., The accuracy of histopathological and cytopathological techniques in the identification of the Mycetoma causative agents, *PLoS Neglected Trop. Dis.* 13 (8) (2019), e0007056.
- [9] T. Yadav, Clinico-radiological-pathological correlation in eumycetoma spectrum: case series, *North Clin. Istanbul* 7 (4) (2019) 400–406.
- [10] A. Basirat, E. Boothe, A. Mazal, B. Mansoori, M. Chalian, Soft tissue mycetoma: "Dot-in-circle" sign on magnetic resonance imaging, *Radiol. Case Rep.* 15 (5) (2020) 467–473.
- [11] M. Gameraddin, A. Gareeballah, S. Mokhtar, M. M. Abuzaid, F. Alhazmi, H. Ali, Characterization of foot mycetoma using sonography and color Doppler imaging, *Pakistan J. Biol. Sci.* 23 (7) (2020) 968–972.
- [12] W. van de Sande, In vitro susceptibility testing for black grain eumycetoma causative agents, *Trans. R. Soc. Trop. Med. Hyg.* 115 (4) (2021) 343–354.
- [13] A. Fahal, S. Mahgoub el, A. El Hassan, M. Abdel, Mycetoma in the Sudan: an update from the mycetoma research centre, university of khartoum, Sudan, *PLoS Neglected Trop. Dis.* 9 (3) (2015), e0003679.
- [14] S. Suleiman, E. Wadaella, A. Fahal, The surgical treatment of Mycetoma, *PLoS Neglected Trop. Dis.* 10 (6) (2016), e0004690.
- [15] E. Mohamed, S. Bakhiet, M. El Nour, S. Suliman, H. El Amin, A. Fahal, Surgery in mycetoma-endemic villages: unique experience, *Trans. R. Soc. Trop. Med. Hyg.* 115 (4) (2021) 320–323.