

# Lateral Lymph Nodes in Rectal Cancer: Do we all Think the Same? A Review of Multidisciplinary Obstacles and Treatment Recommendations

Tania C. Sluckin,<sup>1,2</sup> Alice M. Couwenberg,<sup>2</sup> Doenja M.J. Lambregts,<sup>3</sup>  
 Sanne-Marije J.A. Hazen,<sup>1</sup> Karin Horsthuis,<sup>4</sup> Philip Meijnen,<sup>5</sup>  
 Regina G.H. Beets-Tan,<sup>3,6</sup> Pieter J. Tanis,<sup>7,8</sup> Corrie A.M. Marijnen,<sup>2,9</sup>  
 Miranda Kusters<sup>1</sup>

## Abstract

Lateral lymph nodes in low, locally advanced, rectal cancer have proven implications for local recurrence rates, which increase drastically in the presence of persistently enlarged lateral lymph nodes. These clinical implications warrant a thorough understanding of lateral nodal disease with awareness and knowledge from all three specialties involved – radiology, radiation oncology, and surgery – to ensure proper treatment. Relevant literature for each specialty, including all current guidelines and perspectives, were examined. Variations in definitions and treatment paradigms were evaluated. There is still no consensus for the standardized treatment of lateral nodal disease. Each discipline works according to their own available evidence, but relevant data are scarce. Current international guidelines and standard recommendations for the diagnostics and treatment of lateral lymph nodes are lacking. This results in differing perspectives and interpretations between the disciplines which can lead to challenging communication in an area where multidisciplinary collaboration is essential. This review addresses this by presenting the current evidence, perspectives and practices of each specialty and makes suggestions for each phase of the diagnostic and treatment process for patients with lateral nodal disease. By doing this, steps are taken toward achieving international consensus, and multidisciplinary collaboration.

*Clinical Colorectal Cancer*, Vol. 21, No. 2, 80–88 © 2022 The Author(s). Published by Elsevier Inc. This is an open access article under the CC BY license (<http://creativecommons.org/licenses/by/4.0/>)

**Keywords:** Multidisciplinary team, Radiology, Radiation oncology, Surgery, Rectal carcinoma

**Abbreviations:** LLNs, Lateral lymph nodes; (C)RT, (Chemo)radiotherapy; LR, Local recurrence; LLR, Lateral local recurrence; LLND, Lateral lymph node dissection; SA, Short-axis.

<sup>1</sup>Department of Surgery, Amsterdam University Medical Centers, Vrije Universiteit Amsterdam, Cancer Center Amsterdam, Amsterdam, the Netherlands

<sup>2</sup>Department of Radiation Oncology, The Netherlands Cancer Institute, Amsterdam, the Netherlands

<sup>3</sup>Department of Radiology, The Netherlands Cancer Institute, Amsterdam, the Netherlands

<sup>4</sup>Department of Radiology, Amsterdam University Medical Centers, Vrije Universiteit Amsterdam, Cancer Center Amsterdam, Amsterdam, the Netherlands

<sup>5</sup>Department of Radiation Oncology, Amsterdam University Medical Centers, Vrije Universiteit Amsterdam, Cancer Center Amsterdam, Amsterdam, the Netherlands

<sup>6</sup>GROW School of Oncology and Developmental Biology, University of Maastricht, Universiteitssingel 40, Maastricht, the Netherlands

<sup>7</sup>Department of Surgery, Amsterdam University Medical Centers, University of Amsterdam, Cancer Center Amsterdam, Amsterdam, the Netherlands

<sup>8</sup>Department of Surgical Oncology and Gastrointestinal Surgery, Erasmus MC, Rotterdam, the Netherlands

<sup>9</sup>Department of Radiation Oncology, Leiden University Medical Centre, Leiden, the Netherlands

Submitted: Oct 1, 2021; Revised: Feb 3, 2022; Accepted: Feb 13, 2022; Epub: 19 February 2022

Address for correspondence: Miranda Kusters, MD, PhD, Department of Surgery, Amsterdam University Medical Centers, Vrije Universiteit Amsterdam, Cancer Center

## Introduction

Rectal carcinomas below the peritoneal reflection have a tendency to spread laterally toward lymph nodes surrounding the (internal) iliac and obturator vessels.<sup>1</sup> These lateral lymph nodes (LLNs) are situated outside the standard total mesorectal excision (TME) surgical plane. In the era before adequate neoadjuvant treatment ((C)RT) and TME, local recurrences (LRs) frequently occurred and were often located centrally in the pelvis. However, since standard (C)RT and TME for more advanced (high risk stage II/stage III) patients, the absolute risk of LR has decreased, while approximately 50% of LR now occur in the lateral compartments.<sup>2-4</sup> This is most likely due to LLNs which are still not treated appropriately.

In 30-40% of patients with primarily enlarged LLNs (> 10 mm, short-axis [SA]) treated with (C)RT and TME, lateral local recurrence (LLR) occurs within 5 years.<sup>3,5-7</sup> A recent international cohort of 1216 patients with standardized re-review of all MR-

Amsterdam, De Boelelaan 1117, PO Box 7057, 1007 MB, Amsterdam, the Netherlands  
 E-mail contact: [m.kusters@amsterdamumc.nl](mailto:m.kusters@amsterdamumc.nl)

images found that patients with enlarged LLNs ( $\geq 7$  mm [SA]) prior to (C)RT had a 5-year LLR rate of 19.5%.<sup>8</sup> LLNs  $\geq 7$  mm prior to (C)RT in the internal iliac compartment, which remained  $> 4$  mm (SA) at restaging, had a 52.3% 5-year LLR rate. Obturator LLNs had a 5-year LLR risk of 17.8% when remaining  $> 6$  mm (SA). Only 22% of internal iliac LLNs reduced significantly in size ( $< 4$  mm) at restaging, compared to 63% for obturator LLNs. This suggests oncological differences between anatomical locations, possibly explained by distinctive disease advancements or the proportion of reactively enlarged LLNs.<sup>5,9,10</sup>

In contrast, enlarged LLNs in the external iliac compartment did not result in increased LLR, regardless of their size, but resulted in a 2-fold increase in distant metastases.<sup>5,9,10</sup> External iliac LLNs may be more indicative of advanced disease, while internal iliac and obturator LLNs behave as regional disease. However, these results are from only one large study, and require verification.

Despite increasing evidence for the importance of LLNs, international guidelines are scarce.<sup>8,9,11-17</sup> For select patients, (C)RT and TME may be insufficient and this group might benefit from a lateral lymph node dissection (LLND), during which all lymphatic tissue is removed from the lateral compartments. An LLND has been associated with decreased LLR rates, but increased risks of bleeding and/or nerve-damage<sup>11,16,18,19</sup> meaning that an LLND should only be performed for “high-risk” patients by surgeons with relevant expertise.

Close collaboration is needed between radiology, radiation oncology, and surgery in order to optimize the treatment of LLNs. To fully exploit this, broad consensus is required. This review discusses the current perspectives and obstacles per discipline, after which treatment recommendations are proposed.

## Radiology

The majority of research regarding nodal imaging in rectal cancer considers mesorectal lymph nodes and very few have specifically examined LLNs.<sup>20</sup> A primary strength of mesorectal nodal research is the ability to perform radiology-pathology correlated studies after standardized surgery.<sup>20-22</sup> This level of evidence is scarce for LLNs as an LLND is not standard practice in many (Western) countries. The characterization of LLNs on imaging is therefore unfortunately, sparingly investigated, and poorly documented.

The most recent consensus-meeting guidelines on MRI for rectal cancer by the European Society of Gastrointestinal and Abdominal Radiology (ESGAR) stated: “there is to date no solid evidence regarding specific or alternative (size) criteria for extra-mesorectal nodes and as such it was not deemed feasible to recommend any specific criteria for these nodes.” The expert panel concluded that there was still insufficient evidence and determined that “the same criteria recommended for mesorectal lymph nodes may also be used for extra-mesorectal nodes.”<sup>23</sup>

Magnetic resonance imaging (MRI) is considered by many as the primary staging tool for rectal cancer, with advantages such as a large field-of-view (FOV) allowing for broad assessment of all compartments.<sup>23</sup> Evidence from two meta-analyses with data from size-based imaging studies suggest limited sensitivities and specificities (55%-78%) for mesorectal nodal staging.<sup>24,25</sup> In an attempt to increase

this, morphologic criteria such as irregular border, heterogenous signal intensity and round (rather than oval) shape were introduced in combination with size, which increased the sensitivity (36%-85%), and specificity (95%-100%) for determining malignancy in mesorectal lymph nodes.<sup>21,22</sup> The benefit of morphologic criteria has so far not been confirmed for LLNs. Evidence for LLNs was lacking until recent publications by the Lateral Node Consortium, which recognized the importance of LLN size, not morphologic criteria, for predicting LLR rates.<sup>8,9</sup>

To our knowledge, one case report has considered the value of diffusion weighted MR-imaging (DWI-MRI) for LLNs, in which an LLN was found to have a high DWI-signal.<sup>26</sup> This LLN was surgically removed and later histologically proven to be metastatic. This case report however, contradicts evidence for DWI in mesorectal nodes. Previous studies have mainly shown that DWI-MRI can improve the visibility of lymph nodes with 10%-83% compared to standard T2-weighted MRI.<sup>27,28</sup> However, DWI-MRI highlights both N+ and N- mesorectal nodes with reported positive predictive values for N+ nodes of just 52%.<sup>27</sup> Quantitative DWI-measurements [apparent diffusion coefficient (ADC)] were also limited in the differentiation between N+ and N-, with results not or only slightly better than examination based on current size criteria.<sup>27,29</sup>

Finally, positron emission tomography (PET) is not routinely advised for rectal cancer staging and appears to have limited value for nodal assessment considering many lymph nodes fall under the detection limit and/or are obscured by uptake from the tumor or bladder. The evidence of PET for LLNs is equally sparse, with one single study cohort of eighteen patients. Twenty-eight of the thirty-four LLNs identified on CT/MRI were also seen on PET-CT; metastatic LLNs (82%) were significantly larger than non-metastatic LLNs when measuring  $> 12$  mm; a size which is already generally considered as suspicious.<sup>30</sup>

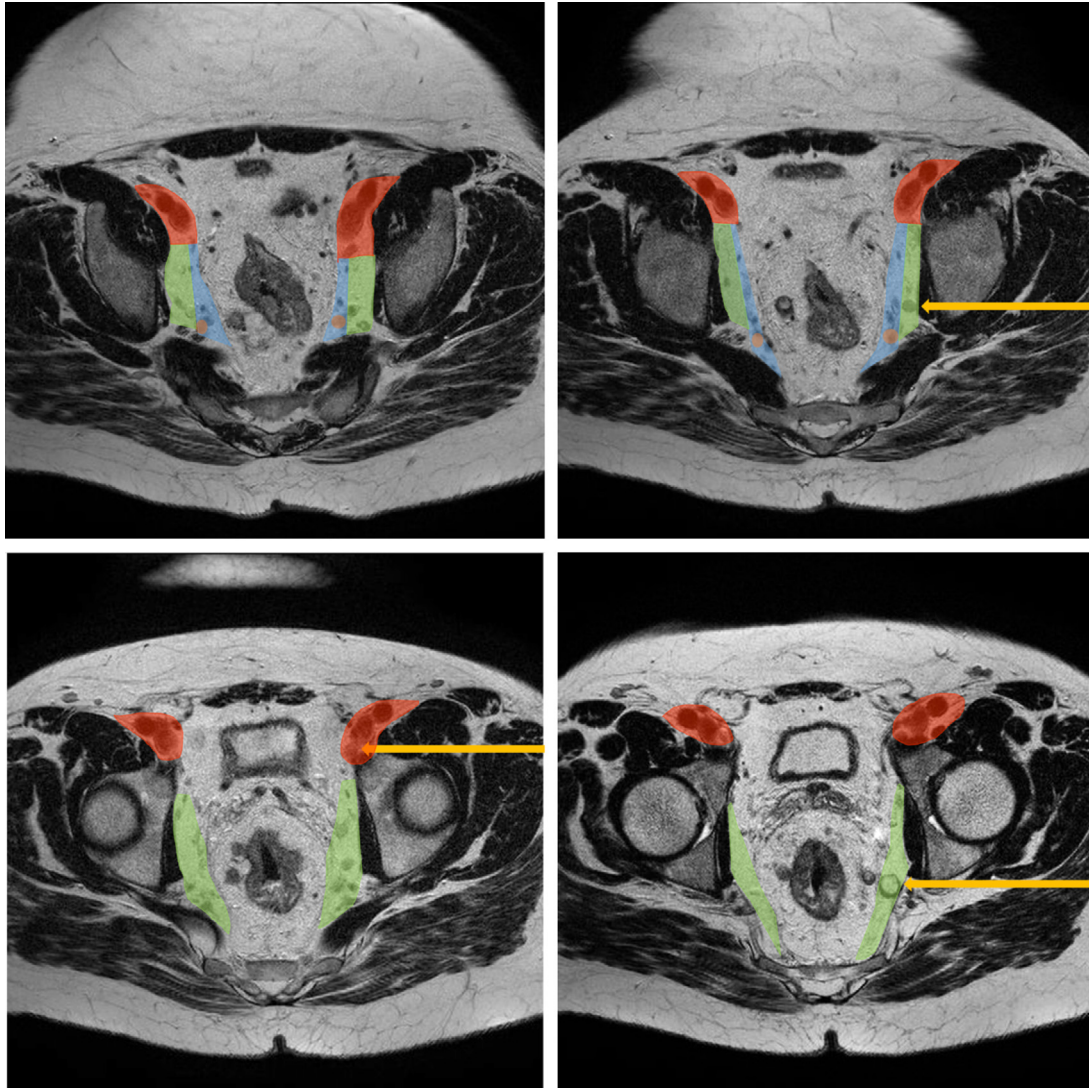
## MRI-protocol and Reports

Awareness and adequate reporting of LLNs is necessary and a systematic “search” for enlarged LLNs in the lateral compartments is essential.<sup>5,8-10</sup>

An international survey highlighted the insufficient consensus and potential knowledge gap regarding LLN staging and terminology. This study tested the applicability and understanding of the TNM (8th ed.) staging system for rectal cancer. Over 300 participants including radiologists and clinicians from 31 countries did not reach consensus as to whether obturator LLNs (58% regional, 42% distant) or internal iliac LLNs (67% regional, 33% distant) represent regional or distant disease.<sup>31</sup> In a yet unpublished national survey, 53 Dutch radiologists were asked to classify the compartments of LLNs. In 1 case, 50% defined the location as internal iliac while the other 50% as obturator (Figure 1). Consensus was often not reached. Another study examined the beneficial use of templates during radiology reporting; the inclusion of terms such as extra-mural venous invasion (EMVI) increased significantly after introducing a template; from 50% to almost 99%.<sup>32</sup> Nodal reporting was already high prior to a template (96%), but the study does not mention whether reports differentiated between mesorectal, and extra-mesorectal

## Lateral Lymph Nodes in Rectal Cancer

**Figure 1** T2-MRI atlas of lateral compartments according to surgical definitions. Caudal progression through a T2-MRI from left to right. Red: external iliac compartment surrounding the external iliac vessels. Green: obturator compartment located lateral of the lateral border of the internal iliac artery (brown spot) and caudal of when the internal iliac artery exits the pelvis. Blue: internal iliac compartment located medial of the lateral border of the internal iliac artery (brown spot). Orange arrows indicate a lateral lymph node (Color version of the figure is available online.)



nodes. Furthermore, results from another unpublished, single center retrospective cohort which examined 202 primary MRI-reports of patients with LARC (stage II high risk/stage III) from 2012-2020 found that only 45% mentioned the presence or absence of LLNs.

Discrepant terminology is also found; McMahon et al.<sup>33</sup> specify the common iliac, external iliac and internal iliac lymph nodes to be LLNs, while the American Joint Committee on Cancer (AJCC) describe the lateral sacral, presacral, internal iliac and sacral promontory lymph nodes to be LLNs.<sup>33-35</sup> This variation, along with the inability to sometimes reach consensus, likely has an effect on daily

practice, and indicates the current lack of knowledge regarding lateral nodal disease, for which clear guidelines are necessary.

### Radiation Oncology

A large proportion of patients with rectal cancer receive neoadjuvant treatment in order to decrease the chance of developing an LR, to achieve a complete clinical response (cCR) for organ preservation, or in advanced settings, to downsize the tumor to allow for surgical resection with negative margins.

Indications for neoadjuvant treatment according to LR-risk are presented in the European Society for Medical Oncology guidelines.<sup>36,37</sup> Patients with a low LR-risk are considered not to benefit

**Table 1** Anatomical Borders of the Lateral Compartments per Specialty (see Also Figure 3).

		<b>Radiation Oncology (Valentini et al)<sup>42</sup></b>	<b>Surgery (Ogura et al)<sup>8</sup></b>
Internal iliac compartment	Cranial	Bifurcation of common iliac artery	Bifurcation of common iliac artery
	Caudal	Insertion of levator ani muscle into external sphincter	Where the internal iliac artery exits the pelvis via the sciatic foramen
	Anterior	<i>Upper:</i> 7mm around the vessel <i>Mid:</i> virtual plane crossing the anterior wall of the ureters when they join the bladder <i>Lower:</i> Posterior limit of obturator fossa	–
	Medial	<i>Upper:</i> 7mm around the vessel <i>Lower:</i> Mesorectal fascia, pelvic organs	Mesorectal fascia
	Lateral	<i>Upper:</i> iliopsoas, pelvic bones <i>Lower:</i> Medial edge of pelvic wall muscle	Lateral border of the internal iliac artery
	Posterior	Lateral edge of sacroiliac joint	Piriformis muscle, sacrum
Obturator compartment	Cranial	Bifurcation of common iliac artery	Bifurcation of common iliac artery
	Caudal	Insertion of levator ani muscle into external sphincter	Where the lateral lymphatic tissue meets pelvic side-wall
	Anterior	<i>Mid:</i> posterior wall of the EIN <i>Lower:</i> Anterior surface of obturator artery	–
	Medial	<i>Upper:</i> 7mm around the vessel <i>Lower:</i> Mesorectal fascia, pelvic organs	Lateral border of the internal iliac artery
	Lateral	<i>Upper:</i> iliopsoas, pelvic bones <i>Lower:</i> Medial edge of pelvic wall muscle	Internal obturator muscle and pelvic side-wall
	Posterior	–	Piriformis muscle

from neoadjuvant treatment. For intermediate risk tumors, without mesorectal fascia (MRF) or LLN involvement and no signs of extramural venous invasion (EMVI), short-course radiotherapy ( $5 \times 5$  Gy) is often recommended. When either the MRF or levator muscles are threatened or in the presence of EMVI or LLNs, patients are considered “high-risk,” and neoadjuvant (C)RT ( $25 \times 2$  or  $28 \times 1.8$  Gy with concurrent oral capecitabine  $825 \text{ mg/m}^2$ ) is advised.<sup>34,36</sup> Alternatively, total neoadjuvant treatment (TNT), consisting of neoadjuvant (C)RT preceded or followed by neoadjuvant chemotherapy, can be considered for high-risk locally advanced cases.<sup>38</sup>

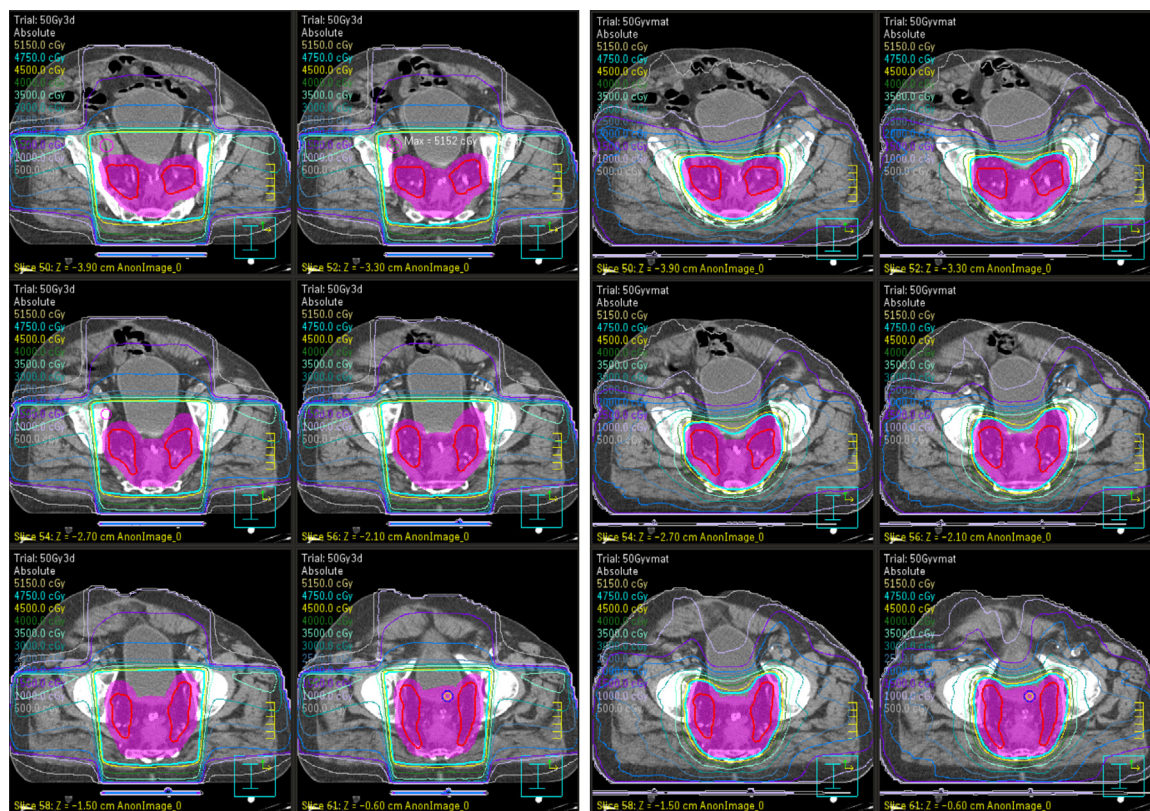
Definitions of target volumes for delineations are essential for optimal treatment and minimal toxicity. Radiotherapy planning in rectal cancer is based on 3 volumes; gross tumor volume (GTV), clinical target volume (CTV) containing areas with potential microscopic tumor spread and planning target volume (PTV), allowing for uncertainties in planning or daily variation.<sup>39,40</sup> Target volumes have been developed based on evidence for areas at risk for LR such as tumor location or lymphatic drainage patterns.<sup>1,4,41,42</sup> Steup et al.<sup>1</sup> linked lymph node metastases to anatomical locations in 605 patients with primary rectal cancer where a lymph node dissection had been performed. Tumors below the peritoneal reflection exhibited more lateral lymphatic spread, especially toward nodes surrounding the obturator artery.

Several studies used information about the location of recurrence and/or lymphatic spread for delineation guidelines concerning

the rectal tumor, mesorectum, and various nodal compartments.<sup>4,43</sup> Some authors advise to adapt the CTV based on specific T- or N-stage, resulting in smaller target volumes for selected patients.<sup>44-46</sup> In an attempt to decrease heterogeneity, Valentini et al.<sup>42</sup> established international guidelines for the delineation of the elective nodal compartments. In addition, they indicate in which situation certain nodal compartments should be irradiated. For this purpose, the LLNs are divided into 2 sub-volumes; anterior and posterior LLNs (see Table 1). It is suggested to delineate posterior LLNs for all patients, and to delineate the anterior LLNs only in cases of cT4 tumors, cN2 mesorectal lymph nodes, internal sphincter invasion or positive posterior LLNs.<sup>42</sup>

Until recently, a CT-scan formed the basis for dose planning because dose deposition is calculated according to Hounsfield units. Delineation of treatment volumes is therefore performed on a planning CT-scan. An MRI-scan is often matched to the CT-scan for visual assistance, with the risk of limited accuracy due to internal organ motion between the 2 scans. Nowadays, some institutions perform a dedicated planning-MRI to allow for delineation directly onto the MRI with simulated Hounsfield units used for dose calculation. This significantly improves visualization of pelvic soft tissues and may therefore improve the accurate delineation of the lateral nodal compartments and decrease inter-observer variation. There is, however, currently no available evidence to support or oppose this and future research should examine whether delineations directly onto the planning-MRI results in

**Figure 2** 3D-conformal and VMAT radiation therapy techniques for lateral compartments in rectal cancer. Left image: 3D-conformal radiation therapy. Right image: Volumetric-modulated arc therapy (VMAT). Pink: planning target volume (PTV). Red lines: lateral compartments. Closest turquoise line to PTV: 95% isodose (Color version of the figure is available online.)



improved delineation accuracy and a decrease in inter-observer variation.

External beam radiation therapy (EBRT) is usually delivered with intensity modulated radiation therapy (IMRT) or volumetric modulated arc therapy (VMAT) although many institutions still apply 3D-conformal radiation therapy (3D-CRT). IMRT and VMAT, compared to 3D-CRT, allow for the modulation of radiation beams during treatment, resulting in a more homogenous coverage of the target volume, decreased dose to organs-at-risk and reduced treatment-related toxicity.<sup>47</sup> As demonstrated in Figure 2, the more precise dose distribution in IMRT/VMAT requires the correct identification of LLNs, whereas in 3D-CRT the PTV coverage is more “forgiving,” and underdosage of LLNs is less likely.

Dose-escalation (boost) on LLNs is not routinely performed as there is sparse evidence to support it. An unpublished national questionnaire in the Netherlands revealed that 4 institutions apply a boost to enlarged LLNs. Three institutions apply a simultaneous integrated boost (SIB; a differential dose per fraction to a specific target volume compared to the elective target volume during the same treatment session) of 2.4Gy over 25 fractions to clinically suspicious LLNs. In 1 institution, a SIB of 2.15Gy over 28 fractions is administered if there are multiple internal iliac LLNs or if the

LLNs will not be surgically removed. Only 2 studies have reported on dose-escalation, both with very small patient cohorts. The first study provided an additional boost to clinically positive LLNs of 54.0-59.4Gy at 1.8Gy/fraction, while the second study delivered 53.48-60.2Gy in 27-30 fractions (1.8-2.15Gy/fraction) to clinically suspicious LLNs.<sup>48,49</sup> Both found similar local-control rates for patients who did and did not receive a boost. Therefore, until more evidence is available, the advantages of dose-escalation for enlarged LLNs remains therefore questionable.

## Surgery

The traditional surgical standard of care for rectal cancer is according to the principle of total mesorectal excision (TME). However, surgical options can depend on the response and/or staging of the rectal tumor and (lateral) lymph nodes. Patients with (very) early disease may be treated with local excision using minimally invasive techniques with preservation of the rectum. Similarly, patients who have a cCR after (C)RT may first proceed in a “Watch & Wait” trajectory with intensive surveillance.<sup>36</sup> TME can be performed for primarily resectable disease or after (C)RT for locally advanced disease with favorable response without cCR. In patients with persistent mesorectal fascia involvement or ingrowth

in surrounding structures/organs, a “beyond-TME” approach, such as a pelvic exenteration, is indicated.

LLNs are not routinely removed during surgery, although there are indications that this may be beneficial for certain patients. Various studies have considered when it is necessary to remove LLNs, however, clear international recommendations are lacking. In various Eastern studies, where neoadjuvant treatment is not routinely performed, the primary size of LLNs is often used as indication of involvement.<sup>6,50,51</sup> Sizes ranging from 5-10 mm are mentioned as thresholds for performing an LLND.<sup>6,8,50,52</sup> Histologic examination of LLNs removed during LLND reveal metastases in 37.3%-75.0%.<sup>52-57</sup> Figures for the incidence of LLN metastases are scarce in Western patients, as LLNDs are rarely performed. Evidence focuses therefore primarily on LLR rates, instead of pathologically proven LLNs. The administration of neoadjuvant (C)RT also makes the selection more complex, due to the possibility of downsizing. Several studies have found that LLNs remaining  $\geq 5$  mm after (C)RT were “high-risk” with LLR rates up to 50%.<sup>3,5,7,13,34</sup>

### Surgical Technique

A formal LLND removes all tissue within the lateral compartments following anatomical borders. The ureter and inferior hypogastric nerve-plexus are visualized and retracted medially to ensure they are separated from the operating field, after which all tissue can be dissected.

There are two lateral compartments, the internal iliac, and the obturator compartment (see Figure 1A). These compartments are divided by the lateral border of the primary trunk of the internal iliac artery. The obturator internus muscle forms the lateral border of the dissection and the ureterohypogastric fascia forms the medial border. If necessary, all branches of the internal iliac artery can be dissected, allowing for the complete removal of lymphatic tissue. The surgical division between the compartments is vertical, following the position of the main trunk of the internal iliac artery. The Lateral Node Consortium found that performing a formal LLND for persistently enlarged LLNs resulted in a significant decrease in the LLR rate after 5 years (from 52% to 8%<sup>9</sup>).

### Which Technique to Use?

Some surgeons will perform a LLND together with the urologist or gynecologist as they often have more experience with this procedure. However, urologists and/or gynecologists usually dissect the obturator and external iliac lymph nodes, while the most oncologically important lymph nodes in rectal cancer, the internal iliac nodes, are left behind.<sup>58,59</sup>

Other institutions may only remove individual LLNs, without removing the entire compartment, known as “node-picking.” This approach does not follow general oncological principles, ignoring potential micro-metastatic involvement, extracapsular growth or (lympho-)vascular invasion that may result in tumor spillage or residual disease. Furthermore, this technique poses challenges, such as the correct identification of the LLN. Extraction may also be complex due to excessive fibrosis after radiotherapy with a risk of damaging the hypogastric plexus while searching for the LLN. Two studies with very small populations, found node-picking to be an

ineffective treatment for enlarged LLNs with a 3-year LLR rate of 50%.<sup>8,60</sup>

## Differences in Terminology

An awareness of the various protocols and interpretations within each discipline is essential in supporting effective multidisciplinary collaboration and treatment. An important aspect is the understanding of each specialty’s terminology. According to guidelines and references, radiology, radiation oncology, and surgery currently adhere to differing interpretations of the borders of the lateral compartments. While radiation oncology guidelines present the lateral compartments as being located ventral and dorsal to each other, the surgical interpretation adheres to a vertical separation, with compartments located medial and lateral to each other (Table 1) (Figure 3). The anatomical borders of the lateral compartments are not defined in an official guideline for radiologists.

Results from Steup et al.<sup>1</sup> refer to obturator LLNs which were surgically removed. These “obturator” lymph nodes were then used to discover patterns of recurrence; however, surgical, and radiotherapy interpretations of this location may have differed. While surgeons most likely meant the obturator compartment described by Ogura et al.<sup>9</sup>, radiation oncologists may have interpreted this as the obturator or “anterior” compartment described by Valentini et al.<sup>42</sup> (Table 1 shows how these two compartments differ anatomically from each other). This difference may be understandable when considering each specialty; radiation oncologists define compartments based on a risk-profiles and lymphatic spread, not necessarily including an entire anatomical compartment which surgeons consider during formal dissection. However, while current techniques do not necessarily need to change, an understanding is essential for effective daily practice.

## Recommendations

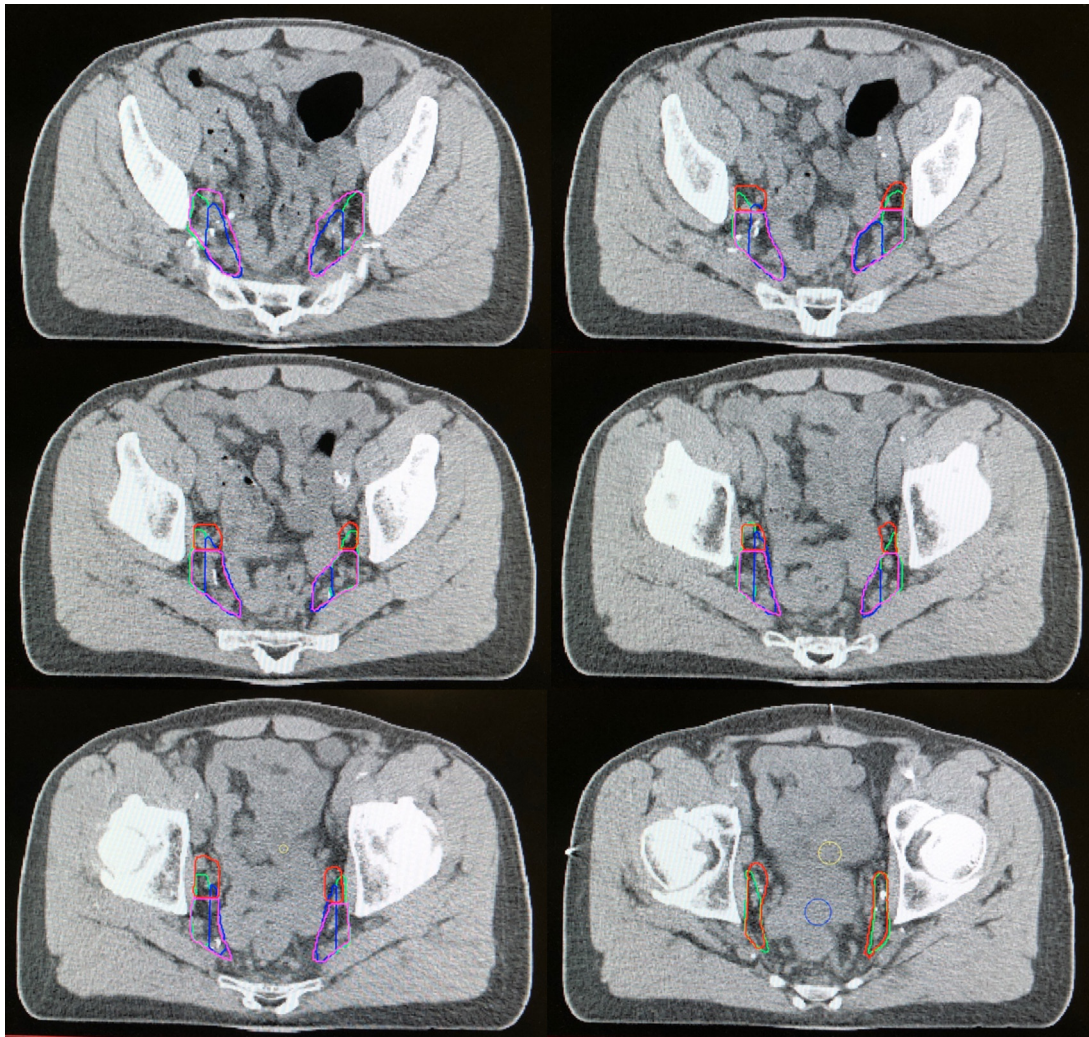
### General

- LLNs should be defined as clinically suspicious if enlarged ( $\geq 7$  mm, SA) and located in the internal iliac or obturator compartment, regardless of other features.
- (Suspicious) LLNs should be discussed during multidisciplinary meetings (MDTs) with all relevant disciplines present whereafter a suitable treatment plan can be made.

### Radiology

- To accurately report LLNs, the MRI should include:
  - High resolution T2-weighted images to study the morphology of LLNs (slice thickness  $\leq 3$  mm,<sup>23</sup> plane resolution of  $\pm 0.6 \times 0.6$  mm<sup>61</sup>).
  - At least 1 sequence with a large FOV to evaluate the lateral compartments and all relevant LLN stations (covering the craniocaudal plane from the promontory to anal canal).
- The presence or absence of LLNs should always be reported, along with the SA (in mm), and in which anatomical compartment the LLN is situated.
- An (additional) MRI-series which is not angulated according to the tumor axis, but a standard axial plane similar to those often

**Figure 3** Anatomical borders of the lateral compartments. Radiation oncology versus surgical definitions for lateral compartments (left to right in caudal progression). Green: surgical obturator compartment. Blue: surgical internal iliac compartment. Red: radiation oncology obturator compartment. Purple: radiation oncology internal iliac compartment (Color version of the figure is available online.)



used in visual atlases, could be considered for a consistent evaluation of LLNs.

- Visual atlases may help radiologists accurately define lateral compartments and decrease heterogeneity during reporting.<sup>9,20</sup> According to the surgical atlas by Ogura et al.,<sup>9</sup> the lateral border of the main trunk of the internal iliac artery should be used as anatomical border between the internal iliac and obturator compartments (Figure 1).
- Annotated “key images” displaying the suspicious LLN(s) are strongly recommended as a visual guide for other specialists.

### *Radiation Oncology.*

- LLNs in curative cases should be considered locally advanced disease and treated with CRT, or a form of TNT.
- An MRI, preferably non-angulated, should be used for delineation to ensure a reliable match with the planning-CT.
- Clinically involved LLNs should lead to bilateral LLN involvement in the CTV, with individual nodal-GTV per LLN to allow for tracking.
- In adherence to the international guidelines by Valentini et al.,<sup>42</sup> at least the “posterior” compartment should be delineated for all “high-risk” patients (Table 1). The additional delineation of the “anterior” compartment is dependent on cT4, N2, internal sphincter involvement or presence of suspicious posterior LLNs.
- In the presence of lateral lymph nodes, the upper border of the mesorectal CTV should be at the level of S1-S2. Inclusion of other areas (such as inguinal regions) are not dependent on the

posterior/anterior compartments but according to tumor defining aspects (see Valentini et al.<sup>42</sup>).

- Preferably, radiotherapy should be delivered using IMRT or VMAT to ensure complete coverage of lateral compartments with limited treatment-related toxicity.
- There is presently insufficient evidence for a boost on LLNs.

#### Reassessment after preoperative treatment.

- Restaging should be performed after neoadjuvant treatment and discussed during MDT meetings.
- Surgical decisions should be based on the response of LLNs:
  - Current evidence infers that internal iliac LLNs > 4 mm (SA) and obturator LLNs > 6 mm (SA) after (C)RT benefit from LLND surgery.
- Patients with LLNs who experience a clinical complete remission (cCR) of both the primary tumor and LLNs after chemoradiation should be carefully assessed with MRI and undergo frequent follow-up.

#### Surgery.

- Current evidence supports LLND to be the most effective treatment strategy for persistently enlarged LLNs after (C)RT.
- An LLND following pre-defined anatomical borders allows for the removal of all lymphatic tissue from the obturator and internal iliac compartments in a nerve-sparing manner. Unilateral or bilateral LLNDs are possible.
- The advisement of TME+LLND surgery should be readdressed for patients who display regrowth of the primary tumor and LLNs after a cCR.
- LLND should be performed in expert tertiary centers to ensure high surgical quality and limit morbidity.
- The scarce evidence available suggests node-picking to be insufficient to decrease LLR rates.

## The Future

Current evidence for selective LLNDs for persistently enlarged LLNs are based on retrospective cohorts. The international prospective LaNoReC study includes all patients with rectal cancer and at least 1 LLN  $\geq$  7 mm (SA). These patients receive standardized (C)RT and all MRI-images and irradiation delineations are centrally reviewed by experts. Patients with persistently enlarged LLNs after (C)RT (> 4 mm SA internal iliac or > 6 mm SA obturator) are advised to undergo a LLND (Figure 4). The primary objective is to reduce the LLR rate to < 6%.

## Conclusion

The risk of developing an LLR is significantly increased in the presence of malignant LLNs. The 3 specialties involved in lateral nodal disease - radiology, radiation oncology and surgery - appear to hold different anatomical interpretations of LLNs, which can result in challenging communication. By presenting the current evidence as well as providing recommendations per specialty, this review aims to facilitate multidisciplinary collaboration, and increase international consensus.

Ultimately, a systematic search for LLNs is warranted with specific attention for primary- and restaging sizes and anatomical locations. Neoadjuvant treatment is recommended, and when LLNs remain persistently enlarged, a formal LLND within anatomical boundaries should be considered.

## Funding

No funding was received.

## Declaration of Interests

All authors declare to have no conflicts of interest.

## References

1. Steup WH, Moriya Y, van de Velde CJ. Patterns of lymphatic spread in rectal cancer. A topographical analysis on lymph node metastases. *Eur J Cancer*. 2002;38:911–918.
2. Iversen H, Mardling A, Johansson H, Nilsson PJ, Holm T. Pelvic local recurrence from colorectal cancer: surgical challenge with changing preconditions. *Colorectal Dis*. 2018;20:399–406.
3. Kim TH, Jeong SY, Choi DH, et al. Lateral lymph node metastasis is a major cause of locoregional recurrence in rectal cancer treated with preoperative chemoradiotherapy and curative resection. *Ann Surg Oncol*. 2008;15:729–737.
4. Roels S, Duthoy W, Haustermans K, et al. Definition and delineation of the clinical target volume for rectal cancer. *Int J Radiat Oncol Biol Phys*. 2006;65:1129–1142.
5. Schaap DP, Ogura A, Nederend J, et al. Prognostic implications of MRI-detected lateral nodal disease and extramural vascular invasion in rectal cancer. *Br J Surg*. 2018;105:1844–1852.
6. Kim MJ, Kim TH, Kim DY, et al. Can chemoradiation allow for omission of lateral pelvic node dissection for locally advanced rectal cancer? *J Surg Oncol*. 2015;111:459–464.
7. Kim TG, Park W, Choi DH, et al. Factors associated with lateral pelvic recurrence after curative resection following neoadjuvant chemoradiotherapy in rectal cancer patients. *Int J Colorectal Dis*. 2014;29:193–200.
8. Ogura A, Konishi T, Cunningham C, et al. Neoadjuvant (Chemo)radiotherapy with total mesorectal excision only is not sufficient to prevent lateral local recurrence in enlarged nodes: results of the multicenter lateral node study of patients with low cT3/4 rectal cancer. *J Clin Oncol*. 2019;37:33–43.
9. Ogura A, Konishi T, Beets GL, et al. Lateral nodal features on restaging magnetic resonance imaging associated with lateral local recurrence in low rectal cancer after neoadjuvant chemoradiotherapy or radiotherapy. *JAMA surgery*. 2019;154.
10. Schaap DP, Boogerd LSF, Konishi T, et al. Rectal cancer lateral lymph nodes: multicentre study of the impact of obturator and internal iliac nodes on oncological outcomes. *Br J Surg*. 2021;108:205–213.
11. Kusters M, Slater A, Muirhead R, et al. What to do with lateral nodal disease in low locally advanced rectal cancer? A call for further reflection and research. *Dis Colon Rectum*. 2017;60:577–585.
12. Kusters M, Uehara K, Velde C, Moriya Y. Is there any reason to still consider lateral lymph node dissection in rectal cancer? Rationale and technique. *Clin Colon Rectal Surg*. 2017;30:346–356.
13. Malakorn S, Yang Y, Bednarski BK, et al. Who should get lateral pelvic lymph node dissection after neoadjuvant chemoradiation? *Dis Colon Rectum*. 2019;62:1158–1166.
14. Peacock O, Chang GJ. The landmark series: management of lateral lymph nodes in locally advanced rectal cancer. *Ann Surg Oncol*. 2020;27:2723–2731.
15. Haanappel A, Kroon HM, Schaap DP, et al. Lateral lymph node metastases in locally advanced low rectal cancers may not be treated effectively with neoadjuvant (chemo)radiotherapy only. *Front Oncol*. 2019;9:1355.
16. Williamson JS, Quyn AJ, Sagar PM. Rectal cancer lateral pelvic sidewall lymph nodes: a review of controversies and management. *Br J Surg*. 2020;107:1562–1569.
17. Kim MJ, Oh JH. Lateral lymph node dissection with the focus on indications, functional outcomes, and minimally invasive surgery. *Ann Coloproctol*. 2018;34:229–233.
18. Ito M, Kobayashi A, Fujita S, et al. Urinary dysfunction after rectal cancer surgery: results from a randomized trial comparing mesorectal excision with and without lateral lymph node dissection for clinical stage II or III lower rectal cancer (Japan Clinical Oncology Group Study, JCOG0212). *Eur J Surg Oncol*. 2018;44:463–468.
19. Saito S, Fujita S, Mizusawa J, et al. Male sexual dysfunction after rectal cancer surgery: results of a randomized trial comparing mesorectal excision with and without lateral lymph node dissection for patients with lower rectal cancer: Japan clinical oncology group study JCOG0212. *Eur J Surg Oncol*. 2016;42:1851–1858.
20. Gollub MJ, Lall C, Lalwani N, Rosenthal MH. Current controversy, confusion, and imprecision in the use and interpretation of rectal MRI. *Abdom Radiol*. 2019;44:3549–3558.
21. Kim JH, Beets GL, Kim MJ, Kessels AG, Beets-tan RG. High-resolution MR imaging for nodal staging in rectal cancer: are there any criteria in addition to the size? *Eur J Radiol*. 2004;52:78–83.



# Lateral Lymph Nodes in Rectal Cancer

22. Brown G, Richards CJ, Bourne MW, et al. Morphologic predictors of lymph node status in rectal cancer with use of high-spatial-resolution MR imaging with histopathologic comparison. *Radiology*. 2003;227:371–377.
23. Beets-Tan RGH, Lambregts DMJ, Maas M, et al. Magnetic resonance imaging for clinical management of rectal cancer: updated recommendations from the 2016 European society of gastrointestinal and abdominal radiology (ESGAR) consensus meeting. *Eur Radiol*. 2018;28:1465–1475.
24. Lahaye MJ, Engelen SM, Nelemans PJ, et al. Imaging for predicting the risk factors—the circumferential resection margin and nodal disease—of local recurrence in rectal cancer: a meta-analysis. *Semin Ultrasound CT MR*. 2005;26:259–268.
25. Bipat S, Glas AS, Slors FJ, Zwinderman AH, Bossuyt PM, Stoker J. Rectal cancer: local staging and assessment of lymph node involvement with endoluminal US, CT, and MR imaging—a meta-analysis. *Radiology*. 2004;232:773–783.
26. Ogawa S, Itabashi M, Hirotsawa T, Hashimoto T, Bamba Y, Okamoto T. Diagnosis of lateral pelvic lymph node metastasis of T1 lower rectal cancer using diffusion-weighted magnetic resonance imaging: a case report with lateral pelvic lymph node dissection of lower rectal cancer. *Mol Clin Oncol*. 2016;4:817–820.
27. Schurink NW, Lambregts DMJ, Beets-Tan RGH. Diffusion-weighted imaging in rectal cancer: current applications and future perspectives. *Br J Radiol*. 2019;92.
28. Matsuoka H, Nakamura A, Masaki T, et al. Optimal diagnostic criteria for lateral pelvic lymph node metastasis in rectal carcinoma. *Anticancer Res*. 2007;27:3529–3533.
29. Cho EY, Kim SH, Yoon JH, et al. Apparent diffusion coefficient for discriminating metastatic from non-metastatic lymph nodes in primary rectal cancer. *Eur J Radiol*. 2013;82:e662–e668.
30. Ishihara S, Kawai K, Tanaka T, et al. Diagnostic value of FDG-PET/CT for lateral pelvic lymph node metastasis in rectal cancer treated with preoperative chemoradiotherapy. *Tech Coloproctol*. 2018;22:347–354.
31. Lambregts DM, Bogveradze N, Blomqvist LK, et al. Current controversies in TNM for the radiological staging of rectal cancer and how to deal with them: results of a global online survey and multidisciplinary expert consensus. *Europ Radiology*. 2022;1–13. doi:10.1007/s00330-022-08591-z.
32. Brown PJ, Rossington H, Taylor J, et al. Standardised reports with a template format are superior to free text reports: the case for rectal cancer reporting in clinical practice. *Eur Radiol*. 2019;29:5121–5128.
33. McMahon CJ, Rofsky NM, Pedrosa I. Lymphatic metastases from pelvic tumors: anatomic classification, characterization, and staging. *Radiology*. 2010;254:31–46.
34. Kim DJ, Chung JJ, Yu JS, Cho ES, Kim JH. Evaluation of lateral pelvic nodes in patients with advanced rectal cancer. *AJR Am J Roentgenol*. 2014;202:1245–1255.
35. Edge SB, Compton CC. The American joint committee on cancer: the 7th edition of the AJCC cancer staging manual and the future of TNM. *Ann Surg Oncol*. 2010;17:1471–1474.
36. Glynne-Jones R, Wyrwicz L, Tiret E, et al. Rectal cancer: ESMO clinical practice guidelines for diagnosis, treatment and follow-up. *Ann Oncol*. 2017;28(suppl\_4):iv22–iv40.
37. Zoccali M, Fichera A. Role of radiation in intermediate-risk rectal cancer. *Ann Surg Oncol*. 2011;19:126–130.
38. Bahadoer RR, Dijkstra EA, van Etten B, et al. Short-course radiotherapy followed by chemotherapy before total mesorectal excision (TME) versus preoperative chemoradiotherapy, TME, and optional adjuvant chemotherapy in locally advanced rectal cancer (RAPIDO): a randomised, open-label, phase 3 trial. *Lancet Oncol*. 2021;22:29–42.
39. Burnet NG, Thomas SJ, Burton KE, Jefferies SJ. Defining the tumour and target volumes for radiotherapy. *Cancer Imaging*. 2004;4:153–161.
40. Brændengen M, Hansson K, Radu C, Siegbahn A, Jacobsson H, Glimelius B. Delineation of gross tumor volume (GTV) for radiation treatment planning of locally advanced rectal cancer using information from MRI or FDG-PET/CT: a prospective study. *Int J Radiat Oncol Biol Phys*. 2011;81:e439–e445.
41. Nijkamp J, Kusters M, Beets-Tan RG, et al. Three-dimensional analysis of recurrence patterns in rectal cancer: the cranial border in hypofractionated preoperative radiotherapy can be lowered. *Int J Radiat Oncol Biol Phys*. 2011;80:103–110.
42. Valentini V, Gambacorta MA, Barbaro B, et al. International consensus guidelines on clinical target volume delineation in rectal cancer. *Radiother Oncol*. 2016;120:195–201.
43. Myerson RJ, Garofalo MC, El Naqa I, et al. Elective clinical target volumes for conformal therapy in anorectal cancer: a radiation therapy oncology group consensus panel contouring atlas. *Int J Radiat Oncol Biol Phys*. 2009;74:824–830.
44. Nijkamp J, de Haas-Kock DF, Beukema JC, et al. Target volume delineation variation in radiotherapy for early stage rectal cancer in the Netherlands. *Radiother Oncol*. 2012;102:14–21.
45. Peters FP, Teo MTW, Appelt AL, et al. Mesorectal radiotherapy for early stage rectal cancer: a novel target volume. *Clin Transl Radiat Oncol*. 2020;21:104–111.
46. Buijck K, Nowacki MP. Emerging standards of radiotherapy combined with radical rectal cancer surgery. *Cancer Treat Rev*. 2002;28:101–113.
47. Wee CW, Kang HC, Wu HG, et al. Intensity-modulated radiotherapy versus three-dimensional conformal radiotherapy in rectal cancer treated with neoadjuvant concurrent chemoradiation: a meta-analysis and pooled-analysis of acute toxicity. *Jpn J Clin Oncol*. 2018;48:458–466.
48. Chen H, Nguyen KNB, Huang H, et al. Effect and safety of radiation therapy boost to extramesorectal lymph nodes in rectal cancer. *Pract Radiat Oncol*. 2020;10:e372–e3e7.
49. Hartvigson PE, Apisarnthanarax S, Schaub S, et al. Radiation therapy dose escalation to clinically involved pelvic sidewall lymph nodes in locally advanced rectal cancer. *Adv Radiat Oncol*. 2019;4:478–486.
50. Akiyoshi T, Ueno M, Matsueda K, et al. Selective lateral pelvic lymph node dissection in patients with advanced low rectal cancer treated with preoperative chemoradiotherapy based on pretreatment imaging. *Ann Surg Oncol*. 2014;21:189–196.
51. Fujita S, Mizusawa J, Kanemitsu Y, et al. Mesorectal excision with or without lateral lymph node dissection for clinical stage II/III lower rectal cancer (JCOG0212): a multicenter, randomized controlled, noninferiority trial. *Ann Surg*. 2017;266:201–207.
52. Akiyoshi T, Matsueda K, Hiratsuka M, et al. Indications for lateral pelvic lymph node dissection based on magnetic resonance imaging before and after preoperative chemoradiotherapy in patients with advanced low-rectal cancer. *Ann Surg Oncol*. 2015;22(3):S614–S620 Suppl.
53. Moriya Y, Sugihara K, Akasu T, Fujita S. Importance of extended lymphadenectomy with lateral node dissection for advanced lower rectal cancer. *World J Surg*. 1997;21:728–732.
54. Sugihara K, Kobayashi H, Kato T, et al. Indication and benefit of pelvic sidewall dissection for rectal cancer. *Dis Colon Rectum*. 2006;49:1663–1672.
55. Ueno H, Mochizuki H, Hashiguchi Y, Hase K. Prognostic determinants of patients with lateral nodal involvement by rectal cancer. *Annals of surgery*. 2001;23:190–197.
56. Ueno M, Oya M, Azekura K, Yamaguchi T, Muto T. Incidence and prognostic significance of lateral lymph node metastasis in patients with advanced low rectal cancer. *Br J Surg*. 2005;92:756–763.
57. Konishi T, Watanabe T, Nagawa H, et al. Preoperative chemoradiation and extended pelvic lymphadenectomy for rectal cancer: two distinct principles. *World J Gastrointest Surg*. 2010;2:95–100.
58. Beveridge TS, Allman BL, Johnson M, Power A, Sheinfeld J, Power NE. Retroperitoneal lymph node dissection: Anatomic and technical considerations from a cadaveric study. *J Urol*. 2016;196:1764–1771.
59. Chen HH, Ting WH, Lin HH, Hsiao SM. Predictors of lymphoceles in women who underwent laparotomic retroperitoneal lymph node dissection for early gynecologic cancer: a retrospective cohort study. *Int J Environ Res Public Health*. 2019;16(6):936. doi:10.3390/ijerph16060936.
60. Kim YI, Jang JK, Park IJ, et al. Lateral lymph node and its association with distant recurrence in rectal cancer: a clue of systemic disease. *Surg Oncol*. 2020;35:174–181.
61. Brown GR M, Williams S. *Recommendations for Cross-Sectional Imaging in Cancer Management*. 2nd Edition. London, UK: The Royal College of Radiologists; 2014.