





Original Article

NeuroSAFE in radical prostatectomy increases the rate of nerve-sparing surgery without affecting oncological outcome

Margaretha A. van der Slot^{1,2,3} , Michael A. den Bakker^{1,2}, Tamara S. C. Tan⁴, Sebastiaan Remmers⁴ , Martijn B. Busstra^{1,4}, Melanie Gan^{1,3}, Sjoerd Klaver^{1,3}, John B. W. Rietbergen^{1,5}, Charlotte F. Kweldam^{1,2}, Mike Kliffen^{1,2}, Karen E. Hamoen^{1,2}, Leo M. Budel^{1,2}, Natascha N. T. Goemaere^{1,2}, Jozien Helleman⁴, Chris H. Bangma⁴, Monique J. Roobol⁴ , and Geert J. L. H. van Leenders⁶  on behalf of the Anser Prostate Cancer Network[†]

¹Anser Prostate operation Clinic, Department of ²Pathology and ³Urology, Maastad Hospital, Department of ⁴Urology, and ⁵Pathology, Erasmus MC University Medical Centre, and ⁶Department of Urology, Franciscus Gasthuis & Vlietland, Rotterdam, The Netherlands

[†]Anser Prostate Cancer Network members are presented in Appendix S1.

Objectives

To investigate the impact of intra-operative neurovascular structure-adjacent frozen-section examination (NeuroSAFE) on the rate of nerve-sparing surgery (NSS) and oncological outcome in a large radical prostatectomy (RP) cohort.

Patients and methods

Between January 2016 and December 2020, 1756 prostate cancer patients underwent robot-assisted RP, of whom 959 (55%) underwent this with NeuroSAFE and 797 (45%) without (control cohort). In cases where NeuroSAFE showed tumour in the margin, a secondary resection was performed. The effect of NeuroSAFE on NSS and positive surgical margin (PSM) status was analysed using logistic regression. Cox regression was used to identify predictors of biochemical recurrence-free survival (BCRFS).

Results and limitations

Patients in the NeuroSAFE cohort had a higher tumour grade ($P < 0.001$) and clinical stage ($P < 0.001$) than those in the control cohort. NeuroSAFE enabled more frequent NSS for both pT2 (93% vs 76%; $P < 0.001$) and pT3 disease (83% vs 55%; $P < 0.001$). In adjusted analysis, NeuroSAFE resulted in more frequent unilateral (odds ratio [OR] 3.90, 95% confidence interval (CI) 2.90–5.30; $P < 0.001$) and bilateral (OR 5.22, 95% CI 3.90–6.98; $P < 0.001$) NSS. While the PSM rate decreased from 51% to 42% in patients with pT3 stage disease ($P = 0.031$), NeuroSAFE was not an independent predictor of PSM status (OR 0.85, 95% CI 0.68–1.06; $P = 0.2$) in the entire cohort. Patients who underwent NeuroSAFE had better BCRFS compared to the control cohort (hazard ratio 0.62, 95% CI 0.45–0.84; $P = 0.002$). This study is limited by its comparison with a historical cohort and lack of functional outcomes.

Conclusions

NeuroSAFE enables more unilateral and bilateral NSS without negatively affecting surgical margin status and biochemical recurrence. This validation study provides a comprehensive overview of the implementation, evaluation and intra-operative decision making associated with NeuroSAFE in clinical practice.

Keywords

frozen-section analysis, nerve-sparing, neurosafe, prostate cancer, robot-assisted radical prostatectomy

Introduction

Radical prostatectomy (RP) has mostly been performed for low- and intermediate-risk prostate cancer but is increasingly offered to men with high-risk disease [1]. RP is complicated by erectile dysfunction and urinary incontinence in 20–90% and 3–16% cases, respectively [2,3]. Preservation of the neurovascular bundles adjacent to the prostate results in better functional outcomes after surgery [4–8]. Clinical suspicion of extraprostatic extension is a relative contraindication for nerve-sparing surgery (NSS) because it could compromise oncological outcomes by increasing the risk of positive surgical margins (PSMs) [9,10]. Preoperative risk assessment of extraprostatic extension is currently based on clinical stage, MRI and nomograms, but prediction is still inaccurate [11]. This might lead to unnecessary removal of neurovascular bundles in localized tumours, or non-focal PSMs if bundles are left intact.

The number of patients undergoing surgery with a nerve-sparing approach can be significantly increased by standardized intra-operative frozen-section (IFS) assessment of prostate surgical margins adjacent to the neurovascular bundles using the NeuroSAFE technique (neurovascular structure-adjacent frozen-section examination), without compromising oncological outcomes [12–15]. With this approach, the prostate is initially removed leaving both neurovascular bundles intact within the pelvis. The tissue adjacent to the neurovascular bundle is removed from the prostate by the urologist and submitted for IFS assessment. If adenocarcinoma extends into the IFS surgical margin, the ipsilateral neurovascular bundle is subsequently removed, otherwise the neurovascular bundle remains intact [16].

Since the development of the NeuroSAFE technique by the Martini Klinik, several centres have implemented this approach, but large independent validation studies are lacking [12–14]. Furthermore, details on the level of NSS and intra-operative clinical decision making have not yet been reported. Since September 2018, RPs in the south-west of the Netherlands have been performed in the high-volume Anser Prostate Operation Clinic with standard NeuroSAFE assessment. The aim of this study was to compare NSS frequency, surgical margin status and oncological outcomes in patients who underwent surgery with and without NeuroSAFE, and to provide guidance for its clinical implementation.

Patients and Methods

Study Population

This study included patients who underwent robot-assisted RP with NeuroSAFE for prostate adenocarcinoma in the Anser Prostate Operation Clinic, situated in Maasstad

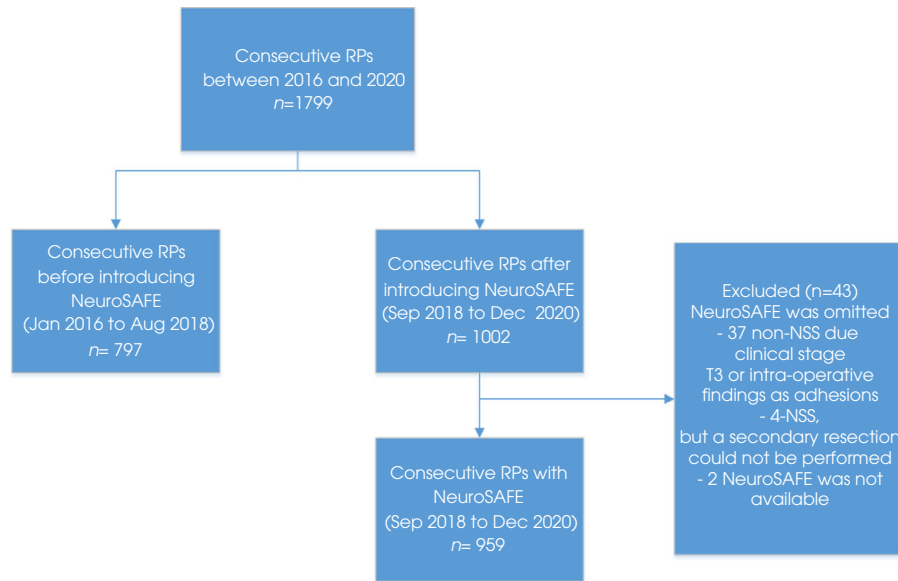
Hospital, between September 2018 and December 2020 (NeuroSAFE cohort), and patients operated in Maasstad Hospital, Franciscus Gasthuis and Vlietland and Erasmus MC, Rotterdam, the Netherlands between January 2016 and September 2018 (control cohort). All operations in the NeuroSAFE and control cohorts were consecutive and performed by the same surgical team of four urologists, each of whom had performed more than 100 laparoscopic or robot-assisted RPs before 2016. Since September 2018 NeuroSAFE has been offered to all consecutive patients in the study cohort irrespective of preoperative erectile dysfunction or urinary incontinence. In a minority of patients ($n = 43$), NeuroSAFE was omitted because of clinically established extraprostatic extension or fibrotic adhesions or no availability of the NeuroSAFE technique; these patients were excluded from further analysis (Fig. 1). None of the patients in the control cohort underwent NeuroSAFE assessment. The clinical decision on NSS in the control cohort was subjectively based on clinical stage, MRI, biopsy Gleason score, and intra-operative assessment. Patients with preoperative radiotherapy or neoadjuvant androgen deprivation therapy were not included. This prospective study was approved by the local ethics committee (METC-2019-352, METC-2019-108).

NeuroSAFE Technique

The NeuroSAFE technique as developed by the Martini Klinik was implemented by the Anser Prostate Operation Clinic as described previously [12,16]. Briefly, the prostate is dissected from the adjacent neurovascular bundles leaving both bundles intact. After removal of the prostate, the surgeon dissects off prostatic tissue adjacent to the neurovascular bundle, from apex to base bilaterally. The dissected posterolateral tissues fragments are inked for orientation and submitted to the Pathology Department for IFS assessment. Meanwhile the surgeon performs haemostasis, vesicourethral anastomosis preparation and pelvic lymph node dissection if indicated. No further resection is performed if the IFS surgical margin status is negative. Our previous study showed no tumour in secondary resections when the IFS had a limited PSM, defined as being present in one frozen section equal to or less than 1 mm and, at most, Gleason pattern 3 at the margin ($n = 58$) [16]. Since February 2019, a secondary resection has been omitted where the IFS analysis showed a limited PSM. A partial or total secondary resection of the neurovascular bundle was carried out when the margin was involved, as described previously [16].

Frozen Section and Pathological Analysis

The inked posterolateral prostate samples were cut into 5-mm sections, snap frozen and stained with haematoxylin and

Fig. 1 Study flow diagram. NSS, nerve-sparing surgery; RP, radical prostatectomy.

eosin, resulting in a total of 7–10 stained sections per side. At microscopic IFS evaluation, a PSM was defined as at least one malignant gland reaching into the inked margin. In case of a PSM, the pathologist reported the number and location of the positive slides, the cumulative length and the Gleason pattern at the margin. Equivocal frozen sections were discussed with a second pathologist intra-operatively to reach a consensus diagnosis. The median (interquartile range [IQR]) time from specimen submission to reporting was 43 (39–50) min, and typically involved three technicians, two cryostats and one pathologist [16].

After the operation, the NeuroSAFE samples, the residual RP specimen and, if present, additional neurovascular bundle resections were formalin-fixed and totally embedded for final diagnosis. RP specimens were graded according to the International Society of Urological Pathology 2014/ WHO 2016 guidelines and staged following the American Joint Committee on Cancer TNM 8th edition. Patients with a negative outer surface margin of the secondary resection after a PSM finding on IFS analysis were considered to have a final negative surgical margin at this site. A detailed description of our NeuroSAFE technique and pathological assessment has been reported previously [16]. To minimize inter-observer variability of pathological assessment between the NeuroSAFE and control cohorts, pathologists from the participating centres held joint educational sessions [17].

Nerve-Sparing Analysis

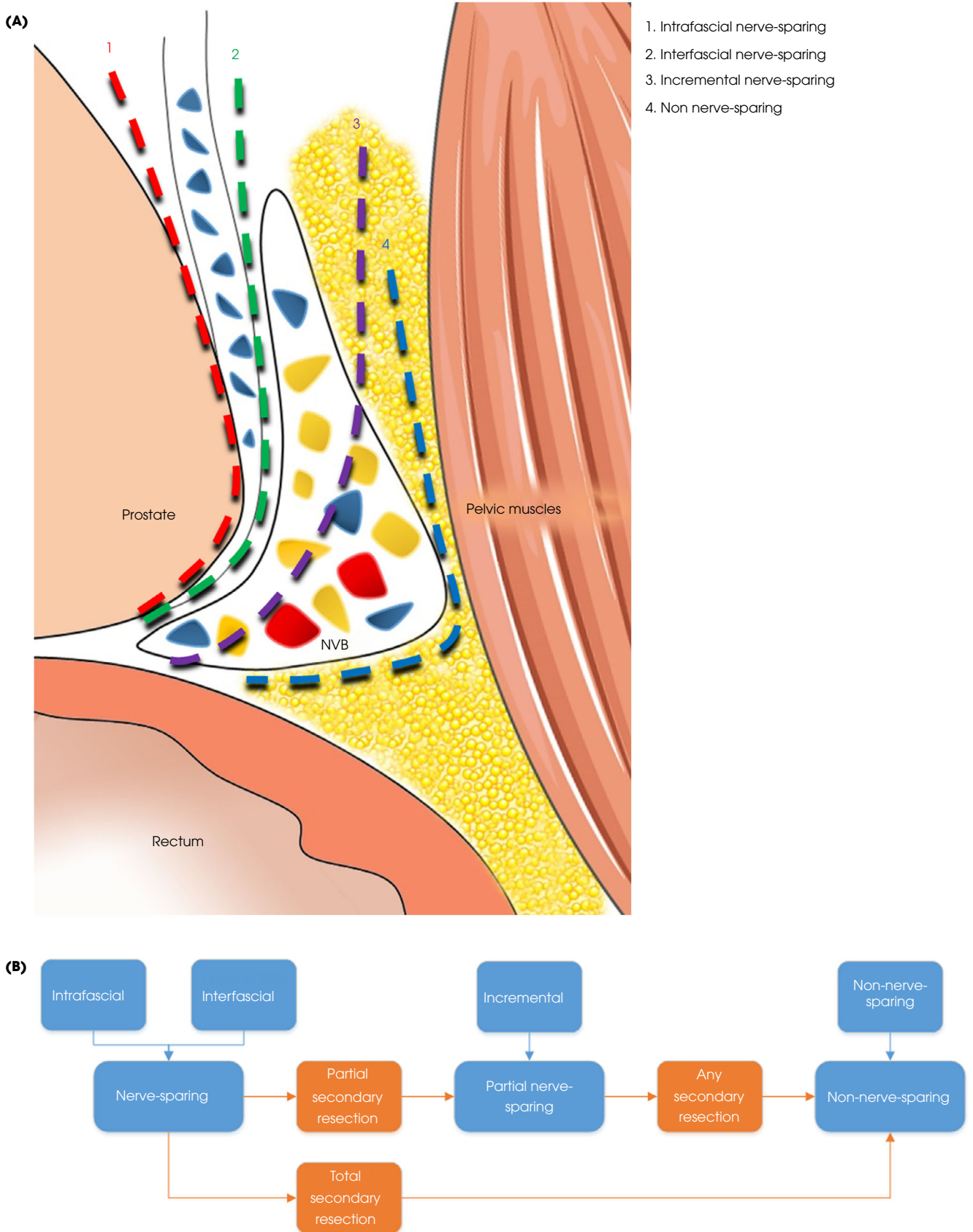
The definitive level of NSS in both the NeuroSAFE and control cohorts was classified as intrafascial, interfascial, incremental and non-nerve-sparing (Fig. 2) [18]. Intrafascial

and interfascial dissection planes are both nerve-sparing techniques, with the intrafascial dissection being closest to the prostate capsule. Incremental dissection is partial NSS, in which some of the nerves are sacrificed while others are preserved, while the complete neurovascular bundle is resected in non-NSS. In this study both intra- and interfascial techniques were categorized as nerve-sparing, and incremental dissection as partial nerve-sparing. In cases of partial secondary resection after NSS, preservation of the neurovascular bundle was defined as partial nerve-sparing and in case of total secondary resection after NSS it was defined as non-nerve-sparing. Any secondary resection after initial partial NSS was considered as non-nerve-sparing. In case of a secondary resection after a positive NeuroSAFE, the definitive level of NSS after secondary resection was used for further analysis.

Statistical Analysis

Median age and PSA levels were compared between the NeuroSAFE and the control cohorts using the Mann–Whitney test, and categorical Grade Groups (GGs) and pT stage were compared using the chi-squared test. The effect of NeuroSAFE on bilateral, unilateral and non-NSS frequency in all patients was evaluated by multinomial logistic regression because the assumption of the ordinal regression was violated. For this purpose, partial dissection was considered as non-NSS. The effect of NeuroSAFE on PSM status was evaluated by logistic regression. Cox regression was used to identify predictors of biochemical recurrence-free survival (BCRFS) in all patients. Biochemical recurrence (BCR) was defined as the first PSA level ≥ 0.2 ng/mL after RP. Patients should at least

Fig. 2 (A) Radical prostatectomy dissection planes in relation to the neurovascular bundle (NVB). (B) Overview of categorization of dissection plane in relation to levels of nerve-sparing.



have 3 months of follow-up. The proportional hazards assumption was met when the differences in follow-up length between the two cohorts were taken into account by censoring the follow-up after 95% of the available follow-up length in the NeuroSAFE cohort. Statistical analyses were performed with R version 4.0.5. A P value of ≤ 0.05 was taken to indicate statistical significance.

Results

Patient Characteristics

The clinicopathological features of the 959 patients in the NeuroSAFE cohort and the 797 patients in the control cohort ($n = 797$) are summarized in Table 1. Patients in the NeuroSAFE cohort were older ($P < 0.001$) and had higher preoperative cT stage ($P < 0.001$), preoperative GG ($P < 0.001$) and D'Amico risk classification ($P < 0.001$) than patients in the control cohort. At RP, patients in the NeuroSAFE cohort had significantly higher tumour grade than those in the control group ($P < 0.001$); 92/959 patients (9.6%) had GG 1 compared to 150/797 (18.8%) in the control group. A slightly greater

proportion of patients in the NeuroSAFE cohort had non-organ-confined disease (40.7%) compared to the control cohort (36.4%), but the difference was not statistically significant ($P = 0.096$). Lymph node metastases were found in 72 patients (7.5%) in the NeuroSAFE cohort and 75 (9.4%) in the control cohort ($P < 0.001$).

Nerve-Sparing Frequency

In the NeuroSAFE cohort, 550/959 patients (57.4%) had undergone bilateral NSS compared to 344/797 (43.2%) in the control cohort, and 301/959 patients (31.4%) had unilateral nerve-sparing compared to 200/797 in the control cohort (25.1%). The frequency of non-NSS in the NeuroSAFE cohort (108/818; 11.3%) was significantly lower ($P < 0.001$) than in the control cohort (253/797; 31.7%). Table 2 shows NSS frequency categorized for pT2 and pT3/4 disease. NeuroSAFE resulted in more frequent NSS in both pathological stages, with the strongest impact observed for pT3 patients who received any form of NSS in 82.8% compared to 54.8% in the control group.

Table 1 Pre- and postoperative patient characteristics of the NeuroSAFE and control radical prostatectomy cohorts.

	NeuroSAFE cohort, $N = 959$	Control cohort, $N = 797$	P
Preoperative characteristics			
Median (IQR) age, years	68 (63–71)	66 (61–70)	<0.001
Median (IQR) PSA, ng/mL	9.1 (6.3–13.4)	9.2 (6.6–13.0)	0.5
Clinical stage, n (%)			
cT1	455 (47.4)	416 (52.2)	<0.001
cT2	375 (39.1)	341 (42.8)	
cT3	129 (13.5)	40 (5.0)	
Biopsy Grade Group, n (%)			
1	200 (20.9)	264 (33.1)	<0.001
2	402 (41.9)	302 (37.9)	
3	202 (21.1)	106 (13.3)	
4	105 (10.9)	73 (9.2)	
5	50 (5.2)	52 (6.5)	
D'Amico risk classification, n (%)			
Low	107 (11.2)	133 (16.7)	<0.001
Intermediate	496 (51.7)	417 (52.3)	
High	356 (37.1)	244 (30.6)	
Unknown	0	3 (0.4)	
Pathological stage, n (%)			
pT2	569 (59.3)	507 (63.6)	0.096
pT3	390 (40.7)	289 (36.3)	
pT3a	266 (27.7)	182 (22.8)	
pT3b	124 (12.9)	107 (13.4)	
pT4		1 (0.1)	
Grade Group (RP), n (%)			
1	92 (9.6)	150 (18.8)	<0.001
2	495 (51.6)	348 (43.7)	
3	269 (28.1)	189 (23.7)	
4	49 (5.1)	60 (7.5)	
5	54 (5.6)	50 (6.3)	
PLND, n (%)			
pN0	491 (51.2)	332 (41.7)	<0.001
pN1	72 (7.5)	75 (9.4)	
pNx	396 (41.3)	390 (48.9)	

IQR, interquartile range; PLND, pelvic lymph node dissection; RP, radical prostatectomy.

Table 2 Frequency of nerve-sparing surgery and positive surgical margin status in the NeuroSAFE and control cohorts.

	NeuroSAFE cohort, N = 959 n (%)	Control cohort, N = 797 n (%)	P	
Nervesparing pT2				
Bilateral	403 (70.8)	275 (54.2)	<0.001	
Unilateral	125 (22.0)	110 (21.7)		
Unilateral	54 (9.5)	62 (12.2)		
Unilateral + partial*	71 (12.5)	48 (9.5)		
None	41 (7.2)	122 (24.1)		
Bilateral partial	30 (5.3)	52 (10.3)		
One side partial	9 (1.6)	4 (0.8)		
None	2 (0.4)	66 (13.0)		
Nervesparing pT≥3				
Bilateral	147 (37.7)	69 (23.8)		<0.001
Unilateral	176 (45.1)	90 (31.0)		
Unilateral	109 (27.9)	70 (24.1)		
Unilateral + partial*	67 (17.2)	20 (6.9)		
None	67 (17.2)	131 (45.2)		
Bilateral partial	29 (7.4)	11 (3.8)		
One side partial	28 (7.2)	4 (1.4)		
None	10 (2.6)	116 (40.0)		
Positive surgical margin			0.4	
pT2	106 (18.6)	93 (18.3)	>0.9	
≤1 mm, GG3 [†]	53 (9.3)	n.a.		
pT3/4	164 (42.1)	147 (50.7)	0.031	
≤1 mm, GG3 [†]	30 (7.7)	n.a.		

*Nerve-sparing on one side plus partial nerve-sparing on the other side. [†]Positive surgical margin of ≤1 mm with only Gleason pattern 3 at surgical margin.

In multinomial logistic regression analysis including age, PSA, RP GG and pT stage as covariates, NeuroSAFE was an independent predictor of both unilateral (odds ratio [OR] 3.92, 95% CI 2.90–5.30; $P < 0.001$) and bilateral (OR 5.22, 95% CI 3.90–6.98; $P < 0.001$) NSS (Table 3). Other factors associated with more frequent NSS were younger age, lower PSA level, RP GG 1–2, and pT2 stage. When only preoperative characteristics were included, namely, biopsy instead of RP GG and clinical stage instead of pathological stage, NeuroSAFE remained an independent predictor for both unilateral (OR 4.06, 95% CI 2.97–5.55; $P < 0.001$) and

bilateral NSS (OR 6.89, 95% CI 5.07–9.36; $P < 0.001$ [Table S1]).

Surgical Margin Status

On final pathological assessment, a PSM was present in 270/959 patients (28.2%) in the NeuroSAFE cohort. After secondary resection, 160 patients (16.8%) had a PSM on an apical, basal or anterolateral non-NeuroSAFE side only, 71 (7.5%) had a PSM on the NeuroSAFE side only, and 39 (4.1%) had a PSM on both the NeuroSAFE side and non-

Table 3 Multinomial logistic regression for unilateral and bilateral nerve-sparing surgery (NSS) in the entire cohort (non-NSS as reference) and multivariable logistic regression analysis for positive surgical margin status.

	Unilateral nerve-sparing			Bilateral nerve-sparing			P	Positive surgical margin			P
	OR	CI	P	OR	CI	P		OR	CI	P	
Age per 10 years	0.60	(0.47–0.78)	<0.001	0.51	(0.41–0.66)	<0.001	<0.001	1.34	(1.18–1.53)	<0.001	0.5
Log ₂ PSA	0.73	(0.62–0.86)	<0.001	0.79	(0.67–0.93)	0.004					
GG											
GG1		Reference									
GG2	1.22	(0.72–2.06)	0.465	0.73	(0.46–1.15)	0.170		1.21	(0.84–1.77)	0.321	
GG3	0.95	(0.55–1.66)	0.867	0.39	(0.24–0.63)	<0.001		1.12	(0.75–1.69)	0.584	
GG4 and GG5	0.60	(0.33–1.10)	0.100	0.22	(0.13–0.38)	<0.001		1.40	(0.89–2.22)	0.153	
pT stage											
pT2		Reference									
pT3/4	1.05	(0.77–1.43)	0.742	0.34	(0.26–0.46)	<0.001		3.25	(2.57–4.11)	<0.001	
NeuroSAFE	3.92	(2.90–5.30)	<0.001	5.22	(3.90–6.98)	<0.001	0.85	(0.68–1.06)	0.151		

GG, grade group; OR, odds ratio.

NeuroSAFE side. In the NeuroSAFE cohort, 53 (9.3%) and 30 patients (7.7%) had a PSM of ≤ 1 mm with Gleason pattern 3 at the surgical margin in pT2 and pT3 group, respectively (Table 2). In the control cohort the Gleason pattern and length of the PSM had not been assessed. PSM rates did not differ significantly ($P = 0.4$) between the NeuroSAFE (28.2%) and control cohorts (30.1%). In multivariable logistic regression, PSA and pT stage were significantly associated with PSM status, while NeuroSAFE (OR 0.85, 95% CI 0.68–1.06; $P = 0.2$) and GG were not (Table 3).

Biochemical Recurrence-Free Survival

Prostate-specific antigen follow-up of at least 3 months after surgery was available for 664 patients (69.2%) in the NeuroSAFE cohort and 448 (56.2%) in the control cohort. The median (IQR) follow-up of patients without BCR was 10.3 (7.0–15.7) months and 15.1 (8.9–26.0) months, respectively.

Biochemical recurrence occurred in 86 patients (12.9%) in the NeuroSAFE cohort and 113 (25.2%) in the control cohort. Cox regression was performed to identify variables associated with BCRFS, with censoring after 24 months (95% of the available follow-up length in the NeuroSAFE cohort) to account for differences in follow-up length. GGs 3–5 were combined into one group because of low numbers of patients. PSA (hazard ratio [HR] 1.2, 95% CI 1.1–1.4; $P = 0.004$), GG ≥ 3 (HR 2.7, 95% CI 1.9–3.9; $P < 0.001$), pT3 stage (HR 1.9, 95% CI 1.4–2.8; $P < 0.001$) and pN1 stage (HR 3.1, 95% CI 0.5–1.1; $P < 0.001$) were significant variables for BCRFS (Table S2). Patients in the NeuroSAFE cohort (HR 0.6, 95% CI 0.5–0.8; $P = 0.002$) had longer BCRFS.

Definitive pathological assessment of the NeuroSAFE cohort after eventual secondary resections showed that 270 patients (28.2%) had a PSM, 106 (11.0%) had a positive IFS which converted to a definitive negative surgical margin after a secondary resection, and 583 (60.8%) had a negative surgical margin. The 24-month BCRFS for patients with a PSM was 0.65 (95% CI 0.55–0.77), for patients with a converted negative surgical margin it was 0.72 (95% CI 0.56–0.93), and for those with a negative surgical margin it was 0.85 (95% CI 0.79–0.91).

Discussion

In this study, we show that use of NeuroSAFE significantly increased the number of patients undergoing NSS without negatively impacting surgical margin status and BCR. The impact of NeuroSAFE was most pronounced in patients with pT3 disease, of whom 82.8% had NSS as compared to 54.8% in the control cohort, while, in patients with pT2 disease, the NSS rates were 92.8% and 75.9% in the NeuroSAFE and control cohorts, respectively. Therefore, NeuroSAFE is a safe

methodology for increasing the rate of NSS without negatively impacting oncological outcome.

Few groups have investigated the impact of NeuroSAFE in prostate cancer patients. Our overall rate of NSS was 92.8% in pT2 and 82.8% in pT3 RPs, which is lower than rates reported by Beyer et al. and Preisser et al., but higher than that reported by Mirmilstein et al. [13,14,19]. Beyer et al. reported an NSS rate of 99% in pT2, 94% in pT3a and 91% in \geq pT3b in 693 robot-assisted RPs at the Martini Klinik [19]. They performed NeuroSAFE mostly in patients with low- and intermediate-risk disease and in a few selected high-risk patients, with 72.4% of patients having pT2 and 79.7% GG 1–2 disease compared to 58.4% and 59.2% in our study, respectively. This selection bias might explain their relatively high NSS frequency. In 156 patients, Preisser et al. reported an NSS rate of 99.0% in pT2 and 88.2% in pT3 patients in their cohort, consisting of 67.3% pT2 and 44.8% GG 1–2 patients [14]. In the study by Mirmilstein et al., 76.7% of the NeuroSAFE patients had pT2 disease and were mostly at intermediate or high risk [13,20]. They perceived an overall NSS frequency of 78% in pT2 and 65.1% in pT3 in their cohort of 120 patients. The NSS rates are difficult to compare due to heterogeneity of the study populations. Furthermore, details on level of NSS, impact of limited positive NeuroSAFE margins, and classification of partial secondary resections were not provided by most studies.

In our logistic regression model, we defined partial nerve-sparing as non-NSS. However, in cases of 'partial' nerve-sparing only a part of the neurovascular bundle has been removed. Partial nerve-sparing was not specified in any of the previous studies; only the feasibility study by Dinneen et al. described partial dissection as one of the nerve-sparing techniques, along with partial secondary resection [13,14,19,21]. The degree of bundle preservation is associated with both urinary incontinence and erectile dysfunction [6]. For instance, men with partial secondary resection after NSS or incremental dissection had better erectile function than those with non-NSS [18,22]. While large studies on functional outcome are still ongoing, NeuroSAFE improved potency rates from 46–51% to 74–77% in two relatively small groups [7,13]. At this moment, the number of patients without preoperative erectile dysfunction and with sufficient follow-up is still too low for analysis of functional outcome.

In agreement with previous studies, we found that NeuroSAFE did not increase PSM rates [13,14,19]. As observed in other studies, we found a significant PSM decrease from 50.7% to 42.1% ($P = 0.031$) in patients with pT3 tumours. While the majority of PSMs occurred at non-NeuroSAFE sides, one-third of margins were positive in the NeuroSAFE area, which could be explained by not performing a secondary resection in minimally positive

NeuroSAFE margins. This was prompted by the fact that a PSM length of ≤ 3 mm and Gleason pattern 3 are associated with low risk for BCR [23–27].

When corrected for PSA, GG, pT stage, surgical margin status and lymph node metastasis, patients undergoing NeuroSAFE had better BCRFS than those without, although follow-up was very short. Schlomm *et al.* found no difference in BCRFS between the NeuroSAFE and non-NeuroSAFE cohorts and Preisser *et al.* showed that NSS was not associated with worse BCRFS in high-risk patients [12,28]. We speculate that our improved outcome in adjusted analysis is explained by more favourable tumour characteristics at the margin with only limited PSM length and presence of Gleason pattern 3, for whom we did not perform a secondary resection. Nevertheless, these results indicate that NeuroSAFE does not negatively impact postoperative clinical outcome.

This is the first prospective comparison study validating the NeuroSAFE results of the Martini Klinik in more than 500 NeuroSAFE patients and without negatively affecting oncological outcome in the short term [12,19]. We provide detailed information on the pathological assessment and subsequent intra-operative clinical decision making facilitating NeuroSAFE implementation in other centres. The most important limitation of this study is the comparison of outcomes in a NeuroSAFE cohort with those of a multicentre historical cohort, although the cohort was operated by the same surgeons and comprised consecutive patients. This, together with the fact that 4.2% of patients in the study cohort were omitted from NeuroSAFE and excluded from analysis, has probably led to patient selection bias. Although the NeuroSAFE technique led to a significant increase in NSS, it is not clear yet to what extent it also reduces postoperative erectile dysfunction and urinary incontinence. In our prospective study, we routinely collect patient-reported outcomes, but the follow-up to date is too short for robust statistical analyses. Similarly, oncological follow-up was short for both cohorts and for the historical control cohort we cannot exclude the possibility that there was therefore positive bias towards patients with BCR. Both the patient selection bias and follow-up time could have influenced the findings of this study. We used a NeuroSAFE approach in the vast majority of patients regardless of their preoperative functional performance. To reduce cost and prolonged operation times, decision algorithms might support selection of patients who are suggested to benefit most from NeuroSAFE. Furthermore, novel imaging techniques, such as three-dimensional modelling to guide NSS or intra-operative fluorescence confocal microscopy, might turn out to be faster and more practical than conventional IFS for NeuroSAFE evaluation in the future [29–31].

In conclusion, in this study, we show that implementation of NeuroSAFE led to more unilateral and bilateral NSS without negatively affecting surgical margin status and BCR rate in a

large RP cohort. Furthermore, we provide a comprehensive description of the implementation of, evaluation of and intra-operative decision making associated with NeuroSAFE in clinical practice.

Acknowledgements

The study was sponsored by a generous grant from the BeterKeten foundation. Open access funding enabled and organized by ProjektDEAL.

Disclosure of Interests

None.

References

- 1 Preisser F, Marchioni M, Nazzani S *et al.* Trend of adverse stage migration in patients treated with radical prostatectomy for localized prostate cancer. *Eur Urol Oncol* 2018; 1: 160–8
- 2 Arroyo C, Martini A, Wang J, Tewari AK. Anatomical, surgical and technical factors influencing continence after radical prostatectomy. *Ther Adv Urol* 2019; 11: 1756287218813787
- 3 Tal R, Alphas HH, Krebs P, Nelson CJ, Mulhall JP. Erectile function recovery rate after radical prostatectomy: A meta-analysis. *J Sex Med* 2009; 6: 2538–46
- 4 Suardi N, Moschini M, Gallina A *et al.* Nerve-sparing approach during radical prostatectomy is strongly associated with the rate of postoperative urinary continence recovery. *BJU Int* 2013; 111: 717–22
- 5 Avulova S, Zhao Z, Lee D *et al.* The effect of nerve sparing status on sexual and urinary function: 3-year results from the CEASAR study. *J Urol* 2018; 199: 1202–9
- 6 Steineck G, Bjartell A, Hugosson J *et al.* Degree of preservation of the neurovascular bundles during radical prostatectomy and urinary continence 1 year after surgery. *Eur Urol* 2015; 67: 559–68
- 7 Fossa SD, Beyer B, Dahl AA *et al.* Improved patient-reported functional outcomes after nerve-sparing radical prostatectomy by using NeuroSAFE technique. *Scand J Urol* 2019; 53: 385–91
- 8 Noel J, Spencer NH, Lodia S *et al.* Neurovascular structure-adjacent frozen-section examination robotic-assisted radical prostatectomy: Outcomes from 500 consecutive cases in the UK. *J Robot Surg* 2021. <https://doi.org/10.1007/s11701-021-01324-2>
- 9 Preston MA, Breau RH, Lantz AG *et al.* The association between nerve sparing and a positive surgical margin during radical prostatectomy. *Urol Oncol* 2015; 33: 18.e1–6
- 10 Mottet N, van den Bergh RCN, Briers E *et al.* EAU-EANM-ESTRO-ESUR-SIOG guidelines on prostate Cancer-2020 update. Part 1: Screening, diagnosis, and local treatment with curative intent. *Eur Urol* 2021; 79: 243–62
- 11 Rocco B, Sighinolfi MC, Sandri M *et al.* Is Extraprostatic extension of cancer predictable? A review of predictive tools and an external validation based on a large and a single center cohort of prostate cancer patients. *Urology* 2019; 129: 8–20
- 12 Schlomm T, Tennstedt P, Huxhold C *et al.* Neurovascular structure-adjacent frozen-section examination (NeuroSAFE) increases nerve-sparing frequency and reduces positive surgical margins in open and robot-assisted laparoscopic radical prostatectomy: Experience after 11,069 consecutive patients. *Eur Urol* 2012; 62: 333–40
- 13 Mirmilstein G, Rai BP, Gbolahan O *et al.* The neurovascular structure-adjacent frozen-section examination (NeuroSAFE) approach to nerve sparing in robot-assisted laparoscopic radical prostatectomy in a British

- setting - a prospective observational comparative study. *BJU Int* 2018; 121: 854–62
- 14 Preisser F, Theissen L, Wild P et al. Implementation of intraoperative frozen section during radical prostatectomy: Short-term results from a German tertiary-care center. *Eur Urol Focus* 2021; 7: 95–101
 - 15 Dinneen EP, Van Der Slot M, Adasonla K et al. Intraoperative frozen section for margin evaluation during radical prostatectomy: A systematic review. *Eur Urol Focus* 2020; 6: 664–73
 - 16 van der Slot MA, den Bakker MA, Klaver S et al. Intraoperative assessment and reporting of radical prostatectomy specimens to guide nerve-sparing surgery in prostate cancer patients (NeuroSAFE). *Histopathology* 2020; 77: 539–47
 - 17 van der Slot MA, Hollemans E, den Bakker MA et al. Inter-observer variability of cribriform architecture and percent Gleason pattern 4 in prostate cancer: Relation to clinical outcome. *Virchows Arch* 2021; 478: 249–56
 - 18 Tewari AK, Srivastava A, Huang MW et al. Anatomical grades of nerve sparing: A risk-stratified approach to neural-hammock sparing during robot-assisted radical prostatectomy (RARP). *BJU Int* 2011; 108(6 Pt 2): 984–92
 - 19 Beyer B, Schlomm T, Tennstedt P et al. A feasible and time-efficient adaptation of NeuroSAFE for da Vinci robot-assisted radical prostatectomy. *Eur Urol* 2014; 66: 138–44
 - 20 Vasdev N, Agarwal S, Rai BP et al. Intraoperative frozen section of the prostate reduces the risk of positive margin whilst ensuring nerve sparing in patients with intermediate and high-risk prostate cancer undergoing robotic radical prostatectomy: First reported UK series. *Curr Urol* 2016; 9: 93–103
 - 21 Dinneen E, Haider A, Grierson J et al. NeuroSAFE frozen section during robot-assisted radical prostatectomy (RARP): Peri-operative and histopathological outcomes from the NeuroSAFE PROOF feasibility randomised controlled trial. *BJU Int* 2021; 127: 676–86
 - 22 Hatzichristodoulou G, Wagenpfeil S, Weirich G et al. Intraoperative frozen section monitoring during nerve-sparing radical prostatectomy: Evaluation of partial secondary resection of neurovascular bundles and its effect on oncologic and functional outcome. *World J Urol* 2016; 34: 229–36
 - 23 Preisser F, Coxilha G, Heinze A et al. Impact of positive surgical margin length and Gleason grade at the margin on biochemical recurrence in patients with organ-confined prostate cancer. *Prostate* 2019; 79: 1832–6
 - 24 Sooriakumaran P, Ploumidis A, Nyberg T et al. The impact of length and location of positive margins in predicting biochemical recurrence after robot-assisted radical prostatectomy with a minimum follow-up of 5 years. *BJU Int* 2015; 115: 106–13
 - 25 Dev HS, Wiklund P, Patel V et al. Surgical margin length and location affect recurrence rates after robotic prostatectomy. *Urol Oncol* 2015; 33 (3): 109.e7–13
 - 26 Brimo F, Partin AW, Epstein JI. Tumor grade at margins of resection in radical prostatectomy specimens is an independent predictor of prognosis. *Urology* 2010; 76: 1206–9
 - 27 Kates M, Sopko NA, Han M, Partin AW, Epstein JI. Importance of reporting the Gleason score at the positive surgical margin site: Analysis of 4,082 consecutive radical prostatectomy cases. *J Urol* 2016; 195: 337–42
 - 28 Preisser F, Gandaglia G, Arad F et al. Association of neurovascular bundle preservation with oncological outcomes in patients with high-risk prostate cancer. *Prostate Cancer Prostatic Dis* 2021; 24: 193–201
 - 29 Rocco B, Sarchi L, Assumma S et al. Digital frozen sections with fluorescence confocal microscopy during robot-assisted radical prostatectomy: Surgical technique. *Eur Urol* 2021; 80: 724–9
 - 30 Porpiglia F, Amparore D, Checcucci E et al. Current use of three-dimensional model Technology in Urology: A road map for personalised surgical planning. *Eur Urol Focus* 2018; 4: 652–6
 - 31 Schiavina R, Bianchi L, Lodi S et al. Real-time augmented reality three-dimensional guided robotic radical prostatectomy: Preliminary experience and evaluation of the impact on surgical planning. *Eur Urol Focus* 2021; 7: 1260–7

Correspondence: Margaretha A. van der Slot, MD, Anser Prostate operation Clinic, Maasstadweg 21, 3079 DZ Rotterdam, The Netherlands.

e-mail: slotm@maasstadziekenhuis.nl

Abbreviations: BCR, biochemical recurrence; BCRFS, biochemical recurrence-free survival; GG, grade group; HR, hazard ratio; IFS, intra-operative frozen section; NeuroSAFE, neurovascular structure-adjacent frozen-section examination; NSS, nerve-sparing surgery; OR, odds ratio; PSM, positive surgical margin; RP, radical prostatectomy.

Supporting Information

Additional Supporting Information may be found in the online version of this article:

Appendix S1 On behalf of the Anser Prostate Cancer Network', dated 23 July 2021.

Table S1. Multinomial logistic regression for unilateral and bilateral nerve-sparing with preoperative characteristics (odds ratio [OR] with confidence interval [CI]).

Table S2. Biochemical recurrence-free survival of the entire cohort.