

World Journal of *Clinical Cases*

World J Clin Cases 2021 October 6; 9(28): 8280-8626



REVIEW

- 8280** Transmission of severe acute respiratory syndrome coronavirus 2 via fecal-oral: Current knowledge
Silva FAFD, de Brito BB, Santos MLC, Marques HS, da Silva Júnior RT, de Carvalho LS, de Sousa Cruz S, Rocha GR, Santos GLC, de Souza KC, Maciel RGA, Lopes DS, Silva NOE, Oliveira MV, de Melo FF
- 8295** Nutrition, nutritional deficiencies, and schizophrenia: An association worthy of constant reassessment
Onaolapo OJ, Onaolapo AY

MINIREVIEWS

- 8312** Grounded theory qualitative approach from Foucault's ethical perspective: Deconstruction of patient self-determination in the clinical setting
Molina-Mula J
- 8327** Diabetes mellitus and COVID-19: Understanding the association in light of current evidence
Sen S, Chakraborty R, Kalita P, Pathak MP

ORIGINAL ARTICLE**Case Control Study**

- 8340** Pregnancy complications effect on the nickel content in maternal blood, placenta blood and umbilical cord blood during pregnancy
Ding AL, Hu H, Xu FP, Liu LY, Peng J, Dong XD

Retrospective Study

- 8349** Clinical observation of Kuntai capsule combined with Fenmotong in treatment of decline of ovarian reserve function
Lin XM, Chen M, Wang QL, Ye XM, Chen HF
- 8358** Short-term effect and long-term prognosis of neuroendoscopic minimally invasive surgery for hypertensive intracerebral hemorrhage
Wei JH, Tian YN, Zhang YZ, Wang XJ, Guo H, Mao JH
- 8366** Ultrasonographic assessment of cardiac function and disease severity in coronary heart disease
Zhang JF, Du YH, Hu HY, Han XQ
- 8374** COVID-19 among African Americans and Hispanics: Does gastrointestinal symptoms impact the outcome?
Ashktorab H, Folake A, Pizuorno A, Oskrochi G, Oppong-Twene P, Tamanna N, Mehdipour Dalivand M, Umeh LN, Moon ES, Kone AM, Banson A, Federman C, Ramos E, Awoyemi EO, Wonni BJ, Otto E, Maskalo G, Velez AO, Rankine S, Thrift C, Ekwunazu C, Scholes D, Chirumamilla LG, Ibrahim ME, Mitchell B, Ross J, Curtis J, Kim R, Gilliard C, Mathew J, Laiyemo A, Kibreab A, Lee E, Sherif Z, Shokrani B, Aduli F, Brim H

Observational Study

- 8388** Validated tool for early prediction of intensive care unit admission in COVID-19 patients
Huang HF, Liu Y, Li JX, Dong H, Gao S, Huang ZY, Fu SZ, Yang LY, Lu HZ, Xia LY, Cao S, Gao Y, Yu XX
- 8404** Comparison of the impact of endoscopic retrograde cholangiopancreatography between pre-COVID-19 and current COVID-19 outbreaks in South Korea: Retrospective survey
Kim KH, Kim SB

Randomized Controlled Trial

- 8413** Effect of family caregiver nursing education on patients with rheumatoid arthritis and its impact factors: A randomized controlled trial
Li J, Zhang Y, Kang YJ, Ma N

SYSTEMATIC REVIEWS

- 8425** Dealing with hepatic artery traumas: A clinical literature review
Dilek ON, Atay A
- 8441** Clinical considerations for critically ill COVID-19 cancer patients: A systematic review
Ramasamy C, Mishra AK, John KJ, Lal A

CASE REPORT

- 8453** Atypical granular cell tumor of the urinary bladder: A case report
Wei MZ, Yan ZJ, Jiang JH, Jia XL
- 8461** Hepatocyte nuclear factor 1B mutation in a Chinese family with renal cysts and diabetes syndrome: A case report
Xiao TL, Zhang J, Liu L, Zhang B
- 8470** Ultrasound features of primary non-Hodgkin's lymphoma of the palatine tonsil: A case report
Jiang R, Zhang HM, Wang LY, Pian LP, Cui XW
- 8476** Percutaneous drainage in the treatment of intrahepatic pancreatic pseudocyst with Budd-Chiari syndrome: A case report
Zhu G, Peng YS, Fang C, Yang XL, Li B
- 8482** Postmenopausal women with hyperandrogenemia: Three case reports
Zhu XD, Zhou LY, Jiang J, Jiang TA
- 8492** Extremely high titer of hepatitis B surface antigen antibodies in a primary hepatocellular carcinoma patient: A case report
Han JJ, Chen Y, Nan YC, Yang YL
- 8498** Surgical treatment of liver metastasis with uveal melanoma: A case report
Kim YH, Choi NK

- 8504** Intermittent appearance of right coronary fistula and collateral circulation: A case report
Long WJ, Huang X, Lu YH, Huang HM, Li GW, Wang X, He ZL
- 8509** Synchronous concomitant pancreatic acinar cell carcin and gastric adenocarcinoma: A case report and review of literature
Fang T, Liang TT, Wang YZ, Wu HT, Liu SH, Wang C
- 8518** Spontaneous resolution of gallbladder hematoma in blunt traumatic injury: A case report
Jang H, Park CH, Park Y, Jeong E, Lee N, Kim J, Jo Y
- 8524** Rupture of ovarian endometriotic cyst complicated with endometriosis: A case report
Wang L, Jiang YJ
- 8531** Rotarex mechanical thrombectomy in renal artery thrombosis: A case report
Li WR, Liu MY, Chen XM, Zhang ZW
- 8537** Necrotizing fasciitis of cryptoglandular infection treated with multiple incisions and thread-dragging therapy: A case report
Tao XC, Hu DC, Yin LX, Wang C, Lu JG
- 8545** Endoscopic joint capsule and articular process excision to treat lumbar facet joint syndrome: A case report
Yuan HJ, Wang CY, Wang YF
- 8552** Spinocerebellar ataxia type 3 with dopamine-responsive dystonia: A case report
Zhang XL, Li XB, Cheng FF, Liu SL, Ni WC, Tang FF, Wang QG, Wang XQ
- 8557** Disseminated soft tissue diffuse large B-cell lymphoma involving multiple abdominal wall muscles: A case report
Lee CH, Jeon SY, Yhim HY, Kwak JY
- 8563** Genetic characteristics of a patient with multiple primary cancers: A case report
Ouyang WW, Li QY, Yang WG, Su SF, Wu LJ, Yang Y, Lu B
- 8571** Hypereosinophilia with cerebral venous sinus thrombosis and intracerebral hemorrhage: A case report and review of the literature
Song XH, Xu T, Zhao GH
- 8579** Itraconazole therapy for infant hemangioma: Two case reports
Liu Z, Lv S, Wang S, Qu SM, Zhang GY, Lin YT, Yang L, Li FQ
- 8587** One-stage total hip arthroplasty for advanced hip tuberculosis combined with developmental dysplasia of the hip: A case report
Zhu RT, Shen LP, Chen LL, Jin G, Jiang HT
- 8595** *Pneumocystis jirovecii* and *Legionella pneumophila* coinfection in a patient with diffuse large B-cell lymphoma: A case report
Wu WH, Hui TC, Wu QQ, Xu CA, Zhou ZW, Wang SH, Zheng W, Yin QQ, Li X, Pan HY

- 8602** Delayed massive cerebral infarction after perioperative period of anterior cervical discectomy and fusion: A case report
Jia F, Du CC, Liu XG
- 8609** Cortical bone trajectory fixation in cemented vertebrae in lumbar degenerative disease: A case report
Chen MM, Jia P, Tang H
- 8616** Primary intramedullary melanocytoma presenting with lower limbs, defecation, and erectile dysfunction: A case report and review of the literature
Liu ZQ, Liu C, Fu JX, He YQ, Wang Y, Huang TX

ABOUT COVER

Editorial Board Member of *World Journal of Clinical Cases*, Domenico De Berardis, MD, PhD, Adjunct Professor, Chief Doctor, NHS, Department of Mental Health, Teramo 64100, Italy. domenico.deberardis@aslteramo.it

AIMS AND SCOPE

The primary aim of *World Journal of Clinical Cases* (*WJCC*, *World J Clin Cases*) is to provide scholars and readers from various fields of clinical medicine with a platform to publish high-quality clinical research articles and communicate their research findings online.

WJCC mainly publishes articles reporting research results and findings obtained in the field of clinical medicine and covering a wide range of topics, including case control studies, retrospective cohort studies, retrospective studies, clinical trials studies, observational studies, prospective studies, randomized controlled trials, randomized clinical trials, systematic reviews, meta-analysis, and case reports.

INDEXING/ABSTRACTING

The *WJCC* is now indexed in Science Citation Index Expanded (also known as SciSearch®), Journal Citation Reports/Science Edition, Scopus, PubMed, and PubMed Central. The 2021 Edition of Journal Citation Reports® cites the 2020 impact factor (IF) for *WJCC* as 1.337; IF without journal self cites: 1.301; 5-year IF: 1.742; Journal Citation Indicator: 0.33; Ranking: 119 among 169 journals in medicine, general and internal; and Quartile category: Q3. The *WJCC*'s CiteScore for 2020 is 0.8 and Scopus CiteScore rank 2020: General Medicine is 493/793.

RESPONSIBLE EDITORS FOR THIS ISSUE

Production Editor: Yan-Xia Xing; Production Department Director: Yan-Jie Ma; Editorial Office Director: Jin-Lai Wang.

NAME OF JOURNAL

World Journal of Clinical Cases

ISSN

ISSN 2307-8960 (online)

LAUNCH DATE

April 16, 2013

FREQUENCY

Thrice Monthly

EDITORS-IN-CHIEF

Dennis A Bloomfield, Sandro Vento, Bao-Gan Peng

EDITORIAL BOARD MEMBERS

<https://www.wjgnet.com/2307-8960/editorialboard.htm>

PUBLICATION DATE

October 6, 2021

COPYRIGHT

© 2021 Baishideng Publishing Group Inc

INSTRUCTIONS TO AUTHORS

<https://www.wjgnet.com/bpg/gerinfo/204>

GUIDELINES FOR ETHICS DOCUMENTS

<https://www.wjgnet.com/bpg/GerInfo/287>

GUIDELINES FOR NON-NATIVE SPEAKERS OF ENGLISH

<https://www.wjgnet.com/bpg/gerinfo/240>

PUBLICATION ETHICS

<https://www.wjgnet.com/bpg/GerInfo/288>

PUBLICATION MISCONDUCT

<https://www.wjgnet.com/bpg/gerinfo/208>

ARTICLE PROCESSING CHARGE

<https://www.wjgnet.com/bpg/gerinfo/242>

STEPS FOR SUBMITTING MANUSCRIPTS

<https://www.wjgnet.com/bpg/GerInfo/239>

ONLINE SUBMISSION

<https://www.f6publishing.com>

Primary intramedullary melanocytoma presenting with lower limbs, defecation, and erectile dysfunction: A case report and review of the literature

Zhi-Qiang Liu, Chao Liu, Jia-Xin Fu, Yan-Qing He, Ying Wang, Tian-Xiang Huang

ORCID number: Zhi-Qiang Liu 0000-0002-7579-6280; Chao Liu 0000-0003-2184-9102; Jia-Xin Fu 0000-0002-9309-9411; Yan-Qing He 0000-0002-6009-8383; Ying Wang 0000-0002-7112-7813; Tian-Xiang Huang 0000-0003-3613-0977.

Author contributions: Liu ZQ drafted the manuscript; Huang TX reviewed the literature and contributed to manuscript drafting; Liu C and Fu JX collected and analysed the data; He YQ and Wang Y were responsible for the follow-up; all authors issued final approval for the version to be submitted.

Supported by Natural Science Foundation of Hunan Province, China, No. 2019JJ50964.

Informed consent statement: Informed written consent was obtained from the patient for publication of this report and any accompanying images.

Conflict-of-interest statement: The authors declare that they have no conflict of interest to report.

CARE Checklist (2016) statement: The authors have read the CARE Checklist (2016), and the manuscript was prepared and revised according to the CARE

Zhi-Qiang Liu, Department of Neuroscience, Erasmus Medical Center, Erasmus University Rotterdam, Rotterdam 3015 AA, Netherlands

Chao Liu, Department of Oncology, Xiangya Hospital of Central South University, Changsha 410008, Hunan Province, China

Jia-Xin Fu, Grade of 2015 in Oral Medicine, Medical College of Jinzhou Medical University, Jinzhou 121001, Liaoning Province, China

Yan-Qing He, Ying Wang, Tian-Xiang Huang, Department of Neurosurgery, Xiangya Hospital of Central South University, Changsha 410008, Hunan Province, China

Corresponding author: Tian-Xiang Huang, MD, PhD, Research Associate, Department of Neurosurgery, Xiangya Hospital of Central South University, No. 87 Xiangya Road, Changsha 410008, Hunan Province, China. zhiqiangliu668@163.com

Abstract

BACKGROUND

Primary intramedullary melanocytoma is an exceedingly rare type of primary melanocytic tumor in the central nervous system. Unfortunately, primary intramedullary melanocytoma lacks specificity in clinical symptoms and imaging features and there is currently no standard strategy for diagnosis or treatment.

CASE SUMMARY

A 52-year-old male patient suffered from weakness and numbness involving the bilateral lower limbs for 18 mo, and defecation and erectile dysfunction for 6 mo. Furthermore, these symptoms started to worsen for the last 3 mo. Preoperative magnetic resonance imaging (MRI) revealed an intramedullary tumor located at the T9-T10 level. In subsequently surgery, the maximal safe resection extent approached to 98%. The lesion was confirmed to be melanocytoma by pathological examination. In addition, the possibility of original melanocytoma outside the spinal cord was excluded after the examination of the whole body. Therefore, a diagnosis of primary intramedullary melanocytoma was established. The patient refused to accept radiotherapy or Gamma Knife, but MRI examination on July 28, 2020 showed no sign of development. In addition, on April 10, 2021, the recent review showed that the disorder of defecation and lower limbs improved further but erectile dysfunction benefited a little from the surgery.

Checklist (2016).

Open-Access: This article is an open-access article that was selected by an in-house editor and fully peer-reviewed by external reviewers. It is distributed in accordance with the Creative Commons Attribution NonCommercial (CC BY-NC 4.0) license, which permits others to distribute, remix, adapt, build upon this work non-commercially, and license their derivative works on different terms, provided the original work is properly cited and the use is non-commercial. See: <http://creativecommons.org/licenses/by-nc/4.0/>

Manuscript source: Unsolicited manuscript

Specialty type: Clinical neurology

Country/Territory of origin: China

Peer-review report's scientific quality classification

Grade A (Excellent): 0
Grade B (Very good): 0
Grade C (Good): C
Grade D (Fair): 0
Grade E (Poor): 0

Received: May 29, 2021

Peer-review started: May 29, 2021

First decision: June 14, 2021

Revised: June 16, 2021

Accepted: August 6, 2021

Article in press: August 6, 2021

Published online: October 6, 2021

P-Reviewer: Bains L

S-Editor: Wu YXJ

L-Editor: Wang TQ

P-Editor: Ma YJ



CONCLUSION

After diagnosing intramedullary melanocytoma by postoperative pathology, the inspection of the whole body contributed to excluding the possibility of metastasis from other regions and further suggested a diagnosis of primary intramedullary melanocytoma. Complete resection, adjuvant radiation, and regular review are critical. In addition, maximal safe resection also benefits prognosis while the tumor is difficult to be resected totally.

Key Words: Primary intramedullary melanocytoma; Diagnosis; Treatment; Prognosis; Case report

©The Author(s) 2021. Published by Baishideng Publishing Group Inc. All rights reserved.

Core Tip: Primary intramedullary melanocytoma is an extremely rare kind of primary melanocytic tumor within the spinal cord. The features in imaging are nonspecific depending on the degree of melanization, intra-tumoral hemorrhage, and duration of bleeding. Therefore, diagnosis confirmation consists of two key points: (1) Pathological test; and (2) excluding the possibility of metastases from other melanocytomas outside the spinal cord using the positron emission tomography-computed tomography scanning and physical examination of the whole body. The recommended therapy strategy includes complete resection and subsequent adjuvant radiation or Gamma Knife radiosurgery. Besides, maximal safe resection is also beneficial for cases with difficulty to be resected totally. More case studies are needed to determine the optimal management strategy due to its rarity.

Citation: Liu ZQ, Liu C, Fu JX, He YQ, Wang Y, Huang TX. Primary intramedullary melanocytoma presenting with lower limbs, defecation, and erectile dysfunction: A case report and review of the literature. *World J Clin Cases* 2021; 9(28): 8616-8626

URL: <https://www.wjgnet.com/2307-8960/full/v9/i28/8616.htm>

DOI: <https://dx.doi.org/10.12998/wjcc.v9.i28.8616>

INTRODUCTION

Primary melanocytic tumors can be generally divided into diffuse melanocytosis, melanocytoma, malignant melanoma, and meningeal melanomatosis according to the 2007 World Health Organisation (WHO) classification of tumors in the central nervous system (CNS)[1]. Besides, primary melanocytoma in the CNS derived from melanocyte of the leptomeninges instead of meningotheial cells is a rare type of neoplasm with an incidence of 1 per 10 million[2]. In general, melanocytomas are classified as intermediate grade melanocytic tumors and are usually located in the posterior fossa and spinal cord. In addition, the distribution percentage of primary intramedullary melanocytoma at the cervical, thoracic, and lumbosacral levels is 28.3%, 52.8%, and 18.9%, respectively[2].

Melanocytomas have been historically considered as benign neoplasms with mild cytology, but an increasing body of evidence has indicated the latent tendency of melanocytomas to relapse, metastasize, or transform to malignant melanocytic neoplasms[3]. Given the potential malignancy of melanocytomas, gross total resection and following radiotherapy may be the preferable treatment in an attempt to have a better prognosis of the disease[3]. Here, we describe the case of a 52-year-old man with primary intramedullary melanocytoma and furthermore discuss the diagnosis and therapy by combining the relevant background literature and the present case.

CASE PRESENTATION

Chief complaints

A 52-year-old male patient was admitted for weakness and numbness involving the bilateral lower limbs for 18 mo, and disorder of defecation and erectile dysfunction for

6 mo. For the last 3 mo, these symptoms started to worsen.

History of present illness

The patient started to present disorders of bilateral lower limbs in January 2016, and defecation and erectile dysfunction in January 2017. Subsequently, he received magnetic resonance imaging examination at a local hospital, which suggested an intramedullary mass located at the level of T9-T10. However, he did not take any cure. In April 2017, the clinical symptoms began to worsen. Therefore, the patient was admitted to our department on July 13, 2017 for further treatment.

History of past illness

The patient underwent an appendectomy in 1984, and had suffered from diabetes for 7 years and hypertension for 2 years. He had been taking nimodipine, metformin, and gliclazide to control the blood pressure and blood glucose levels under the supervision of local doctors.

Personal and family history

Neither he nor anyone in his family had a history of primary intramedullary melanocytoma.

Physical examination

Neurologic examination presented that the myodynamia of the right lower limb was grade 3 and left lower limb was grade 4. Besides, the superficial and deep sense in the right lower limb was clearly worse than that of the left lower limb and these dysfunctions in distal lower limbs were more severe than those of proximal lower limbs as well. Moreover, achilles tendon reflex and patellar tendon reflex were brisk with absence of ankle and patellar clonus. Babinski sign was positive in the right lower limb. Anal reflex revealed a mild decrease and the Romberg sign was positive.

Laboratory examinations

Total protein was slightly low (63.2 g/L). Triglyceride (1.75 mmol/L) and low density lipoprotein (3.47 mmol/L) were a little high. Color doppler ultrasound of the stomach and pelvis indicated a single gallbladder polyp (3 mm × 3 mm) and gallstone (5 mm × 4 mm), and benign prostate hyperplasia with multiple calcifications. The routine blood, urine, and stool tests were normal. Electrocardiogram, chest X-ray, cardiac color Doppler ultrasound, pulmonary ventilation function, and blood glucose were also normal.

Imaging examinations

Magnetic resonance imaging (MRI) revealed an intramedullary tumor located at the T9-T10 level with oval borders and a size of 5.5 cm × 1.2 cm × 1.2 cm. The mass was slightly hyperintense on T1-weighted images (T1WI) (Figure 1A) and hypointense on T2-weighted images (T2WI) (Figure 1B). Contrast-enhanced MRI of the tumor showed mildly inhomogeneous enhancement after gadolinium administration (Figure 1C and G). The secondary lesions like syringomyelia induced by the intramedullary tumor were hypointense on T1WI (Figure 1A) and hyperintense on T2WI (Figure 1B) with mild enhancement after gadolinium management at the T5-T8 level (Figure 1C).

FINAL DIAGNOSIS

The lesion was confirmed to be melanocytoma by histopathological examination with typical characteristics of primary melanocytic tumors like positive manifestation of sex determinant region Y box 10 (SOX10) protein, human melanoma black 45 (HMB-45), and antimelanoma antibody, and negative presence of epithelial membrane antigen (EMA) and glial fibrillary acidic protein (GFAP). The proliferative index (Ki 67) was almost equal to 3% (Figure 2). The possibility of original melanocytoma outside the spinal cord was excluded after the examinations of postoperative positron emission tomography-computed tomography (PET-CT) scanning, ophthalmological test, and gastrointestinal and dermatological inspection (Figure 3A-C). Accordingly, the final diagnosis of the patient was primary and intramedullary intermediate grade melanocytoma at the T9-T10 level.

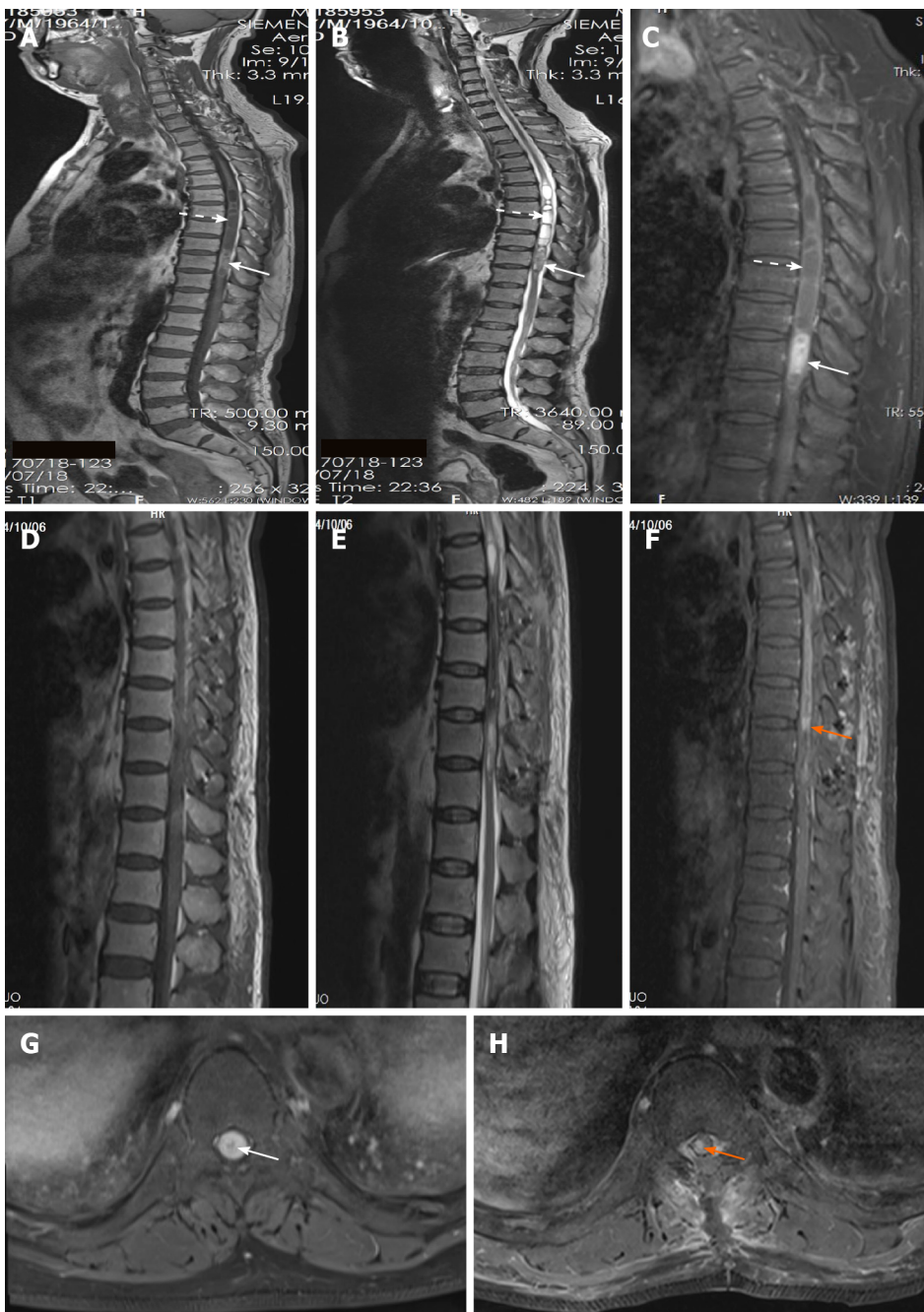


Figure 1 Preoperative and postoperative magnetic resonance imaging. A: Sagittal T1-weighted image (TIWI); B: Sagittal T2-weighted image (T2WI); C: Sagittal TIWI with gadolinium enhancement; D: Sagittal TIWI; E: Sagittal T2WI; F: Sagittal TIWI with gadolinium enhancement at the T10 level; H: Axial TIWI with gadolinium enhancement at the T10 level. A-C and G: Intramedullary melanocytoma (white solid arrows) and syringomyelia (white dashed arrows) were located at the T9-T10 level and T5-T8 level, respectively; D-F and H: An approximate gross total resection of the intramedullary melanocytoma was achieved in spite of tiny residual (orange arrow).

TREATMENT

The patient underwent surgical operation with approximately gross total resection on July 19, 2017. The resection extent reached to 98%. During the operation, clear cerebrospinal fluid was visible in the intramedullary cavity with golden yellow substance adhering to the wall of chamber at the T5-T8 level. At T9-T10, some stale blood clots were observed. After removing these blood clots, the mass was found in the right of T9-T10 without capsule. The mass was well-circumscribed, but it possessed abundant vascularity. Furthermore, a tiny part adhered to the normal spinal cord closely, so we only performed the maximal safe resection with minimal residual (1.5 cm × 0.4 cm × 0.3 cm) to ensure patient's life quality. The duration of surgery lasted for 5 h and the blood loss was 300 mL. The patient did not receive blood transfusion.

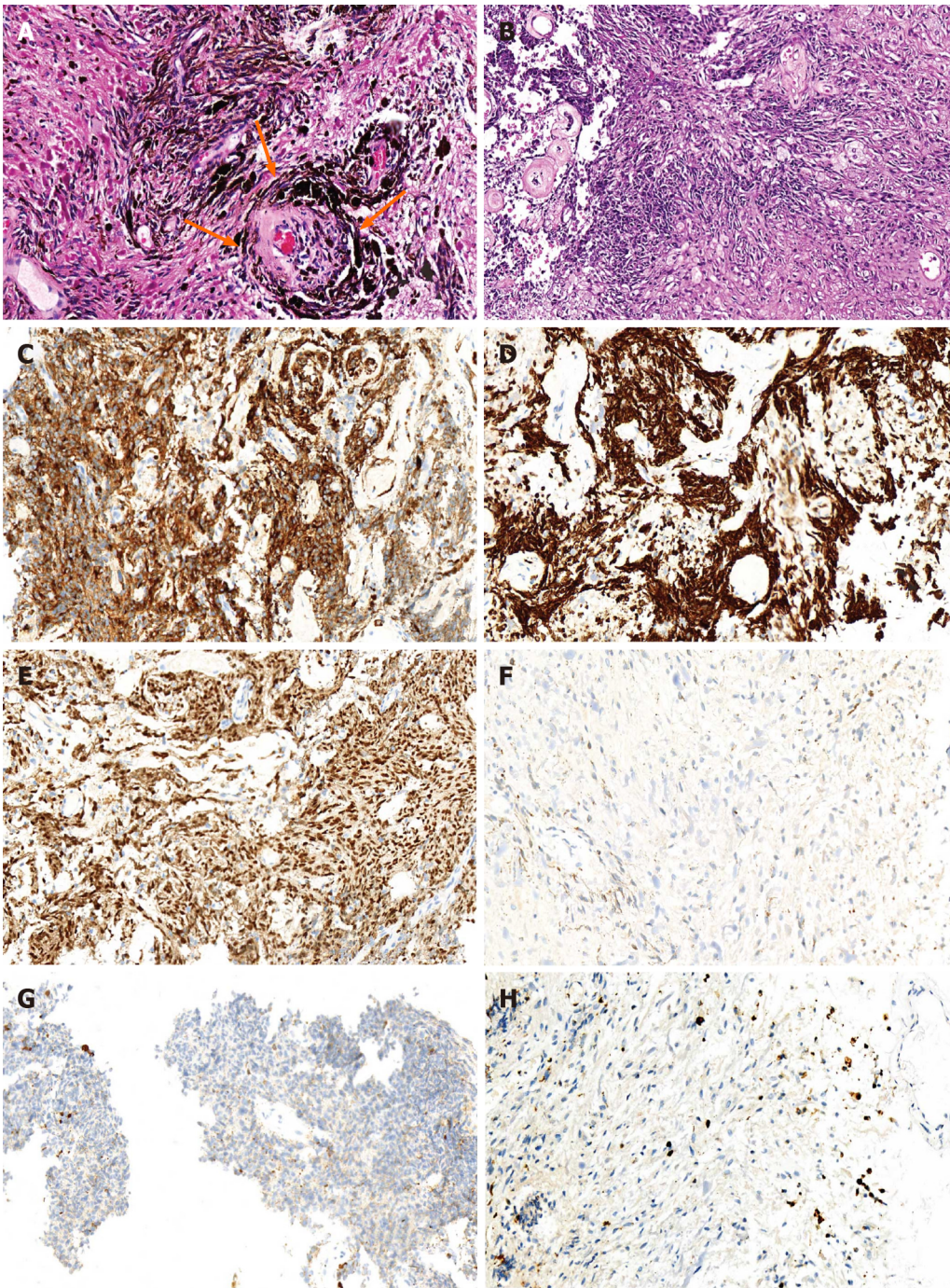


Figure 2 Postoperative pathology images showing the typical features of melanocytoma. A: Hematoxylin and eosin (HE) staining (400 ×) revealed spindle and epithelioid cells containing melanin pigment in the cytoplasm assembled to form sheets, bundles, nests, or whorls surrounded by reticulin fibres (yellow arrow); B: HE staining (400 ×) after removing melanin pigment in the cytoplasm; C-H: Immunohistochemical staining (400 ×) demonstrated human melanoma black 45 (C), antimelanoma antibody (D), and sex determinant region Y box 10 protein (E) were positive. Besides, epithelial membrane antigen (F) and glial fibrillary acidic protein (G) were negative, and the proliferative index was only 3% (H).

OUTCOME AND FOLLOW-UP

The hospital stay was 15 d and there was no hospital stay related issues. Postoperative MRI revealed that a small piece of tumor remained with heterogeneous enhancement before discharge (Figure 1D-F and H). The patient refused to accept radiotherapy or Gamma Knife radiosurgery. Follow-up examination on July 28, 2020 showed no sign of further growth of the lesion with heterogeneous enhancement, compared to the previous MRI scans (Figure 3D-G). On April 10, 2021, the patient received regular review at a local hospital without performing MRI scan. As for clinical symptoms, the weakness involving the bilateral lower limbs got significant improvement from rehabilitation, as the myodynamia of the right lower limb was grade 4 and left lower

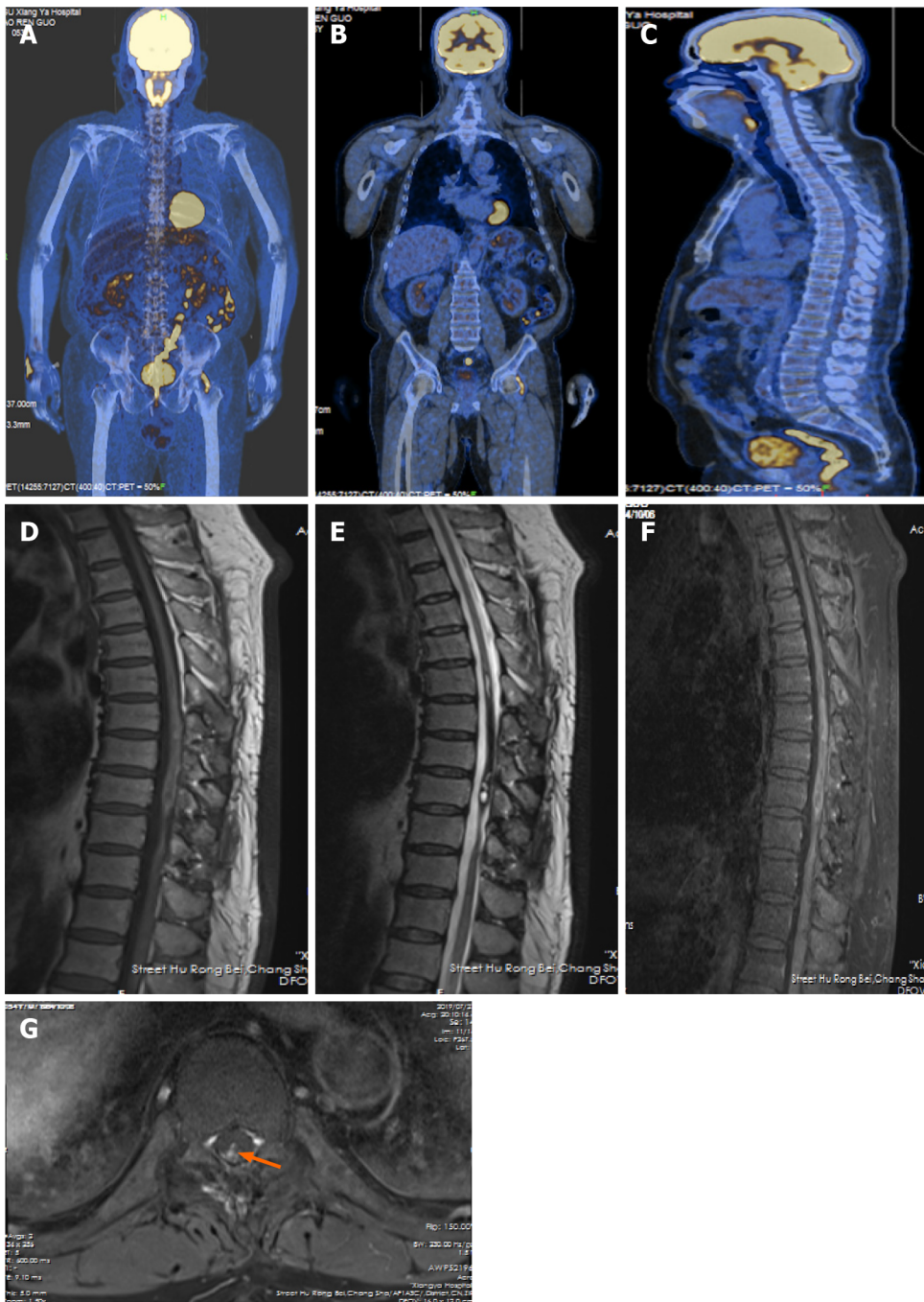


Figure 3 Postoperative positron emission tomography-computed tomography images and the latest review of magnetic resonance imaging. A and B: Coronal positron emission tomography-computed tomography (PET-CT) images; C: Sagittal PET-CT image; D: Sagittal T1-weighted image (TIWI); E: Sagittal T2-weighted image; F: Sagittal TIWI with gadolinium enhancement; G: Axial TIWI with gadolinium enhancement at the T10 level. A-C: There were no abnormal regions with significant hypermetabolism in the whole body; D-G: The tiny residual (orange arrow) maintained stable. The heterogeneous enhancement of residual did not grow up, but the local edema of the spinal cord mitigated apparently.

limb was grade 5. Furthermore, the disorder of defecation obtained relatively significant improvement but erectile dysfunction only acquired mild benefit from the resection. According to the latest review, the progression free survival had approached to 45 mo.

DISCUSSION

The designation “meningeal melanocytoma” in the primary melanocytic tumors of the CNS was confirmed for the first time in 1972, which frequently tended to occur in the ventro of medulla or the upper segments of the spinal cord, but the term “melano-

cytoma" defining the subtype of neoplasms was adopted by the WHO classification[1, 4]. The age of onset ranged from 5 years to 79 years with a peak around the fifth decade[5]. The ratio of male to female was 2.2:1, and the tumors are mainly located at the level of cervical vertebra[6]. Benign histology and favorable clinical course are the key factors to differentiate melanocytomas from malignant melanomas. Hence, the clinical symptoms of melanocytoma are usually caused by expanding extrusion instead of infiltrative growth, which was also verified in the present case during operation, and there are various neurologic deficits depending on the locations of tumors[4]. However, some literature reported potential aggressive behaviour of melanocytomas such as metastasis, recurrence, and malignant transformation[3,7]. Therefore, it is crucial to parse primary melanocytomas from metastasis melanocytomas. However, there has been no standard strategy of diagnosis and treatment for primary melanocytomas in the CNS so far due to the insufficient data available. Nonetheless, the criteria proposed by Hayward might be helpful to diagnose primary CNS melanocytic tumors: (1) No malignant melanoma tumor outside the CNS; (2) Involvement of the leptomeninges (spinal or cranial); (3) Intramedullary spinal lesions; (4) Hydrocephalus; (5) Tumor in the pituitary or pineal gland; and (6) a single intracerebral lesion[8].

Preoperative diagnosis of melanocytomas in the CNS on radiologic examinations is also a dilemma, as the imaging features are nonspecific depending on the degree of melanization, intra-tumoral hemorrhage, and duration of bleeding. Besides, paramagnetic free radicals in melanin were considered to be responsible for shortening the relaxation times of T1 and T2 by the proton-electron dipole-dipole proton relaxation enhancement mechanism[9]. The MRI appearance mainly was hyper-intensity on T1WI and hypo-intensity on T2WI with homogenous enhancement after gadolinium enhancement[10]. As for this case, the presence of inhomogeneous enhancement may be caused by intratumoral hemorrhage.

Pathological examination is an accurate and indispensable way to confirm the explicit diagnosis of melanocytomas in the CNS. The characteristics of primary melanocytic tumors are spindle or epithelioid cells arranged in the formation of sheets, bundles, nests, or whorls surrounded by reticulin fibres, which contain various degrees of melanin pigment in the cytoplasm. The appearance of melanocytomas includes low mitotic activity and absence of necrosis, nuclear atypia, and microvascular invasion. By contrast, the presence of primary malignant melanocytic tumors such as melanomas generally reveals a high proliferation index (Ki 67 > 5%) [11,12]. The mean rate of soluble protein-100 (S-100), HMB-45, and antimelanoma antibody to diagnose melanocytic tumors was 95%, 86%, and 84% respectively. In addition, HMB-45 was considered to be more specific but less sensitive than S-100[13]. SOX10 protein, a transcription factor, encoded by a gene located on chromosome 22q13.1, could regulate the differentiation of neural crest-derived melanocytes by affecting the expression of microphthalmia transcription factor[14]. Compared with S-100, SOX10 was recognized as having a higher sensitivity and/or specificity for melanocytic tumors, as S-100 protein was positively expressed in multiple types of tumors in spite of high sensitivity[14]. Therefore, SOX10 identification was adopted instead of S-100 in this case. The negative expression of GFAP and EMA is helpful to differentiate melanocytic tumors from gliomas and meningiomas[15,16]. In combination with previous studies, the diagnostic criteria for melanocytomas were proposed on the basis of positive manifestation of S-100 and/or SOX10 protein, Vimentin, HMB- 45, and antimelanoma antibody and negative presence of EMA, GFAP, and neuron specific enolase[11,12,14]. As for our case, the PET-CT and physical examination of whole body helped to exclude the malignant melanoma tumor outside the spinal cord, and the confirmation of pathological examination further validated the diagnosis of primary intramedullary melanocytoma.

Surgical resection plays a crucial role in the treatment of melanocytomas in the CNS. Complete tumor resection remarkably decreased the recurrence rates at 3 years and 5 years compared to incomplete tumor resection[17]. Owing to the extensive growth of melanocytomas, surgical resection could relieve pain symptoms immediately, but neurological deficits might need more time to recover. To date, the standard adjuvant therapy for melanocytomas has not yet proposed due to its rarity. Adjuvant radiation therapy and Gamma Knife radiosurgery for incomplete tumor resection should be taken into account, as these strategies were helpful to control tumor growth and improve the clinical outcome[18]. Even for the patients who underwent complete tumor resection, adjuvant radiation therapy could diminish the recurrence rates to 22% at 5 years[19,20]. Moreover, irradiation could be used to treat these tumors which are otherwise difficult to be resected[21,22]. Verma *et al*[23] treated a patient suffering from recurrent melanocytoma in the spinal cord after first surgical operation

Table 1 Reported cases of primary intramedullary melanocytomas

| Case No. | Ref. | Time | Age (yr) | Sex | Location | EOR | RT | Relapse | MT | Metastasis | Treatment | Follow-up | Comment |
|----------|-----------------------------|------|----------|-----|-------------|----------|-----|---------|-----|------------|-------------------------------|-----------|--|
| 1 | Verma <i>et al</i> [23] | 1979 | 71 | F | T2-T3 | Subtotal | Yes | Yes | NG | No | Re-resection and chemotherapy | 53 mo | PFS is 15 mo after the second therapy |
| 2 | Litofsky <i>et al</i> [26] | 1992 | 32 | M | Clivus - C5 | Total | No | No | - | - | - | 40 mo | |
| 3 | Ibáñez <i>et al</i> [22] | 1997 | 44 | F | T11 | Total | No | No | - | - | - | 54 mo | |
| 4 | Matsumoto <i>et al</i> [27] | 1998 | 48 | M | T8-T9 | Total | No | No | - | - | - | 12 mo | |
| 5 | Rades <i>et al</i> [17] | 2001 | 23 | F | T4-T7 | Subtotal | No | Yes | Yes | Yes | Re-resection and RT | 54 mo | Died from brain metastases |
| 6 | Das <i>et al</i> [28] | 2001 | 50 | M | T10 | NG | Yes | Yes | NG | Yes | - | 30 mo | Died from aspiration pneumonia |
| 7 | Iida <i>et al</i> [29] | 2002 | 42 | M | T8-T10 | NG | No | No | - | - | - | 4 mo | Died from a urinary tract infection |
| 8 | Iida <i>et al</i> [29] | 2002 | 52 | M | C2 | Subtotal | No | No | - | - | - | 24 mo | |
| 9 | Turhan <i>et al</i> [7] | 2004 | 64 | M | T12-L2 | Total | No | No | - | - | - | 24 mo | |
| 10 | Turhan <i>et al</i> [7] | 2004 | 19 | F | T8 | Total | No | No | - | - | - | 36 mo | |
| 11 | Wang <i>et al</i> [30] | 2007 | 57 | M | L5-S1 | Total | No | Yes | NG | No | Re-resection and RT | 17 mo | 5 mo after the second surgery, metastases were found in the liver and the left ninth rib |
| 12 | Chacko <i>et al</i> [31] | 2008 | 22 | M | T6-T11 | Total | No | No | - | - | - | 96 mo | |
| 13 | Karikari <i>et al</i> [10] | 2009 | 32 | F | T10 | Total | No | No | - | - | - | 3 mo | |
| 14 | Karikari <i>et al</i> [10] | 2009 | 20 | M | T12 | Total | No | No | - | - | - | 6 W | |
| 15 | Caruso <i>et al</i> [32] | 2009 | 62 | M | T11 | Total | No | No | - | - | - | 24 mo | |
| 16 | Perrini <i>et al</i> [3] | 2010 | 79 | F | T10-T11 | Subtotal | No | Yes | Yes | No | Re-resection | 30 mo | |
| 17 | Eskandari <i>et al</i> [33] | 2010 | 45 | M | T11 | Total | No | Yes | NG | No | RT | 36 mo | |
| 18 | Wagner <i>et al</i> [34] | 2015 | 63 | M | C2-C3 | Total | No | Yes | NG | No | RT | 18 mo | Neurological stabilization for 15 mo after radiotherapy |
| 19 | Wang <i>et al</i> [35] | 2016 | 60 | M | T1; T3-T4 | Total | No | No | - | - | - | 19 mo | |
| 20 | Reutov <i>et al</i> [36] | 2016 | 28 | F | C1-C2 | Total | No | No | - | - | - | 24 mo | |
| 21 | Lee <i>et al</i> [12] | 2017 | 45 | M | C1 | Total | No | No | - | - | - | 6 mo | |
| 22 | Gupta <i>et al</i> [37] | 2017 | 20 | M | C1-C2 | Total | Yes | No | - | - | - | 12 mo | |

F: Female; M: Male; EOR: Extent of resection; RT: Radiotherapy; MT: Malignant transformation; NG: Not given; PFS: Progression free survival.

(approximate 95%) and then radiation therapy followed by a second partial excision (approximate 90%) and adjuvant therapy with corynebacterium parvum, dactinomycin, dacarbazine, and the progression free survival was 15 mo. Koch *et al*[24] treated a patient with recurrent melanocytoma in the cerebello-pontine angle with intracerebral and spinal meningeal seeding after first resection by radiotherapy in combination with chemotherapy (oral temozolomide), but the patient died after 5 mo. The two cases indicated that the recurrent tumor might not respond to a combined radiotherapy and chemotherapy. The same result was also reported by Roser *et al*[25]. In fact, the role of radiochemotherapy in the treatment of melanocytomas needs further research. In terms of the present case, after approximately complete resection, the clinical symptoms induced by extensive growth of tumor was ameliorated remarkably and no relapse or aggression was discovered in spite of not getting radiochemotherapy. In addition, to now, the patient has been receiving regular review every 6 to 12 mo in order to avoid neglecting potential malignant transformation and metastasis. Some previous studies about primary melanocytomas in the spinal cord are summarized in Table 1.

In summary, the 5-year survival rate of primary melanocytomas in the spinal cord is more than 90% after surgical operation, but it is vital for doctors and patients to pay more attention to the potential malignance of primary melanocytomas such as local recurrence, adjacent structure invasion, cerebrospinal fluid spread, and distant metastases[6].

CONCLUSION

We report a case of primary intramedullary melanocytoma at the T9-T10 level presenting with lower limbs, defecation, and erectile dysfunction. In addition, the postoperative progression free survival had reached to 45 mo till the latest follow-up. The main therapy strategy includes gross total resection and adjuvant radiation. This case proves evidence that maximal safe resection can provide benefits to prognosis and improve the quality of life, when complete resection is difficult to achieve. Considering the potential malignancy, postoperative examination of whole body regions, after the pathological diagnosis of intramedullary melanocytoma, can help exclude the probability of metastasis from other regions. Therefore, it is reasonable to confirm the diagnosis of primary intramedullary melanocytoma. Based on this case, we would recommend patients to receive adjuvant radiation, which can prolong their progression free survival. Notably, regular follow-up is crucial, as physical examination and MRI scan can help find early progression or relapse.

REFERENCES

- 1 **Louis DN**, Ohgaki H, Wiestler OD, Cavenee WK, Burger PC, Jouvet A, Scheithauer BW, Kleihues P. The 2007 WHO classification of tumours of the central nervous system. *Acta Neuropathol* 2007; **114**: 97-109 [PMID: [17618441](#) DOI: [10.1007/s00401-007-0243-4](#)]
- 2 **Liubinas SV**, Maartens N, Drummond KJ. Primary melanocytic neoplasms of the central nervous system. *J Clin Neurosci* 2010; **17**: 1227-1232 [PMID: [20558070](#) DOI: [10.1016/j.jocn.2010.01.017](#)]
- 3 **Perrini P**, Caniglia M, Pironi M, Castagna M, Parenti GF. Malignant transformation of intramedullary melanocytoma: case report. *Neurosurgery* 2010; **67**: E867-9; discussion E869 [PMID: [20657325](#) DOI: [10.1227/01.NEU.0000372919.96651.34](#)]
- 4 **Limas C**, Tio FO. Meningeal melanocytoma ("melanotic meningioma"). Its melanocytic origin as revealed by electron microscopy. *Cancer* 1972; **30**: 1286-1294 [PMID: [4343293](#) DOI: [10.1002/1097-0142\(197211\)30:5<1286::aid-cnrcr2820300522>3.0.co;2-v](#)]
- 5 **Salah El-Din AM**, Aboul-Ela HM, Alsawy MF, Koheil A, Ashry AH. Spinal meningeal melanocytoma in a 5-year-old child: a case report and review of literature. *Egypt J Neurol Psychiatr Neurosurg* 2018; **54**: 13 [PMID: [29780233](#) DOI: [10.1186/s41983-018-0017-z](#)]
- 6 **Yang C**, Fang J, Li G, Jia W, Liu H, Qi W, Xu Y. Spinal meningeal melanocytomas: clinical manifestations, radiological and pathological characteristics, and surgical outcomes. *J Neurooncol* 2016; **127**: 279-286 [PMID: [26940907](#) DOI: [10.1007/s11060-015-2006-8](#)]
- 7 **Turhan T**, Oner K, Yurtseven T, Akalin T, Ovul I. Spinal meningeal melanocytoma. Report of two cases and review of the literature. *J Neurosurg* 2004; **100**: 287-290 [PMID: [15029918](#) DOI: [10.3171/spi.2004.100.3.0287](#)]
- 8 **Hayward RD**. Malignant melanoma and the central nervous system. A guide for classification based on the clinical findings. *J Neurol Neurosurg Psychiatry* 1976; **39**: 526-530 [PMID: [950562](#) DOI: [10.1136/jnnp.39.6.526](#)]
- 9 **Czarnecki EJ**, Silbergleit R, Gutierrez JA. MR of spinal meningeal melanocytoma. *AJNR Am J Neuroradiol* 1997; **18**: 180-182 [PMID: [9010539](#)]
- 10 **Karikari IO**, Powers CJ, Bagley CA, Cummings TJ, Radhakrishnan S, Friedman AH. Primary intramedullary melanocytoma of the spinal cord: case report. *Neurosurgery* 2009; **64**: E777-8; discussion E778 [PMID: [19349809](#) DOI: [10.1227/01.NEU.0000341516.22126.AA](#)]
- 11 **Reddy R**, Krishna V, Sahu BP, Uppin M, Sundaram C. Multifocal spinal meningeal melanocytoma: an illustrated case review. *Turk Neurosurg* 2012; **22**: 791-794 [PMID: [23208918](#) DOI: [10.5137/1019-5149.JTN.4322-11.1](#)]
- 12 **Lee JK**, Rho YJ, Jeong DM, Rhim SC, Kim SJ. Diagnostic Clue of Meningeal Melanocytoma: Case Report and Review of Literature. *Yonsei Med J* 2017; **58**: 467-470 [PMID: [28120582](#) DOI: [10.3349/ymj.2017.58.2.467](#)]
- 13 **Yu CH**, Chen HH, Liu CM, Jeng YM, Wang JT, Wang YP, Liu BY, Sun A, Chiang CP. HMB-45 may be a more sensitive maker than S-100 or Melan-A for immunohistochemical diagnosis of primary oral and nasal mucosal melanomas. *J Oral Pathol Med* 2005; **34**: 540-545 [PMID: [16138892](#) DOI: [10.1111/j.1600-0714.2005.00340.x](#)]
- 14 **Ordóñez NG**. Value of SOX10 immunostaining in tumor diagnosis. *Adv Anat Pathol* 2013; **20**: 275-283 [PMID: [23752089](#) DOI: [10.1097/PAP.0b013e318297a9d0](#)]
- 15 **Tichy J**, Spechtmeyer S, Mittelbronn M, Hattingen E, Rieger J, Senft C, Foerch C. Prospective evaluation of serum glial fibrillary acidic protein (GFAP) as a diagnostic marker for glioblastoma. *J Neurooncol* 2016; **126**: 361-369 [PMID: [26518540](#) DOI: [10.1007/s11060-015-1978-8](#)]
- 16 **Menke JR**, Raleigh DR, Gown AM, Thomas S, Perry A, Tihan T. Somatostatin receptor 2a is a more sensitive diagnostic marker of meningioma than epithelial membrane antigen. *Acta Neuropathol* 2015; **130**: 441-443 [PMID: [26195322](#) DOI: [10.1007/s00401-015-1459-3](#)]
- 17 **Rades D**, Heidenreich F, Tatagiba M, Brandis A, Karstens JH. Therapeutic options for meningeal melanocytoma. Case report. *J Neurosurg* 2001; **95**: 225-231 [PMID: [11599841](#) DOI: [10.3171/spi.2001.95.2.0225](#)]
- 18 **Ali Y**, Rahme R, Moussa R, Abadjian G, Menassa-Moussa L, Samaha E. Multifocal meningeal melanocytoma: a new pathological entity or the result of leptomeningeal seeding? *J Neurosurg* 2009; **111**: 488-491 [PMID: [19361258](#) DOI: [10.3171/2009.3.JNS081096](#)]
- 19 **Rades D**, Schild SE. Dose-response relationship for fractionated irradiation in the treatment of spinal meningeal melanocytomas: a review of the literature. *J Neurooncol* 2006; **77**: 311-314 [PMID: [16328723](#) DOI: [10.1007/s11060-005-9048-2](#)]
- 20 **Rades D**, Schild SE, Tatagiba M, Molina HA, Alberti W. Therapy of meningeal melanocytomas. *Cancer* 2004; **100**: 2442-2447 [PMID: [15160350](#) DOI: [10.1002/cncr.20296](#)]
- 21 **Chow M**, Clarke DB, Maloney WJ, Sangalang V. Meningeal melanocytoma of the planum sphenoidale. Case report and review of the literature. *J Neurosurg* 2001; **94**: 841-845 [PMID: [11354421](#) DOI: [10.3171/jns.2001.94.5.0841](#)]
- 22 **Ibáñez J**, Weil B, Ayala A, Jimenez A, Acedo C, Rodrigo I. Meningeal melanocytoma: case report and review of the literature. *Histopathology* 1997; **30**: 576-581 [PMID: [9205863](#) DOI: [10.1046/j.1365-2559.1997.5660798.x](#)]
- 23 **Verma DS**, Spitzer G, Legha S, McCredie KB. Chemoimmunotherapy for meningeal melanocytoma of the thoracic spinal cord. Report of a case. *JAMA* 1979; **242**: 2435-2436 [PMID: [490860](#) DOI: [10.1001/jama.242.22.2435](#)]
- 24 **Koch HJ**, Roeber S, Zimmermann UW, Schäfer C, Villarrubia V, Kuchelmeister K, Schachenmayr

- W, Bogdahn U, Steinbrecher A. [Spinal and cerebral leptomeningeal seeding from a melanocytoma of the cerebello-pontine angle]. *Wien Med Wochenschr* 2005; **155**: 360-364 [PMID: 16160923 DOI: 10.1007/s10354-005-0199-8]
- 25 **Roser F**, Nakamura M, Brandis A, Hans V, Vorkapic P, Samii M. Transition from meningeal melanocytoma to primary cerebral melanoma. Case report. *J Neurosurg* 2004; **101**: 528-531 [PMID: 15352613 DOI: 10.3171/jns.2004.101.3.0528]
- 26 **Litofsky NS**, Zee CS, Breeze RE, Chandrasoma PT. Meningeal melanocytoma: diagnostic criteria for a rare lesion. *Neurosurgery* 1992; **31**: 945-948 [PMID: 1436422 DOI: 10.1227/00006123-199211000-00019]
- 27 **Matsumoto S**, Kang Y, Sato S, Kawakami Y, Oda Y, Araki M, Kawamura J, Uchida H. Spinal meningeal melanocytoma presenting with superficial siderosis of the central nervous system. Case report and review of the literature. *J Neurosurg* 1998; **88**: 890-894 [PMID: 9576259 DOI: 10.3171/jns.1998.88.5.0890]
- 28 **Das A**, Ratnagopal P, Puvanendran K, Teo JG. Spinal meningeal melanocytoma with hydrocephalus and intracranial superficial siderosis. *Intern Med J* 2001; **31**: 562-564 [PMID: 11767875 DOI: 10.1046/j.1445-5994.2001.00119.x]
- 29 **Iida M**, Llana JF, Suarez MA, Malik S, Weidenheim KM, LaSala P, Hirano A. Two cases of spinal meningeal melanocytoma. *Brain Tumor Pathol* 2002; **19**: 41-45 [PMID: 12455888 DOI: 10.1007/BF02482455]
- 30 **Wang F**, Li X, Chen L, Pu X. Malignant transformation of spinal meningeal melanocytoma. Case report and review of the literature. *J Neurosurg Spine* 2007; **6**: 451-454 [PMID: 17542513 DOI: 10.3171/spi.2007.6.5.451]
- 31 **Chacko G**, Rajshekhar V. Thoracic intramedullary melanocytoma with long-term follow-up. *J Neurosurg Spine* 2008; **9**: 589-592 [PMID: 19035754 DOI: 10.3171/SPI.2008.9.08323]
- 32 **Caruso R**, Marrocco L, Wierzbicki V, Salvati M. Intramedullary melanocytoma: case report and review of literature. *Tumori* 2009; **95**: 389-393 [PMID: 19688984 DOI: 10.1177/030089160909500322]
- 33 **Eskandari R**, Schmidt MH. Intramedullary spinal melanocytoma. *Rare Tumors* 2010; **2**: e24 [PMID: 21139826 DOI: 10.4081/rt.2010.e24]
- 34 **Wagner F**, Berezowska S, Wiest R, Gralla J, Beck J, Verma RK, Huber A. Primary intramedullary melanocytoma in the cervical spinal cord: Case report and literature review. *Radiol Case Rep* 2015; **10**: 1010 [PMID: 27408655 DOI: 10.2484/rcr.v10i1.1010]
- 35 **Wang YB**, Wang WJ, Zhao HT, Li W, Peng T, Zhang XF. Multiple melanocytoma of the thoracic spine: a case report and literature review. *Spine J* 2016; **16**: e59-e63 [PMID: 26409209 DOI: 10.1016/j.spinee.2015.09.036]
- 36 **Reutov AA**, Ryzhova MV, Kushel' YV. [Intramedullary melanocytoma: a clinical case report and literature review]. *Zh Vopr Neurokhir Im N N Burdenko* 2016; **80**: 75-80 [PMID: 27500776 DOI: 10.17116/neiro201680475-80]
- 37 **Gupta PK**, Misra S, Verma R, Soni N, Lamin JC, Mishra RK, Behari S, Kumar S. Primary intradural cervical spine melanocytoma: A rare tumor and review of literature. *Neurol India* 2017; **65**: 653-657 [PMID: 28488646 DOI: 10.4103/neuroindia.NI_171_16]



Published by **Baishideng Publishing Group Inc**
7041 Koll Center Parkway, Suite 160, Pleasanton, CA 94566, USA

Telephone: +1-925-3991568

E-mail: bpgoffice@wjgnet.com

Help Desk: <https://www.f6publishing.com/helpdesk>

<https://www.wjgnet.com>

