

Human actinomycetoma caused by *Actinomadura mexicana* in Sudan: the first report

Emmanuel Edwar Siddig^{a,b}, Bertrand Nyuykonge^b, Mohammed Tayfour Ahmed^a, Rowa Hassan^{a,c}, Eiman Siddig Ahmed Saad^a, Najwa Adam Mhmoud^a, Sahar Mubarak Bakhiet^{a,d}, Wendy W. J. van de Sande^b, and Ahmed Hassan Fahal^{a,*}

^aMycetoma Research Centre, University of Khartoum, P.O. Box 102, Khartoum, Sudan; ^bDepartment of Medical Microbiology and Infectious Diseases, Erasmus University Medical Centre, Rotterdam, The Netherlands; ^cBrighton and Sussex Centre for Global Health Research, Brighton and Sussex Medical School, Brighton, UK; ^dInstitute of Endemic Diseases, University of Khartoum, Khartoum, Sudan

*Corresponding author: Tel.: 00249912346703; E-mail: ahfahal@hotmail.com, ahfahal@uofk.edu

Received 18 September 2020; revised 9 October 2020; editorial decision 12 October 2020; accepted 8 November 2020

Mycetoma is a localized, chronic, granulomatous disease that can be caused by fungi (eumycetoma) or bacteria (actinomycetoma). Of the 70 different causative agents implicated in mycetoma worldwide, *Actinomadura madurae* is the only one that causes multiple cases on all continents. Recently, new *Actinomadura* species were described as causative agents of human mycetoma. One of these new causative agents was *Actinomadura mexicana*, which was identified in Latin America. Here we demonstrate that this causative agent is not confined to Latin America and that it is also a causative agent of actinomycetoma in Sudan. The disease was managed by antibiotic treatment alone and resulted in complete cure after 6 months of treatment, which is quick when compared with actinomycetoma cases caused by other *Actinomadura* species.

Keywords: *Actinomadura mexicana*, actinomycetoma, Sudan

Introduction

Mycetoma is a chronic, granulomatous localized disease that is caused by either fungi or bacteria.^{1–4} The disease develops after the traumatic inoculation of the causative agent into the subcutaneous tissue.⁵ The feet are most commonly infected,⁶ however, other parts of the body are not exempt.⁷ The disease is characterized by painless, subcutaneous swellings and draining sinuses.⁸ The population at risk is mainly adult and 20–40 y of age.⁷ Treatment is dependent on the causative agent and consists of antifungal treatment combined with surgery for eumycetoma or antibacterial treatment for actinomycetoma. The duration of the medical treatment is long and takes at least 6 months and often up to 2 y. The duration of the treatment is dependent on the extent of the lesion, but is probably also linked to the aetiology of the causative agent. Therefore accurate species identification is important in the proper treatment and management of mycetoma patients. In this communication, we report for the first time in Sudan a case of actinomycetoma caused by *Actinomadura mexicana*; the patient was cured after short-term antibiotic treatment.

Case report

The patient is a 26-year-old male, a teacher from Al Gezira State, Central Sudan who presented to the Mycetoma Research Centre (MRC), University of Khartoum, Sudan in December 2018 with a foot swelling. His condition started 6 months prior to presentation, with a small swelling on the dorsal aspect of the left foot first web space. It was of gradual onset and progress. He denied any history of local trauma at the lesion site and he had no local pain. He has no family history of a similar condition. His past medical, social or geographic history was non-contributory to his present condition. He was not on long-term medication.

On clinical examination, the patient looked well, was not pale and neither jaundiced nor cyanosed. He had a normal pulse rate of 76/min, respiratory rate of 17/min, blood pressure of 110/75 mmHg and temperature of 37°C. A systematic clinical examination was normal. Local examination revealed a localised lesion, 3 cm in diameter, on the dorsal aspect of the left foot first toe web. The swelling was not tender, with normal temperature, firm in consistency, localised and attached to the skin and deep structures. The skin was normal and no local sweating or sinuses were noted. The regional lymph nodes were not enlarged.

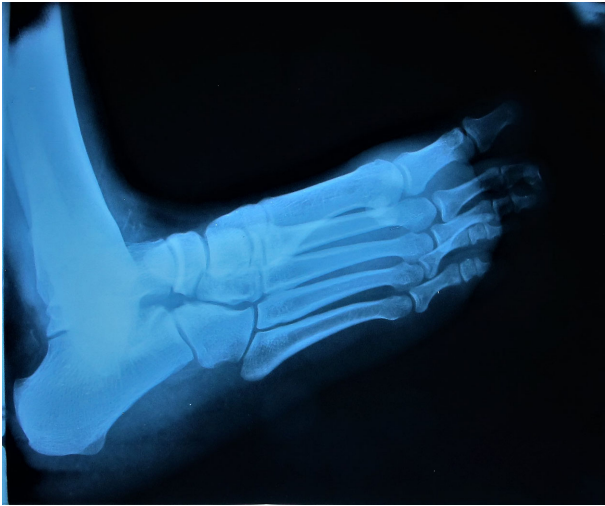

Figure 1. X-ray of the left foot in a lateral view showing no apparent abnormality.

His renal and hepatic function tests, as well as his full blood count, were within normal limits. X-rays of the left foot were reported as normal (Figure 1), but the ultrasound examination showed multiple cavities with thick walls that contained fluid, with sharp echogenic grains and intact bone, in line with the diagnosis of eumycetoma (Figure 2).

For confirmation and identification of the causative organism, a deep surgical excisional biopsy was performed. The grains present in the biopsy were white to yellow in colour and small in size. They resembled those of *Actinomyces madurae* and to

lesser extent *Streptomyces somaliensis*. The grains were smooth in consistency and easily crushed.

The biopsy was processed for histopathological examination and the sections were stained with haematoxylin and eosin (H&E). Microscopic examination showed multiple dark blue to purple-stained grains surrounded by granulation tissue (Figure 3A). The grains looked opaque at the periphery, with deep blue staining. The centres of the grains were less densely stained. The peripheries of the grains were eosinophilic. There were marked histiocytic and mixed inflammatory cellular infiltrates, in line with *A. madurae* (Figure 3B).

After separation from the surgical biopsy, the grains were washed three times in normal saline and then cultured in yeast extract media and Lowenstein media at 37°C. After 10 d, red to pink colonies were visible with a convex surface. The colonies were very tough in consistency and wrinkled in shape (Figure 4A). These colonies resembled those of *A. madurae* (Figure 4B) and were identified as such.

To confirm the identification of the causative agent, DNA from the isolate was extracted and the 16S ribosomal RNA region was amplified and sequenced using forward primer (5'-CTTTACGCCARTRAWTCCG-3') and reverse primer (5'-AGAGTTTGATCMTGGYTACG-3'). After analysing and blasting the sequence, it was found to be 100% identical to *A. mexicana* strain A290 16S sequence NR_025110.1. The obtained MRC/A-04 16S sequence was deposited in GenBank with the accession number MT302842.

On January 2019, the patient started on an antimicrobial combination of 2 g co-amoxiclav (875 mg amoxicillin and 125 mg clavulanic acid) and two tablets of 1840 mg co-trimoxazole daily. The patient was followed up regularly at the Mycetoma Clinic

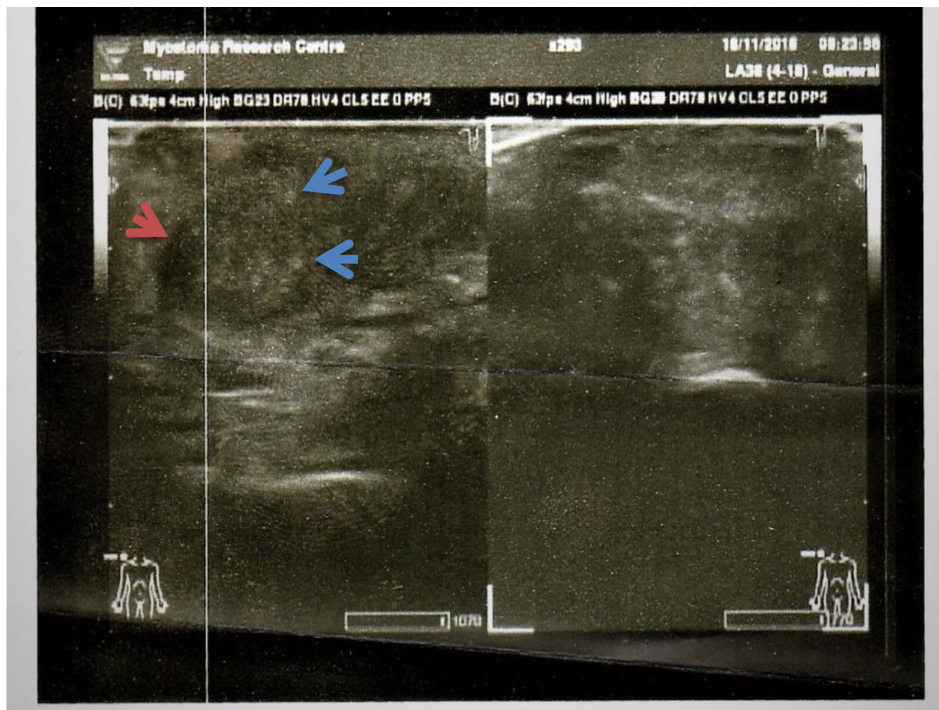


Figure 2. Photograph shows the lesion ultrasound examination with thick-walled multiple cavities (red arrow) that contain fluid, with sharp echogenic grains (blue arrows) and intact bone, in line with eumycetoma.

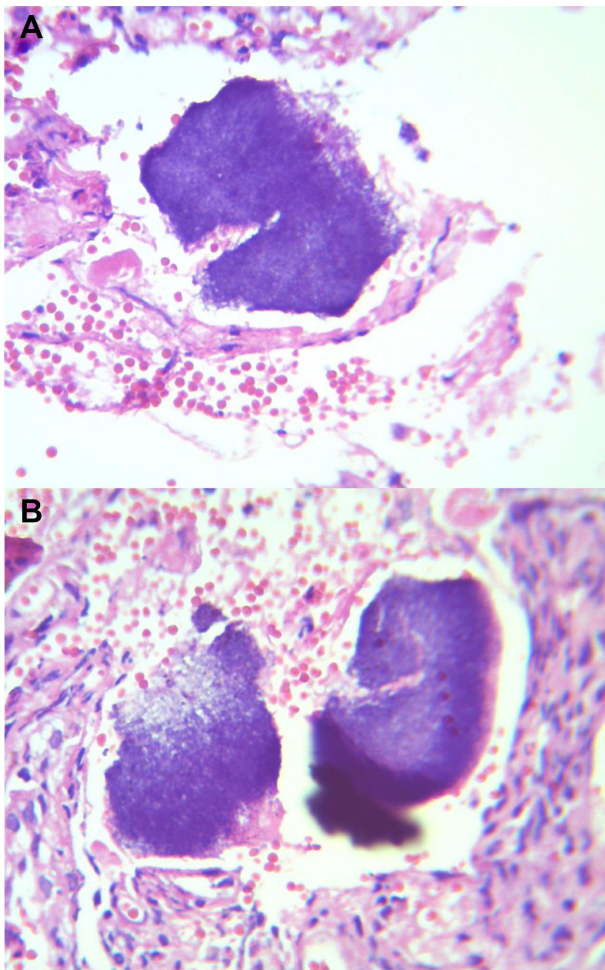


Figure 3. (A) Photomicrograph shows *A. mexicana* grains, which are opaque at the periphery with deep blue staining, the centre is less densely stained and the periphery is slightly eosinophilic (H&E, $\times 10$). (B) *A. madurae* grains. The periphery is dense, homogeneous and deep blue, while the centre is less dense or even appears hollow (H&E, $\times 10$).

of the MRC. After 1 month of treatment, the swelling was reduced in size and in 6 months the lesion had disappeared. The lesion ultrasound examination revealed no cavities or grains. The patient continued the treatment for another 3 months. Four lesion site ultrasound examinations conducted 3 months apart showed no evidence of recurrence.

Discussion

Mycetoma is reported globally but is endemic in tropical and subtropical regions in a belt known as the mycetoma belt.^{1,2} It includes the countries of Sudan, Somalia, Senegal, India, Yemen, Mexico, Venezuela, Columbia, Argentina and a few others.^{3,4} Sudan is known to have the highest reported mycetoma prevalence.^{5,6} The geographical distribution of mycetoma depends on environmental parameters that include temperature, humidity and rainfall.^{7,8} More than 70 causative agents are responsible for mycetoma and the distribution of these causative agents is

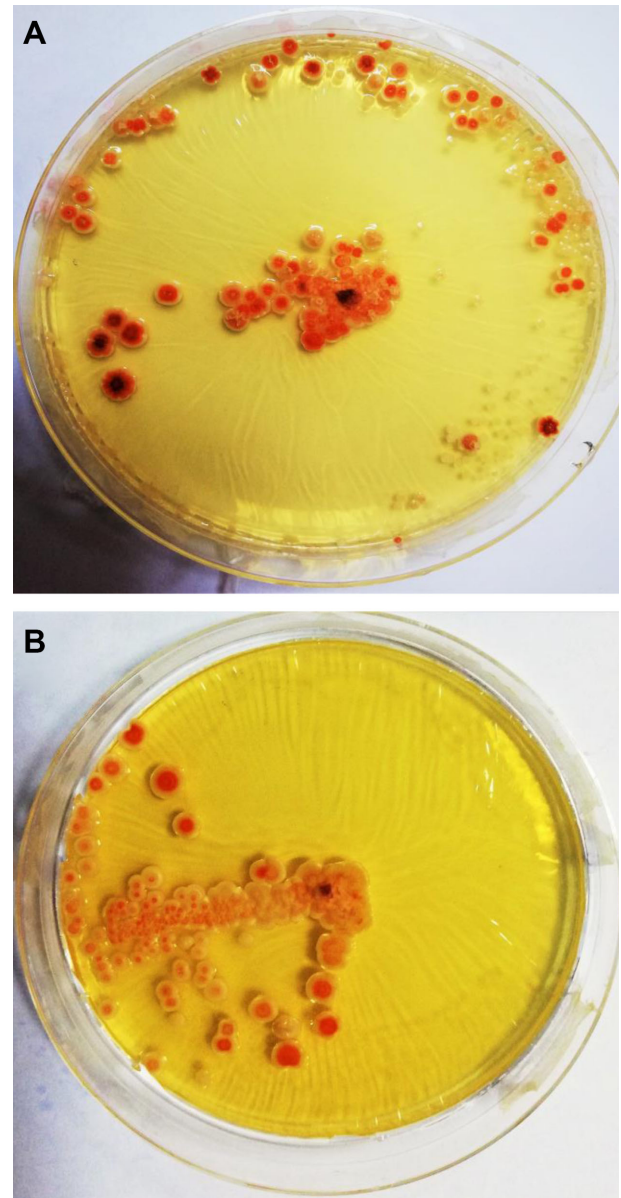


Figure 4. (A) Photograph shows *A. mexicana* colonies with a convex surface and wrinkled in shape in yeast extract agar (YEA). (B) Photomicrograph shows *A. madurae* colonies after a 10-d incubation, showing a pink to pallid red, convex, wrinkled morphology in YEA.

not uniform globally.⁹ *Madurella mycetomatis*, the most common causative agent of eumycetoma, is reported extensively in Africa and India, but rarely in South America.¹⁰ *Nocardia brasiliensis* is the actinomycetoma causative agent most frequently reported in South America but is rarely seen in Africa.¹¹

It should be noted that *A. (A) madurae* is the only mycetoma causative agent reported in all the mycetoma-endemic regions.¹² *Actinomadura* commonly resides in the soil, and the members of this genus encompass 40 species.¹³ Apart from *A. madurae*, other *Actinomadura* species have been reported to cause mycetoma. These include *Actinomadura pelletieri*, *Actinomadura*

Table 1. Characteristics of *Actinomadura* species that cause human diseases

Species name	Grain colour	Disease	Reference
Non-mycetoma disease			
<i>Actinomadura sputi</i>	NA	Pulmonary infection	13
Mycetoma disease			
<i>Actinomadura madurae</i>	White or yellow	Actinomycetoma	12
<i>Actinomadura pelletieri</i>	Red	Actinomycetoma	12
<i>Actinomadura mexicana</i>	White or yellow	Actinomycetoma	18
<i>Actinomadura bangladeshensis</i>	NA	Actinomycetoma	15

bangladeshensis and *A. mexicana*¹⁴ (Table 1), which produce different red and white/yellow grains.

A. mexicana was initially described by Quintana et al.¹⁵ in 2003 following isolation of the organism from the soil in Mexico, hence the name. *A. mexicana* was not known to cause human mycetoma until 2020, when Bessis et al.¹⁶ reported it for the first time in a 38-year-old woman from the Caribbean region with actinomycetoma. However, mycetoma due to *A. mexicana* could be more prevalent than currently thought. Macroscopically, *A. mexicana* grains have white to yellow colour similar to the grains seen in *A. madurae* and *S. somaliensis*. In histopathological sections, *A. mexicana* grains are indistinguishable from those of *A. madurae*, as they both stain deep blue in H&E-stained sections.¹⁷ When cultured, *A. mexicana* and *A. madurae* morphology are also comparable. Therefore misidentifications may explain the rarity of this organism.

The reported patient is from Central Sudan, where eumycetoma due to *Madurella mycetomatis* is predominant and actinomycetoma is less commonly reported.^{3,4} More in-depth environmental study of the patient's village is needed to explain the occurrence of the reported causative organism. Mycetoma is characterised by a triad of painless subcutaneous swellings, grains and draining sinuses.¹⁸ However, the reported patient had no sinuses, which is more commonly seen with actinomycetoma, and the diagnosis was established by lesional ultrasound and histological examinations. The explanation for this presentation is unclear.

The reported patient was treated with an antibiotic combination similar to that reported by Bessis et al.,¹⁶ which was 2 g amoxicillin/clavulanate and 1600 mg/280 mg sulfamethoxazole/trimethoprim three times a day. Both patients showed a marked improvement after 3 months of therapy. In our patient, the swelling completely diminished, while in the case presented by Bessis et al.,¹⁶ a marked reduction in size and pain was noted. This indicates that the causative organism responds well to a combination of antibiotics.

Of the 1549 actinomycetoma patients seen at the MRC, 576 were due to *A. madurae*, 175 to *A. pelletieri* and 798 to *Streptomyces* species. The cure rate of patients with *A. madurae*, *A. pelletieri* and *Streptomyces* species was 80.6%, 88.9% and 90.5%, respectively. Interestingly, the average treatment duration for *A. pelletieri* was 16 months and for *A. madurae* it was 24 months. Both the *A. mexicana* patients were cured within 6–9 months. This could indicate that mycetoma caused

by *A. mexicana* is more responsive to treatment than the other *Actinomadura* species.

In conclusion, we report the first patient with actinomycetoma caused by *A. mexicana* in Sudan. The diagnosis was established by molecular identification of the organism. Hence, molecular identification should be part of the routine diagnostic tools. The patient responded well to medical treatment and in a shorter time and therefore had a better prognosis compared with other actinomycetoma-causative agents.

Authors' contributions: EES, BN, WVS and AHF conceived and designed the study. EES, BN, WVS, MTA, RH, ESA, NAM and AHF performed the study. EES, BN, WVS and AHF analysed the data. EES, BN, WVS, MTA, RH, ESA and AHF wrote the manuscript. EES, BN, WVS, MTA, RH, ESA, NAM and AHF revised the manuscript. All authors read and approved the final manuscript.

Acknowledgements: None.

Funding: None.

Competing interests: None declared.

Ethical approval: The study was approved by the Mycetoma Research Center Institutional Review Board (December 2018). Written, informed consent to publish the history, findings and images for educational purposes was obtained from the patient.

Data availability: Data available on request.

References

- Hay RJ, Fahal AH. Mycetoma: an old and still neglected tropical disease. *Trans R Soc Trop Med Hyg.* 2015;109(3):169–70.
- Fahal AH, Hassan MA Mycetoma. *Br J Surg.* 1992;79(11):1138–41.
- Bonifaz A, Tirado-Sánchez A, Calderón L, et al. Mycetoma: experience of 482 cases in a single center in Mexico. *PLoS Negl Trop Dis.* 2014;8(8):e3102.
- Fahal AH. Mycetoma: a thorn in the flesh. *Trans R Soc Trop Med Hyg.* 2004;98(1):3–11.

- 5 Zijlstra EE, van de Sande WWJ, Welsh O, et al. Mycetoma: a unique neglected tropical disease. *Lancet Infect Dis.* 2016;16(1):100–12.
- 6 van de Sande WWJ. Global burden of human mycetoma: a systematic review and meta-analysis. *PLoS Negl Trop Dis.* 2013;7(11):e2550.
- 7 Nenoff P, van de Sande WW, Fahal AH, et al. Eumycetoma and actinomycetoma – an update on causative agents, epidemiology, pathogenesis, diagnostics and therapy. *J Eur Acad Dermatol Venereol.* 2015;29(10):1873–83.
- 8 Relhan V, Mahajan K, Agarwal P, et al. Mycetoma: an update. *Indian J Dermatol.* 2017;62(4):332–40.
- 9 Ahmed AA, van de Sande WW, Fahal A, et al. Management of mycetoma: major challenge in tropical mycoses with limited international recognition. *Curr Opin Infect Dis.* 2007;20(2):146–51.
- 10 Ahmed AO, van Leeuwen W, Fahal A, et al. Mycetoma caused by *Madurella mycetomatis*: a neglected infectious burden. *Lancet Infect Dis.* 2004;4(9):566–74.
- 11 Sampaio FMS, Wanke B, Freitas DFS, et al. Review of 21 cases of mycetoma from 1991 to 2014 in Rio de Janeiro, Brazil. *PLoS Negl Trop Dis.* 2017;11(2):e0005301.
- 12 Trujillo ME, Goodfellow M. Numerical phenetic classification of clinically significant aerobic sporoactinomycetes and related organisms. *Antonie van Leeuwenhoek.* 2003;84(1):39–68.
- 13 Yassin AF, Spröer C, Siering C, et al. *Actinomadura sputi* sp. nov., isolated from the sputum of a patient with pulmonary infection. *Int J Syst Evol Microbiol.* 2010;60(Pt 1):149–53.
- 14 Bérot V, Ousser AF, Sougakoff W, et al. A patient from Mali with *Actinomadura bangladeshensis*-induced foot mycetoma: a diagnostic challenge. *Travel Med Infect Dis.* 2019;31:101452.
- 15 Quintana ET, Trujillo ME, Goodfellow M. *Actinomadura mexicana* sp. nov. and *Actinomadura meyerii* sp. nov., two novel soil sporoactinomycetes. *Syst Appl Microbiol.* 2003;26(4):511–7.
- 16 Bessis S, Noussair L, Rodriguez-Nava V, et al. Actinomycetoma caused by *Actinomadura mexicana*, a neglected entity in the Caribbean. *Emerg Infect Dis.* 2020;26(2):379–80.
- 17 Siddig EE, Mhmoud NA, Bakhiet SM, et al. The accuracy of histopathological and cytopathological techniques in the identification of the mycetoma causative agents. *PLoS Negl Trop Dis.* 2019;13(8):e0007056.
- 18 Fahal AH, Suliman SH, Hay R. Mycetoma: the spectrum of clinical presentation. *Trop Med Infect Dis.* 2018;3(3):97.