



Isocitrate Dehydrogenase Mutant Grade II and III Glial Neoplasms

Ingo K. Mellinghoff, MD^a, Susan M. Chang, MD^b,
Kurt A. Jaeckle, MD^c, Martin van den Bent, MD^{d,*}

KEYWORDS

- Isocitrate dehydrogenase (IDH) • Low-grade glioma (LGG) • Cancer metabolism
- Response assessment in neuro-oncology (RANO)

KEY POINTS

- 70-80% of diffuse lower grade gliomas are characterized by IDH mutations.
- IDH mutations are an early event in the gliomagenesis of both astrocytoma, IDHmt and of oligodendroglioma.
- IDH mutations result in a mutated enzyme that increases the intracellular levels of 2-hydroxyglutarate; this substance acts as an onco-metabolite that induces many cellular alterations.
- Novel therapeutic approaches aim at inhibiting the mutated enzyme and other abnormalities that occur due to the mutated enzyme, such as double strand DNA repair deficiencies.

MOLECULAR PATHOGENESIS OF ISOCITRATE DEHYDROGENASE MUTANT GLIOMA

Cancer-associated isocitrate dehydrogenase (IDH) mutations first emerged from a comprehensive analysis of mutations in protein-coding genes in colorectal cancer.¹ In 2008, whole-genome sequencing uncovered the presence of these mutations in glioma,² a surprising finding that was rapidly confirmed in a much larger number of tumors.^{3,4}

Funded by: VSNU2020.

^a Memorial Sloan Kettering Cancer Center, 1275 York Avenue, New York, NY 10065, USA;

^b Department of Neurological Surgery, University of California San Francisco, 505 Parnassus Room M 774SF, San Francisco, CA 94142-0112, USA; ^c Department of Neurology and Oncology, Mayo Clinic Florida, Mangurian 4415, 4500 San Pablo Road, Jacksonville, FL 32224, USA;

^d Department of Neuro-oncology, Brain Tumor Center at Erasmus MC Cancer Institute, Nt-542, Dr Molenwaterplein 40, Rotterdam 3015 GD, The Netherlands

* Corresponding author. Brain Tumor Center at Erasmus MC Cancer Institute, Rotterdam, the Netherlands.

E-mail address: m.vandenbent@erasmusmc.nl

Hematol Oncol Clin N Am 36 (2022) 95–111

<https://doi.org/10.1016/j.hoc.2021.08.008>

hemonc.theclinics.com

0889-8588/22/© 2021 The Author(s). Published by Elsevier Inc. This is an open access article under the CC BY license (<http://creativecommons.org/licenses/by/4.0/>).

The extraordinarily high prevalence of IDH mutations in adult low-grade and anaplastic glioma (see later) and the fact that these mutations clustered in key arginine residues within the enzyme's active site (R132 of IDH1 and R140 or R172 of IDH2) immediately pointed toward a prominent role of the mutant IDH enzyme in the pathogenesis of these tumors. Several additional observations supported this conclusion. First, IDH mutations occur at the earliest stages of low-grade glioma (LGG).⁵ Secondly, introduction of the IDH mutant (mIDH) enzyme into cells is sufficient to induce the distinct pattern of DNA hypermethylation associated with IDH mutations in human glioma.⁶ And unlike many other genetic alterations found in diffuse glioma, IDH mutations remain detectable throughout the disease course, suggesting a contribution of the mutant enzyme to tumor maintenance.^{7–9}

Metabolic studies revealed that cells expressing the mIDH enzyme produce the R(–) enantiomer of the metabolite R(–)-2-hydroxyglutarate (R-2-HG), which accumulates in IDH-mutant human gliomas.^{10–12} Accumulation of R-2-HG leads to competitive inhibition of α -ketoglutarate-dependent enzymes, a large protein family that includes the ten-eleven translocation (TET) family of 5-methyl cytosine hydroxylases, the jumonji domain-containing family of histone lysine demethylases, enzymes involved in nucleic acid metabolism, and many enzymes with still unknown functions.¹³

Several findings support the conclusion that the “onco-metabolite” 2-HG is the critical mediator of the oncogenic functions of mIDH. Cell-permeable esters of R-2-HG phenocopy, the effects of mIDH in experimental models, and ectopic expression of the dehydrogenase that counteracts the activity of the mIDH enzyme are sufficient to reverse the cellular effects of cancer-associated mIDH.^{14–16} Nonetheless, much remains to be learned about the role of mIDH in gliomagenesis. Of note, there are currently no preclinical models that recapitulate the genetics and growth pattern of IDH-mutant LGG. It seems plausible that several factors might relieve mIDH cancer cells from their dependency on the mutant enzyme for growth and survival.¹⁷

CLINICAL PRESENTATION OF ISOCITRATE DEHYDROGENASE MUTANT GLIOMA

IDH mutations are exceptionally common in adult low-grade and anaplastic glioma. IDH mutation has been reported in 50% to 81% of World Health Organization (WHO) grade II gliomas,^{18,19} 54% of grade III, and 15% to 20% of grade IV gliomas.^{18,20} In a series of patients with LGG, 52% were mIDH, 30% were mIDH 1p/19q codeleted (codel), and 18% were IDH wild type (IDHwt).¹⁹ In a large database of 2193 mIDH gliomas, 80% were LGG and 20% grade IV tumors.²⁰ In a correlative analysis of 106 patients with high-risk LGG treated on NRG/RTOG 9802, 41% were mIDH/non-codel; 35% were mIDH/codel, and 24% were IDHwt. Most 1p/19q codel gliomas also have IDH R132H mutations or noncanonical mutations (eg, R132C or IDH2).^{21,22} In a database study of 911 patients with mIDH high-grade glioma, 47% were 1p/19q non-codeleted and 53% were 1p/19q codeleted.²³

IDH mutated gliomas are more common in patients younger than 55 years. Grade IV mIDH tumors are more frequently encountered in older patients but also occur in young patients.^{18,24}

IDH mutated astrocytomas usually show robust immunohistochemical staining for p53 and loss of expression of alpha-thalassemia/mental retardation X-linked (ATRX) protein. In contrast, mIDH/codel tumors are more often p53wt and have *TERT* promoter mutations.^{25–27} In patients with mIDH tumors, the presence of *CDKN2A* homozygous deletion varies from 7% to 42% (median, 22%) and is an unfavorable prognostic marker for progression-free survival (PFS) and overall survival (OS), in

both LGGs and high-grade gliomas.²⁰ In the POLA database and the series from Wijnenga, *CDKN2A* homozygous deletions were not typically encountered in the WHO grade II tumors.^{23,28} Although most mIDH tumors have low tumor mutation burden (TMB), the presence of higher TMB was associated with a less favorable prognosis.²⁹ It should be noted, however, that these studies did not use the classic “high TMB” definition issued for checkpoint inhibitors and instead defined TMB cutoff values within their dataset to distinguish patient subgroups.

IDH R132H mutated tumors more commonly arise in the frontal lobes, whereas those with noncanonical mutations (ie, R132C; IDH2) have a wider central nervous system distribution, including infratentorial or multicentric locations.^{22,30} The “T2-FLAIR mismatch sign,” present in a minority of mIDH astrocytomas, is characterized by a T2 hyperintense rim on FLAIR imaging and homogeneous T2 internal appearance (Fig. 1). Gliomas with IDH mutation more frequently enhance than mIDH/codel tumors, whereas the latter (Fig. 2) are more often associated with heterogeneous T2 internal appearance and calcification.^{31–33} Recently, there has been interest in application of radiogenomics to distinguish mIDH tumors but thus far these efforts have shown limited sensitivity and specificity.³⁴

IDH mutated gliomas typically have a more indolent biological behavior than IDHwt tumors. Patients often present with seizures without other focal signs or symptoms. Patients with mIDH grade II and III tumors more commonly present with seizures than those with IDHwt tumors.²² Patients with IDHwt tumors, compared with those with mIDH, seem to associate with greater cognitive and physical impairment.³⁵

In a multivariable analysis, mIDH was one of the most significant independent variables correlating with lower risk of death, in particular among patients with WHO grade II and III tumors.³⁶ Gross total or “supratotal” resection is more frequently achieved in patients with mIDH tumors compared with IDHwt tumors,^{37,38} possibly in part due to relatively sharply demarcated borders radiographically³⁷ and the more frequent unifocal nature and frontal location. Patients with mIDH/non-codel tumors have intermediate survival outcome between those with oligodendroglioma (mIDH/codel) and IDHwt

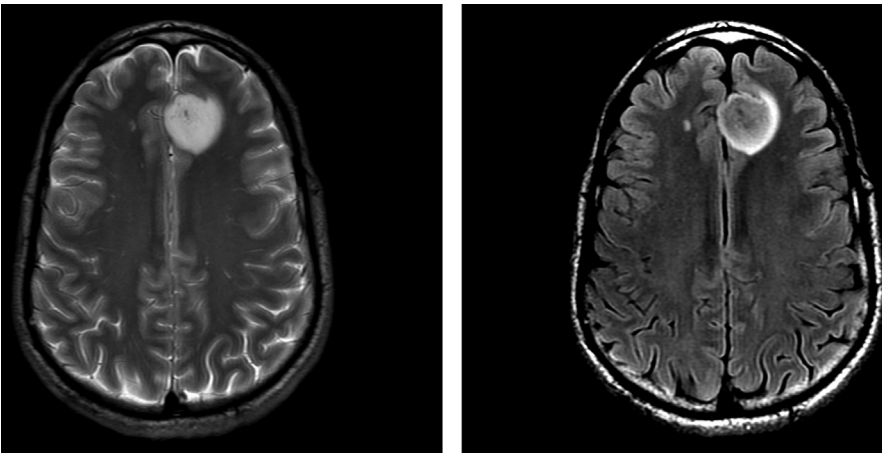


Fig. 1. “T2-FLAIR mismatch” sign. A brain MRI of a 35-year-old man with a histologically confirmed mIDH 1p/19q non-codel WHO Grade II glioma. (Left) T2-weighted sequence showing a hyperintensive, relatively homogeneous area. (Right) FLAIR sequence with hyperintense rim surrounding a relatively hypointense central area.

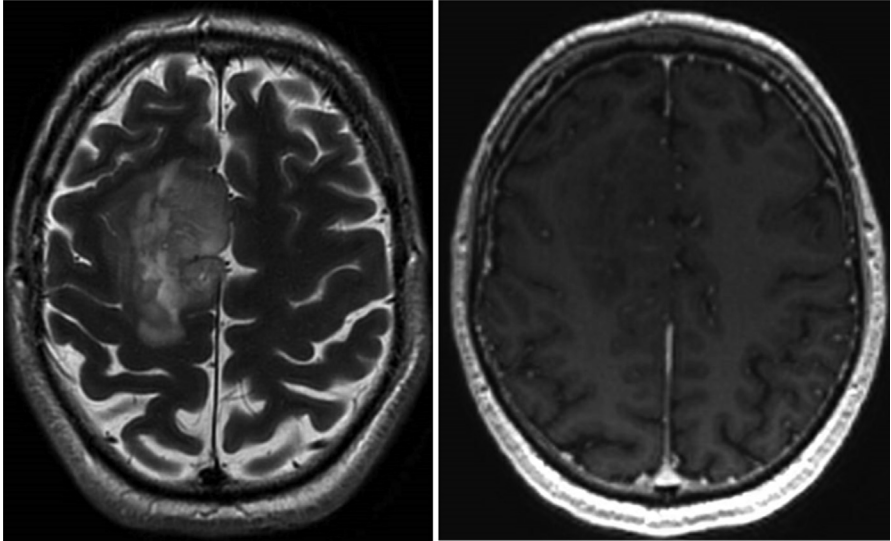


Fig. 2. Low-grade oligodendroglioma. Brain MRI T2 (*left*) and T1 after intravenous contrast (*right*), showing inhomogeneous lesion with cortical involvement and no contrast uptake.

tumors. In NRG/RTOG 9802, treatment of patients with high-risk low-grade mIDH gliomas with combined modality radiotherapy plus adjuvant PCV was associated with longer survival outcome than with RT alone (PFS: mIDH/non-codel: HR 0.32, $P = .003$; mIDH/codel: HR 0.13, $P < .001$; OS: mIDH/non-codel: HR 0.38, $P = .13$; mIDH/codel: HR 0.21, $P = .29$).³⁹ In the phase III CATNON trial for patients with WHO grade III non-codeleted gliomas the OS for IDH1/2 mt patients with genome wide methylation profiles consistent with astrocytoma IDHmt consistent with lower grade tumors has not been reached and 5.6 years in those methylation profiles consistent with high grade astrocytoma IDHmt.⁴⁰ In a study of pediatric and young adult patients with mIDH tumors, median PFS was 4.62 years and OS 17.2 years, with shorter survival observed in the young adult cohort.⁴¹

CURRENT TREATMENT OF LOWER GRADE GLIOMA

The treatment of lower grade glioma is based on a multimodality approach. It is important to note that the landmark studies that provide the foundation for the current treatment approach for LGG and anaplastic glioma were designed and conducted before current molecular classification of glioma being established and when modern surgical or radiotherapy techniques such as intensity-modulated radiotherapy or proton therapy were not available. As such, there are inherent limitations in trying to extrapolate results to the IDH-mutated glioma subgroup. Future studies stratifying patients into homogeneous populations will be critical to assess the benefit of novel therapies.

Maximal safe surgical resection remains the initial treatment of LGG to enable an accurate diagnosis and improve clinical outcomes such as PFS, OS, and risk of malignant transformation.^{42–44} The impact of maximal resection as first-line treatment may be more important for mIDH astrocytoma than oligodendroglioma.⁴⁵ Improved surgical techniques such as intraoperative MRI and electrostimulation mapping during an awake craniotomy allow for more extensive resection while minimizing neurologic injury.

Radiation therapy (RT) is an important adjunct in the management of LGG, and several studies have explored the optimal timing and dosing schedule. The European Organization for Research and Treatment of Cancer (EORTC) 22845 study comparing early RT after surgery versus RT delayed until time of progression showed no significant difference in OS (7.4 years vs 7.2 years), but patients who received early RT had improvements in seizure control and median PFS (5.3 years vs 3.4 years with delayed RT).⁴⁶ Two randomized studies evaluating high-dose RT versus low-dose RT did not show any significant differences in PFS and OS, but long-term analysis demonstrated improved quality of life in patients treated at the lower radiation dose.^{47–49}

The optimal use of RT and/or chemotherapy after surgery for low-grade gliomas continues to be defined. Several prognostic factors have been proposed to better identify patients at high risk for malignant transformation and may benefit from early management with adjuvant chemoradiation. High-risk factors include age greater than 40 years, subtotal resection/biopsy only, astrocytic lineage (lack of 1p/19q codeletion), neurologic deficits before surgery, tumor diameter greater than 6 cm, tumor crossing the midline of the brain, and tumors located within or adjacent to eloquent areas of the brain.^{50–52}

Patients without these risk factors can be considered at low risk; therefore, after gross total resection, they are usually observed closely with regularly scheduled surveillance imaging to assess for intervention at the time of progression. The EORTC brain tumor group is conducting a phase III study for patients with *IDH* mutated 1p/19q intact lower grade glioma following resection, without a need for immediate postoperative treatment, to establish whether early adjuvant treatment with radiotherapy and adjuvant temozolomide in this clinically favorable group of patients will improve outcome compared with active surveillance. The primary endpoint is first intervention free survival with multiple secondary endpoints of PFS, OS, seizure control, and health-related quality of life (EORTC-1635-BTG [ClinicalTrials.gov Identifier: NCT03763422](https://clinicaltrials.gov/ct2/show/study/NCT03763422)).

In an attempt to defer the adverse effects of RT, several studies have evaluated chemotherapy alone.^{53,54} A report of the EORTC 22033 study of temozolomide versus RT in high-risk LGG did not demonstrate a difference in PFS, but radiotherapy tended to be superior in mIDH astrocytoma. The results regarding the effects on OS are pending.⁵⁵

The survival benefit of adjuvant chemoradiotherapy for high-risk LGG was demonstrated in the Radiation Therapy Oncology Group 9802 phase III trial that randomized patients to receive RT or RT plus combination chemotherapy with PCV (procarbazine, lomustine, and vincristine). Based on the pivotal data showing an almost 2-fold increase in OS for patients in the chemoradiation therapy arm compared with the RT alone arm (13.3 years vs 7.8 years), high-risk patients with low-grade gliomas should receive radiotherapy followed by adjuvant chemotherapy rather than RT alone⁵⁶ (Fig. 3). This study was conducted before the molecular characterization of LGG. A post-hoc molecular analysis on a subgroup of patients from this trial³⁹ confirmed that patients with *IDH* mutated gliomas with or without 1p/19q codeletion benefited from the addition of PCV to radiotherapy but suggested that patients with *IDH* wild-type astrocytomas may not benefit from this combination.

The CATNON trial investigated concurrent and adjuvant temozolomide in anaplastic glioma and observed only benefit of the adjuvant treatment in mIDH anaplastic astrocytoma, not in IDHwt anaplastic astrocytoma. In mIDH tumors, adjuvant temozolomide improved outcome (hazard ratio [HR] 0.48, 95% confidence interval [CI] 0.35, 0.67; $P < .0001$), and 5-year survival increased from 62.0% (95% CI: 54.4, 68.7) to 81.6% (95% CI: 75.5, 86.4).⁵⁷

With the introduction of temozolomide as the standard of care for glioblastoma⁵⁸ and based on the improved safety profile compared with nitrosoureas, in clinical

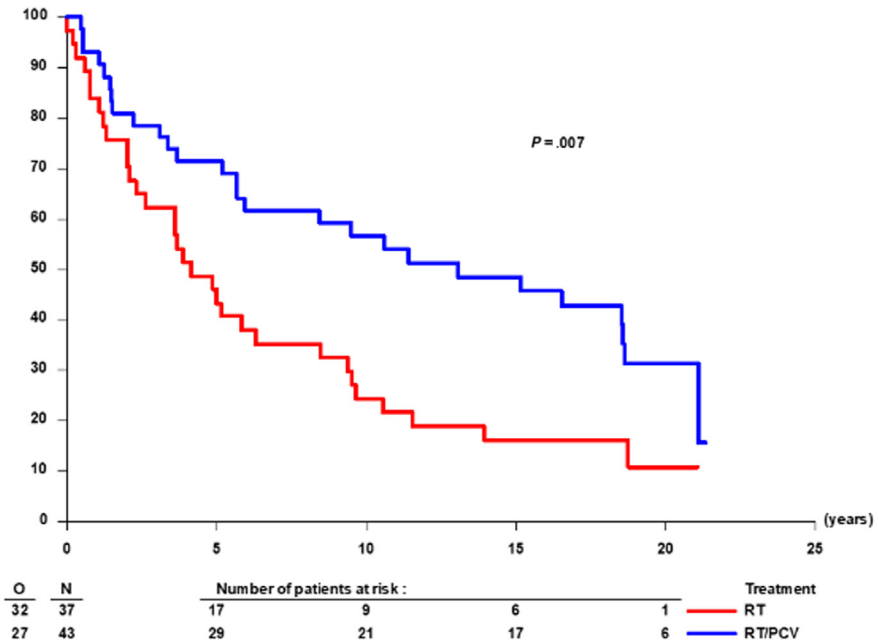


Fig. 3. Long-term follow-up of progression-free survival (PFS) of RT/PCV versus RT alone in 1p/19q codeleted glioma patients (n = 80) in EORTC 26951.

practice, patients are commonly treated with temozolomide. The ongoing CODEL phase III study randomizes patients with 1p/19q codeleted WHO grade II and III gliomas to receive either RT followed by PCV or RT with concurrent and then adjuvant temozolomide to address the comparison of these 2 chemotherapy regimens (*ClinicalTrials.gov Identifier*: NCT00887146).

DEVELOPMENT OF ISOCITRATE DEHYDROGENASE MUTANT INHIBITORS

Inhibiting the aberrant activity of mutant enzymes represents an established pharmacologic strategy for the treatment of human cancer, exemplified by the class of kinase inhibitors.⁵⁹ Cancer-associated mutant IDH enzymes represent attractive drug targets for the development of mutant-selective inhibitors because these mutations cluster in key arginine residues within the enzymes' active sites (R132 of IDH1 and R140 or R172 of IDH2) and because successful inhibition of the mutant enzyme can readily be ascertained through measurements of 2-HG in tumor biopsies.^{10,60} In patients with acute myeloid leukemia (AML) or cholangiocarcinoma, 2 other human cancers with frequent IDH mutations, 2-HG can also be detected in patient serum.^{61,62} Noninvasive imaging approaches for the detection of 2-HG in patients with glioma have been reported,^{63,64} but their utility for clinical practice and clinical drug development remains to be defined.

Preclinical studies demonstrated that inhibition of mutant IDH enzymes retards tumor growth in experimental models of glioma, leukemia, and cholangiocarcinoma.^{65–67}

The clinical development of inhibitors of mIDH proceeded most expeditiously for AML where, unlike in glioma, *IDH2* mutations are more common than *IDH1* mutations. Enasidenib, the first-in-class inhibitor of mIDH2, produced clinical responses in approximately 40% of patients with advanced mIDH2 AML.^{68,69} Ivosidenib, the first-

in-class inhibitor of the mIDH1 enzyme, similarly induced remissions in patients with advanced mIDH1 AML.⁷⁰ Both drugs have received regulatory approval for the treatment of mIDH AML.

A phase I study with ivosidenib in subjects with mIDH1 advanced solid tumors, including previously treated glioma ([ClinicalTrials.gov](https://clinicaltrials.gov) identifier: NCT02073994), reported no dose-limiting toxicities, and the maximum tolerated dose was not reached. A dose of 500 mg once daily was selected for expansion based on the pharmacokinetic/pharmacodynamic data from all solid tumor cohorts. This trial showed early signs of clinical activity in IDH1-mutant glioma, with a reduction in tumor volume growth rates (ie, compared with pretreatment growth rates) and tumor shrinkage in several patients.⁷¹ In patients with mIDH1 advanced cholangiocarcinoma, ivosidenib was also well tolerated and showed preliminary evidence for antitumor activity.⁷² The clinical benefit of targeting IDH1 mutations in advanced, mIDH1 cholangiocarcinoma was subsequently confirmed in a phase III trial.⁷³

Vorasidenib (AG-881) is a first-in-class dual inhibitor of mIDH1 and mIDH2 that was developed for improved penetration across the blood-brain barrier.⁷⁴ In a phase I study ([ClinicalTrials.gov](https://clinicaltrials.gov) identifier: NCT02481154), vorasidenib showed a favorable safety profile at doses less than 100 mg QD in previously treated patients with nonenhancing glioma. Many patients remained on treatment after several years of continuous treatment, and tumor shrinkage was observed in multiple patients with nonenhancing glioma.⁷⁵ In a follow-up perioperative phase I study in patients with nonenhancing glioma ([ClinicalTrials.gov](https://clinicaltrials.gov), NCT03343197), vorasidenib 50 mg QD resulted in greater than 90% reduction in intratumoral 2-HG concentrations compared with untreated controls, indicating near complete inhibition of the enzyme.⁶⁰

Because a watch-and-wait approach following surgery remains a treatment option for patients with low-risk LGG, there is an opportunity to explore the activity of mIDH inhibitors during the active observation period. Vorasidenib (50 mg QD) is now being tested versus placebo in the ongoing, randomized, phase III INDIGO study ([ClinicalTrials.gov](https://clinicaltrials.gov), NCT04164901) that enrolls patients with grade II nonenhancing mIDH glioma treated with surgery only.

Several other inhibitors targeting the mIDH enzymes are in earlier stages of clinical development for mIDH human cancers, including glioma.

OTHER THERAPEUTIC APPROACHES FOR ISOCITRATE DEHYDROGENASE MUTANT GLIOMA

Clinical and preclinical studies conducted since the first discovery of IDH mutations in cancer have provided deeper insights into the pathogenesis of IDH mutated human cancer and uncovered alternative and potentially complimentary approaches to exploit the effects of IDH mutations on cellular metabolism, epigenetic regulation, and immune function:

Targeting Tumor Metabolism

D-2-HG directly and indirectly influences multiple and diverse metabolic intracellular events, but the myriad of interactions, the specific and most critical oncogenic driving events have yet to be elucidated. IDH mutated glioma cells are prone to oxidative stress and are associated with increase reactive oxygen species.⁷⁶ Strategies involving activation of antioxidant pathways, including glutathione synthesis inhibition, have been proposed. Metabolic reprogramming characterized by increased oxidative metabolism in the Krebs cycle, with suppression of reductive glutamine metabolism, is a hallmark of IDH mutation. This increased rate of reductive glutaminolysis in

preclinical models⁷⁷ provides the rationale for evaluating the safety and efficacy of the oral glutaminase inhibitor CB-839 in combination with radiation and temozolomide in mIDH glioma (NCT03528642).

Poly (ADP-ribose) Polymerase Inhibitors

Poly (ADP-ribose) polymerase 1 (PARP1) (and other PARPs) plays critical roles in the repair of DNA single-strand breaks (SSBs) through several mechanisms that include base excision repair, nucleotide excision repair, and other DNA damage response pathways.⁷⁸ PARP inhibition leads to persistence of unrepaired SSBs and cytotoxic PARP-DNA complexes, which leads to the formation of potentially lethal DNA double-strand breaks (DSBs).⁷⁹ Cells with deficient homologous recombination, the main compensatory mechanism to manage the increased DSB stress imposed by PARP inhibition, are unable to efficiently repair these DSB and subsequently enter mitotic catastrophe and apoptosis.⁸⁰ Recent evidence suggests that 2-HG produced by mIDH enzymes causes homologous recombination processes to become dysfunctional,⁸¹ with evidence of activation of compensatory PARP-driven base excision repair mechanisms^{82,83}; this has raised interest in exploring PARP inhibitors such as olaparib (NCT03212274) or BGB-290 (NCT03749187) for the treatment of mIDH gliomas.

DNA Demethylation Agents

Another major consequence of IDH mutations and 2-HG accumulation is the inhibition of various components of the epigenetic machinery including histone and DNA demethylases (DNMTs), and this leads to aberrations in numerous biological processes that result in the glioma-CpG island methylator phenotype, characterized by genome-wide DNA hypermethylation.⁸⁴ Restoring epigenetic programming via DNA demethylation is a current research strategy in mIDH glioma. The 2 prototypal DNA-demethylating agents, decitabine (DAC, trade name Dacogen, Eisai) and 5-azacitidine (AZA, trade name Vidaza, Celgene), are Food and Drug Administration approved for treating patients with myelodysplastic syndrome. These drugs are cytidine analogues that incorporate into the DNA in the case of both agents, and RNA in the case of azacitidine, and form an irreversible covalent bond with DNMTs triggering the ubiquitin-dependent degradation of the enzymes. Both DAC and AZA have short half-lives and poor in vivo stability due to their rapid deamination by the ubiquitously expressed cytidine deaminase (CDA). Overcoming this barrier for sustained and effective therapy for DNA methylation inhibition is being addressed in a clinical study of ASTX727, which consists of DAC and E7727 (cedazuridine), a novel CDA, in mIDH glioma (NCT03922555). The value of these strategies has yet to be demonstrated clinically.

Immunotherapy Approaches

Recent studies showed that the most common form of the mIDH enzyme in glioma (IDH1R132H) is presented on human MHC class II and induces mutation-specific CD4+ antitumor T-cell responses.⁸⁵ The opportunity for peptide-based vaccination strategies using mutation-specific peptides has been evaluated in early clinical trials demonstrating safety and immunogenicity.⁸⁶ In addition, 2 pilot studies in patients with LGG are exploring the neoadjuvant administration of vaccines with immune modulatory adjuncts. Several studies suggest that mIDH and the 2-HG oncometabolite may play critical roles in shaping the immunologic landscape of the tumor micro-environment. IDH mutation in glioma seems to be associated with impaired T-cell recruitment and T-cell receptor signaling, decreased tumor-infiltrating lymphocytes, and reduced programmed death ligand 1 expression.⁸⁷⁻⁹³ These observations have prompted initial clinical trials involving checkpoint inhibition with avelumab

(NCT02968940) and pembrolizumab (NCT02658279). These studies illustrate the interest in modulating the immune response using check point inhibitors in IDH mutated tumors as a single agent but also in combination with peptide vaccination strategies. However, the role and efficacy of immunomodulatory therapies in treatment of mIDH glioma remain open questions.

EVALUATION OF TREATMENT RESPONSE AND TUMOR GROWTH IN ISOCITRATE DEHYDROGENASE MUTANT GLIOMA

Treatment efficacy in oncology is traditionally assessed with survival endpoints, in particular OS; this is assumed to present the most reliable endpoint reflecting ultimate patient benefit. For some tumors, the use of PFS is a well-established surrogate for OS, and, in individual patients, response or absence of progression to a particular treatment is taken as evidence of benefit to that treatment.

This general approach to assess efficacy is less straightforward in mIDH lower grade glioma for several reasons. First, many of these patients are for many years clinically asymptomatic apart from usually well-controlled seizures, and maintaining that status is clinically relevant. Secondly, these tumors are slowly but continuously growing entities if left untreated,⁹⁴ which implies that the tumor will progress after surgery, from the first day after surgery, and the date of progression is arbitrarily based on the cutoff that is taken to define progression on imaging. Thirdly, response assessment in glioma is usually based on changes in enhancement, which is an indirect and specific measure of tumor growth and not applicable to nonenhancing tumors. Changes in nonenhancing tumor volume are often limited and may appear late, even after the end of lengthy chemotherapy cycles.⁹⁵ Lastly, radiotherapy and surgical effects may induce areas with increased signal intensities on T2-weighted and FLAIR MR images that are similar to radiographic changes associated with tumor progression, challenging the distinction between these 2 opposite conditions.

To address the many differences between high-grade gliomas and LGGs, specific RANO criteria for outcome and assessment of LGG have been proposed, which incorporate measures for seizure and cognition assessment.⁹⁶ RANO response criteria to treatment of unenhancing LGG are built on the classic Macdonald's criteria, with a 50% reduction of unenhancing area qualifying for response and 25% increase for progression. With modern computer technology, it has become feasible to assess (changes in) tumor volume and relate that to outcome in a semiautomated manner⁴⁵ and has resulted in new ways of evaluating outcome, as the assessment of change in volumetric growth rate during treatment.⁹⁷ It will take, however, a review of large prospective datasets to validate such endpoints, preferably of homogeneously treated patients.

For everyday clinical practice, looking at change in tumor size will remain the standard approach for many years to come. With that in mind, it is important to realize the confusion that may arise of enhancing pseudoprogression after radiotherapy and white matter changes after extensive surgery and after radiotherapy, which both may give the false impression of tumor progression.⁹⁸

Future Directions in Isocitrate Dehydrogenase Mutant Glioma

Despite the progress made in the understanding of the prognostic significance and altered cellular events in mIDH gliomas, many unanswered questions remain regarding the specific oncogenic mechanisms resulting from this alteration. In order to improve the outcome of these patients, it will be important to delineate the most significant oncogenic driving mechanisms in mIDH glioma and translate key findings to targeted and combined treatment/modality strategies.

In the clinical arena, there are several unanswered questions with respect to the best therapeutic compounds beyond standard radiation and chemotherapy, the role of combination strategies, and optimal timing of therapy and sequencing of treatments. Some of these questions are articulated as follows:

What are Relevant Endpoints in the Evaluation of Novel Agents for Isocitrate Dehydrogenase Mutant Glioma?

A major issue in LGG is the assessment of survival from a functional perspective. Cognition is often impaired in patients with glioma, and therapy (radiotherapy, surgery) may contribute to that. A particularly notorious delayed effect of radiotherapy is delayed leukoencephalopathy associated with decreased memory function and attention span.^{99,100} It is unclear to what extent radiotherapy delivered with modern techniques induces this side effect. Given the relatively favorable prognosis of most patients with LGG, the challenge is not only long survival but also survival with a good quality of functioning in the posttreatment period. Surviving without cognitive deficits is of vital interest to patients, and some ongoing studies have this as a primary endpoint but data from these trials and a critical evaluation of this type of endpoint are still lacking. An impossible to answer question is what level of change in a cognitive test equals some loss in OS. Seizures are in general better controlled after extensive surgery, radiotherapy, and chemotherapy. Although recurrent seizures do not necessarily indicate tumor progression, being seizure free obviously is a matter of importance for patients and does reflect a relevant clinical endpoint.¹⁰¹ Lastly, with the addition of chemotherapy to radiotherapy, survival from the start of these treatments in low-grade mIDH glioma and anaplastic oligodendroglioma is beyond 14 years.⁵⁶ From a practical perspective, the development of alternative endpoints that reflect patient benefit is urgently needed and is being explored in the CODEL and POLA studies. Such endpoints could be radiological, provided a validated relationship with ultimate clinical patient benefit is demonstrated, or cognitive functioning, assuming that this might best reflect the patient's well-being.

Is There a Role for Direct Inhibition of Isocitrate Dehydrogenase and, If So, at What Stage of the Disease?

Although the mIDH enzyme likely plays a critical role in the initiation of mIDH LGGs, its contribution to the relentless growth of fully developed diffuse gliomas remains to be proved. The current experience with the mIDH inhibitors ivosidenib and vorasidenib suggests that this contribution might be greatest at the earlier disease stage. In contrast, ivosidenib and vorasidenib showed no clear antitumor activity in patients with enhancing tumors. The lack of single-agent antitumor efficacy for ivosidenib or vorasidenib in patients with enhancing gliomas may be due to the presence of additional genetic alterations in these tumors that can bypass the need for the mIDH enzyme for tumor maintenance.

Can Treatment be Delayed for a Specific Subgroup of Patients with Isocitrate Dehydrogenase Mutant Glioma?

At this time, there are several additional markers, such as 1/p/19q codeletion status, CDKN2A/B, TP53, ATRX, TERT mutation, TMB, methylation status of the MGMT gene promoter, and clinical factors including conventional histologic grade, performance status, and extent of resection, which can influence the prognosis of IDHmt patients, and new genomic alterations continue to be discovered. It is conceivable that in the future a subgroup of better prognosis patients may be identified in which RT, or radio chemotherapy, can be delayed; conversely, poor prognostic patient subgroups may be

identified who should receive earlier and aggressive treatment. It is likely that such factors will be identified and used as grouping or stratification factors or eligibility for entry in future clinical trials. The other possibility is that patients with more favorable prognosis derive greater benefit from early aggressive treatment and that patients with more unfavorable prognosis fare worse regardless what is tried. Answering these important questions will require carefully collected and molecularly annotated datasets.

CLINICAL CARE POINTS

- The diagnoses of glioma today are based on integrated molecular diagnostics, in particular of the IDH gene and of the 1p/19q codeletion status.
- An essential part of the treatment of these tumors is a resection as extensive as safely possible, this is to be considered upon the first radiological diagnosis of a presumed glioma.
- Radiotherapy followed by chemotherapy improves survival in IDH mutated glioma that require post-operative adjuvant treatment.
- A significant percentage of patients with IDH mutated glioma become long term survivor after resection, radiotherapy and chemotherapy, but the current understanding is that this treatment is not curative.
- The quality of long term survival is an important consideration while planning treatment for these patients.
- Novel therapeutic approaches aim at inhibiting the mutated isocitrate dehydrogenase enzyme, and of cellular vulnerabilities that are the result of the mutated enzyme.

ACKNOWLEDGMENTS

This work was supported by 1 R35 NS105109 03 (I.K. Mellinghoff), P30CA008748 (I.K. Mellinghoff), and Cycle of Survival (I.K. Mellinghoff).

DISCLOSURE

I.K. Mellinghoff reports serving as a consultant for Agios Pharmaceuticals, Inc, Black Diamond, DC Europa, Debiopharm, Puma Biotechnology, and Voyager, and research grants from Amgen, Eli Lilly, and General Electric. M. van den Bent reports serving as a consultant for Agios Pharmaceuticals, Karyopharm, Cellgene, Nerviano, Carthera, and Genenta. S.M. Chang reports institutional research support from Agios Pharmaceuticals.

REFERENCES

1. Sjöblom T, Jones S, Wood LD, et al. The consensus coding sequences of human breast and colorectal cancers. *Science* 2006;314(5797):268–74.
2. Parsons DW, Jones S, Zhang X, et al. An integrated genomic analysis of human glioblastoma multiforme. *Science* 2008;321(5897):1807–12.
3. Balss J, Meyer J, Mueller W, et al. Analysis of the IDH1 codon 132 mutation in brain tumors. *Acta Neuropathol* 2008;116(6):597–602.
4. Yan H, Parsons DW, Jin G, et al. IDH1 and IDH2 mutations in gliomas. *N Engl J Med* 2009;360(8):765–73.
5. Watanabe T, Nobusawa S, Kleihues P, et al. IDH1 mutations are early events in the development of astrocytomas and oligodendrogliomas. *Am J Pathol* 2009; 174(4):1149–53.

6. Turcan S, Rohle D, Goenka A, et al. IDH1 mutation is sufficient to establish the glioma hypermethylator phenotype. *Nature* 2012;483(7390):479–83.
7. Johnson BE, Mazor T, Hong C, et al. Mutational analysis reveals the origin and therapy-driven evolution of recurrent glioma. *Science* 2014;343(6167):189–93.
8. Miller AM, Shah RH, Pentsova EI, et al. Tracking tumour evolution in glioma through liquid biopsies of cerebrospinal fluid. *Nature* 2019;565(7741):654–8.
9. Barthel FP, Johnson KC, Varn FS, et al. Longitudinal molecular trajectories of diffuse glioma in adults. *Nature* 2019;576(7785):112–20.
10. Dang L, White DW, Gross S, et al. Cancer-associated IDH1 mutations produce 2-hydroxyglutarate. *Nature* 2009;462(7274):739–44.
11. Gross S, Cairns RA, Minden MD, et al. Cancer-associated metabolite 2-hydroxyglutarate accumulates in acute myelogenous leukemia with isocitrate dehydrogenase 1 and 2 mutations. *J Exp Med* 2010;207(2):339–44.
12. Ward PS, Patel J, Wise DR, et al. The common feature of leukemia-associated IDH1 and IDH2 mutations is a neomorphic enzyme activity converting alpha-ketoglutarate to 2-hydroxyglutarate. *Cancer Cell* 2010;17(3):225–34.
13. Xu W, Yang H, Liu Y, et al. Oncometabolite 2-hydroxyglutarate is a competitive inhibitor of alpha-ketoglutarate-dependent dioxygenases. *Cancer Cell* 2011;19(1):17–30.
14. Lu C, Ward PS, Kapoor GS, et al. IDH mutation impairs histone demethylation and results in a block to cell differentiation. *Nature* 2012;483(7390):474–8.
15. Reitman ZJ, Sinenko SA, Spana EP, et al. Genetic dissection of leukemia-associated IDH1 and IDH2 mutants and D-2-hydroxyglutarate in *Drosophila*. *Blood* 2015;125(2):336–45.
16. Losman JA, Cooper RE, Koivunen P, et al. (R)-2-hydroxyglutarate is sufficient to promote leukemogenesis and its effects are reversible. *Science* 2013;339(6127):1621–5.
17. Tateishi K, Wakimoto H, Iafrate AJ, et al. Extreme Vulnerability of IDH1 Mutant Cancers to NAD⁺ Depletion. *Cancer Cell* 2015;28(6):773–84.
18. Andrews C, Prayson RA. IDH mutations in older patients with diffuse astrocytic gliomas. *Ann Diagn Pathol* 2020;49:151653.
19. Choi J, Kim SH, Ahn SS, et al. Extent of resection and molecular pathologic subtype are potent prognostic factors of adult WHO grade II glioma. *Sci Rep* 2020;10(1):2086.
20. Lu VM, O'Connor KP, Shah AH, et al. The prognostic significance of CDKN2A homozygous deletion in IDH-mutant lower-grade glioma and glioblastoma: a systematic review of the contemporary literature. *J Neurooncol* 2020;148(2):221–9.
21. Wang LM, Li Z, Piao YS, et al. Clinico-neuropathological features of isocitrate dehydrogenase 2 gene mutations in lower-grade gliomas. *Chin Med J (Engl)* 2019;132(24):2920–6.
22. Poetsch L, Bronnimann C, Loiseau H, et al. Characteristics of IDH-mutant gliomas with non-canonical IDH mutation. *J Neurooncol* 2021;151:279–86.
23. Appay R, Dehais C, Maura CA, et al. CDKN2A homozygous deletion is a strong adverse prognosis factor in diffuse malignant IDH-mutant gliomas. *Neuro Oncol* 2019;21(12):1519–28.
24. Roux A, Pallud J, Saffroy R, et al. High-grade gliomas in adolescents and young adults highlight histomolecular differences from their adult and pediatric counterparts. *Neuro Oncol* 2020;22(8):1190–202.

25. Eckel-Passow JE, Lachance DH, Molinaro AM, et al. Glioma groups based on 1p/19q, IDH, and TERT promoter mutations in tumors. *N Engl J Med* 2015; 372(26):2499–508.
26. Cancer Genome Atlas Research N, Brat DJ, Verhaak RG, et al. Comprehensive, integrative genomic analysis of diffuse lower-grade gliomas. *N Engl J Med* 2015; 372(26):2481–98.
27. Ohba S, Kuwahara K, Yamada S, et al. Correlation between IDH, ATRX, and TERT promoter mutations in glioma. *Brain Tumor Pathol* 2020;37(2):33–40.
28. Wijnenga MMJ, French PJ, Dubbink HJ, et al. Prognostic relevance of mutations and copy number alterations assessed with targeted next generation sequencing in IDH mutant grade II glioma. *J Neurooncol* 2018;139(2):349–57.
29. Alghamri MS, Thalla R, Avvari RP, et al. Tumor mutational burden predicts survival in patients with low-grade gliomas expressing mutated IDH1. *Neurooncol Adv* 2020;2(1):vdaa042.
30. Lai A, Kharbanda S, Pope WB, et al. Evidence for sequenced molecular evolution of IDH1 mutant glioblastoma from a distinct cell of origin. *J Clin Oncol* 2011; 29(34):4482–90.
31. van Lent DI, van Baarsen KM, Snijders TJ, et al. Radiological differences between subtypes of WHO 2016 grade II-III gliomas: a systematic review and meta-analysis. *Neurooncol Adv* 2020;2(1):vdaa044.
32. Kapsalaki EZ, Brotis AG, Tsirikla A, et al. The role of the T2-FLAIR mismatch sign as an imaging marker of IDH status in a mixed population of low- and high-grade gliomas. *Brain Sci* 2020;10(11):874.
33. Throckmorton P, Graber JJ. T2-FLAIR mismatch in isocitrate dehydrogenase mutant astrocytomas: variability and evolution. *Neurology* 2020;95(11):e1582–9.
34. Bhandari AP, Liong R, Koppen J, et al. Noninvasive determination of IDH and 1p19q status of lower-grade gliomas using MRI radiomics: a systematic review. *AJNR Am J Neuroradiol* 2021;42(1):94–101.
35. Bunevicius A, Miller J, Parsons M. Isocitrate dehydrogenase, patient-reported outcomes, and cognitive functioning of glioma patients: a systematic review. *Curr Oncol Rep* 2020;22(12):120.
36. Franceschi E, Tosoni A, Bartolini S, et al. Histopathological grading affects survival in patients with IDH-mutant grade II and grade III diffuse gliomas. *Eur J Cancer* 2020;137:10–7.
37. De Leeuw BI, Van Baarsen KM, Snijders TJ, et al. Interrelationships between molecular subtype, anatomical location, and extent of resection in diffuse glioma: a systematic review and meta-analysis. *Neurooncol Adv* 2019;1(1):vdz032.
38. Rossi M, Gay L, Ambrogio F, et al. Association of supratotal resection with progression-free survival, malignant transformation, and overall survival in lower-grade gliomas. *Neur Oncol* 2021;23:812–26.
39. Bell EH, Zhang P, Shaw EG, et al. Comprehensive genomic analysis in NRG Oncology/RTOG 9802: a phase III trial of radiation versus radiation plus procarbazine, lomustine (CCNU), and vincristine in high-risk low-grade glioma. *J Clin Oncol* 2020;38(29):3407–17.
40. Tesileanu C, Bent M, Sabedot T, et al. PATH-11. Prognostic significance of epigenetic subtypes and CpGs ASSOCIATED with progression to G-CIMP low in the eortc randomized phase iii intergroup catnon. *Neuro-Oncology*. 2020; 22:ii166.
41. Lim-Fat M, Vogelzang J, Woodward E, et al. EPID-11. A multi-institutional comparative analysis of the clinical, genomic, and survival characteristics of

- pediatric, young adult and older adult patients with idh-mutant glioma. *Neuro Oncol* 2020;22:ii80–1.
42. Shaw EG, Berkey B, Coons SW, et al. Recurrence following neurosurgeon-determined gross-total resection of adult supratentorial low-grade glioma: results of a prospective clinical trial. *J Neurosurg* 2008;109(5):835–41.
 43. Sanai N, Berger MS. Glioma extent of resection and its impact on patient outcome. *Neurosurgery* 2008;62(4):753–64 [discussion 264–756].
 44. Duffau H. Surgery of low-grade gliomas: towards a 'functional neurooncology'. *Curr Opin Oncol* 2009;21(6):543–9.
 45. Wijnenga MMJ, French PJ, Dubbink HJ, et al. The impact of surgery in molecularly defined low-grade glioma: an integrated clinical, radiological, and molecular analysis. *Neuro Oncol* 2018;20(1):103–12.
 46. van den Bent MJ, Afra D, de Witte O, et al. Long-term efficacy of early versus delayed radiotherapy for low-grade astrocytoma and oligodendroglioma in adults: the EORTC 22845 randomised trial. *Lancet* 2005;366(9490):985–90.
 47. Karim AB, Maat B, Hatlevoll R, et al. A randomized trial on dose-response in radiation therapy of low-grade cerebral glioma: European Organization for Research and Treatment of Cancer (EORTC) Study 22844. *Int J Radiat Oncol Biol Phys* 1996;36(3):549–56.
 48. Kiebert GM, Curran D, Aaronson NK, et al. Quality of life after radiation therapy of cerebral low-grade gliomas of the adult: results of a randomised phase III trial on dose response (EORTC trial 22844). *EORTC Radiotherapy Co-operative Group. Eur J Cancer* 1998;34(12):1902–9.
 49. Shaw E, Arusell R, Scheithauer B, et al. Prospective randomized trial of low-versus high-dose radiation therapy in adults with supratentorial low-grade glioma: initial report of a North Central Cancer Treatment Group/Radiation Therapy Oncology Group/Eastern Cooperative Oncology Group study. *J Clin Oncol* 2002;20(9):2267–76.
 50. Pignatti F, van den Bent M, Curran D, et al. Prognostic factors for survival in adult patients with cerebral low-grade glioma. *J Clin Oncol* 2002;20(8):2076–84.
 51. Chang EF, Smith JS, Chang SM, et al. Preoperative prognostic classification system for hemispheric low-grade gliomas in adults. *J Neurosurg* 2008;109(5):817–24.
 52. Daniels TB, Brown PD, Felten SJ, et al. Validation of EORTC prognostic factors for adults with low-grade glioma: a report using intergroup 86-72-51. *Int J Radiat Oncol Biol Phys* 2011;81(1):218–24.
 53. Wahl M, Phillips JJ, Molinaro AM, et al. Chemotherapy for adult low-grade gliomas: clinical outcomes by molecular subtype in a phase II study of adjuvant temozolomide. *Neuro Oncol* 2017;19(2):242–51.
 54. Ruda R, Pellerino A, Pace A, et al. Efficacy of initial temozolomide for high-risk low grade gliomas in a phase II AINO (Italian Association for Neuro-Oncology) study: a post-hoc analysis within molecular subgroups of WHO 2016. *J Neurooncol* 2019;145(1):115–23.
 55. Baumert BG, Hegi ME, van den Bent MJ, et al. Temozolomide chemotherapy versus radiotherapy in high-risk low-grade glioma (EORTC 22033-26033): a randomised, open-label, phase 3 intergroup study. *Lancet Oncol* 2016;17(11):1521–32.
 56. Buckner JC, Shaw EG, Pugh SL, et al. Radiation plus Procarbazine, CCNU, and vincristine in low-grade glioma. *N Engl J Med* 2016;374(14):1344–55.
 57. van den Bent MJ, Tesileanu MS, Wick W, et al. Adjuvant and concurrent temozolomide for 1p/19q non-co-deleted anaplastic glioma (CATNON; EORTC study

- 26053-22054): second interim analysis of a randomised, open-label, phase 3 study. *Lanc Oncol* 2021;22:813–23.
58. Stupp R, Mason WP, van den Bent MJ, et al. Radiotherapy plus concomitant and adjuvant temozolomide for glioblastoma. *N Engl J Med* 2005;352(10):987–96.
 59. Ferguson FM, Gray NS. Kinase inhibitors: the road ahead. *Nat Rev Drug Discov* 2018;17(5):353–77.
 60. Mellinghoff IK, Cloughesy TF, Wen P, et al. A phase 1, open-label, perioperative study of ivosidenib (AG-120) and vorasidenib (AG-881) in recurrent, IDH1-mutant, low-grade glioma: updated results. *Neuro Oncol* 2019;21:vi28–9.
 61. DiNardo CD, Probert KJ, Loren AW, et al. Serum 2-hydroxyglutarate levels predict isocitrate dehydrogenase mutations and clinical outcome in acute myeloid leukemia. *Blood* 2013;121(24):4917–24.
 62. Borger DR, Goyal L, Yau T, et al. Circulating oncometabolite 2-hydroxyglutarate is a potential surrogate biomarker in patients with isocitrate dehydrogenase-mutant intrahepatic cholangiocarcinoma. *Clin Cancer Res* 2014;20(7):1884–90.
 63. Andronesi OC, Kim GS, Gerstner E, et al. Detection of 2-hydroxyglutarate in IDH-mutated glioma patients by in vivo spectral-editing and 2D correlation magnetic resonance spectroscopy. *Sci Transl Med* 2012;4(116):116ra114.
 64. Choi C, Ganji SK, DeBerardinis RJ, et al. 2-hydroxyglutarate detection by magnetic resonance spectroscopy in IDH-mutated patients with gliomas. *Nat Med* 2012;18(4):624–9.
 65. Rohle D, Popovici-Muller J, Palaskas N, et al. An inhibitor of mutant IDH1 delays growth and promotes differentiation of glioma cells. *Science* 2013;340(6132):626–30.
 66. Wang F, Travins J, DeLaBarre B, et al. Targeted inhibition of mutant IDH2 in leukemia cells induces cellular differentiation. *Science* 2013;340(6132):622–6.
 67. Saha SK, Parachoniak CA, Ghanta KS, et al. Mutant IDH inhibits HNF-4alpha to block hepatocyte differentiation and promote biliary cancer. *Nature* 2014;513(7516):110–4.
 68. Yen K, Travins J, Wang F, et al. AG-221, a first-in-class therapy targeting acute myeloid leukemia harboring oncogenic IDH2 mutations. *Cancer Discov* 2017;7(5):478–93.
 69. Amatangelo MD, Quek L, Shih A, et al. Enasidenib induces acute myeloid leukemia cell differentiation to promote clinical response. *Blood* 2017;130(6):732–41.
 70. DiNardo CD, Stein EM, de Botton S, et al. Durable Remissions with Ivosidenib in IDH1-mutated relapsed or refractory AML. *N Engl J Med* 2018;378(25):2386–98.
 71. Mellinghoff IK, Ellingson BM, Touat M, et al. Ivosidenib in Isocitrate Dehydrogenase 1-mutated advanced glioma. *J Clin Oncol* 2020;38(29):3398–406.
 72. Lowery MA, Burris HA 3rd, Janku F, et al. Safety and activity of ivosidenib in patients with IDH1-mutant advanced cholangiocarcinoma: a phase 1 study. *Lancet Gastroenterol Hepatol* 2019;4(9):711–20.
 73. Abou-Alfa GK, Macarulla T, Javle MM, et al. Ivosidenib in IDH1-mutant, chemotherapy-refractory cholangiocarcinoma (ClarIDHy): a multicentre, randomised, double-blind, placebo-controlled, phase 3 study. *Lancet Oncol* 2020;21(6):796–807.
 74. Konteatis Z, Artin E, Nicolay B, et al. Vorasidenib (AG-881): a first-in-class, brain-penetrant dual inhibitor of mutant IDH1 and 2 for treatment of glioma. *ACS Med Chem Lett* 2020;11(2):101–7.

75. Mellinghoff IK, Penas-Prado M, Peters KB, et al. Vorasidenib, a dual inhibitor of mutant IDH1/2, in Recurrent or progressive glioma. *Clin Cancer Res* 2021; 27(16):4491–9.
76. Gilbert MR, Liu Y, Neltner J, et al. Autophagy and oxidative stress in gliomas with IDH1 mutations. *Acta Neuropathol* 2014;127(2):221–33.
77. Ohka F, Ito M, Ranjit M, et al. Quantitative metabolome analysis profiles activation of glutaminolysis in glioma with IDH1 mutation. *Tumour Biol* 2014;35(6): 5911–20.
78. Wei H, Yu X. Functions of PARylation in DNA damage repair pathways. *Genomics Proteomics Bioinformatics* 2016;14(3):131–9.
79. Murai J, Huang SY, Das BB, et al. Trapping of PARP1 and PARP2 by clinical PARP inhibitors. *Cancer Res* 2012;72(21):5588–99.
80. Curtin NJ. DNA repair dysregulation from cancer driver to therapeutic target. *Nat Rev Cancer* 2012;12(12):801–17.
81. Sulkowski PL, Corso CD, Robinson ND, et al. 2-Hydroxyglutarate produced by neomorphic IDH mutations suppresses homologous recombination and induces PARP inhibitor sensitivity. *Sci Transl Med* 2017;9(375):eaal2463.
82. Lu Y, Kwintkiewicz J, Liu Y, et al. Chemosensitivity of IDH1-mutated gliomas due to an impairment in PARP1-Mediated DNA repair. *Cancer Res* 2017;77(7): 1709–18.
83. Sulkowski PL, Sundaram RK, Oeck S, et al. Krebs-cycle-deficient hereditary cancer syndromes are defined by defects in homologous-recombination DNA repair. *Nat Genet* 2018;50(8):1086–92.
84. Noushmehr H, Weisenberger DJ, Diefes K, et al. Identification of a CpG island methylator phenotype that defines a distinct subgroup of glioma. *Cancer Cell* 2010;17(5):510–22.
85. Schumacher T, Bunse L, Pusch S, et al. A vaccine targeting mutant IDH1 induces antitumour immunity. *Nature* 2014;512(7514):324–7.
86. Platten M, Bunse L, Wick A, et al. A vaccine targeting mutant IDH1 in newly diagnosed glioma. *Nature* 2021;592(7854):463–8.
87. Tyrakis PA, Palazon A, Macias D, et al. S-2-hydroxyglutarate regulates CD8(+) T-lymphocyte fate. *Nature* 2016;540(7632):236–41.
88. Amankulor NM, Kim Y, Arora S, et al. Mutant IDH1 regulates the tumor-associated immune system in gliomas. *Genes Dev* 2017;31(8):774–86.
89. Kohanbash G, Carrera DA, Shrivastav S, et al. Isocitrate dehydrogenase mutations suppress STAT1 and CD8+ T cell accumulation in gliomas. *J Clin Invest* 2017;127(4):1425–37.
90. Bunse L, Pusch S, Bunse T, et al. Suppression of antitumor T cell immunity by the oncometabolite (R)-2-hydroxyglutarate. *Nat Med* 2018;24(8):1192–203.
91. Berghoff AS, Kiesel B, Widhalm G, et al. Correlation of immune phenotype with IDH mutation in diffuse glioma. *Neuro Oncol* 2017;19(11):1460–8.
92. Sorensen MD, Nielsen O, Reifenberger G, et al. The presence of TIM-3 positive cells in WHO grade III and IV astrocytic gliomas correlates with isocitrate dehydrogenase mutation status. *Brain Pathol* 2020;31(3):e12921.
93. Wang Z, Zhang C, Liu X, et al. Molecular and clinical characterization of PD-L1 expression at transcriptional level via 976 samples of brain glioma. *Oncoimmunology* 2016;5(11):e1196310.
94. Mandonnet E, Delattre JY, Tanguy ML, et al. Continuous growth of mean tumor diameter in a subset of grade II gliomas. *Ann Neurol* 2003;53(4):524–8.

95. Peyre M, Cartalat-Carel S, Meyronet D, et al. Prolonged response without prolonged chemotherapy: a lesson from PCV chemotherapy in low-grade gliomas. *Neuro Oncol* 2010;12(10):1078–82.
96. van den Bent MJ, Wefel JS, Schiff D, et al. Response assessment in neuro-oncology (a report of the RANO group): assessment of outcome in trials of diffuse low-grade gliomas. *Lancet Oncol* 2011;12(6):583–93.
97. Huang RY, Young RJ, Ellingson BM, et al. Volumetric analysis of IDH-mutant lower-grade glioma: a natural history study of tumor growth rates before and after treatment. *Neuro Oncol* 2020;22(12):1822–30.
98. van West SE, de Bruin HG, van de Langerijt B, et al. Incidence of pseudoprogression in low-grade gliomas treated with radiotherapy. *Neuro Oncol* 2017;19(5):719–25.
99. Douw L, Klein M, Fagel SS, et al. Cognitive and radiological effects of radiotherapy in patients with low-grade glioma: long-term follow-up. *Lancet Neurol* 2009;8(9):810–8.
100. Habets EJ, Taphoorn MJ, Nederend S, et al. Health-related quality of life and cognitive functioning in long-term anaplastic oligodendroglioma and oligoastrocytoma survivors. *J Neurooncol* 2014;116(1):161–8.
101. Avila EK, Chamberlain M, Schiff D, et al. Seizure control as a new metric in assessing efficacy of tumor treatment in low-grade glioma trials. *Neuro Oncol* 2017;19(1):12–21.