

## CASE REPORT

ADVANCED

## CLINICAL CASE

# Combined Triple Transcatheter Aortic Procedure in a Patient With Aortic Stenosis, Coarctation, and Aneurysm



Wei Zhong, MD,<sup>a,b,c</sup> Cunren Li, MD,<sup>a,b,c</sup> Ben Ren, MD, PhD,<sup>d,e</sup> Zhidong Liu, MD,<sup>a,b,c</sup> Xianfang Wang, MD,<sup>a,b,c</sup> XianfangGu, MD,<sup>a,b,c</sup> Bin Ou, MD,<sup>a,b,c</sup> Min Zhong, MD,<sup>a,b,c</sup> Ernest Spitzer, MD,<sup>d,e</sup> Zhixiong Zhong, MD<sup>a,b,c</sup>

## ABSTRACT

We present the case of a 71-year-old man admitted because of chest tightness, palpitations, and progressive shortness of breath. The diagnosis of severe aortic stenosis, coarctation, and aneurysm was established, as well as severely depressed left ventricular ejection fraction. Three consecutive transcatheter procedures were successfully performed in a single session. (**Level of Difficulty: Advanced.**) (J Am Coll Cardiol Case Rep 2021;3:1782-1786) © 2021 The Authors. Published by Elsevier on behalf of the American College of Cardiology Foundation. This is an open access article under the CC BY-NC-ND license (<http://creativecommons.org/licenses/by-nc-nd/4.0/>).

## HISTORY OF PRESENTATION

A 71-year-old man was admitted because of chest tightness, palpitations, and progressive shortness of breath becoming more severe 1 week before admission. The physical examination revealed hypotension (90/50 mmHg), a rhythmic pulse (92 beats/min), and a 4/6 grade precordial systolic murmur. No pulse differences were evidenced among extremities. Mild pitting edema was evidenced in both lower extremities. New York Heart Association functional class was IV.

## MEDICAL HISTORY

The progressive symptoms had started 2 years earlier and yielded a diagnosis of severe aortic stenosis (AS) and chronic heart failure, 1 year before this admis-

## LEARNING OBJECTIVES

- To demonstrate the value of investigating concomitant aortic disease in patients presenting with aortic valve disease, using multimodality imaging
- To recognize the value of multidisciplinary decision making to ensure successful results in treating a patient with complex aortic disease
- To be able to complete a combined transcatheter intervention in patients with co-existing aortic valve and aortic diseases
- To recognize that right carotid access is safe in patients needing a transcatheter aortic valve replacement, with limited access options

From the <sup>a</sup>Center for Cardiovascular Diseases, Meizhou People's Hospital, Huangtang Hospital, Meizhou, China; <sup>b</sup>Guangdong Provincial Engineering and Technology Research Center for Molecular Diagnostics of Cardiovascular Diseases, Meizhou, China; <sup>c</sup>Guangdong Provincial Key Laboratory of Precision Medicine and Clinical Translational Research of Hakka Population, Meizhou, China; <sup>d</sup>Cardialysis, Rotterdam, the Netherlands; and the <sup>e</sup>Cardiology Department, Thoraxcenter, Erasmus University Medical Center, Rotterdam, the Netherlands.

The authors attest they are in compliance with human studies committees and animal welfare regulations of the authors' institutions and Food and Drug Administration guidelines, including patient consent where appropriate. For more information, visit the [Author Center](#).

Manuscript received March 19, 2021; revised manuscript received August 24, 2021, accepted September 2, 2021.

sion. The patient received medical therapy for heart failure and had decided not to undergo surgical or transcatheter correction of AS because of a perceived risk. The patient had no other known comorbidities.

## DIFFERENTIAL DIAGNOSIS

With the existing diagnosis of severe AS, other causes of precordial systolic murmur, such as supra- or subvalvular AS and hypertrophic obstructive cardiomyopathy were ruled out. The co-existence of mitral regurgitation would require further assessment. Moreover, acute coronary syndromes and heart failure decompensation were included in the differential diagnosis.

## INVESTIGATIONS

Echocardiography showed a severely depressed left ventricular ejection fraction (LVEF) (17%) and confirmed severe AS (peak gradient [PG] of 84 mm Hg and mean gradient [MG] of 51 mmHg) accompanied by mild regurgitation. No other significant findings were observed, except for severe pulmonary regurgitation and a discrete pericardial effusion. A chest computed tomography angiogram (CTA) showed coarctation of the distal aortic arch (59% narrowing) and a true aneurysm of the proximal descending aorta (5.1 cm) (Figure 1). Coronary CTA confirmed the absence of severe lesions.

Troponin I was slightly elevated at admission, which was attributed to heart failure. Similarly, B-type natriuretic peptide (BNP) was elevated, 3,231 pg/mL. Hemoglobin and platelets, as well as white blood cells, were within normal limits. Renal function was normal, with creatinine of 105  $\mu$ mol/L.

After admission, the patient's condition was stabilized with furosemide, spironolactone, dopamine 3  $\mu$ g/kg/min, and metoprolol 6.25 mg twice daily. The patient was deemed inoperable by the heart team because of a high risk of mortality (Society of Thoracic Surgeons predicted risk of mortality, 8.1%; EuroScore II predicted risk of mortality, 13.4%).

After consultation with the patient and the family, it was decided to perform a single interventional procedure, including transcatheter aortic valve replacement (TAVR), thoracic endovascular aortic repair (TEVAR), and percutaneous balloon angioplasty of aortic coarctation (PBAAC). A pre-TAVR CTA showed severely calcified leaflets and an aortic annulus with an area of 545 mm<sup>2</sup>, indicating that a 27-mm prosthetic aortic valve (Vitaflow Aortic Valve System, Shanghai MicroPort Medical Group) would be

suitable. Access was considered appropriate through the right carotid artery, which was straight, wide (>8 mm), and with no obvious plaque. Transsubclavian access might have been an alternative approach (1).

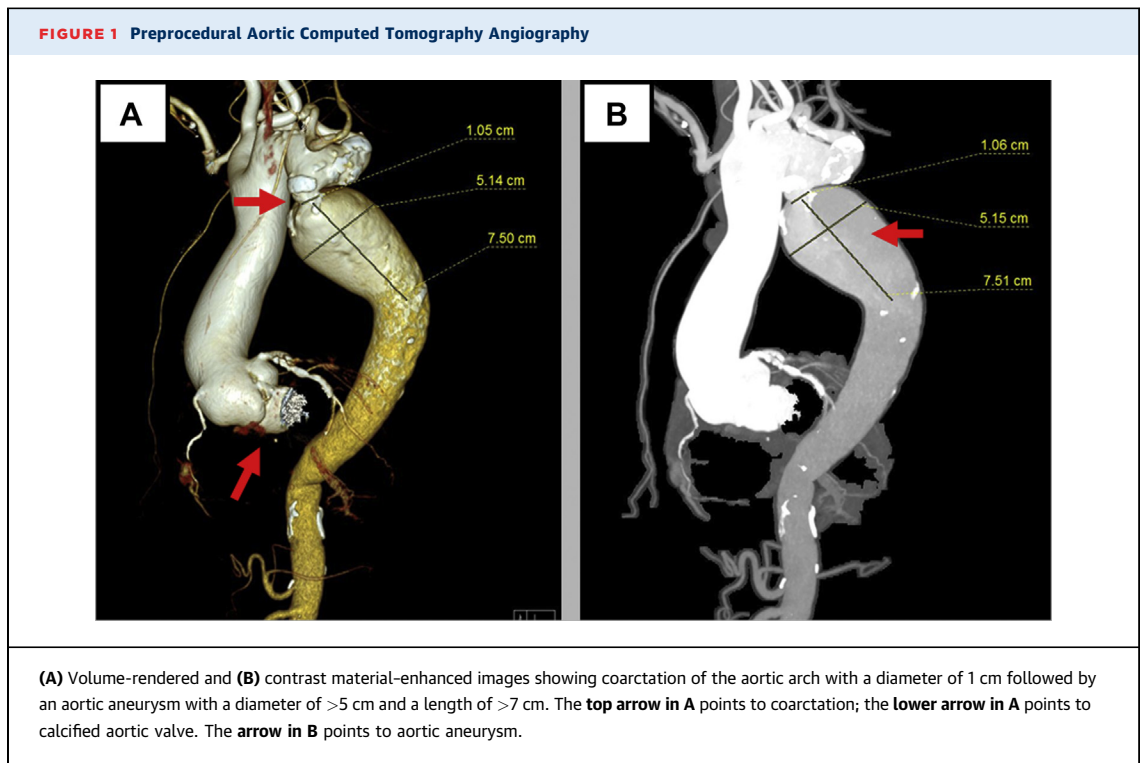
## MANAGEMENT

A combined intervention was performed in the catheterization laboratory (Figure 2), starting with TAVR. The patient underwent general anesthesia, and the procedure was guided under fluoroscopy and transesophageal echocardiography. Femoral arterial and venous access were obtained. A temporary pacemaker electrode was implanted in the right ventricle, which was set at 60 beats/min. In addition, and because trans-femoral TAVR was impossible, access was obtained through a 6-F sheath inserted at the right common carotid artery posteriorly replaced by a 20-F sheath. A purse string suture was used on the carotid incision, and there was a continuous blood leakage around the vascular sheath; hence, TAVR had to be performed as fast as possible. An AL1 guiding catheter was inserted into the left ventricle and exchanged with a 6-F pigtail catheter, and then exchanged with a Lunderquist wire. A pigtail catheter was inserted through a sheath in the left brachial artery into the aortic root. Under temporary pacing (180 beats/min), the aortic valve was predilated with a 24-F balloon catheter. Angiography showed mild aortic regurgitation. Next, under angiographic guidance, a 27-mm prosthetic aortic valve was successfully implanted with pacing at 150 beats/min, leading to a decrease in the gradient of invasive systolic pressure from 101 mmHg to 16 mmHg. No paravalvular regurgitation was evidenced. This concluded the TAVR procedure, and the surgeon sutured the carotid artery.

The TEVAR and PBAAC procedures were performed through femoral access. A loach guidewire was placed at the root of the ascending aorta. A 24-F femoral artery sheath was introduced to the left femoral artery, and the orbital guidewire was placed into the root of the ascending aorta through the right femoral artery. Then, the pigtail catheter was inserted into the ascending aorta through the right femoral artery, and the vertebral artery catheter was placed into the location of the aortic aneurysm in the ascending aorta through the left brachial artery. A 32- × 200-mm covered stent was inserted through the left femoral artery to the aortic arch and implanted with angiography guidance below the opening of the left carotid artery. Postimplantation angiography

## ABBREVIATIONS AND ACRONYMS

<b>AS</b>	= aortic stenosis
<b>BNP</b>	= B-type natriuretic peptide
<b>CTA</b>	= computed tomography angiography
<b>ICU</b>	= intensive care unit
<b>LVEF</b>	= left ventricular ejection fraction
<b>MG</b>	= mean gradient
<b>PBAAC</b>	= percutaneous balloon angioplasty of aortic coarctation
<b>PG</b>	= peak gradient
<b>TAVR</b>	= transcatheter aortic valve replacement
<b>TEVAR</b>	= thoracic endovascular aortic repair



showed underexpansion of the stent and discrete leakage within the aneurysm of the aortic arch and the distal part of the stent. Subsequently, a 32- × 120-mm aortic covered stent was successfully delivered to the descending aorta (partially overlapping with the first stent), and the stent delivery system was withdrawn. A 28- × 40-mm balloon was next placed into the aortic arch and dilated, and a spring coil was inserted through the left brachial artery and delivered through the vertebral artery catheter to embolize the aortic arch aneurysm, addressing the remaining leakage. The left common carotid artery was not affected, and the left subclavian artery was unobstructed. The 8-hour operation was successful, and the patient was transferred to the intensive care unit (ICU) for further management.

The patient remained in the ICU for 2 days, and his condition continued to improve in the cardiology ward. A 24-hour postintervention echocardiography showed good function of the prosthetic aortic valve with no regurgitation, with a peak aortic gradient of 21 mmHg and a mean gradient of 12 mm Hg. The improvement in LVEF was remarkable, measured at 42%. Likewise, BNP levels dropped progressively, to 1,386 pg/mL 48 hours after intervention, and 807 pg/mL 5 days after intervention. There were no in-hospital complications, and the patient was discharged on day 6 after intervention, with oral diuretic

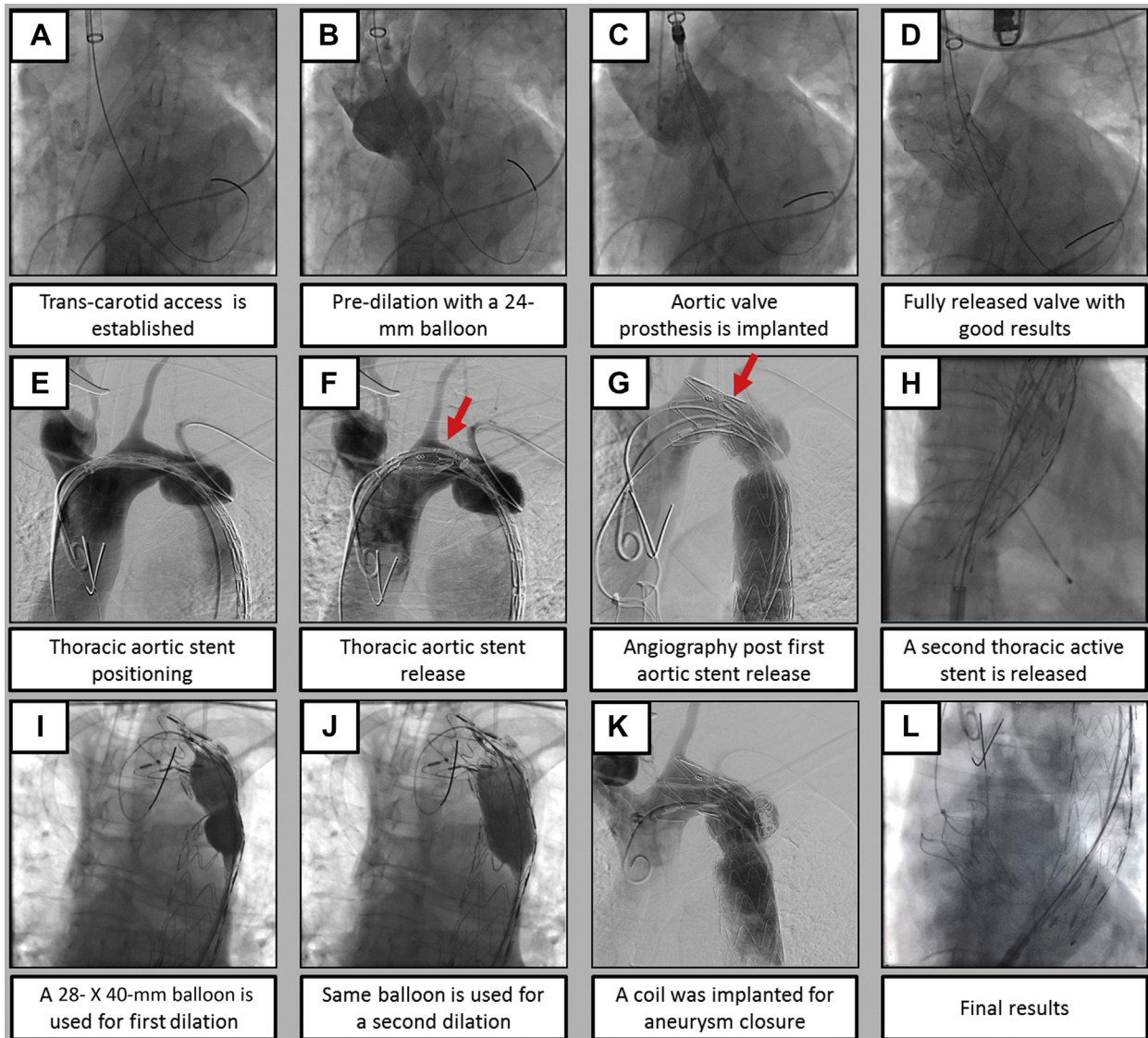
agents and sacubitril valsartan sodium tablets (0.05 g twice daily). Moreover, dual antiplatelet therapy (aspirin 100 mg and clopidogrel 75 mg once daily) was prescribed for 6 months.

## DISCUSSION

Approximately 6% of patients receiving TAVR present with an aortic aneurysm (2). However, coarctation of the aorta is relatively rare. If it is untreated, survival generally does not exceed 50 years. The co-existence of these three conditions is exceptional and is first reported in this document in a 71-year-old patient undergoing a single combined transcatheter intervention. Practice guidelines do not address these uncommon scenarios, and no specific reports were available to guide the decision-making process, but the multidisciplinary heart team favored this approach.

Stepwise procedures have been used in the past, and earlier successful reports of combined intervention were available for a patient undergoing simultaneous treatment of AS and aortic aneurysm, but not the 3 conditions (3). The complexity of risk assessment was increased because it was difficult to predict the hemodynamic impact of TAVR on the other two conditions. Planning a staged procedure may have required additional time for recovery with the existing risk of aneurysm progression.

**FIGURE 2** Combined Triple Procedure



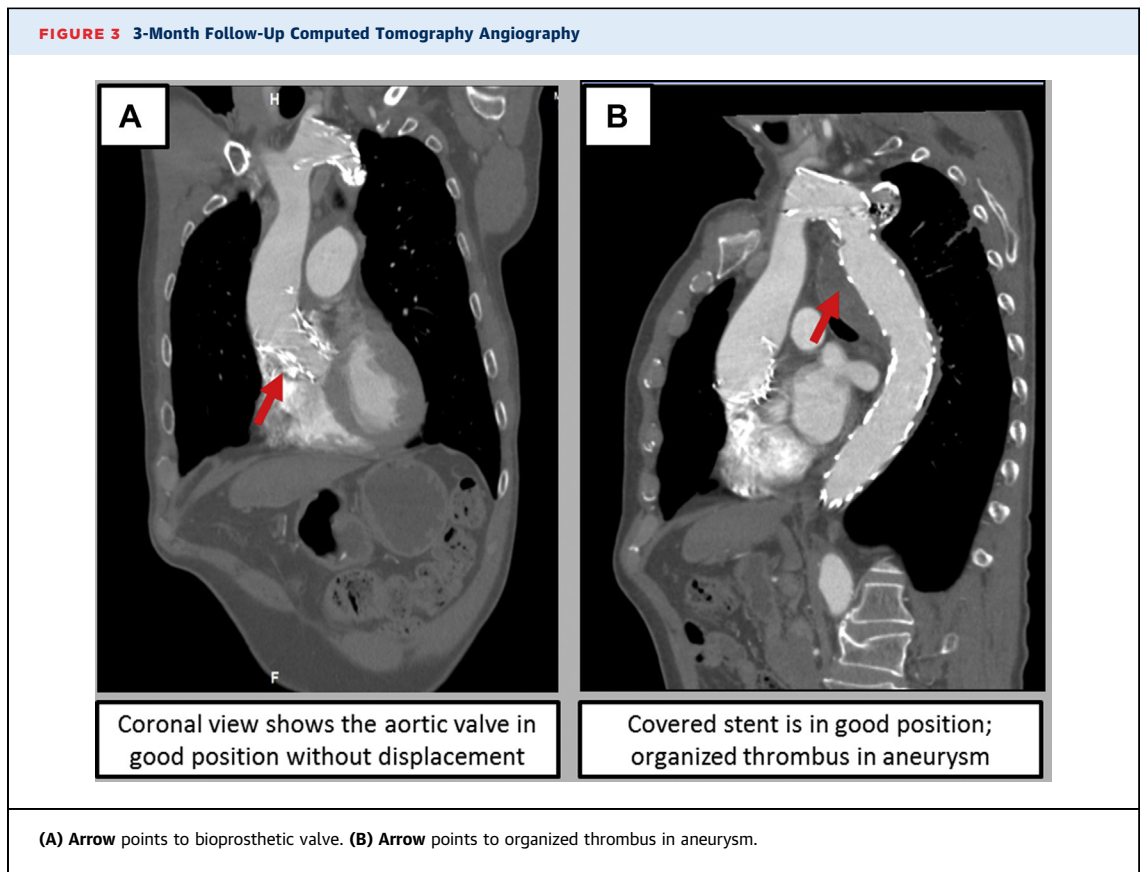
The first covered stent was initially positioned at the opening of the left carotid artery, but it then moved distally (red arrows).

The careful formulation of the surgical strategy and operation plan were key determinants of the procedure's success. The following aspects were considered: 1) LVEF was only 17%, which greatly increased the surgical risk of aortic disease treatment, leaving the interventional approach as the only option; 2) treatment of the coarctation and aneurysm had to be simultaneous because the correction of the AS would inevitably lead to faster blood flow through the coarctation and aneurysm, increasing the risk of aneurysm rupture (4); and 3) TAVR had to be performed through carotid access and first, being

the most serious condition of the patient and the possibility of circulatory collapse if not treated first.

#### FOLLOW-UP

At the 1-month follow-up visit, the patient had no chest tightness, shortness of breath, edema, or post-intervention complications. His blood pressure was within normal ranges (108-126/67-80 mm Hg), and his heart rate was 72 to 94 beats/min. Echocardiography confirmed good function of the aortic valve, with mild central aortic insufficiency; LVEF had further



improved to 53%. The descending aorta flow rate was consistent with  $V_{max} = 58$  cm/s, after the endovascular exclusion of the thoracic aortic aneurysm. At the 3-month follow-up visit, CTA of the aorta (Figure 3) showed that the position of the aortic valve stent was adequate; the diameter of the original coarctation of aorta was approximately 26 mm. Thrombus organization could be seen in the lumen of the true aortic aneurysm.

### CONCLUSIONS

We report a successful combined transcatheter intervention in a 71-year-old patient with coexistence of severe AS, aortic aneurysm, and aortic coarctation. A careful evaluation by a

multidisciplinary heart team allowed the design of a one-stop procedure, solving all conditions with state-of-the-art technological and clinical developments.

### FUNDING SUPPORT AND AUTHOR DISCLOSURES

Dr Spitzer has institutional contracts with MicroPort Medical, Shanghai, China. All other authors have reported that they have no relationships relevant to the contents of this paper to disclose.

**ADDRESS FOR CORRESPONDENCE:** Dr Zhixiong Zhong, Center for Cardiovascular Diseases, Meizhou People's Hospital, Huangtang Hospital, No. 63 Huangtang Road, Meijiang District, Meizhou 514031, China. E-mail: [zhongzhixiong@mzrmyy.com](mailto:zhongzhixiong@mzrmyy.com). Twitter: [@Dr.Zhong](https://twitter.com/Dr.Zhong).

### REFERENCES

1. Beurtheret S, Karam N, Resseguier N, et al. Femoral versus non-femoral peripheral access for transcatheter aortic valve replacement. *J Am Coll Cardiol*. 2019;74:2728-2739.
2. Kurra V, Schoenhagen P, Roselli EE, et al. Prevalence of significant peripheral artery disease in patients evaluated for percutaneous aortic valve insertion: preprocedural assessment with multidetector computed tomography. *J Thorac Cardiovasc Surg*. 2009;137:1258-1264.
3. Koutsias S, Karaolanis GI, Papafaklis MI, et al. Simultaneous transcatheter aortic valve implantation and infrarenal aortic aneurysm repair for severe aortic stenosis and abdominal aortic aneurysm: report of 2 cases and literature review. *Vasc Endovasc Surg*. 2020;54:544-548.
4. Regeer MV, Versteegh MI, Klautz RJ, et al. Aortic valve repair versus replacement for aortic regurgitation: effects on left ventricle remodeling. *J Card Surg*. 2015;30:13-19.

**KEY WORDS** aortic coarctation, aortic valve, shortness of breath, systolic heart failure