



# Hemophagocytic Lymphohistiocytosis in Activated PI3K Delta Syndrome: an Illustrative Case Report

Zijun Zhou<sup>1,2</sup> · Timo Zondag<sup>2</sup> · Maud Hermans<sup>2</sup> · P. Martin van Hagen<sup>1,2</sup> · Jan A. M. van Laar<sup>1,2</sup>

Received: 19 April 2021 / Accepted: 25 May 2021 / Published online: 11 June 2021  
© The Author(s), under exclusive licence to Springer Science+Business Media, LLC, part of Springer Nature 2021

To the Editor,

Hemophagocytic lymphohistiocytosis (HLH) is a life-threatening condition characterized by a dysregulated immune system. HLH is driven by impaired antigen clearance that leads to uncontrolled immune activation [1]. In primary HLH, a genetic mutation impairs the cytotoxic function of natural killer (NK) cells and cytotoxic T-cells, resulting in persistent antigen presentation and dysregulation of histiocyte activation. In secondary HLH (sHLH), unknown or non-genetic triggers result in a state of hyperinflammation. The most common triggers associated with HLH include infections, such as Epstein–Barr virus (EBV), hematological malignancies, and autoimmune diseases.

Activated PI3K delta syndrome (APDS) is a primary immunodeficiency (PID) caused by a gain-of-function mutation in *PIK3CD*. As a result of the of the PI3K/AKT/mTOR pathway over-activation, T and B cell senescence is induced [2–4]. APDS is characterized by recurrent sinopulmonary infections, non-malignant lymphoproliferation, (persistent) viral infections, autoimmunity, and increased risk of lymphomas [5].

In APDS patients, HLH might be expected. However, it is only scarcely reported. Here, we describe a young adult with APDS who developed persistent EBV-related HLH. We subsequently discuss the association between HLH and APDS.

## Case Report

A 19-year-old man of Indian descent was referred for the evaluation of chronic active EBV disease. The patient's medical history revealed congenital stenosis of the left bronchus, recurrent sinopulmonary infections, and autism spectrum disorder with an IQ of 80–86. EBV seroconversion was identified at 7 years of age when the patient presented idiopathic abdominal lymphadenopathy. Furthermore, a previous laboratory examination revealed IgA deficiency and low IgG2 and IgG4 levels without an overarching diagnosis. Four months before presentation, the patient developed fatigue, fever, night sweats, hepatosplenomegaly, anemia, hepatitis, weight loss of 10 kg, and lymphadenopathy (Fig. 1). Serum EBV copy numbers were repeatedly > 1500/mL. Histology of the three lymph nodes did not reveal any evidence of malignant lymphoma, but rather a markedly positive EBV-encoded RNA (EBER). Chronically active EBV was diagnosed, and rituximab therapy of 500 mg weekly during 4 weeks was initiated. In the workup of PID, whole exome sequencing (confirmed by Sanger sequencing) revealed a heterozygous c.3074A > C, p.Glu1025Gly mutation in the *PIK3CD* gene (NM\_005026.3), which is associated with APDS (Fig. 2) [6]. Neither parent carried this mutation, suggesting a de novo origin.

A stable condition without any additional immunosuppressive drugs was achieved for 3 months after which he developed high spiking fever, pneumonia, progressive lymphadenopathy, severe unexplained cardiomyopathy with progressive anemia, thrombocytopenia, and hyperferritinemia (Table 1). Malignant lymphoma was excluded and hemophagocytosis was detected in the bone marrow (Fig. 3A, B). The patient therefore fulfilled six out of eight diagnostic HLH-04 criteria (Table 2) [7]. His clinical status quickly deteriorated, and he developed acute respiratory distress syndrome and multiple organ failure. Salvage therapy was initiated with high-dose steroids, sirolimus, and intravenous immunoglobulin. PI3K delta inhibitors were withheld

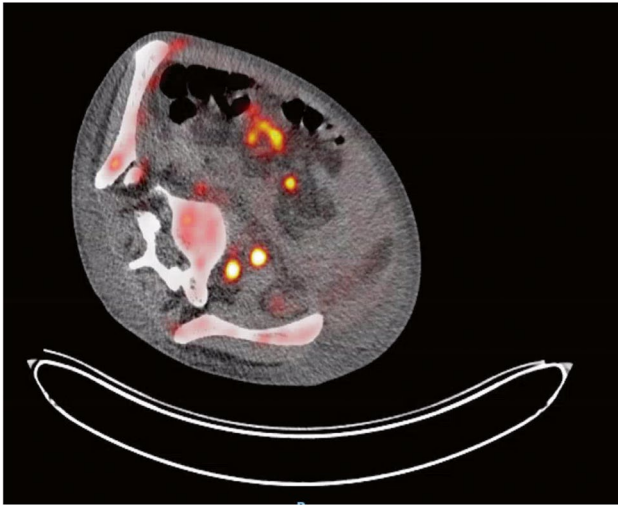
---

Zijun Zhou and Timo Zondag contributed equally to the manuscript.

✉ Jan A. M. van Laar  
j.vanlaar@erasmumc.nl

<sup>1</sup> Department of Immunology, Laboratory Medical Immunology, Erasmus University Medical Centre, Rotterdam, The Netherlands

<sup>2</sup> Department of Internal Medicine, Section Clinical Immunology, Erasmus University Medical Center, Doctor Molewaterplein 40, 3015 GD Rotterdam, The Netherlands



**Fig. 1** High glucose metabolism in  $^{18}\text{F}$ -fluorodeoxyglucose positron emission tomography positive lymph nodes

due to heart and respiratory failure. Etoposide was withheld due to leucopenia and severe sepsis with systemic infection (hospital acquired pneumonia with *H. influenza*, not responding to treatment). Within 1 month, the patient died from cardiac failure with refractory pulmonary edema.

## HLH in APDS

APDS is caused by a heterozygous gain-of-function mutation in *PIK3CD*. This mutation is known to activate leucocyte development, pushing immune cells towards differentiation and exhaustion by raising  $\text{CD8}^+\text{CD57}^+$  and  $\text{CD8}^+$  effector memory cells [2, 3]. This is indicative of a defective immune response that is incapable of effective elimination of pathogens. Persisting antigen presentation can then evoke HLH. Especially in the case of persistent EBV, a virus that is already able to trigger HLH, APDS patients are theoretically more prone to develop hyperinflammation and thus HLH [8]. Although chronically active EBV and EBV-associated lymphomas are common in APDS,

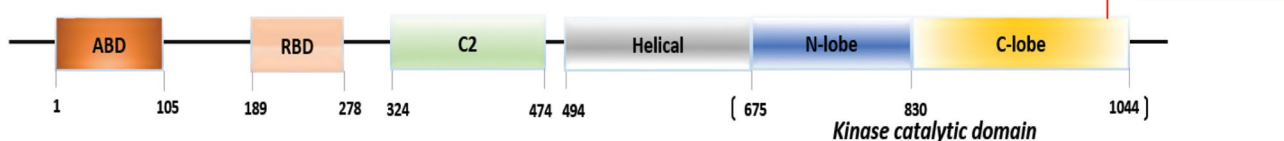
**Table 1** Laboratory investigations

| Laboratory investigations              | At admission | At time of clinical deterioration | Reference |
|--|--------------|-----------------------------------|-----------|
| Hemoglobin (g/dL)                      | 6.28         | 5.8                               | 13.9–16.9 |
| Leukocytes ( $\times 10^9/\text{L}$ )  | 4.4          | 5.0                               | 3.5–10    |
| Neutrophils ( $\times 10^9/\text{L}$ ) | 2.5          | 3.84                              | 1.4–8.0   |
| Platelets ( $\times 10^9/\text{L}$ )   | 177          | 24                                | 150–370   |
| CRP (mg/L)                             | 190          | 321                               | < 10      |
| ASAT (U/L)                             | 40           | 312                               | < 35      |
| ALAT (U/L)                             | 19           | 46                                | < 45      |
| Lactate dehydrogenase (U/L)            | 263          | 798                               | < 248     |
| Gamma-GT (U/L)                         | 230          | 391                               | < 55      |
| Alkaline phosphatase (U/L)             | 918          | 1301                              | < 115     |
| Total bilirubin ( $\mu\text{mol/L}$ )  | 26           | 66                                | < 17      |
| NT-pro-BNP (pmol/L)                    |              | 1028                              | < 15      |
| IgA (g/L)                              | 0.76         |                                   | 0.76–3.9  |
| IgG (g/L)                              | 5.70         |                                   | 7.0–16.0  |
| IgM (g/L)                              | 1.24         |                                   | 0.45–2.30 |
| IgG1 (g/L)                             | 4.67         |                                   | 4.9–11.4  |
| IgG2 (g/L)                             | 0.62         |                                   | 1.5–6.4   |
| IgG3 (g/L)                             | 0.32         |                                   | 0.2–1.1   |
| IgG4 (g/L)                             | < 0.08       |                                   | 0.08–1.4  |
| Ferritin ( $\mu\text{g/L}$ )           | 1985         | 10,364                            | 30–240    |
| sIL2R (pg/mL)                          | > 110,000    | > 110,000                         | < 2500    |
| Triglycerides (mmol/L)                 | 2.41         | 6.58                              | < 2       |
| EBV DNA (IU/mL)                        | 2.54E4/P     | 1.17E6/P                          |           |

Abbreviations: *CRP* C-reactive protein, *ASAT* aspartate aminotransferase, *ALAT* alanine aminotransferase, *Gamma-GT* gamma-glutamyltransferase, *NT-pro-BNP* N-terminal prohormone of brain natriuretic peptide, *Ig* immunoglobulin, *sIL2R* soluble interleukin-2 receptor

HLH has only been reported in two APDS patients, who are summarized in Table 3 [9, 10]. Both patients were children at the time of APDS diagnosis, which suggests that genetic diagnosis is more often considered in pediatric HLH. Because a high index of suspicion is necessary to identify both HLH and APDS, underdiagnosis is likely.

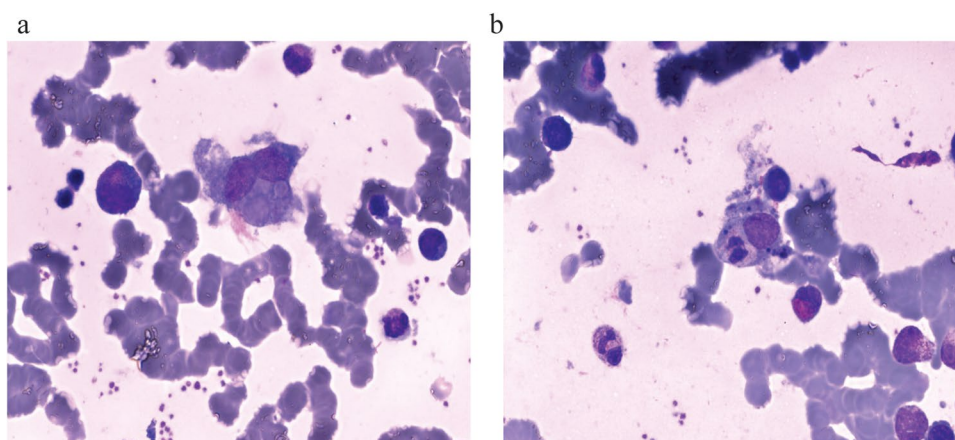
P110 $\delta$  PIK3CD gene



**Fig. 2** Heterozygous c.3074A>C, p.Glu1025Gly mutation in *PIK3CD* identified in the patient. Linear representation of P110 $\delta$ (PIK3CD) protein domains. The mutation identified in the

patient is shown in red. Abbreviations: ABD, adaptor-binding domain; RBD, Ras-binding domain; C2, putative membrane-binding domain

**Fig. 3** Bone marrow biopsies from the patient with mutated *PIK3CD*. **A** Hematoxylin and eosin (H&E) staining shows the hemophagocytosis of erythroid cells by a macrophage. **B** May–Grünwald–Giemsa staining shows hemophagocytosis of a polynuclear granulocyte by a macrophage



**Table 2** HLH criteria

| HLH-04 criteria [7]   | Patient finding                   |
|---|-----------------------------------|
| Fever   | Present                           |
| Splenomegaly  | Present                           |
| Cytopenias (affecting $\geq 2$ of 3 lineages in the peripheral blood) | Present                           |
| Hemoglobin $< 90$ g/L   | 58 g/L                            |
| Platelets $< 100 \times 10^9/L$                                       | $24 \times 10^9/L$                |
| Neutrophils $< 1.0 \times 10^9/L$                                     | $3.84 \times 10^9/L$              |
| Hypertriglyceridemia and/or hypofibrinogenaemia                       | Not present                       |
| Fasting triglycerides $\geq 3.0$ mmol/L                               | 6.58 mmol/L                       |
| Fibrinogen $\leq 1.5$ g/L   | Not done                          |
| Hemophagocytosis in bone marrow or spleen or lymph nodes              | Present                           |
| Low or absent NK-cell activity  | Not done                          |
| Ferritin $\geq 500$ $\mu\text{g/L}$                                   | Present (10,364 $\mu\text{g/L}$ ) |
| Soluble IL-2 receptor $\geq 2400$ U/mL                                | Present ( $> 110,000$ pg/mL)      |

**Table 3** Previously published cases on HLH in APDS patients

| Characteristic                                       | Patient 1 [9]  | Patient 2 [10]   |
|--|--|--|
| Sex  | Male   | Male   |
| Age at the time of APDS diagnosis                    | 12 years   | 2 years  |
| Age at the time of HLH onset                         | 12 years   | 5 months   |
| Trigger of HLH                                       | Idiopathic   | Hodgkin lymphoma   |
| Presentation   | Diffuse lymphadenopathy, hepatosplenomegaly, arthritis, rash | Diffuse lymphadenopathy, hepatosplenomegaly, autoimmune hemolytic anemia |
| PIK3D mutation                                       | c.323C > G p.R108L   | c.3061G > A p.E1021K   |
| Concurrent mutation                                  | None noted   | PRF1 p.L236F   |
| Functional NK and T-cell test                        | Normal   | Normal function. Lower (but not deficient) perforin levels in NK cells   |
| White blood cell count ( $\times 10^3/\text{mm}^3$ ) | 6.14 (4.0–10.8)  | 9.08   |
| Neutrophils ( $\times 10^3/\text{mm}^3$ )            | 4.58 (1.5–8.0)   | 2.39   |
| Lymphocytes ( $\times 10^3/\text{mm}^3$ )            | 1.21 (0.9–4.0)   | 4.89   |
| IgG (mg/dL)  | 2119 (700–1600)  | 426 (270–792)  |
| IgA (mg/dL)  | 207 (70–400)   | 47 (5.8–58)  |
| IgM (mg/dL)  | 127 (40–230)   | 258 (18.4–145)   |

This case emphasizes the importance of genetic testing for PID (including HLH genes) in patients with the first episode of HLH, regardless of age. An increasing number of genetic mutations in older patients with HLH have been reported [11]. In particular, a medical history of recurrent infections, autoimmunity, developmental delay, and EBV-related HLH in young adults should indicate PID. Correct genetic diagnosis enables personalized treatment and thereby improving survival. Appropriate treatment of APDS patients developing HLH is a great therapeutic challenge. In our opinion, the mainstay of treatment should be appropriate management of APDS, such as hematopoietic stem cell transplantation or mTOR inhibitors, especially the new promising PI3K inhibitor leniolisib. By doing so, the patient is less susceptible to developing HLH. If HLH arises, an additional trigger (e.g., infectious or malignant) should be sought thoroughly and treated rigorously. In severe cases, HLH-directed therapy could be considered to halt the hyperinflammation. This therapy should consist of corticosteroids, with the addition of etoposide in life threatening cases [12]. This case illustrates that earlier diagnosis of APDS could have resulted in more adequate monitoring and targeted treatment before the occurrence of multi-organ failure.

**Data Availability** Data transparency.

**Code Availability** Not applicable.

## Declarations

**Ethics Approval** To our opinion, this research does not necessitate ethic approval. It concerns a retrospective study in which no data could be traced back to the presented patient. The patient is not subjected to any intervention and no behavior is imposed.

**Consent to Participate** Not applicable.

**Consent for Publication** Not applicable.

**Conflict of Interest** The authors declare no competing interests.

## References

- Jordan MB, Hildeman D, Kappler J, Marrack P. An animal model of hemophagocytic lymphohistiocytosis (HLH): CD8+ T cells and interferon gamma are essential for the disorder. *Blood*. 2004;104:735–43.
- Lucas CL, Kuehn HS, Zhao F, Niemela JE, Deenick EK, Palendira U, Avery DT, Moens L, Cannons JL, Biancalana M, Stoddard J, Ouyang W, Frucht DM, Rao VK, Atkinson TP, Agharahami A, Hussey AA, Folio LR, Olivier KN, Fleisher TA, Pittaluga S, Holland SM, Cohen JI, Oliveira JB, Tangye SG, Schwartzberg PL, Lenardo MJ, Uzel G. Dominant-activating germline mutations in the gene encoding the PI(3)K catalytic subunit p110delta result in T cell senescence and human immunodeficiency. *Nat Immunol*. 2014;15:88–97.
- Wentink MWJ, Mueller YM, Dalm V, Driessen GJ, van Hagen PM, van Montfrans JM, van der Burg M, Katsikis PD. Exhaustion of the CD8(+) T cell compartment in patients with mutations in phosphoinositide 3-kinase delta. *Front Immunol*. 2018;9:446.
- Okkenhaug K, Vanhaesebroeck B. PI3K in lymphocyte development, differentiation and activation. *Nat Rev Immunol*. 2003;3:317–30.
- Coulter TI, Chandra A, Bacon CM, Babar J, Curtis J, Screamon N, Goodlad JR, Farmer G, Steele CL, Leahy TR, Doffinger R, Baxendale H, Bernatoniene J, Edgar JD, Longhurst HJ, Ehl S, Speckmann C, Grimbacher B, Sediva A, Milota T, Faust SN, Williams AP, Hayman G, Kucuk ZY, Hague R, French P, Brooker R, Forsyth P, Herriot R, Cancrini C, Palma P, Ariganello P, Conlon N, Feighery C, Gavin PJ, Jones A, Imai K, Ibrahim MA, Markelj G, Abinun M, Rieux-Laucat F, Latour S, Pellier I, Fischer A, Touzot F, Casanova JL, Durandy A, Burns SO, Savic S, Kumararatne DS, Moshous D, Kracker S, Vanhaesebroeck B, Okkenhaug K, Picard C, Nejentsev S, Condliffe AM, Cant AJ. Clinical spectrum and features of activated phosphoinositide 3-kinase delta syndrome: a large patient cohort study. *J Allergy Clin Immunol*. 2017;139:597–606 e594.
- DulauFlorea AE, Braylan RC, Schafernak KT, Williams KW, Daub J, Goyal RK, Puck JM, Rao VK, Pittaluga S, Holland SM, Uzel G, Calvo KR. Abnormal B-cell maturation in the bone marrow of patients with germline mutations in PIK3CD. *J Allergy Clin Immunol*. 2017;139:1032–1035 e1036.
- Henter JI, Horne A, Arico M, Egeler RM, Filipovich AH, Imashuku S, Ladisch S, McClain K, Webb D, Winiarski J, Janka G. HLH-2004: diagnostic and therapeutic guidelines for hemophagocytic lymphohistiocytosis. *Pediatr Blood Cancer*. 2007;48:124–31.
- Ramos-Casals M, Brito-Zeron P, Lopez-Guillermo A, Khamashta MA, Bosch X. Adult haemophagocytic syndrome. *Lancet*. 2014;383:1503–16.
- G. Tessarin, S. Rossi, M. Baronio, L. Gazzurelli, M. Colpani, A. Benvenuto, F. Zunica, F. Cardinale, B. Martire, L. Brescia, G. Costagliola, L. Luti, G. Casazza, M.C. Menconi, F. Saettini, L. Palumbo, M.F. Girelli, R. Badolato, G. Lanzi, M. Chiarini, D. Moratto, A. Meini, S. Giliani, M.P. Bondioni, A. Plebani, V. Lougaris, Activated phosphoinositide 3-kinase delta syndrome 1: clinical and immunological data from an Italian cohort of patients, *J Clin Med*, 9 (2020)
- Cansever M, Zietara N, Chiang SCC, Ozcan A, Yilmaz E, Karakucukcu M, Rohlf M, Somekh I, Canoz O, Abdulrezzak U, Bryceson Y, Klein C, Unal E, Patiroglu T. A rare case of activated phosphoinositide 3-kinase delta syndrome (APDS) presenting with hemophagocytosis complicated with Hodgkin lymphoma. *J Pediatr Hematol Oncol*. 2020;42:156–9.
- Miao Y, Zhu HY, Qiao C, Xia Y, Kong Y, Zou YX, Miao YQ, Chen X, Cao L, Wu W, Liang JH, Wu JZ, Wang L, Fan L, Xu W, Li JY. Pathogenic gene mutations or variants identified by targeted gene sequencing in adults with hemophagocytic lymphohistiocytosis. *Front Immunol*. 2019;10:395.
- La Rosee P, Horne A, Hines M, von Bahr Greenwood T, Machowicz R, Berliner N, Birndt S, Gil-Herrera J, Girschikofsky M, Jordan MB, Kumar A, van Laar JAM, Lachmann G, Nichols KE, Ramanan AV, Wang Y, Wang Z, Janka G, Henter JI. Recommendations for the management of hemophagocytic lymphohistiocytosis in adults. *Blood*. 2019;133:2465–77.

**Publisher's Note** Springer Nature remains neutral with regard to jurisdictional claims in published maps and institutional affiliations.