

# TREATMENT OF PENETRATING INJURIES



Surgical lessons learned  
in Rotterdam, Cape Town  
and the Combat Zones  
of Afghanistan

Oscar J.F. van Waes





**Treatment of Penetrating Injuries**

*Surgical Lessons learned in Rotterdam, Cape Town and the  
combat zones of Afghanistan*

Oscar Jan Francies van Waes

Printing of this thesis was made possible by:



Ministerie van Defensie



Treatment of Penetrating Injuries - Surgical Lessons Learned in Rotterdam, Cape Town and the Combat Zones of Afghanistan

ISBN: 978-94-6380-210-9

Cover design by: OvW, JH and proefschriftmaken.nl

Layout and printing by: ProefschriftMaken // [www.proefschriftmaken.nl](http://www.proefschriftmaken.nl)

Copyright © 2018 O.J.F. van Waes, The Hague, The Netherlands

All rights reserved. No part of this publication may be reproduced, stored in a retrieval system, or transmitted in any form or by any means, electronic or otherwise without written permission of the author.

A PDF file can be requested via: [o.vanwaes@erasmusmc.nl](mailto:o.vanwaes@erasmusmc.nl).

This document is published under the auspices of the Rotterdam Knife&Gun Club



**Treatment of Penetrating Injuries**

*Surgical Lessons Learned in Rotterdam, Cape Town and the  
Combat Zones of Afghanistan*

**Behandeling van Penetrerend Letsel**

*Chirurgische ervaring vergaard in Rotterdam, Kaapstad en het  
slagveld van Afghanistan*

Proefschrift

ter verkrijging van de graad van doctor aan de  
Erasmus Universiteit Rotterdam  
op gezag van de  
rector magnificus

Prof.dr. R.C.M.E. Engels  
en volgens besluit van het College voor Promoties.  
De openbare verdediging zal plaatsvinden op  
woensdag 30 januari, 2019 om 09:30 uur

door  
Oscar Jan Francies van Waes  
geboren te Tilburg

**Promotiecommissie**

Promotor: Prof.dr. M.H.J. Verhofstad

Overige leden: Prof.dr. M.J.R. Edwards  
Prof.dr. J.M. Hendriks  
Prof.dr. H.W. Tilanus

Co-promotoren: Dr. E.M.M. van Lieshout  
Dr. J. Vermeulen

TO THOSE WHO WANT TO SAVE THE INJURED REGARDLESS

Opgedragen aan: Daisy, Caesar en Quirine

## TABLE OF CONTENTS

<b>Chapter One</b>	General introduction and aim of thesis	9
<hr/>		
<b>PART ONE</b>		
<b>Chapter Two</b>	Penetrating injuries and damage control surgery: considerations and treatment options	21
<hr/>		
<b>PART TWO</b>		
<b>Chapter Three</b>	Penetrating brain injury: a prospective observational study	47
<b>Chapter Four</b>	Management of penetrating neck injuries	65
<b>Chapter Five</b>	Selective non-operative management of penetrating thoracic injury	79
<b>Chapter Six</b>	Immediate thoracotomy for penetrating injuries: ten years' experience at a Dutch Level I trauma center	95
<b>Chapter Seven</b>	Out of hospital thoracotomy for cardiac arrest after penetrating thoracic trauma	117
<b>Chapter Eight</b>	Outcome after introduction of a selective non-operative management protocol for penetrating abdominal injury in a Dutch Level I trauma center	133
<b>Chapter Nine</b>	Management of penetrating injuries of the upper extremities	151



<b>Chapter Ten</b>	Treatment of penetrating trauma of the extremities: ten years' experience at a Dutch Level I trauma center	165
--------------------	--	-----

---

**PART THREE      Penetrating prose**

<b>Chapter Eleven</b>	Afghan "Wild Life"	181
<b>Chapter Twelve</b>	A late pericardial tamponade after penetrating thoracic injury; "Shaved and saved by cold blue steel"	189
<b>Chapter Thirteen</b>	Dynamic Hip Slug (DHS)?	199
<b>Chapter Fourteen</b>	"The Practical Perforator Flap": the sural artery flap for lower extremity soft tissue reconstruction in wounds of war	205
<b>Chapter Fifteen</b>	Treatment of rectal war wounds	217
<b>Chapter Sixteen</b>	"Thunderstruck": Penetrating thoracic injury from lightning strike	229
<b>Chapter Seventeen</b>	Summary and conclusions (English)	237
<b>Chapter Eighteen</b>	Samenvatting en conclusies (Nederlands)	247
<b>Chapter Nineteen</b>	General discussion - Implications and future perspective	259
	Appendices	264
	List of publications	270
	Acknowledgements	274
	PhD portfolio	276
	Curriculum vitae	278



# Chapter One

## INTRODUCTION

All current surgery and the contemporary sub-specialties find their origin on the battlefield. Surgeon involvement in treating the wounded of war and trauma has been documented going back as far as early Egyptian records and possibly even prior to that (1). Evidence for trepanation procedures for traumatic injury to the neurocranium have been found in prehistoric human remains in cave paintings and ancient Greece (2,3). In the sixteenth century Ambroise Paré started to use ligatures, the backbone of surgical hemostasis in surgery, and wound packing during a military campaign against Turin (4).

The present day specialty of trauma surgery most closely reassembles the origin of surgery and will be a predominant field of surgery in the future with trauma advancing into the top ten WHO (World Health Organization) causes of death list within the next 10 to 15 years. Mortality from trauma is responsible for 5.8 million deaths yearly, accounting for 10% of the world's deaths. This number exceeds the number of deaths resulting from malaria, tuberculosis, and HIV/AIDS combined. A third of these fatalities are a result of violence and trauma deaths represent only a fraction of all who are injured (5). Although the largest increase in trauma is found in the lower and middle-income countries, fatalities due to penetrating injuries are also increasing in Western European countries such as the Netherlands (6). These facts and the recent terror-attacks in these countries, which are predominantly causing penetrating injuries, imply that present and future trauma care providers should be familiar with treating patients suffering from penetrating injury (7). Although the percentage of severely injured patients due to penetrating trauma in a European trauma registry, such as the DGU® registry (8), is only around 5% these patients can be undertriaged pre-hospitally and are also renowned self-referrals and as such can and will present to medical facilities possessing only rudimental skills in advanced trauma care (9). In comparison to oncology, vascular disease and transplantation medicine there are hardly any trauma patient support groups dedicated to championing and protecting the rights and needs of these patients. Let alone that there is a special interest in trauma patients suffering from penetrating

injuries. This, more or less, outcast position of these patients is as such reflected by the minimal amount of research, which is done in The Netherlands, concerning this topic. The lack of public and private research funds for trauma in general is an important contributing factor.

These are all arguments to raise interest for treating patients with penetrating injuries in European trauma care systems.

## **AIM OF THIS THESIS**

The aim of this thesis is to offer trauma care providers treatment strategies for patients suffering from penetrating injury. In **part one** and **part two: *penetrating injury management***, damage control surgery (DCS) considerations for penetrating injuries and treatment options are presented. Followed by types of penetrating injuries to specific body regions, which are discussed from "head to toe", based on retro- and prospective studies conducted in Rotterdam, the Netherlands and Cape Town, South Africa. In **part three: *penetrating prose***; lessons learned from a series of cases with particular penetrating injuries experienced in Rotterdam, Cape Town and the combat zones in Afghanistan are discussed.

Whereas in blunt trauma the trauma mechanism and injury pattern usually predicts the physiological state of the patient, seemingly minor penetrating injury can result in a rapidly deteriorating patient without warning. These patients, when in extremis, do not have the physiological "reserve" to undergo a definitive treatment and are in need of DCS. In the first operation of this staged surgery bleeding and contamination are controlled. Following resuscitation on the intensive care unit, the patients are brought back to the operating room for definitive reconstruction once acidosis, hypothermia and coagulopathy have been corrected (10).

**PART ONE, chapter two** discusses general considerations and body region specific treatment options for patients suffering from penetrating injury who are in need of DCS.

**PART TWO** discusses both selective non-operative management (SNOM) and operative treatment for penetrating injuries from "head to toe". The conservative treatment of penetrating injuries, such as penetrating injury to the abdomen, in selected patients with careful observation and serial reassessments is accepted in high volume trauma centers for penetrating injury in the USA and South Africa (11-12). In low volume penetrating injury trauma centers in Europe, SNOM for penetrating injury is still debatable especially when proposed for gunshot wounds (13-17). In **chapter three** penetrating brain injury (PBI) is discussed using the results of a prospective study. In contrast to blunt traumatic brain injury there is no consensus for treatment of this injury, this is in part due to the fact that the mechanism of brain injury by stab wounds might not need the same approach as gunshot injuries. In a prospective study the outcome of both PBI from gunshot and stab wounds in a civilian population is evaluated and a treatment algorithm is proposed.

Penetrating injuries are rare in Western Europe; penetrating neck injury (PNI) is even rarer and thus makes it impossible for surgeons in these countries to gain adequate management experience. This results in routine neck explorations for PNI to prevent rapid hemodynamic or airway deterioration, with a high rate of non-therapeutic explorations and the risk of iatrogenic injury (18-19). In **chapter four** the feasibility of SNOM for penetrating neck injuries was evaluated prospectively in a high-volume center for penetrating injuries. In the same center and again in a prospective cohort study the success rate and the survival of SNOM using protocolled management strategies for penetrating thoracic injury (PTI) were analyzed and discussed in **chapter five**. In **chapter six** the outcome of all immediate thoracotomies for PTI, over a period of ten years, in a Dutch trauma center was compared to high volume centers for penetrating injury.

As in all trauma surgery time is of the essence and this particularly applies to patients in need of a thoracotomy following PTI. Hence the Helicopter Emergency Medical Service (HEMS) of Rotterdam (Life Liner Two) has introduced the out of hospital thoracotomy for cardiac arrest after PTI in accordance to the London HEMS. In **chapter seven** the outcome of all out of

hospital thoracotomies for PTI performed in a time span of five years was evaluated.

SNOM for penetrating abdominal injury (PAI) has been accepted for years as a safe treatment strategy in high volume trauma center in the United States of America and South Africa, which will reduce the length of stay and the rate of non-therapeutic laparotomies (12-13). Although technically a low volume center for penetrating injuries a SNOM for PAI protocol was introduced in the ErasmusMC Trauma Center.

The feasibility of SNOM for PAI and to assess whether or not this protocol would improve the outcome was appraised by a retrospective study described in **chapter eight**. The success of SNOM for penetrating trauma of the extremities was evaluated prospectively for the upper extremities as described in **chapter nine** and for both upper and lower extremities in a retrospective study in **chapter ten**.

In **part three: penetrating prose, chapter eleven** present pediatric PAI case in Afghanistan caused by shrapnel complicated by an "ascariasis ileus". A rare case of late pericardial tamponade following penetrating chest injury is presented in **chapter twelve**. In **chapter thirteen** a bullet protruding into the hip joint after following "the path of a dynamic hip screw" is presented. **Chapter fourteen** describes the feasibility for a non-plastic surgeon to provide soft tissue reconstruction using a sural artery perforator flap for wounds of war to the lower extremity. Treatment of penetrating rectal injury can present a challenge for which there is no uniformly agreed upon advice. **Chapter fifteen** describes three cases of penetrating rectal injury, treated in a deployed combat environment, and outlines the management strategies successfully employed. **Chapter sixteen** describes the improvised explosive device (IED) like-penetrating injury to the chest due to lightning strike, which until now has not been reported in (kerauno)medicine.

In **chapter seventeen** the general advice for damage control options for penetrating injuries, main conclusions of the studies and the lessons learned for the case series are summarized.

**Chapter eighteen** is a Dutch translation of Chapter seventeen. In **chapter nineteen** a general discussion of the main conclusions and lessons learned on the treatment of patients suffering from penetrating injury is provided, including future perspectives.



## REFERENCES

1. W. J. Bishop. The early history of Surgery. Hale, London, 1960
2. A. Agelarakis. The Shanidar cave Proto-Neolithic human population: Aspects of demography and paleopathology. Hum. Evol. (1993) 8: 235.
3. A. Agelarakis, "Early Evidence of Cranial Surgical Intervention in Abdera, Greece, A Nexus to *On Head Wounds of the Hippocratic Corpus*". Mediterranean Archaeology & Archaeometry, Vol.6, No.1, 5-18, 2006
4. Njus N. Gunshot wounds - Historical perspective. IOJ 1989;5;87-91
5. [http://apps.who.int/iris/bitstream/10665/44288/1/9789241599375\\_eng.pdf](http://apps.who.int/iris/bitstream/10665/44288/1/9789241599375_eng.pdf)
6. Bruinsma MY, Moors JA. Illegale vuurwapens. Gebruik, bezit en handel in Nederland 2001-2003, IV A beleidsonderzoek en advies.
7. Khorram-Manesh A. Europe on Fire; Medical management of terror attacks - New era and new considerations. Bull Emerg Trauma 2016;4:183-85.
8. [http://www.traumaregister-dgu.de/fileadmin/user\\_upload/traumaregister-dgu.de/docs/Downloads/TR-DGU\\_Annual\\_Report\\_2016.pdf](http://www.traumaregister-dgu.de/fileadmin/user_upload/traumaregister-dgu.de/docs/Downloads/TR-DGU_Annual_Report_2016.pdf)
9. Lale A, Krajewski A, Friedman LS. Undertriage of firearm-related injuries in a major metropolitan area. JAMA Surg. 2017;5:467-74
10. Goettler CE, Giannoudis PV, Rotondo MF. The concept of damage control. Damage control management in the polytrauma patient 2017;2:18-25
11. Zafar SN, Rushing A, Haut ER, Kisat MT, Villeggs CV, Chi A, Stevens K, Efron DT, Zafar H, Haider AH. Outcome of selective non-operative management of penetrating abdominal injuries of the North American National Trauma Database. Br J Surg 2011;99(Suppl 1):155-65
12. Navsaria PH, Berli JU, Edu S, Nicol AJ. Non-operative management of abdominal stab wounds - analysis of 186 patients. SAJS 2007;45:128-32
13. Hoffmann C, Goudard Y, Falzone E, Leclerc T, Planchet M, Cazes N, Pons F, Lenoir B, Debien B. Management of penetrating abdominal trauma: What we need to know? Ann Fr Anesth Reanim 2013;32:104-111.
14. Casali M, Di Salomone S, Tugnoli G, Biscardi A, Villani S, Cancellieri F, Ciaroni V, Giordani A, Gordini G, Baldoni F. Penetrating abdominal trauma: 20 years experience in a Western European Trauma Center. Ann Ital Chir 2008;79:399-407.
15. Goin G, Massalou D, Bege T, Contargyris C, Avaro JP, Pauleau G, Balandraud P. Feasibility of selective non-operative management for penetrating abdominal trauma in France. J Visc Surg 2017;154(3):167-174
16. Jansen JO, Inaba K, Rizoli SB, Boffard KD, Demetriades D. Selective non-operative management of penetrating abdominal injury in Great Britain and Ireland: Survey of practice. Injury 2012;43:1799-1804

17. Van Brussel M, van Hee R. Abdominal stab wounds: a five-year patient review. *EJEM* 2001;8:83-88
18. Demetriades D, Asensio JA, Velmahos G, Thal E. Complex problems in penetrating neck trauma. *Surg Clin North Am* 1996;76:661-83
19. Apffelstaedt JP, Müller R. Results of mandatory exploration for penetrating neck trauma. *World J Surg* 1994;18:917-19





# **PART ONE**

*"He who is not courageous enough  
to take risks will accomplish  
nothing in life"*

*Muhammad Ali*



# Chapter Two

---

van Waes OJF, Verhofstad MHJ (2017) Penetrating Injuries and Damage Control Surgery: Considerations and Treatment Options.

In: Pape HC., Peitzman A., Rotondo M., Giannoudis P. (eds) Damage Control Management in the Polytrauma Patient. Springer, Cham

## INTRODUCTION

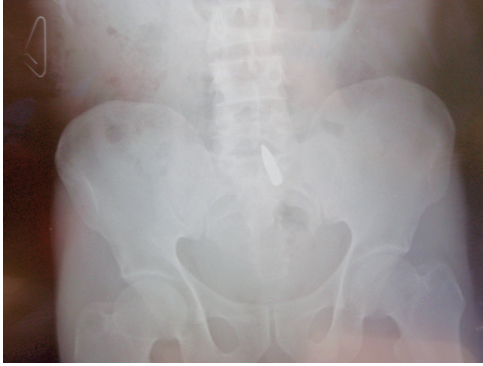For most trauma care providers, patients in need of DCS due to penetrating injury are still a rarity. This certainly accounts for the bigger part of Western Europe (1-4). There are however, some indications that the number of patients suffering from PI is slightly rising (5-7), if not for the least under victims of terrorist attacks (8-9). Another argument to elaborate on this specific trauma mechanism is that these patients are known self-referrals who can present themselves at any emergency department of even the smaller peripheral hospitals with a seemingly minor injury rapidly deteriorating into a resuscitative setting. Hence the authors will present in this chapter general considerations and body region specific treatment options for patients suffering from PI and who are in need of DCS.

### **General considerations with regard to penetrating injuries and Damage Control Management**

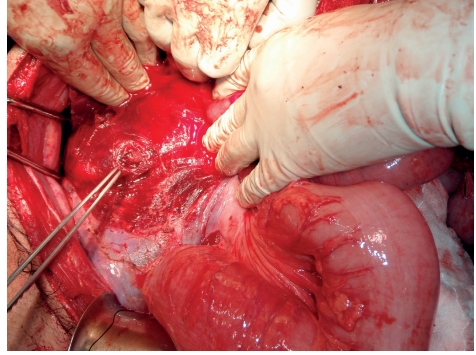
Trauma mechanisms for penetrating injury (PI) are classically described as being either high or low velocity injuries. Stab injuries with knives or sharpened object were recognized as low velocity PI. As for gunshot wounds a differentiation was proposed based on the muzzle velocity of the projectile. A more sensible discrimination can however be made by the amount of energy the projectile transfers to the body (10). So it is possible that for example an AK-47 bullet, with a muzzle velocity of 1100 meters per second, will hit a victim placed several hundred meters away from the assailant only with enough energy to penetrate the skin and subcutaneous tissue. This gunshot wound (GSW) can then be considered a low energy transfer injury (LET), similar to a small caliber pistol injury. However, a close range pistol GSW can reveal a high energy transfer (HET) concomitant injury such as devitalization seen by the temporary cavitation caused by the shockwave of the passing projectile (Figure 1). Though notably inconclusive ("minding his own business when suddenly attacked by strangers"), a history of a patient suffering from PI, might render information whether he might suffer from HET or LET. This information could, for example, support the surgeon's decision to perform staged surgery for injuries to the gastrointestinal tract to assess the vitality before performing



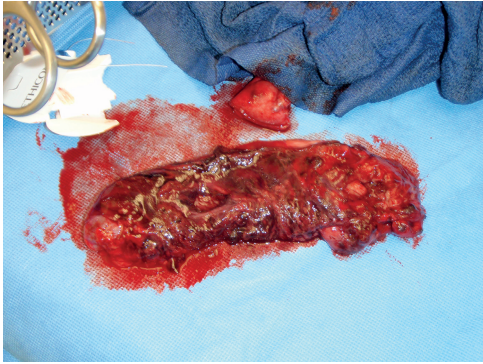
a



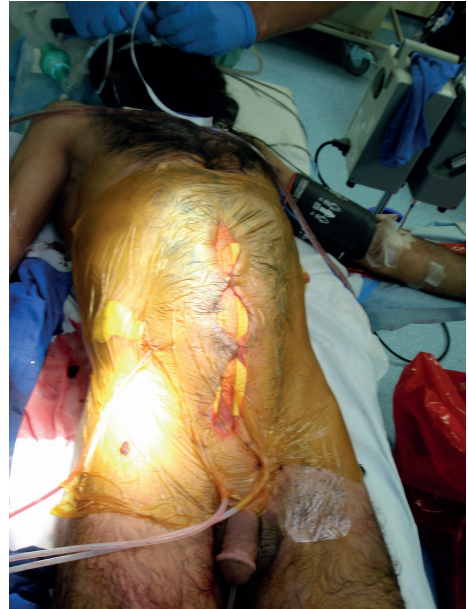b



c

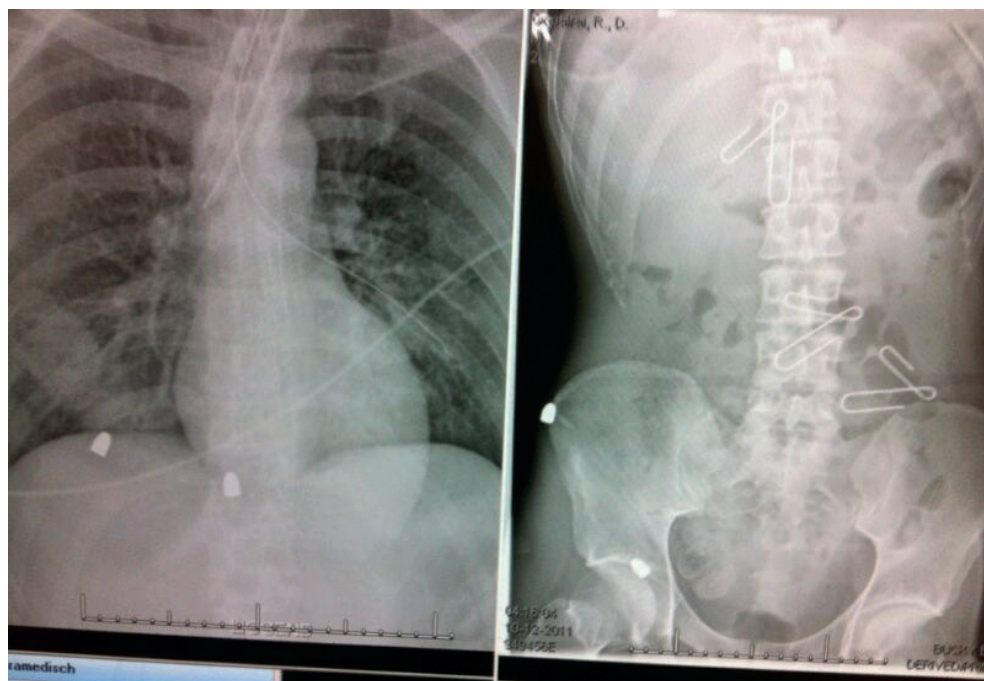

d



**Figure 1 a,b, c:** a HET projectile (a) causing not only penetrating injury to the coecum (b), but also ischaemia of the whole coecum and ascending colon (c), hence the patient was treated with staged surgery (d). After 12 hours definitive surgery with ileocolic anastomosis was performed.

a definitive anastomosis in (suspected) HET PI. On physical examination all clothing should be removed as soon as possible to exclude additional injuries of which the patient or pre-hospital emergency services personnel was not aware. Special care should be given to junctional areas (axillae, groin, neck) and skin folds, since these areas are prone to miss PI. It is advisory to mark all wounds. Paperclips can be bend a P or A shape, as to indicate the posterior or anterior side of the patient (Figure 2). This is helpful to assess which body cavities or organs might be injured. It should be mentioned though, that the projectiles might not have travelled through the tissue in a straight line. In case of GSW the number of paperclips should be an even number (entry wound corresponding with exit wound), or corresponding with a bullet. When an uneven number is counted, not matched with a projectile, the examiners should depict the adjacent body regions with X-rays until the bullet is found, if the hemodynamic status of the patient allows (11,12).

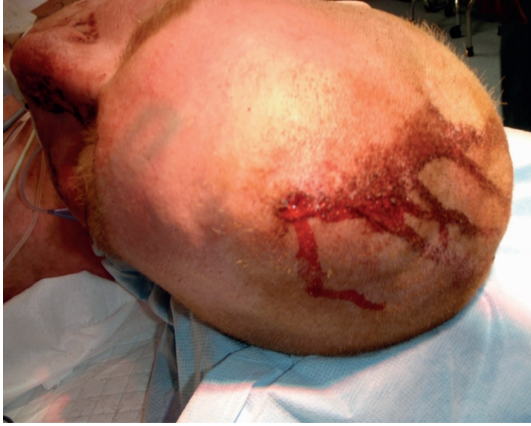

**Figure 2:** X-ray without (a) and with paperclip markers (b). The A-shape bend paperclips indicate three anterior gunshot wounds corresponding with three bullets.

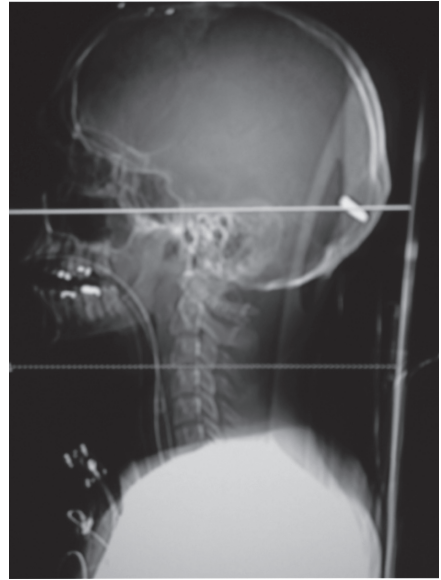
## **Damage control options for penetrating injuries to the head and neck**

As mentioned prior the amount of energy, which is transferred to patient's tissue, indicates the outcome. This is certainly true for gunshot wounds to the brain. Though it should be mentioned that not all gunshot wounds to the brain are lethal. The recent military conflicts in Iraq and Afghanistan produced data in which rapid damage control craniectomies for penetrating brain injuries produced an increase in survival (13-15). In civilian practice these aggressive damage control resuscitation and neurosurgical treatment strategies have also been successfully implemented, under the adagium "time is brain" (16,17). Patients with brainstem reflexes and a Glasgow coma score of 3 and over, after successful resuscitation with CT-scan proven mass lesion effect, should undergo decompression via craniectomy (Figure 3) as soon as possible to improve survival and outcome. Patients who display a "tramtrack sign" caused by cavitation of a passing projectile, or those with transventricular injury approximately 4 centimeters above the dorsum sellae "the so called zona fatalis" will not benefit from decompression and should be treated expectantly (18-20). If the patient's hemodynamic status does not permit a CT-scan of the brain, synchronous damage control surgery by both trauma surgeon and neurosurgeon can be performed if a mass effect due to the penetrating brain injury is suspected. If the measured intracranial opening pressure does not warrant diagnostic burr holes and damage control surgery has been successful, a CT-scan of the brain should be acquired as soon as possible to assess brain injury and treatment options (16). For stab wounds to brain with sharpened objects apply the same indications for neurosurgical treatment as for gunshot wounds with exteriorized objects "in situ" as additional indications (Figure 4) (21-23). Penetrating injury to the neck can generate a predicament, especially when gross bleeding is noted (24,25). In low volume centers for penetrating injury there might be the tendency to rush to theater for surgical exploration, with an increased risk on iatrogenic injury (26,27). Foley catheter balloon tamponade can be used as a damage control resuscitative tool to regain hemodynamic stability and temporary hemostasis to bridge to endovascular or surgical treatment after CTA-assessment of the neck (Figure 5 and 6). When no arterial bleeding needs to be

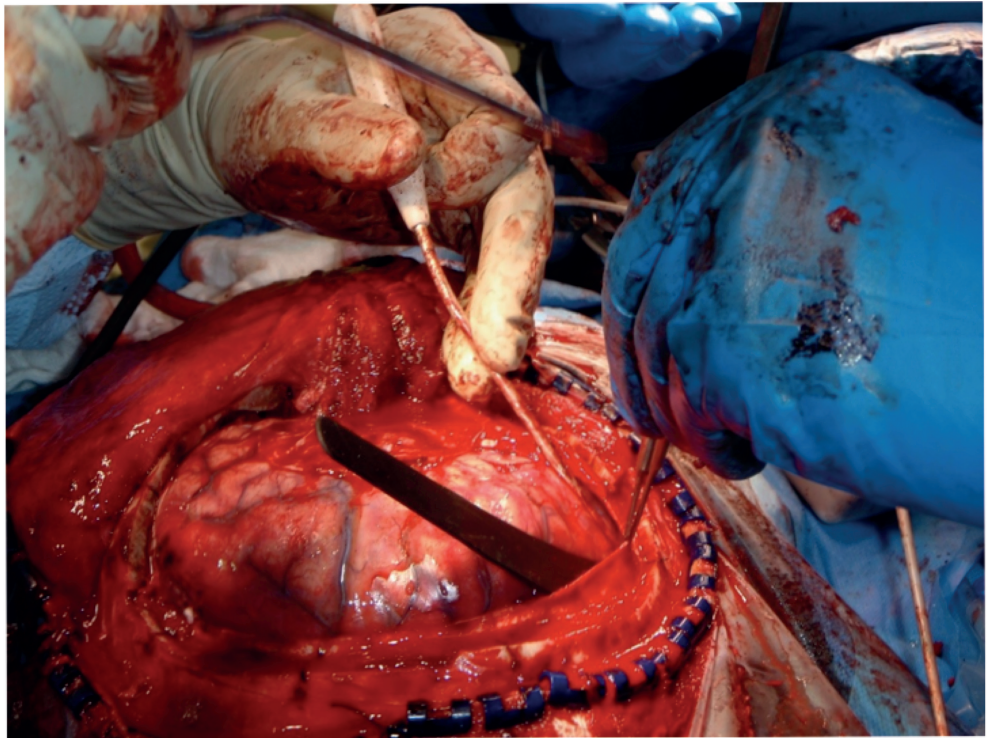
a



b



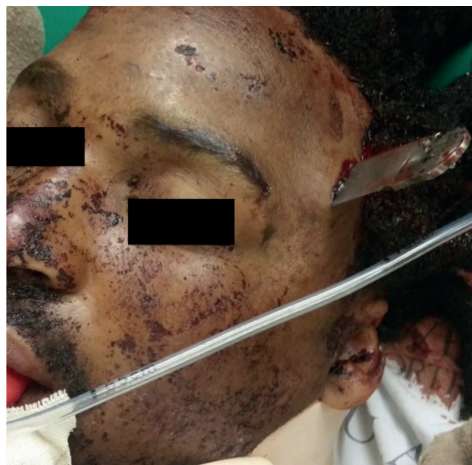c



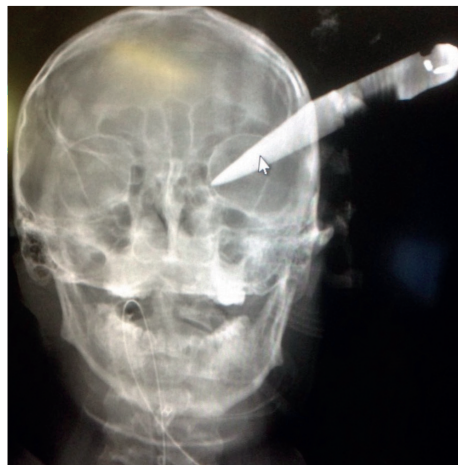**Figure 3:** Clinical presentation (a) and CT planogram (b) of HET gunshot wound limited to one hemisphere as indication for decompression via craniectomy (c).

addressed, the catheter be deflated and removed in controlled surroundings. Successful conservative treatment for penetrating neck injury, when using this strategy, can be 87 percent (28). When surgical exploration is indicated, the surgeon should be familiar with shunts suitable for the carotid vessels if the patient's condition does not allow definitive primary repair or an interposition graft. For bail out options in case of persistent bleeding in which suture techniques might not be successful, such as injury to vertebral artery, again Foley catheter balloon tamponade can be used or hemostatic granules or bone wax. Esophageal injury repairs, especially in combination with tracheal injury, should be protected with mobilized strap muscle and a drain.

a



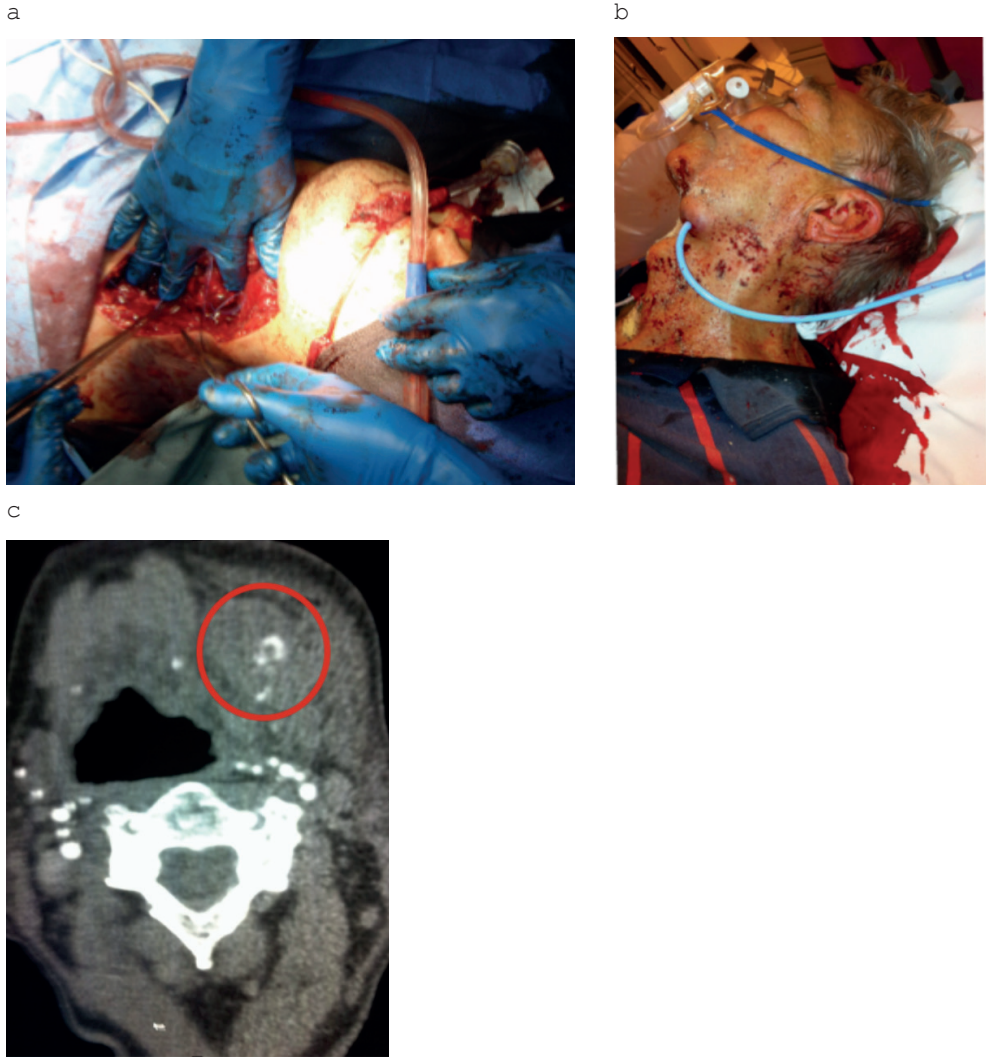
b



**Figure 4:** Clinical presentation (a) and X-ray (b) of an exteriorized knife still in situ.

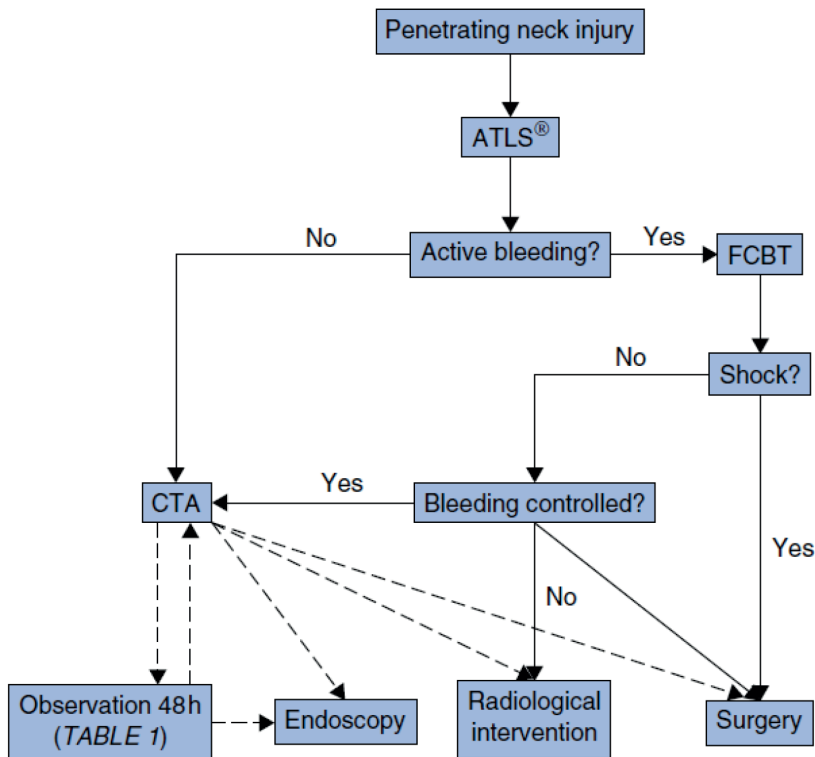
### **Damage control options for penetrating injuries to the chest**

For penetrating injuries of the chest it should be mentioned that gunshot wounds, especially with an oblique trajectory, are likely to perforate the diaphragm and thus might inflict intra-abdominal injury. This indicates that patients should have sterile exposure and surgical draping that, if needed, allows an additional laparotomy when the primary surgical exploration is a sternotomy or thoracotomy (Figure 7). In case of a transient or



**Figure 5:** Rushed into exploration of a penetrating neck injury with considerable change of iatrogenic injury (a). Foley catheter balloon tamponade achieving hemostasis (b), thus creating a controlled situation for the patient to be assessed for vascular or hollow organ injury via computed tomography angiogram of the neck (c).

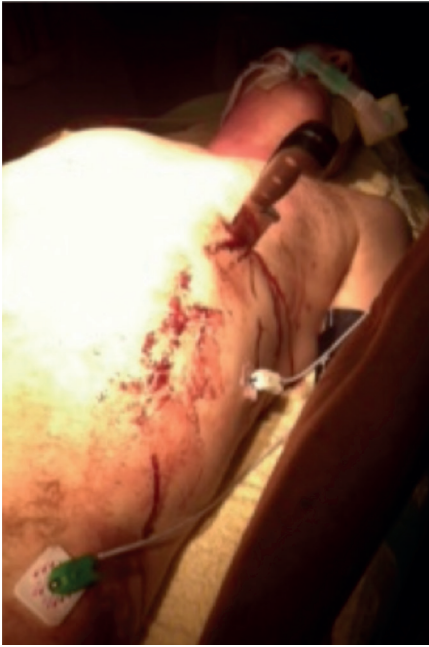non-responder to resuscitation with a systolic blood pressure that cannot be raised over 60 mmHg in the shock room, a resuscitative thoracotomy is indicated (29,30). This also applies for patients suffering from penetrating chest injury with witnessed cardiac arrest. Though there is no global consensus with regard to the



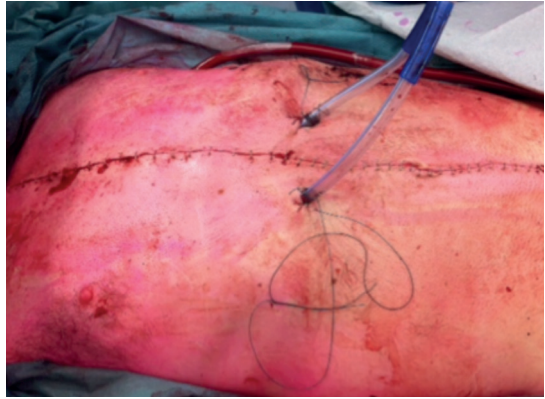
**Figure 6:** Flowchart for management of penetrating neck injury with optional Foley catheter balloon tamponade.

“down time” after which an emergency thoracotomy is still justified, it is generally accepted that survival for patients with ongoing cardiopulmonary resuscitation longer than 15 minutes is nil (31). Unless the injury is clinically limited to the right side of the chest, a left sided anterolateral approach is standard for an emergency department thoracotomy. The pericardium should always be opened as soon as possible, since from the outside it cannot be assessed for the presence of a hemothorax. Opening of the pericardium, ventral to the phrenic nerve, has the additional benefit of being able to perform more efficient cardiac compressions. For massive bleeding from the lung clamping of the paracardium or hilum is an option. Another alternative is the so-called “pulmonary hilar twist”, in which the apex of the lung is twisted downwards and the diaphragm and the lower lobulae upwards

a



b

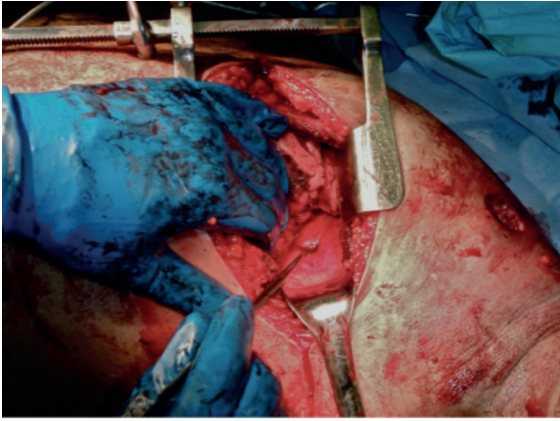


**Figure 7:** Penetrating injury to the chest with both pericardial and subdiaphragmatic injury (a), indicating a sternolaparotomy (b). Full sterile exposure facilitated a swift extension from sternotomy to laparotomy.

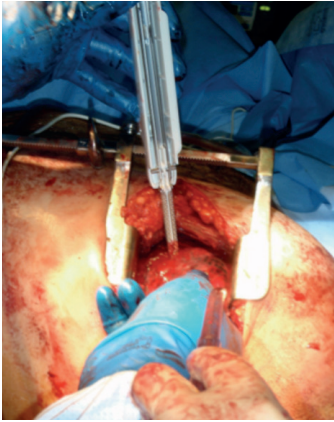
after release of the inferior pulmonary ligament (32). Simple suture closure of perforating brisk bleeding lung injuries is not an option, and the development of intrapulmonary hematoma or a possible air embolism can only be prevented by performing a pulmonary tractotomy. This can be achieved by "connecting" the entrance and exit (or creating an exit) wound of the lung parachyma using a GIA stapler. The injured vessels and bronchi which have not been sealed by staples can then be selectively ligated (Figure 8) (33). In order to limited the circulation to the chest and head while other resuscitation techniques are applied such as placement of central lines, the aorta can be clamped. Positioning of the clamp can be cumbersome in a flaccid aorta. It is more practical to compress the aorta to the vertebral column with fingertips. After successful administration of circulating volume the aorta will be pulsatile again with a normal caliber and easier to clamp. If the injury is transmediastinal or injury to other side of the chest is suspected, the thoracotomy can be extended by cutting the sternum and the intercostal musculature of the right side of the chest into a so called "clamshell thoracotomy" with an excellent exposure of



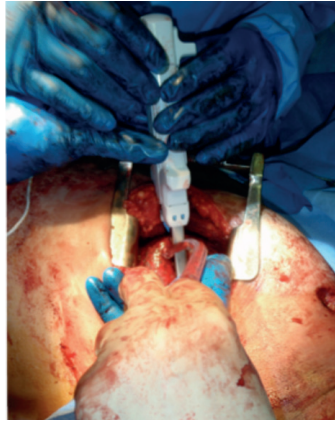a



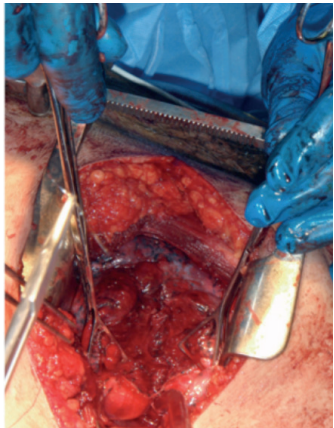
b



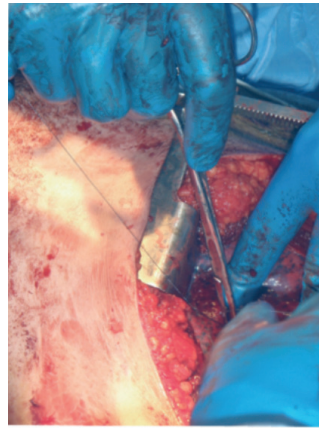
c



d



e



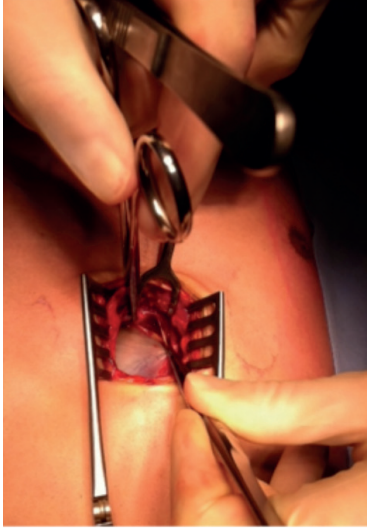**Figure 8:** A gunshot wound to the left lung (a). A tractotomy using a GIA stapler (b,c) and selective ligation of bronchi and vessels with persistent leakage (d,e).

both left and right side of the thorax and mediastinum (34). In patients in extremis with a penetrating injury trajectory that is suspect for pericardial injury and in whom the clinical status did not allow assessment of the pericardium via CTA or ultrasonography, a "subxiphoid window" procedure should be performed prior to laparotomy. The pericardial sac is approached preperitoneal, aided by elevating the xyphoid process with a clamp. If the evacuated fluid from the pericardium is clear or serosanguilent and remains clear after rinsing with saline, the drain production can be monitored. When blood is encountered, the procedure should be converted to sternotomy for most likely myocardial repair (35-37) (Figure 9). Small injury of the right side of diaphragm can be repaired if easily reached by limited mobilization of the liver to prevent the possibility of bile leakage in the pleural cavity. Left sided diaphragmatic injuries always need closure with non-absorbable sutures to prevent future complication (e.g intrathoracic herniation of peritoneal content). In case of gross intra-abdominal fecal spillage the laceration can be enlarged, parallel to the phrenic innervation, or using an additional incision posterolaterally in a curvilinear orientation to facilitate washout of the pleural cavity with several liters of saline to diminish the bacterial load and change of formation of pleural empyema (38).

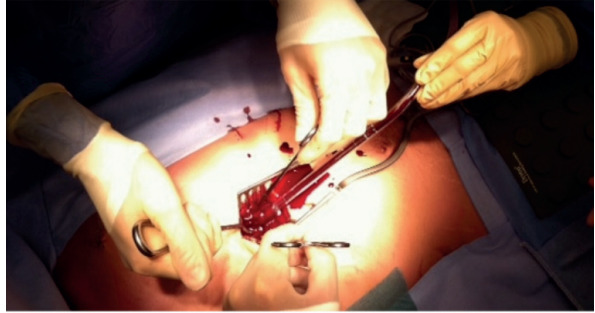### **Damage control options for penetrating injuries to the abdomen**

A fair number of tangential abdominal gunshot wounds and the majority of abdominal stab wounds can be treated via selected non-operative management principles of careful examination and repetitive clinical re-assessment. Exploratory laparotomies are indicated for patients with peritoneal signs with or without shock (39). Venous (liver) bleeding, encountered during clock- or counterclockwise inspection of the four quadrants of the peritoneal cavity, is amenable for packing. Arterial bleeding, such as mesenteric vascular injuries, cannot be packed but should be temporary clamped and repaired or suture ligated as soon as possible. Since penetrating injuries to the gastro intestinal tract are easily missed, especially at the border of the mesentery with the bowel wall, both the lead surgeon and his assistant should "flip flop" the entire bowel with mesentery

a

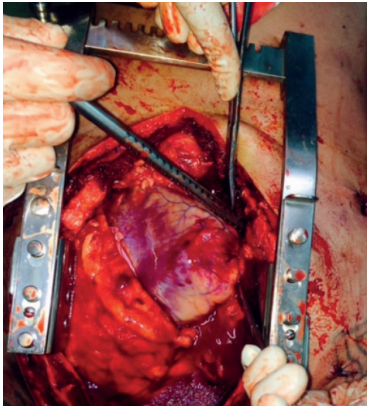


b

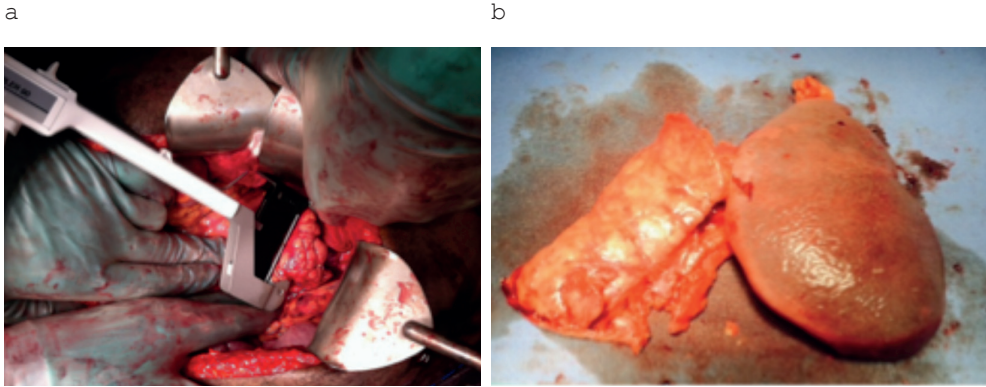


**Figure 9:** A subxyphoid window procedure for a suspected pericardial injury (a). Clear fluid can be monitored using a drain for 12 hours. Bloody effusion (b) indicates conversion to a sternotomy (c).

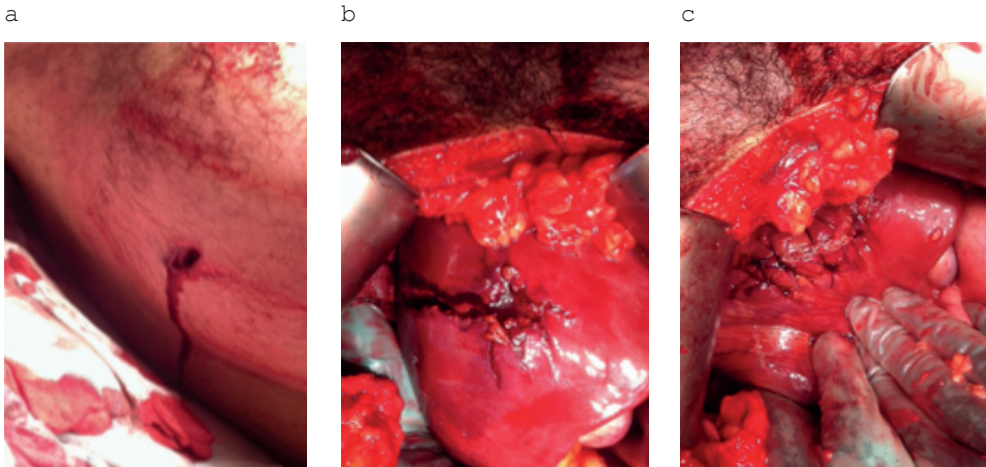
c



from side to side to inspect the whole circumference. If the patient's condition dictates staged surgery, injured bowel segments can be stapled or resected and temporary tied for later definitive anastomosis during relook laparotomy. Kocher's maneuver is mandatory if a duodenal injury is suspected. Primary tensionless repair of duodenal lacerations should be attempted and concomitant pancreatic injuries are to be drained. The suture line can be protected with decompressive jejunal-cutaneous fistula using (Foley) catheters and optional a more distal one for enteral feeding. Another possibility to spare the duodenal repair is by pyloric exclusion (40). However,



**Figure 10:** A penetrating injury to the tail of the pancreas swiftly controlled using a linear stapler (a) for “en bloc” resection of pancreas tail and spleen (b).



**Figure 11:** A gunshot injury (a) to the liver. Instead of packing, large monofilament sutures in a figure of eight configuration were used to treat the laceration (b, c). Thus avoiding the need for pack removal and relook surgery.

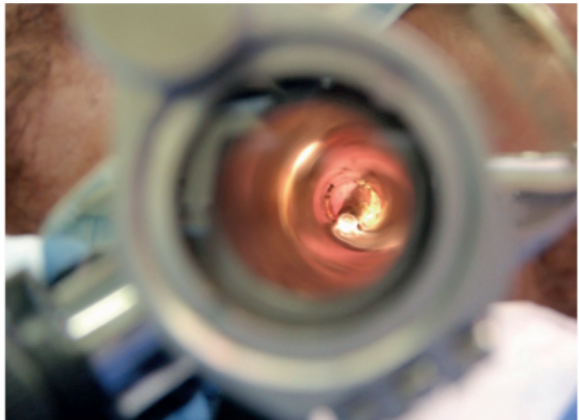
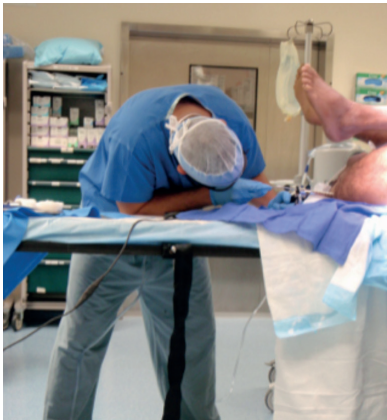these procedures are time demanding and not recommended in a DCS modus. The lesser sac is always to be explored to exclude injury to the posterior gastric wall and pancreas. Indications for an emergency Whipple’s procedure are scarce and not recommended since most patients suffering from pancreatic head injuries, in combination with duodenal injury, are usually in need of a DCS approach due to additional vascular injuries. A prompt but sound assessment of the extent of gland and duct injury

dictates further future surgical management. Minor injuries without visible duct involvement are drained. Injury to body and tail of the pancreas with duct laceration are treated with a distal pancreatectomy, "en bloc" with the spleen using a linear stapler, gaining rapid control of bleeding and leakage (Figure 10) (41). Liver lacerations treated with "packing", in which six abdominal sponges should suffice, dictates a relook laparotomy for pack removal preferably after 48 hours post placement to prevent re-bleeding (42). Another option for liver lacerations in a non-shocked patient, to prevent open abdominal treatment, is careful placement of several large diameter monofilament sutures using the figure of eight configuration to gain hemostasis and diminish bile leakage (Figure 11). Central retroperitoneal hematomas are in need of exploration to exclude injury to the duodenum, pancreas, aorta and inferior vena cava (43). Injury to the latter can be masked by a low flow state in combination with containment by the peritoneum, especially in through and through peri-vertebral gunshot injuries. Cava injuries are notorious for rapid exsanguination once the tamponading effect of the peritoneum is released. Hence it is advocated, if inferior vena cava injury is suspected, to compress proximal and distal of the injury onto the vertebral column by an extra assistant before opening the peritoneum. If the injury is not amenable for primary repair, ligation is an option for hemorrhage control, which will be tolerated by the patient (44). A non-expanding lateral retroperitoneal hematoma does not need surgical exploration, unless colonic injury is suspected. Large expanding lateral hematomas are most likely to be caused by kidney injury beyond repair (AAST injury scoring scale grade 4 and 5). Nephrectomy is best performed via a lateral approach using the dissection established by the hematoma, after which the hilum and ureter can be ligated (45). Repair of ureter injury in a DCS setting is not advisable. Instead the injury can be drained and tacked for repair in relook surgery. Percutaneous nephrostomy can be used as a bridge to definitive ureter repair. Simple intraperitoneal bladder injuries should be repaired with transurethral and/or suprapubic drainage. More complex or extraperitoneal injuries receive a para-cystic drain after provisional hemostatic suturing (46). In contrast to pelvic retroperitoneal hematoma caused by blunt force, hematoma by gunshot or stabbing will need

exploration. Usually caused by injury to iliac artery, vene or predicamentally a combination of both. Shunting, with optional fasciotomy of the lower leg, can be a limb saving damage control strategy in these injuries. When the trajectory is suspect for injury to the rectum, a negative digital rectal examination should always be followed by rigid rectosigmoido scopy prior to laparotomy (Figure 12). When blood or injury to the rectum is confirmed, pelvic sepsis should be prevented by a diverting colostomy. Injury to the rectosigmoid should be assessed, during laparotomy, for primary repair or "bail out" diverting colostomy and drainage (47). Damage control lapartomies should always finish with a (provisional) closure of the abdominal wall wounds caused by the firearm or blade, to prevent future herniation of abdominal viscera, and a thorough washout with several liters of warmed saline. In order to protect the viscera till the subsequent surgery and prevent an abdominal compartment syndrome, a temporary abdominal closure device can be fashioned from a combination of (adhesive) plastic sheets, gauze and percutaneous drains connected to a suction device (Figure 13) as a (cheaper) alternative to commercial negative Pressure Wound Therapy (48).

a

b



**Figure 12:** Rigid rectosigmoidoscopy prior to laparotomy (a), revealing a bullet in the rectum (b).

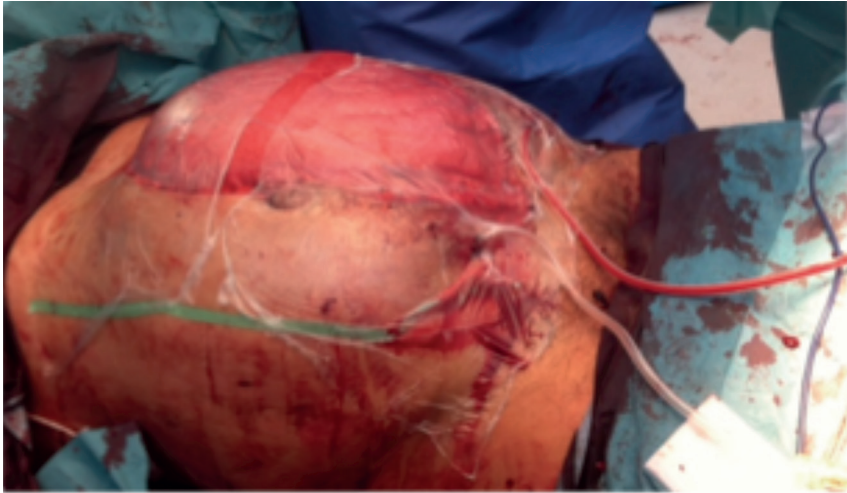## **Damage control options for penetrating injuries to the extremities**

Though the doctrine of damage control surgery dictates "the life over limb" principle, it should be stressed that seemingly insignificant injuries to the extremities can be life threatening. Junctional penetrating injuries (e.g. groin, axillae) can be difficult to control since these injuries, in contrast to the more distal injuries, are not suitable for temporary hemorrhage control using a standard tourniquet. Not only in a pre-hospital or emergency department setting, but also in the operation theatre can hemostatic bandages or granules and catheter balloon tamponade render provisional hemorrhage control for these injuries in which rapid access for vascular control is difficult (49,50). As mentioned prior, the surgeon should be familiarized with shunt options to bridge vascular injuries. Most vascular injuries due to stabbing or projectiles are not fit for primary repair and thus will need an interposition graft. Patients in need of DCS are not in the condition to undergo the lengthy procedure of gaining proximal and distal vascular control followed by harvesting and preparing a vene graft, which can then be sutured into the defect. A more realistic scenario is a patient with multiple penetrating injuries in need of DCS. When confronted with a penetrating injury to the extremities with a vascular deficit, it is more than likely to be accompanied with a fracture and nervous injury. The latter can be tagged with 5:0 monofilament suture for later definitive repair. The most practical approach to these combined injuries is to gain vascular control and shunt the defect to preserve distal flow. This is followed by placement of an external fixator, in case of a fracture (Figure 14). Prophylactic fasciotomy of the affected limb is highly advocated, prior to definitive repair or when using a shunt in a DCS case (51,52).

## **CONCLUSION**

Patients with penetrating injuries can present themselves to any emergency department. Hence all trauma care providers should be familiar with the injury patterns (HET versus LET) and treatment options. Hemorrhage control techniques used in pre-hospital or emergency department settings (e.g. hemostatic agents and

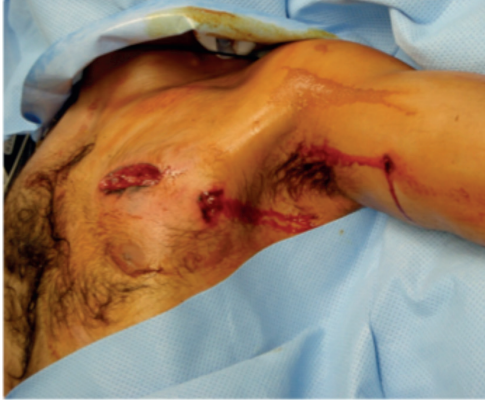catheter balloon tamponade) can be used as “bail out” options in theatre as well. When DCS is needed, it is advised to return the patient to theatre for definitive repair as soon as the preset resuscitation values are established to avoid the detrimental effects of missed injury for which this patient group is prone.



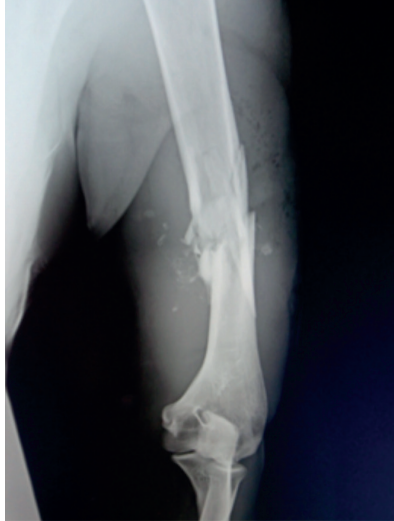**Figure 13:** A temporary abdominal closure device (TAC) fashioned from two percutaneous drains connected to wall suction and abdominal packs covered by adhesive plastic sheets. A low cost solution in patients prone for an abdominal compartment syndrome or in need of relook abdominal surgery as part of DCS.



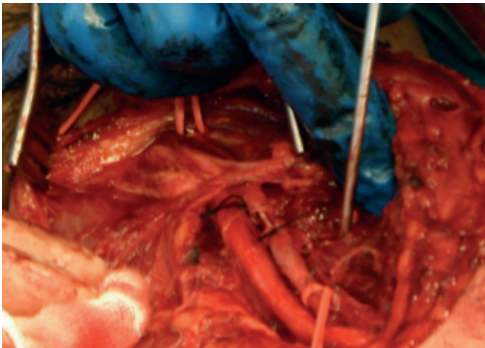
a



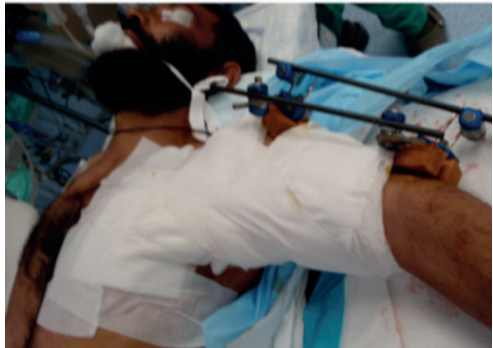b



c



d



**Figure 14:** a gunshot injury to the left upper extremity (a) with a concomitant fracture of the humerus (b). In DCS treated with a shunt for the brachial artery injury (c) and external fixator (d).

## REFERENCES

1. MacKenzie EJ. Epidemiology of injuries: current trends and future challenges. *Epidemiol Rev* 2000;22(1): 112-9.
2. Sektion NCS of the German Trauma Society (DGU®) / AUC-academy of Trauma Surgery GmbH. TraumaRegister DGU® Annual Report 2013.
3. Störmann P, Gartner K, Wyen H, Lustenberger T, Marzi I, Wutzler S. Epidemiology and outcome of penetrating injuries in a Western European urban region. *Eur J Trauma Emerg Surg*. 2016 Jan 13.
4. Kapusta ND, Etzersdorfer E, Krall C, Sonneck G. Firearm legislation reform in the European Union: impact on firearm availability, firearm suicide and homicide rates in Austria. *Br J Psychiatry*. 2007 Sep;191:253-7.
5. Bellis MA, Hughes K, Anderson Z, Tocque K, Hughes S. Contribution of violence to health inequalities in England: demographics and trends in emergency hospital admissions for assault. *J Epidemiol Community Health* 2008;62:1064-1071
6. Efron DT, Haider A, Chang D, Haut ER, Brooke B, Cornwell III EE. Alarming Surge in Nonsurvivable Urban Trauma and the Case for Violence Prevention. *Arch Surg*. 2006; 141:800-805
7. Maxwell R, Trotter C, Verne J, Brown P, Gunnell D. Trends in admissions to hospital involving an assault using a knife or other sharp instrument, England, 1997-2005
8. Hirsch M, Carli P, Nizard R, Riou B, Baroudjian B, Baubet T, Chhor V, Chollet-Xernard C, Dantchev N, Fleury N, Fontaine JP, Yordanov Y, Raphael M, Paugam Brutz C, Lafont A. The medical response to multisite terrorist attacks in Paris. *Lancet* 2015; 386: 2535-38
9. Biddinger PD, Baggish A, Harrington L, d'Hemecourt P, Hooley J, Jones J, Kue R, Troyanos C, Dyer S. Be Prepared – The Boston Marathon and Mass-Casualty Events. *N Engl J Med*. 2013; 368:1958-60
10. Stefanopoulos PK, Hadjigeorgiou GF, Filippakis K, Gyftokostas D. Gunshot wounds: A review of ballistics related to penetrating trauma. *Journal of Acute Disease* 2014;178-185
11. Peterson B, Shapiro MB, Crandall M, Skinner R, West MA. Trauma Clip-Art: Experience with an improved radiopaque marker system for delineating the path of penetrating injuries. *J Trauma* 2005; 58:1078-81
12. Brook A, Bowley DMG, Boffard KD. Bullet Markers - A Simple Technique To Assist In The Evaluation Of Penetrating Trauma. *J R Army Med Corps* 2002; 148: 259-261

13. Bell RS, Mossop CM, Dirks MS, Stephens FL, Mulligan L, Ecker R, et al. Early decompressive craniectomy from severe penetrating and closed head injury during wartime. *Neurosurg Focus*. 2010; 28(5):EI.
14. Rosenfeld JV, Bell RS, Armonda R. Current Concepts in Penetrating and Blast Injury to the Central Nervous System. *World J Surg* 2015; 39:1352-62
15. Nessen Sc, Lounsbury DE, Hetz Sp. War surgery in Afghanistan and Iraq; a series of cases, 2003-2007. Office of the surgeon General Borden institute, Walter Reed army Medical Center, Washington 2008:85-89, 101-107
16. Lin DJ, Lam FC, Siracuse JJ, Thomas A, Kasper EM. "Time is brain" the Gifford factor-or: Why do some civilian gunshot wounds to the head do unexpectedly well? A case series with outcomes analysis and a management guide. *Surgical Neurology International* 2012; 98:1-12
17. Helling TS, McNabney K, Whittaker K, Schultz CC, Watkins M. The role of early surgical intervention in civilian gunshot wounds to the head. *J Trauma*. 1992;32:398-400.
18. Temple N, Donald C, Skora A, Reed W. Neuroimaging in adult penetrating brain injury: a guide for radiographers. *J med radiat Sci* 2015;62:122-131
19. Kim AK, Wang MY, McNatt SA, Pinsky G, Liu Cy, Glannotta SL, Apuzzo MLJ. Vector analysis correlating bullet trajectory to outcome after civilian through-and-through gunshot wound to the head: using imaging cues to predict fatal outcome. *Neurosurgery* 2005;57:737-747
20. Aarabi B, Tofighi B, Kufera JA, Hadley J, Ahn ES, Cooper C, Malik JM, Naff NJ, Chang L, Radley M, Kheder A, Uscinski RH. Predictors of outcome in civilian gunshot wounds to the head. *J Neurosurg* 2014;120:1138-46
21. Khalil N, Elwany MN, Miller JD. Transcranial stab wounds: morbidity and medicolegal awareness. *Surg Neurol* 1991;35:294-9
22. Enicker B, Madiba TE. Cranial injuries secondary to assault with a machete. *Injury* 2014;45:1355-1358
23. Exadaktylos AK, Stettbacher A, Bautz PC. The Value of Protocol-Driven CT Scanning in Stab Wounds to the Head. *Am J Emerg Med* 2002;20: 295-297
24. Thal ER, Meyer DM. Penetrating neck trauma. *Curr Probl Surg* 1992;29:51-61
25. Tallon JM, Ahmed JM, Sealy B. Airway management in penetrating neck trauma at a Canadian tertiary trauma centre. *CJEM* 2007;9:101-104
26. Demetriades D, Asensio JA, Velmahos G, Thal E. Complex problems in penetrating neck trauma. *Surg Clin North Am* 1996;76:661-683
27. Apffelstaedt JP, Müller R. Results of mandatory exploration for penetrating neck trauma. *World J Surg* 1994;18:917-919
28. van Waes OJF, Cheriex KCAL, Navsaria PH, van Riet PA, Nicol AJ, Vermeulen J. Management of penetrating neck injuries. *Br J Surg* 2012;99:149-154

29. Fairfax LM, Hsee L, Civil ID. Resuscitative Thoracotomy in Penetrating Trauma. *World J Surg* 2015;39:1343-1351
30. van Waes OJF, van Riet PA, Van Lieshout EMM, Den Hartog D. Immediate Thoracotomy for penetrating injuries: ten years' experience at a Dutch level I trauma center. *Eur J Trauma Emerg Surg* 2012;38:543-51
31. Seamon MJ, Haut ER, Van Arendonk K, Barbosa RR, Chiu WC, Dente CJ, MD, Fox N, Jawa RS, Khwaja K, Lee JK, Magnotti LJ, Mayglothling JA, MD, McDonald AA, Rowell S, MD, MCR, To KB, Falck-Ytter Y, Rhee P. An evidence-based approach to patient selection for emergency department thoracotomy: A practice management guideline from the Eastern Association for the Surgery of Trauma. *J Trauma Acute Care Surg* 2015;79: 159-173.
32. Wilson A, Wall Jr MJ, Maxson R, Mattox K. The pulmonary hilum twist as a thoracic damage control procedure. *Am J Surg* 2003;186:49-52
33. Petrone P, Asensio JA. Surgical management of penetrating pulmonary injuries. *Scand J Trauma Resusc Emerg Med*;2009;17:1-8
34. Navsaria PH, Chowdhury S, Nicol AJ, Edu S, Naidoo N. Penetrating Trauma to the Mediastinal Vessels: a Taxing Injury. *Curr Trauma Rep* 2016;2:1-10
35. Nicol AJ, Navsaria PH, Beningfield S, Hommes M, Kahn D. Screening for occult penetrating cardiac injuries. *Ann Surg.* 2015;261:573-8
36. Navsaria PH, Nicol AJ. Haemopericardium in stable patients after penetrating injury: Is subxyphoid pericardial window and drainage enough? *Injury.* 2005;36:745-50
37. Nicol AJ, Navsaria PH, Hommes M, Ball CG, Edu S, Kahn D. Sternotomy or drainage for hemopericardium after penetrating trauma. *Ann Surg.* 2013;00:1-5
38. DeBarros M, Martin MJ. Penetrating Traumatic Diaphragm Injuries. *Curr Trauma Rep* 2015;1:92-101
39. Benjamin E, Demetriades D. Nonoperative Management of Penetrating Injuries to the Abdomen. *Curr Trauma Rep* 2015; 1:102- 6
40. Weinberg JA, Croce MA. Penetrating Injuries to the Stomach, Duodenum, and Small Bowel. *Curr Trauma Rep* 2015; 1:107-112
41. Krige JEJ, Beningfield SJ, Nicol AJ, Navsaria P. The management of complex pancreatic Injuries. *S Afr J Surg* 2005;43:92-102
42. Nicol AJ, Hommes M, Primrose R, Navsaria PH, Krige JEJ. Packing for Control of Hemorrhage in Major Liver Trauma. *World J Surg* 2007; 31: 569-574
43. Manzini N, Madiba TE. The management of retroperitoneal haematoma discovered at laparotomy for trauma. *Injury* 2014;45:1378-83
44. Navsaria PH, Bruyn de P, Nicol AJ. Penetrating abdominal vena cava injuries. *Eur J Vasc Endovasc Surg* 2005;30:499-503

45. Joseph B, Khalil M, Rhee P. Penetrating Injuries to the Spleen and Kidney:an Evolution in Progress. *Curr Trauma Rep* 2015;1:76-84
46. Zaid UB, Bayne DB, CR Harris, Alwaal A, McAninch AJ, Breyer BN. Penetrating Trauma to the Ureter, Bladder, and Urethra. *Curr Trauma Rep* 2015; 1:119-124
47. Trust MD, Brown CVR. Penetrating Injuries to the Colon and Rectum. *Curr Trauma Rep* 2015; 1:113-118
48. Barker DE, Kaufman HJ, Smith LA, Ciraulo DL, Richart CL, Burns RP. Vacuum Pack Technique of Temporary Abdominal Closure: A 7-Year Experience with 112 Patients. *J Trauma* 2000;48:201-207
49. Zietlow JM, Zietlow SP, Morris DS, Berns KS, Jenkins DH. Prehospital Use of Hemostatic Bandages and Tourniquets: Translation From Military Experience to Implementation in Civilian Trauma Care. *J Spec Oper Med* 2015;15:48-53
50. Van Waes OJF, Van Lieshout EMM, Hogendoorn W, Halm JA, Vermeulen J. Treatment of penetrating trauma of the extremities: ten years' experience at a dutch level 1 trauma center. *Scand J Trauma Resusc Emerg Med* 2013;14;21:2-6
51. Clouse WD, Rasmussen TE, Peck MA, Eliason JL, Cox MW, Bowser AN, Jenkins DH, Smith DL, Rich NM. In-Theater Management of Vascular Injury: 2 Years of the Balad Vascular Registry. *J Am Coll Surg* 2007;204:625-32
52. Starnes BW, MD, Beekley AC, MD, Sebesta JA, Andersen CA, M. Rush Jr. RM. Extremity Vascular Injuries on the Battlefield: Tips for Surgeons Deploying to War. *J Trauma*. 2006;60:432- 42.



# **PART TWO**

---

*"If everyone is thinking alike  
then somebody isn't thinking"*

*George S. Patton*





# Chapter Three

---

van Waes OJF, Reinders Folmer EI, Visser 't Hooft ME, van Lieshout EMM, Navsaria PH, Schouten JW, Nicol AJ, Verhofstad MHJ, Vermeulen J.

Penetrating Brain Injury; a prospective observational study

- *submitted*

## INTRODUCTION

Penetrating brain injury (PBI) includes all traumatic brain injuries (TBI) that are caused by projectiles (e.g., bullets), knives, or other sharp objects (1). The incidence of PBI is far less frequent than blunt injuries to the brain, however mortality is significantly higher in PBI with an overall mortality reported in literature of up to 88% compared with 32.5% mortality in non-penetrating TBI (2-3). Just like blunt traumatic brain injury (TBI), incidence and mortality of PBI are highly variable regionally and over time. Perception of the burden of PBI is further complicated by the enormous heterogeneity within PBI, as is also reported in TBI (4). In Western Europe the incidence of PBI is relatively low compared with combat areas and parts of the world with higher violence rates and thus European trauma care providers are unfamiliar in treating these injuries. An abstinent attitude towards aggressive treatment of PBI is fairly often encountered, especially when CT scans appear "impressive", or when brain is oozing out a cranial wound in the emergency room (5-7).

PBI can be separated in two main groups that differ in injury severity and energy transfer mechanism. The first includes lower velocity sharp objects, such as knives. This kind of trauma maybe characterized by so called "slot fractures" of the calvarium (8). The tissue damage is confined to the primary track with minimal injury to surrounding tissues, also called low kinetic energy transmission (LET) PBI. LET type PBI by machetes and axes causes a combination of penetrating and blunt mechanism that focally harms the cerebral tissue (9). The second mechanism involves higher velocity projectiles, mostly bullets, which result in more complex wounding patterns. This PBI due to high kinetic energy transfer (HET) causes a shock wave through the brain tissue, which after passage of the projectile implodes into the bullet track and thus creating additional injury (10).

Treatment strategies of PBI have been sawing from an aggressive surgical approach as introduced by Cushing during World War I (11,12) and practiced up to the Vietnam conflict (13), to a more conservative treatment as suggested by Brandvold *et al.*

during the Lebanese conflict (14). More recent data from military conflicts in Iraq and Afghanistan propose early decompression via hemi-craniectomy in order to limit secondary injury (15-17). This strategy of early surgery in high velocity HET PBI is acknowledged in a civilian population, which appears to benefit from this approach (18,19).

Evidence-based algorithm for PBI developed by the American Association of Neurological Surgeons and the Brain Trauma Foundation to standardize medical and surgical treatment of PBI is mostly based upon retrospective studies concerning and expert opinions (10,20).

Since prospective PBI studies are scarce especially for LET PBI, this prospective observational study was done in cooperation with high volume trauma center for penetrating injury in South Africa, to assess the outcome of both HET and LET PBI in a civilian setting.

## **METHODS**

All consecutive patients aged 18 years or older with possible PBI presenting to the Trauma Unit of a level I Trauma Center in South Africa, between March 16 and July 8, 2013 were included in this prospective observational study. Approval for data collection was obtained from the local research ethics committee (Department of Surgery Research Committee under project number 2013/048). Age, gender, mechanism of injury, New Injury Severity Score (NISS), clinical manifestations and (pre)hospital vital signs, time of transfer from point of injury (POI) to the Emergency Department (ED), indications for special investigations, viscera injured, and treatment strategy of all patients were collected using a standardized datasheet. PBI was defined as penetration of the skull by a bullet, knife, or other sharp object identified by radiographic investigation. Patients were excluded when the time of injury was more than 48 hours prior to presentation at the ED or when an evident infaust prognosis (GCS 3 with non-reactive brain stem reflexes) was set immediately at presentation (Figure 1). The primary outcome variable was death. Patients

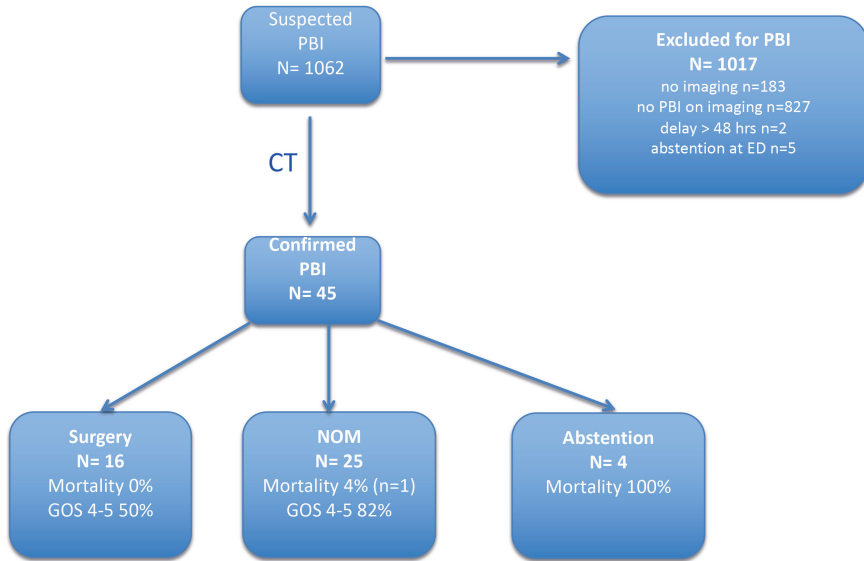
were assessed and treated using the Advanced Trauma Life Support (ATLS®) principles (21). The on-call neurosurgeon and trauma surgeon set the indication for surgical intervention. The decision for non-operative management (NOM) was made for patients who had no strong indications for surgery, considering their clinical parameters and the absence of hard findings such as drainable collections or suspected increased intracranial pressure. The NOM group was kept for neurological observation during 72 hours and received resuscitation and medication when needed.

Injury severity score (ISS) is used to assess trauma severity. It uses the abbreviated injury scale (AIS) to number the three most severe injured ISS body regions from one to six, which consists of six different regions. The new injury severity score uses the highest AIS regardless of anatomical region to calculate the trauma severity.

All calculations and statistical analyses were performed using SPSS statistics version 21.0. Continuous data were non-parametric, and are presented as median with  $P_{25}$ - $P_{75}$ . Categorical data are shown as numbers with percentages. Statistical significance of difference was tested using a Mann-Whitney U-test for continuous data and a Chi-Squared test or Fisher Exact test for categorical data. A p-value <0.05 was used as threshold.

## RESULTS

During the study period, 1,062 patients with possible PBI presented to the Emergency Department (Figure 1). Patients who did not receive neuroimaging (n=183) or for whom no PBI was noted with radiological diagnostics (n=827) and patients referred with a delay over 48 hours post injury (n=2) were excluded. Five patients suffering gross injuries to the head with GCS of 3 and without brainstem reflexes after adequate resuscitation were declared brain death.



**Figure 1:** Flowchart of included patients

PBI, penetrating brain injury; ED, emergency department; SNOM, selective non-operative management; GOS, Glasgow outcome score.

**Table 1: Indicators for outcome**

	Favorable outcome (GOS 4-5) N=33	Unfavorable outcome (GOS 1-3) N=12	P
Age (years)	26 (21-34)	22 (16-29)	0.068
Males	33 (100%)	11 (92%)	0.267
High energy trauma	6 (18%)	6 (50%)	0.055
ISS	25 (25-30)	29 (25-35)	0.112
NISS	57 (50-57)	66 (57-75)	<b>0.001</b>
GCS*			
3-5	0 (0%)	6 (50%)	<b>&lt;0.001</b>
6-8	2 (7%)	3 (25%)	
9-15	28 (93%)	3 (25%)	
Operative treatment	9 (27%)	7 (58%)	0.080

Glasgow Outcome Score (GOS), Injury Severity Score (ISS), New Injury Severity Score (NISS), Glasgow Coma Score (GCS),\* in three patients the GCS was inconclusive

These five patients did not receive further treatment and subsequently died in the ED and were also excluded. The median age of remaining 45 patients (98% male) was 24 years ( $P_{25}$ - $P_{75}$  20-34). The overall mortality was 5 of the 45 included patients

(9%). PBI was for 33 patients (73%) due to low energy transfer mechanism by sharpened weapons (e.g., knife, screwdriver) versus 12 patients (27%) with high-energy transfer PBI GSW. The type of injury mechanism did not significantly relate the overall survival ( $p = 0.598$ ). Six of the GSW injuries patients (50%) had a favorable outcome (GOS 4-5) versus 27 patients with PBI due to LET (82%) ( $p=0.082$ ) (see Table 1). Twenty-three of the 45 patients suffered additional injuries (51%). These injuries were compiled of extremity injuries in 9 (36%), maxillofacial injuries in 8 (32%), thoracic in 4 (16%) and abdominal in 4 (16%). All patients who could remain their own airway ( $n=33$ ) survived. A third of the patients in need for intubation ( $n=12$ ) died. The mortality increased with a higher shock classification. From patients with shock class I ( $n=28$ ), class II ( $n=15$ ) and class III ( $n=2$ ), respectively 7, 13 and 50% died. Patients with dilated ( $n=9$ ) and unreactive pupils ( $n=6$ ), respectively 22 and 33% died, versus only 4 and 3% mortality in the non-dilated ( $n=26$ ) and reactive pupils ( $n=35$ ). The mortality rate for patients with a GCS 3-5 was 83% ( $n=5$ ). Patients with GCS 9-15, and GCS 6-8 all survived. The overall GCS was not significantly different for conservatively or neurosurgical treated patients ( $p=0.08$ ) (see Table 2). The survivors had a favorable outcome of function (GOS 4-5) in 71% on discharge. None of the surgical treated patients ( $n=16$ ) died. Conservatively treated patients had a better percentage (82%) of favorable outcome on discharge compared with the operated patients (50%). Patients who displayed "oozing" of brain matter ( $n=8$ ) survived in 63% of whom 3 (38%) with a favorable outcome (GOS 4-5).

Factors predominantly noted in surgical treated patients versus conservative treatment included a significantly higher NISS 63 ( $P_{25}-P_{75}$  57-66) versus 57 ( $P_{25}-P_{75}$  50-57)  $p=0.005$  and lateralization 38% vs. 3% ( $p=0.010$ ).

The median time delay from presentation at the ED to the first CT was two hours and forty-five minutes ( $P_{25}-P_{75}$  104-249 minutes).

CT findings significantly related with surgical treatment versus NOM, were respectively a retained penetrating object in 6 surgical patients (38%) versus 3 NOM patients (10%) ( $p=0.050$ ),

trans ventricular injury in 3 surgical patients (19%) versus nil (0%) NOM patients (p=0.039), hematoma in 15 surgical patients (94%) versus 18 (62%) NOM patients (p=0.033), edema in 13 surgical patients (81%) versus 10 NOM patients (35%) (p=0.005) and midline shift in 12 surgical patients (75%) versus 10 NOM patients (35%) (p=0.013).

**Table 2: Characteristics of operated versus SNOM PBI patients**

	Operated N=16	SNOM N=29	P
Age (years)	27 (22-31)	24 (18-34)	0.434
Males	15 (94%)	29 (100%)	0.356
High energy trauma	6 (38%)	6 (21%)	0.296
GCS*			
3-5	1 (7%)	5 (18%)	
6-8	4 (29%)	1 (4%)	0.052
9-15	9 (64%)	22 (79%)	
Brain oozing	4 (25%)	4 (14%)	0.427
Lateralization	6 (38%)	1 (3%)	<b>0.010</b>
Pupil dilatation	5 (33%)	4 (20%)	0.451
Reactive pupils	13 (81%)	22 (88%)	0.662
CT findings			
Hematoma	15 (94%)	18 (62%)	<b>0.033</b>
Midline shift	12 (75%)	10 (35%)	<b>0.013</b>
Multilobular	11 (69%)	12 (41%)	0.120
Mortality	0 (0%)	5 (17%)	0.144

Selective Non Operative Management (SNOM), Glasgow Coma Score (GCS), Computed Tomography scan (CT),\* in three patients the GCS was inconclusive

All deceased patients (n=5) suffered from multilobular injuries (p = 0.049), and from the survivors 18 patients (45%) sustained this type of injury. The presence of midline shift was seen in 18 survivors (45%) versus 4 (80%) of patients who died (p=0.187). Four of the five expired patients displayed " non-survivable injuries" on CT scan. Two patients suffered so called central bihemispheric gunshot wounds, in which the trajectory crosses midline structures of the brain and affects both right and left hemispheres (22). Both patients with a GCS 3-5 were treated expectant for this reason and shortly hereafter expired.

The third patient suffering a machete injury transferred from elsewhere with an initial GCS of 9 was presented with GCS of 3. CT scan 7 hours after injury displayed a combination of "slot"

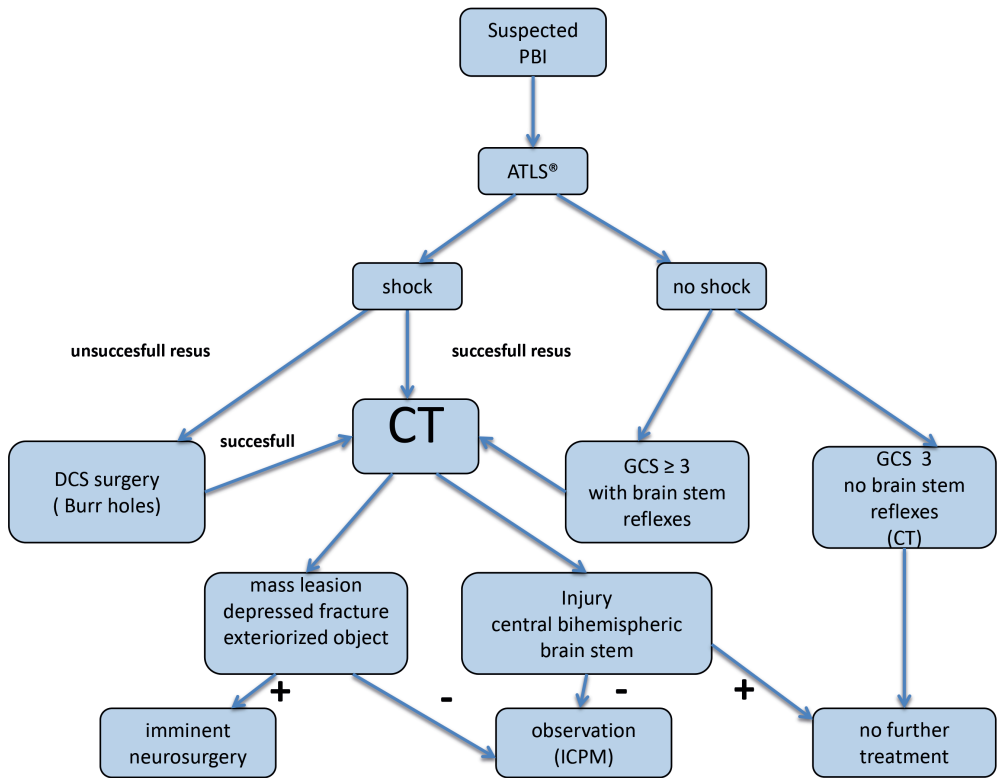
fractures with massive hemorrhagic contusion and both uncal and brain stem herniation. Surgical treatment in this case was considered futile. The same treatment decision was made for a transferred patient suffering several SW's. CT also 7 hours after injury displayed massive infarction of both the medial cerebral artery (MCA) and posterior cerebral artery (PCA). The fifth patient suffering from SW to head, chest and abdomen with a maximal GCS at POI, presented in the ED with profound shock (systolic blood pressure of 70 mmHg) due to intra-abdominal bleeding. The patient was rushed to theater for damage control surgery (DCS). Post-operative CT, 18 hours after admittance displayed extensive right-sided temporoparietal comminuted fractures with underlying hemorrhagic contusion, edema and midline shift. Since neurological examination revealed a GCS of 3 with non-reactive dilated pupils, further treatment was withheld soon after which the patient died.

In two patients infection complicated their treatment. One patient suffering a temporal SW with a comminuted fracture for which debridement of the track was done, developed hydrocephalus due to an intraventricular hematoma. This was treated with drainage. The ensuing ventriculitis was successfully treated with antibiotic therapy. The second patient conservatively treated for a frontotemporal machete injury, returned 1.5 weeks later with pussy egress from the wound. A contrast enhanced CT scan displayed a small abscess, which was again successfully treated with antibiotics without any additional morbidity.

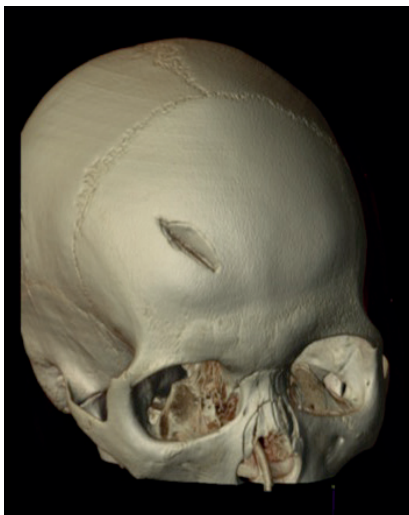## DISCUSSION

With regard to the low incidence levels of penetrating head injuries in Europe, it is hard for trauma surgeons and neurosurgeons to gain experience in the management and treatment of PBI. A global consensus for treatment strategies for PBI remains unclear (1-3,10,21). A proposal for a treatment algorithm of PBI is presented in (Figure 2) based on the data from this study and relevant prior research.





**Figure 2:** Proposed treatment algorithm for patients suspect for suffering PBI penetrating brain injury (PBI), advanced trauma live support (ATLS), computed tomography scan (CT), damage control surgery (DCS), Glasgow coma score (GCS), resuscitation (resus), intensive care unit (ICU).



**Figure 3:** 3D CT skull reconstruction of a "slot fracture" by knife causing PBI

From all patients suspected for PBI, information of the injury mechanism should be obtained. GSW's are HET injuries in which due to the velocity of projectile ( $E=\frac{1}{2}mv^2$ ) more energy is likely to be transferred to the intracranial tissue and thus creating more diffuse injury, compared with SW's (1,3). In SW's with a low energy transfer (LET) the injury is usually limited to the focal track of the penetrated tissue accompanied by a so-called slot fracture of the skull (23-27) (Figure 3). In case of injuries by heavier weapons (machete, axe) there might be a larger compound skull fracture and more, but still focal, soft tissue injury (28-29). In this study, in which both HET and LET PBI were analyzed, there was no significant difference in outcome with respect to mortality and type of PBI (HET versus LET), the frequency of surgical treatment or number of patients with favorable GOS at discharge. All patients with suspected PBI were initially evaluated using ATLS® principles, which also state that in order to assess the patients GCS properly, shock has to be corrected first (21). Large studies such as the IMPACT (30) show that patients suffering from blunt TBI with prolonged shock have a worse outcome than patients who are aggressively resuscitated. We also observed this in PBI with an increasing mortality for an increasing shock level (3,31). Mortality in shock class I, II, and III, was 7%, 13%, and 50%, respectively. In patients suffering additional injuries that require surgical treatment, a CT to assess the PBI is favoured prior to operation. In a transient or non-responder to resuscitation, hemorrhage control should be established via the principles of damage control surgery (DCS) after which the PBI can be evaluated by CT.

Another option for multiple injured patients in severe shock and with clinical presentation of mass lesion effects due to the PBI, might be synchronous DCS by the trauma surgeon and placement of an intracranial pressure (ICP) measurement device with optional diagnostic burr holes followed by craniotomy or craniectomy if needed by the neurosurgeon (18). This treatment strategy might have been option for one of the deceased patients who was suffering from multiple SW to head, chest and abdomen with a maximal GCS at POI, but in profound shock. The patient underwent DCS without neurosurgical care. Post-operative CT 18 hours after admittance

clinical evaluation displayed extensive unsurvivable cerebral injury that might have benefitted from decompression.

In case of a successful resuscitation the GCS should be evaluated. If score does not exceed 3 and the non-sedated patient does not display brainstem reflexes brain death can be diagnosed, with an optional CT to confirm non-survivable brain injury or if available, absence of perfusion. Organ donation should be considered if no major additional injuries are present (31). In case of GCS 3 and over, CT evaluation should be performed as soon as possible. If the treating medical facility is not equipped with a CT scanner, X-ray (two view) or LODOX film might render some information on retained penetrating objects and extend of fractures. No assumptions can be made concerning trajectory due to a possible ricochet effect, nor the extent of soft tissue injuries (32). CT can depict the trajectory, effect of mass lesions such as hematomas and present or developing hydrocephalus or any type of brain herniation. CT-angiography (CTA) can be used to determine vascular injury, dissection or perfusion defects (33). It should be stressed that CT should be made without delay after successful resuscitation in order to evaluate to possible benefit of neurosurgical exploration. In this series there was a fair delay from presentation at the ED until CT evaluation with a median of two hours and 45 minutes. Diminishing these intervals will limit the impact of secondary injury and is likely to improve outcome (18,19,34). Patients suffering injury to brainstem or with a central bihemispheric trajectory of the projectile are known to have a very poor outcome (GOS 1 and 2) and are not likely to benefit from surgical treatment (22,35,36). In this study two patients (GSW) displayed such an injury pattern and were accordingly treated expectantly after which they soon expired. General consensus dictates that all patients suffering from PBI with a GCS >8 displaying effect of a mass lesion, a compound depressed skull fracture or an exteriorized object (e.g., remaining blade) should undergo neurosurgical exploration. If necessary, a craniotomy or craniectomy will be performed for hemorrhage control, evacuation of hematoma, and decompression in case of measured or suspected increased intracranial pressure. This is usually accompanied by ventricular drainage and/or ICP monitoring and if possible watertight closure of the dura in order to minimize infectious complications (1,10,20). In the current study over a third of the operated patients underwent

a wide craniectomy with minimal brain tissue debridement. Two patients developed a cerebral infection, which were successfully treated with prolonged antibiotic therapy in accordance to the current neurosurgical treatment strategies (20). Patients with PBI and post resuscitation GCS between 3 and 8 still form point of discussion whether or not surgical treatment is contraindicated. Some retrospective (European) studies dictate that, since the GOS of these patients is so poor that they present a burden to society and their relatives, and thus should be treated expectantly (7,37). More evidence, both military and civilian studies, however arises that also this group will benefit from aggressive resuscitation and imminent neurosurgical exploration (15-18,38). In the current study from the patients with GCS 3-5 and GCS 6-8, respectively 1 patient (17%) and 4 patients (80%) were operated. Survival for the operated patients was 100% versus 0% survival of the conservatively treated patients with GCS 3-5 (n=5) and only 1 NOM patient with GCS 6-8 survived. A favorable GOS at discharge was noted in six operated patients (67%) with admittance GCS 9-15, one patient (25%) with GCS 6-8 and none with a GCS 3-5.

This contradicts the statement that all patients with a GCS 3-8 should be treated expectantly. Only two (13%) of the operated patients were treated within six hours after presentation on the ED. Although all operated patients survived they might have displayed a better percentage of favorable GOS on hospital discharge, by diminishing the secondary injury through imminent surgery as suggest by in the "time is tissue" article by Lin (18), although no association between GOS and surgical treatment delay was noted in this study.

## CONCLUSION

Civilian PBI can have an excellent in-hospital survival, in this study 89%. PBI with a GCS  $\leq$  8 or brain matter "oozing" are no contra-indications for surgery. Central bihemispheric injuries on the other hand, have a very poor outcome. Well known indications for neurosurgical treatment in blunt TBI, such as mass lesion effect and depressed skull fractures apply for PBI

as well. Damage control resuscitation and surgery with a limited delay for CT scanning are advised to improve survival and GOS.

## REFERENCES

1. Esposito DP, Walker JP. Contemporary management of penetrating brain injury. *Neurosurg Q.* 2009;19:249-54.
2. Part 2. Prognosis in penetrating brain injury. *J Trauma.* 2001;51:S44-86.
3. Aldrich EF, Eisenberg HM, Saydjari C, et al. Predictors of mortality in severely head-injured patients with civilian gunshot wounds: a report from the NIH Traumatic Coma Data Bank. *Surg Neurol.* 1992;38:418-423.
4. Maas AIR, Murray GD, Roozenbeek B, Lingsma HF, Butcher I, McHugh GS, Weir J, Lu J, Steyerberg EW. Advancing the care for traumatic brain injury: summary results from the IMPACT studies and perspectives on future research. *Lancet neurol.* 2013;12:1200-10
5. Kapusta ND, Etzersdorfer E, Krall C, Sonneck G. Firearm legislation reform in the European Union: impact on firearm availability, firearm suicide and homicide rates in Austria. *Br J Psychiatry.* 2007 Sep;191:253-7.
6. Kühne CA, Zettl RP, Baume B., Vogt FM, Taeger G, Ruchholtz S, Stolke D, Nast-Kolb D. Penetrating gunshot injuries to the head and brain. Diagnosis, management and prognosis. *Unfallchirurg* 2007;110:341-350.
7. Petridis AK, Doukas A, Barth H, Mehdorn. Outcome of craniocerebral gunshot injuries in the civilian population. Prognostic factors and treatment options. *Cen Eur Neurosurg* 2011;72:5-14
8. Khalil N, Elwany MN, Miller JD. Transcranial stab wounds: morbidity and medicolegal awareness. *Surg Neurol* 1991;35:294-9
9. Enicker B, Madiba TE. Cranial injuries secondary to assault with a machete. *Injury* 2014;45:1355-1358
10. Part 1: Guidelines for the management of penetrating brain injury. Introduction and methodology. *J Trauma.* 2001;51:S1-6.
11. Cushing H. A study of a series of wounds involving the brain and its enveloping structures. *Br J Surg.* 1918; 5:558-684.
12. Hanigan WC. Neurological surgery during the great war: the influence of Colonel Cushing. *Neurosurgery* 1988;23:283-294.
13. Hammon WM. Analysis of 2187 consecutive penetrating wounds of the brain from Vietnam. *J Neurosurg* 1971;34:127-131
14. Brandvold B, Levi L, Feinsond M, George E. Penetrating craniocerebral injuries in the Israeli involvement in the Lebanese conflict, 1982-1985. *J Neurosurg* 1990;72:15-21
15. Bell RS, Mossop CM, Dirks MS, Stephens FL, Mulligan L, Ecker R, et al. Early decompressive craniectomy from severe penetrating and closed head injury during wartime. *Neurosurg Focus.* 2010; 28(5):E1.

16. Rosenfeld JV, Bell RS, Armonda R. Current Concepts in Penetrating and Blast Injury to the Central Nervous System. *World J Surg* 2015;39:1352-62
17. DuBose JJ, Barmparas G, Inaba K, Stein DM, Scalea T, Cancio LC, Cole J, Eastridge B, Blackbourne L. Isolated severe traumatic brain injuries sustained during combat operations: demographics, mortality outcomes, and lessons to be learned from contrasts to civilian counterparts. *J Trauma* 2011;70(1):11-6
18. Lin DJ, Lam FC, Siracuse JJ, Thomas A, Kasper EM. "Time is brain" the Gifford factor-or: Why do some civilian gunshot wounds to the head do unexpectedly well? A case series with outcomes analysis and a management guide. *Surgical Neurology International* 2012; 98:1-12
19. Charry JD, Rubiano AM, Puyana JC, Carney N, David Adelson P. Damage control of civilian penetrating brain injuries in environments of low neuro-monitoring resources. *Br J Neurosurg.* 2016;30(2):235-9
20. Kazim SF, Shamim MS, Tahir MZ, Enam SA, Wheed S. Management of penetrating brain injury. *J Emerg Trauma Shock.* 2011 Jul-Sep; 4(3): 395-402.
21. Advanced Trauma Life Support © Student Course Manual, 9th edition:162-163
22. Turco L, Cornell DL, Phillips B. Penetrating bihemispheric traumatic brain injury: A collective review of gunshot wounds to the head. *World Neurosurg.* 2017;104:653-59
23. Dempsey LC, Winestock DP, Hoff JT. Stab wounds of the brain. *West J Med* 1977;126:1-4
24. Chibarro S, Tacconi L. Orbito-cranial injuries caused by penetrating non-missile foreign bodies. Experience with eighteen patients. *Acta Neurochir* 2006;148: 937-942
25. Exadaktylos AK, Stettbacher A, Bautz PC. The Value of Protocol-Driven CT Scanning in Stab Wounds to the Head. *Am J Emerg Med* 2002;20: 295-297
26. Gulati A, Srinivasan B, Hunter R, Flood TR. Penetrating knife injury to the frontal lobe - a case report. *Ann R Coll Surg Engl* 2010; 92:1-2
27. Kataria R, Singh D, Chopra S, Sinha VD. Low velocity penetrating head injury with impacted foreign bodies in situ. *Asian J Neurosurg* 2011;(6):39-44
28. Modi M, Arivazhagan A, Bharath RD, Rao MB. Penetrating brain injury with machete, stuck to calvarium: hurdles in imaging and solutions. *J Neurosci Rural Pract.* 2014;5:63-65
29. Enicker B, Madiba TE. Cranial injuries secondary to assault with a machete. *Injury* 2014;45:1355-58.
30. McHugh GS, Engel DC, Butcher I, Steyerberg EW, Lu J, Mushkudiani N, Hernandez AV, Marmarou A, Maas AI, Murray GD. Prognostic value of secondary insults in traumatic brain injury: Results from the IMPACT study. *J. Neurotrauma* 2007;24:287-93

31. Bellal J, Aziz H, Pandit V, Kulvatunyou N, O'Keefe T, Wynne J, Tang A, Friese RS, Rhee P. Improving survival rates after civilian gunshot wounds to the brain. *J Am Coll Surg* 2014;218:58-65
32. Fu CY, Wu SC, Chen RJ. Lodox/Statscan provides rapid identification of bullets in multiple gunshot wounds. *J Emerg Med.* 2008 Oct; 26(8):965.e5-7.
33. Temple N, Donald C, Skora A, Reed W. Neuroimaging in adult penetrating brain injury: a guide for radiographers. *J med radiat Sci* 2015;62:122-131
34. Liebenberg AW, Demetriades AK, Hankins M, Hardwidge C, Hartzenberg BH. Penetrating civilian craniocerebral gunshot wounds: a protocol of delayed surgery. *Neurosurgery* 2005;57:293-99
35. Kim AK, Wang MY, McNatt SA, Pinsky G, Liu Cy, Glannotta SL, Apuzzo MLJ. Vector analysis correlating bullet trajectory to outcome after civilian through-and-through gunshot wound to the head: using imaging cues to predict fatal outcome. *Neurosurgery* 2005;57:737-747
36. Aarabi B, Tofighi B, Kufera JA, Hadley J, Ahn ES, Cooper C, Malik JM, Naff NJ, Chang L, Radley M, Kheder A, Uscinski RH. Predictors of outcome in civilian gunshot wounds to the head. *J Neurosurg* 2014;120:1138-46
37. Hofbauer M, Kdolsky R, Figl M, Grünauer J, Aldrian S, Ostermann RC, Vécsei V. Predictive factors influencing the outcome after gunshot injuries to the head—a retrospective cohort study. *J Trauma* 2010;69:770-75
38. Joseph B, Aziz H, Pandit V, Kulvatunyou N, O'Keefe T, Wynne J, Tang A, Friese RS, Rhee P. Improving Survival Rates after Civilian Gunshot Wounds to the Brain *J Am Coll Surg* 2014;218:58-65.







# Chapter Four

---

van Waes OJF, Cheriex KCAL, Navsaria PH, van Riet PA, Nicol AJ, Vermeulen J.

Management of penetrating neck injuries. BJS 2012;(99) Suppl 1;149-54

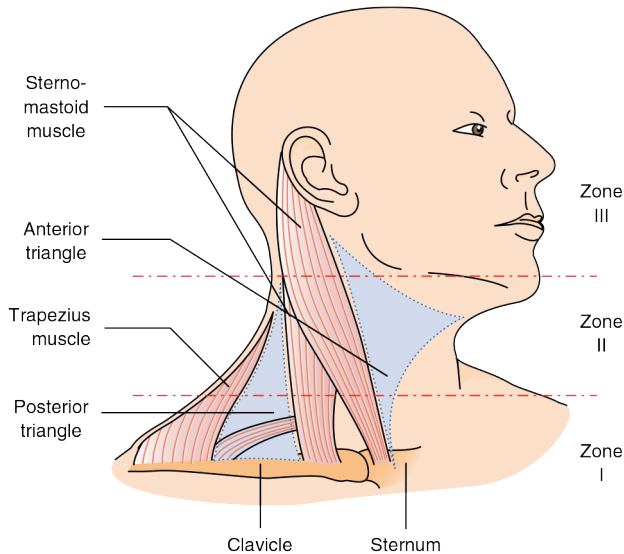
## INTRODUCTION

The low incidence of penetrating neck injury (PNI) in many European countries makes it impossible for trauma surgeons to gain adequate management experience. Moreover, patients with stab injuries or gunshot wounds usually present to the emergency department unannounced, and therefore the local trauma team may not be prepared for immediate clinical assessment, especially in smaller hospitals.

PNI is considered difficult to manage because of the complex anatomy, immediate proximity of vital structures, and potential for rapid haemodynamic and airway deterioration (1-3). A well prepared trauma team is essential to improve the outcome. In the past, routine neck exploration was common practice for these patients, resulting in a large number of unnecessary procedures and iatrogenic injuries (4,5). Based on the experience from high-volume hospitals in developing countries, selective non-operative management (SNOM) is currently the standard of care (6-8). Groote Schuur Hospital in Cape Town, South Africa, is a high-volume, tertiary referral trauma centre managing in excess of 200 patients with PNI each year (6). The centre adheres to a treatment protocol of SNOM for PNI (6). The present study was undertaken to evaluate the SNOM protocol.

## METHODS

All patients presenting with a PNI to the trauma centre in Groote Schuur Hospital, Cape Town, during an interval of 3.5 months (September to December 2009) were included in this prospective observational study. Patients aged over 18 years with a PNI that penetrated the platysma muscle were included. Patients who died within 24 h from other injuries were excluded. Age, sex, mechanism of injury, New Injury Severity Score (NISS), clinical manifestations including presenting vital signs, indications for special investigations, viscera injured, and treatment strategy of all patients were collected prospectively and analysed. All patients were managed and treated according to the local protocol for PNI, as described below (6).



**Figure 1:** Classification of zones of injury for penetrating neck injury. The neck is divided into a posterior and an anterior triangle; the anterior triangle is subsequently divided into three horizontal zones

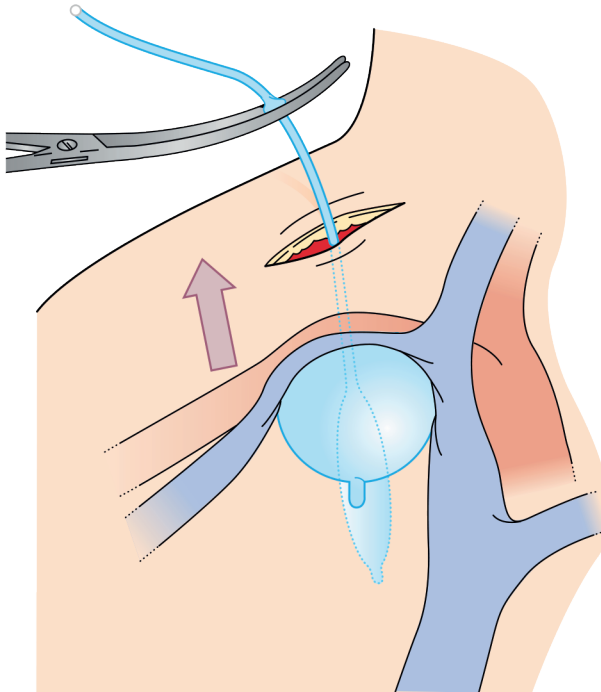
### **Protocol for management of penetrating neck injury**

Patients with penetrating injuries of the neck were resuscitated according to the Advanced Trauma Life Support (ATLS<sup>®</sup>) guidelines. Haemodynamically stable patients and those who became stable after initial simple resuscitation (normal pulse rate, blood pressure, breathing rate, etc.) using 1-2 litres of crystalloid were evaluated with a thorough history and clinical examination. Wounds were classified according to the different anatomical zones of the neck Figure 1 (9). A chest X-ray and a lateral soft tissue shoot-through X-ray of the cervical spine was performed in all patients to look for signs of aerodigestive or vascular trauma. Patients with a transmidline gunshot wound had routine computed tomography angiography (CTA).

Special investigations were requested according to a pre-established neck injury evaluation protocol based on clinical manifestations and findings on the plain cervical spine and chest radiographs Table 1. If any additional investigations were positive and surgical intervention was needed, the patient was transferred immediately to the operating room.

Haemodynamically stable patients with a negative history and clinical examination were admitted to the high-care trauma surgical ward, with haemodynamic and airway monitoring, and clinical neck examination every 4 h by the surgical registrar on call. After 24 h an oral diet was commenced and, if tolerated, the patient was discharged 12 h later. All patients were given a neck injury form that listed alarm signs and symptoms of vascular and/or aerodigestive injuries; if these occurred, patients were advised to return to the hospital immediately.

In haemodynamically unstable patients with a bleeding neck wound, haemorrhage control was attempted by means of Foley catheter balloon tamponade (FCBT)(10,11).



**Figure 2:** Foley catheter balloon tamponade. A Foley catheter is introduced into the bleeding neck wound following the wound track. The balloon is inflated with 10-15 ml water or until resistance is felt. The catheter is clamped to prevent bleeding through the lumen. The neck wound is sutured around the catheter. Continuing bleeding around the catheter is an indication to proceed to surgery

**Table 1:** Symptoms and signs associated with underlying visceral injuries after penetrating neck injury and investigation performed

<b>Structure</b>	<b>Symptoms and signs</b>	<b>Investigation</b>
Vascular	<ul style="list-style-type: none"> <li>- Moderate to large haematoma</li> <li>- Pulsatile stable haematoma</li> <li>- Pulse deficit</li> <li>- Bruit</li> <li>- Any mediastinum changes on CXR</li> <li>- Foley catheter balloon tamponade</li> </ul>	Angiography/CTA
Pharynx/oesophagus	<ul style="list-style-type: none"> <li>- Odynophagia</li> <li>- Dysphagia</li> <li>- Saliva leak from wound</li> <li>- Blood in nasogastric tube</li> <li>- Hematemesis</li> <li>- Subcutaneous emphysema</li> <li>- Prevertebral air on lat cervical spine</li> <li>- Pneumomediastinum on CXR</li> <li>- Lowered consciousness</li> </ul>	Oesophogram/Endoscopy
Larynx/ Trachea/ bronchus	<ul style="list-style-type: none"> <li>- Dysphonia/hoarseness</li> <li>- Tension pneumothorax</li> <li>- Severe surgical emphysema</li> <li>- Persistent air leak from chest drain</li> </ul>	Laryngo-/Bronchoscopy

CTA = Computerized tomography angiography; CXR = Chest X-ray

Figure 2. If control of the bleeding was not achieved, surgical exploration of the neck followed immediately. If haemorrhage was controlled by FCBT and the patient stabilized after resuscitation, angiography was undertaken. Positive findings were treated surgically or using endovascular methods. A venous injury was diagnosed if angiographic findings were normal. If no arterial injury was diagnosed, the patient was observed for 48-72 h, after which the Foley catheter was removed in the operating room. In case of rebleeding, surgical intervention was required.

## RESULTS

A total of 78 patients with PNI presented to the trauma centre during the study interval. One patient died from associated abdominal bleeding within 24 h and was excluded from the study. The median NISS of the 77 included patients was 25 (range 9–59). There were 84 neck wounds in the 77 patients; 61 patients (79 percent) patients had 67 stab wounds, the majority in zone II of the left anterior triangle of the neck Table 2. Fifty-six patients (73 percent) underwent one or more additional investigations because of suspected visceral injury Table 1; 37 patients underwent 38 barium swallows/endoscopic investigations because of suspected oesophageal injury (dysphagia/odynophagia, 17; prevertebral air, 10; odynophagia and prevertebral air, 5; depressed level of consciousness, 3; other, 2). None of the investigations uncovered an oesophageal injury Table 2. In one patient, who underwent emergency surgery because of haemodynamic instability, an oesophageal perforation at the level of the seventh cervical vertebra was found during perioperative oesophagoscopy. The lesion was repaired primarily during neck exploration. No upper airway injuries were found.

**Table 2:** Patients demographics

Patients	77
Male/female	70 / 7
Age, years <sup>1</sup>	26 (17–54)
NISS <sup>1</sup>	25 (9–59)
Mortality	2
Hospital stay, days <sup>1</sup>	2 (1–36)
Penetrating neck injury	
Stab wound	67
Gunshot wound	17
Zone of neck injury	
I	30
II	39
III	7
Posterior triangle	8
Suspected injury	
Vascular	
Angiography <sup>2</sup>	31 (14)
CT-scan <sup>2</sup>	10 (1)
Oesophagus	
Barium swallow <sup>2</sup>	34 (0)
Scopy <sup>2</sup>	4 (1)

1. Values are median (range); 2. Values in parentheses are numbers of additional investigation with positive findings.

NISS = New Injury Severity Score; CT-scan = Computerized tomography scan



A total of ten patients had computed tomography angiography (CTA) Table 3.

In eight, a protocol CTA was performed for a transmidline gunshot injury to the neck, although there were no clinical signs of active bleeding. No vascular injuries were detected. Seven patients with active bleeding from a neck wound were initially treated with FCBT. In one patient haemostasis could not be achieved and urgent surgery was required. The other six, in whom haemostasis was secured, were observed and underwent diagnostic angiography within 24 h. Five of these patients had an arterial injury. Three had surgery (common carotid artery, internal carotid artery, subclavian artery), one had a radiological stent (false aneurysm of subclavian artery) and one was managed conservatively (dissected and occluded vertebral artery). The Foley catheter of both patients who did not need to undergo surgery or stenting was removed in the operating room 2 days after admission. No bleeding occurred on removal of the catheter.

**Table 3:** Indications for additional vascular investigations and arterial injuries detected

Indication for investigation	Investigation	
	Angiography	CTA
Hematoma/blood loss with need for blood supply	8 (4)	
Hematoma/blood loss without blood supply (normal Hb)	6 (0)	
Foley Catheter Balloon tamponade	6 (5)	
Transmidline trajectory without signs of vascular injury		8 (0)
Pulsating Hematoma	4 (3)	
Pulse deficit upper limb	3 (2)	
Hemothorax	1 (0)	1 (1)
Bruit	1 (0)	1 (0)

Values in parentheses are numbers of additional investigation with positive findings.

CTA = Computerized tomography angiography; Hb = Hemoglobin

Besides the patients with FCBT, a further 25 underwent angiography based on standard indications Table 3. Only two patients (3 percent) needed to undergo emergency exploration of the neck because of haemodynamic instability due to bleeding. Subsequently, a further seven patients (9 percent) underwent elective vascular surgery and three (4 percent) were treated

by radiological intervention Table 4. Sixty-five (87 percent) of all patients who were haemodynamically stable, or who could be stabilized after initial resuscitation, were treated successfully conservatively. After conservative observation, none of the patients needed intervention for late onset complications. The median hospital stay was 2 (range 1–36) days. Two patients (3 percent) died from cerebral ischaemia.

**Table 4.** Detected arterial injuries and treatment

Injury at radiography or CTA	Treatment
<b>Carotid artery injuries</b>	
Active bleeding com. carotid a.	Surgery
Arteriovenous fistula com. carotid a. and internal jugular v.	Surgery
Arteriovenous fistula int. carotid a. and jugular v.	Surgery
False aneurysm ext. carotid a.	Conservative
Dissected int. carotid a., without active bleeding	Conservative
<b>Central subclavian artery injuries</b>	
Dissected subclavian a. with active bleeding	Surgery
False aneurysm subclavian a.	Surgery
False aneurysm subclavian a.	Surgery
False aneurysm subclavian a.	Stenting
<b>Peripheral arterial injuries</b>	
Occlusion brachial a.	Surgery
False aneurysm costovertebral branch of subclavian a.	Stenting
Active bleeding lingual a.	Stenting
Occlusion vertebral a.	Conservative
Dissected vertebral a., without active bleeding	Conservative
Mammary a. lesion	Conservative

CTA = Computerized tomography angiography; Hb = Hemoglobin

One patient had a transmidline gunshot injury, and did not wake up after general anaesthesia for an emergency tracheostomy. The second patient had a stab injury and underwent primary reconstruction of the carotid artery, but post operative brain CT showed multiple infarcts and the patient was declared brain-dead 5 days later.

## DISCUSSION

Owing to the low incidence of PNI in Europe, it is seldom possible for a trauma surgeon to gain experience in its management and treatment. In the past, routine neck exploration was the standard

treatment for PNI, which led to a high rate of negative neck exploration (a quarter of patients) and significant associated morbidity (half of patients) (6,8,12,13).

In high-volume trauma centres, SNOM is becoming accepted for PNI. It is based on clinical examination and additional investigations (13,14). Together, they have been shown to be reliable indicators of clinically significant injury, with a sensitivity of 93-95 percent and a negative predictive value of 97 percent (13-17).

To achieve optimal treatment a hospital must have a well organized and dedicated traumateam. All of the patients described in the present study presented to Groote Schuur Hospital, Cape Town, which is a high-volume, tertiary-referral trauma centre where a multidisciplinary management approach for this kind of trauma is guaranteed. The protocol for assessing and treating patients with PNI is based on haemodynamic and airway status, together with a thorough physical examination. The initial management of gunshot and knife injuries is similar, as previous studies found no significant difference in the rate of successful SNOM between them (6,15). Transmidline gunshot wounds, however, have a significantly higher rate of injury than other PNIs (18). In the present study, eight patients with a transmidline gunshot wound underwent CTA, yet none had vascular, oesophageal or tracheal injuries, and all were treated successfully conservatively. Mandatory neck exploration would not have been useful. The value of routine CTA in patients with transmidline gunshot wounds remains debatable, especially when the patient is fully conscious (15).

Oesophageal injuries are uncommon and difficult to detect early, because clinical findings are not always obvious (19,20). More than 90 percent of patients survive when the diagnosis is made within 24 h, but thereafter the survival rate drops quickly (20). Because the consequences of a missed oesophageal lesion are great, additional investigations are often done, even when the suspicion is low. Missed pharyngeal lesions are less likely to be fatal than oesophageal lesions (21,22). Pharyngeal lesions

can usually be treated conservatively with antibiotics alone, whereas oesophageal lesions needs surgery(22-24).

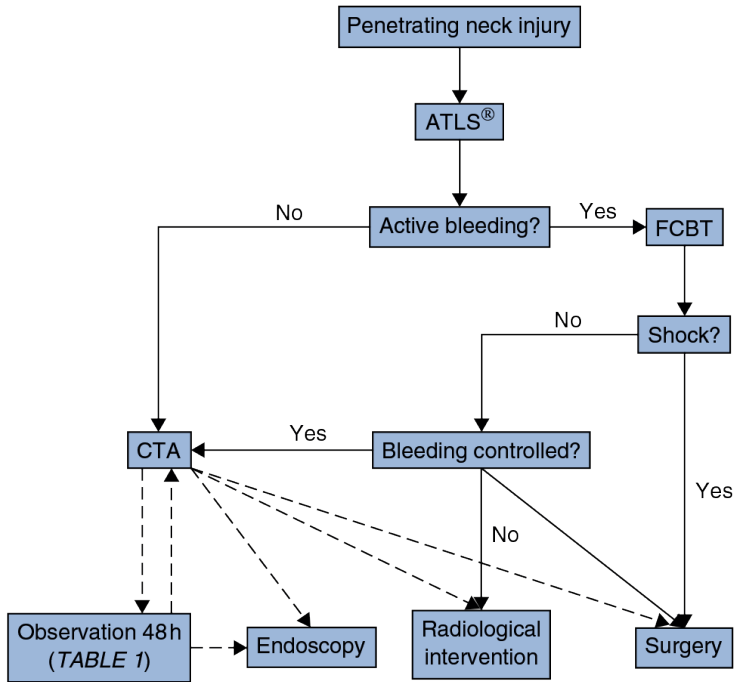
Vascular injuries were common in the present study. Even when vascular symptoms are present after PNI, emergency surgery is often not necessary. In patients with active haemorrhage, FCBT is indicated. Patients who are successfully stabilized with FCBT can subsequently undergo semiurgent diagnostic angiography or CTA(10,11). Venous injuries are particularly amenable to FCBT, and in these patients it is often definitive treatment(10). Emergency neck exploration is indicated only for the haemodynamically unstable, actively bleeding patient in whom FCBT was unsuccessful. In the present study, of seven unstable patients in whom FCBT was attempted, six stabilized and could undergo diagnostic angiography(25). In two patients FCBT was the definitive treatment as no rebleeding occurred on removal of the catheter. Furthermore, none of the patients who were treated conservatively bled from a missed vascular injury. All of these findings indicate that initial SNOM of PNI is a feasible and safe approach (10,11,25,26).

An alternative to conventional angiography is CTA. Experience with CTA was limited in the institution at the time of the study, and was not often available after office hours. An advantage of using diagnostic angiography, however, is the possibility of proceeding to intervention (coiling or stenting), if indicated, during the same session.

Nevertheless, for diagnostic evaluation of PNI, CTA has several advantages: it is relatively fast, minimally invasive, and has fewer potential complications(1,13,27). It is readily available in most trauma centres in Western countries. It is reliable and accurate, with a sensitivity and specificity of 90 and 100 percent respectively, with a positive predictive value of 100 percent and a negative predictive value of 98 percent(1,13,27). CTA is therefore becoming the diagnostic tool of choice during initial evaluation of stable patients with vascular injury.

The results of the present study suggest that the proposed algorithm Figure 3 should be appropriate for the management

of penetrating neck injury in most trauma departments. The low failure rate also validates the SNOM protocol for initial management.



**Fig. 3** Algorithm for initial management of patients with penetrating neck injury. ATLS®, Advanced Trauma Life Support; FCBT, Foley catheter balloon tamponade; CTA, computed tomography angiography

## REFERENCES

1. Munera F, Cohn S, Rivas LA. Penetrating injuries of the neck: use of helical computed tomographic angiography. *J Trauma* 2005; 58: 413-418.
2. Thal ER, Meyer DM. Penetrating neck trauma. *Curr Probl Surg* 1992; 29: 51-56.
3. Tallon JM, Ahmed JM, Sealy B. Airway management in penetrating neck trauma at a Canadian tertiary trauma centre. *CJEM* 2007; 9: 101-104.
4. Demetriades D, Asensio JA, Velmahos G, Thal E. Complex problems in penetrating neck trauma. *Surg Clin North Am* 1996; 76: 661-683.
5. Apffelstaedt JP, Muller R. Results of mandatory exploration for penetrating neck trauma. *World J Surg* 1994; 18: 917-919.
6. Thoma M, Navsaria PH, Edu S, Nicol AJ. Analysis of 203 patients with penetrating neck injuries. *World J Surg* 2008; 32: 2716-2723.
7. Ngakane H, Muckart DJ, Luvuno FM. Penetrating visceral injuries of the neck: results of a conservative management policy. *Br J Surg* 1990; 77: 908-910.
8. Gouleke P, Goldstein A, Sclafani S, Mitchell W, Shaftan G. Routine versus selective exploration of penetrating neck injuries: a randomized prospective study. *J Trauma* 1984; 24:1010-1014.
9. Roon AJ, Christensen N. Evaluation and treatment of penetrating cervical injuries. *J Trauma* 1979; 19: 391-397.
10. Navsaria P, Thoma M, Nicol A. Foley catheter balloon tamponade for life-threatening hemorrhage in penetrating neck trauma. *World J Surg* 2006; 30: 1265-1268.
11. Gilroy D, Lakhoo M, Charalambides D, Demetriades D. Control of life-threatening haemorrhage from the neck: a new indication for balloon tamponade. *Injury* 1992; 23: 557-559.
12. Tisherman SA, Bokhari F, Collier B, Cumming J, Ebert J, Holevar M et al. Clinical practice guideline: penetrating zone II neck trauma. *J Trauma* 2008; 64: 1392-1405.
13. Osborn RM, Bell RB, Qaisi W, Long WB. Computed tomographic angiography as an aid to clinical decision making in the selective management of penetrating injuries to the neck: a reduction in the need for operative exploration. *Trauma* 2008; 64: 1466-1471.
14. Atteberry LR, Dennis JW, Menawatt SS, Frykberg ER. Physical examination alone is safe for evaluation of vascular injuries in penetrating zone II neck trauma. *J Am Coll Surg* 1994; 179: 657-662.

15. Sofianos C, Degiannis E, Van der Aardweg MS, Levy RD, Naidu M, Saadia R. Selective surgical management of zone II gunshot injuries to the neck: a prospective study. *Surgery* 1996; 120: 785-788.
16. Gonzalez RP, Falimirski M, Holevar MR, Turk B. Penetrating zone II neck injury: does dynamic computed tomographic scan contribute to the diagnostic sensitivity of physical examination for surgically significant injury? A prospective blinded study. *J Trauma* 2003; 54:61-64.
17. Azuaje RE, Jacobson LE, Glover J, Gomez GA, Rodman GH Jr, Broadie TA et al. Reliability of physical examination as a predictor of vascular injury after penetrating neck trauma. *Am Surg* 2003; 69: 804-807.
18. Demetriades D, Theodorou D, Cornwell E, Asensio J, Belzberg H, Velmahos G et al. Transcervical gunshot injuries: mandatory operation is not necessary. *J Trauma* 1996; 40: 758-760.
19. Demetriades D, Theodorou D, Cornwell EE, Berne TV, Asensio J, Belzberg H et al. Evaluation of penetrating injuries of the neck: prospective study of 223 patients. *World J Surg* 1997; 21: 41-47.
20. Bladergroen MR, Lowe JE, Postlethwait RW. Diagnosis and recommended management of esophageal perforation and rupture. *Ann Thorac Surg* 1986; 42: 235-239.
21. Thompson EC, Porter JM, Fernandez LG. Penetrating neck trauma: an overview of management. *J Oral Maxillofac Surg* 2002; 60: 918-923.
22. Stanley RB Jr, Armstrong WB, Fetterman BL, Shindo ML. Management of external penetrating injuries into the hypopharyngeal-cervical esophageal funnel. *J Trauma* 1997; 42: 675-679.
23. Normando R, Tavares MAF, Azevedo IU, Modesto A, Janahu AJL. Mediastinitis from perforation and rupture of the thoracic esophagus. *Rev Col Bras Cir* 2006; 33: 361-364.
24. Vogel SB, Rout WR, Martin TD, Abbitt PL. Esophageal perforation in adults: aggressive, conservative treatment lowers morbidity and mortality. *Ann Surg* 2005; 241: 1016-1021.
25. Ball CG, Wyrzykowski AD, Nicholas JM, Rozycki GS, Feliciano DV. A decade's experience with balloon catheter tamponade for the emergency control of hemorrhage. *Trauma* 2011; 70: 330-333.
26. Larsen DW. Traumatic vascular injuries and their management. *Neuroimaging Clin N Am* 2002; 12: 249-269.
27. Schroeder JW, Baskaran V, Aygun N. Imaging of traumatic arterial injuries in the neck with an emphasis on CTA. *Am Soc Emergency Radiol* 2009; 17: 109-122.





# Chapter Five

---

van Waes OJF, Halm JA, Van Imhoff DI, Navsaria PH, Nicol AJ, Verhofstad MHJ, Vermeulen J.

Selective nonoperative management of penetrating thoracic injury. *Eur J Emerg Med* 2018;25(1):32-8

## INTRODUCTION

Thoracic penetrating injury causes up to a fifth of all non-natural deaths (1-3). The number of patients suffering from penetrating thoracic injuries (PTI) is low in Western Europe compared to the urban trauma centers of the USA or South Africa (4-8). Studies of treatment strategies in penetrating trauma of the chest are rare. Based on the experience with penetrating trauma in a high volume tertiary referral center for penetrating trauma, we have initiated a penetrating thoracic injury treatment protocol on which we have previously reported (9). In the current study the success rate of selective non-operative management (SNOM) using protocolled management strategies and the survival after PTI were prospectively analyzed.

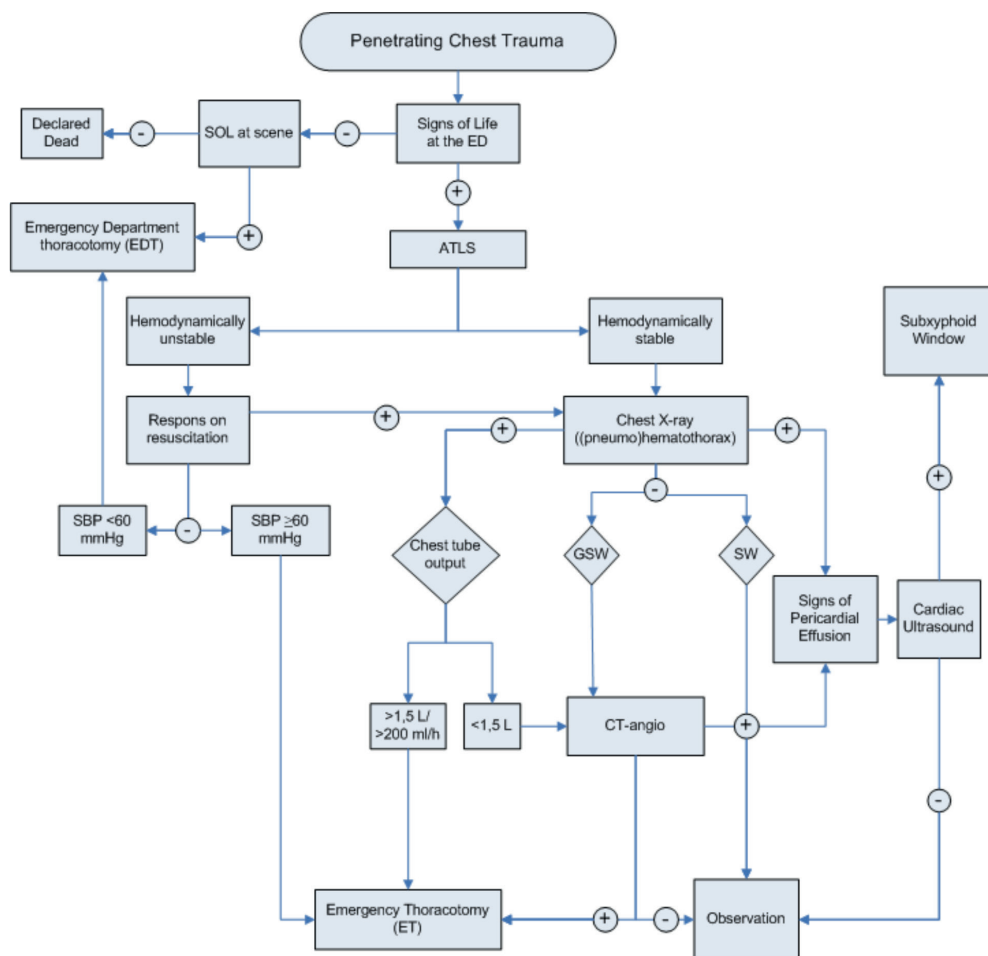
## METHODS

All consecutive patients with PTI presenting to the Trauma Center of the Groote Schuur Hospital, Cape Town, from April 1 through August 30, 2012 were included in this prospective observational study. Approval for data collection was obtained from local research ethics committee. Age, gender, mechanism and type of injury, New Injury Severity Score (NISS), clinical manifestations including pre-hospital and presenting vital signs, additional investigations, treatment strategy and outcome of all patients were collected and analyzed. All patients were managed and treated according to an institutionalized protocol for PTI (Figure 1). All calculations and statistical analyses were performed using SPSS statistics version 21.0. Continuous data were non-parametric, and are presented as median with  $P_{25}$ - $P_{75}$ . Categorical data are shown as numbers with percentages. Statistical significance of difference between  $p < 0.001$  and  $p < 0.05$  was assessed using a Mann-Whitney U-test for continuous data and a Chi-Squared test or Fisher Exact test for categorical data.

### **Protocol for management of penetrating thoracic injury**

All patients were considered at risk for a PTI if they sustained stab wounds (SW) ranging cranially from neck, the sternum or clavicles to caudally the level of the twelfth rib on the

anterior side of the patient and posteriorly from the lower neck to twelfth rib. For gunshot wounds (GSW) these margins were increased judiciously (including the groin region anteriorly and buttocks posteriorly) to account for bullet-track-injury. Special attention was paid to inspection of body creases and folds. If the patients were suspected for PTI according to the abovementioned definitions they were assessed and resuscitated according to the ATLS® guidelines (10) and subsequently managed according to the local PTI protocol.



**Figure 1:** Summary of local protocol for resuscitation and initial treatment of patients sustaining penetrating thoracic injury

SOL=signs of life; ED=emergency department; ATLS®=advanced trauma life support; SBP= systolic blood pressure; GSW=gunshot wound; SW=stab wound; CT=computed tomography

A resuscitative anterolateral emergency department thoracotomy (EDT) was indicated for patients who presented with loss of signs of life (SOL) but with a witnessed cardiac arrest less than 15 minutes before. Witnessed loss of SOL in the ED or a persistent systolic hypotension <60 mmHg (severe shock) despite aggressive resuscitation also warranted an EDT. All hemodynamically stable patients (systolic >90 mmHg) and patients stabilized after resuscitation from moderate shock (systolic BP >60 mmHg and <90 mmHg) underwent a plain chest X-ray as part of ATLS® protocol. Chest drainage of more than 1500 ml of blood immediately or more than 200 ml per hour over the next several hours accompanied by hemodynamically instability was an indication for urgent thoracic surgery (UTS).

Computed tomography angiography (CTA) was indicated for patients with a SW with significant drainage (>500 ml) directly after insertion of chest drain to assess whether or not the injury was suitable for SNOM. All hemodynamically stable patients with a GSW underwent additional CTA to exclude a mediastinal injury.

Signs of a pericardial effusion on chest X-ray (e.g. globular heart, straightened left heart border) needed confirmation by CTA or trans-thoracic ultrasound (US). Patients with clinical signs of tamponade underwent urgent median sternotomy. Patients with pericardial effusion without clinical signs of tamponade were planned for drainage through a subxyphoid window (SXW) after 24-hours. These patients were admitted to the high-care trauma ward for hemodynamic and airway monitoring as well as clinical wound and chest drainage examination every four hours.

There were four different types of surgical intervention. 1. A resuscitative anterolateral left sided thoracotomy performed in the shock room at the emergency department (EDT). 2. Urgent thoracic surgery (UTS) was performed for patients responding to resuscitation with vital parameters (e.g. systolic blood pressure above 60 mmHg), which allowed transport to the operation theater for definite care of life-threatening injuries, e.g. an urgent SXW or massive blood loss after chest drainage. 3. A planned SXW was performed after 24-hours in hemodynamically stable patients with pericardial effusion. 4. The last group

consisted of patients who required late (>48 hours) surgical treatment such as video assisted thoracic surgery (VATS) or thoracotomy for retained clot, empyema or persistent air leakage as well as SXW procedure for delayed pericardial tamponade.

## RESULTS

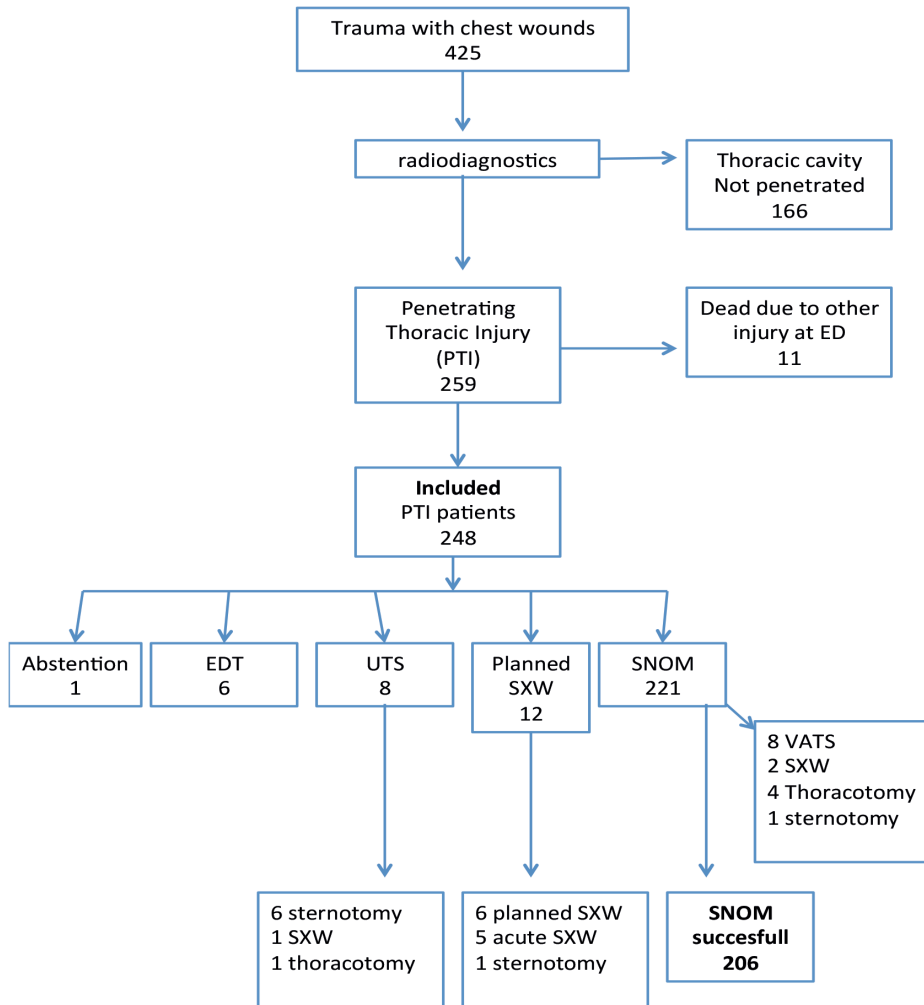
### Demographics

Over a 5-month period 425 patients were presented with chest injuries of which 259 patients were diagnosed with PTI. Of these 259 patients 188 presented with stab wounds, 66 with one or more gunshot wounds, and five patients with a combination of both GSW and SW. Eleven patients deceased in the ED from associated injuries: 6 of these suffered from un-survivable traumatic brain injury and five died from a major extra thoracic vascular injury not responding to resuscitation. These patients were excluded from the study, leaving 248 patients included for analysis (Figure 2).

The patients with PTI had a median age of 27 years ( $P_{25}$ - $P_{75}$  21-32) and 239 (96.4%) patients were males. Nearly half of the patients (n=124) presented with isolated injury to the chest. Associated injuries were predominantly to the head, neck and face 23.4% (n=58), extremities 19.8% (n=49) and abdomen 17.7% (n=44).

Most patients (n=157) were referred from local community medical facilities or non-trauma specialized hospitals (63.3%). The remainder of patients was transferred directly from the accident scene. Seven out of the eleven patients excluded from this study that died at the ED due to others injuries then PTI were referred from another medical facility. Three from the five patients, who died during treatment of their PTI, were referrals. The point of origin proved not significantly different (directly from injury scene versus referral) ( $p=1.000$ ). Of the patients requiring admission, 70.6% (n=175) underwent chest tube drainage for a hemopneumothorax. In 51 patients (20.6%), fitted with a chest tube prior to arrival on the ED, an additional thoracic drain was placed on the ED. Most patients arrived at the ED with normal blood pressures. Only 5 patients (2.2%) were in severe shock, and 26 (11.6%) in moderate shock upon arrival at the ED.

From 23 patients no initial systolic blood pressure was recorded. None of the patients with severe shock died, 7.7% of patients with moderate shock (2 out of 26) died, whereas only 1% (n=2) of normotensive patients eventually died. These differences were not found to be statistically significant ( $p= 0.052$ ).



**Figure 2:** Study inclusion flowchart

ED=emergency department; SXW=subxyphoid window; VATS=video assisted thoracoscopy

### **Selective non-operative management (SNOM)**

Of all patients with PTI 89.1% (n=221) were primarily treated with SNOM. SNOM treatment failed in 6.8% of these patients (n=15). Eight patients required video assisted thoracic surgery (VATS) to treat late onset PTI complications: empyema (n=3), clotted hemothorax (n=4), and a combination of persistent air leakage with empyema (n=1). CT scan confirmed the need for VATS in these eight patients. Two patients developed thoracic sepsis and were treated by wash out of the chest through thoracotomy. Two other patients underwent a thoracotomy for massive residual cloth removal. Three patients, who had already been discharged from hospital for several days, returned to the ED with signs of cardiac tamponade and needed to undergo SXW procedure for drainage. One of them revealed a positive SXW and hence needed conversion to a sternotomy with myocardial repair. None of the patients primarily selected for SNOM died and therefore overall survival of the SNOM group was 100 percent.

The median NISS was significantly lower, 9 ( $P_{25}$ - $P_{75}$  5-13) for the patients in whom SNOM was successful (n=206) compared with those who required surgical intervention 25 ( $P_{25}$ - $P_{75}$  18-32) (n=41)  $p<0.0001$ .

### **Surgical interventions**

Results of surgical interventions are listed in Table 1. Six patients underwent EDT, because of loss of signs of life (n=4) or because of being non-responders to resuscitation (n=2). Three patients that underwent EDT survived (50%). Two survivors were successfully treated for cardiac tamponade, which caused loss of SOL. One patient, in extremis, survived thoracic hemorrhage by clamping the lung hilum after which definitive surgical treatment of the lung injury was performed in the operating room. A fourth non-responder to initial resuscitation did not receive an EDT, since the treating physician deemed a massive hemothorax non-survivable.

UTS was performed in eight patients and comprised six sternotomies, 1 SXW, and 1 thoracotomy (Table 1). One patient died after emergency left-sided thoracotomy for unexpected asystole while performing neck exploration for penetrating injury. The

**Table 1.** Emergency and planned surgical procedures for patients after PTI

<b>Procedure</b>	<b>Sub type</b>	<b>Indication</b>	<b>Findings / treatment</b>	<b>Survival</b>
Emergency department thoracotomy (EDT) (n=6)	Anterolateral thoracotomy (n=6)	Loss of SOL (n=4)  Non-responder to resuscitation (n=2)	Tamponade with myocardial injury with 2x successful suture repair 1x unsuccessful,, lung hilum successful clamped (n=1)  Gross cardiovascular injury beyond repair (n=2)	50%
Urgent Thoracic Surgery (UTS) (n=8)	Sternotomy (n=6)  SXW (n=1)  Thoracotomy (n=1)	Subclavian artery injury control (n=1)  medinastinal vascular injury (n=2)  cardiac injury (n=2)  shock with suspected pericardial effusion (n=1)  Exploratory SXW for transthoracic GSW (n=1)  Severe shock with neck and thoracic SW, died in theater (n=1)	Subclavian artery injury repair (n=1)  Primary vascular repair (n=2)  Primary cardiac suture repair (n=2)  Rinsing pericardium without repair (n=1)  Rinsing pericardium without repair (n=1)  Negative exploratory thoracotomy for asystole during neck exploration (n=1)	87.5%
Planned SXW (n=12)		Pericardial effusion without clinical signs (n=6)  Clinical deterioration while planned for SXW (n=5)  Sternotomy (n=1)	Rinsing pericardium without repair (n=6)  Rinsing pericardium without repair (n=5)  Hemopericardium conversion of SXW to sternotomy for ventricular repair (n=1)	100%



**Table 1.** Continued

Surgery for complications after SNOM (n=15)	VATS (n=8)	Retained cloth (n=5), empyema (n=3), air leakage and empyema (n=1)	Irrigation and drainage (n=8), irrigation, drainage and wedge resection (n=1)	100%
	Thoracotomy (n=4)	Empyema with sepsis (n=2)	Decortication with irrigation and drainage (n=4)	
	SXW (n=2)	Large retained cloth (n=2)	Rinsing pericardium without repair (n=2)	
	Sternotomy (n=1)	Delayed tamponade (n=2)	Successful suture repair (n=1)	
		Clinical worsening + CT pericardial effusion		

SOL=signs of life; SXW=subxyphoid window; VATS=video assisted thoracoscopy

thoracotomy did not reveal any lethal intra-thoracic injury. Six sternotomies were performed. Three patients required sternotomy for proximal vascular control. In two patients exhibiting signs of cardiac tamponade, sternotomy revealed a penetrating cardiac injury, which could be successfully sutured. One patient with suspected cardiac tamponade underwent a negative sternotomy. A SXW procedure was performed as UTS in a patient after a transthoracic GSW resulting in a pneumohemo-pericardium. After evacuating 50 ml of blood, no ongoing bleeding was noted and was consequently treated by drainage alone and observation.

Twelve patients with diagnosed pericardial effusion, but without signs of tamponade, were planned for SXW procedure after 24-hours according the local protocol. Six patients awaiting their planned SXW displayed acute clinical deterioration on the ward (hypotension or tachycardia) and therefore underwent acute SXW. One of these patients needed conversion to sternotomy, which revealed injury to the right ventricle amiable for suture-repair. The other six patients could be treated by SXW pericardial drainage alone and close observation in the high care ward afterwards. After an uneventful observation of twelve hours the pericardial drain was removed in all patients without complications. All 12 patients who were initially planned for delayed SXW survived.

## DISCUSSION

This study displayed that patients suffering from PTI who reach the ED with signs of life have an excellent change of survival (98%), with only 1 out of 10 patients requiring surgical intervention. Only 15 patients (6.8%) failed their initial SNOM but without additional mortality.

Pre-hospital mortality for patients with PTI is as high as 75% (11). In contrast, in-hospital outcome after PTI is reported to be very good (12). The in-hospital mortality after PTI was only 2.0% (5/248) in this study. A selection bias might be suggested since a large number of patients (63.3%) are referred from outside care facilities. In Europe and America most patients are directly transferred from the incident scene to the ED of the nearest trauma center without a primary assessment and treatment in a local medical facility (3,7,9). Point of origin was however not significantly different in this study for the deceased patients. A possible other explanation for the high in-hospital survival rate in this study may be the relative high incidence of SW (75%), as compared to other studies in which up to 60% of all PTI patients are injured by GSW (2,12-14).

This study confirms that most PTI could be treated conservatively by SNOM principles as has been published (3,5,11-13). Eighty-three percent (n=206) could be managed successfully by observation alone, possibly with chest drainage as only treatment.

Using ATLS® guidelines and an institutionalized protocol, PTI patients were selected for SNOM or necessary surgical treatment. CTA was the diagnostic adjunctive of choice in hemodynamically stable patients with PTI due to GSW's or with a significant hemothorax. CTA has an excellent sensitivity of 95% and predictive value of 98% to rule out occult injuries that might impede SNOM (15-17). SNOM had a success rate of 93.2%. Only fifteen patients failed SNOM, because of the late onset of complications, which could be treated subsequently without any mortality.

The use of VATS for the treatment of persistent clot and for washout of pleural empyema has been widely advocated (18-21).

Eight patients initially treated non-operatively needed to undergo VATS to treat late onset complications after PTI. VATS procedure led to an uneventful recovery. Two of the patients in which SNOM failed had already been discharged from hospital but returned to the ED several days later because of new signs of cardiac tamponade and needed treatment.

Delayed cardiac tamponade is a potentially lethal complication of PTI. Being a rare entity, it has only been described in small series or case reports (22-24). The question is whether all patients with PTI need to undergo standard additional diagnostic investigations such as trans-esophageal ultrasound or CTA to rule out pericardial effusion. Three patients with a pericardial effusion were missed. One admitted and two already discharged without noted pericardial effusion. Trans-esophageal ultrasound is less suitable for repetitive screening for pericardial effusion since the patient usually needs to be sedated (25-27). Although US is advocated as an accurate and sensitive tool to detect a hemopericardium (28-31) the presence of hemothorax and/or pneumopericardium confounds the interpretation of US and may lead to high number of false negative investigations. In case of equivocal US results or the presence of a hemothorax, CT is the adjunctive of choice to screen for occult penetrating cardiac injuries or repeat US at 24 hours once the hemothorax has cleared (32). In only 10.4% of all patients presenting with diagnosed PTI, there was a primary indication for surgical treatment; EDT (2.4%), UTS (3.2%), planned SXW (4.8%). A planned SXW was reserved for those patients with ultrasound (or CT) proven pericardial effusion, but without hemodynamic instability. Nevertheless, in six of the twelve patients with noted pericardial effusion that were initially hemodynamically stable during their stay and management on the ED showed unexpected clinical deterioration on the ward and subsequently needed an acute SXW. None of these six patients suffered additional morbidity after acute SXW. When intensive observational care is guaranteed, a planned SXW is a safe management strategy in hemodynamically stable PTI patients with pericardial effusion (33,34). It should be mentioned that in contrast to trauma populations in Western Europe or America, pericardial effusion in South Africa might be caused by tuberculosis, which explains the high rate (91.7%) of negative

planned SXW (35). Although potentially lethal as shown in prior research, PTI has a low in hospital mortality rate of 2.0% (three EDT, one UTS, and one abstained patient) in this series. A judicious use of clinical protocol and adjuncts will render a high success rate of SNOM (93.2%) thereby limiting unnecessary surgical explorations with possible (iatrogenic) complications. On the other hand aggressive surgical resuscitation including low threshold for EDT might contribute to this high survival rate for PTI.

## **CONCLUSION**

PTI has a low in-hospital mortality rate of only 2.0%. Only 16.5% (41/248) of the patients presenting with PTI will need surgical treatment. The other patients are safe to be treated conservatively according to a protocolised SNOM approach for PTI without any additional mortality. Conservative treatment of patients that were selected for this non-operative treatment strategy with repeated clinical re-assessment was successful in 93.2%.

## REFERENCES

1. MacKenzie EJ. Epidemiology of injuries: current trends and future challenges. *Epidemiol Rev* 2000;22(1): 112-9.
2. LoCicero J, 3rd, Mattox KL. Epidemiology of chest trauma. *Surg Clin North Am* 1989;69(1): 15-9.
3. von Oppell UO, Bautz P, de Groot M. Penetrating thoracic injuries: what have learnt. *Thorac Cardio Surg* 2000;48:55-61
4. Mattox KJ, Feliciano DV, Burch J, Beall AC, Jordan GL jr, Debakey ME. Five thousand sevenhunderd sixty cardiovascular injuries in 4459 patients. *Ann surg* 1989;209(6):698-705
5. Asensio JA, Navarro Soto S, Forno W, Roldan G, Petrone P, Gambaro E, Salim A, Rowe V, Demetriades D. Penetrating cardiac injuries: a complex challenge. *Surg Today* 2001;31:1041-53
6. Soreide K, Soiland H, Lossius HM, Vetrhus M, Soreide JA, Soreide E. Resuscitative emergency thoracotomy in a Scandinavian trauma hospital, is it justified? *Injury* 2007;38(1):34-42
7. Kandler K, Konge L, Rafiq S, Larsen CT, Ravn J. Emergency thoracotomies in the largest trauma center in Denmark: 10 years experience. *Eur J Trauma Emerg Surg* 2012;38:151-6
8. NCS of the German Trauma Society (DGU) / AUC-academy of Trauma Surgery GmbH. *TraumaRegister DGU® Annual Report 2013*.
9. van Waes OJF, van Riet PA, Van Lieshout EMM, Den Hartog D. Immediate Thoracotomy for penetrating injuries: ten years' experience at a Dutch level I trauma center. *Eur J Trauma Emerg Surg* 2012;38:543-51
10. American College of Surgeons Committee on Trauma (2004) *Advanced trauma life support program for doctors, 9th edn*. American College of Surgeons, Chicago
11. Clarke DL, Quazi MA, Reddy K, Rutherford Thomson S. Emergency operation for penetrating thoracic trauma in a metropolitan surgical service in South Africa. *J Thorac Cardio vasc Surg* 2011;142:563-8
12. Mandal AK, Sanusi M. Penetrating chest wounds: 24 years experience . *World J Surg* 2001;25:1145-9
13. Mollberg NM, Tobachnick D, Lin FJ, Merlotti GJ, Varghese TK, Arensman RM, Massad MG. Age-associated impact on presentation and outcome for penetrating thoracic trauma in the adult and pediatric patient populations. *J Trauma Acute Surg*. 2014;76(2):273-7
14. Onat S, Ulku R, Avci A, Ates G, Ozcelik C. Urgent thoracotomy for penetrating chest trauma: analysis of 158 patients of a single center. *Injury*. 2010;41(7): 876-880.

15. O' Conner JR, Scalae TM. Penetrating thoracic great vessel injury: impact of admission hemodynamics and preoperative imaging. *J Trauma* 2010;68(4):834-7
16. de Vries CS, Africa M, Gebremariam FA, van Rensburg JJ, Otto SF, Potgieter HF. The imaging of stab injuries. *Acta Radiol.* 2010;51(1): 92-106.
17. Nunez DB Jr, Torres-Leon M, Munera F. Vascular injuries of the neck and thoracic inlet: helical CT-angiographic correlation. *Radiographics.* 2004;24(4):1087-98
18. Lang-Lazdumski L, Mouroux J, Pons et al. Role of thoracoscopy in chest trauma. *Am Thorac Surg.* 1997;63:327-33
19. Heniford BT, Carrillo EH, Spain DA, Sosa JL, Fulton RL, Richardson JD. The role of thoracoscopy in the management of retained thoracic collections after trauma. *Am Thorac Surg.* 1997;4:940-3
20. Billeter AT, Druen D, Franklin SA, Smith JW, Wrightso W, Richardson JD. Video-assisted thoracoscopy as an important tool for trauma surgeons: a systematic review. *Langenbecks Arch Surg.* 2013;4:515-23
21. Navsaria PH, Vogel RJ, Nicol AJ. Thorascopic evacuation of retained post traumatic hemothorax. *Ann Thorac Surg.* 2004;78:282-5
22. Harris DG, Janson JT, van Wyk J, Pretorius J, Rossouw GJ. Delayed pericardial effusion following stab wounds to the chest. *Eur J Card Thor Surg.* 2003;23:473-6
23. Gonzalez Enriquez S, Gonzalez Fernandez C, Rodriguez Entem F, Garagarza JMSJ, Duran RM. Delayed pericardial tamponade after penetrating chest trauma. *Eur J Emerg Med.* 2005;12:86-8
24. Huis in 't Veld, Halm JA, van Waes OJF. Een late pericardiale tamponade na penetrerend thoraxletsel 'Shaved and saved by the cold blue steel'. *Ned Tijdschr Traum.* 2012;5:149-52
25. Porembka DT, Johnson DJ, Hoit BD, Reising J, Davis K Jr, Koutlas T. Penetrating cardiac trauma: a perioperative role for transesophageal echocardiography. *Anest Analg.* 1993;77:1275-7
26. Parasramka SV, Ghotkar S, Kendall J, Fabri BM. Use of transoesophageal echocardiography in management of penetrating cardiac injury. *Eur J Echocardiography.* 2008;9:563-4
27. ASA task force on perioperative transesophageal echocardiography. Practice guidelines for perioperative transesophageal echocardiography. *Anesthesiology.* 2010;112:1-13
28. Plummer D, Bunette D, Asinger R, Ruiz E. Emergency department echocardiography improves outcome in penetrating cardiac injury. *Ann Emerg Med.* 1992;21:709-12

29. Aaland M, Bryan FC, Sherman R. two dimensional echocardiogram in hemodynamically stable victims of penetrating precordial trauma. *Am Surg.* 1994;60:412-15
30. Jimenez E, Martin M, Krukenkamp I, Barret J. Subxyphoid pericardiotomy versus echocardiography: a prospective evaluation of the diagnosis of occult penetrating cardiac injury. *Surgery.* 1990;108:676-86
31. Meyer D, Jessen M, Grayburn P. Use of echocardiography to detect occult cardiac injury after penetrating thoracic trauma: a prospective study. *J Trauma.* 1995;39:902-9
32. Nicol AJ, Navsaria PH, Beningfield S, Hommes M, Kahn D. Screening for occult penetrating cardiac injuries. *Ann Surg.* 2015;261:573-8
33. Navsaria PH, Nicol AJ. Haemopericardium in stable patients after penetrating injury: Is subxyphoid pericardial window and drainage enough? *Injury.* 2005;36:745-50
34. Nicol AJ, Navsaria PH, Hommes M, Ball CG, Edu S, Kahn D. Sternotomy or drainage for hemopericardium after penetrating trauma. *Ann Surg.* 2013;00:1-5
35. Reuter H, Burgess LJ, Doubell. Epidemiology of pericardial effusions at a large academic hospital in South Africa. *Epidemiol Infect.* 2005;133:393-99





# Chapter Six

---

van Waes OJF, van Riet PA, van Lieshout EMM, den Hartog D. Immediate thoracotomy for penetrating injuries: ten years" experience at a Dutch level I trauma center. Eur J Trauma Emerg Surg 2012;38(5):543-51

## INTRODUCTION

Thoracic injuries represent one of the leading causes of death in all age groups and accounts for 25-50 percent of all traumatic injuries (1). Thoracic trauma ranks third, after head and extremity trauma, in major accidents in the United States (US), and is responsible for approximately half of all traumatic deaths (2). Most penetrating injuries of the chest can be managed non-operatively or with minimally invasive techniques. A small but significant group of 10-15 percent of patients with penetrating thoracic injuries requires an immediate thoracotomy as part of their initial resuscitation. An immediate thoracotomy can be performed in the operation room, herein referred to as an emergency thoracotomy (ET), or at the Emergency Department herein referred to as an Emergency Department thoracotomy (EDT). Survival rates after an immediate thoracotomy following penetrating thoracic trauma are usually reported around 9-12 percent(3), but have been reported to be as high as 38 percent (4). Much effort has been given to the identification of those patients who are likely to benefit from an immediate thoracotomy (5-9). Most of the experience in performing an immediate thoracotomy has been gained in high incidence regions like the US and in South Africa (7,8). Although penetrating trauma only accounts for 5-10 percent of all trauma in Europe, compared with 40-50 percent in the US, the incidence rates of patients presenting to an Emergency Department (ED) in the Netherlands with penetrating injury raised gradually over the past few years, up to 8 percent annually (10). Despite this rise in incidence in the Netherlands and other European countries, there is a paucity of studies from Europe regarding the use and outcome of an immediate thoracotomy following penetrating thoracic trauma. Moreover, outcomes-related physiologic parameters have only been validated in three studies (11-13), which makes it even more difficult to interpret and use this data in the European emergency situation (3).

Ten years ago, immediate thoracotomy in the management of life-threatening thoracic penetrating injury was embedded in our level I trauma center. Since the experience in performing an immediate thoracotomy in Europe is limited compared with the US and South Africa (14,15), the aim of this study was to evaluate our ten

year experience with immediate thoracotomy and to describe the practices and outcomes of penetrating thoracic trauma.

## **METHODS**

### **Study setting**

This study was performed at a level I trauma center in the Southwestern part of the Netherlands. This 1300+ bed university medical center serves a population of 4.9 million. Patients sustaining penetrating chest injuries in our adherence area are announced by pre-hospital care providers (either ambulance or helicopter emergency medical services), after which a trauma team is assembled (available 24/7) The team consists of a trauma surgeon (head of the trauma team), a surgical resident, an anesthesiologist, an emergency physician, two emergency nurses and a radiologist. Blood products and surgical equipment for either thoracotomy or sternotomy are available in the resuscitation room. In case of a resuscitative EDT both thoracic surgeon and operation room facilities are notified for subsequent definitive care. In hemodynamically stable patients Computed Tomographic Angiography (CTA), if required, is readily available opposite to the resuscitation room.

### **Patient selection**

Patients who underwent an immediate thoracotomy after sustaining penetrating thoracic injury between October 2000 and January 2011 were selected from the Trauma Registry. An immediate thoracotomy was defined as a thoracotomy required as an integral part of the initial resuscitation of the trauma patient in the ED, or for imminent surgical repair of the sustained injuries in the operation theatre(6). Both ET and EDT were included. An ET was performed in resuscitative responsive patients (systolic blood pressure (SBP)  $\geq 60$  mmHg), versus an EDT in resuscitative unresponsive or transient patients with a SBP  $< 60$  mmHg. Both thoracotomies allow evacuation of pericardial tamponade, direct control of intrathoracic hemorrhage, control of massive air-embolism, open cardiac massage, and cross-clamping of the descending aorta to redistribute blood flow and limit subdiaphragmatic hemorrhage (17,18). Patients who had undergone an elective thoracotomy only were excluded. An elective thoracotomy was defined as a procedure

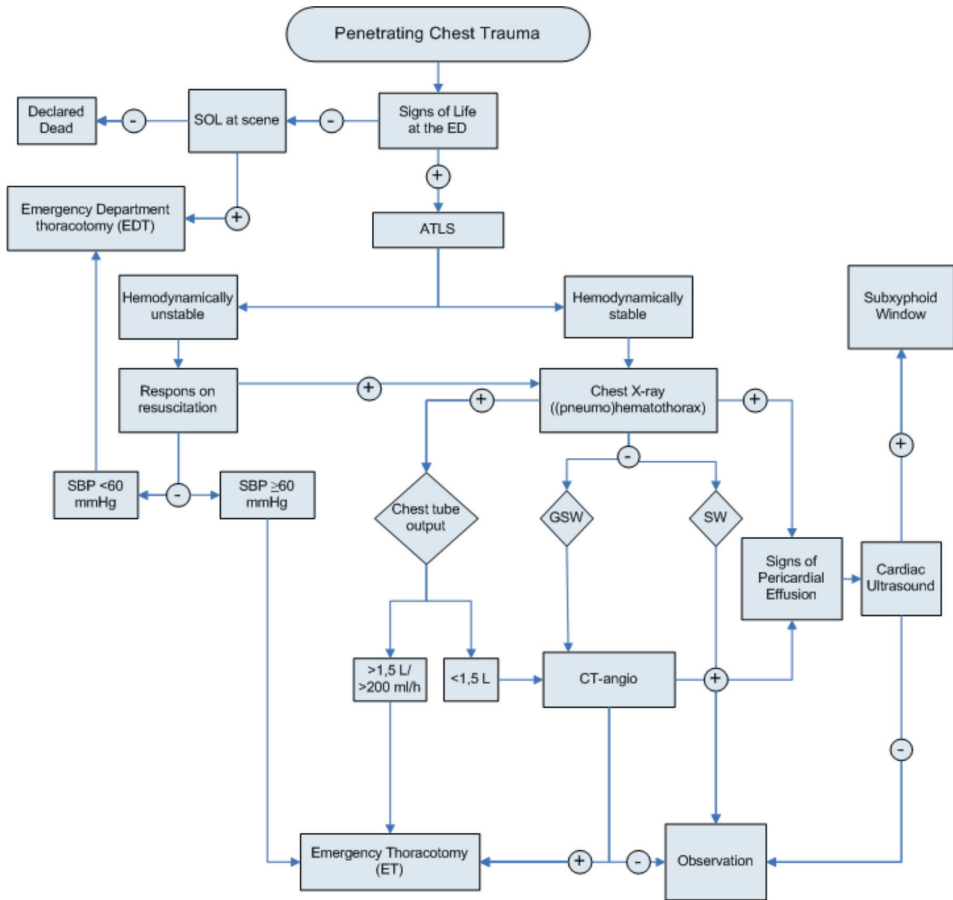
to correct non-acute life-threatening thoracic injury or post injury complications such as empyema. Patients receiving a thoracotomy after blunt thoracic trauma or after a non-traumatic thoracic injury (indicated when massive intra-thoracic or abdominal bleeding occurs), were also excluded.

### **Intervention**

Advanced Trauma Life Support (ATLS®) guidelines were used for initial assessment and treatment(19). Patients who sustained penetrating thoracic injuries were managed as shown in (Figure 1). Indications for an EDT and an ET are shown in (Figure 2). Indications for an EDT included; 1) Loss of Signs of life (SOL) on arrival at the ED, but presence of SOL on scene of injury and 2) failure to respond on resuscitation with a SBP <60 mmHg. Pericardial tamponade only formed an indication for an EDT when accompanied with an associated SBP <60 mmHg. ET indications included; 1) a hemothorax on Chest X-ray (CXR) with an initial chest tube output of >1500mL or an ongoing chest tube output of >200 mL/h for two to four hours after insertion of the tube accompanied by hemodynamically instability, 2) a hemothorax on CXR with chest tube output <1500mL, but with computed tomography angiogram (CTA) of the chest findings prompting surgical intervention (e.g. gross contrast extravasation or air leakage) 3) signs of pericardial tamponade 4) or a massive air embolism (19). Operative maneuvers performed during a thoracotomy and/or a laparotomy are shown in Table 1. Table 2 shows the operative findings following a thoracotomy and/or an additional laparotomy.

### **Data collection**

Data on patient characteristics, injury characteristics, physiological parameters and outcome were prospectively collected in and retrieved from our Trauma Registry and the patient hospital files. Data collected included age, gender, mechanism of injury, SOL, Glasgow Coma Scale (GCS score), injury severity score (ISS) (20), triage revised trauma score riage-RTS) (21), SBP, the need for cardiopulmonary resuscitation (CPR), transportation time, indications for thoracotomy, operative maneuvers, intra-operative findings, and complications. The length of hospital stay (H-LOS) was categorized as <24 hours or >24 hours. Presence of SOL was defined by at least one of the following was observed; GCS >3,



**Figure 1:** Flowchart with decision making pathway for an immediate thoracotomy after penetrating chest trauma

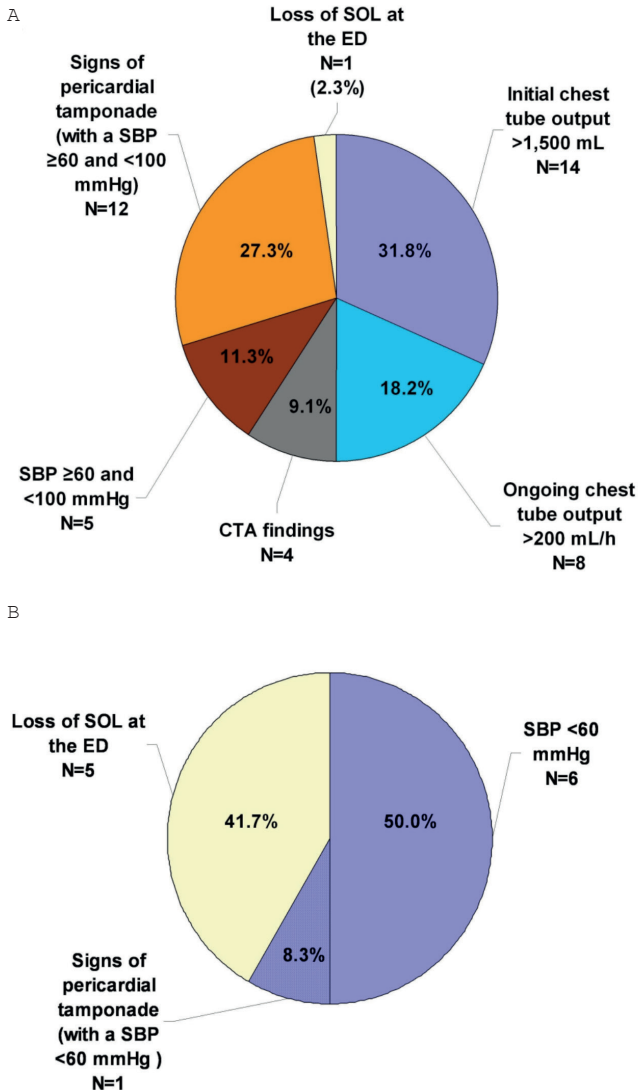
ATLS<sup>®</sup>, Advanced Trauma Life Support; ED, Emergency Department; SOL, Signs of life; SBP, Systolic Blood Pressure; GSW, Gunshot wound; SW, Stab wound; CT-angio, Computed Tomography Angiography.

A hemodynamically unstable condition was defined as a SBP <100 mmHg with or with no response on resuscitation. A hemodynamically stable condition was defined as a SBP ≥100 mmHg.

respiratory effort, cardiac activity on ECG or ultrasound (with or without a pulse) or evidence of pupillary reflexes. ISS was scored according to the Abbreviated Injury Scale (AIS-90) (22). CPR was performed following the Guidelines for resuscitation of the European Resuscitation Council (2005) (23).

## Data analysis

Statistical analysis was performed using the Statistical Package for the Social Sciences (SPSS) version 16.0 (SPSS, Chicago, IL, USA). Normality of continuous data was tested with the Shapiro-Wilk and Kolmogorov-Smirnov test and by inspecting the frequency distributions (histograms). The homogeneity of variances was tested using the Levene's test. Since most continuous data were skewed all data were analyzed using a nonparametric Mann-Whitney U-test. Categorical data were compared using a Fisher's Exact test or Chi square test. In small samples, or if the the Chi-square assumptions were not met, a Fisher exact test was performed. P values <0.05 were considered statistically significant.



**Figure 2:** Indications for performing an ET (panel A) or an EDT (panel B) SOL, Signs of life; ED, Emergency Department. Persisting shock was defined as a systolic blood pressure between  $\geq 60$  mmHg and  $< 100$  mmHg not responding to resuscitation or transient responder. Severe shock was defined as a systolic blood pressure of  $< 60$  mmHg not responding to resuscitation or transient responder. CTA findings included gross contrast extravasation, a hemothorax or air leakage.

## RESULTS

Over a 10-year period, a total of 416 patients with penetrating thoracic injury were referred to the Emergency Department; 72 presented with one or more gunshot wounds and 344 with one or more stab wounds. Of all 416 patients, 346 patients presented with thoracic trauma solely, 70 patients presented with both, thoracic and abdominal trauma. An intervention was indicated in 127 of 416 patients, including 39 thoracotomies, 32 laparotomies, and 17 patients undergoing both a thoracotomy and a laparotomy. The remaining 39 patients underwent other operative interventions. Of all 56 patients who underwent an immediate thoracotomy, 46 patients sustained a stab wound and 10 patients a gunshot wound. The male to female ratio was 6:1 and their median age was 32 years ( $P_{25}$ - $P_{75}$  25-41 years).

Of the included 56 patients, 12 had undergone an EDT and 44 an ET. The demographic and physiological data of these patients are shown in Table 1. Considering the mechanism of injury, relatively more gunshot wounds were found in the EDT group compared with the ET group ( $p=0.028$ ). Overall, stab wounds dominated in both groups. Patients in the EDT group had a lower pre-hospital GCS ( $p<0.001$ ), lower pre-hospital and hospital triage-RTS ( $p<0.001$  and  $p=0.009$ , respectively), and a lower hospital SBP ( $p=0.038$ ) than patients in the ET group. ISS, however, was similar in both groups.

Cardiopulmonary resuscitation was performed in 19 patients, of which six received pre-hospital closed chest cardiopulmonary resuscitation (CC-CPR). All six patients who received pre-hospital CC-CPR, with or without additional in-hospital CPR, progressed to an ET. Five of whom after a successful EDT. The majority of all patients receiving in-hospital CPR underwent an EDT ( $p<0.001$ ). The median time interval from arrival of emergency medical services at point of injury, until admittance at the ED was shorter in the EDT group (13 minutes;  $P_{25}$ - $P_{75}$  2-23) than in the ET group (33 minutes;  $P_{25}$ - $P_{75}$  18-35;  $p = 0.006$ ). Median time span from injury scene to thoracotomy was also shorter in the EDT group (25 minutes;  $P_{25}$ - $P_{75}$  15-107) than in the ET group (79 minutes;  $P_{25}$ - $P_{75}$  52-155;  $p=0.037$ ; (Table 1)).

**Table 1:** Patient characteristics of the study population, in which immediate thoracotomy was performed in the ED (EDT) or the operation theater (ET)

Parameter	Overall (N=56)	EDT (N=12)	ET (N=44)	P value
Pre-hospital				
Age (years) <sup>1</sup>	32 (25-41)	28 (24-41)	33 (25-41)	0.555 <sup>a</sup>
Gender (men) <sup>2</sup>	48 (86)	10 (83)	38 (86)	N.S. <sup>a</sup>
Stab wounds <sup>2</sup>	46 (82)	7 (58)	39 (89)	0.028 <sup>b</sup>
Signs of life <sup>2</sup>	55 (98)	12 (100)	43 (98)	N.S. <sup>a</sup>
Glasgow Coma Score <sup>1</sup>	14 (3-15)	3 (3-10)	14 (12-15)	<0.001 <sup>a</sup>
Systolic Blood Pressure (mmHg) <sup>1</sup>	98 (60-114)	0 (0-110)	100 (80-120)	0.0140 <sup>a</sup>
Revised Trauma Score <sup>1</sup>	11.00 (7.00-12.00)	4.50 (4.00-7.00)	12.00 (8.50-12.00)	<0.001 <sup>a</sup>
Closed-Chest Cardiopulmonary resuscitation <sup>2</sup>	6 (11)	0 (0)	6 (14)	N.S. <sup>c</sup>
In-hospital				
Time until ED arrival (minutes) <sup>1</sup>	24 (15-32)	13 (2-23)	33 (18-35)	0.006 <sup>a</sup>
Time until thoracotomy (minutes) <sup>1</sup>	68 (42-128)	25 (15-107)	79 (52-155)	0.037 <sup>a</sup>
Cardiopulmonary resuscitation <sup>2</sup>	17 (30)	9 (75)	8 (18)	<0.001 <sup>b</sup>
Signs of life <sup>2</sup>	50 (89)	7 (58)	43 (98)	0.001 <sup>a</sup>
Systolic Blood Pressure (mmHg) <sup>1</sup>	105 (69-120)	0 (0-113)	107 (80-126)	0.038 <sup>a</sup>
Injury Severity Score <sup>1</sup>	25 (16-34)	34 (17-36)	20 (15-34)	N.S. <sup>a</sup>
Triage-Revised Trauma Score <sup>1</sup>	8 (4-8)	4 (1-8)	8 (5-8)	0.009 <sup>a</sup>
H-LOS (days) <sup>1</sup>	7 (0-12)	0 (0-5)	8 (5-14)	0.005 <sup>a</sup>
IC-LOS (days) <sup>1</sup>	1 (0-3)	0 (0-2)	1 (1-3)	0.012 <sup>a</sup>

<sup>1</sup> Data are displayed as median, with the first and third quartile given within brackets.

<sup>2</sup> Patient numbers are displayed, with the percentages given within brackets.

<sup>a</sup> Mann-Whitney U-test, <sup>b</sup> Fisher's exact test, <sup>c</sup> Chi-square test.

H-LOS, Hospital length of stay, IC-LOS, duration of stay at the Intensive Care Unit.



**Table 2:** Operative findings (A) and maneuvers (B) during EDT versus ET

A

<b>Operative findings (per patient)</b>	<b>Overall (N=56)</b>	<b>EDT (N=12)</b>	<b>ET (N=44)</b>	<b>P value</b>
Hemothorax	41 (73)	6 (50)	35 (80)	0.039 <sup>a</sup>
Lung injury	27 (48)	4 (33)	23 (52)	0.334 <sup>b</sup>
Cardiac injury	28 (50)	7 (58)	21 (48)	0.746 <sup>b</sup>
Diaphragm perforation	6 (11)	0 (0)	6 (14)	0.359 <sup>a</sup>
Transection of intrathoracic vessels	8 (14)	4 (33)	4 (9)	0.055 <sup>b</sup>

B

<b>Operative maneuvers (per patient)</b>	<b>Overall (N=56)</b>	<b>EDT (N=12)</b>	<b>ET (N=44)</b>	<b>p-value</b>
Control of intra-thoracic hemorrhage	47 (84)	9 (75)	38 (86)	0.385 <sup>b</sup>
Release of pericardial tamponade	16 (29)	4 (33)	12 (27)	0.726 <sup>b</sup>
Internal cardiac massage	13 (23)	7 (58)	6 (14)	<0.001 <sup>b</sup>
Pneumectomy	3 (5)	0 (0)	3 (7)	0.512 <sup>b</sup>
Pulmonary hilar twist or clamp	2 (4)	2 (17)	0 (0)	0.043 <sup>b</sup>
Wedge resection	2 (2)	0 (0)	2 (5)	N.S. <sup>b</sup>
Aortic cross clamping	1 (2)	1 (8)	0 (0)	0.214 <sup>b</sup>

Data are shown as numbers with the percentage between brackets, and were analyzed using a <sup>a</sup> Chi-square test or a <sup>b</sup> Fisher's exact.

Of all 56 immediate thoracotomies, 10 were performed within one hour after injury, 14 within 1-3 hours and six within 4-10 hours. The transportation time of 26 patients could not be obtained. The indications for an ET are presented in Figure 2A and the indications for an EDT are shown in Figure 2B. Indications are in agreement with the flowchart in Figure 1.

A total of 64 incisions were performed; 22 midsternal incisions, 20 left anterolateral, 10 right anterolateral, two left posterolateral, six right posterolateral, and four clamshell. Operative findings and maneuvers for EDT and ET are shown in Table 2. Hemothorax was found significantly more often in the ET group. Internal cardiac massage and pulmonary hilar twist were performed more frequently in the EDT group ( $p < 0.001$  and  $p = 0.043$ , respectively). Abdominal trauma was found in ten of all 17

patients undergoing an additional laparotomy and was not observed more often in the ET or the EDT group ( $p=0.433$ ). The most common intra-abdominal findings were damage to the diaphragm and the liver.

**Table 3:** Complications following EDT and ET

Complications	Overall (N=56)	EDT (N=12)	ET (N=44)
Mortality	20 (36)	9 (75)	11 (25)
Re-bleeding	7 (13)	1 (8)	6 (14)
Acute respiratory distress syndrome	2 (4)	1 (8)	1 (2)
Superficial wound infection	1 (2)	0 (0)	1 (2)
Abscess	2 (4)	0 (0)	2 (5)
Pneumonia	3 (5)	1 (8)	2 (5)
Empyema	2 (4)	0 (0)	2 (5)
Sepsis	1 (2)	0 (0)	1 (2)
Rhabdomyolysis	2 (4)	1 (8)	1 (2)
Neurological impairment	2 (4)	0 (0)	2 (5)
Re-operation	9 (16)	1 (8)	8 (18)

Data are shown as numbers with the percentage between brackets. Complications other than mortality are shown for survivors only.

In survivors, post-operative complications occurred in 20 patients, of which five patients experienced one or more complications (Table 3). Complications ranged from superficial wound infection to re-bleeding in seven patients.

Re-operation was performed in nine patients and included two laparotomies and seven re-thoracotomies. Of this latter group, two patients underwent an elective thoracotomy and five a re-thoracotomy due to persistent thoracic blood loss. Operative findings following persistent thoracic blood loss included progressive rupture of the cardiac apex, despite of the placement of several cardiac sutures two hours earlier, continuous bleeding of intercostal vessels, laceration of the aortic arch, bleeding of the subclavian artery and a negative re-thoracotomy in one patient. The overall survival of patients was 64 percent; 25 percent in the EDT group 75 percent in the ET group (Table 4). In the EDT group five out of 12 patients (42 percent) advanced to definitive surgical care. The three patients who survived

**Table 4:** Factors associated with mortality after an immediate thoracotomy

Factors				P value
	Total (N =56)	Non- survivors (N = 20)	Survivors (N =36)	
Pre-hospital				
Signs of life <sup>2</sup>	55 (98)	19 (95)	36 (100)	0.357 <sup>b</sup>
Pupillary respons <sup>2</sup>	45 (80)	11 (55)	34 (94)	0.002 <sup>c</sup>
Triage-Revised Trauma Score <sup>1</sup>	11 (7-12)	8 (4-11)	12 (10-12)	0.001 <sup>a</sup>
Glasgow Coma Scale <sup>1</sup>	14 (3-15)	3 (3-13)	15 (13-15)	<0.001 <sup>a</sup>
Systolic Blood Pressure (mmHg) <sup>1</sup>	98 (60-114)	68 (0 - 109)	101 (80-127)	0.009 <sup>a</sup>
Hemodynamic unstable <sup>2</sup>	29 (52)	15 (75)	14 (39)	0.031 <sup>c</sup>
Gunshot wound <sup>2</sup>	10 (17)	6 (30)	4 (11)	0.142 <sup>b</sup>
Abdominal injury <sup>2</sup>	10 (18)	8 (40)	2 (6)	0.002 <sup>b</sup>
In-hospital				
Injury Severity Score <sup>1</sup> Triage-Revised Trauma Score <sup>1</sup>	25 (16-34)	34 (17-45)	20 (12-30)	0.011 <sup>a</sup>
Systolic Blood Pressure (mmHg) <sup>1</sup>	8 (4-8)	4 (1-8)	8 (6-8)	0.008 <sup>a</sup>
Systolic Blood Pressure (mmHg) <sup>1</sup>	105 (69-120)	70 (0-108)	110 (91-130)	0.003 <sup>a</sup>
Signs of life <sup>2</sup>	50 (89)	14 (70)	36 (100)	0.001 <sup>b</sup>
CPR <sup>2</sup>	17 (30)	15 (75)	2 (6)	<0.001 <sup>b</sup>
EDT <sup>2</sup>	12 (21)	9 (45)	3 (8)	0.002 <sup>b</sup>
Transection intrathoracic vessels <sup>2</sup>	8 (14)	6 (30)	2 (6)	0.019 <sup>b</sup>
Thoracotomy indications				0.003 <sup>c</sup>
Pericardial tamponade <sup>2</sup> (with associated shock)	13 (23)	2 (10)	11 (31)	
Ongoing chest tube production	8 (14)	1 (5)	7 (19)	
>200 mL/h <sup>2</sup>				
Hemodynamic unstable condition <sup>2</sup>	11 (20)	7 (35)	4 (11)	
Absence of Signs of life <sup>2</sup>	5 (9)	5 (25)	0 (0)	

<sup>1</sup> Data are displayed as median, with the first and third quartile given within brackets.

<sup>2</sup> Patient numbers are displayed, with the percentages given within brackets. Data were analyzed using a <sup>a</sup>Mann-Whitney U-test, <sup>b</sup>Fisher's exact test, <sup>c</sup>Chi-square test

ED, Emergency Department; CPR, Cardiopulmonary resuscitation; EDT, Emergency Department Thoracotomy. Pre-hospital hemodynamic unstable condition was defined as a SBP <100 mmHg or no response on resuscitation. Hemodynamic unstable condition as an indication for thoracotomy was defined as a SBP <60 mmHg or no response on resuscitation.

an EDT left the hospital without neurological impairment. Of all 44 patients in the ET group 33 (75 percent) survived until discharge, of whom (94 percent) neurologically intact.

Physiological conditions of patients in relation to survival are shown in Table 4. Patients who survived had a lower ISS ( $p=0.011$ ) and a lower rate of pre-hospital and hospital hemodynamic instability ( $p=0.031$  and  $p=0.003$ , respectively). Fifty-five of the 56 patients who underwent an immediate thoracotomy had obtainable SOL after injury; 50 of the 55 still had SOL at the Emergency Department. One patient who lost of SOL at the ED did not receive resuscitative interventions at the ED, but underwent an ET instead of an EDT. All six patients who lost SOL died. Patients who died had a higher prevalence of concomitant abdominal injury (Table 4). The finding of peritoneal and retroperitoneal fluid during the operation, suggesting the existence of additional abdominal trauma, also coincided with a higher mortality rate ( $p=0.009$  and  $p=0.036$ , respectively). Conclusively, patients who died showed a higher rate of a transected aorta or vena cava ( $p=0.018$ ). Suspected pericardial tamponade on the other hand had a more favorable outcome ( $p=0.003$ ).

## DISCUSSION

Nowadays, an EDT or an ET is performed in emergency situations following life-threatening thoracic, especially penetrating, trauma (8,24,25). Guidelines for the treatment of thoracic injuries were established after World War II and derived originally from military experience (16). In 2001, the National Association of Emergency Physicians and the American College of Surgeons composed a series of guidelines (3). An EDT is recommended in patients sustaining penetrating thoracic (cardiac) injuries who arrive at a trauma center after a short on-scene time and short transportation time with witnessed or objectively measured SOL. However, physiological predictors of outcome, definitions of SOL and identifying the patients, for whom an immediate thoracotomy can be life saving, remain subject of debate (3,8,14,26-29). Furthermore, the outcome data from the high incidence regions like the US and South Africa may not be generalizable to the European

population. Therefore, we described our 10-year experience with immediate thoracotomies in a European level I trauma center.

The survival rate after an EDT published by the American College of Surgeons Committee on Trauma (ACSCOT) was only 11.2 percent, of which approximately 15 percent survived with neurological impairment (3). In our cohort, three out of twelve patients survived until discharge following an EDT; all were discharged without neurological impairment. Our survival rates compare favorably to other European studies in which mortality rates after EDT or ET up to 100 percent were found (15). The most promising European experience so far was the Glasgow series (30), reporting a 32 percent survival rate (*i.e.*, eight out of 25 patients survived) following an immediate thoracotomy. Our overall survival rate of 64 percent (36 out of 56 patients) is twice as high. The survival rate in the Glasgow series following an EDT was 6 percent, which is much lower than the observed survival rate of 25 percent in the our level 1 trauma center. In order to determine if our favorable outcomes could partly be caused by overtreatment, pre-operative indications were compared with the operative findings. When analyzing the EDTs, it seemed that the three patients who survived an EDT initially manifested with; radiographic signs of a large hemothorax, shock and signs of a pericardial tamponade like pericardial effusion on ultrasound or CTA. Consecutive operative findings were; laceration of the lung parenchyma, myocardial rupture and laceration of the lung parenchyma. All patients were in severe shock (*i.e.*, SBP <60 mmHg) and unresponsive to resuscitation. These patients could not have been transported to the OR for surgical treatment, and thus underwent an EDT. Above-mentioned findings suggest that the decision to perform an EDT in these cases was adequate. Moreover, indications were in correspondence with the ATLS® and ERC® guidelines (19,31). Based on our study findings, we are confident that the standard of care in combination with the developed treatment algorithm as shown in (Figure 1) allows us to achieve a relatively favorable outcome. Nevertheless, the decision whether or not to perform an immediate thoracotomy remains a challenge.

Several indications, including specific physical parameters, were proven to be associated with a favorable outcome (3,5,14, 17,19,32,33). In our study certain indications, like the presence of SOL, suspected traumatic pericardial tamponade or the presence of concomitant abdominal injury, showed to have a significant influence on the outcome after EDT or ET.

Loss of SOL is an important variable describing a patient's physical condition, which presented more often in the patients who died. Nevertheless, controversy exists when and which SOL are related to a better outcome (34). An immediate thoracotomy is believed to be beneficial in patients who arrive with vital signs at the Emergency Department with vital signs or those with witnessed loss of SOL, not in those who already lost all SOL before the (Helicopter) Emergency Medical Services arrived at the scene of injury (3). In our cohort, obtainable SOL were present in all 36 survivors. Survivors, however, did not show all possible SOL; two lost their pupillary response after injury, one suffered a prehospital asystoly that persisted until arrival at the Emergency Department, and one had loss of SOL during the EDT. Seamon *et al.* reported similar findings and suggested that EDT can have a favorable outcome as long as one or more SOL are present at the scene of injury. Moreover, the moment in time when the SOL were observed seemed to affect the outcome (32). All five patients with recordable SOL at the incident scene, that lost all SOL at or during transportation to the Emergency Department, died in our study. Several authors support the theory that witnessed loss of SOL is one of the indications to perform an immediate thoracotomy (3,35); however, our data proved a poor outcome following witnessed loss of SOL. Considering this outcome, it was noted by Hall *et al.* that current recommendations to perform an immediate thoracotomy might be a little optimistic. They put forward that they are mainly based on the outcomes of the more specialized and experienced institutions, where immediate thoracotomies are performed more routinely (35). An other option for improvement for survival of patients with witnessed loss of SOL might be a pre-hospital thoracotomy following the indications mentioned by Coats *et al* (36). Altogether, loss of SOL as an indication for an immediate thoracotomy deserves extra observation in the future, especially focusing on the low

incidence regions. Concomitant abdominal injury was found to be more prominent among the patients who died, which is in agreement with several studies from higher incidence regions (5,6,37,38). Mortality rates in our study were higher in patients receiving both, a thoracotomy and a laparotomy. Negative laparotomy rates up of 30 percent in thoracoabdominal injuries (39,40), with a complication rate of 2.5 percent to 41 percent (41). Both findings reflect the importance of a reliable diagnostic approach for thoracoabdominal injuries. Further research in this area is desired, since most studies describe diagnostic imaging following blunt, not penetrating trauma (42-45).

As for cardiac injury, the ACSCOT guidelines support the use of an EDT in hemodynamically unstable patients or patients with witnessed loss of SOL, in whom a pericardial tamponade is suspected. The ACSCOT also propagate that an EDT can be used as a diagnostic tool for discriminating cardiac from non-cardiac thoracic injury (3). Clinical or CXR suspicion on pericardial tamponade (PT) is in our center treated following our algorithm (Figure 1). Ultrasound confirmed pericardial effusion (> 8 mm) in patients with a SBP < 60 mmHg immediately undergo an EDT. In patients with a SBP > 60 mmHg who undergo an ET for additional injuries, the pericardium is opened, to assess the myocardium for injuries. In hemodynamic stable patients the pericardium is inspected via the subxyphoid pericardial window (SPW) technique as described by Arom et al.(46) In case of Gross blood drainage from the pericardial sac, the procedure is converted to a sternotomy to treat the injuries to the heart. If only serosanguinolent fluid is encountered, a drain is placed in the pericardial sac till the output is less than 50 ml over 12 hours, as is advocated by Navsaria et al. (47). In our cohort, patients with a suspected traumatic pericardial tamponade were more abundant among survivors, suggesting a more favorable outcome (36,48,49). Since outcome data from the high incidence regions may not be generalizable to low-volume areas such as most European countries, further research from low incidence regions is needed. Despite a lower occurrence of penetrating thoracic injuries, we were able to show that performing immediate thoracotomy in a level I trauma center in a lower incidence region can achieve similar outcomes as in high

incidence regions. However, since immediate thoracotomies are not part of the daily routine of most trauma centers within these low incidence regions, cooperation between different European hospitals could contribute to the improvement of penetrating trauma research in the future. In addition, training programs in high volume centers, in combination with recurrent surgical technique training on cadavers, may contribute to better outcomes.



## REFERENCES

1. MacKenzie EJ. Epidemiology of injuries: current trends and future challenges. *Epidemiol Rev* 2000;**22**(1): 112-119.
2. LoCicero J, 3rd, Mattox KL. Epidemiology of chest trauma. *Surg Clin North Am* 1989;**69**(1): 15-19.
3. Practice management guidelines for emergency department thoracotomy. Working Group, Ad Hoc Subcommittee on Outcomes, American College of Surgeons-Committee on Trauma. *J Am Coll Surg* 2001;**193**(3): 303-309.
4. Baxter BT, Moore EE, Moore JB, Cleveland HC, McCroskey BL, Moore FA. Emergency department thoracotomy following injury: critical determinants for patient salvage. *World J Surg* 1988;**12**(5): 671-675.
5. Rhee PM, Acosta J, Bridgeman A, Wang D, Jordan M, Rich N. Survival after emergency department thoracotomy: review of published data from the past 25 years. *J Am Coll Surg* 2000;**190**(3): 288-298.
6. Karmy-Jones R, Nathens A, Jurkovich GJ, Shatz DV, Brundage S, Wall MJ, Jr., Engelhardt S, Hoyt DB, Holcroft J, Knudson MM, Michaels A, Long W. Urgent and emergent thoracotomy for penetrating chest trauma. *J Trauma* 2004;**56**(3): 664-668; discussion 668-669.
7. Miglietta MA, Robb TV, Eachempati SR, Porter BO, Cherry R, Brause J, Barie PS. Current opinion regarding indications for emergency department thoracotomy. *J Trauma* 2001;**51**(4): 670-676.
8. Brown SE, Gomez GA, Jacobson LE, Scherer T, 3rd, McMillan RA. Penetrating chest trauma: should indications for emergency room thoracotomy be limited? *Am Surg* 1996;**62**(7): 530-533; discussion 533-534.
9. Durham LA, 3rd, Richardson RJ, Wall MJ, Jr., Pepe PE, Mattox KL. Emergency center thoracotomy: impact of prehospital resuscitation. *J Trauma* 1992;**32**(6): 775-779.
10. Bruinsma MY MJ. Onderzoeksrapport Illegale vuurwapens, gebruik, bezit en handel in Nederland 2001-2003. 2005.
11. Asensio JA HD, Demetriades D, et al. The futility of the liberal utilization of emergency department thoracotomy. A prospective study. 1998.
12. Asensio JA, Murray J, Demetriades D, Berne J, Cornwell E, Velmahos G, Gomez H, Berne TV. Penetrating cardiac injuries: a prospective study of variables predicting outcomes. *J Am Coll Surg* 1998;**186**(1): 24-34.
13. Asensio JA, Berne JD, Demetriades D, Chan L, Murray J, Falabella A, Gomez H, Chahwan S, Velmahos G, Cornwell EE, Belzberg H, Shoemaker W, Berne TV. One hundred five penetrating cardiac injuries: a 2-year prospective evaluation. *J Trauma* 1998;**44**(6): 1073-1082.

14. Soreide K, Petrone P, Asensio JA. Emergency thoracotomy in trauma: rationale, risks, and realities. *Scand J Surg* 2007;**96**(1): 4-10.
15. Soreide K, Soiland H, Lossius HM, Vetrhus M, Soreide JA, Soreide E. Resuscitative emergency thoracotomy in a Scandinavian trauma hospital--is it justified? *Injury* 2007;**38**(1): 34-42.
16. Hunt PA, Greaves I, Owens WA. Emergency thoracotomy in thoracic trauma--a review. *Injury* 2006;**37**(1): 1-19.
17. Beall AC, Jr., Diethrich EB, Crawford HW, Cooley DA, De Bakey ME. Surgical management of penetrating cardiac injuries. *Am J Surg* 1966;**112**(5): 686-692.
18. Grove CA, Lemmon G, Anderson G, McCarthy M. Emergency thoracotomy: appropriate use in the resuscitation of trauma patients. *Am Surg* 2002;**68**(4): 313-316; discussion 316-317.
19. Trauma ACoSoc. *Advanced Trauma Life Support for Doctors* (8th edition edn). American College of Surgeons: Chicago, 2008.
20. Baker SP, O'Neill B, Haddon W, Jr., Long WB. The injury severity score: a method for describing patients with multiple injuries and evaluating emergency care. *J Trauma* 1974;**14**(3): 187-196.
21. Champion HR, Sacco WJ, Copes WS, Gann DS, Gennarelli TA, Flanagan ME. A revision of the Trauma Score. *J Trauma* 1989;**29**(5): 623-629.
22. Garthe E, States JD, Mango NK. Abbreviated injury scale unification: the case for a unified injury system for global use. *J Trauma* 1999;**47**(2): 309-323.
23. Handley AJ, Koster R, Monsieurs K, Perkins GD, Davies S, Bossaert L. European Resuscitation Council guidelines for resuscitation 2005. Section 2. Adult basic life support and use of automated external defibrillators. *Resuscitation* 2005;**67 Suppl 1**: S7-23.
24. Gomez G, Fecher A, Joy T, Pardo I, Jacobson L, Kemp H. Optimizing outcomes in emergency room thoracotomy: a 20-year experience in an urban Level I trauma center. *Am Surg*; **76**(4): 406-410.
25. Brautigam MW. Patient selection in emergency thoracotomy. *Resuscitation* 1991;**22**(1): 103-108.
26. Henderson VJ, Smith RS, Fry WR, Morabito D, Peskin GW, Barkan H, Organ CH, Jr. Cardiac injuries: analysis of an unselected series of 251 cases. *J Trauma* 1994;**36**(3): 341-348.
27. Danne PD, Finelli F, Champion HR. Emergency bay thoracotomy. *J Trauma* 1984;**24**(9): 796-802.
28. Athanasiou T, Krasopoulos G, Nambiar P, Coats T, Petrou M, Magee P, Uppal R. Emergency thoracotomy in the pre-hospital setting: a procedure requiring clarification. *Eur J Cardiothorac Surg* 2004;**26**(2): 377-386.

29. Cothren CC, Moore EE. Emergency department thoracotomy for the critically injured patient: Objectives, indications, and outcomes. *World J Emerg Surg* 2006;**1**: 4.
30. Bleetman A, Kasem H, Crawford R. Review of emergency thoracotomy for chest injuries in patients attending a UK Accident and Emergency department. *Injury* 1996;**27**(2): 129-132.
31. Onat S, Ulku R, Avci A, Ates G, Ozcelik C. Urgent thoracotomy for penetrating chest trauma: analysis of 158 patients of a single center. *Injury*; **41**(7): 876-880.
32. Seamon MJ, Fisher CA, Gaughan JP, Kulp H, Dempsey DT, Goldberg AJ. Emergency department thoracotomy: survival of the least expected. *World J Surg* 2008;**32**(4): 604-612.
33. Lorenz HP, Steinmetz B, Lieberman J, Schecoter WP, Macho JR. Emergency thoracotomy: survival correlates with physiologic status. *J Trauma* 1992;**32**(6): 780-785; discussion 785-788.
34. Moore EE, Knudson MM, Burlew CC, Inaba K, Dicker RA, Biffl WL, Malhotra AK, Schreiber MA, Browder TD, Coimbra R, Gonzalez EA, Meredith JW, Livingston DH, Kaups KL. Defining the limits of resuscitative emergency department thoracotomy: a contemporary Western Trauma Association perspective. *J Trauma*; **70**(2): 334-339.
35. Hall BL, Buchman TG. A visual, timeline-based display of evidence for emergency thoracotomy. *J Trauma* 2005;**59**(3): 773-777.
36. Coats TJ, Keogh S, Clark H, Neal M. Prehospital resuscitative thoracotomy for cardiac arrest after penetrating trauma: rationale and case series. *J Trauma* 2001;**50**(4): 670-673.
37. Mejia JC, Stewart RM, Cohn SM. Emergency department thoracotomy. *Semin Thorac Cardiovasc Surg* 2008;**20**(1): 13-18.
38. Morgan BS, Garner JP. Emergency thoracotomy--the indications, contraindications and evidence. *J R Army Med Corps* 2009;**155**(2): 87-93.
39. Soffer D, McKenney MG, Cohn S, Garcia-Roca R, Namias N, Schulman C, Lynn M, Lopez P. A prospective evaluation of ultrasonography for the diagnosis of penetrating torso injury. *J Trauma* 2004;**56**(5): 953-957; discussion 957-959.
40. van den Berg HR, Lere SG, Schipper IB, Patka P. [Abdominal gunshot wounds: possibilities for selective conservative management]. *Ned Tijdschr Geneeskde* 2007;**151**(15): 841-847.
41. de Vries CS, Africa M, Gebremariam FA, van Rensburg JJ, Otto SF, Potgieter HF. The imaging of stab injuries. *Acta Radiol*; **51**(1): 92-106.
42. Salera D, Argalia G, Giuseppetti GM. Screening US for blunt abdominal trauma: a retrospective study. *Radiol Med* 2005;**110**(3): 211-220.

43. Brown MA, Casola G, Sirlin CB, Patel NY, Hoyt DB. Blunt abdominal trauma: screening us in 2,693 patients. *Radiology* 2001;**218**(2): 352-358.
44. Lingawi SS, Buckley AR. Focused abdominal US in patients with trauma. *Radiology* 2000;**217**(2): 426-429.
45. Nural MS, Yordan T, Guven H, Baydin A, Bayrak IK, Kati C. Diagnostic value of ultrasonography in the evaluation of blunt abdominal trauma. *Diagn Interv Radiol* 2005;**11**(1): 41-44.
46. Arom KV, Richardson JD, Webb G, Grover FL, Trinkle JK. Subxiphoid pericardial window in patients with suspected traumatic pericardial tamponade. *Ann Thorac Surg* 1977;**23**(6): 545-549.
47. Navsaria PH, Nicol AJ. Haemopericardium in stable patients after penetrating injury: is subxiphoid pericardial window and drainage enough? A prospective study. *Injury* 2005;**36**(6): 745-750.
48. Trunkey D. Initial treatment of patients with extensive trauma. *N Engl J Med* 1991;**324**(18): 1259-1263.
49. Molina EJ, Gaughan JP, Kulp H, McClurken JB, Goldberg AJ, Seamon MJ. Outcomes after emergency department thoracotomy for penetrating cardiac injuries: a new perspective. *Interact Cardiovasc Thorac Surg* 2008;**7**(5): 845-848.





# Chapter Seven

---

Van Vledder MG, van Waes OJF, Kooij F, Peters JH, van Lieshout EMM, Verhofstad MHJ. Out of hospital thoracotomy for cardiac arrest after penetrating thoracic trauma. *Injury* 2017;48(9):1865-9

## INTRODUCTION

Traditional cardiopulmonary resuscitation for out of hospital traumatic cardiac arrest is associated with poor survival (1). For patients with cardiac arrest resulting from cardiac tamponade after penetrating thoracic injury, emergency thoracotomy with decompression of the pericardial sac may offer a significant chance of survival. Emergency department series have reported survival rates up to 21%(1).

Emergency department thoracotomy has been included in the guidelines of the European resuscitation council as a resuscitative procedure for patients suspected of having circulatory arrest and cardiac tamponade (2). Emergency room thoracotomy has been an established procedure in Dutch trauma centers for many years with favorable results (3). Longer transportation times to the hospital may be associated with poor outcome in these patients; Ideally thoracotomy should be performed within 10 minutes after circulatory arrest, which is very hard to achieve when arrest occurs in an out of hospital setting. Davies *et al.* reported on prehospital thoracotomies performed by the physician-led London Helicopter Emergency Medical Service (HEMS) in patients suffering from cardiac arrest after sustaining a stab wound to the chest. Thirteen out of 71 patients survived to hospital discharge after out of hospital emergency thoracotomy (4). Therefore, it was hypothesized that adding this procedure to the armamentarium of Dutch HEMS personnel may lead to increased odds of survival in selected patients.

The aim of this retrospective case-series was to determine the proportion of patients with return of spontaneous circulation and subsequent survival after out of hospital thoracotomy. Furthermore, we describe the introduction and implementation of this procedure in the Dutch physician staffed Helicopter Emergency Medical Service (HEMS).



## **METHODS**

### **Dutch HEMS operation**

The Netherlands covers approximately 41,000 square kilometers and holds about 17 million inhabitants. Prehospital emergency medical services are mostly provided by ground ambulance crews staffed with paramedics, trained in prehospital trauma life support (PHTLS) and a background in intensive care or emergency medicine. Ground emergency medical services (EMS) are supplemented by four physician-led HEMS-operations across the country. A HEMS team consists of a board-certified anesthesiologist or trauma surgeon, a specialized nurse, and a helicopter pilot. The primary purpose of the Dutch HEMS operation is to provide specialized medical care on scene, including advanced airway management and specific procedures such as thoracostomy and chest tube drainage.

Three of four Dutch HEMS operations implemented prehospital thoracotomy and participated in this study. The fourth HEMS station is located in a largely rural environment in which penetrating thoracic injury due to gunshot or stab wounds is less frequently encountered and have not yet introduced this procedure into their practice.

### **Training for out of hospital thoracotomy**

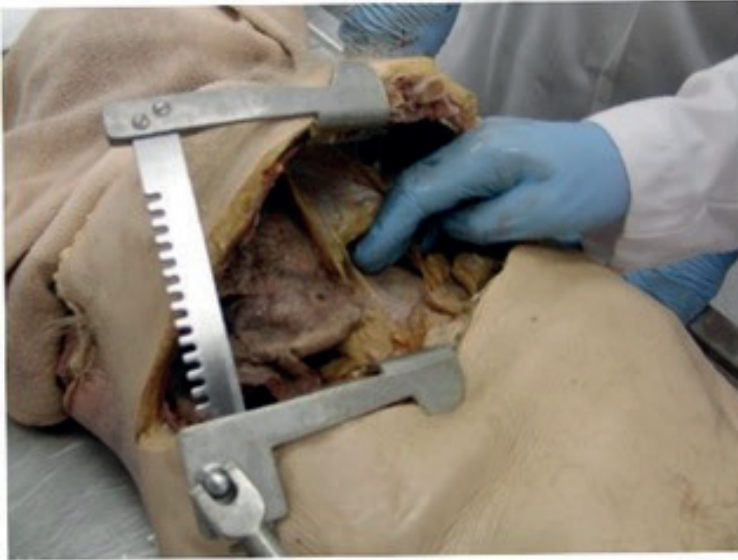In order to familiarize HEMS crew members with the procedure of emergency thoracotomy, physicians and nurses received theoretical and practical training by board certified trauma surgeons with extensive experience in emergency department thoracotomy. First, the available protocols and literature with regard to indications and outcomes for resuscitative thoracotomy were discussed. Thereafter, the anatomy of the thoracic wall and mediastinum were reviewed thoroughly and the technique for anterolateral and clamshell thoracotomy was described. Finally, skills were extensively and repeatedly trained in the cadaver lab on fresh frozen cadavers (Figure 1).

### **Indications, technique and equipment**

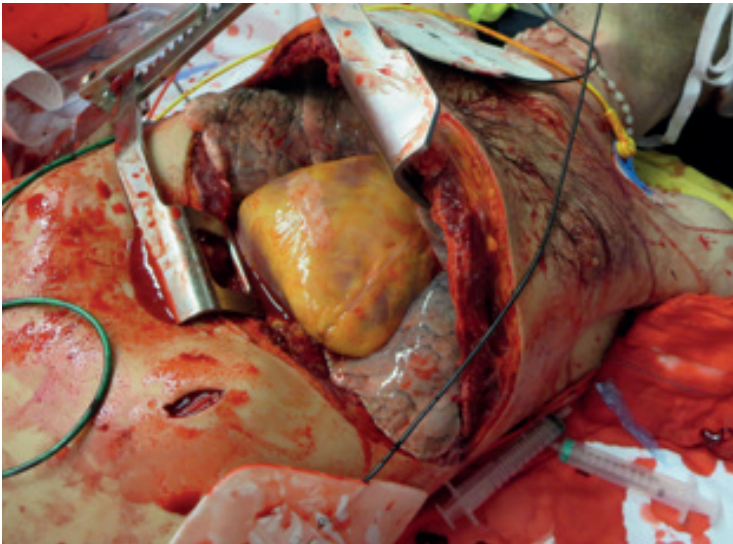During in-hospital resuscitation on a stretcher or operating table at near eye level, a left anterolateral thoracotomy provides sufficient access to the mediastinum to open the pericardium

and decompress cardiac tamponade. In the prehospital setting, a clamshell thoracotomy is preferred as this provides optimal exposure for the supine patient on the ground. The procedure is relatively easy to perform and allows for treatment of various traumatic injuries, even for non-surgical personnel (5). Indications and technique are strictly protocolled and modeled on the recommendations of Wise *et al.*(6). In short, thoracotomy is performed in all patients with 1. penetrating thoracic injury or upper abdominal injury with suspected cardiac tamponade, 2. a delay shorter than 10 minutes between cardiac arrest and arrival of the HEMS crew or signs of life (pupil reflexes, gasping or ECG activity) at arrival of the HEMS crew, 3. no other non-survivable injuries and 4. the inability to transport the patient to an ER equipped for thoracotomy within 10 minutes of cardiorespiratory arrest.

After the HEMS crew and EMS personnel agree on the indication for out of hospital thoracotomy, the patient is placed in supine position, asepsis is applied and bilateral thoracostomies are created in the 5<sup>th</sup> intercostal space in the mid-axillary line to exclude a tension pneumothorax as a possible cause for arrest. If circulation does not recover, both thoracostomies are connected resulting in a clamshell thoracotomy. A Finochietto rib-spreader is used for permanent exposure. After opening the thorax and pericardium, fluids and clotted blood are removed and bleeding wounds in the heart are occluded with a finger, a balloon catheter or sutures (Figure 2). If the heart does not start beating spontaneously, internal massage is attempted with additional procedures such as leg raise, prehospital blood transfusion or transthoracic defibrillation (if ventricular fibrillation occurs) at the discretion of the treating physician. When exsanguination from a source outside of the heart is encountered (lung, great vessels or below the diaphragm), hemostatic measures including lung twist or cross-clamping the aorta may be attempted. In case of return of spontaneous circulation (ROSC), standard post ROSC care is initiated and the patient is transferred to the nearest trauma center. If no ROSC is noted 15 min after opening of the pericardium further resuscitation is withheld.



**Figure 1:** Thoracotomy training in the cadaver lab on fresh-frozen body



**Figure 2:** On-scene clamshell thoracotomy

Our thoracotomy kit contains the following instruments; 2 pair of protective goggles, 2 pair of surgical gloves, anti-septic solution, gauzes, five abdominal packs, two disposable scalpels

(size 20), one pair of heavy scissors, two hemostatic clamps, two forceps, one pair of Metzenbaum scissors, a Gigli-saw, a Finocietto ribspreader, a needle holder, one double armed polypropylene 3-0 suture, a 6 Fr Foley Catheter and a skin stapler.

**Table 1:** Characteristics and outcome of patients undergoing out of hospital thoracotomy for cardiac arrest following penetrating chest injury

	Stab wound N=23	Gunshot wound N=10
Age		
Median (SD)	38 (18)	31 (9)
Unknown	5	1
Delay between arrest and thoracotomy		
Witnessed	5 (22%)	2 (20%)
<10 min	11 (48%)	3 (30%)
>10 min	5 (22%)	2 (20%)
Unknown	2 (8%)	3 (30%)
Peri-arrest rhythm		
EMD	16 (70%)	3 (30%)
Asystole	6 (26%)	5 (50%)
Unknown	1 (4%)	2 (20%)
Other penetrating injuries		
None	19 (84%)	7 (70%)
Abdomen	1 (4%)	0
Head	0	2 (20%)
Abdomen and neck	1 (4%)	1 (10%)
Extremity	2 (8%)	0
Technique		
Anterolateral	4 (17%)	0
Clamshell	19 (83%)	10 (100%)
Cardiac Tamponade		
Yes	14 (61%)	1 (10%)
No	9 (39%)	7 (70%)
Unknown	0	2 (30%)
Outcome		
Dead at the scene	14 (61%)	10 (100%)
Dead in ER	2 (9%)	0
Dead in OR	3 (13%)	0
Dead in ICU	3 (13%)	0
Survival to discharge	1 (4%)	0

### Data collection and statistical analysis

This study is a retrospective analysis of data collected between April 1<sup>st</sup>, 2011 and September 30<sup>th</sup>, 2016. Patients were identified by searching a prospective database of patients undergoing out of hospital emergency thoracotomy. This was cross checked and supplemented by data from a computer database in which all

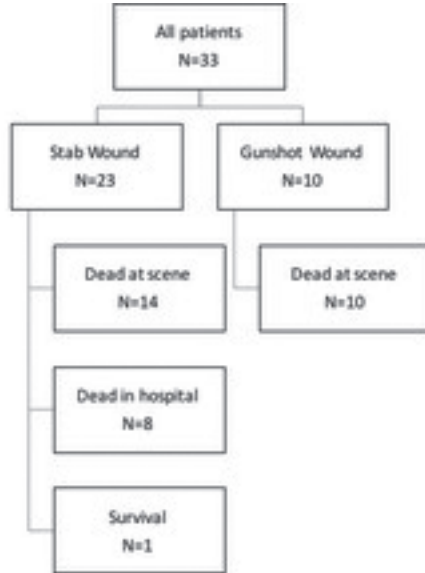
Dutch HEMS dispatches are registered using the Dutch terms for "thoracotomy" and relevant synonyms. Missing data as well as data on in-hospital treatment and outcome were retrospectively acquired from the electronic patient files. The following variables were collected; age, gender, trauma mechanism, peri-arrest ECG rhythm, delay between cardiac arrest and thoracotomy, technique used to enter the thorax, injuries found after thoracotomy and outcome. Data were analyzed using the Statistical Package for the Social Sciences (SPSS) version 23.0 (SPSS, Chicago, Ill., USA). Missing values were not imputed. For continuous parametric data (e.g., age) the mean and standard deviation, and for continuous non-parametric data the median and percentiles are reported. For categorical data (e.g., gender) numbers and frequencies are reported. The study protocol was approved by the Medical Research Ethics Committee of the coordinating center.

## RESULTS

A total of 33 out of hospital thoracotomies were performed. Fourteen thoracotomies (42%) were performed by five trauma surgeons and 19 thoracotomies (58%) were performed by eleven anesthesiologists. Patient characteristics and outcome are presented in table one, stratified by trauma-mechanism.

Zero out of ten patients with gunshot wounds had return of spontaneous circulation. Nine out of 23 patients with stab wounds (39%) had return of spontaneous circulation after thoracotomy on-scene and were presented to the hospital with spontaneous circulation (Figure 3). Of these, one patient (4%) survived neurologically intact to hospital discharge. Three patients died in the ICU (13%) among whom was one patient that died as a result of ongoing hemorrhage from a stab wound to the neck combined with severe coagulopathy. Two patients were found to have severe post-anoxic brain damage once in ICU and further treatment was withheld. Two patients (9%) succumbed in the ER due to ongoing hemorrhage from other penetrating injuries to superior vena cava injury and aorta respectively. Three patients (13%) died in the OR: One died due to exsanguination from a large right ventricle tear, another patient died due to cardiac

failure resulting from right ventricle ischemia following traumatic transection of the right main coronary artery and the third patient died due to refractory cardiogenic shock after prolonged open chest cardiac massage.



**Figure 3:** Flowchart with patient outcomes

The one surviving patient in this series was a 35-year-old man that sustained a stab wound just below the left nipple. On arrival of the ground EMS and HEMS crew within 10 minutes of the initial call, the patient was still conscious and had spontaneous circulation. The patient was urgently loaded into the ambulance. An ultrasound performed during transportation to the nearest trauma center confirmed cardiac tamponade. Seconds after the diagnosis, the patient went into circulatory arrest. After tracheal intubation a left anterolateral thoracotomy was performed by the HEMS physician in the ambulance. The pericardial sac was opened and blood clots evacuated. The patient regained spontaneous circulation and there was profuse bleeding from a penetrating wound in the anterior side of the right ventricle which was successfully occluded with gentle finger pressure. Once in the hospital, the patient was urgently transferred to the OR where the perforation was sutured with minimal further blood loss. Apart from a slightly prolonged period of ICU admission

due to pneumonia, the further course was uneventful. Nine days after hospital admission the patient was discharged home without any neurological impairment.

### **Provider Safety**

Multiple glove tears with subsequent skin exposure to the patient's blood were reported (no complete data). Two HEMS physicians reported a superficial skin cut following scalpel injury during the prehospital surgery. In both cases, the patients' blood was found to be free of pathogens.

## **DISCUSSION**

This paper describes the introduction of prehospital emergency thoracotomy in the Dutch HEMS operation. A total of 33 prehospital emergency thoracotomies were performed in patients suffering cardiac arrest after sustaining penetrating thoracic injury. Nine patients had ROSC and one patient survived to hospital discharge. Since 59% of thoracotomies were performed by anesthesiologists (among which the only surviving patient in this series), we believe this procedure can be successfully taught to and safely performed by all Dutch HEMS physicians (7). Outcomes in the current series are relatively poor when compared to the scarce data that is available on the subject. However, we believe this large consecutive case series to be an important addition to the existing literature, as it may provide important lessons for other pre-hospital services with regard to expected outcomes and potential pitfalls. In 2001, Coats *et al.* reported on 34 patients in cardiac arrest after sustaining penetrating thoracic injury (gunshot or stab wound) undergoing out of hospital emergency thoracotomy of whom four patients survived (10%) (8). Four years later, after excluding all patients that did not meet the very stringent inclusion criteria for their study, Davies *et al.* reported on 71 patients with a single stab wound to the chest and a delay of less than 10 minutes between arrest and thoracotomy. Thirteen patients survived (18%) (4). From both series it is clear that patients with cardiac arrest due to a single stab wound to the chest and a short delay to thoracotomy have the best odds of survival.

This notion is further supported by the fact that all available case series and case reports that document survival after out of hospital emergency thoracotomy pertain to patients with a single stab wound to the chest or epigastrium, a short delay to thoracotomy and cardiac tamponade upon opening the chest (6,9,10). Indeed, when we limit the current analysis to this group of patients with a single stab wound, short delay and cardiac tamponade, the survival rate in this series is one out of seven (14%). Conversely, it is clear from the current series as well as other available data that patients going into cardiorespiratory arrest after sustaining gunshot wounds to the heart, patients with multiple gunshot or stab wounds, patients without signs of life after sustaining their injury and patients who arrest as a result of exsanguination do uniformly succumb when going into cardiac arrest in an out of hospital setting, even when on-scene emergency thoracotomy is performed. Withholding resuscitative thoracotomy in these patients remains a point of debate. Experience from ER thoracotomy has shown that even in these patients there is an -albeit small- chance of neurologically intact survival (1,3,11). Since the available data on out of hospital emergency thoracotomy for pulseless patients with gunshot wounds to the chest is extremely limited, the first survivor may as well be expected. Whether out of hospital thoracotomy should be performed in patients with cardiopulmonary arrest after blunt force trauma has not been addressed in the current study. Although some Dutch HEMS physicians have achieved return of spontaneous circulation in patients with a witnessed arrest after blunt trauma (but no survivors), we decided not to include these patients in the current study. A Japanese series reporting on 34 prehospital thoracotomies for blunt trauma did not identify any survivors in their cohort either (12). Patient selection is probably the largest contributor to the poor overall results in this series. More stringent criteria will certainly lead to less futile thoracotomies, but may refute some patients a last chance of survival.

Perhaps ultrasound may aid a better identification of potential survivors, as a recent study showed that the absence of both cardiac motility and pericardial effusion on transthoracic ultrasound is associated with zero survivors(13). On the other



side, precious time may be lost while performing ultrasound which may even affect neurological outcome. Two other factors should be considered when evaluating the poor survival-rate in this study. First, as this is a novel procedure for most of Dutch HEMS physicians, many may not have reached the top of their learning curve for out of hospital emergency thoracotomy yet. Second, of the nine patients who had ROSC and made it to the hospital, eight succumbed in the ED, OR, or ICU. As these nine patients were admitted to seven different hospitals across the country, experience with patients presented after prehospital emergency thoracotomy is severely limited in most emergency departments. Better education and selection of receiving hospitals and the development of specific protocols for these patients may contribute to a higher rate of survivors in the near future. Of the eight patients that made it to the hospital but did not survive until discharge, uncontrollable hemorrhage was the cause of death in four patients. Two patients died due to severe post-anoxic brain damage and two patients due to cardiac failure. Unfortunately, the exact cause of death in patients that did not make it to the hospital is unknown in the current series. Likely, the majority of these patients will have suffered from massive cardiac or intrapericardial great vessel injury, extrapericardial great vessel injuries, parenchymal lung injuries or mixed injuries with concomitant exsanguination. Indeed, a series from South Africa identified these injuries to be responsible for 50%, 22%, 15% and 13% of prehospital deaths resulting from penetrating thoracic trauma respectively (14). One of the major concerns we had regarding the introduction of this procedure is provider safety. As a significant proportion of trauma victims may be carrier of blood borne pathogens, this is a main concern (15). Indeed, some have reported glove tears and two incidents were reported in which the HEMS physician sustained a penetrating finger injury. Luckily, no blood borne pathogens were detected in the trauma victims blood. Wearing double gloves and protective eye gear and incorporating the risk of incidents due to sharp needles, knives or fractured ribs in the team briefing should be standard of care. Another concern is the psychological burden laid upon non-medical emergency providers personnel at the scene, since being confronted with an opened chest may be a traumatic experience. We recommend rapid

pre-briefing and post-procedural debriefing. Additional support should be offered if needed.

In summary, out of hospital emergency thoracotomy for pulseless patients with penetrating thoracic injury was successfully implemented in the Dutch HEMS operation leading to return of spontaneous circulation after thoracotomy in 27% of patients and a first survivor. We therefore believe prehospital emergency thoracotomy is a feasible and justified resuscitative procedure in the trauma care system of the Netherlands. However, since out of hospital thoracotomy exerts certain risks for the healthcare providers and may be a traumatic experience for bystanders, exact indications and contra-indications should be an area of constant evaluation.

## REFERENCES

1. Seamon MJ, Haut ER, Van Arendonk K, Barbosa RR, Chiu WC, Dente CJ, et al. An evidence-based approach to patient selection for emergency department thoracotomy: A practice management guideline from the Eastern Association for the Surgery of Trauma. *J Trauma Acute Care Surg.* 2015;79(1):159-73.
2. Truhlar A, Deakin CD, Soar J, Khalifa GE, Alfonzo A, Bierens JJ, et al. European Resuscitation Council Guidelines for Resuscitation 2015: Section 4. Cardiac arrest in special circumstances. *Resuscitation.* 2015;95:148-201.
3. Van Waes OJ, Van Riet PA, Van Lieshout EM, Hartog DD. Immediate thoracotomy for penetrating injuries: ten years' experience at a Dutch level I trauma center. *Eur J Trauma Emerg Surg.* 2012;38(5):543-51.
4. Davies GE, Lockey DJ. Thirteen survivors of prehospital thoracotomy for penetrating trauma: a prehospital physician-performed resuscitation procedure that can yield good results. *J Trauma.* 2011;70(5):E75-8.
5. Flaris AN, Simms ER, Prat N, Reynard F, Caillot JL, Voiglio EJ. Clamshell incision versus left anterolateral thoracotomy. Which one is faster when performing a resuscitative thoracotomy? The tortoise and the hare revisited. *World J Surg.* 2015;39(5):1306-11.
6. Wise D, Davies G, Coats T, Lockey D, Hyde J, Good A. Emergency thoracotomy: "how to do it". *Emerg Med J.* 2005;22(1):22-4.
7. Puchwein P, Sommerauer F, Clement HG, Matzi V, Tesch NP, Hallmann B, et al. Clamshell thoracotomy and open heart massage--A potential life-saving procedure can be taught to emergency physicians: An educational cadaveric pilot study. *Injury.* 2015;46(9):1738-42.
8. Coats TJ, Keogh S, Clark H, Neal M. Prehospital resuscitative thoracotomy for cardiac arrest after penetrating trauma: rationale and case series. *J Trauma.* 2001;50(4):670-3.
9. Corral E, Silva J, Suarez RM, Nunez J, Cuesta C. A successful emergency thoracotomy performed in the field. *Resuscitation.* 2007;75(3):530-3.
10. Wright KD, Murphy K. Cardiac tamponade: a case of kitchen floor thoracotomy. *Emerg Med J.* 2002;19(6):587-8.
11. Keller D, Kulp H, Maher Z, Santora TA, Goldberg AJ, Seamon MJ. Life after near death: long-term outcomes of emergency department thoracotomy survivors. *J Trauma Acute Care Surg.* 2013;74(5):1315-20.
12. Matsumoto H, Mashiko K, Hara Y, Kutsukata N, Sakamoto Y, Takei K, et al. Role of resuscitative emergency field thoracotomy in the Japanese helicopter emergency medical service system. *Resuscitation.* 2009;80(11):1270-4.

13. Inaba K, Chouliaras K, Zakaluzny S, Swadron S, Mailhot T, Seif D, et al. FAST ultrasound examination as a predictor of outcomes after resuscitative thoracotomy: a prospective evaluation. *Ann Surg.* 2015;262(3):512-8; discussion 6-8.
14. von Oppell UO, Bautz P, De Groot M. Penetrating thoracic injuries: what we have learnt. *Thorac Cardiovasc Surg.* 2000;48(1):55-61.
15. Sloan EP, McGill BA, Zalenski R, Tsui P, Chen EH, Duda J, et al. Human immunodeficiency virus and hepatitis B virus seroprevalence in an urban trauma population. *J Trauma.* 1995;38(5):736-41.





# Chapter Eight

---

van Waes OJF, Van Lieshout EMM, Van Silfhout DJ, Halm JA, Wijffels MME, Van Vledder MG, Van Leur-de Graaff HP, Verhofstad MHJ. Outcome after introduction of a selective non-operative management protocol for penetrating abdominal injury in a Dutch level I trauma center.

Accepted by Ann R Coll Surg Engl

## INTRODUCTION

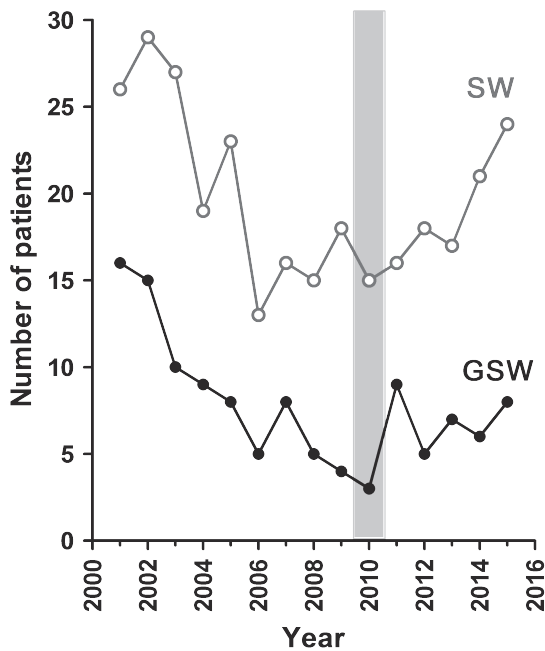
The selective non-operative management (SNOM) for penetrating abdominal injury has been proposed by military surgeons during World War II to diminish the rate of unnecessary laparotomies with their increased morbidity and mortality, as mentioned by Shaftan in the Nineteen-sixties who advocated SNOM for PAI in the civilian population (1). SNOM) is now an accepted treatment option for penetrating abdominal injury (PAI) in trauma centers with a high volume for penetrating injury (PI) such as in South Africa and the United States of America. SNOM for PAI will diminish the days of hospitalization and the rate of non-therapeutic laparotomies and concomitant complications (2-4). Trauma care providers in Western Europe are hesitant to implement SNOM for PAI, especially when PAI is due to a gunshot wound (GSW) (5-9). In spite of being a relatively low volume center for PI, our Dutch Level I trauma center receives nearly twice the number (around 7% versus 4%) of patients suffering from PI with an Injury Severity Score (ISS) of 16 and over than other Trauma Centers participating in the trauma registry of the Deutsche Gesellschaft für Unfallchirurgie (TraumaRegisterDGU®) (10). The average number of patients admitted with PAI is between 25-30 annually and has been increasing the last five years (Figure 1). This relative abundance of PAI led to the introduction of a protocol for SNOM. In this study the outcome of patients treated for PAI in our Dutch Level I trauma center was evaluated and compared, considering the implementation of a protocol for PAI including SNOM.



## METHODS

### Population and setting

All patients with PAI presenting to the emergency department (ED) of a Level I trauma center in The Netherlands between January 1, 2001 and December 31, 2015 were extracted from the trauma registry containing 22,149 trauma patients registered during the study period. Approval for this study was obtained from the local Medical Research Ethics Committee (study number MEC-2016-657). Only patients with PAI either due to assault or self-inflicted wounds were included. In order to prevent bias, patients admitted with PAI six months before and after implementation of the PAI algorithm (February 1, 2010) were excluded (Figure 1).



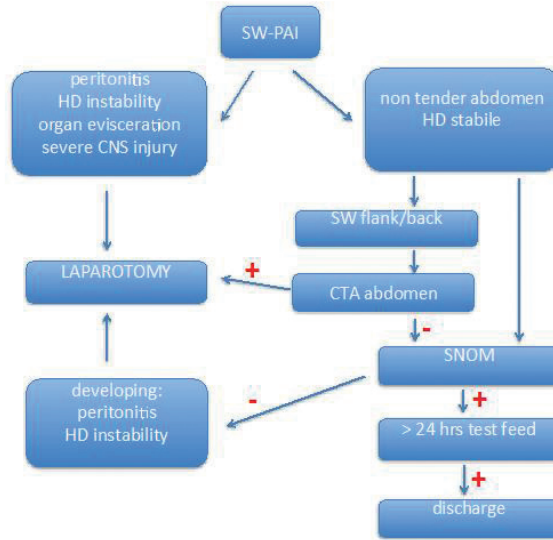
**Figure 1:** Number of patients admitted with penetrating abdominal injury (PAI) per year  
Grey bar: period excluded from analysis and marks transition to new protocol

## **Implemented protocol for management of penetrating abdominal injury**

After implementation of the protocol, patients were managed and treated according to an institutionalized protocol for either SW-PAI or GSW-PAI (Figure 2). Prior to implementation, patients were managed on an ad hoc basis choosing between SNOM or an operative treatment (OT).

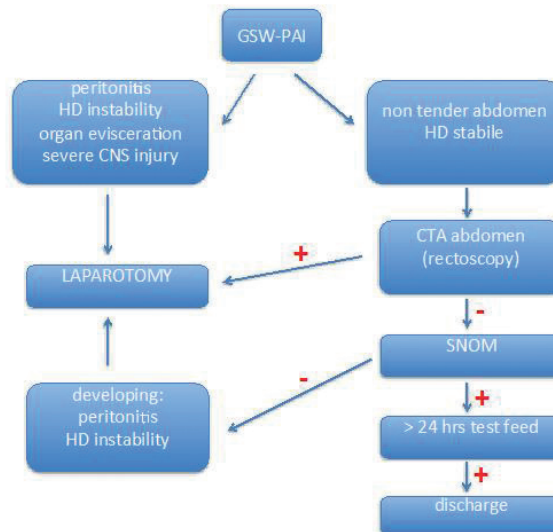
The protocol stated that all patients were considered at risk for a PAI if they sustained stab wounds (SW) ranging cranially anterior from the level of the fourth intercostal, down to the pubic bone caudally, continuing laterally wrapping around to the posterior abdomen following the iliac crest to the buttock crease and posterior up cranially to the inferior scapulae tips. For gunshot wounds (GSW) these margins were increased judiciously (including the groin region anteriorly and buttocks posteriorly). Special attention was paid to inspection of body creases and folds. If the patients were suspected for PAI according to the aforementioned definitions they were assessed and resuscitated according to the ATLS® guidelines (11) and subsequently managed according to the local SW/GSW PAI protocol (Figure 2).

A resuscitative anterolateral emergency department thoracotomy (EDT) was indicated for patients who presented with loss of signs of life (SOL) but with a witnessed cardiac arrest less than 15 minutes before. Witnessed loss of SOL in the ED or a persistent systolic hypotension (<60 mmHg) despite aggressive resuscitation also warranted an EDT. All hemodynamically stable patients (systolic >90 mmHg) and patients stabilized after resuscitation from moderate shock (systolic BP >60 mmHg and <90 mmHg) underwent a plain chest X-ray as part of ATLS® protocol. Hemodynamically instability, peritonitis and organ evisceration were indication for urgent exploratory laparotomy in the operating theater. Laparoscopy for primary assessment or treatment was not advocated in the protocol. Plain abdominal X-ray was reserved for GSW-PAI. Wound markers were used to delineate possible bullet tracks. An uneven number warranted additional investigations in adjacent body regions. Abdominal ultrasound assessment and local wound exploration on the ED were not advocated.



**Figure 2a:** Treatment algorithm for patients suffering from penetrating abdominal injury (PAI) due to stab wounds (SW)

SW-PAI, penetrating abdominal injury due to stab wounds; HD, hemodynamic; CNS, central nervous system; SW, stab wound; CTA, computed tomography angiogram; SNOM, selective non-operative management.



**Figure 2b:** Treatment algorithm for patients suffering from penetrating abdominal injury (PAI) due to gunshot wounds (GSW)

GSW-PAI, penetrating abdominal injury due to gunshot wounds; HD, hemodynamic; CNS, central nervous system; GSW, gunshot wound; CTA, computed tomography angiogram; SNOM, selective non-operative management.

Computed tomography angiography (CTA) was indicated for hemodynamically stable patients with posterior abdomen or flank SW to excluded retroperitoneal injury and assess whether or not the patient was a suitable candidate for SNOM. All hemodynamically stable patients with a GSW without peritonitis underwent CTA to evaluate the track of the projectile and amiability for SNOM.

Patients admitted for observation were kept nil by mouth with hourly control of vital parameters (blood pressure, heart rate, respiratory rate, and temperature). The admitting surgeon performed four-hourly abdominal examination to exclude peritonitis and general abdominal symptoms (distention, nausea and vomitus). An uneventful observation period of 24 hours followed by well-tolerated oral intake declared the patient ready for discharge with instructions for aftercare and was defined as successful SNOM.

### **Data collection**

Age, gender, mechanism and type of injury, clinical manifestations and vital signs at presentation as well as Injury Severity Score (ISS), additional investigations performed, chosen treatment strategy (SNOM versus OT) and outcome of all patients were extracted and analyzed. The indication for OT, whether or not in a damage control surgery fashion (DCS), or a non-therapeutic laparotomy (NTL) was performed and the occurrence of adverse events were assessed by five experienced trauma care providers (OJFVW, MMEW, MHJV, HPVLDEG, MHJV).

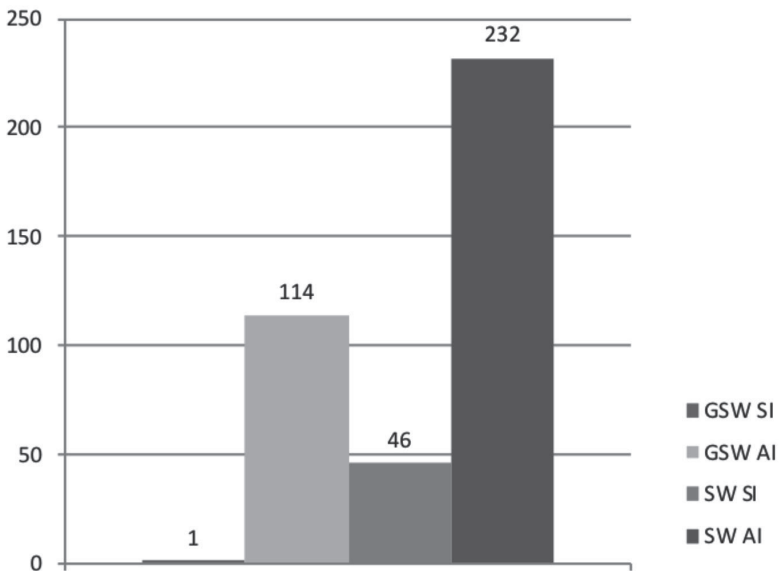
### **Statistical analysis**

All calculations and statistical analyses were performed using SPSS statistics version 21.0. Continuous data were non-parametric, and are presented as median with  $P_{25}$ - $P_{75}$ . Categorical data are shown as numbers with percentages. Statistical significance of difference between  $p < 0.001$  and  $p < 0.05$  was assessed using a Mann-Whitney U-test for continuous data and a Chi-Squared test or Fisher Exact test for categorical data.

# RESULTS

## Demographics

In the 15 year study period 415 patients were diagnosed with PAI. Twenty-two patients admitted within the six months before and after implementation of the PAI algorithm (February 1, 2010) were excluded in order to prevent bias. From the remaining 393 patients, 346 (88%) sustained wounds during assaults, the remnant was self-inflicted (Figure 3). Most patients were presented by the emergency medical services, 13 (11%) with GSW and 36 (13%) with SW were self-referrals.



**Figure 3:** Representation of the type of penetrating abdominal injury SW AI, abdominal stab wound assault-induced; SW SI, abdominal stab wound self-inflicted; GSW AI, abdominal gunshot wound assault-induced; GSW SI; abdominal gunshot wound self-inflicted.

PAI was due to SW in 278 patients (71%) of whom 84% male with a median age of 33 years ( $P_{25}$ - $P_{75}$  23-44). Patients presented with a median Injury Severity Score (ISS) of 8 ( $P_{25}$ - $P_{75}$  2-14); 68 (25%) with an ISS  $\geq$  16. Baseline characteristics did not differ significantly before and after protocol implementation. Median systolic blood pressure at the ED (BP), hemoglobin level (Hb) and acidity (pH) for SW were similar, respectively 134 mmHg ( $P_{25}$ - $P_{75}$

117-148) ( $p=0.161$ ), 8.6 millimol per liter (mmol/L) ( $P_{25}-P_{75}$  7.6-9.2) ( $p=0.612$ ) and pH of 7.36 ( $P_{25}-P_{75}$  7.28-7.40) ( $p=0.309$ ).

For 115 GSW patients (29%) of whom 94% male with a median age of 30 years ( $P_{25}-P_{75}$  24-38), the median ISS was 17 ( $P_{25}-P_{75}$  10-25); 66 (57%) presented with an ISS  $\geq 16$ . No significant differences were found between pre- and post-protocol implementation regarding age ( $p=0.279$ ) or ISS ( $p=0.967$ ). There was also no significant difference for the median values of the median systolic blood pressure 140 mmHg ( $P_{25}-P_{75}$  114-155) ( $p=0.937$ ), median Hb 7.9 mmol/L ( $P_{25}-P_{75}$  6.6-9.1) ( $p=0.085$ ) and pH 7.34 ( $P_{25}-P_{75}$  7.29-7.38) ( $p=0.552$ ).

Thoraco-abdominal injuries were found in 41 GSW patients (36%) versus 42 (15%) in SW. Pelvic region injuries were uncommon; GSW  $n=11$  (10%) versus SW  $n=6$  (2%). Additional injured body regions were predominantly thorax (GSW 43%, SW 26%), extremities (GSW 37%, SW 24%) and head/neck (GSW 10%, SW 15%). A total of 4 patients, all PAI due to GSW, were in need of a resuscitative thoracotomy (three before, one after protocol initiation who survived).

The number of CTA evaluations did not differ. In GSW patients, 47 scans (60%) before, versus 29 (78%) after ( $p=0.061$ ). In SW patients, 103 scans (58%) versus 54 (54%) before and after protocol respectively ( $p=0.614$ ). The number of US however dropped significantly from  $n=68$  (87%) to  $n=16$  (43%) ( $p<0.001$ ) for GSW, and for SW from  $n=150$  (84%) to  $n=32$  (32%) ( $p<0.001$ ) (Table 1).

### **Treatment**

Patients suffering from PAI due to stab wounds (SW) 178 before versus 100 after protocol were admitted for treatment; respectively 111 (62%) and 59 (59%) were treated with SNOM with a success rate of 90% and 88% (Table 2).

For the 32 (41%) GSW patients treated with SNOM before protocol implementation and 11 (30%) after, the success of SNOM was 94% and 100% respectively (Table 2).

**Table 1:** Patient demographics and diagnostic adjunctives for stab wounds versus gunshot wounds, before and after implementation of protocol

	Pre-protocol		Post-protocol		P <sub>sw</sub>	P <sub>gsw</sub>
	SW	GSW	SW	GSW		
	N=178 (69.5%)	N=78 (30.5%)	N=100 (73.0%)	N=37 (27.0%)		
Age (years)	34 (24-43)	30 (24-36)	32 (24-45)	31 (24-43)	0.911	0.279
Male (%)	149 (83.7%)	73 (93.6%)	84 (84.0%)	35 (94.6%)	1.000	1.000
ISS	6 (3-13)	17 (9-25)	9 (2.0-18)	18 (10-24)	0.676	0.967
SBP (mmHg)	137 (118-149)	138 (110-160)	130 (115-147)	140 (120-151)	0.161	0.937
Hb (mmol/L)	8.6 (7.5-9.3)	7.8 (6.5-8,9)	8.6 (7.9-9.2)	8.7 (6.9-9.3)	0.612	0.085
pH	7.36 (7.29-7.40)	7.33 (7.27-7.38)	7.35 (7.28-7.39)	7.34 (7.30-7.38)	0.309	0.552
CTA	103 (57.9%)	47 (60.3%)	54 (54.0%)	29 (78.4%)	0.614	0.061
US	150 (84.3%)	68 (87.2%)	32 (32.0%)	16 (43.2%)	<b>&lt;0.001</b>	<b>&lt;0.001</b>
X-abdomen	11 (6.2%)	34 (43.6%)	1 (1.0%)	4 (10.8%)	0.061	<b>0.001</b>

Data are shown as n (%) or as median (P<sub>25</sub>-P<sub>75</sub>).

SW, stab wound; GSW, gunshot wound; ISS, injury severity score; SBP, systolic blood pressure; Hb, hemoglobin (mmol/L); Ph, acidity; CTA, Computed tomography angiography; US, ultrasound; X-abdomen, abdominal X-ray.

The success rate of SNOM for both SW and GSW was not significantly different before or after implementation (p=0.794 versus p=1.000). None of the twenty patients in whom SNOM failed (2 GSW and 18 SW) and subsequently underwent laparotomy, died. In total eight patients (4%) developed adverse events after initial SNOM. In two successful SNOM patients, both after protocol implementation, adverse events were noted; one patient suffering a tangential GSW to the liver developed an intra-abdominal abscess that was successfully treated with percutaneous drainage. The other patient required additional coiling for hemorrhage from a kidney injury not diagnosed upon admission for SNOM of SW to the back. Six other patients who failed SNOM and progressed to an exploratory laparotomy were in need for a relook. One for breakdown of a bowel anastomosis, one for dehiscence of the laparotomy wound and in four patients for a washout of intra-abdominal absces. The need for interventional radiology during SNOM was limited, and comparable between pre- and post-protocol implementation, for GSW n= 2(3%) versus n=3(8%) (p=0.326) and SW n=3 (2%) versus n=4 (4%) (p=0.256). Hospitalization for SW treated with SNOM did differ, but without clinical relevance, with a median 3 (P<sub>25</sub>-P<sub>75</sub> 2-4) versus 3 (P<sub>25</sub>-P<sub>75</sub> 2-6) on the ward (p=0.042), and equal for the ICU with both 2 (P<sub>25</sub>-P<sub>75</sub> 2-3) days before and after protocol (p=0.893). The same applied for SNOM

**Table 2:** SNOM and operative treatment for stab wounds versus gunshot wounds, before and after implementation of protocol  
Data are shown as n (%) or median ( $P_{25}$ - $P_{75}$ ).

	Pre-protocol (N=178)		Post-protocol (N=100)		$P_{sw}$	$P_{gsw}$
	SW	GSW	SW	GSW		
<b>SNOM</b>	111 (62.4%)	32 (41.0%)	59 (59.0%)	11 (29.7%)	0.609	0.304
SNOM success	100 (90.1%)	30 (93.8%)	52 (88.1%)	11 (100.0%)	0.794	1.000
failed	11 (9.9%)	2 (6.3%)	7 (11.9%)	0 (0.0%)		
Laparotomy AFS	11 (100.0%)	2 (100.0%)	7 (100.0%)	0 (0.0%)	N.A.	N.A.
Laparoscopy AFS	0 (0.0%)	0 (0.0%)	0 (0.0%)	0 (0.0%)		
NTL AFS	2 (18.2%)	0 (0.0%)	1 (14.3%)	0 (0.0%)	1.000	N.A.
RI	3 (1.7%)	2 (2.6%)	4 (4.0%)	3 (8.1%)	0.256	0.326
LOS ST (days)	3 (2-4)	5 (2-10)	3 (2-6)	3 (2-18)	<b>0.042</b>	0.863
ICU ST (days)	2 (2-3)	2 (2-5)	2 (2-3)	2 (2-10)	0.893	0.614
AE ST	3 (2.7%)	0 (0%)	4 (6.8%)	1 (9.1%)	0.238	0.256
SNOM mortality	1 (0.9%)	3 (9.4%)	0 (0.0%)	0 (0.0%)	1.000	0.558
<b>OT</b>	67 (37.6%)	46 (59.0%)	41 (41.0%)	26 (70.3%)	0.304	0.609
Laparotomy	65 (97.0%)	46 (100.0%)	41 (100.0%)	26 (100.0%)	0.525	N.A.
Laparoscopy	2 (3.0%)	0 (0.0%)	0 (0.0%)	0 (0.0%)		
DCS	9 (11.5%)	9 (19.6%)	4 (8.3%)	5 (19.2%)	0.765	1.000
NTL	7 (10.4%)	3 (6.5%)	7 (17.1%)	2 (7.7%)	0.381	1.000
LOS OT(days)	9 (6-16)	12 (8-12)	8 (4-13)	9 (7-16)	0.175	0.051
ICU OT(days)	3 (2-6)	7 (2-31)	2 (1-4)	3 (2-6)	0.197	<b>0.038</b>
AE OT	12 (17.9%)	13 (28.3%)	5 (12.2%)	4 (15.4%)	0.588	0.260
OT mortality	7 (10.4%)	4 (8.7%)	2 (4.9%)	3 (11.5%)	0.478	0.698

SW, stab wound; GSW, gunshot wound; SNOM, selective non-operative management; AFS, after failed SNOM; RI, radiological intervention; LOS, length of stay on ward; ST, SNOM therapy; ICU, length of stay on intensive care unit; OT, operative therapy; AE, adverse events; DCS, damage control surgery; NTL, non-therapeutic laparotomy.



treated GSW with 5 ( $P_{25}$ - $P_{75}$  2-10) versus 3 ( $P_{25}$ - $P_{75}$  2-18) ( $p=0.863$ ) on the ward and 2 ( $P_{25}$ - $P_{75}$  2-5) versus 2 ( $P_{25}$ - $P_{75}$  2-10) on the ICU ( $p=0.614$ ).

Mortality rate from SNOM for SW pre- and post-protocol was similar,  $n=1$  (1%) versus  $n=0$  (0%) ( $p=1.000$ ). Mortality for GSW pre and post protocol,  $n=3$  (9%) versus  $n=0$ , was considered insignificant ( $p=0.558$ ). Two patients died of non-reversible shock due to extra-abdominal bleeding and two patients died of concomitant neurological injury.

Indications for operative treatment (OT) did not differ for SW before and after protocol, with the clinical and radiological (CT) aspect of the wound tract in  $n=32$  (41%) versus  $n=21$  (44%), shock  $n=21$  (27%) versus  $n=9$  (19%), peritonitis  $n=14$  (18%) versus  $n=11$  (23%) and failure of SNOM  $n=11$  (14%) versus  $n=7$  (15%) patients ( $p=0.739$ ). However, the indication for acute surgery did significantly change for GSW with a higher rate of peritonitis on abdominal investigation  $n=5$  (10%) versus  $n=10$  (38%), but less by the clinical and radiological aspect of the wound tract  $n=23$  (48%) versus  $n=8$  (31%), failure of SNOM  $n=2$  (4%) versus  $n=0$  (0%) and less due to shock  $n=18$  (38%) versus  $n=8$  (31%) ( $p=0.029$ ).

The majority of the primary OT for SW was a laparotomy ( $n=65$  (97%) before,  $n=41$  (100%) after protocol implementation). Laparoscopy was solely performed in the pre-protocol time frame ( $n=2$ ; 3%). For GSW only laparotomies were performed ( $n=72$ , 100%), of which 14 in damage control surgery (DCS) mode. DCS for SW was performed in 13 cases (10%). The rate of DCS did not differ (SW  $p=0.765$  and GSW  $p=1.000$ ). The survival after DCS was 52% ( $n=14$ ) and not influenced by the protocol ( $p=0.695$ ). The protocol did not change the rate of non-therapeutic laparotomies for both SW  $n=7$  (10%) versus  $n=7$  (17%) ( $p=0.381$ ) and GSW  $n=3$  (6%) versus  $n=2$  (8%) ( $p=1.000$ ). The rate of patients in need of re-laparotomy was similar for both GSW and SW (GSW  $n=9$  (11%) versus  $n=5$  (13%) ( $p=0.767$ ) and SW  $n=12$  (7%) versus  $n=6$  (6%) ( $p=1.000$ )). The rate of adverse events such as breakdown of the laparotomy wound, failure of vascular or intestinal anastomosis, intra-abdominal abscesses and iatrogenic injury was equal before and after protocol implementation both for SW  $n=12$  (18%) versus  $n=5$

(12%)) ( $p=0.588$ ) and GSW  $n=13$  (28%) versus  $n=4$  (15%) ( $p=0.260$ ). From all twenty-two initial NTL patients, two (9%) developed adverse events. One GSW patient was conservatively treated for a retroperitoneal abscess. The other SW patient became septic after a NTL due to a missed retroperitoneal colonic injury, for which a colonic diversion was required. The mean duration on the ICU after laparotomy for GSW was significantly reduced by the protocol from respectively 7 ( $P_{25}$ - $P_{75}$  2-31) days to 3 ( $P_{25}$ - $P_{75}$  2-6) days ( $p=0.038$ ). The ward days for GSW were similar, 12 ( $P_{25}$ - $P_{75}$  8-12) versus 9 ( $P_{25}$ - $P_{75}$  7-16) ( $p=0.051$ ). For SW both the ICU days, 3 ( $P_{25}$ - $P_{75}$  2-6) versus 2 ( $P_{25}$ - $P_{75}$  1-4) ( $p=0.175$ ) and post-operative ward days 9 ( $P_{25}$ - $P_{75}$  6-16) versus 8 ( $P_{25}$ - $P_{75}$  4-13) ( $p=0.588$ ) were similar. The mortality rate for operated GSW patients,  $n=4$  (9%) versus  $n=3$  (11%), was not significantly different ( $p=0.698$ ). Also a similar mortality rate was noted for operated SW patients,  $n=7$  (10%) versus  $n=2$  (5%) ( $p=0.478$ ). Three patients died of concomitant neurological injury, eleven of uncontrollable hemorrhage / persistent shock, one of multi-organ failure and one patient of cardiac arrest with unknown cause.

## DISCUSSION

The initiation of the management protocol for PAI patients did not increase the rate of patients treated conservatively (56% before versus 52% after). SNOM had similar success rates before and after protocol implementation 90% versus 88% respectively for SW and 94% versus 100% for GSW.

The combined mortality (both GSW and SW) for SNOM dropped after initiation of protocol from 3% to 0%, but not significantly different ( $p=0.305$ ).

After protocol implementation surgeons relied significantly more on clinical evaluation to move to laparotomy for abdominal gunshot wound patients (10% versus 38%) rather than on CT evaluation (48% versus 31%). Implementation was found to reduce the number of US examinations significantly from 87% to 43% for GSW and 84% to 32% for SW. Protocol implementation did not change the rate of non-

therapeutic laparotomies for both SW (10% versus 17%) and GSW (7% versus 8%) nor the rate of re-laparotomies (GSW 11% versus 13% and SW 7% versus 6%). After protocol implementation the ICU stay for GSW after laparotomy was reduced from 7 to 3 days.

Although SNOM for PAI due to SW is increasingly used in Western Europe, most trauma care providers in these countries are reluctant to treat PAI due to GSW with SNOM (5-9,12). This study reports, although in a low PI volume European trauma center, rates of success for SNOM (both SW and GSW) similar to South African and Northern American trauma centers (2-4,13). A protocol for PAI will guide the trauma care providers of (low volume) trauma centers to successful SNOM for PAI, and thus diminish the adverse events of a non-therapeutic laparotomy and reduce days of hospitalization (14-15).

A protocol also provides a scaffold for a diagnostic work-up, which forces the treating surgeon to rely more on clinical evaluation of the abdomen than redundant adjuncts. When needed an additional single contrast abdominal CT scan with a sensitivity of 98%, a specificity of 90%, a positive predictive value of 84%, a negative predictive value of 99% and an accuracy of 93% rather than ultrasound of the abdomen is advocated to predict the need for laparotomy in patients with PAI (16-18). Ultrasound is useful to excluded pericardial tamponade (or a pneumothorax) in a thoraco-abdominal penetrating injury. However it's low sensitivity (28-100%) and poor identification of hollow viscus injuries does not contribute to the management strategy for penetrating abdominal injury (3,18-20).

During clinical evaluation the wounds are never locally explored in the ED, because this is painful and time consuming, additionally stab wounds are rarely perpendicular to the abdominal wall (3). Furthermore laparotomies for anterior fascial penetration have been reported as negative in almost 50% (21). If peritonitis is equivocal or cannot be assessed, we progress to CT, or exploratory laparotomy. Serial examinations (four-hourly), preferably by the admitting surgeon, are essential to limit the failure and adverse event rate whilst treating the patient with SNOM (3,4,8,22,23). Whether or not abdominal symptoms within the

first 12 hours are prompting a laparotomy is to be considered a failure of SNOM is debatable. Alternatively it can be called part of the management chosen (24).

We abandoned laparoscopy to treat PAI in the acute phase. Equivocal patients undergo CT and are observed but not exposed to possible iatrogenic injury of a non-therapeutic diagnostic laparoscopy, or the possible complications of a missed hollow viscus injury during a "trauma" laparoscopy (13, 25). Laparoscopy is preserved for elective treatment of a patient suspect for isolated left-sided diaphragm injury (26). In this study the overall rate of AE was low after laparotomy (SW 16% and GSW 24%). The rate of failure of SNOM (10-12% SW and GSW 6-0%) was comparable to other Western European trauma centers with failure rate between 3 and 14%. The NTL rate was considerably lower (6-8% GSW and 10-17% SW) compared to other European reports (NTL rate 21-59%) (6,7,9). The median days admitted to the ward, 3 (3-7) for SNOM were 7 days less than in the operated patients 10 (7-18), which favors SNOM as a costs saver as mentioned by other studies (7,27).

## CONCLUSION

SNOM for PAI after both SW and GSW can be successfully implemented in Western European Trauma centers with a low volume of penetrating injuries. A protocol will guide the trauma care provider in evaluation of the patient and reduce unnecessary utilization of radiological adjuncts. A protocol will also help in the decision to treat the patient operatively or with SNOM and will reduce the days of postoperative hospitalization.

## REFERENCES

1. Shaftan GW. Selective conservatism in penetrating abdominal trauma. *J Trauma* 1969;9:1026-28
2. Navsaria PH, Nicol AJ, Edu S, Gandhi R, Ball CG. Selective Nonoperative Management in 1106 Patients With Abdominal Gunshot Wounds. Conclusions on Safety, Efficacy, and the Role of Selective CT Imaging in a Prospective Single-center Study. *Ann Surg.* 2015;261:760-764)
3. Navsaria PH, Berli JU, Edu S, Nicol AJ. Non-operative management of abdominal stab wounds - analysis of 186 patients. *SAJS.* 2007;45:128-132
4. Outcome of selective non-operative management of penetrating abdominal injuries of the North American National Trauma Database. Zafar SN, Rushing A, Haut ER, Kisat MT, Villegas CV, Chi A, Stevens K, Efron DT, Zafar H, Haider AH. *Br J of Surg* 2011; 99(Suppl 1): 155-165
5. Hoffmann C, Goudard Y, Falzone E, Leclerc T, Planchet M, Cazes N, Pons F, Lenoir B, Debien B. Management of penetrating abdominal trauma: What we need to know? *Ann Fr Anesth Reanim* 2013;32:104-111.
6. Casali M, Di Salomone S, Tugnoli G, Biscardi A, Villani S, Cancellieri F, Ciaroni V, Giordani A, Gordini G, Baldoni F. Penetrating abdominal trauma: 20 years experience in a Western European Trauma Center. *Ann Ital Chir* 2008;79:399-407.
7. Goin G, Massalou D, Bege T, Contargyris C, Avaro JP, Pauleau G, Balandraud P. Feasibility of selective non-operative management for penetrating abdominal trauma in France. *J Visc Surg* 2017;154(3):167-174
8. Jansen JO, Inaba K, Rizoli SB, Boffard KD, Demetriades D. Selective non-operative management of penetrating abdominal injury in Great Britain and Ireland: Survey of practice. *Injury* 2012;43:1799-1804
9. Van Brussel M, van Hee R. Abdominal stab wounds: a five-year patient review. *EJEM* 2001;8:83-88
10. [http://www.traumaregister-dgu.de/fileadmin/user\\_upload/traumaregister-dgu.de/docs/Downloads/TR-DGU\\_Annual\\_Report\\_2016.pdf](http://www.traumaregister-dgu.de/fileadmin/user_upload/traumaregister-dgu.de/docs/Downloads/TR-DGU_Annual_Report_2016.pdf)
11. American College of Surgeons Committee on Trauma (2004) Advanced trauma life support program for doctors, 9th edn. American College of Surgeons, Chicago
12. Van Vugt R, Bosscha K, Olsman J, Jager GJ, Canter de Jager CP. Management of hepatic trauma: a 9-year experience in 's-Hertogenbosch. *Acta Chir Belg* 2009;109:42-46
13. Como JJ, Bokhari F, Chiu WC, Duane TM, Holevar MR, Tandoh MA, Ivantury RR, Scalea TM. Practice management guidelines for selective nonoperative management of penetrating abdominal trauma. *J Trauma* 2010;68:721-733

14. Kevric J, O'Reilly GM, Gocentas RA, Hasip O, Pilgrim C, Mitra B. Management of haemodynamically stable patients with penetrating abdominal stab injuries: review of practice at an Australian major trauma centre. *Eur J Trauma Emerg Surg* 2016;42:671-675
15. Laing GL, Skinner DL, Bruce JL, Bekker W, Oosthuizen GV, Clarke DL. A multi faceted quality improvement programme results in improved outcomes for selective non-operative management of penetrating abdominal trauma in a developing world trauma centre. *Injury* 2014;45:327-332
16. Ramirez RM, Cureton EL, Ereso AQ, Kwan RO, Dozier KC, Sadjadi J, Bullard K, Liu TH, Victorino GP. Single-contrast computed tomography for the triage of patients with penetrating torso trauma. *J Trauma* 2009;67:583-588
17. Goodman CS, Hur JY, Adajar MA, Coulam CH. How well does CT predict the need for laparotomy in hemodynamically stable patients with penetrating abdominal injury? A review and meta-analysis. *Am J Roentgenol* 2009;193:432-437
18. De Vries CS, Africa M, Gebremariam FA, Janse van Rensburg J, Otto SF, Potgieter HF. The imaging of stab injuries. *Acta Rad* 2010;51:92-106
19. Varin DSE, Ringburg AN, van Lieshout EMM, Patka P, Schipper IB. Accuracy of conventional imaging of penetrating torso injuries in the trauma resuscitation room. *EJEM* 2009;16:305-311
20. Quinn AC, Sinert R. What is the utility of focused assessment with sonography in trauma (FAST) exam in penetrating torso trauma? *Injury* 2011;42:482-487
21. Como JJ, Bokhari F, Chiu WC, Duane TM, Holevar MR, Tandoh MA, Ivatury RR, Scalea TM. Practice management guidelines for selective nonoperative management of penetrating abdominal trauma. *J Trauma* 2010;68:721-733
22. Navsaria PH, Nicol AJ, Edu S, Gandhi R, Ball CG. Selective nonoperative management in 106 patients with abdominal gunshot wounds; Conclusions on safety, efficacy, and the role of selective CT imaging in a prospective single-center study. *Ann Surg* 2015;261:760-764
23. Laing GL, Skinner DL, Bruce JL, Bekker W, Oosthuizen GV, Clarke DL. A multi faceted quality improvement programme results in improved outcomes for selective non-operative management of penetrating abdominal trauma in a developing world trauma centre. *Injury* 2014;45:327-332
24. Clarke DL, Allorto NL, Thomson SR. An audit of failed non-operative management of abdominal stab wounds. *Injury* 2010;41:488-491
25. O'Malley E, Boyle E, O'Callaghan A, Coffey JC, Walsh SR. Role of laparoscopy in penetrating abdominal trauma: a systematic review. *World J Surg* 2013;37:113-122

26. D'Souza N, Bruce JL, Clarke DL, Laing GL. Laparoscopy for occult left-sided diaphragm injury following penetrating thoracoabdominal trauma is both diagnostic and therapeutic. *Surg Laparosc Endosc Percutan Tech* 2016;26:e5-e8
27. Dayananda KSS, Kong V, Bruce JL, Clarke DL. Selective non-operative management of abdominal stab wounds is safe and cost effective strategy: A South African experience. *Ann R Coll Surg Engl* 2017;6:490-496





# Chapter Nine

---

van Waes OJF, Navsaria PH, Verschuren RCm, Vroon LC, van Lieshout EMM, Halm JA, Nicol AJ, Vermeulen J. Management of penetrating injuries of the upper extremities. *Ulus Travma Acil Cerrahi Derg* 2013;19(5):405-10

## INTRODUCTION

Penetrating injuries to the extremities account for about 50% of penetrating traumas, but overall they are still very uncommon in West European countries(1,2). The low incidence makes it difficult for trauma surgeons to gain experience in its management. Moreover, patients with penetrating injury usually present unexpectedly to the emergency department. This could lead to an inappropriate preparation for assessment, especially when the hospital is not an allocated trauma center for such trauma with a protocol treatment strategy. Penetrating upper extremity trauma (PUET) is considered a difficult injury to manage because vascular and nerve injuries are serious and may significantly impair the patient outcome. [2,3] In the past, routine emergent exploration was common practice for the deeper penetrating trauma, resulting in a large number of unnecessary extremity explorations and iatrogenic injuries (1-4). Although rapid detection, localization and specification of a vascular injury in these patients are essential for the effective management of PUET, it is ill-advised to perform diagnostic computed tomography angiography (CTA) or conventional angiography in every patient (5-7). Over 90% of CTAs in these patients will be negative, representing a large cost as a screening tool(7). Based on the experience from high-volume hospitals in developing countries, selective screening based on physical examination is gaining in favor. The accuracy of the physical examination to detect vascular injury is very high in patients after penetrating trauma (6,8-10). Hard signs of a vascular injury (Table 1) mandate emergent surgical exploration, or, when the patient is hemodynamically stable, endovascular treatment could be considered (7-11). Diagnostic CTA is indicated in hemodynamically stable patients with clinical sign of vascular injury (Table 1). Similar to the case with penetrating trauma in other body regions, a selective non-operative management (SNOM) protocol should be used in PUET (2, 8, 9). Without signs of vascular impairment in PUET, a conservative observational strategy is likely (8). The present study was undertaken to assess SNOM in PUET in a tertiary referral trauma center (Groote Schuur Hospital, Cape Town), to which over 800 patients with penetrating trauma of the extremities present each year. Based

on the results, a management algorithm is proposed and adjusted towards health care in western countries.

**Table 1.** Signs of arterial injury

<b>Hard signs</b>
Active hemorrhage
Absent distal pulses or ischemia
Expanding or pulsatile hematoma
Bruit or thrill
<b>Soft signs</b>
Subjective reduced or unequal pulses
Large non-pulsatile hematoma
Orthopedic injuries carrying a high index of suspicion of vascular injury
Neural injury
History of bleeding

## **MATERIALS AND METHODS**

To create a database, details of all consecutive patients presenting with PUET to the Trauma Center at Groote Schuur Hospital in Cape Town, South Africa, from 6 June 2011 to 2 October 2011 (4 months) were prospectively collected using standardized data forms. Inclusion criteria were patients with PUET and age over 18 years. The range of injury that was included was from below the axilla up to the wrist of the upper extremity. Patients who died within 24 hours (hrs) due to other injuries were excluded from the study. Amongst others, age, gender, mechanism of injury, type of injury (vascular, orthopedic, nerve), clinical manifestations and vitals, indications for additional investigations, treatment strategy, and outcome of all patients were collected and analyzed. All patients were initially resuscitated along Advanced Trauma Life Support (ATLS®) guidelines. Hemodynamically stable patients and patients who stabilized after immediate simple resuscitation were first evaluated with a thorough history and clinical examination. Wounds were described by different anatomic zones of the arm (upper or lower arm, elbow or cubital fossa, anterior-posterior, medial-lateral). Special investigations were requested when indicated by a preset protocol based on history and clinical manifestations. A routine X-ray was performed in case of gunshot injuries. Indications for CTA were symptoms suggesting vascular

injury (hard and soft signs) as found by clinical examination of the upper extremities (Table 1) in the presence of a viable limb. If any severe injury was found by additional investigations and surgical care was needed, patients were immediately transferred to the operating room for surgical intervention. Hemodynamically stable patients with a negative history and clinical examination suggestive of vascular injury were admitted to the trauma surgical ward for observation and were discharged after 24 hours. All patients were informed about alarm symptoms of vascular injury; if these occurred, patients were advised to return to

**Table 2:** Demographics of 161 patients with penetrating upper extremity injury

Sex ratio (Male/Female)	140/21
Number of upper extremities injured	179
Median age, years (range)	27 (16-71)
<b>Penetrating upper extremity injury</b>	
Deep glass injury	13
Stab wound	132
Gunshot wound	34
<b>Zone of extremity injury</b>	
<i>Right arm</i>	
Upper	30
Elbow, cubital fossa	6
Lower	25
Upper and lower	4
<i>Left arm</i>	
Upper	53
Elbow, cubital fossa	4
Lower	40
Upper and lower	11
<i>Bilateral injury</i>	6
<b>Suspected extremity injury</b>	
<i>Vascular</i>	
Emergent exploration <sup>1</sup>	16 (14)
Computed tomography angiography <sup>1</sup>	24 (11)
<i>Fracture</i>	
X-ray <sup>2</sup>	19 (10)
<i>Nerve</i>	
Physical examination <sup>2</sup>	35 (11)
<b>Accompanying penetrating injury</b>	
Neck	14
Neck and chest	4
Chest	19
Abdomen	12
Chest and abdomen	6
Thigh	6

1: Values in parentheses are numbers of positive findings; 2: Values in parentheses are numbers of surgical interventions because of injury.

**Table 3:** Indications and results of emergent surgical exploration or additional vascular investigations.

<b>Indication for emergency exploration</b>	
Active hemorrhage or shock	4 (4)
Absent pulses	3 (3)
Foley catheter balloon tamponade failure	1 (1)
Hematoma accompanied with neural injury	8 (6)
<b>Indication for computed tomography angiography</b>	
Absent or diminished pulses	12 (6)
Large hematoma	3 (2)
Foley catheter balloon tamponade	2 (1)
Bruit	1 (1)
Injury at cubital fossa	3 (1)
Fracture and neural injury	1 (0)
Not specified	2 (0)

Values in parentheses are number of patients, if more than one.

the hospital immediately. Hemodynamically unstable patients and those with ischemia were immediately transferred to the operating room. In actively bleeding patients, hemorrhage control was attempted by using Foley catheter balloon tamponade (FCBT).[12] If hemorrhage control was not established, surgical exploration of the injured arm followed immediately. If hemorrhage was controlled by FCBT, CTA was performed to detect major arterial injury and, if positive, patients could still be transferred to the operating room or were treated by endovascular options. Without any serious arterial injury, the patient was observed for 24-48 hrs, after which the Foley catheter was removed in the operating room. In case of re-bleeding, surgical intervention was performed.

## **RESULTS**

A total of 162 patients with PUET presented during the four-month study period. One patient died of accompanying abdominal bleeding within 24 hrs after admission and was excluded from the study. Some patients had multiple wounds to the upper

extremities, with a total of 179 wounds in 161 patients (Table 2). Stab wounds (SW) or deeper penetrating glass wounds were found in 128 (79.5%) patients (145 arms) and gunshot wounds (GSW) in the remaining 33 (20.5%) patients (34 arms). Sixteen (9.9%) patients underwent emergency exploration because of active bleeding or hemodynamic instability not improving during initial resuscitation or due to other reasons mentioned in (Table 3). In all but two patients, an arterial injury was detected during exploration that required repair. A total of 24 (14.9%) patients underwent CTA (Table 3) for a suspected vascular injury. In 2 patients, CTA was performed without relevant indication and neither showed any vascular injury. A total of 3 patients were initially treated with FCBT because of active bleeding. In 1 patient, hemostasis could not be achieved, and the patient was subsequently emergently surgically treated. The other 2, in whom hemostasis was achieved, were observed and underwent diagnostic CTA within 24 hrs. Only 1 of these patients showed an arterial injury, which was repaired during semi-elective exploratory surgery. The Foley catheter of the patient, who did not need to undergo surgery, was removed in the operating room 2 days after the patient's presentation, and no re-bleeding occurred. Overall, 16 (9.9%) patients underwent emergency exploration of the upper extremity, including two negative explorations. Eventually, another 8 (5.0%) patients underwent elective surgery for a vascular injury (Table 4); no patients were treated with radiological intervention. One hundred and thirty-seven (85.1%) patients underwent non-operative management with observation only. Following observation, none of the patients subsequently needed surgical intervention to treat (late-onset) vascular complications. Some of the later-mentioned patients did undergo surgical treatment by orthopedics (n=10) or plastic or neurosurgeons (n=8). In 3 patients, the plastic surgeon joined the trauma surgeon during emergent exploration to repair a nerve injury primarily. The median hospital stay was 4 days (range, 1-30 days). Longer hospital stay was related to associated injuries as listed in Table 2. One patient died of abdominal sepsis after penetrating chest and abdominal injury. Upper extremity-related complications were surgical site infection in 8 of the patients that underwent surgery. Loss of function or other nerve impairment was found in only 5 patients, besides the

11 patients that underwent surgical repair of damaged nerves. Long-term functional outcome of these 11 patients was not known at the end of this study. Fractures of the upper extremity after penetrating injury were almost exclusively found after GSW. In 1 patient, an ulnar shaft fracture was found in a patient with SW in combination with blunt assault.

**Table 4: Summary of arterial injuries and their management.**

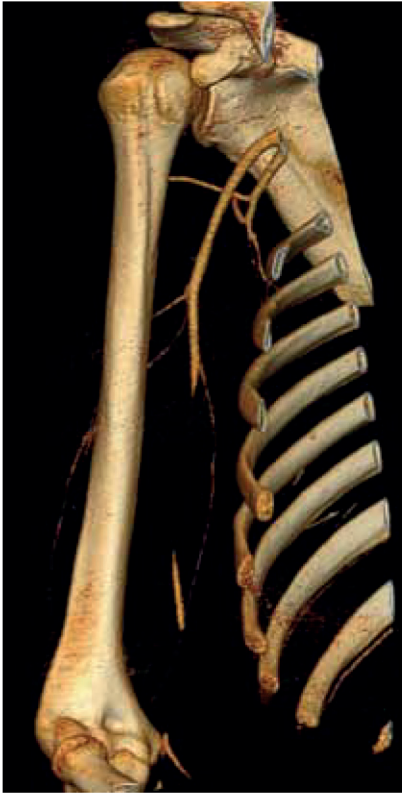
<b>Site of injury</b>	<b>Treatment</b>
<b>During emergency exploration</b>	
<i>Brachial artery</i>	Venous interposition graft with fasciotomy (5)
	Primary repair (3)
<i>Radial artery</i>	Primary repair with fasciotomy (3)
	Ligation (2)
	Ligation with fasciotomy
<b>After computed tomography angiography</b>	
<i>Axillary artery</i>	
Occlusion	Primary repair
False aneurysm	Primary repair
<i>Brachial artery</i>	
Occlusion	Venous interposition graft (2)
AV fistula with basilica vein	Venous interposition graft
Active bleeding	Primary repair (2)
False aneurysm	Primary repair
False aneurysm	Conservative
<i>Posterior circumflex humeral artery</i>	
Active bleeding	Conservative
<i>Ulnar artery</i>	
False aneurysm	Conservative

Values in parentheses are number of patients, if more than one.

## DISCUSSION

In the Netherlands, as in the rest of West Europe, the incidence of penetrating injury is rather low. In Dutch trauma centers, there is definitely much less experience with the management of PUEET than, for example, in the United States or South Africa. Due to this low incidence, it is not possible for a trauma surgeon to gain experience with the management and treatment of this kind of trauma. Protocol management of PUEET is lacking, causing obscurity, disagreement in diagnostic and treatment options, and an insufficient or incomplete management of this trauma patient. The lack of protocol assessment of patients suffering PUEET increases the risk of mistakes and hampers good outcome. In trauma centers that do treat a high number of patients with penetrating trauma, SNOM is becoming more and more accepted (6,8). SNOM is based on clinical examination and additional investigations. Together, they have shown to be a reliable indicator of clinically significant injury, with a sensitivity of 99% and a negative predictive value of 99% in patients with PUEET (5,13). The present study was done in a high-volume, tertiary referral trauma center for penetrating injuries, which manages about 800 patients with penetrating extremity injury each year. The management protocol for assessing and treating patients with PUEET is based essentially on hemodynamic status, together with a thorough physical examination. Initial management of GSW and SW is similar, except that X-ray to rule out a fracture of the upper extremity is standard care in GSW patients. Adjuvant CTA is only indicated based on hard and subtle signs of vascular injury found during clinical assessment in hemodynamically stable patients. At present, in most trauma centers, CTA has replaced angiography as the preferred diagnostic tool in assessment of vascular injuries. An advantage of using angiography, however, is the possibility of interventional procedures, if indicated, during the same session. Nevertheless, for diagnostic evaluation of PUEET, CTA has several advantages over conventional angiography (14,15). It is relatively fast, minimally invasive, has fewer potential complications, and is available in most trauma centers in western countries. Moreover, no support of additional physician staff is required, unlike with conventional angiography, and structures other than vascular structures can be visualized on





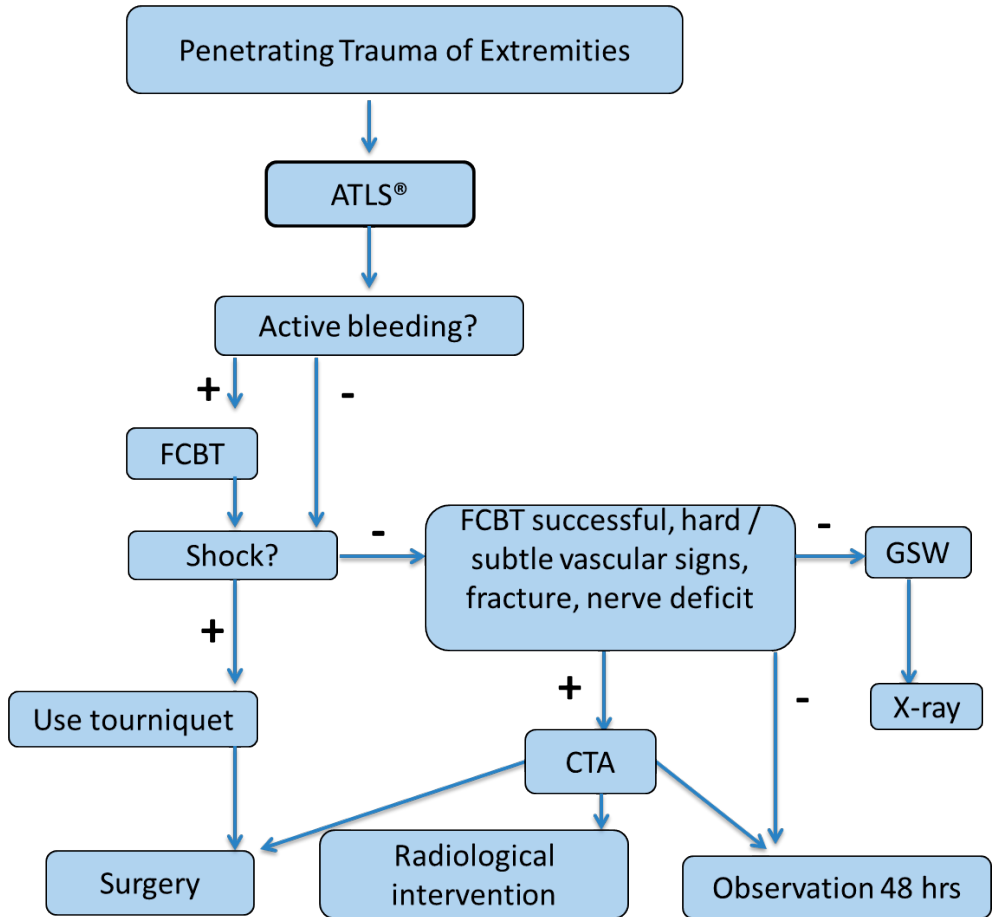
**Figure 1:** Computed tomography angiography of a patient without peripheral pulses on physical examination, showing an occlusion of the brachial artery, which was subsequently surgically reconstructed with venous interposition grafting.

CTA (Figure 1). Most important, it is a reliable and accurate investigation with a sensitivity and specificity of over 90% and 100%, respectively, a positive predictive value of almost 100%, and a negative predictive value of 98% (16,17). Therefore, CTA is more and more becoming the diagnostic tool of choice during the initial evaluation of stable patients with vascular injury and thus very useful in patients with PUET. In this study, the SNOM protocol for penetrating extremity injury was correctly executed with good persistence. Violation of the hospital protocol was noted in a total of 10 patients. Two patients with no signs of vascular injury underwent CTA. As neither showed vascular lesions, they were successfully treated conservatively. On the other hand, eight patients with hematoma accompanied by nerve injury underwent immediate surgical exploration. As they were hemodynamically stable, they should have undergone protocol CTA. Two of those patients showed no vascular injury during exploration, and surgery could have been withheld if CTA had

been performed. The use of FCBT has been shown to be beneficial in penetrating injury of the neck and extremities (12, 18). This procedure allows for rapid hemorrhage control and stabilization of patients, giving the opportunity to visualize any vascular injury on CTA. Especially venous injuries are compliant to FCBT, and in those patients, FCBT is often the definitive treatment.[12] If hemostasis cannot be achieved by FCBT, emergency exploration is indicated. Alternatively, temporary hemorrhage control can be achieved by using a tourniquet or hemostatic dressings before surgery or FCBT. After FCBT, diagnostic CTA should be performed; CTA is useless with a tourniquet in place. In this study, FCBT was used in three patients, of whom one failed, and the patient subsequently underwent emergent exploration with brachial artery repair. Vascular observational management after PUET was applied in 85% of patients without or after CTA assessment. During the follow-up, none of the patients who was conservatively treated and observed presented with a missed vascular injury. This indicates that initial conservative management (or SNOM) of patients with PUET is feasible and safe. The total surgical treatment rate was 26% (24 vascular injuries, 10 fractures, 8 exclusive nerve injuries), indicating that PUET should be considered a serious injury that requires intensive and thorough assessment of the arm.[19] The prevalence of vascular injury after PUET that requires intervention is 15%. Frequently, PUET is associated with penetrating injuries (this study, in 38% of cases) that possibly need to be managed first or that distract the physician's attention away from the injuries of the upper extremity. Eventually missed or even delayed assessment of PUET may significantly impair patient outcome. This is best prevented by protocol-driven management strategies. In penetrating trauma, the different protocols could be combined.

In summary, clinical examination has a high negative predictive value for the absence of any injury, and can therefore dictate CTA to prove or exclude clinically significant vascular injuries in PUET. The low failure rate in this study further validates the SNOM protocol for initial management of PUET. Following the results of this study, we present a simple and practical algorithm for the initial management of PUET in western countries (Figure 2). Vascular assessment after GSW should not be different from that of SW,

although one must realize that the severity of injury usually is more extensive due to high energy, and an X-ray is performed to exclude a fracture.



**Figure 2:** Algorithm for initial management of patients with penetrating trauma of extremities

ATLS® = Advanced Trauma Life Support; CTA = Computed tomography angiography, FCBT = Foley Catheter Balloon Tamponade, GSW = Gun Shot Wound, CTA = Computed Tomographic Angiography.

## REFERENCES

1. Doody O, Given MF, Lyon SM. Extremities-indications and techniques for treatment of extremity vascular injuries. *Injury* 2008;39:1295-303.
2. Manthey DE, Nicks BA. Penetrating trauma to the extremity. *J Emerg Med* 2008;34:187-93.
3. Zellweger R, Hess F, Nicol A, Omshoro-Jones J, Kahn D, Navsaria P. An analysis of 124 surgically managed brachial artery injuries. *Am J Surg* 2004;188:240-5.
4. Geuder JW, Hobson RW 2nd, Padberg FT Jr, Lynch TG, Lee BC, Jamil Z. The role of contrast arteriography in suspected arterial injuries of the extremities. *Am Surg* 1985;51:89-93.
5. Inaba K, Branco BC, Reddy S, Park JJ, Green D, Plurad D, et al. Prospective evaluation of multidetector computed tomography for extremity vascular trauma. *J Trauma* 2011;70:808-15.
6. Frykberg ER, Dennis JW, Bishop K, Laneve L, Alexander RH. The reliability of physical examination in the evaluation of penetrating extremity trauma for vascular injury: results at one year. *J Trauma* 1991;31:502-11.
7. Keen JD, Dunne PM, Keen RR, Langer BG. Proximity arteriography: cost-effectiveness in asymptomatic penetrating extremity trauma. *J Vasc Interv Radiol* 2001;12:813-21.
8. Dennis JW, Frykberg ER, Veldenz HC, Huffman S, Menawat SS. Validation of nonoperative management of occult vascular injuries and accuracy of physical examination alone in penetrating extremity trauma: 5- to 10-year follow-up. *J Trauma* 1998;44:243-52.
9. Van Waes OJ, Cheriex KC, Navsaria PH, van Riet PA, Nicol AJ, Vermeulen J. Management of penetrating neck injuries. *Br J Surg* 2012;99:14954.
10. Dragas M, Davidovic L, Kostic D, Markovic M, Pejkić S, Ille T, et al. Upper extremity arterial injuries: factors influencing treatment outcome. *Injury* 2009;40:815-9.
11. Stone WM, Fowl RJ, Money SR. Upper extremity trauma: current trends in management. *J Cardiovasc Surg (Torino)* 2007;48:551-5.
12. Navsaria P, Thoma M, Nicol A. Foley catheter balloon tamponade for life-threatening hemorrhage in penetrating neck trauma. *World J Surg* 2006;30:1265-8.
13. Peng PD, Spain DA, Tataria M, Hellinger JC, Rubin GD, Brundage SI. CT angiography effectively evaluates extremity vascular trauma. *Am Surg* 2008;74:103-7.

14. Wallin D, Yaghoubian A, Rosing D, Walot I, Chauvapun J, de Virgilio C. Computed tomographic angiography as the primary diagnostic modality in penetrating lower extremity vascular injuries: a level I trauma experience. *Ann Vasc Surg* 2011;25:620-3.
15. Patterson BO, Holt PJ, Cleanthis M, Tai N, Carrell T, Loosemore TM; London Vascular Injuries Working Group. Imaging vascular trauma. *Br J Surg* 2012;99:494-505.
16. Miller-Thomas MM, West OC, Cohen AM. Diagnosing traumatic arterial injury in the extremities with CT angiography: pearls and pitfalls. *Radiographics* 2005;25:133-42.
17. Seamon MJ, Smoger D, Torres DM, Pathak AS, Gaughan JP, Santora TA, et al. A prospective validation of a current practice: the detection of extremity vascular injury with CT angiography. *J Trauma* 2009;67:238-44.
18. Ball CG, Wyrzykowski AD, Nicholas JM, Rozycki GS, Feliciano DV. A decade's experience with balloon catheter tamponade for the emergency control of hemorrhage. *J Trauma* 2011;70:330-3.
19. Brown KR, Jean-Claude J, Seabrook GR, Towne JB, Cambria RA. Determinates of functional disability after complex upper extremity trauma. *Ann Vasc Surg* 2001;15:43-8.
20. Brown KR, Jean-Claude J, Seabrook GR, Towne JB, Cambria RA. Determinates of functional disability after complex upper extremity trauma.
21. Ann Vasc Surg 2001;15:43-8.



# Chapter Ten

---

van Waes OJF, van Lieshout EMM, Hogendoorn W, Halm JA, Vermeulen J. Treatment of penetrating trauma of the extremities: ten years' experience at a Dutch level I trauma center. Scand J Trauma Resusc Emerg Med 2013;14;21:2

## BACKGROUND

Penetrating trauma of the extremities (PTE) is considered a difficult injury to manage because artery and nerve injuries can be serious and may significantly impair outcome of the patient. PTE accounts for about 50% of penetrating trauma. Despite possible (long-term) complications, overall survival is very high (1,2). Nevertheless, the low incidence of this kind of trauma in Western Europe makes it difficult for trauma surgeons to gain experience in its management.

A selective non-operative management (SNOM) has found to be an adequate and safe strategy to assess and treat patients suffering from PTE (3-6). With this SNOM comes a strategy in which diagnostic computed tomography angiography (CTA) screening is not routinely performed, but based on physical examination only. The accuracy of physical examination to detect vascular injury is very high in patients after penetrating trauma (3, 7). Hard signs of a vascular injury (Table 1) mandate emergent surgical exploration, or, if the patient is hemodynamically stable, endovascular treatment could be considered. Diagnostic CTA is indicated in hemodynamically stable patients with clinical signs of vascular injury (Table 1). Without signs of vascular impairment in PTE a conservative observational strategy without CTA is viable (5,6,8). The present study was undertaken to assess SNOM in relation to long-term outcome and complications.

**Table 1: Signs of arterial injury (3)**

---

<b>Hard signs</b>
Active hemorrhage
Absent distal pulses or ischemia
Expanding or pulsatile hematoma
Bruit or thrill

---

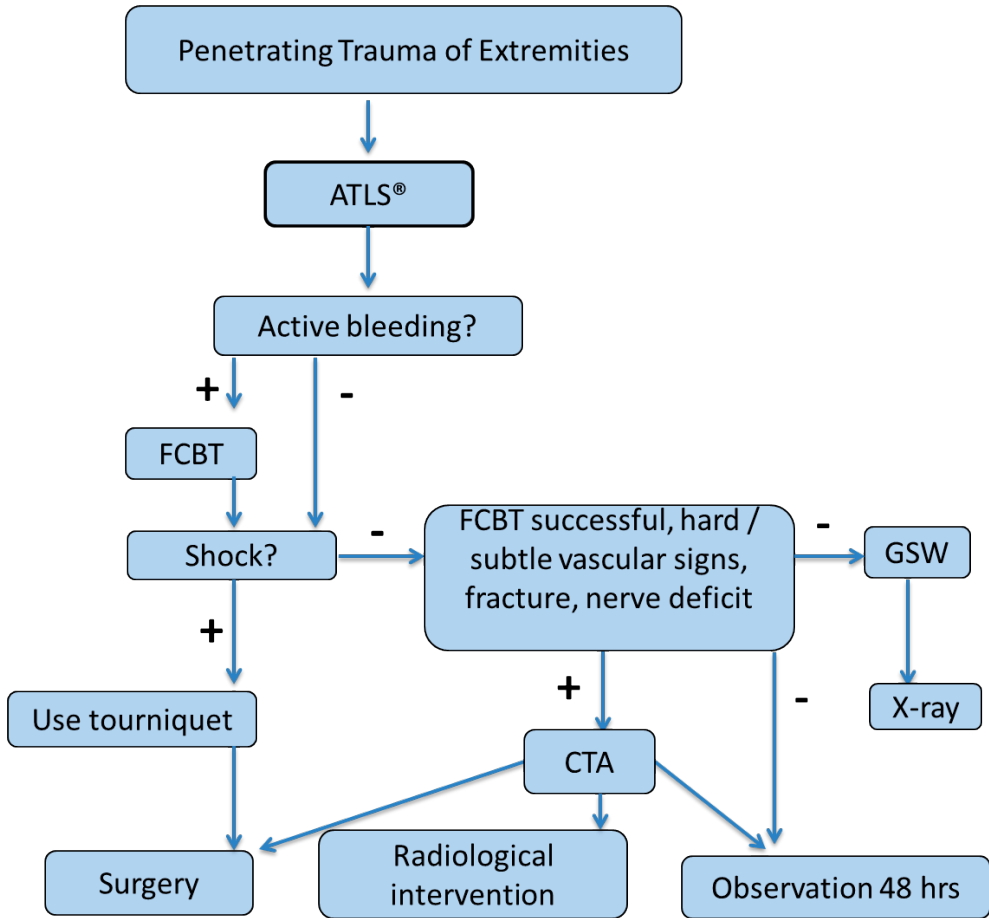
<b>Subtle signs</b>
Subjective reduced or unequal pulses
Large non-pulsatile hematoma
Orthopedic injuries carrying a high index of suspicion of vascular injury
Neural injury
History of large hemorrhage on trauma scene

---



## **Patients and methods**

All patients presented with PTE at a single Dutch level I trauma center from October 2000 to June 2011 were included in this study. Data regarding age, gender, mechanism of injury, type of injury (i.e. vascular, orthopaedic, or nerve), anatomical location and concomitant injuries, clinical manifestations and vital parameters, indications for additional investigations, and treatment strategy of all patients were collected and analyzed in the light of patient's long-term outcome. All patients were initially resuscitated according to the Advanced Trauma Life Support (ATLS®) (8) guidelines and to the discretion of the trauma surgeon in charge. A local protocol was established in order to manage these injuries (Figure 1): Hemodynamically stable patients, and patients who stabilize after immediate simple resuscitation, were first evaluated with a thorough history and physical examination. Additional diagnostic investigations were performed when indicated by the preset protocol based on history and clinical manifestations. A routine X-ray of the injured extremity was made in patients with a gunshot wound (GSW). Indication for CTA was based on the presence of signs and symptoms of vascular injury found by clinical examination. Patients were immediately transferred to the operating room for surgical intervention if additional severe injuries in need of immediate surgical were diagnosed, or no preliminary hemostasis could be achieved in the ER. Hemodynamically stable patients with a negative history and clinical examination suspicious of vascular injury were admitted to the trauma surgical ward for observation. After 24 hours without complications the patient could be discharged home. All patients were instructed for alarm symptoms of vascular injury (loss of "vascular integrity" in the affected limb, e.g. expanding haematoma, loss of pulse, palor and coolness, or loss of sensation and function of the affected limb. Plus general signs of infection (erythema, swollen, warm); if these occurred, they had to return to the hospital immediately.



**Figure 1:** Algorithm for initial management of patients with penetrating trauma of extremities

ATLS® = Advanced Trauma Life Support; CTA = Computed tomography angiography, FCBT = Foley Catheter Balloon Tamponade, GSW = Gun Shot Wound, CTA = Computed Tomographic Angiography.

Hemodynamically unstable patients were immediately transferred to the operating room. In actively bleeding patients hemorrhage control was attempted by using a tourniquet followed by Foley catheter balloon tamponade (FCBT). If hemorrhage control was not established, surgical exploration of the injured extremity had to follow immediately. If hemorrhage was controlled by FCBT, angiography or CTA was indicated after removal of an eventual tourniquet, in order to detect major arterial injury. If

positive, patients should still be transferred to the operating room or treated by endovascular stenting or coiling. Without any arterial injury deemed in need of surgical or radiological interventional (RI) treatment, the patient should be observed for 24-48 hours, after which the Foley catheter was removed in the operating room. In case of re-bleeding, surgical intervention was performed.

## **RESULTS**

A total of 668 patients (88.2% male; 33.8% GSWs) with PTE presented at the Emergency Department during the study period. After initial assessment, 512 patients were discharged home from the Emergency Department as the type and severity of their injury did not necessitate admission for observation or intervention. None of these patients returned to the hospital with late onset complications due to PTE. Analysis of our prospective gathered trauma patient database revealed that a total of 156 patients were admitted after PTE. Stab wounds (SW) were found in 75 patients (10 women) and GSW in the remaining 81 patients (2 women). Characteristics of the patients and type and location of their sustained penetrating injuries are listed in Table 2. Sixteen patients underwent CTA as additional investigation to assess vascular integrity (Table 3). Although CTA should only be performed based on findings at physical examination with suspicion for vascular injury, according to the protocol, in four patients primary CTA was performed without relevant indication and without clinical signs of active bleeding. None of the four CTAs showed vascular injuries. Only one patient was initially treated with FCBT because of active bleeding. Subsequent diagnostic CTA showed minor arterial injury, which could be treated conservatively as no re-bleeding occurred after removal of the Foley catheter.

**Table 2:** Demographics of 156 patients admitted with penetrating extremity injury

Sex ratio (M:F)	144:12
Age, years (median; range)	27 (11-86)
<b>Penetrating extremity injury</b>	
Stab wound (female)	75 (10)
Gunshot wound (female)	81 (2)
<b>Extremity injury</b>	
Vascular	
Emergent exploration	14
Computed tomography angiography	8
Fracture	
X-ray <sup>1</sup>	14 (5)
Neural	
Physical examination <sup>1</sup>	22 (10)
<b>Concomitant penetrating injury<sup>2</sup></b>	
Stab wound	45
Gunshot wound	22
Location	
Head	13
Neck	12
Chest	31
Abdomen	29
Thigh/Pelvis	3

1. Values in parentheses are numbers of surgical intervention because of injury;
2. Patients can have more than one concomitant penetrating injury

**Table 3:** Indications for and results of vascular investigations

Indication for investigation	CTA (n=16)
Absent or diminished pulses	1 (1)
Large hematoma	6 (5)
Foley catheter balloon catheter	1 (1)
Bruit	1 (1)
Proximity to major vessels	3 (0)
Not specified	4 (0)

Values in parentheses are numbers of additional investigations with positive findings on CTA, e.g. extravasation, stop, fistula

CTA = Computed tomography angiography

Twenty patients underwent emergency surgery because of ongoing bleeding or hemodynamic instability, not improving during initial resuscitation or because of extremity ischemia or specific findings at CTA. Another 20 patients underwent surgery for reasons mentioned in Table 4. Overall, 22 (14%) patients that were admitted underwent exploration of the extremity for vascular injury. In 12 of these patients reconstruction of

vascular injury with use of a venous graft was performed, instead of primary repair or suture ligation. No patients were treated primarily by radiological intervention. Six patients underwent surgery to repair traumatic fractures and another nine patients underwent surgery because of nerve injury. In one patient the plastic surgeon joined the trauma surgeon during fracture care surgery to repair neural injury (Table 4). Primary fasciotomy was performed in four patients: one underwent fasciotomy to treat an acute compartment syndrome, the others underwent pre-emptive fasciotomy after vascular reconstructive surgery (n=2) and one nerve injury repair. Fractures of the extremities after penetrating injury were almost exclusively found after GSW (n=13). One metacarpal fracture was found in a patient with SW.

**Table 4:** Indications for surgical intervention

<b>Indication for emergency exploration</b>	<b>20</b>
Active hemorrhage or shock	9
Absent pulses	5
Vascular injury found at CTA	6
<b>Indication for early surgery</b>	<b>20</b>
Vascular injury found at CTA	2
Fracture	5
Neural injury	9 <sup>1</sup>
Wound management	2
Removal of bullet	1
Fasciotomy of the lower leg	1

1. One patient who underwent exploration because of nerve injury also was operated on to repair a metacarpal fracture.

CTA = Computed tomography angiography

In 134 patients conservative observational strategy for vascular symptoms could be initialized after PTE. This equals 86% of admitted patients and 97% of all patients presented at the Emergency Department after PTE. After conservative observation, two (1.5%, or 0.3%, respectively) of these patients subsequently needed an intervention to treat (late onset) vascular complications (Table 5). In one patient emergent repair of the deep femoral artery was complicated by the formation of an arterio-venous fistula discovered after clinical observation and additional CTA, which was treated by endovascular coiling. The other patient returned with a false aneurysm of the popliteal artery several months

later, which was missed at CTA during first admission. This patient was successfully operated on by the vascular surgeon.

**Table 5:** (Long-term) complications that were initially missed or had severe consequences

<b>Initial treatment</b>	<b>Complication</b>	<b>Consequence/result</b>
<b>Stab wound</b>		
<i>Exploration</i>	-Brain-injury due to exsanguination (n=2)	Death
	-Femoral nerve injury	Weakness leg
	-Arterio-venous fistula after femoral a. repair	Coiling
<i>Conservative</i>	-Brachial plexus lesion	Limp/ weakness arm
	-Median nerve lesion	Ape hand deformity
	-Ulnar nerve injury (n=2)	Paraesthesiae and weakness
<b>Gunshot wound</b>		
<i>Exploration</i>	-Leg length difference after femur fracture	Surgical correction
	-Sciatic nerve injury after femoral a. repair	Leg pain and foot weakness
	-Hip joint disarticulation after femoral a. injury and femur fracture	Wheelchair bound
	-Peroneal nerve injury after compartment syndrome after popliteal a. repair (n=2)	Foot drop
<i>Conservative</i>	-False aneurysm popliteal a.	Surgical repair
	-Erysipelas foot due to bullet	Surgical exploration
	-Ulnar nerve injury	Claw hand

Two patients (both SW) died of diffuse axonal injury and post anoxic encephalopathy after exsanguination due to penetrating chest and extremity injury. Besides, the complications mentioned above, long-term extremity related complications were loss of function or other deformity (n=9) including two patients with peroneal nerve injury caused by delayed compartment syndrome treatment, late onset infection and severe wound healing problems resulting in hip exarticulation (n=1; combined injury of femoral artery and proximal femur).

## DISCUSSION

In the Netherlands, as in the rest of Western Europe, the incidence of penetrating injury is rather low. Due to the low incidence it is not possible for a trauma surgeon to get extensive experience with the management and treatment of this kind of trauma, causing obscurity, disagreement in diagnostic and treatment options, and an insufficient or incomplete management of this trauma patient. All together, inexperience in assessment of patients with PTE might increase the risk of mistakes and may hamper outcome. In trauma centers that treat a higher number of patients with penetrating trauma, SNOM is becoming more and more accepted. SNOM is based on clinical examination and additional investigations (on indication). Together they have shown to be a reliable indicator of clinically significant injury, with a sensitivity and specificity of 99% and a negative predictive value of 99% (6,10). The management protocol for assessing and treating patients with PTE is based essentially on hemodynamic status, together with a thorough physical examination. Adjuvant CTA is only indicated based on hard and subtle signs of vascular injury found during clinical assessment in hemodynamically stabilized patients. CTA is a reliable and accurate investigation with a sensitivity and specificity of 95% and 100% respectively, a positive predictive value of 100% and a negative predictive value of 98% (11-13). Therefore CTA is more and more becoming the diagnostic tool of choice during initial evaluation of stable patients with suspected vascular injury, including patients after PTE (13,14). The combination of FCBT and CTA could also diminish the rate of negative explorations and iatrogenic injuries. In one patient an actively bleeding groin was successfully controlled by FCBT. Subsequent CTA revealed no indication for surgical exploration, and after two days the catheter was removed without rebleeding. In the present study the SNOM protocol for penetrating extremity injury was correctly executed with good persistence. Only four out of 124 admitted patients with no signs of vascular injury still underwent CTA. None showed signs of vascular lesions, and all four were successfully treated conservatively. Vascular observational management after PTE was applied in 86% of admitted patients without (n=126) or after CTA (n=8) assessment. During follow up only one (0.7%) of the patients who were conservatively

treated and observed returned with symptoms of a false aneurysm several months later. This indicates that initial conservative management (or SNOM) of patients with PTE is feasible and safe. Although the majority of patients presented at the Emergency Department with supposed PTE are not seriously injured and can be discharged after physical examination and treatment of wounds, up to a quarter of patients should be admitted for observation, additional investigations or surgical treatment. The total surgical treatment rate of the latter group was 24% (22 vascular injuries, five fractures, 10 exclusively neural injuries), indicating that PTE should be considered a serious trauma which requires intensive and thorough assessment of the extremities. PTE is frequently accompanied by other penetrating injuries (in this study in 43% of cases), that possibly needs to be managed first or distracts the physician's attention away from the injuries of the extremities. Eventually missed or even delayed assessment of PTE may significantly impair outcome of the patient [15,16]. In the present study, seven patients (5%) who were treated conservatively showed symptoms of nerve injury that were missed during the initial hospital stay. Although the larger part of nerve injuries cannot be treated, it is important to recognize these injuries at initial assessment, in order to adequately inform patients and provide supportive treatment. These are important factors in the rehabilitation process after penetrating trauma, especially for patients with prolonged or definitive impairment of the extremity [17]. Not only is it important to recognize nerve injury at initial assessment, it is of vital importance to prevent nerve injury in a later stage of treatment. Of all 12 patients that underwent primary vascular repair, only two underwent fasciotomy during the same vascular-reconstructive operation in order to prevent compartment syndrome. In two (20%) patients who had not undergone fasciotomy, compartment syndrome after revascularisation of the leg was diagnosed too late, resulting in persistent peroneal nerve injury. In other words, a patient sustaining PTE should not only be intensively reassessed several times during conservative treatment, but also after surgical treatment, not only for vascular injury, but nerve injury as well. Besides, pre-emptive fasciotomy is advised, in patients sustaining a combination of arterial and venous injury, multiple or complex fractures and



an ischemia time longer than six hours (18,19), as continuous compartment pressure-monitoring is not reliable. Blood flow should be restored as soon as possible by using a shunt. After initial shunting, fractures should be rigidly stabilized using external fixation devices, in order to perform definitive vascular repair with a tension free (venous) interposition graft (20). Since these repairs usually take a fair amount of time, there is a serious threat of compartment syndrome after revascularisation. Therefore, a pre-emptive fasciotomy is highly recommended.

In summary, the low failure rate in this study validates the SNOM protocol for initial management of PTE. Clinical examination of the injured extremity is a reliable diagnostic approach for excluding vascular injury. It is important to assess for possible nerve injuries, both pre- and post operatively, as these injuries are frequently missed and might result in long-term disability.

## REFERENCES

1. Doody O, Given MF, Lyon SM: Extremities-indications and techniques for treatment of extremity vascular injuries. *Injury* 2008, 39:1295-303.
2. Manthey DE, Nicks BA: Penetrating trauma to the extremity. *J Emerg Med* 2008, 34:187-93.
3. Dennis JW, Frykberg ER, Veldenz HC, Huffman S, Menawat SS: Validation of nonoperative management of occult vascular injuries and accuracy of physical examination alone in penetrating extremity trauma: 5- to 10-year follow-up. *J Trauma* 1998, 44:243-52.
4. Dragas M, Davidovic L, Kostic D, Markovic M, Pejckic S, Ille T, Ilic N, Koncar I: Upper extremity arterial injuries: factors influencing treatment outcome. *Injury* 2009, 40:815-9.
5. Stone WM, Fowl RJ, Money SR: Upper extremity trauma: current trends in management. *J Cardiovasc Surg* 2007, 48:551-5.
6. Van Waes OJF, Navsaria PH, Verschuren RCM, Vroon LC, Van Lieshout EMM, Halm JA, Nicol AJ, Vermeulen J: Management of penetrating injuries of the upper extremities. (submitted)
7. Frykberg ER, Dennis JW, Bishop K, Laneve L, Alexander RH. The reliability of physical examination in the evaluation of penetrating extremity trauma for vascular injury: results at one year. *J Trauma* 1991, 31:502-11.
7. Keen JD, Dunne PM, Keen RR, Langer BG: Proximity arteriography: cost effectiveness in asymptomatic penetrating extremity trauma. *J Vasc Interv Radiol* 2001, 12:813-2.
8. Corballis B, Nitowski L: Prim Care. *Advanced trauma life support* 1986, 13:33-44.
9. Peng PD, Spain DA, Tataria M, Hellinger JC, Rubin GD, Brundage SI: CT angiography effectively evaluates extremity vascular trauma. *Am Surg* 2008, 74:103-7.
10. Wallin D, Yaghoubian A, Rosing D, Walot I, Chauvapun J, de Virgilio C: Computed tomographic angiography as the primary diagnostic modality in penetrating lower extremity vascular injuries: a level I trauma experience. *Ann Vasc Surg* 2011, 25:620-3.
11. Soto JA, Múnera F, Cardoso N, Guarín O, Medina S: Diagnostic performance of helical CT angiography in trauma to large arteries of the extremities. *J Comput Assist Tomogr* 1999, 23:188-96.
12. Seamon MJ, Smoger D, Torres DM, Pathak AS, Gaughan JP, Santora TA, Cohen G, Goldberg AJ: A prospective validation of a current practice: the detection of extremity vascular injury with CT angiography. *J Trauma* 2009, 67:238-43.

13. Halvorson JJ, Anz A, Langfitt M, Deonanan JK, Scott A, Teasdall RD, Carroll EA: Vascular injury associated with extremity trauma: initial diagnosis and management. *J Am Acad Orthop Surg* 2011, 19:495-504.
14. Hafez HM, Woolgar J, Robbs JV: Lower extremity arterial injury: results of 550 cases and review of risk factors associated with limb loss. *J Vasc Surg* 2001, 33:1212-9.
15. Richardson JD, Vitale GC, Flint LM Jr: Penetrating arterial trauma. Analysis of missed vascular injuries. *Arch Surg* 1987, 122:678-83.
16. Jaquet JB, Kalmijn S, Kuypers PD, Hofman A, Passchier J, Hovius SE: Early psychological stress after forearm nerve injuries: a predictor for long-term functional outcome and return to productivity. *Ann Plast Surg* 2002, 49:82-90.
17. Farber A, Tan TW, Hamburg NM, Kalish JA, Joglar F, Onigman T, Rybin D, Doros G, Eberhardt RT: Early fasciotomy in patients with extremity vascular injury is associated with decreased risk of adverse limb outcomes: A review of the National Trauma Data Bank. *Injury* 2011, 28. Epub ahead of print.
18. Zaraca F, Ponzoni A, Stringari C, Ebner JA, Giovannetti R, Ebner H: Lower extremity traumatic vascular injury at a level II trauma center: an analysis of limb loss risk factors and outcomes. *Minerva Chir* 2011, 66:397-407.
19. Desai P, Audige L, Suk M: Combined orthopedic and vascular lower extremity injuries: sequence of care and outcomes. *Am J Orthop (Belle Mead NJ)* 2012, 41:182-6.
20. Gifford SM, Eliason JL, Clouse WD, Spencer JR, Burkhardt GE, Propper BW, Dixon PS, Zarzabal LA, Gelfond JA, Rasmussen TE: Early versus delayed restoration of flow with temporary vascular shunt reduces circulating markers of injury in a porcine model. *J Trauma* 2009, 67:259-65.



# PART THREE

---

*Penetrating prose*

“What we do in life echoes in  
eternity”

*Maximus Decimus Meridius*



# Chapter Eleven

---

Afghan "Wild Life".

translated to English from:

van Waes OJF, Morak MJM.

Afghaans "Wild Life". Ned Tijdsch Heelk 2011;20(5):191-2

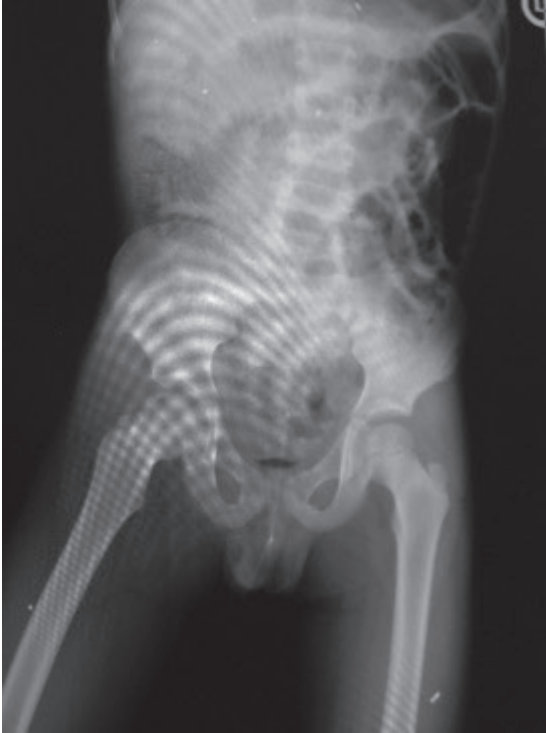## INTRODUCTION

Ascariasis in childhood in developing countries is a common problem. Ascariasis resulting in a post-operative ileus is less known. This case describes a obstructive and paralytic ileus, and its treatment for a pediatric Afghan war victim.

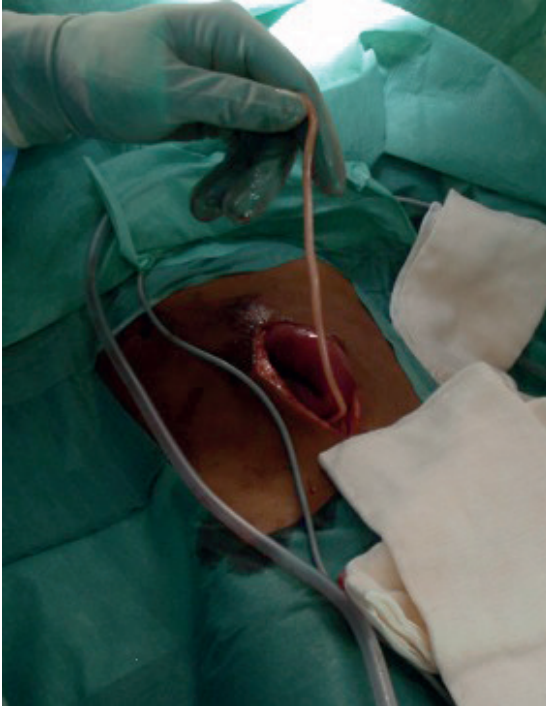### Case description

A six-year-old boy was presented during triage of a "Mass Call" (several victims delivered at the same time) at the emergency department of the Role-2 Uruzgan Medical Center at Camp Holland in Tarin Kowt, Afghanistan. The patient was part of a group of eight people, two young women and six children ranging in age from two years to twenty years old. All were victims of a grenade attack on their quala (fenced Afghan farm). The patient's airway was free, and had normal vesicular respiratory sounds. There was a tachycardia of 132 beats per minute, with a slight hypotension of 100/72 mmHg. The patient scored a maximum Glasgow Coma Score of 15 and suffered multiple penetrating injuries across the entire abdomen, flank and legs (see Figure 1). Abdominal tenderness and guarding were observed during examination, and it was decided to perform an explorative laparotomy. After opening the peritoneum and introducing a hand into the abdomen, to eviscerate the intestine, the operator felt a moderately thrashing worm like structure. When removing this corpus alienum, it was an ascaris lumbricoides of about 25 cm in length (see Figure 2). Upon further inspection of the abdomen, several small bowel lacerations were observed, which were primarily closed or resected with primary "side to side" anastome. In addition to a penetrating injury of the corpus of the stomach (see Figure 3), which was also closed primarily, a second roundworm was removed from the upper left quadrant in the abdomen. Post-operatively, the patient was treated with Mebendazol 3 times daily 2 tablets of 100 milligram for two days, to eradicate the still present ascaris. After this the patient developed a mechanical ileus based on an intra-luminal ball of dead roundworms (Figure 4). This bolus was successfully mobilized with the help of 3 tablets Erythromicin 50 mg. However, the patient developed a recurrent ileus that was treated conservatively for 48 hours. With an increasingly thicker and more painful abdomen, with an increasing CRP to 200

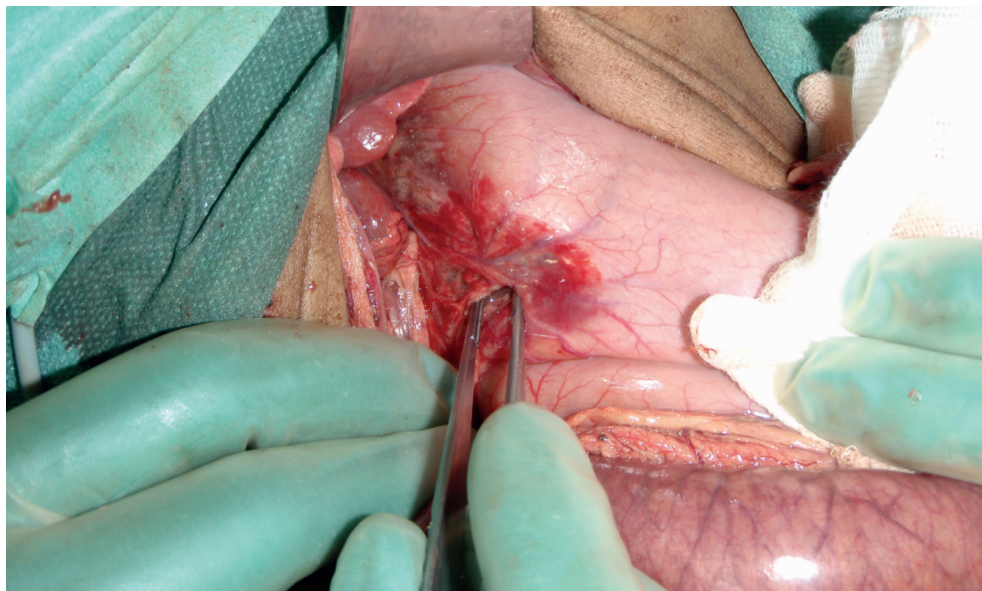




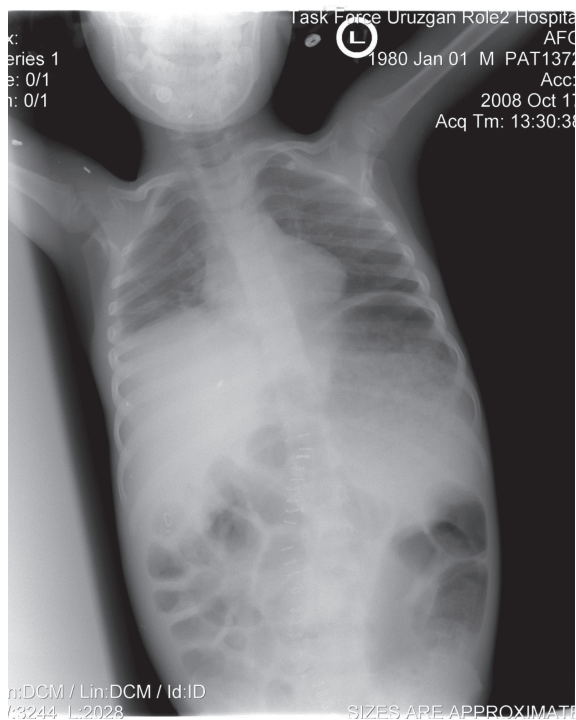
**Figure 1:** Penetrating "Shrapnell" injuries of abdomen, pelvis and thighs.



**Figure 2:** An ascaris lumbricoides of about 25 cm in length.



**Figure 3:** Penetrating injury to the corpus of the stomach.



**Figure 4:** Ileus due to a conglomerate of ascaris. With radiological aspect of a "whirlpool, or beehive".

mg / L, hyponatremy of 125 mmol / L and a leucocyte count of 20 10<sup>9</sup> / L, it was decided to perform a relaparotomy. An intact anastomosis, which could pass stool, was observed per-operative. Except for a partially erythematous small bowel, no further abnormalities were found. Post-operatively, the recovery went well and the patient passed stool after 48 hours.

## **DISCUSSION**

Ascariasis, which presents itself especially during childhood, is a frequently occurring condition in developing countries due to limited hygiene. The course of a massive infestation with these helminths can be complicated, with ileus, but also gastrointestinal bleeding (1,2). In a patient suspected of ascariasis, signs of a obstructive ileus with bolus of worms can be observed on a conventional abdominal X-ray image. The conglomerate of ascaris is described as a "whirlpool, beehive or bread crumbs" (3) (see Figure 4). As a possible explanation for the ileus that developed in the patient after the worm bolus was mobilized, an adrenal insufficiency was initially considered given the hyponatremie of 125 mmol / L. For this, the patient was treated postoperatively with 18 mg prednisolone once daily for two days without success. A more plausible explanation for the paralytic Ileus in combination with hyponatremia in patients with ascariasis is described by Steinberg et al. (4). This article describes two cases of ascariasis complicated by post-operative ileus and peritonitis based on a necrotizing inflammatory response of the small intestine. A toxic excretion of the destroyed worms as a possible cause of the inflammatory response is postulated. This description is more plausible with the per-operative findings during relaparotomy of our patient.

## **CONCLUSION**

In conclusion, the authors believe that in treating children in developing countries with ileus complaints, one should be vigilant for ascariasis and the associated complications.

## REFERENCES

1. Crane PS, Pak YH, Lee HK. Surgical complications of massive infestations with ascaris lumbricoides. *Ann Surg* 1965;162:34-36
2. Sangkhathat S, Patrapinyokul S et al. Massive gastrointestinal bleeding in infants with ascariasis. *J Pediatr Surg* 2003;38:1696-1698
3. Ellman BA, Wynne JM, Freeman A. Intestinal ascariasis: new plain film features. *AJR* 1980;135:37-42
4. Steinberg R, Davies J, Millar AJW, Brown RA, Rode H. Unusual intestinal sequelae after operations for ascaris lumbricoides infestation. *Pediatr surg Int* 2003;19:85-87





# Chapter Twelve

---

Late onset pericardial tamponade after penetrating thoracic injury. 'Shaved and saved by the cold blue steel'

translated to English from:

Huis in't Veld MA, Halm JA, van Waes OJF. Een late pericardiale tamponnade na penetrerend thoraxletsel. tijd. Traumatologie (2012) 20: 149.

## INTRODUCTION

Penetrating injury of the heart results in 80-90% of the cases in a pericardial tamponade (1,2). In most cases the tamponade is formed by injury of the myocardium with bleeding in the pericardial cavity (1). Late onset pericardial tamponade is rare and can occur after both blunt and penetrating chest injuries (3,4). We present a case of delayed pericardial tamponade a week after a self-inflicted stab wound in the left thorax half.

## CASE DESCRIPTION

A 23-year-old man with no medical history was brought in by the emergency medical services to the emergency department. In an attempted suicide he had stabbed himself in the left chest and the left upper leg with a samurai sword.

Patient was not short of breath but was tachycardic with normal blood pressure (120 / min, RR 120/70 mmHg). Physical examination further revealed, a stab wound of 2 centimeters above the left nipple with subcutaneous emphysema, and additional stab wound in the left upper leg. On auscultation of the thorax, normal vesicular breathing sounds was heard. An x-ray of the thorax displayed a pneumothorax on the left and an air configuration contouring the left heart border, suggestive of a pneumomediastinum. No pericardial effusion was noted during ultrasound of the heart.

A chest drain was inserted with initial output 20 ml of blood. Additional Computed Tomography scan (CT) of the chest showed no air in the mediastinum or pericardial effusion. The hemoglobin content was 6.7 mmol / l. Patient was admitted to the trauma surgical ward for observation. After three days the pneumothorax was no longer visible on the manufactured chest X-ray and the drain was removed. Shortly thereafter, the patient left hospital against medical advice.

A week after the initial presentation, the patient returned to the emergency department with complaints of thoracic pain. He displayed no shortness of breath and had a normal pulse and

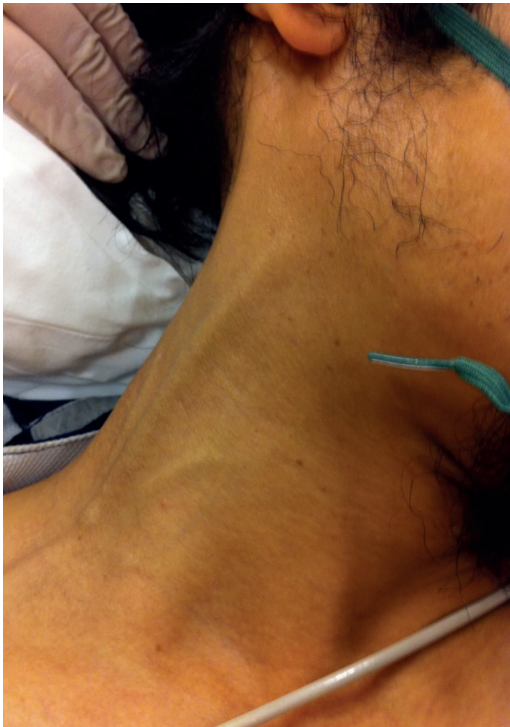

blood pressure (80 / min, RR 129/79 mmHg). On the x-ray of the chest, a minor pneumothorax was seen on the left side, with no indication of other abnormalities. An expectant treatment was pursued with regard to this residual pneumothorax. No ultrasound of the heart was made and the patient was discharged with pain medication.

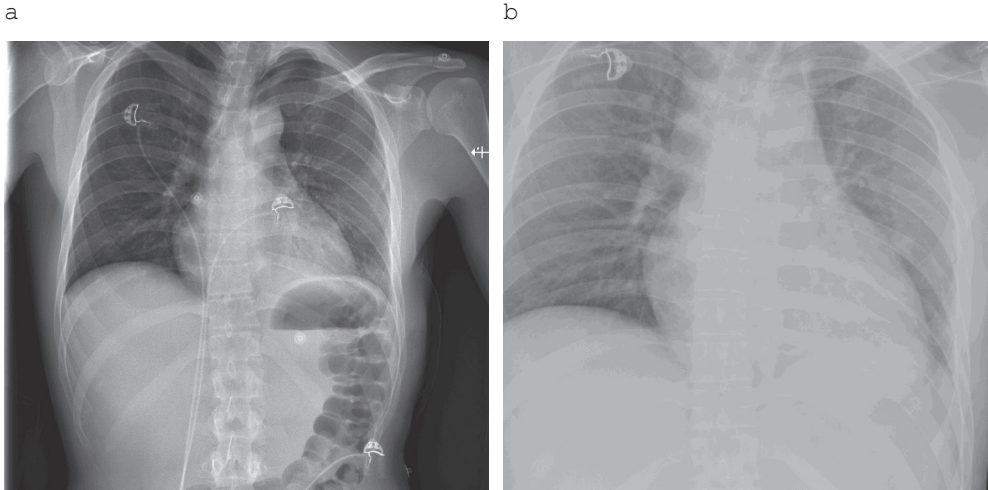
The next day patient again presented to the emergency department after he had been found unconscious in the street, after bystanders had alerted the ambulance services.

Physical examination revealed a dyspnoeic patient with a blood pressure of 92/63 mmHg and a pulse of 188 beats per minute. Vesicular breathing sounds noted, but heart sounds were subdued.

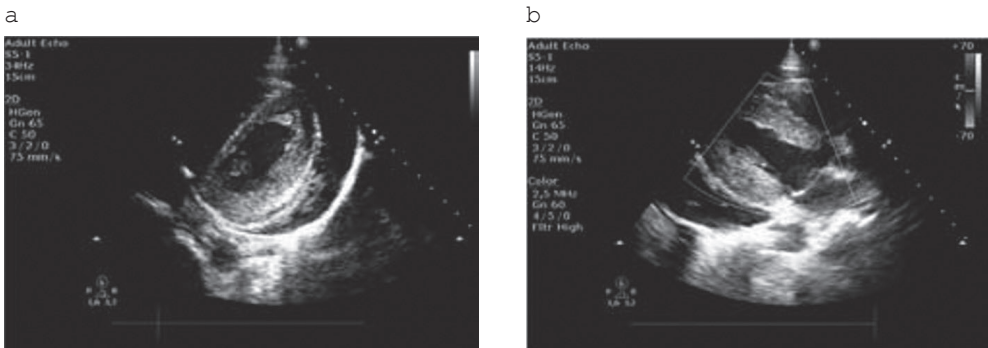
In addition, Jugular venous distention was seen to complete Beck's triad (Figure 1). The X-ray of the thorax showed an enlarged contour of the heart in comparison with the X-ray of the previous day (Figure 2). Echocardiography, displayed gross pericardial effusion of 20-25 mm (Figure 3).



**Figure 1:** Distended jugular veins as a sign of increased central venous pressure



**Figure 2:** X-ray of the chest with a globular heart contour (a). A day prior to diagnosis of the late onset pericardial tamponade. (b) X-ray when diagnosis of late onset pericardial tamponade was made.



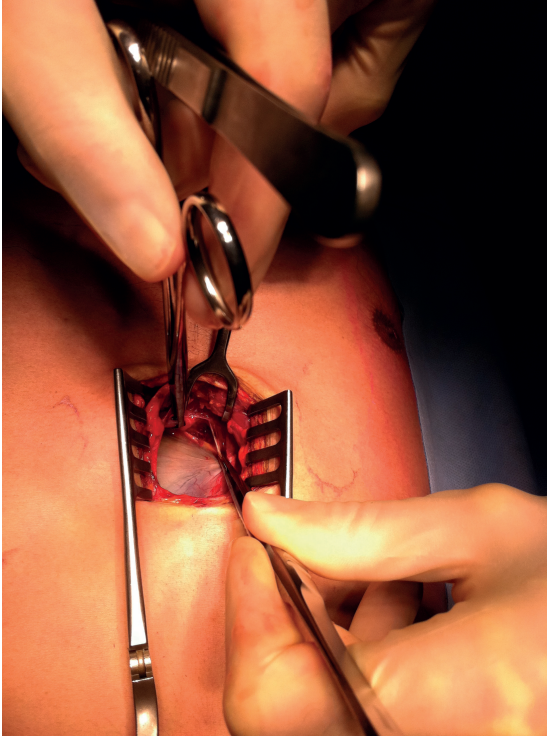
**Figure 3:** Echocardiography with evident pericardial effusion (20-25 mm).

The hemoglobin level was 6.4 mmol / l. The diagnosis pericardial tamponade was made. The patients were operated, using the subxiphoid window (Figure 4). During surgery 900 ml of liquefied hematoma was evacuated and a pericardial drain was placed (Figure 5). An intra-operative transesophageal ultrasound showed normal cardiac contractility after drainage. There were no signs of additional injuries to the heart during inspection. The postoperative course was uncomplicated, the pericardial drain could be removed after two days and the patient was discharged in good clinical condition after four days. The patient has withdrawn from medical check ups.

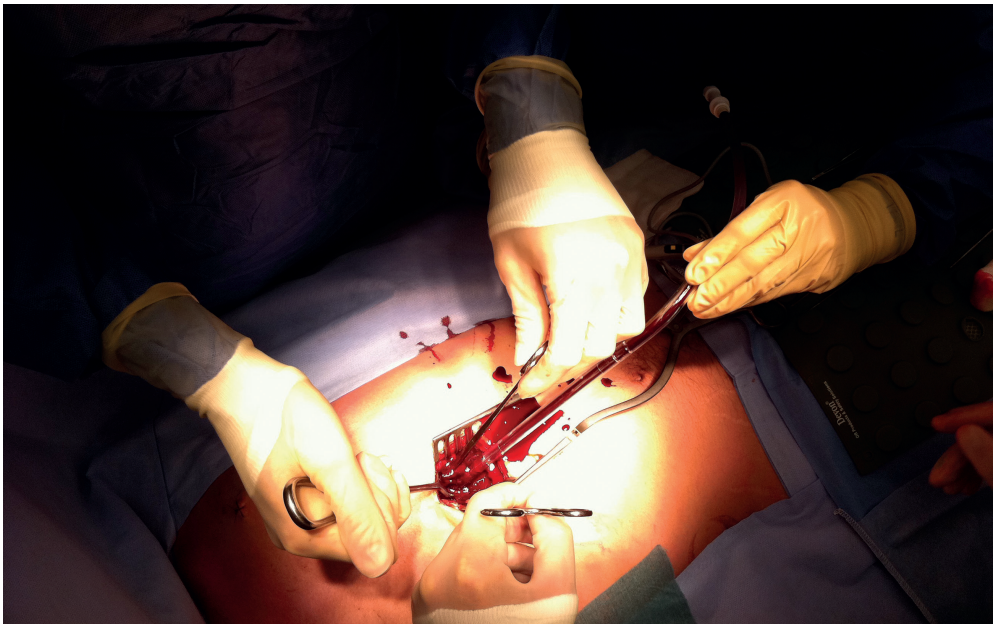
### **Surgical technique of the subxiphoid window**

A six-centimeter vertical incision, on top of (or slightly to the left to) the xiphoid process is made. This is extended to the midline of the abdomen. The linea alba is opened. The retrosternal space is opened by blunt dissection, keeping the peritoneum intact. With a retractor the sternum can be lifted to visualize the diaphragm and the pericardium.

The pericardium can be tented with clamps and opened under direct vision. Suction is used to to evacuate the pericardial effusion. A pericardial drain is inserted via a separate stab incision for postoperative monitoring. If bright red blood is released during pericardiotomy, the procedure is converted to a sternotomy. Serosanguinolent effusion and liquefied hematoma can be treated by drainage en observation. The pericardiotomy is left open, the abdominal incision is closed in layers using a polydioxanone attachment (PDS II, Ethicon) for the linea alba (5-7).



**Figure 4:** Subxiphoid window



**Figure 5:** Per-operative drainage of 900 ml of liquefied hematoma.

## DISCUSSION

Although exact data are lacking, late onset pericardial tamponade is considered a rarity (8). Exudative non-haemorrhagic pericardial effusion (PE) leading to cardiac tamponade has been described in the literature. In general, the effect of PE was only rarely clinically relevant (3,9). The first report of delayed pericardial effusion after blunt chest trauma was published by Goodkind et al. In 1960 (10).

The exact mechanism of late onset pericardial effusion or pericardial tamponade is unknown. Dislocation of a previously formed thrombus in the pericardium or the tearing of adhesions have been described (8). The occurrence of an inflammatory or autoimmune reaction against the pericardium or myocardium is also mentioned as a possible cause (8). This reaction produces sterile pericarditis compared as seen in the Dressler syndrome (postmyocardial infarction pericarditis) (11). Due to the development of an effusion in the pericardium, intracardiac pressure rises above intracavity pressure. This creates mechanical pressure on the chambers causing diastolic dysfunction, leading to the observed symptoms of tachycardia, central venous stasis and dyspnoea. Beck's classic triad consists of hypotension, increased jugular venous pressure and absent or muffled heart tones (12).

These symptoms were also present in our patient. This triad is only seen in 10% of the patients with pericardial tamponade. Other signs suggestive of pericardial tamponade are the pulsus paradoxus, electrical alternans (alternation of the QRS complex on the ECG) and persistent tachycardia (8).

Standard X-rays of the chest and echocardiography (> 10 mm pericardial effusion) are, in addition to a high clinical suspicion, the appropriate diagnostic tools for late onset pericardial tamponade (8).

A tent-shaped or globular heart contour can be seen on the standard radiographs. To diagnose a pericardial effusion, ultrasound is a very sensitive means whereby very small volumes of 20 ml can

be detected even by surgeons, with a sensitivity and specificity of 100% and 96.9% respectively (8). Echographically, the diagnosis tamponade is a combination of pericardial effusion and diastolic collapse of the right ventricle. Paradoxical wall movements can also be seen.

In patients who present themselves with penetrating trauma near the heart, it is advisable to perform a second echocardiography before discharge in order to be able to detect late onset pericardial tamponade in a simple and non-invasive manner (8).

In retrospect this should have taken place in our patient, especially when the patient presented himself with complaints of dyspnoea and pain on the chest and an enlarged heart contour. The role of pericardiocentesis in a traumatic pericardial tamponade is limited both as a diagnostic tool or as treatment (1). The effusion is often loculated and there are clots that can not be aspirated. Surgery, in the form of relieving the cardiac tamponade by using a subxiphoid window, is the preferred therapy for late onset pericardial effusions, especially if there are clinical signs of tamponade. If the patient has a systolic blood pressure above 60 mmHg, surgery using the subxiphoid window technique is preferred to thoracotomy (13). When bright red blood is evacuated, the procedure can be converted to a sternotomy. In case of just serous or serosanguinolent fluid, a drain should be left for 24 hours. The number of negative sternotomies can be reduced in using this strategy.

## **CONCLUSION**

In patients with penetrating thoracic injuries, it is important to be aware of the occurrence of late onset pericardial tamponade, even if no signs of pericardial effusion have been initially observed. It is advisable repeat an ultrasound evaluation of the pericardium in patients with penetrating thoracic injury with a normal initial CT, before hospital discharge. Surgical treatment via a subxiphoid window is minimally invasive and is preferable to a sternotomy.

## REFERENCES

1. Karrel R, Shaffer MA, Franaszek JB. Emergency diagnosis, resuscitation, and treatment of acute penetrating cardiac trauma. *Ann Emerg Med.* 1982;11:504-17.
2. Mechem CC, Alam GA. Delayed cardiac tamponade in a patient with penetrating chest trauma. *J Emerg Med.* 1997;15:31-3.
3. Solomon D. Delayed cardiac tamponade after blunt chest trauma: case report. *J Trauma.* 1991;31:1322-4.
4. Aaland MO, Sherman RT. Delayed pericardial tamponade in penetrating chest trauma: case report. *J Trauma.* 1991;31:1563-5.
5. Rothuizen L, Potgieter D, Nicol A, Vermeulen J. Subxyphoid window in pericardial stabwounds. *Ned Tijdschr Heelkunde.* 2010;19:303-6.
6. Moores DW, Allen KB, Lininger L, et al. Subxyphoid pericardial drainage for pericardial tamponade. *J Thorac Cardiovasc Surg.* 1995;109:546-2.
7. Allen KB, Faber LP, Warren WH, Shaar CJ. Pericardial effusion: subxyphoid pericardiostomy versus percutaneous catheter drainage. *Ann Thorac Surg.* 1999;67:437-40.
8. Simmons JD, Haraway AN, Schmieg RE Jr, et al. Is there a role for secondary thoracic ultrasound in patients with penetrating injuries to the anterior mediastinum? *Am Surg.* 2008;74:11-4.
9. Wiegand L, Zwillich CW. The post-cardiac injury syndrome following blunt chest trauma: case report. *J Trauma.* 1993;34:445-7.
10. Goodkind MJ, Bloomer WE, Goodyer AVN. Recurrent pericardial effusion after nonpenetrating chest trauma. *N Engl J Med.* 1960;263:874-81.
11. Pastor BH, Betts RH. Late symptoms due to traumatic hemopericardium. *N Engl J Med.* 1961;265:1139-43.
12. Shoemaker WC, Carey JS, Yao ST, et al. Hemodynamic alterations in acute cardiac tamponade after penetrating injuries of the heart. *Surgery.* 1970;67:754-64.
13. Navsaria PH, Nicol AJ. Haemopericardium in stable patients after penetrating injury: is subxyphoid pericardial window and drainage enough? A prospective study. *Injury.* 2005;36:745-50.





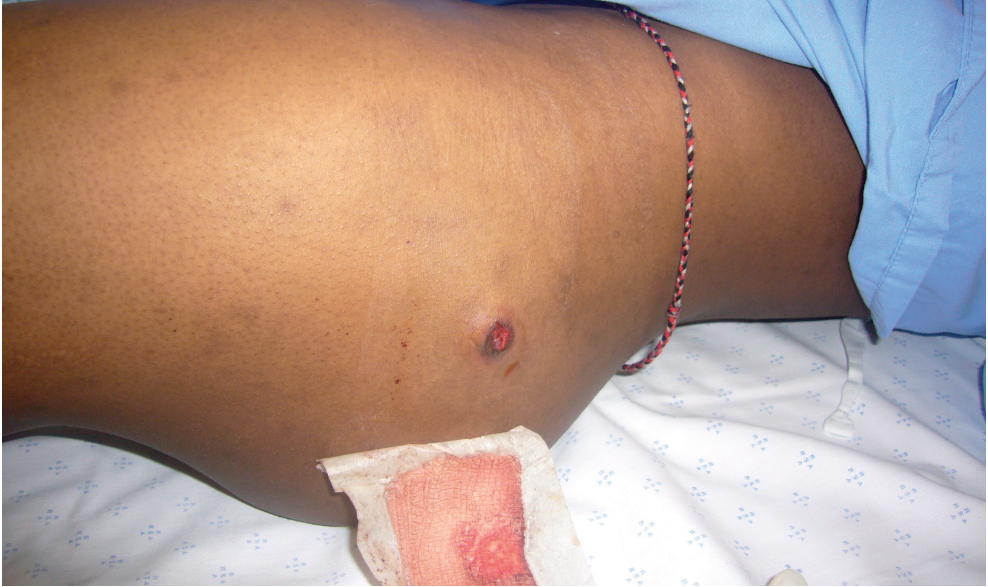# Chapter Thirteen

Dynamic Hip Slug (DHS)?

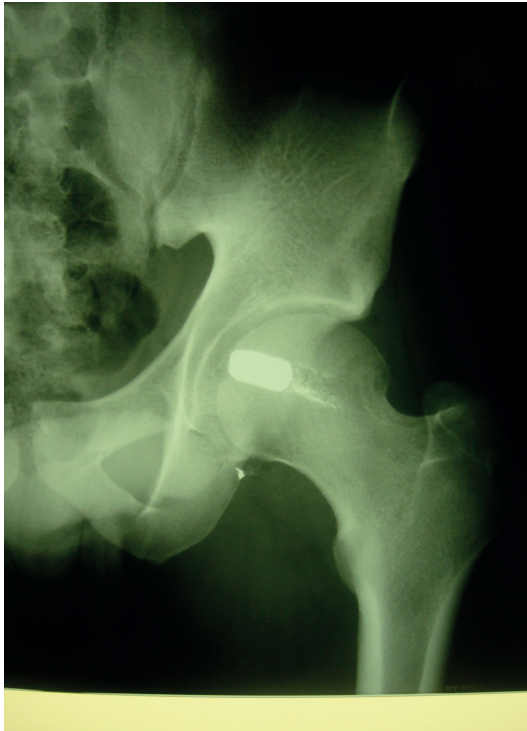translated to English from:

van Waes OJF, van der Elst M. Dynamic Hip Slug (DHS)? Nederlands tijdschrift voor Traumatologie 2008;16:15

A South African in his twenties was presented on the trauma unit of Het Groote Schuur. He mentioned that he was walking in the street and was 'shot down without reason' by some "dudes" he did not know. Physical examination involved an ABC-stable patient (ABC = airway, breathing, circulation) with a maximum EMV score (EMV = eyes, motor reaction, verbal reaction). The only injury was a gunshot wound at the left hip, without neurological or vascular injury (Figure 1). Radiological evaluation showed the bullet track and the position of projectile (Figure 2). Though low velocity gunshot injuries which are not extensively contaminated (e.g. after bowel perforation) can be left in situ (1-3), it was decided to remove the bullet in this case. Considerations that led to this decision were: the subchondral position with a high risk of arthritis symptoms, as well as the risk of lead intoxication (in alkaline synovia dissolves lead) (4-5). The bullet was removed with curved Kischner wires and curettes through the existing bullet trajectory. After extensive lavage, the bone defect was filled up with donor bone. Postoperatively, the patient was treated prophylactically with cefazolin (Kefzol®) for 48 hours, and partial weight-bearing for six weeks.



**Figure 1:** gunshot wound over the greater trochanter



**Figure 2:** bullet track and final position subchondral in femoral head

## REFERENCES

1. Marcus NA, Blair WF, Schuck JM, e.a. Low-velocity gunshot to extremities. *J Trauma* 1980;20:1061-4.
2. Ebbs SR, El-Masry R, Baum. Do all intra-abdominal bullets need to be removed? *Injury* 1990;21:183.
3. Brettler D, Sedlin ED, Mendes DOG. Conservative treatment of low velocity gunshot wounds. *Clin Orthop Relat Res* 1997;140:26-31.
4. Leonard MH. The solution of lead by synovial fluid. *Orthop Relat Res* 1969;44:255-61.
5. Windler EC, Smith RB, Bryan WJ, e.a. Lead intoxication and traumatic arthritis of the hip secondary to retained bullet fragments. *J Bone Joint Surg* 1978;60:254-5





# Chapter

# Fourteen

van Waes OJF, Halm JA, Vermeulen J, Ashford BG. "The Practical Perforator Flap": the sural artery flap for lower extremity soft tissue reconstruction in wounds of war. Eur J Orthop Surg Traumatol 2013;23(Suppl 2):S285-9

## INTRODUCTION

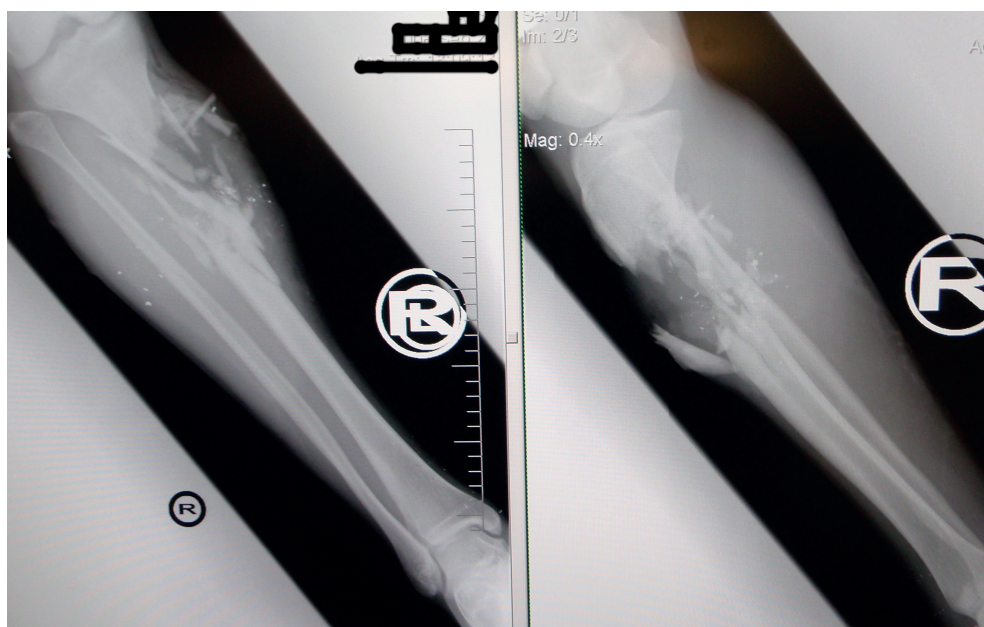When faced with wounds of war or similar devastating trauma mechanism options for replacement of soft tissue and for tissue coverage of exposed bone about the knee are limited. Injuries such as blast and high velocity gunshots translate unpredictable forces and may result in ongoing loss of soft tissue following initial debridement. Soft tissue coverage via vascularized flaps might be necessary for definitive treatment and to achieve both functional results and some degree of cosmesis. In austere conditions a plastic surgeon might not be readily available to provide vascularized flaps for this kind of injuries. A sural artery perforator flap is a straightforward solution to treat a massive tissue defect around the knee. Herein we discuss two cases in which military trauma surgeons with no additional training in plastic surgery used rotational flaps to treat large soft tissue injury. The current case reports and review of literature outlines difficulties faced in an austere setting in managing a blast injury involving the popliteal fossa in a child and the treatment of a high velocity gunshot wound to the proximal tibia in an adult.

### Case 1

A 9 year old Afghani girl sustained a injury to the popliteal fossa due to a blast in which four members of her immediate family perished, The patient was presented after 24 hours of transport to an International Security and Assistance Force (ISAF) Role 2 medical facility in Uruzgan, southern province of Afghanistan. After primary survey, she was resuscitated and given analgesia. The extent of the injury was assessed via the Red Cross Wound Classification (1) as E8X0C1F1V0M2. The initial debridement under general anesthesia included the proximal third of both bodies of gastrocnemius, an avulsed fragment of the medial femoral condyle and the fat of the fossa. A second fragment of the femur, involving the joint could be preserved and fixed in place with two Kirschner wires. The soft tissues were approximated over the knee joint line and a Vacuum Assisted Closure (VAC) device was applied to the wound. Change of dressings was performed two days later. A major part of the joint was exposed with copious egress of synovial fluid. The



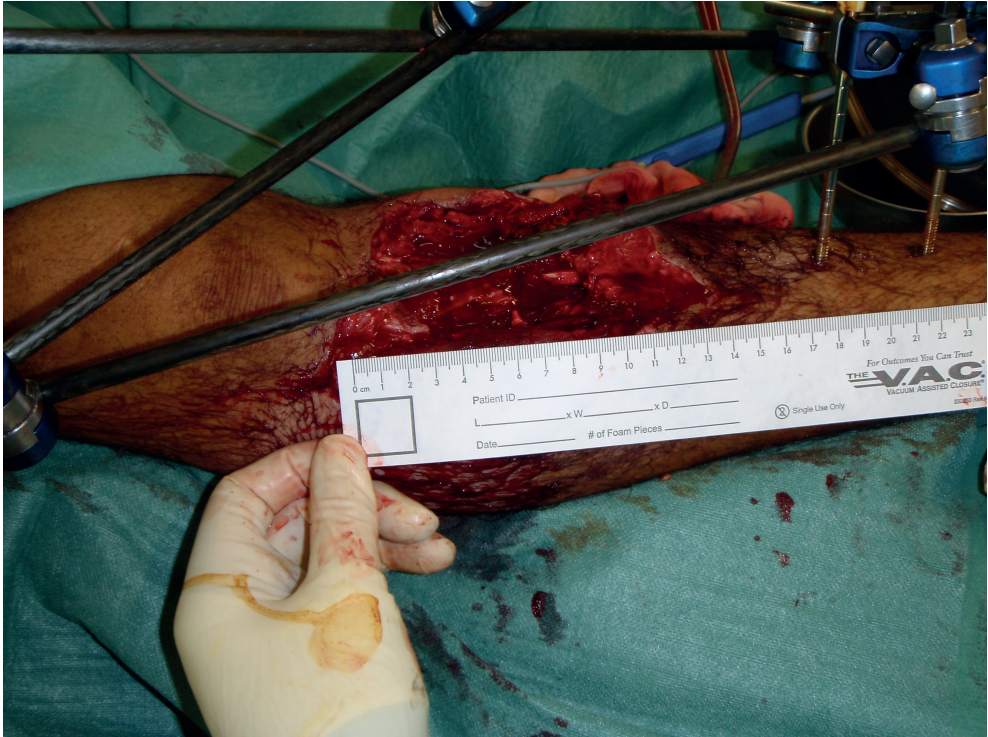
bone fragments and K-wires were removed and subsequently split skin grafts (SSG) were applied to the granulating tissue. Again a VAC was applied and the SSG was inspected after 3 days. The majority of the SSG took, but the problem of synovial fluid discharge persisted. To deal with this problem a more robust coverage of the joint was required. A medial sural perforator fasciocutaneous island flap was performed. Preoperative audible Doppler assessment located 2 usable perforator arteries in the medial calf. The surgery was facilitated by general anesthesia, tourniquet use, and the use of 2.5X surgical loupes with the patient placed in prone position. A flap was designed such that the distal perforator artery was centrally located in the flap. The flap dimensions were chosen to provide sufficient coverage of the joint, but also to make primary closure of the donor site possible. The lateral aspect of the flap was raised first, to allow identification of the perforators. The incision was deepened through skin and subcutaneous tissue down to deep fascia. Incision of the deep fascia allowed the medial body of the gastrocnemius muscle to be found and a sole perforator to be identified. Subfascial dissection was then completed, looking for a second perforating vessel as indicated by Doppler, but this vessel could not be found. The only perforator was released during proximal exploration up to the previously debrided blast wound. There were no superficial veins found in the flap. The flap was applied to cover the defect over the medial aspect of the posterior knee joint, and sutured with absorbable sutures. The limb was immobilized in a slightly flexed position with the aid of a padded plaster of Paris cast. A small amount of distal flap necrosis needed to be removed on the third postoperative day, the remainder of the flap being vital. The synovial fluid discharge from the joint had diminished, and stopped after applying some additional sutures. Simple dressings were then applied to protect the flap and SSG. At one month, the flap was stable and intact. The patient recovered uneventfully.



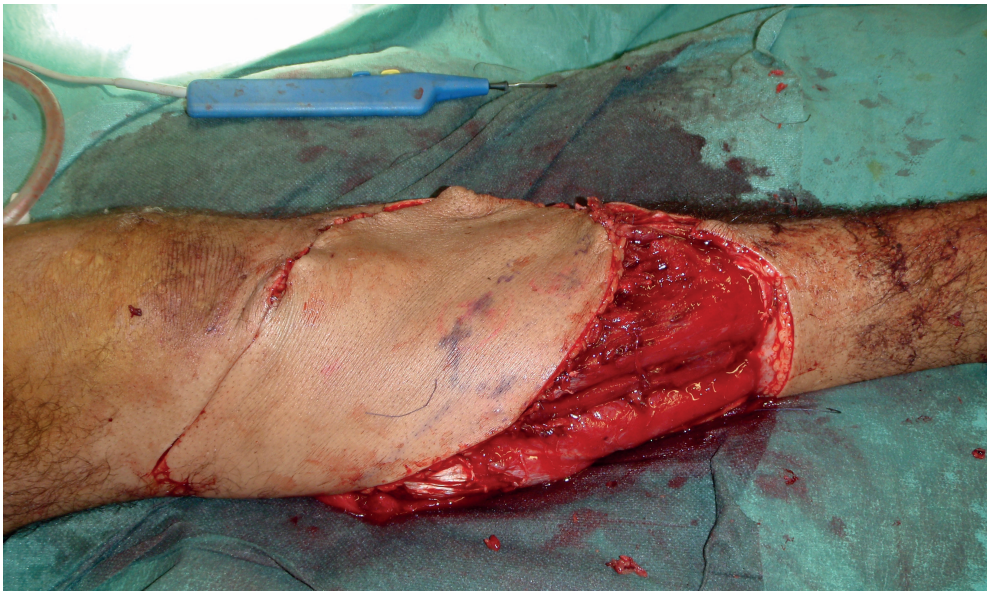**Figure 1:** X-ray of proximal compound tibial fracture

## Case 2

A 25-year-old male was evacuated to the same medical facility as Case 1 after sustaining multiple high velocity gunshot wounds to the right hand, right proximal tibia and left upper leg (Figure 1). After primary assessment and resuscitation, the wound to the tibia was classified by the Red Cross Wound Classification (1) as E5X6C1F2V0M0 grade 3 type VF. The posterior side of right lower leg was intact and no neurovascular injuries were noted. The tibial wound was debrided, and a joint spanning external fixator was applied over the proximal compound fracture of the tibia. A VAC was applied over the 10 by 12 cm tibial wound (Figure 2). After two days a second debridement was performed. At this point, the patient was considered for amputation. Nevertheless, he wished for limb salvage at any costs, since he was the sole provider for his family. A decision was made to attempt limb salvage by means of tissue coverage by use of a local flap. Prior to surgery both medial and lateral sural artery perforators were marked with use of duplex ultrasound. The perforators from the lateral sural artery were found to have a larger diameter compared to the medial perforators (2.3 and 2.2 mm vs 1.5 and 1.7mm), hence



**Figure 2:** Soft-tissue defect of proximal tibia after joint spanning external fixator and debridement.

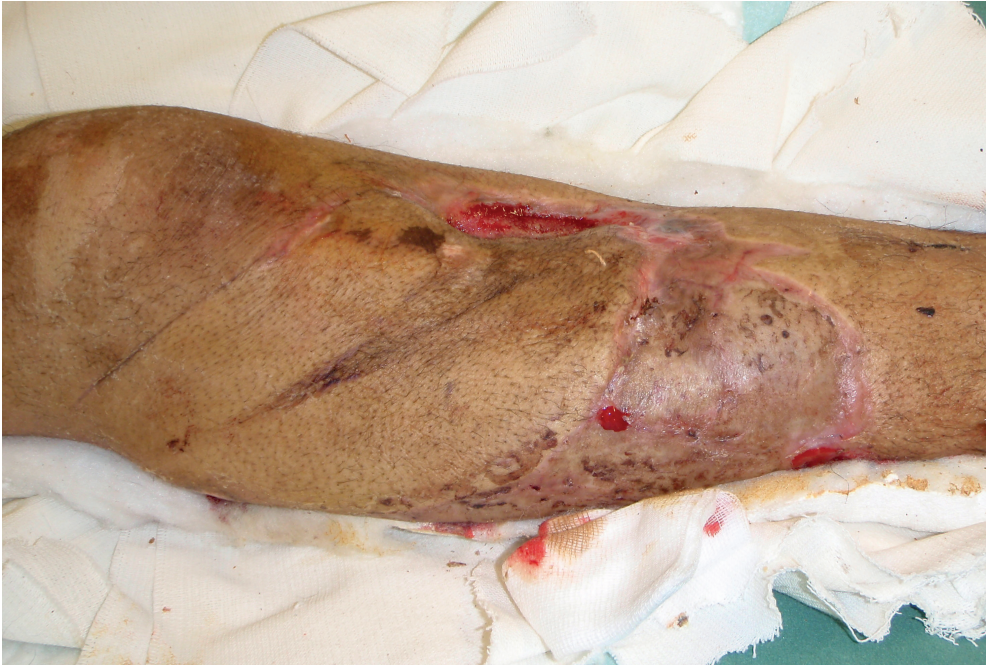

**Figure 3:** Medial sural artery perforator fasciocutaneous island flap in position

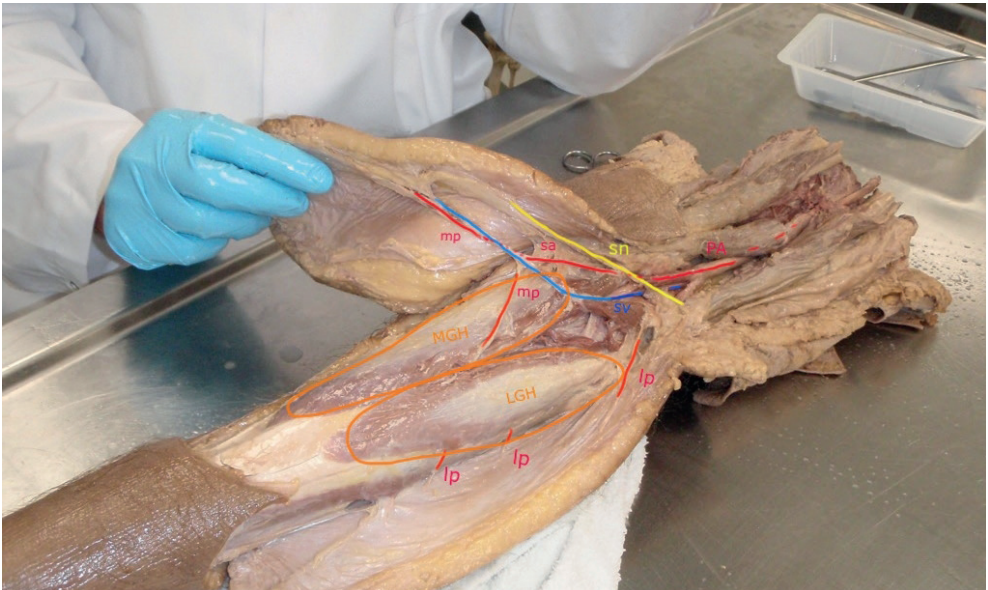
the lateral side was initially chosen for flap harvesting. The patient was positioned in semi-prone position after bone graft harvesting had been performed from the right iliac crest. A near to midline approach was chosen to assess the perforators. The musculocutaneous perforators could not be dissected from the muscle to their origin since they were situated beneath the fibula. For this reason a medial sural artery perforator fasciocutaneous island flap was chosen. This approach provided enough length to cover the tibial defect after rotation. After deflation of the tourniquet, the broad based flap remained vital on the cutaneous perforators (Figure 3). The flap was inserted and the donor site was covered by split skin graft taken from the upper leg. On day 4, most of the flap was vital, with a small necrotic medial border. This was resected and treated with a VAC®. The wound was managed by dressings on the ward. The patient was mobilized non-weight bearing for one month followed by mobilization with a cast for another two months (Figure 4).

## DISCUSSION

The use of perforator flaps for either pedicled or free tissue transfer is well established. Fascial, or fasciocutaneous flaps may be harvested without significant disruption of the underlying muscle. Functional deficit is therefore prevented as the muscle remains in place. The medial sural artery flap is a Type A fasciocutaneous flap based on the sural artery, a direct cutaneous branch of the popliteal artery. The flap is well described for reconstruction for soft tissue defect as either a free graft or local flap in the upper 1/3 of the tibia. The flap can measure up to 12.9 x 7.9 cm and at least 1 perforator is found in each flap, with an average of 1.9 perforators found in the anatomical study by Thione et al (2). Cavadas (3) first described the medial sural artery perforator free flap and provided precise topography of perforating vessels from the medial and lateral gastrocnemius muscle. Others have described the anatomy of the perforating vessels that supply the fascia and skin of the posterior calf in more detail (4-6). Hallock (4) described that successful preparation of a medial sural artery perforator flap was possible in 90% of cases. Walton and Bunkis (7) suggested



**Figure 4:** Final situation after medial sural artery flap and split skin graft



**Figure 5:** Anatomical specimen right lower extremity MGH medial gastrocnemius muscle head, LGH lateral gastrocnemius muscle head, PA popliteal artery, SA sural artery, SV sural vein, SN sural nerve, LP lateral perforators, MP medial perforators

that the requirement to base such flaps on a dominant vessel is not required due the cutaneous vascular plexus between the heads of gastrocnemius. Nevertheless, it is not known whether this also the case in the affected limb after major trauma. Kim et al (8) described of location of the main perforators situated along a line from the midpoint of the popliteal crease to the midpoint of the medial malleolus. The first two perforators are most likely to be found at 8 cm and 15 cm, respectively, measured from the midpoint of the popliteal crease. In the cases described here audible Doppler or Duplex investigation was used across this line for identification of perforators. The flap was outlined as such that the distal perforator artery was situated in the center. This ensured maximum length for rotation. Cavadas (3) described the raising of the flap using a tourniquet and a non-exsanguinated limb. Preoperative Doppler sonography was demonstrated to be useful for locating the position of individual perforating vessels Hallock and Giunta et al Khan et al (9-11). The use of loupe magnification as advocated by Cadavas (3) facilitated the identification and dissection of the perforator vessels. Particularly in the case of the child this strategy was of use, but was not applied during flap harvesting in the adult patient. Results of sural artery flaps are generally favorable. Suri et al described use of this proximally based islanded sural artery flap for the lower thigh, knee, and upper leg defects in 37 patients. No complete failures in the series were seen with only one flap requiring additional bipedicled flap for the necrosis of distal margin (12). Gill et al described results of their experience in soft-tissue reconstruction of leg and foot; of 168 flaps, 154 survived completely, 9 flaps suffered partial necrosis and 5 failed completely (13). Okamoto describes similarities in anatomy for medial sural artery perforators in Caucasians and Asians suggesting that the medial sural artery flap may be universally possible (14). A practical algorithm for lower extremity soft tissue coverage, including the medial sural artery flap, has been proposed by El-Sabbagh (15). In both our cases, the patient was placed in the (semi)prone position. This allowed access to both the flap to be harvested and the placement of the flap onto the defect and has been found useful in previous studies (16). Both cases were commenced by a posterior incision through the deep fascia. This allowed the perforators to be assessed prior to the final skin outline being incised. This

strategy allows for a change of strategy based on the local course of the lateral sural perforators. Both flaps provided a robust thickness of tissue and provided adequate sealing of the joint and to cover bone. More significantly the flap pedicle length, even though limited in Case 1 by blast defect, allowed for sufficient rotation. In Case 1, the flap was rotated over 180 degrees to be placed upward onto the joint line and the skin defect could be closed primarily. In Case 2, the flap was rotated around the leg to overly the tibial tuberosity and proximal shaft defect. A split thickness graft allowed for tissue coverage of the harvest site. The care of local nationals is a reality for most deployed medical forces in combat. Decisions regarding the extent of such humanitarian aid are made by commanding officers. Depending on the level of involvement, challenging surgical cases often need to be managed in a geographically and culturally sensitive fashion. Significantly, the constraints of war and equipment also impact on the management of local civilians. Local nationals are usually unable to be moved out of country for further care, necessitating a definitive local solution. In this context, the management of compound and complex lower limb injuries is a challenge for the deployed surgeon. The surgeon must deal with extensive soft tissue damage, often without having broad reconstructive experience or the benefits of a microvascular armamentarium. The study by Boopalan et al supports soft tissue cover of lower limb defects by a single team involved in bony stabilization and reconstruction using local flaps as an alternative if resources are limited (17).

## **CONCLUSION**

Both cases described, represent local nationals in Afghanistan, who were delivered to an ISAF medical facility that is mainly equipped for damage control procedures. There were no alternative care providers nearby and no reconstructive surgery equipment was available. We believe, in such an austere setting, the medial sural artery perforator flap to be a feasible strategy for soft tissue reconstruction performed by trauma surgeons. It allows for soft tissue coverage of exposed critical bone and joint, facilitating limb salvage without excessive consumption of resources or morbidity to the patient.

## REFERENCES

1. The Red Cross Wound Classification 2nd edition, Robin M. Coupland, IRC, Geneva, 1991
2. Thione A, Valdatta L, Buoro M, Tuinder S, Mortarino C, Putz R. The medial sural artery perforators: anatomic basis for a surgical plan. *Ann Plast Surg.* 2004 Sep.;53(3):250-5.
3. Cavadas, P.C., Sanz-Gimenez-Rico, J.R., Gutierrez-de la Camara, A., Navarro-Monzonis, A., Soler-Nomdedeu and S., Martinez-Soriano, F. The medial sural artery perforator free flap. *Plast. Reconstr. Surg.* 108, 1609. 2001
4. Manchot, C. *The Cutaneous Arteries of the Human Body.* New York: Springer-Verlag, 1983.
5. Montegut WJ, Allen RJ. Sural artery perforator flap as an alternative for the gastrocnemius myocutaneous flap. In: *Proceedings From the 90th Annual Scientific Assembly of the Southern Medical Association.* Baltimore, Md., November 20-24, 1996
6. Hallock GG. Anatomic basis of the gastrocnemius perforator-based flap. *Ann Plast Surg.* 2001 Nov.;47(5):517-22.
7. Walton RL, Bunkis J. The posterior calf fasciocutaneous free flap. *Plast Reconstr Surg* 1984;74:76-85
8. Kim HH, Jeong JH, Seul JH, Cho BC. New design and identification of the medial sural perforator flap: an anatomical study and its clinical applications. *Plast. Reconstr. Surg.* 2006 Apr. 15;117(5):1609-18.
9. Hallock GG. Doppler sonography and color duplex imaging for planning a perforator flap. *Clinics in Plastic Surgery.* 2003 Jul.;30(3):347-57-v-vi.
10. Giunta RE, Geisweid A, Feller AM. The value of preoperative Doppler sonography for planning free perforator flaps. *Plast. Reconstr. Surg.* 2000 Jun.;105(7):2381-6.
11. Khan UD, Miller JG. Reliability of handheld Doppler in planning local perforator-based flaps for extremities. *Aesthetic Plast Surg.* 2007 Sep.;31(5):521-5.
12. Suri MP, Friji MT, Ahmad QG, Yadav PS. Utility of Proximally Based Sural Artery Flap for Lower Thigh and Knee Defects. *Ann Plast Surg.* 2010 Apr.;64(4):462-5.
13. Gill NA, Hameed A. The Sural Compendium: Reconstruction of Complex Soft-Tissue Defects of Leg and Foot by Utilizing the Posterior Calf Tissue. *Ann Plast Surg.* 2011 Jul. 5.



14. Okamoto H, Sekiya I, Mizutani J, Otsuka T. Anatomical basis of the medial sural artery perforator flap in Asians. *Scand J Plast Reconstr Surg Hand Surg.* 2007;41(3):125-9.
15. El-Sabbagh AH. Skin perforator flaps: an algorithm for leg reconstruction. *J Reconstr Microsurg.* 2011 Nov.;27(9):511-23.
16. Hallock GG, Sano K. The medial sural MEDIAL GASTROCNEMIUS perforator free flap: an "ideal" prone position skin flap. *Ann Plast Surg.* 2004 Feb.;52(2):184-7.
17. Boopalan PR, Nithyananth M, Titus VT, Cherian VM, Jepeganatham TS. Experience of using local flaps to cover open lower limb injuries at an Indian trauma center. *J Emerg Trauma Shock.* 2011 Jun. 30;4(3):325-9.



# Chapter

# Fifteen

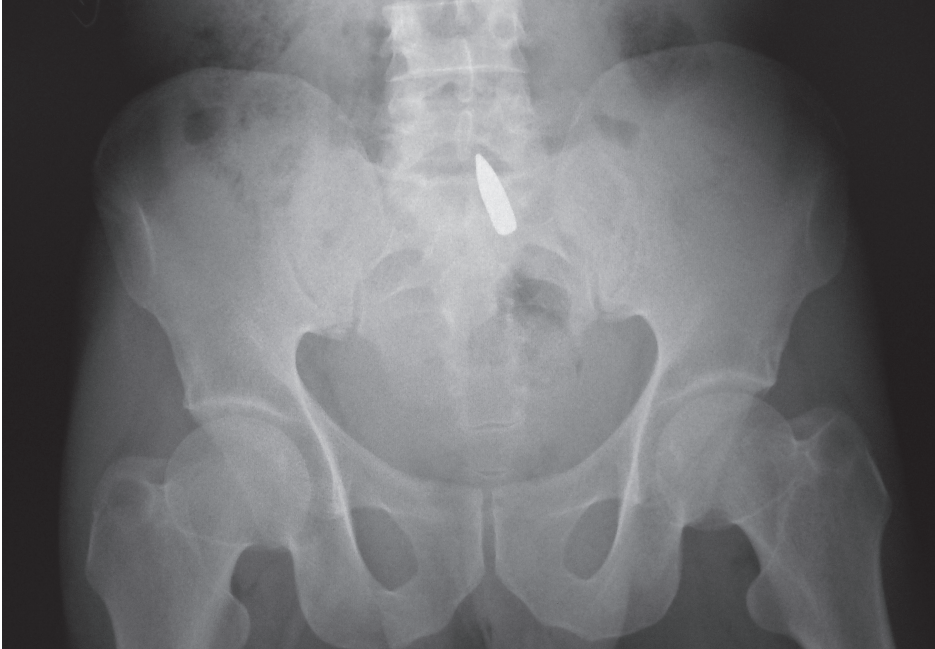
van Waes OJF, Halm JA, Vermeulen J, McAlister. Treatment of rectal war wounds. J R Army Med Corps 2014;160(3):255-7

## INTRODUCTION

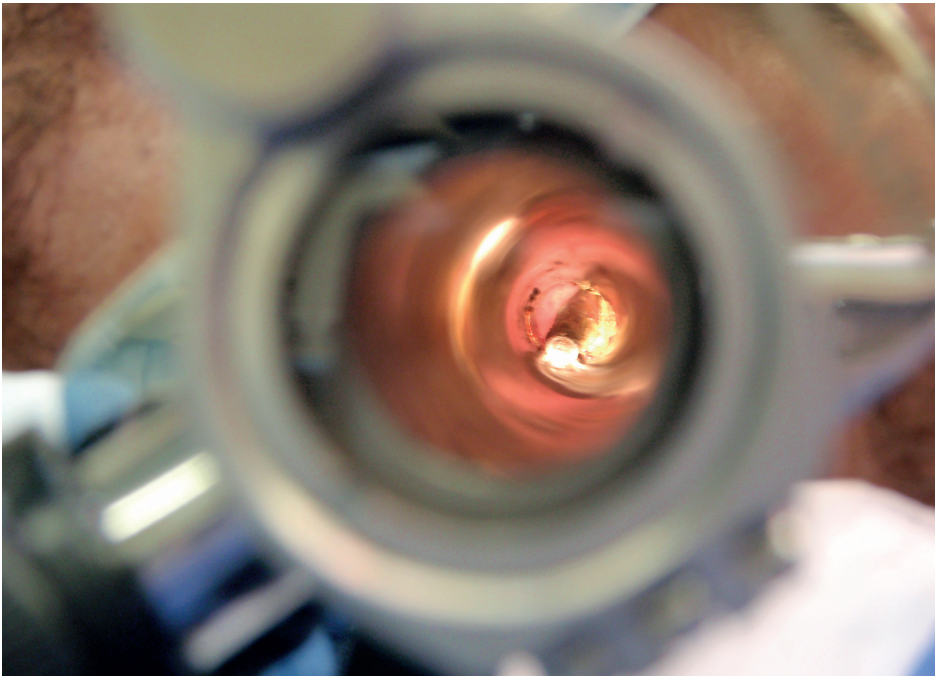
Penetrating ballistic injuries are commonly seen in war, and the shift in recent conflicts in Iraq and Afghanistan away from gunshot wounds (GSW) as the main cause of injury is significant. The increased use of Improvised Explosive Devices (IEDs) has resulted in more severely injured victims with an increase in perineal soft tissue injury and a likely concomitant increase in penetrating rectal injury (PRI) (1-4). PRI may be externally visible if the perineum is disrupted or easily identified by presence of blood on digital rectal examination (DRE). On other occasions, injuries are found only with careful inspection at the time of surgery because of a high degree of suspicion from the injury pattern. There is still debate about optimal treatment strategies in high energy transfer PRI, because publications of combat zone PRI are sparse. Conventional care for civilian PRI is a temporary diverting loop colostomy (5) and pre-sacral drainage (6), but several experienced trauma groups have questioned the need for pre-sacral drainage (6-8). The diversity of opinions in current literature on PRI treatment seems inadequate for many of the high-energy transfer (HET) injuries encountered in military surgical practice. The goal of this paper was to describe practical management strategies of PRI (and concomitant soft-tissue loss) to aid in the management of PRI sustained in military conflict based on representative cases and review of the current literature.

### **Case 1: Penetrating rectal injury due to gunshot**

A 38-year-old Afghan national male was transferred from the point of injury to the emergency department (ED) of an International Security and Assistance Force (ISAF) Role 3 medical treatment facility (R3MTF) in the Kandahar region after sustaining a GSW to the right flank two hours previously. Initial observations were with a heart rate of 110/min and blood pressure 90/40 mmHg. Abdominal examination showed signs consistent with peritonitis and a single wound in the right lower abdomen; DRE was normal and no other injuries were found. Anterior-posterior abdominal X-ray revealed a projectile at the level of the promontory of the sacral spine (Figure 1). An immediate laparotomy revealed gross faecal contamination from circumferential destruction of



**Figure 1:** X-ray image: projectile at the level of the promontory of the sacral spine

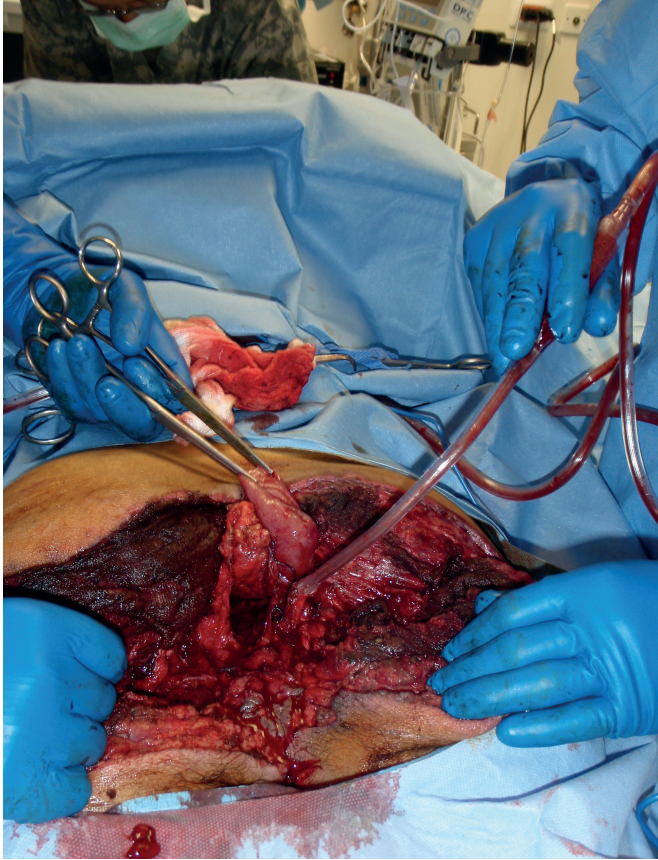


**Figure 2:** Rigid rectoscopy revealing an intraluminal projectile without evident rectal injury

the caecum, treated by right hemicolectomy and side-to-side ileotransverse colonic anastomosis. In addition to the caecal injury, exploration of an expanding retroperitoneal haematoma, necessitated suture ligation of the left internal iliac vein and renorrhaphy of the lower pole of the right kidney to control bleeding. No additional bowel injuries, including injuries of the intra-abdominal rectum were found and the projectile was not identified during laparotomy. After temporary abdominal closure, the patient was admitted to the Intensive Care Unit (ICU) for further resuscitation. Proctoscopy prior to relook laparotomy revealed an intraluminal projectile without evident rectal injury or luminal blood (Figure 2). A diverting loop colostomy was performed after copious intra abdominal and distal rectal washout and the abdomen closed. The patient recovered without complications and was discharged from hospital within one week. The colostomy was closed in a local facility six weeks later.

### **Case 2: Transgluteal injury due to rocket-propelled grenade**

A 25-year-old Afghan male was presented to the ED after a rocket-propelled grenade (RPG) had broadsided his unarmoured vehicle without detonating. He suffered a grade II shock that responded to resuscitation efforts. Inspection revealed an isolated but massive wound of both buttocks and rectum through which the missile had passed (Figure 3). No bony injury of the pelvis was discernible on radiographs. An exploratory laparotomy revealed no intraperitoneal injuries. A proctectomy with end colostomy was performed with resection of the remainder of the rectum. Thorough debridement and washout of both rectal, perineal and gluteal wounds was followed by vacuum assisted therapy (VAC). The patient returned to the operating room three times for completion of debridement followed by VAC dressing and progressive partial closure over the following 5 days. The anorectal sphincter complex had been completely destroyed without prospect for reconstruction. With the patient in the prone position, rotation flaps of skin and subcutaneous tissue were mobilised bilaterally to close the perineal defect over Penrose type drains. The drains were removed after 5 days. The patient was discharged to a local civilian facility for mobility rehabilitation 3 weeks after admittance.



**Figure 3:** Massive trans gluteal and anorectal wounds caused by RPG. Patient in prone position.

### **Case 3: Tangential injury of the coccyx and rectum due to gunshot**

A shocked 7-year-old Afghan male presented to the R3MTF 8 hours after suffering a HET tangential GSW to the pelvis. Following resuscitation in the ED he was transferred to the operating room where laparotomy revealed no intraperitoneal injury and a descending loop colostomy was formed with distal washout of the sigmoid colon and rectum. The patient was turned prone for wash out of the rectal wound. The skin and gluteal muscles were severely injured. The coccyx was completely destroyed and there was a 75% circumferential laceration of the rectum approximately five centimetres from the anal verge, but the anus and sphincter complex were intact, as was the surrounding skin.

After debridement, primary repair of the rectum was achieved with minimal mobilisation using inverting interrupted sutures of 3.0 Vicryl. A VAC dressing was applied over gauze covered with adhesive plastic dressing, which had been placed to protect the rectal repair. The patient returned to the operating room three times for debridement and irrigation over the next week. At each procedure, the skin defect was increasingly covered using skin advancement flaps until it was closed. The patient resumed diet on the third day after admission. He was able to walk with assistance after the first week. He was discharged to the care of his family. He returned for closure of the colostomy six weeks later. Resumption of bowel movement per rectum with normal continence occurred a week later.

## DISCUSSION

The first patient suffered an injury from a single GSW and we believe that even though it was originally a high available energy projectile, by the time it had reached the rectum it had already dissipated most of its energy to penetrate the rectum with no discernible tissue destruction. The literature suggests that non-destructive rectal injuries such as this may be treated without colostomy (9), but unfortunately the austere situation of a war zone does not (always) afford the luxury of a wait and see policy and emergent evacuation to the next level of care may be difficult and so we believe our choice of defunctioning loop colostomy is justified, particularly in the face of the massive faecal contamination caused by the destruction of the caecum. The injuries suffered by the second and third patients resulted from much greater transfer of energy to the rectum causing complete destruction of the posterior pelvis and the anorectum - anorectal preservation was possible in the latter case because the anal sphincter complex was preserved. Defunctioning colostomies in local nationals were closed as soon as possible because of the harsh conditions resulting in a lack of supplies. In civilian practice, most penetrating rectal injuries are caused by low energy transfer (LET) projectiles and can easily be treated by performing diverting colostomy without the need for further repair of the rectal injury or distal rectal washout (5,6). In contrast



to LET PRI, literature on high energy transfer or blast injury of the rectum, as encountered in the current conflict in Afghanistan, is rare. Our experience suggests that multiple operations of a more intense nature are required for combat-related PRI and is needed to treat the gross soft injuries due to the massive energy transfer encountered in the perianal and buttock wounds of war. The primary phase often includes initial cleaning, packing of both the perineal wound and the pre-peritoneal space of the pelvis to control haemorrhage and a diverting colostomy. Subsequent operations are required to complete debridement of soft tissue wounds that close by secondary intention. The colostomy may only then be closed if the rectum has been repaired with preservation of the anorectal complex. This is particularly true for PRI associated with perineal injuries from anti-personnel IED (10). In a retrospective analysis of penetrating pelvic battlefield trauma in 28 patients, 12 suffered extraperitoneal rectal injury from HET projectiles(11). The study demonstrated a significant correlation between pelvic fractures, massive soft tissue injury and rectal injuries resulting in a mortality rate of 33%. High energy transfer injuries usually result in rectal injuries that require some form of local surgical debridement and repair in combination with a diverting colostomy for faecal diversion (7,8,11). In a cohort of colo-rectal injuries in 977 coalition forces serving in Iraq and Afghanistan rectal injury led to faecal diversion twice as often as colonic injury with more than half of patients requiring an 'ostomy' (56.2%) (12). The role of presacral drainage in the management of civilian LET penetrating rectal injuries is limited since morbidity and mortality do not increase when faecal diversion is performed without presacral drainage (13). However, in HET wounds of the extraperitoneal rectum, such as combat injuries, the administration of pre-sacral drainage and distal washout is still advocated (7,14). Based on 26 extraperitoneal civilian rectal gunshot injuries Levy et al recommended that in most cases a loop colostomy is sufficient to divert the faecal stream while Hartmann's procedure must be considered in cases with massive rectal and perineal disruption; rectal wound repair should only be attempted when easy to perform; presacral drainage should be performed via the transperineal route only in cases with significant posterior rectal laceration and dissection of the perirectal spaces; and distal rectal washout is not mandatory,

but may be performed in cases of massive disruption of rectal and surrounding tissues (15). In a series of 29 patients suffering from penetrating rectal injuries a trauma to treatment interval of more than 8 hours, the presence of perianal or gluteal injuries and the presence of faecal contamination were significant factors affecting development of morbidity (16). In the largest published series by Burch et al. (17), and in all subsequent series (11, 18-22), no benefit in reducing septic complications was achieved when distal rectal washout was added to diversion and pre-sacral drainage although Burch et al. showed a significant reduction in pelvic septic complications through the application of presacral drainage (14). There are too few publications on combat PRI for evidence based advice for treatment of these patients, but based on the experience of the authors in combination with the published literature, we recommend repetitive debridement in combination with washout of penetrating rectal wounds with high energy transfer to the tissue, such as those IEDs. They may be managed well with aggressive surgical debridement and assisted by subatmospheric pressure therapy if available. The liberal use of proctoscopy in penetrating trauma in the region of the lower abdomen, buttocks and upper femur is advocated, since it may reveal rectal injuries otherwise missed by digital rectal examination. The diagnostic accuracy of the digital rectal examination and proctoscopy in diagnosing rectal injuries is 76-95% (17,19-21,23,24). Data on false-negative proctoscopy is rare but may be as as high as 31% (25).

## CONCLUSION

In contrast to treatment of low energy transfer PRI, in which an expectant treatment in combination with a diverting colostomy might suffice (although in austere conditions this may not be the safest option), high energy transfer PRI requires aggressive surgical management. Massive soft tissue injuries require repetitive washout and debridement in combination with an end colostomy and drainage or subatmospheric pressure therapy to save the patients life. Only when the patient's condition and healing of the rectal and perineal injuries are deemed to be sufficient, is reversal of the colostomy advised feasible.

## REFERENCES

1. Sarić D, Tudor M, Grandić L et al. Penetrating combat injuries of the colorectal region. *Chirurg*. 2001;72:425-32
2. Brisebois RJ, Tien HC. Surgical experience at the Canadian-led Role 3 multinational medical unit in Kandahar, Afghanistan, *J Trauma*. 2011;71:397-400
3. Belmont PJ Jr, McCriskin BJ, Sieg RN et al. Combat wounds in Iraq and Afghanistan from 2005 to 2009. *J Trauma Acute Care Surg*. 2012;73:3-12
4. Owens BD, Kragh JF, Wenke JC et al. Combat wounds in operation Iraqi freedom and operation enduring freedom. *J Trauma*. 2008;64:295-299
5. Navsaria PH, Edu S, Nicol AJ. Civilian extraperitoneal rectal gunshot wounds: surgical management made simpler. *World J Surg*. 2007;31:1345-51
6. Steinig JP, Boyd CR. Presacral drainage in penetrating extraperitoneal rectal injuries: is it necessary? *Am Surg*. 1996;62:765-7.
7. Brogden TG, Garner JP. Anorectal injury in pelvic blast. *J R Army Med Corps*. 2013;159:i26-31
8. Barkley S, Khan M, Garner J. Rectal trauma in adults. *Trauma*. 2013;0:1-13
9. Plummer JM, McDonald AH, Newnham JP et al. Civilian rectal trauma: the surgical challenge. *West Indian Med J*. 2004;53:382-6.
10. McAlister VC. "The Role of Surgery in Building Resilience to Blast Attacks" *NATO Research & Technology Organisation RTO-MP-HFM-207.KN4* (2011): 1-3. <[ftp://ftp.rta.nato.int/PubFullText/RTO/MP/RTO-MP-HFM-207/\\$MP-HFM-207-KN4.doc](ftp://ftp.rta.nato.int/PubFullText/RTO/MP/RTO-MP-HFM-207/$MP-HFM-207-KN4.doc)> accessed 18 Nov 2012
11. Arthurs Z, Kjorstad R, Mullenix P et al. The use of damage-control principles for penetrating pelvic battlefield trauma. *Am. J. Surg*. 2006 May;191(5):604-9.
12. Glasgow SC, Steele SR, Duncan JE et al. Epidemiology of modern battlefield colorectal trauma: a review of 977 coalition casualties. *J Trauma Acute Care Surg*. 2012 Dec;73(6 Suppl 5):S503-8.
13. Gonzalez RP, Falimirski ME, Holevar MR. The role of presacral drainage in the management of penetrating rectal injuries. *The Journal of Trauma: Injury, Infection, and Critical Care*. 1998 Oct.;45(4):656-61.
14. Burch JM, Feliciano DV, Mattox KL. Colostomy and drainage for civilian rectal injuries: is that all? *Ann. Surg*. 1989;209:600
15. Levy RD, Strauss P, Aladgem D et al. Extraperitoneal rectal gunshot injuries. *The Journal of Trauma: Injury, Infection, and Critical Care*. 1995 Feb.;38(2):273-7.

16. Gümüş M, Kapan M, Önder A et al. Factors affecting morbidity in penetrating rectal injuries: a civilian experience. *Ulus Travma Acil Cerrahi Derg.* 2011 Sep.;17(5):401-6.
17. Burch JM, Brock JC, Gevirtzman L et al. The injured colon. *Ann. Surg.* 1986 Jun;203(6):701-11.
18. Thomas DD, Levison MA, Dykstra BJ, et al. Management of rectal injuries: dogma versus practice. *Am. Surg.* 1990;56:507
19. Ivatury RR, Licata J, Gunduz Y, et al. Management options in penetrating rectal injuries. *Am. Surg.* 1991;57:50-57
20. Levine JH, Longo WE, Pruitt C, et al. Management of selected rectal injuries by primary repair. *Am. J. Surg.* 1996;172:575-68.
21. McGrath V, Fabian TC, Croce MA, et al. Rectal trauma: management based on anatomic distinctions. *Am. Surg.* 1998;64:1136
22. Bostick PJ, Johnson DA, Heard JF, et al. Management of extraperitoneal rectal injuries. *J. Natl. Med. Assoc.* 1993;85:460
23. Morken JJ, Kraatz JJ, Balcos EG, et al. Civilian rectal trauma: a changing perspective. *Surgery* 1999;126:693-700
24. Velmahos GC, Gomez H, Falabella A et al. Operative management of civilian rectal gunshot wounds: simpler is better. *World J Surg* 2000;24:114-118.
25. Grasberger RC, Hirsch EF. Rectal trauma: a retrospective analysis and guidelines for therapy. *Am J Surg* 1983;145:795-799.





# Chapter

# Sixteen

van Waes OJF, van de Woestijne PC, Halm JA. "Thunderstruck": penetrating thoracic injury from lightning. *Ann Emerg Med* 2014;63(4):457-9

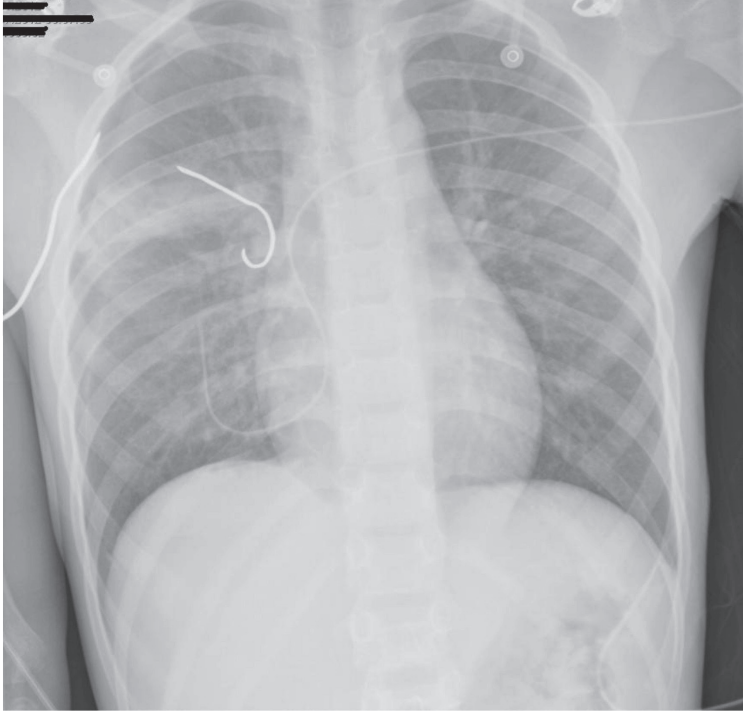
## INTRODUCTION

Penetrating injuries secondary to lightning strike are extremely rare especially in paediatric patients. Referral of lightning strike victims to a burn unit is currently usually advised (1,2). This paper reviews the epidemiology, clinical presentation and management principles of penetrating injury resulting from lightning strike blast.

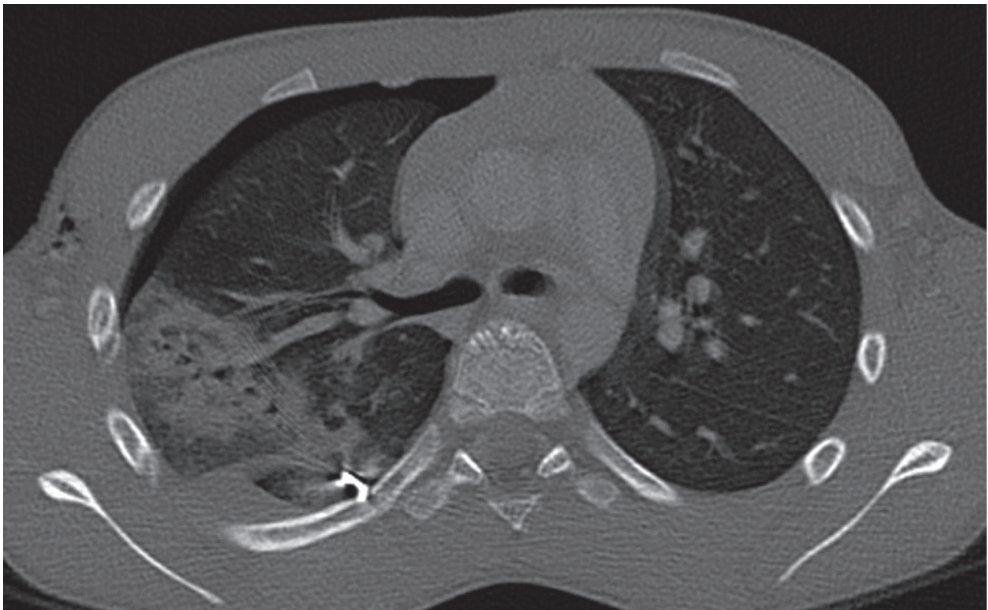
### Case Report

A male twin, 8 years of age was presented to our emergency department (ED), after being injured as a result of lightning strike in an AC (Alternating Current) transformer housing. At the time of the strike, the victims were located in a textile dome tent approximately 15 meters from the housing. On physical examination by dispatched Helicopter Emergency Service Team both patients had a GCS of 15 without respiratory distress or hemodynamic abnormalities. The patients were referred to a regional level I trauma centre. Upon arrival in the emergency department they were evaluated utilizing PTLIS (Paediatric Trauma Life Support) guidelines. During primary survey the first patient was normotensive (117/70 mmHg) with a normal heart rate of 90 bpm, a free airway and a maximum paediatric Glasgow coma score. During full exposure two protruding copper wires were noted at the level of the scapula as well as a 2nd degree burn mark in the face. Conventional thoracic radiography revealed no fractures or pneumothorax. Routine electrocardiography showed no signs of cardiac injury. The facial burn wound was treated per protocol and the copper wires were removed surgically under local anaesthesia. The patient was admitted to the paediatrics ward for observation and treatment of the burn wound and was discharged the ensuing day. His twin brother was normotensive (125/65 mmHg) with a normal heart rate of 100 bpm, a free airway, normal chest auscultation bilaterally and a saturation of 97% without supplemental oxygen. Routine electrocardiography showed no signs of cardiac arrhythmia. Despite a large occipital laceration of 5 by 2 cm, the paediatric Glasgow coma score was 15. Upon inspection of the body a minute puncture wound was identified at the lateral border of the right pectoral muscle (at the level of the 4th rib). Conventional thoracic radiograph in





**Figure 1:** Chest radiograph with "shrapnel" in the patient right hemithorax.



**Figure 2:** CT with an improvised explosive device-like trajectory through the lung parenchyma.

two directions showed a hemato-pneumothorax on the right side. Furthermore, a foreign body was identified in the thoracic cavity (Figure 1). Additional Computer Tomographic angiography (CTA) revealed a missile trajectory through the lung, a projectile located in lung parenchyma and an increase of the pneumo- and hematothorax compared to the conventional thoracic radiograph (Figure 2). During urgent exploratory right-sided antero-lateral thoracotomy the lung lacerations were sutured with polypropylene sutures and a fragment of copper wire, approximately 2 centimetres in length, was removed from the dorsal thoracic wall. Two chest drains were inserted. On the second day post-operatively the two chest tubes were removed. The patient was discharged after uneventful recovery on day seven.

## DISCUSSION

Most commonly lightning strikes act through one or more of five separate mechanisms recognized in keraunomedicine [3,4]. Direct strikes by lightning result in current flowing through the body. Additionally, contact voltage, side splash, ground strike, wire-mediated lightning injury have been described extensively in the literature (3-5). Only recently have Blumenthal et al added a possible sixth mechanism in which a nearby strike causes a blast wave to create barotrauma to the hollow viscus of the patient (see Table 1) (6). In a case report the same author describes an autopsy of a patient suffering from secondary missile injury to the patient's lower extremities after lightning strike to the adjacent pavement. Small pieces of concrete shrapnel were found embedded within the wounds. The patient succumbed from the lightning strike (7). Penetrating thoracic blast injury caused by a nearby lightning strike has not been reported previously, and is potentially devastating in nature. The authors hence propose a seventh type of lightning strike injury; penetrating blast injury due to lightning strike induced explosion of nearby structure (see Table 1). The penetrating injury pattern and mechanism described in this case has great similarities with those seen in victims of improvised explosive devices (IED) (8,9). Blast injuries are commonly categorized by mechanism into primary, secondary, tertiary and quaternary (e.g. burns

or toxic effects) injuries. Primary injury is the result of blast overpressure (BOP) followed by under pressure and affects (air-filled) organs that are stretched beyond their limits. The secondary mechanism results in penetrating injury through shrapnel. In the tertiary mechanism the patients are hurled by the blast, resulting in blunt trauma from impact (10,11). Blast injuries with penetrating injury in the civilian setting are fortunately rare (12). The authors are familiar with the treatment of IED type of injuries from deployment in the recent military conflict in Afghanistan, where the victims arrive in hospital "peppered" by shrapnel as several body cavities are violated and the respective organs injured. It is of utmost importance to include full and complete exposure during the primary survey in these patients to identify possible sites of injury. Special attention needs to be given to the body folds (neck, axillae, groin, gluteal) as wounds located there may be easily missed. In the herein described case the missile entered the thoracic cavity through only small puncture wound in the axilla, which could have been easily missed, but revealed gross injury to the lung parenchyma at surgical exploration.

The most common injuries from exposure to lightning are burns, which usually require immediate care in specialised burn units. However, one must be prepared for additional barotrauma and penetrating blast injuries or possible fractures as a result of the pressure wave.

**Table 1:** Type of lightning strike and ways the human body is affected

Type	Description	Effect on the human body
1	Direct strike	Current flows through the body, high mortality
2	Contact voltage	Lightning strikes an object the victim is touching
3	Side splash	Splashing of current from a nearby direct strike
4	Ground strike	Ground current passes to the victim from the ground strike point
5	Upward streamer	Current flows through the body from the ground upwards
6	Blast Barotrauma	Explosion of the air around the lightning channel causing injury to hollow viscus or fractures by a blast wave
7	Blast penetrating injury	Lighting strike induced explosion of nearby structure in which shrapnel causes penetrating injuries to patient.

## CONCLUSION

Lightning strikes victims are rare to be presented at an emergency department. The range of injuries is broad and often burns are the primary focus. Lightning strike resulting in IED like blast injuries has now been added to its possible trauma mechanisms. These "shrapnel" injuries should be excluded in all patients struck by lightning.

## REFERENCES

1. Guidelines for the operation of burn centers. *J Burn Care and research* 2007;28:134-141
2. Russell KW, Cochran AL, Mehta ST et al. Lightning burns. *J Burn Care and research*. 2013;20:1-3
3. Ritenour AE, Morton ML, McManus JG, Barillo DJ, Cancio LC. Lightning injury: a review. *Burns* 2008;34:585-594
4. Blumenthal R. Lightning fatalities on the south African Highveld; a retrospective descriptive study for the period 1997 to 2000. *Am J Forensic Med Pathol*. 2005;26:66-69
5. Cancio LC, Jimenez-Reyna JF, Barillo DJ et al. One hundred ninety-five cases of high-voltage electric injury. *J Burn Care and rehabilitation* 2005;26:331-340
6. Blumenthal R, Jandrell IR, West NJ. Does a sixth mechanism exist to explain lightning injuries? *Am J forensic Med Pathol*. 2012;33:222-226
7. Blumenthal R. Secondary missile injury from lightning strike. *Am J forensic Med Pathol*. 2012;33:83-85
8. Ramasamy A, Hill AM, Clasper JC. Improvised explosive devices: pathophysiology, injury profiles and current medical management. *JR Army Med Corps*;155(4):265-272
9. Ramasamy A, Harrisson SE, Clasper JC et al. Injuries from roadside improvised explosive devices. *J Trauma* 2008;65(4):910-14
10. Champion HR, Holcomb JB, Young LA. Injuries from explosions: physics, pathology, and required research focus. *J Trauma*. 2009;66(5):1468-77
11. Ramasamy A, Hill AM, Hepper AE et al. Blast mines: physics, injury and vehicle protection. *JR Army Med Corps*;155(4):258-64
12. Born CT. Blast trauma: the fourth weapon of mass destruction. *Scand J Surg*. 2005;94(4):279-85



# Chapter Seventeen

## SUMMARY AND CONCLUSIONS (English)

### PART ONE

In **chapter two** general considerations and body specific treatment option for patients suffering from penetrating injury who are in need of damage control surgery (DCS) are discussed. Seemingly minor penetrating injury can result in a rapidly deteriorating patient without warning. These patients, when in extremis, do not have the physiological "reserve" to undergo a definitive treatment and are in need of DCS. Damage control surgery is especially useful in high energy transfer (HET) penetrating injury, for example a high velocity or close range gunshot wound. In HET gunshot wounds concomitant injury such as devitalization by temporary cavitation caused by the shockwave of the passing projectile might occur. In these cases it is advisable to perform staged surgery for injuries to the gastrointestinal tract to assess the vitality before performing a definitive anastomosis.

Not all penetrating brain injury (PBI), stab or gunshot wounds, are lethal. It is advised that after successful resuscitation patients receive a CT scan as soon as possible to evaluate why neurosurgery, decompressive craniotomy and debridement or removal of foreign bodies, should not be done. If the patients hemodynamic status does not permit a CT scan of the brain, synchronous DCS by both trauma surgeon a neurosurgeon can be performed if a cerebral mass effect is suspected.

Foley catheter balloon tamponade is not only useful for temporary hemorrhage control of penetrating neck injuries in the pre-hospital setting, but can also be used as bailout options in the operation room if suture techniques do not suffice.

The anterolateral thoracotomy is the gold standard for patients in extremis in, which a suspected pericardial tamponade or massive intra-thoracic hemorrhage needs to be addressed. In case of massive pulmonary bleeding clamping of the hilum or a pulmonary hilar twist can be executed. For through and through pulmonary injuries a GIA stapler can be used to fashion a so-called "tractotomy" for hemostasis and air leakage control.



In a damage control laparotomy hemorrhage and contamination control should be achieved as soon as possible. Thus kidney or spleen are removed in case of bleeding and injured bowel segments are resected and removed using gastrointestinal stapler. The physiological status of the patients does not allow attempts for organs salvage or bowel anastomosis. In order to protect the viscera until subsequent surgery and prevent an abdominal compartment syndrome, a temporary abdominal closure device can be fashioned from plastic sheets, gauze and percutaneous drains connect to a suction device.

Foley catheter balloon tamponade is also an option for hemorrhage control of junctional penetrating injuries of the extremities (e.g. groin, axillae), which are not suitable for a tourniquet application. Shunts can be used to temporarily bridge vascular injuries until definitive repair.

Patients suffering from penetrating injuries to the extremities with vascular injury usually suffer concomitant injury to other body regions, which may distract or hinder the treating surgeon in assessment for a developing compartment syndrome. Hence "prophylactic" fasciotomy of the affected limb is advocated.

Post DCS it is advised to return the patient to the operating room for definitive repair as soon as the preset resuscitation values are established and additionally to avoid the detrimental effects of missed injuries.

## **PART TWO**

**Chapter three** discusses the outcome of a prospective cohort study in the management of penetrating brain injury (PBI), from stab and gunshot wounds, in civilian population. In 73% PBI was the result of LET (stab wounds) and in 27% of HET (gunshot wounds). PBI in itself is not a contraindication for neurosurgical treatment. Moreover PBI with a Glasgow Coma Score  $\leq 8$  and brain matter "oozing" are no contra-indications for surgery. Surgery for PBI had an excellent survival (100%) versus good survival (83%) with SNOM. PBI had an in-hospital survival of 89% overall. HET PBI had a favorable Glasgow Outcome Score in 50% at discharge compared with 82% of LET PBI. Known poor

prognostic indicators for blunt BI (*i.e.*, GCS  $\leq$  3, dilated non light reactive pupils, and prolonged hypotension) seem to apply to PBI as well. Specifically for PBI, central bihemispheric injuries can be added as an indicator of poor prognosis. If none of the above mentioned indicators are found, CT will render arguments not to operate on PBI.

The feasibility of SNOM of penetrating neck injury (PNI) is investigated in a prospective study of seventy-seven consecutive patients presenting to a tertiary trauma center with PNI, in **chapter four**. Seven patients received Foley catheter balloon tamponade for (temporary) hemorrhage control and as a "bridge" to definitive (surgical) treatment. Balloon tamponade was the definitive and successful SNOM in two patients and could be removed after two days. Sixty-five (87%) of all hemodynamic stable patients succeeded with SNOM without the need for intervention for late onset complications.

**Chapter five** describes a prospective cohort study of 248 patients with penetrating thoracic injury. The success rate and survival of penetrating thoracic injury treated conservatively by SNOM principals was evaluated. In 70.6% of the SNOM patients chest tube drainage for hemato-pneumothorax was required. PTI was found to have low in-hospital mortality rate of 2%. Only 16.5% of patients required surgical treatment beyond a chest tube. SNOM for PTI was safe and successful in 93.2%.

In **chapter six** the outcome of all immediate thoracotomies for PTI (46 stab wounds and 10 gunshot wounds) over a period of ten years is evaluated in a Dutch trauma center. Retrospective evaluation revealed that 12 of 56 PTI patients were in need of an Emergency Department Thoracotomy (EDT) for resuscitation with a survival rate of 25%. The remaining 44 patients were taken to the operation room for a thoracotomy in a more controlled environment, with a survival of 75%. Although these are the results of a low volume center for penetrating injury, the outcomes are similar to those seen in high-incidence regions such United States of America and South Africa.

The evaluation of 5 year out of hospital thoracotomies for PTI performed by the Helicopter Emergency Medical Service of The Netherlands is described in **chapter seven**. Ten patients went pulseless after PTI due gunshot wounds and 23 after stab wounds. In 27% of the cases, all stab wounds, return of spontaneous circulation (ROSC) after thoracotomy was established. This resulted in one survivor without neurological damage. These results seem to justify the out of hospital thoracotomy for pulseless patients after PTI. However an in hospital mortality of 89% after an out of hospital thoracotomy with ROSC and no cases with ROSC after gunshot wounds warrants ongoing and critical evaluation of the procedure.

A selective non-operative management (SNOM) protocol for penetrating abdominal injury was introduced in the ErasmusMC Trauma Center despite it being a low volume center when dealing with penetrating trauma. The feasibility of SNOM for penetrating abdominal injury (PAI) and to assess whether or not this protocol would improve the patients outcome was appraised in a retrospective study described in **chapter eight**. Of 393 patients with PAI, 278 had stab wounds. Respectively 62% and 59% of patients were treated with SNOM before and after the protocol was embedded in the local modus operandi. From the 115 gunshot patients with PAI, 41% before and 30% after were treated with SNOM. There was no significant difference in the success rate of SNOM for abdominal stab wound before and after protocol introduction with 90% before and 88% successful SNOM. This also applied to abdominal gunshot wounds with SNOM success rates of 94% versus 100%. Protocol introduction did improve the rate of admittance for observation of abdominal stab wounds from 83% to 100%. A significant drop in the use of ultra sound evaluation of the abdomen in abdominal penetrating injury was noted from 84% to 32% of the stab wound patients and 87% to 43% of the abdominal gunshot patient. Selective non-operative management for abdominal penetrating injury can be implemented successfully and safely in Western European Trauma centers with a low volume of penetrating injuries.

In **chapter nine** the results of a prospective study of penetrating upper extremity trauma (PUET) are discussed. Stab wounds caused PUET in 79.5% of the 161 included patients. The remaining 20.5% was caused by gunshot wounds. SNOM for possible vascular injury was successful without complication in 85%. Urgent surgical exploration for suspected vascular injury was necessary in 10% of patients. In 5% vascular surgery was planned electively. None of the injuries were treated by radiological intervention. Ten patients were also in need of planned osteosynthesis for sustained fractures and an additional eight for nerve injury repair. In 38% of the cases patients also sustained penetrating injuries to other body regions. This means that although 85% of the patients with PUET can be treated successful with observation for possible vascular injury, a significant percentage is still in need of surgery for vascular, fracture and nerve repair combined making PUET a serious injury.

A retrospective study on the outcome of treatment of penetrating injury of both upper and lower extremity in the Netherlands is discussed in **chapter ten**. Over a 10 year period 668 patients with suspected penetrating trauma of the extremities (PTE) were identified, of which 156 were actual penetrating injuries requiring admittance for treatment. Of these (34% gunshot wounds and 66% stab wounds) 14% were in need of surgical exploration for vascular injury. Of the 86% of patients initially treated by SNOM, 1.5% required an intervention for (late onset) vascular complications. In 5% concomitant nerve injury was missed during the initial hospitalization. Of ten patients who underwent lower extremity vascular repair with an interposition graft who did not receive a (prophylactic) fasciotomy, two (20%) developed a compartment syndrome which was not recognized as such. This resulted in peroneal nerve palsy in both cases. The low failure rate in this study validates SNOM for penetrating trauma of the extremities. It is however essential to rule out nerve injury and development of a compartment syndrome since these are easily missed and result in long-term disability.

In **PART THREE: penetrating prose, chapter eleven** describes a case of a six year old boy sustaining penetrating abdominal injury due an exploded grenade. During laparotomy numerous ascaris were encountered exiting from the multiple gastrointestinal lacerations. Postoperative the patient was treated with Mebendazol to eradicate the helminthes, after which the patient developed a mechanical bowel obstruction due to conglomerate of dead ascariasis. This was successfully resolved by using Erythromicine as a propulsive agent. In conclusion surgeons should consider ascariasis as a cause for postoperative bowel obstruction in pediatric patients after a (trauma)laparotomy in the developing world.

**Chapter twelve** describes a case of self-inflicted penetrating thoracic injury by a samurai sword, which was conservatively treated with chest drainage. The patient was well enough for discharge after three days. One week after discharge the patient presented at the emergency department (ED) with shortness of breath and chest pain. On the chest X-ray the pericardial effusion was not appreciated and since there were no signs of a (hemato)pneumothorax the patient was discharged. The following day the patient was brought in by the emergency medical services who had found him collapsed in the street. This time the late pericardial tamponade was recognized and successfully drained using a "subxyphoid window" approach. The lesson learned is that even if there are no signs of pericardial effusion during the initial treatment, a late onset pericardial tamponade may develop if the penetrating injury track is near the heart. Ultrasound evaluation prior to discharge in these patients is advised.

In **chapter thirteen** a slug protruding into the hip joint after following "the path of a dynamic hip screw" is presented. Aside from the "exotic bullet track" this case illustrates that although there is no need in general to remove bullets, that those lodged in a joint are advised to be extirpated since they may cause lead poisoning and traumatic arthritis.

**Chapter fourteen** presents two cases of large soft tissue defects as a result of combat related injury treated by sural artery perforator flaps. This technique is not limited to centers with complex surgical armamentarium per se, but is feasible for surgeons with good understanding of the local anatomy.

In **chapter fifteen** treatment strategies of three high energy transfer (HET) penetrating rectal injury cases and the current literature on this topic are discussed. It is concluded that where as in "civilian" low energy transfer (LET) penetrating rectal injury a diverting loop colostomy without the need for further repair or washout suffices, HET or blast injury of the rectum requires aggressive surgical management. Usually in the primary phase debridement, washout and packing followed by repetitive re-debridement with secondary closure of the wounds. The penetrating prose part concludes with **chapter sixteen** in which two 8 year old boys suffering from penetrating thoracic blast injury are described as a result of lighting strike of a nearby alternating current transformer substation. This is the first reported case in which a lightning strike induced explosion causing penetrating injuries from shrapnel is described. The mechanism is added as the seventh known mechanism of injury in keraunomedicine. The lesson learned from this case is that, although lightning strike victims are a rarity and burns are the primary injury, penetrating "shrapnel" injuries should be ruled out in these patients.

In summary, this thesis states that:

- All surgeons providing trauma care, regardless of the level of the trauma center they work at, should be familiar with the principles of damage control surgery. Since seemingly minor penetrating injury, can rapidly deteriorate into patients in extremis. HET penetrating injury will need staged surgery to re-assess the vitality of tissues. (Chapter two).
- Penetrating brain injury presented to the emergency department is survivable, even for gunshot wounds with "oozing" of brain matter. For the larger part a reasonably good Glasgow Outcome Score can be expected. CT scans are required as soon as

possible to render arguments not to operate on penetrating brain injury (Chapter three).

- SNOM principals can successfully be applied for penetrating injury to the neck, chest, abdomen and extremities, even in low volume centers (Chapters four, five, six, eight, nine and ten).
- The out of hospital thoracotomy for pulseless patients after penetrating thoracic injury is justified, but critical attention is warranted (Chapter seven).
- Surgeons should consider "exotic" agents such as ascariasis as a cause for postoperative ileus in pediatric patients after a (trauma)laparotomy and antihelminthic therapy in the developing world (Chapter eleven).
- Late onset pericardial tamponade may develop in penetrating injury near the heart. Ultrasound evaluation prior to discharge in these patients is advised (Chapter twelve).
- Bullets lodged in a joint require removal to prevent lead poisoning and traumatic arthritis (Chapter thirteen).
- Sural artery perforator flaps can be used to cover war wounds of the lower leg. This technique is also feasible for (non-plastic) surgeons with good understanding of the local anatomy (Chapter fourteen).
- HET or blast injuries of the rectum requires aggressive surgical management. In the primary phase debridement, washout, packing and a diverting loop colostomy are called for, followed by repetitive re-debridement with secondary closure of the wounds (Chapter fifteen).
- In lightning strike victims penetrating "shrapnel" injuries should be ruled out (Chapter sixteen).





# Chapter

# Eighteen

## SAMENVATTING EN CONCLUSIES (Nederlands)

### DEEL EEN

In **hoofdstuk 2** worden chirurgische behandelingsopties besproken voor patiënten met penetrerende letsels, per lichaamsregio waarbij de nadruk ligt op damage control principes.

Ogenschijnlijk minimaal penetrerend letsel kan resulteren in een snel verslechterende toestand bij de patiënt zonder duidelijke merkbare waarschuwing vooraf. Deze zwaargewonde patiënten bezitten niet de fysiologische "reserve" om een definitieve operatie te ondergaan. Het voorkomen van lekkage van de darminhoud en chirurgische controle van de bloedingen heeft hoogste prioriteit. Deze zo gehete damage control chirurgie is vooral nuttig bij schotwonden met een hoge energieoverdracht, waarbij additioneel letsel kan optreden, veroorzaakt door de schokgolf van het passerende projectiel. In deze gevallen is het raadzaam om gefaseerde operaties uit te voeren waarbij de patiënt tussentijds op de intensive care gestabiliseerd wordt voordat bijvoorbeeld een definitieve darmnaad wordt aangelegd.

Steek- of schotwonden van het hoofd zijn niet altijd dodelijk. Een groot deel van de patiënten met dit soort letsel heeft profijt van een (neuro)chirurgische behandeling. Het advies is dan ook om zo snel mogelijk, na een succesvolle resuscitatie, een CT-scan van het brein te vervaardigen om te beoordelen of de patiënt een indicatie heeft voor neurochirurgisch ingrijpen. Als de patiënt in verband met additioneel letsel direct geopereerd moet worden en er geen tijd is voor een CT-scan van de hersenen, kan gelijktijdig damage control chirurgie door zowel een traumachirurg en neurochirurg worden uitgevoerd.

De ballonkatheter volgens Foley is niet alleen nuttig voor tijdelijke tamponade om bloedingen van penetrerende nekverwondingen onder controle te krijgen in de pre-hospitalen setting, maar kan ook worden gebruikt als noodoplossing in de operatiekamer als reguliere haemostase technieken niet afdoende zijn.

Het met spoed verrichten van een anterolaterale thoracotomie is de gouden standaard voor patiënten met penetrerend thoraxletsel in

extremis. Een vermoedelijke tamponade van het hart of een massale thoracale bloeding kan zo worden beoordeeld en worden verholpen. In het geval van grote bloedingen ten gevolge van longletsel, kan het afklemmen van de centrale vaat- en luchtwegboom of een draai om de eigen as (pulmonary hilar twist) worden uitgevoerd. Bij een door-en-door longletsel kan een darm (GIA) stapler worden gebruikt om middels een zogenaamde "tractotomie", controle over het luchttek en bloeding te krijgen.

Het doel van een damage control laparotomie, is het zo snel mogelijk bereiken van haemostase en stoppen van contaminatie uit de darmen. De meest effectieve manier om nier- of miltbloedingen tot staan te brengen is, om deze organen te verwijderen. Beschadigde darmsegmenten worden "afgeniet" met de darm (GIA) stapler en verwijderd. Darmnaden (anastomosen) worden tijdens deze fase van damage control niet vervaardigd, tenzij de fysiologische status van de patiënt dat toe staat. Om de ingewanden te beschermen tot de volgende operatie en om een overdruk in de buik (abdominaal compartimentsyndroom) te voorkomen, kan een tijdelijke abdominale bedekking worden gevormd uit plastic afdek materiaal, gaas en drains.

De eerder beschreven Foley katheter kan ook gebruikt worden om bloedingen te controleren bij penetrerende verwondingen in de overgangsgebieden van de ledematen naar de romp (bijv. lies, oksels) die niet geschikt zijn voor de plaatsing van een tourniquet. Shunts kunnen worden gebruikt om vaatletsel tijdelijk te overbruggen tot aan de definitieve herstellende operatie.

Patiënten met penetrerend (vaat)letsel van de ledematen hebben vaak additioneel letsel in andere lichaamsdelen. De behandelend chirurg kan hierdoor afgeleid zijn en een compartimentsyndroom (overdruk door bloeding/zwelling in de spierloges) niet of te laat onderkennen. Daarom wordt een "profylactische" fasciotomie (openen van het spiercompartiment) van de ledematen bij uitgebreid vaatletsel aanbevolen.

Gezien de kans op het missen van letsel gedurende een damage control operatie, wordt het aangeraden om de patiënt, zo snel als de fysiologie het toestaat naar de operatiekamer terug te brengen om de definitieve herstellende operatie uit te voeren. Dit dient uiteraard te gebeuren nadat de voor afgesproken parameters voor adequate resuscitatie op de intensive care unit zijn behaald.

## DEEL TWEE

**Hoofdstuk drie** bespreekt de uitkomsten van een prospectieve cohortstudie van penetrerend hersenletsel door steek- en schotwonden, in een civiele populatie. In 73% was penetrerend hersenletsel het resultaat van steekwonden en in 27% door schotwonden. Penetrerend hersenletsel had een ziekenhuisoverleving van 89%. In tegenstelling tot een gebruikelijke misvatting is penetrerend hersenletsel op zichzelf geen contra-indicatie voor neurochirurgische behandeling. Ook is penetrerend hersenletsel met een Glasgow Coma Score < 8 en hersenweefsel a vue is geen contra-indicaties voor een operatie. In de studie had chirurgie van penetrerend hersenletsel een uitstekende overleving (100%) versus een goede overleving (83%) bij een conservatieve observationele, zogenaamde "selective non-operative management" (SNOM), behandeling. Hersenletsel door schotverwondingen had 50% een goed niveau van functioneren bij ontslag vergeleken met 82% bij steekverwondingen. Kenmerken voor een slechte uitkomst bij stomp hersenletsel (d.w.z. GCS < 3, wijde niet-licht reactieve pupillen en langdurige lage bloeddruk) lijken eveneens op penetrerend hersenletsel van toepassing te zijn. Specifiek voor penetrerend hersenletsel kan een bihemispherisch letsel worden toegevoegd als voorspeller voor een slechte uitkomst. Als geen van de bovengenoemde kenmerken voor slechte uitkomst wordt gevonden, moet een CT-scan argumenten geven om al dan niet penetrerend hersenletsel te opereren.

De haalbaarheid van conservatieve behandeling, zogenaamde selective non-operative management (SNOM), van penetrerend nekletsel staat in **hoofdstuk vier** centraal. In een prospectieve studie van zevenenzeventig patiënten met penetrerend nekletsel die behandeld zijn in een tertiair traumacentrum, werd bij zeven patiënten een Foley katheter ballontamponade voor (tijdelijke) controle van de bloeding toegepast. Ballontamponade was de

definitieve en succesvolle SNOM bij twee patiënten en kon na twee dagen worden gestaakt. Vijfenzestig hemodynamisch stabiele patiënten met penetrerend letsel van de nek (87%) werden succesvol behandeld zonder de noodzaak tot operatie.

**Hoofdstuk vijf** beschrijft in een prospectieve cohortstudie van 248 patiënten het succespercentage en de overleving van penetrerend thoracaal letsel. Bij 70,6% van de SNOM-patiënten was een thoraxdrain voor hematopneumothorax noodzakelijk. Penetrerend thoraxletsel bleek een laag sterftcijfer (2%) in het ziekenhuis te hebben. Bij slechts 16,5% van de patiënten was een aanvullende chirurgische behandeling naast het plaatsen van een thoraxdrain noodzakelijk. SNOM voor penetrerend thoraxletsel was veilig en succesvol bij 93,2% van de patiënten.

In **hoofdstuk zes** worden de uitkomsten van thoracotomiën voor penetrerend thoraxletsel (46 steekwonden en 10 schotwonden) in een periode van tien jaar geëvalueerd. Deze retrospectieve studie toont, dat 12 van de 56 patiënten met penetrerend thoraxletsel een thoracotomie op de Spoedeisende Hulp nodig hadden. Het overlevingspercentage was hierbij 25%. De overige 44 patiënten konden met spoed naar de operatiekamer gebracht worden voor een urgente thoracotomie in een meer gecontroleerde omgeving. Het overlevingspercentage was hierbij 75%. Hoewel dit de resultaten zijn van een centrum met een laag volume voor penetrerend letsel, zijn de uitkomsten vergelijkbaar met die van traumacentra met veel penetrerend letsel, zoals in de Verenigde Staten van Amerika en Zuid-Afrika.

De evaluatie van 33 pre-hospitale thoracotomiën voor penetrerend thoraxletsel in 5 jaar tijd is beschreven in **hoofdstuk zeven**. De thoracotomien zijn uitgevoerd door de Mobiele Medische Teams in Nederland bij tien patiënten zonder hartslag na thoracale schotwonden en bij 23 na thoracale steekwonden. In 27% van de gevallen (alle steekwonden) werden de hartslag en bloeddruk hersteld. Dit resulteerde in één overlevende zonder neurologische restschade bij ontslag uit het ziekenhuis. Deze resultaten lijken een pre-hospitale thoracotomie voor patiënten zonder hartslag na penetrerend thoraxletsel te ondersteunen. Echter, een ziekenhuissterfte van 89% na een pre-hospitale thoracotomie

en geen enkel geval van herstel van de hartslag na schotwonden, blijft een reden voor een voortdurende en kritische evaluatie van de procedure.

Een protocol voor selectief non-operatief management (SNOM) voor penetrerend abdominaal letsel werd geïntroduceerd in het Erasmus MC, ondanks het feit dat penetrerend letsel er weinig voorkomt. **Hoofdstuk acht** beschrijft een retrospectieve studie die de haalbaarheid van SNOM voor penetrerend abdominaal letsel en de uitwerking van dit protocol op patiëntenzorg. Van de 393 patiënten met penetrerend abdominaal letsel hadden 278 patiënten steekwonden. Vóór de implementatie van het protocol werd 62% middels SNOM behandeld. Nadat het protocol lokaal was ingebed bedroeg dit percentage 59%. Van de 115 schotwondpatiënten met penetrerend abdominaal letsel werd 41% voor en 30% na de introductie van het SNOM protocol behandeld. Er was geen significant verschil in het succespercentage van de behandeling van abdominale steekwonden middels SNOM met 90% vóór en 88% na introductie van het protocol. Dit gold ook voor abdominale schotwonden waarbij het succespercentage van 94% vóór versus 100% na de introductie van het protocol kon worden aangetoond. Door de introductie van het protocol verbeterde het opnamepercentage voor observatie van abdominale steekwonden van 83% tot 100%. Een significante afname in het gebruik van echografisch onderzoek van de buik bij abdominaal penetrerend letsel werd opgemerkt; van 84% tot 32% bij steekwondpatiënten en van 87% tot 43% bij de patiënten met een schotwonden. Geconcludeerd wordt dat, SNOM voor abdominaal penetrerend letsel succesvol en veilig kan worden geïmplementeerd in West-Europese traumacentra met een laag volume van penetrerende verwondingen.

In **hoofdstuk negen** worden de resultaten besproken van een prospectieve studie van penetrerend trauma aan de bovenste extremiteiten. Steekwonden veroorzaakten letsel bij 79,5% van de 161 geïnccludeerde patiënten. De resterende 20,5% werd veroorzaakt door schotwonden. SNOM was succesvol en zonder complicaties in 85% van de gevallen. Urgente chirurgische exploratie voor vermoedelijk vaatletsel was nodig bij 10% van de patiënten. Bij 5% werd het vaatletsel electief geopereerd. Geen van de verwondingen werd behandeld door de interventieradioloog. Tien

patiënten werden geopereerd voor additionele fracturen en acht patiënten in verband met zenuwletsel. In 38% van de gevallen hadden de patiënten ook penetrerende verwondingen in andere lichaamsregionen. Hoewel 85% van de patiënten met penetrerend letsel aan de bovenste extremiteiten succesvol kan worden behandeld met slechts observatie, heeft een aanzienlijk deel nog steeds een operatieve behandeling nodig in verband met vaat- en zenuwletsel en/of fracturen. Mede hierdoor moet penetrerend letsel van de bovenste extremiteiten als een ernstig letsel worden beschouwd.

Een retrospectieve studie naar de uitkomsten van de behandeling van penetrerend letsel van de bovenste en onderste extremiteiten in Nederland wordt besproken in **hoofdstuk tien**. In een periode van 10 jaar werden 668 patiënten met vermoeden op penetrerend trauma van de extremiteiten geïdentificeerd. 156 patiënten met bewezen penetrerend letsel werden opgenomen voor behandeling. Van deze patiënten (34% schotwonden en 66% steekwonden) werd 14% geopereerd onder verdenking vaatletsel. Van de 86% die in eerste instantie middels SNOM werden behandeld, had 1.5% een interventie nodig voor een (later gediagnosticeerde) vasculaire complicatie. Bij 5% van de patiënten werd zenuwletsel gemist tijdens de initiële ziekenhuisopname. Van de tien patiënten die vasculair herstel aan een onderste extremiteit ondergingen en waarbij geen (profylactische) fasciotomie werd gedaan, ontwikkelden twee (20%) een compartimentsyndroom, dat niet als zodanig werd herkend. Dit resulteerde in beide gevallen in nervus peroneus uitval. Het hoge succespercentage in deze studie rechtvaardigt SNOM voor penetrerend letsel van de extremiteiten. Het is echter essentieel om zenuwletsel en optreden van een compartimentsyndroom uit te sluiten, omdat deze gemakkelijk over het hoofd worden gezien en kunnen resulteren in langdurige invaliditeit.

In **deel Drie: Penetrerend Proza**, beschrijft in **hoofdstuk elf** een geval van een zes jaar oude jongen die penetrerend abdominaal letsel oploopt door een exploderende granaat. Tijdens de laparotomie werden talrijke Ascaris aangetroffen in de vrije buikholte. Postoperatief werd de patiënt behandeld met Mebendazol om de spoolworm uit te roeien, waarna de patiënt een mechanische

darmobstructie ontwikkelde als gevolg van een opeenhoping van dode wormen. Dit werd met succes opgelost door Erythromicine als een voortstuwingsmiddel te gebruiken. Concluderend moeten chirurgen Ascaris overwegen als een oorzaak van postoperatieve darmobstructie bij pediatrie patiënten na een (trauma-) laparotomie in ontwikkelingslanden.

**Hoofdstuk twaalf** beschrijft een geval van zelf toegebracht penetrerend thoracaal letsel met een samurai zwaard, dat conservatief werd behandeld met een thoraxdrain. De patiënt was na drie dagen goed hersteld en klaar voor ontslag. Een week na ontslag presenteerde de patiënt zich op de spoedeisende hulp met kortademigheid en pijn op de borst. Op een thoraxfoto werd een bestaande pericardiale effusie niet herkend en omdat er geen tekenen van een (hemato) pneumothorax waren, werd de patiënt ontslagen. De volgende dag werd de patiënt binnengebracht door de medische hulpdiensten die hem gecollabeerd op straat hadden gevonden. Deze keer werd de pericardeffusie wel herkend en de diagnose tamponade gesteld. Succesvol drainage door middel van een "subxyphoïdaal venster" was mogelijk. Zelfs als er geen tekenen van pericardiale effusie tijdens de initiële behandeling zijn kan er later alsnog een pericardiale tamponade ontstaan als het penetrerend letsel zich in de buurt van het hart bevindt. Echografie van het hart voorafgaand aan ontslag bij deze patiënten wordt dan ook geadviseerd om geringe effusie aan te tonen.

In **hoofdstuk dertien** wordt het letsel door een kogel beschreven die in het heupgewricht steekt nadat deze het traject had gevolgd vergelijkbaar aan de route waardoor normaal een dynamische heupschroef bij femurhalsfracturen wordt geplaatst. Enerzijds illustreert deze casus een "exotische kogeltraject", anderzijds demonstreert deze casus dat, hoewel algemeen geadviseerd wordt om kogels niet routinematig te verwijderen, kogels in een gewricht wel verwijderd moeten worden omdat ze loodvergiftiging en traumatische artritis kunnen veroorzaken.

**Hoofdstuk veertien** presenteert twee gevallen van grote traumatische weke delen letsel uit een oorlogsgebied, welke zijn behandeld met een sural-artery-perforator flap. Deze chirurgische techniek hoeft niet beperkt te blijven tot (plastisch chirurgische) centra



in een westerse wereld, maar kan juist ook succesvol toegepast worden door (trauma)chirurgen met een goede kennis en begrip van de lokale anatomie en basale middelen onder primitievere omstandigheden.

In **hoofdstuk vijftien** worden behandelingsstrategieën besproken voor drie casus met penetrerend rectaal letsel als gevolg van oorlogsgeweld. Tevens wordt een literatuuroverzicht aangaande dit onderwerp gepresenteerd. Geconcludeerd wordt dat bij "civiel" penetrerend rectaal letsel met lage energieoverdracht een deviërend colostoma als behandeling vaak afdoende is. Hoogenergetisch of ontploffingsletsel van het rectum echter, vereist een agressieve en uitgebreide chirurgisch behandeling. Gewoonlijk worden bij deze rectale letsels primair debridement en het aanleggen van een stoma in combinatie met spoelen en packing gevolgd door herhaald debridement met secundaire genezing van de wonden.

Het penetrerende prozagedeelte wordt afgesloten met **hoofdstuk zestien** waarin twee 8-jarige jongens worden beschreven die beide een penetrerend thoracaal ontploffingsletsel hebben als gevolg van blikseminslag in een nabijgelegen transformatorhuisje. Dit is het eerste gerapporteerde geval waarbij een, door blikseminslag geïnduceerde explosie, penetrerend letsel door rondvliegende scherven tot gevolg had. Dit mechanisme van blikseminslag verwonding is toegevoegd als de zevende mogelijke oorzaak voor letsel in de keraunogeneeskunde. De les die uit deze casus wordt getrokken, is dat, hoewel slachtoffers van blikseminslag een zeldzaamheid zijn en brandwonden op de voorgrond staan penetrerend letsel door rondvliegend debris bij deze patiënten moet worden uitgesloten.

Samenvattend stelt dit proefschrift dat:

- Alle chirurgen die verantwoordelijk zijn voor traumazorg horen, ongeacht het niveau van het traumacentrum waarin ze werken, bekend te zijn met de principes van damage control chirurgie. Dit, omdat een schijnbaar klein penetrerend letsel kan leiden van een stabiele, via een snel verslechterende, tot een patiënt in extremis. Penetrerend letsel door hoge energieoverdracht

vereist naast fysiologisch herstel gefaseerde en herhaalde operaties om potentiële achteruitgang in vitaliteit van weefsels die aanvankelijk nog niet zichtbaar was, alsnog te kunnen behandelen (hoofdstuk twee).

- Penetrerend hersenletsel dat wordt gepresenteerd op de spoedeisende hulp is te overleven. Dit geldt ook voor schotwonden van het hoofd met hersenweefsel a vue. Het overgrote deel kan met een redelijk goede neurologische functie het ziekenhuis verlaten. CT-scans dienen zo snel mogelijk gemaakt te worden om te beargumenteren waarom men niet zou opereren bij penetrerend hersenletsel (hoofdstuk drie).
- Selectief non-operatief management (SNOM) kan met succes worden toegepast voor penetrerend letsel van nek, thorax, abdomen en ledematen, zelfs in centra met een laag volume (hoofdstukken vier, vijf, zes, acht, negen en tien).
- De pre-hospitale thoracotomie voor patiënten zonder hartsflag na een penetrerend thoracaal letsel is gerechtvaardigd, maar continuering van de evaluatie van de uitkomst van deze procedure is noodzakelijk; enerzijds om de ingreep niet te onthouden aan patienten die er baat bij kunnen hebben, anderzijds om te voorkomen dat patienten die niet meer te redden zijn (en omstanders van de reanimatie) nodeloos blootgesteld worden aan deze groteske operatie. (hoofdstuk zeven).
- Chirurgen in ontwikkelingslanden moeten, minder voor de hand liggende oorzaken zoals, ascariasis als oorzaak van postoperatieve ileus bij pediatrie patiënten overwegen na een (trauma)laparotomie en antihelminthische therapie starten (hoofdstuk elf).
- Een late cardiale tamponade kan zich ontwikkelen bij penetrerend letsel nabij het hart. Echografie voordat de patiënt het ziekenhuis verlaat, wordt geadviseerd (hoofdstuk twaalf).
- Kogels die in een gewricht zitten moeten worden verwijderd om loodvergiftiging en traumatische artritis te voorkomen (hoofdstuk dertien).
- Sural-artery-perforator flaps kunnen worden gebruikt om weke delen letsel van het onderbeen te bedekken. Deze techniek is ook mogelijk door (niet-plastische) chirurgen met een goed begrip van de lokale anatomie en basale middelen (hoofdstuk veertien).

- Hoge energieoverdracht- of ontploffingsletsel van het rectum vereist een agressieve chirurgisch behandeling. In de primaire fase zijn debridement, spoelen, packing en een deviërend colostoma vereist, gevolgd door herhaald re-debridement met secundaire genezing van de wonden (hoofdstuk vijftien).
- Bij slachtoffers van blikseminslag moet penetrerend letsel door rondvliegend debris worden uitgesloten (hoofdstuk zestien).



# Chapter Nineteen

# GENERAL DISCUSSION

## Implications and future perspective

Trauma care is a non "office hours" surgical specialty and this is especially true for the severely injured patient. Consequently, the trauma care providers are often "understaffed" in person and experience when these patients are presented to the emergency department, resulting in a higher mortality rate during these hours (1-2). This predicament becomes worse when the patient is in "extremis" and requires damage control surgery (DCS) instead of early total care surgery (3). Chapter two of this thesis provides some treatment options for patients with penetrating injury in need of damage control. Our preliminary research data reflected that, 7% of all patients with penetrating abdominal injury will undergo DCS, 57% receive early total care surgery and the remaining 36% can be treated with selective non-operative management (SNOM). Multiple studies have however reported data implying over-utilization of DCS (4,5) which is related to complications such as multiple organ failure, sepsis, bowel ischemia (6) and prolonged ICU and hospital stay (5,7,8).

In the Netherlands the number of (PI) DCS cases, and whether DCS is over- or underutilized, is unknown. It is assumed that the incidence is of PI increases, also during the coming years in the Netherlands. The possession of (illegal) gunshot weapons in criminal circuits might attribute to that growth. Prospective research (on a national level) will render information regarding the outcome of DCS performed by trauma surgeons in the Netherlands.

The data used for this thesis on SNOM feasibility of penetrating injury is derived from local data from the Erasmus MC Level I Trauma Center (Rotterdam) and a Level I Trauma Center in Cape Town (Groote Schuur Hospitaal). In spite of being a relatively low volume Trauma Center for PI in comparison to the Trauma Center in Cape Town, our Level I Trauma Center receives nearly twice the number of patients suffering from PI with an Injury Severity Score (ISS) of 16 and over compared to other Trauma Centers participating in the trauma registry of the Deutsche Gesellschaft für Unfallchirurgie (TraumaRegisterDGU®) (9). The exact number of patients suffering from PI receiving care in

other Trauma Centers in the Netherlands is not known. This is in part due to the different interpretation, on the definition of a penetrating injury, by the data managers of the specific Trauma Centers. After consensus on the definition of penetrating injury in the future, data may be compared and our local protocols for PI adjusted (if needed) to meet the demands of all Dutch Trauma Centers.

The research in this thesis has led to several body region specific protocols, concerning diagnostic, damage control and definitive treatment. A widespread implementation of these protocols is a first priority, especially in a country with low incidence of PI. Ideally, they should be implemented in an international setting, governed by an independent board. Re-evaluation of these protocols by new clinical research is another priority to fine tune them. A proper antegrade registration of outcome of the healthcare provided to victims of PI, is important to improve reliability of conclusions of such re-evaluations. Also technical diagnostic and therapeutic innovations should be implemented in future protocols. Only then the feedback loop is closed and healthcare provided to victims of PI will improve and concomitant costs reduce.

Trauma surgery will be a predominant field of surgery in the future with trauma advancing into the top ten of the WHO (World Health Organization) causes of death list within the next 10 to 15 years. Mortality from trauma is responsible for 5.8 million deaths yearly, accounting for 10% of the world's deaths (10). Trauma, especially high energy transferring, is a "disease" not limited to specific organs or body regions. Surgeons of the future however are stimulated to differentiate into "organ specialist" surgeons early in their training (11,12). Even fracture care surgery is currently dividing into upper and lower extremity specialists. Thoracic and neurosurgeons are usually trained in surgical treatment of diseases of their organs of interest, but not in trauma. Without a trauma surgical team leader who will manage, and for the larger part perform the surgical treatment of all injuries, a detrimental outcome is likely (13). Dutch military surgeons are trained to perform DCS and primary care regardless the injury type or affected organs (14,15). To maintain

this expertise, future military surgeons should be schooled in the (primary) treatment of all (penetrating) injuries from "head to toe". This theoretical training should be put into practice during their deployments and maintained by repetitive fellowships in high volume trauma centers globally. The effect of this training should be evaluated by prospective research during their fellowships, deployments and patient care in their affiliated Trauma Center. Comparative training and practice may also benefit civilian trauma surgeons and their patients.

All these efforts need to be funded. Lack of proper funding is a major problem in trauma research. This can only be achieved by creating an awareness of the threat trauma presents to global health and subsequent translation into regional, national and local needs for specific populations. Subsequent national and international collaboration between trauma centers with similar needs will benefit the quality and impact of research enormously. More public fear for the devastating consequences of (penetrating) trauma will help.

Dixit.

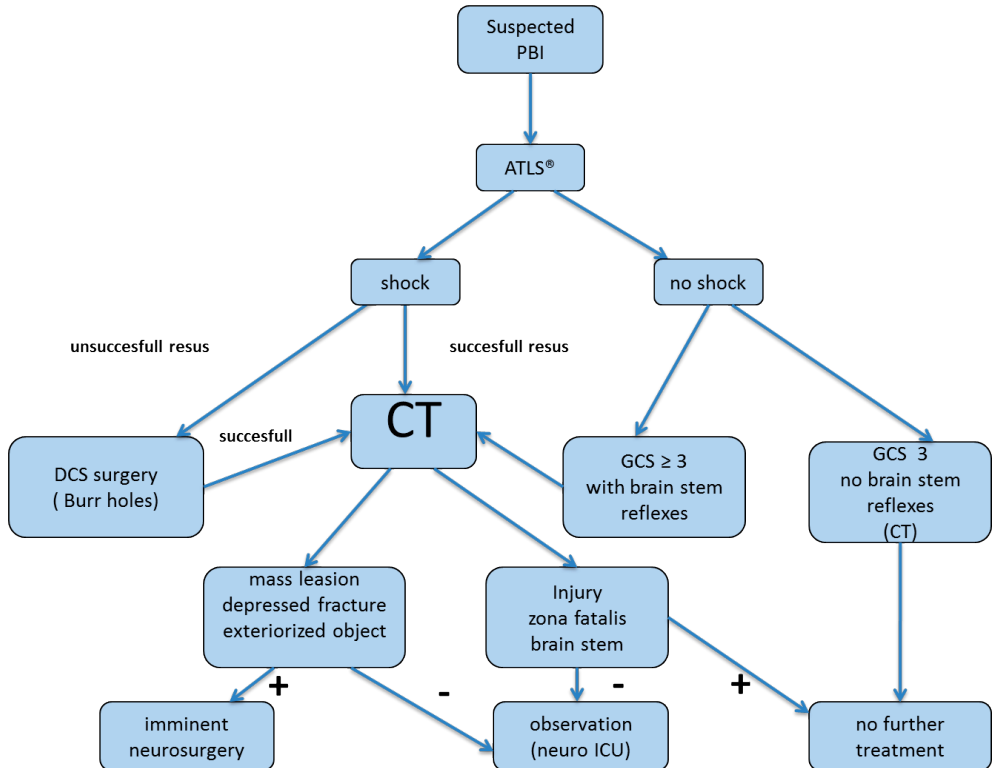


## REFERENCES

1. Kieffer WKM, Michalik DV, Gallagher K, McFadyen I, Bernard J, Rogers BA. Temporal variation in major trauma admissions. *Ann R Coll Surg Engl* 2016;98:128-137
2. Egol KA, Tolisano AM, Spratt KF, Koval KJ. Mortality rates following trauma: The difference is night and day. *J Emerg Trauma Shock* 2011;4:178-83
3. Mitra B, Cameron PA, Fitzgerald MCB, Bernard S, Moloney J, Varma D, Tran H, Keogh M. "After-hours" staffing of trauma centres and outcomes among patients presenting with acute traumatic coagulopathy. *MJA* 2014;201:588-91
4. Hatch QM, Osterhout LM, Podbielski J, Kozar RA, Wade CE, Holcomb JB, et al. Impact of closure at the first take back: complication burden and potential overutilization of damage control laparotomy. *J Trauma*. 2011;71(6):1503-11.
5. Martin MJ, Hatch Q, Cotton B, Holcomb J. The use of temporary abdominal closure in low-risk trauma patients: helpful or harmful? *J Trauma Acute Care Surg*. 2012;72(3):601-6; discussion 6-8.
6. Roberts DJ, Zygun DA, Kirkpatrick AW, Ball CG, Faris PD, Bobrovitz N, et al. A protocol for a scoping and qualitative study to identify and evaluate indications for damage control surgery and damage control interventions in civilian trauma patients. *BMJ Open*. 2014;4(7):e005634.
7. Cirocchi R, Abraha I, Montedori A, Farinella E, Bonacini I, Tagliabue L, et al. Damage control surgery for abdominal trauma. *Cochrane Database Syst Rev*. 2010(1):CD007438.
8. Shapiro MB, Jenkins DH, Schwab CW, Rotondo MF. Damage control: collective review. *J Trauma*. 2000;49(5):969-78.
9. [http://www.traumaregister-dgu.de/fileadmin/user\\_upload/traumaregister-dgu.de/docs/Downloads/TR-DGU\\_Annual\\_Report\\_2016.pdf](http://www.traumaregister-dgu.de/fileadmin/user_upload/traumaregister-dgu.de/docs/Downloads/TR-DGU_Annual_Report_2016.pdf)
10. [http://apps.who.int/iris/bitstream/10665/44288/1/9789241599375\\_eng.pdf](http://apps.who.int/iris/bitstream/10665/44288/1/9789241599375_eng.pdf)
11. Longo WE, Sumpio B, Duffy A, Seashore J, Udelsman R. Early specialization in surgery: the new frontier. *Yale J Biol Med* 2008;81:187-91
12. Ferguson CM. The arguments against fellowship training and early specialization in general surgery. *Arch Surg* 2003;138:915-6
13. Courtenay M, nancarrow S, dawson D. Interprofessional teamwork in the trauma setting: a scoping review. *Hum Resour Health* 2013; 11:57
14. Van Dongen TT, Idenburg FJ, Tan EC, Rasmussen TE, Hamming JF, Leenen LP, Hoencamp R. Combat related vascular injuries: Dutch experience from a role 2 MTF in Afghanistan. *Injury* 2016;47:94-8
15. Hoencamp R, Idenburg FJ, Hamming JF, Tan EC. Incidence and epidemiology of casualties treated at the Dutch role 2 enhanced medical treatment facility at multi national base Tarin Kowt, Afghanistan in the period 2006-2010. *World J Surg* 2014;38:13-8

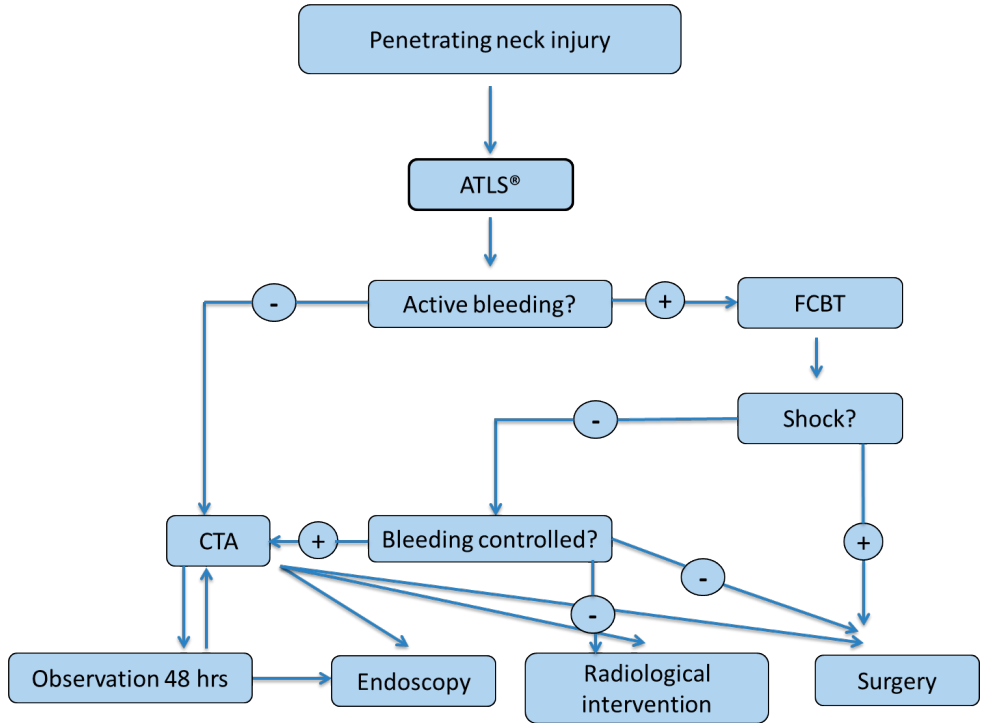
# APPENDICES

Flowchart Penetrating Brain Injury



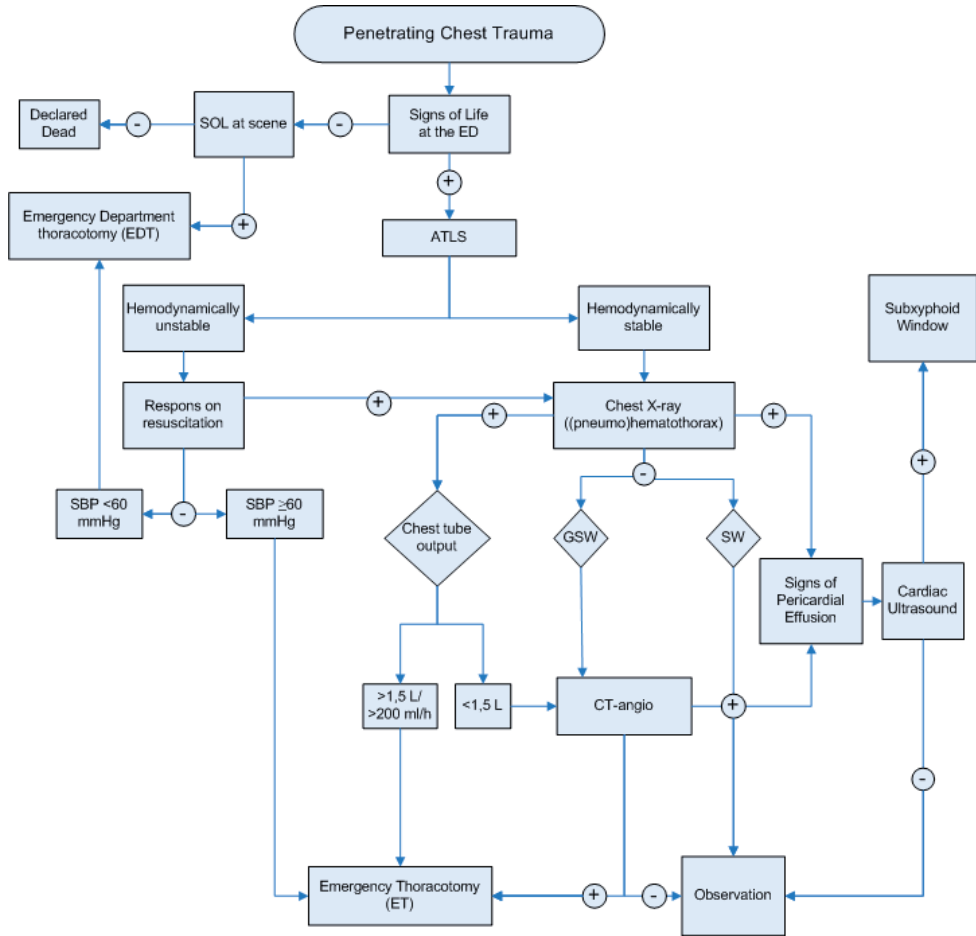
Penetrating brain injury (PBI), advanced trauma life support (ATLS®), computed tomography scan (CT), damage control surgery (DCS), Glasgow coma score (GCS), resuscitation (resus), intensive care unit (ICU).

Flowchart Penetrating Neck Injury



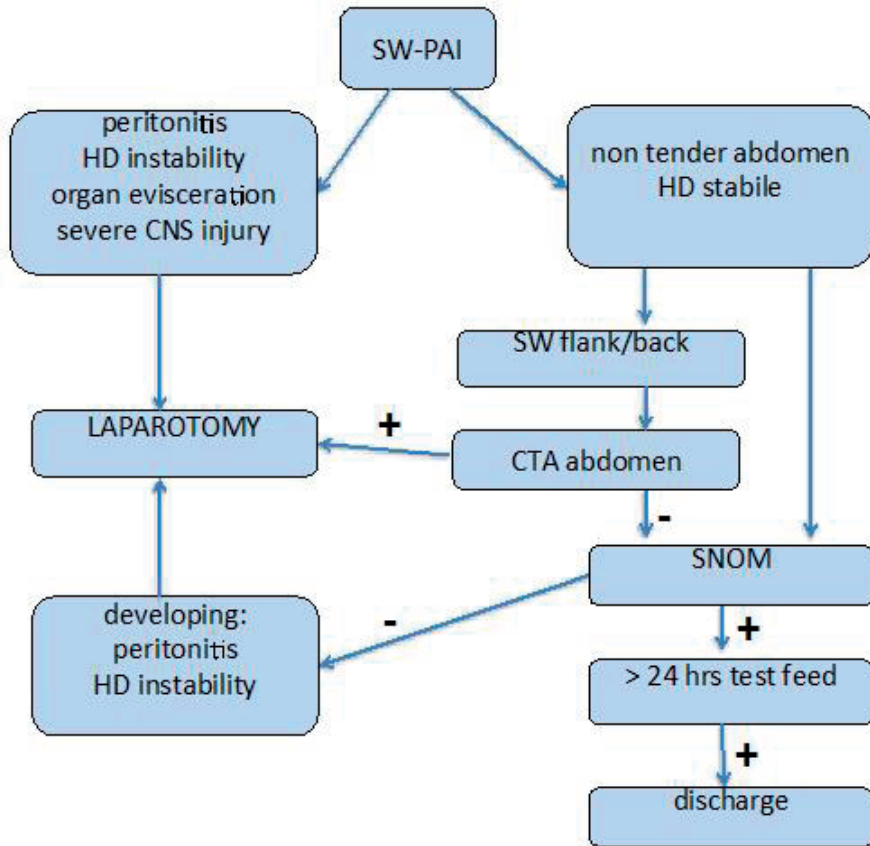
Advanced trauma live support (ATLS®), Foley catheter balloon tamponade (FCBT), computed tomography angiography (CTA)

Flowchart Penetrating Thoracic Injury



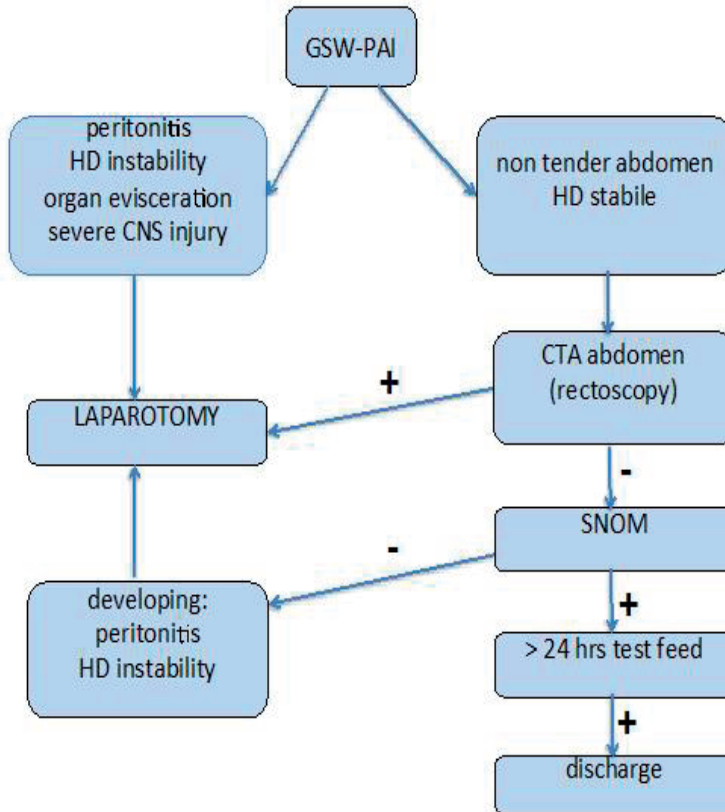
Signs of life (SOL), emergency department (ED), advanced trauma life support (ATLS®), systolic blood pressure (SBP), gunshot wound (GSW), stab wound (SW), computed tomography (CT)

Flowchart Penetrating Abdominal Injury (stab wounds)



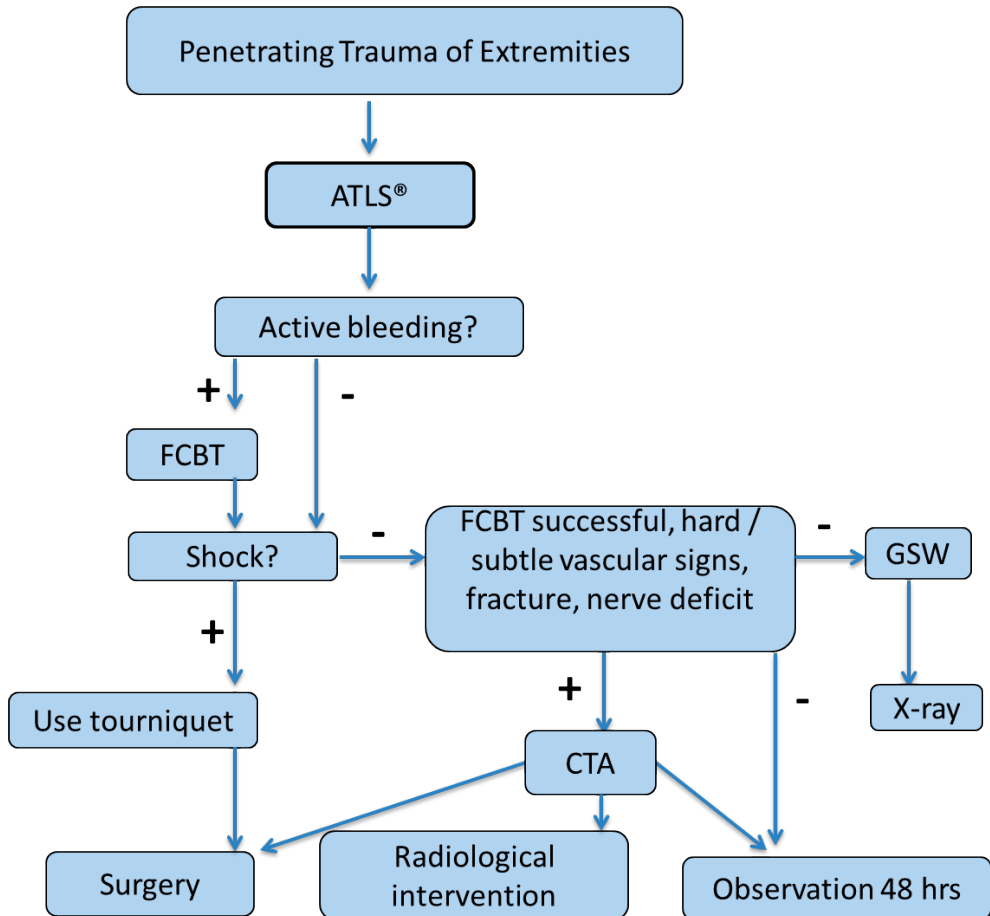
Penetrating abdominal injury due to stab wounds (SW-PAI), hemodynamic (HD), central nervous system (CNS), stab wound (SW), computed tomography angiogram (CTA), selective non-operative management (SNOM).

Flowchart Penetrating Abdominal Injury (gunshot wounds)



Penetrating abdominal injury due to gunshot wounds (GSW-PAI), hemodynamic (HD), central nervous system (CNS), gunshot wound (GSW), computed tomography angiogram (CTA), selective non-operative management (SNOM).

Flowchart Penetrating Trauma of Extremities



Advanced Trauma Life Support (ATLS®), computed tomography angiogram (CTA), Foley Catheter Balloon Tamponade (FCBT), gunshot wound (GSW)

## LIST OF PUBLICATIONS IN THIS THESIS

**van Waes OJF**, van der Elst M. Dynamic Hip Slug (DHS)? TVTR (2008) 16: 15.

**van Waes OJF**, Morak MJM. Afghaans "Wild Life". Ned Tijdsch Heelk 2011;20(5):191-2  
190 nederlands tijdschrift voor heelkunde - jaargang 20 - nummer 5 - juni 2011

**van Waes OJF**, Cheriex KCAL, Navsaria PH, van Riet PA, Nicol AJ, Vermeulen J. Management of penetrating neck injuries. Br J Surg 2012;(99) Suppl 1;149-54

Huis in't Veld MA, Halm JA, **van Waes OJF**. Een late pericardiale tamponnade na penetrerend thoraxletsel. tijd. Traumatologie (2012) 20: 149.

**van Waes OJF**, van Riet PA, van Lieshout EMM, den Hartog D. Immediate thoracotomy for penetrating injuries: ten years' experience at a Dutch level I trauma center. Eur J Trauma Emerg Surg 2012;38(5):543-51

**van Waes OJF**, van Lieshout EMM, Hogendoorn W, Halm JA, Vermeulen J. Treatment of penetrating trauma of the extremities: ten years' experience at a Dutch level 1 trauma center. Scand J Trauma Resusc Emerg Med 2013;14;21:2

**van Waes OJF**, Navsaria PH, Verschuren RCm, Vroon LC, van Lieshout EMM, Halm JA, Nicol AJ, Vermeulen J. Management of penetrating injuries of the upper extremities. Ulus Travma Acil Cerrahi Derg 2013;19(5):405-10

**van Waes OJF**, Halm JA, Vermeulen J, Ashford BG. "The Practical Perforator Flap": the sural artery flap for lower extremity soft tissue reconstruction in wounds of war. Eur J Orthop Surg Traumatol 2013;23Suppl 2:S285-9



**van Waes OJF**, van de Woestijne PC, Halm JA. "Thunderstruck": penetrating thoracic injury from lightning. *Ann Emerg Med* 2014;63(4):457-9

**van Waes OJF**, Halm JA, Vermeulen J, McAlister. Treatment of rectal war wounds. *J R Army Med Corps* 2014;160(3):255-7

**van Waes OJF**, Verhofstad MHJ. (2017) Penetrating Injuries and Damage Control Surgery: Considerations and Treatment Options. In: Pape HC, Peitzman A, Rotondo M, Giannoudis P (eds) *Damage Control Management in the Polytrauma Patient*. Springer, Cham

---

271

Van Vledder MG, **van Waes OJF**, Kooij F, Peters JH, van Lieshout EMM, Verhofstad MHJ. Out of hospital thoracotomy for cardiac arrest after penetrating thoracic trauma. *Injury* 2017;48(9):1865-9

**van Waes OJF**, Halm JA, Van Imhoff DI, Navsaria PH, Nicol AJ, Verhofstad MHJ, Vermeulen J. Selective nonoperative management of penetrating thoracic injury. *Eur J emerg Med* 2018;25(1):32-8

**van Waes OJF**, Van Lieshout EMM, Van Silfhout DJ, Halm JA, Wijffels MME, Van Vledder MG, Van Leur-de Graaff HP, Verhofstad MHJ. Outcome after introduction of a selective non-operative management protocol for penetrating abdominal injury in a Dutch level 1 trauma center. Accepted by *Ann R Coll Surg Engl*.

**van Waes OJF**, Reinders Folmer EI, Visser 't Hooft ME, Van Lieshout EMM, Navsaria PH, Schouten JW, Nicol AJ, Verhofstad MHJ. Penetrating brain injury; a prospective observational study. Submitted.

## OTHER PUBLICATIONS

**van Waes OJF**, van der Elst M, Stassen L, Tjebbes F. Laparoscopic diagnosis and treatment of idiopathic segmental infarction of the greater omentum. Case report. *Surg Endosc*. 2001;15(10):1226.

Coulthard P, Worthington H, Esposito M, Elst M, **Waes OJF**. Tissue adhesives for closure of surgical incisions. *Cochrane Database Syst Rev*. 2004;(2):CD004287

**van Waes OJF**, Jaquet JB, Hop WC, Morak MJ, IJzermans JM, Koning J. A Single-Lumen Central Venous Catheter for Continuous and Direct Intra-abdominal Pressure Measurement. *Eur J Trauma Emerg Surg*. 2009;35(6):532-7

van Ramshorst GH, Salih M, Hop WC, **van Waes OJF**, Kleinrensink GJ, Goossens RH, Lange JF. Noninvasive assessment of intra-abdominal pressure by measurement of abdominal wall tension. *J Surg Res*. 2011;171(1):240-4

Coulthard P, Esposito M, Worthington HV, van der Elst M, **van Waes OJF**, Darcey J. Tissue adhesives for closure of surgical incisions. *Cochrane Database Syst Rev*. 2014;11:CD004287.

Strang SG, Van Lieshout EMM, Breederveld RS, **van Waes OJF**. A systematic review on intra-abdominal pressure in severely burned patients. *Burns*. 2014;40(1):9-16.

Strang SG, Van Imhoff DL, Van Lieshout EM, D'Amours SK, **van Waes OJF**. Identifying patients at risk for high-grade intra-abdominal hypertension following trauma laparotomy. *Injury*. 2015;46(5):843-4

Strang SG, **van Waes OJF**, Van der Hoven B, Ali S, Verhofstad MHJ, Pickkers P, Van Lieshout EMM. Intestinal fatty acid binding protein as a marker for intra-abdominal pressure-related complications in patients admitted to the intensive care unit; study protocol for a prospective cohort study (I-Fabulous study). Scand J Trauma Resusc Emerg Med. 2015;16(23):6

Strang SG, Van Lieshout EMM, **van Waes OJF**, Verhofstad MHJ. Prevalence and mortality of abdominal compartment syndrome in severely injured patients: A systematic review. J Trauma Acute Care Surg. 2016;81(3):585-92

Strang SG, Van Lieshout EMM, Verhoeven RA, **van Waes OJF**, Verhofstad MHJ, IAH-ACS Study Group. Recognition and management of intra-abdominal hypertension and abdominal compartment syndrome; a survey among Dutch surgeons. Eur J Trauma Emerg Surg. 2017;43(1):85-98

## ACKNOWLEDGEMENTS

First and foremost my gratitude is to my wife, son and daughter for granting me my "me time" for my biggest hobby: trauma surgery. Your earnest interest in my work, research projects and (bloody) lectures and your down to earth criticism makes this shared joy even better. Praise to my parents (former Professor in radiology and nurse) for subconsciously steering my planned career as a professional windsurfer, to medical university. I am grateful to all (inter)national trauma care providers from the (H)EMS, emergency departments, operating theaters, ICU's, surgical wards and battlefield hospitals, whom I have worked with and am still working with, in trying to improve the best treatment for the wounded.

I'm in debt to the trauma patients treated by me, in making me a better trauma surgeon case by case and to those consenting to contribute their data for research purposes. Thanks for epidemiological support of both Dr. van Lieshout and Vermeulen who magically transform raw data into tables and figures that I can comprehend. Credits to Dr. Halm who helped me prepare my contemplations and research data into readable articles "au sous vide".

Thanks to the ladies (Els, Monique and Sophie) from the management support staff of the Erasmus MC department of Surgery for helping me combine the separate articles into one thesis. Gratitude to amice and head of Trauma Surgery Michael Verhofstad for facilitating my appearance in the international trauma surgical arena to defend my opinions.

Last but not least "gratiarum actio" to my fellow brothers of the Rotterdam Knife and Gun Club for keeping me sharp and make me hit the mark.



# PHD PORTFOLIO

## Summary of PhD training and teaching activities

Name PhD student: Oscar JF van Waes	PhD period: 2012-present
Erasmus MC Department: Trauma Surgery	Promotor(s): Prof. Dr. M.H.J. Verhofstad
Research School: Erasmus MC	Supervisor: Dr. J. Vermeulen Dr. E.M.M van Lieshout

### 1. PhD training

	Year	Workload (ECTS)
General academic skills		
Research skills		
In-depth courses (e.g. Research school, Medical Training)		
Basic Endovascular Skills for Trauma (Baltimore, USA)	2016	1.0
<b>Presentations</b>		
NVSHV congres (oral presentation)	2012	1.0
Traumaquiz Nationaal coassistenten congress (oral presentation)	2015, 2017	2.0
ZWOT (oral presentation)	2016	1.0
SEHADRZ spoedeisende hulp congress (oral presentation)	2017	1.0
<b>International conferences and symposia</b>		
ESTES Basel (oral presentation)	2012	1.0
ESTES Frankfurt (oral presentation)	2014	1.0
ESTES Amsterdam (oral presentation)	2015	1.0
DGCH München (oral presentation)	2017	1.0
<b>Seminars and workshops</b>		
VATS course (Dept. Thoracic surgery EMCR, Rotterdam)	2018	1.0
Didactic skills		
Other		
<b>2. Teaching activities</b>		
	Year	Workload (Hours/ECTS)

---

**Lecturing**

Lecturing for Medical Students Minerva	2012	1.0
Lecturing surgical registrars: Protocols on penetrating injury	2012-2018	6.0
"Clamshell" course HEMS crew	2012-2017	5.0
"Life Saving Skill" course Military medical Personal	2012-2027	5.0
Faculty DSATC Nijmegen	2012-2016	4.0
Course Director DSATC Nijmegen	2017	2.0
Faculty BATLS®	2013, 2016	2.0
CASH Cursus 2.1 - Traumachirurgie	2015, 2017	2.0

**Supervising Master's theses (8 students)**

Diederik van Imhoff	2012	2.0
Michèle Visser	2013	2.0
Eline Reinders Folmer	2013	2.0
Justin Scheffers	2014	2.0
Bart van Tunen	2014	2.0
Huub de Jonge	2016	2.0
Frank van Roon	2016	2.0
Arthur Bijleveld	2017	2.0

**Other**

Total		54.0
-------	--	------

---

## CURRICULUM VITAE

Oscar van Waes finished his medical training with a degree from the University of Utrecht in 2000. During medical school his interest in trauma surgery was strengthened through several trauma surgical electives at renowned international trauma centers in Seattle, Budapest and Innsbruck. After his surgical training he worked as a fellow at the Trauma Unit of the Groote Schuur Hospital, Cape Town, South Africa. Since 2008 he is a trauma surgeon at the department of surgery of the Erasmus MC University Medical Center Rotterdam and a military surgeon in the Dutch armed forces. He has been deployed on several missions to Afghanistan, the Somali basin and Iraq. The experiences gained both in South Africa and combat zones induced a special interest in treatment of patients with penetrating injuries and eventually led to the writing of this thesis. Besides his activities in trauma care and research, he is engaged in teaching students, surgical residents, emergency room and military medical personnel. Since 2017 he is a course director of the Definitive Surgical and Anaesthetic Trauma Care Course (DSTC-DATC).

Besides surgery he enjoys skiing and life as a waterman (wind/SUP surfing, sailing and scuba diving), but above all his wife Daisy and his two children Caesar and Quirine (and dog Dexter).





