

**CRANIOSYNOSTOSIS:  
CLINICAL AND FUNDAMENTAL ASPECTS**

**CRANIOSYNOSTOSE:  
KLINISCHE EN FUNDAMENTELE ASPEKTEN**

**PROEFSCHRIFT**

**TER VERKRIJGING VAN DE GRAAD VAN DOCTOR AAN DE  
ERASMUS UNIVERSITEIT ROTTERDAM OP GEZAG VAN DE  
RECTOR MAGNIFICUS  
PROF.DR.IR. J.H. VAN BEMMEL**

**EN VOLGENS BESLUIT VAN HET COLLEGE VOOR  
PROMOTIES  
DE OPENBARE VERDEDIGING ZAL PLAATSVINDEN OP  
WOENSDAG 25 OKTOBER 2000 OM 9.45 UUR  
DOOR**

**IRENE MARGREET JACQUELINE MATHIJSSSEN  
GEBOREN TE BREDA**

PROMOTIECOMMISSIE

PROMOTOR: PROF.DR. S.E.R. HOVIUS  
OVERIGE LEDEN: PROF.DR. B.A. OOSTRA  
PROF.DR. D. TIBBOEL  
PROF.DR. A.O.M. WILKIE  
COPROMOTOR: DR. CHR. VERMEIJ-KEERS

This study has been financially supported by an AGIKO grant from NWO (AGI 920.03.011, 1996) and a grant from “Het Van Leersumfonds” from KNAW (5510702, 1998).

Additional sponsoring by Esser Stichting, Inamedical, Mediprof, Nederlandse Vereniging voor Plastische Chirurgie, Stöpler, and Carl Zeiss B.V.

Printed by Wyt Document Services, Rotterdam.

ISBN 90-76580-06-5.

All rights reserved. This book is protected by copyright. No part of this book may be reproduced in any form or by any means, including photocopying, or utilized by any information storage and retrieval system without written permission from the copyright owner.

# CONTENTS

	<b>page</b>
<b>I. Introduction</b>	<b>5</b>
I.1. Historical and clinical perspectives on craniosynostosis	5
Definition, classification, and incidence	5
Diagnosis and treatment	13
Literature overview on pathogenesis	17
I.2. Genetic background of syndromic craniosynostosis	21
Genes and craniosynostosis	21
FGFR1 mutations	24
FGFR2 mutations	25
FGFR3 mutations	29
TWIST mutations	31
Expression and function of FGFRs and TWIST during skull development	41
I.3. Aim of this study	45
<b>II. Morphologic study of the human calvaria in craniosynostosis</b>	<b>65</b>
II.1. The role of bone centers in the pathogenesis of craniosynostosis: An embryologic approach using CT measurements in isolated craniosynostosis and Apert and Crouzon syndromes.	67

II.2.	Tracing craniosynostosis to its developmental stage through bone center displacement.	79
<b>III.</b>	<b>Histologic study of the developing murine coronal suture: Normal and abnormal</b>	<b>89</b>
III.1.	Apoptotic cell death during normal embryogenesis of the coronal suture: Early detection of apoptosis in mice using Annexin V.	91
III.2.	Simultaneous induction of apoptosis, collagen type I expression and mineralization in the developing coronal suture following FGF4 and FGF2 application.	99
<b>IV.</b>	<b>FGFR-mutations and their phenotypes</b>	<b>129</b>
IV.1.	Pfeiffer syndrome resulting from a Ser351Cys mutation in the fibroblast growth factor receptor-2 gene.	131
IV.2.	Additional phenotypic features of the FGFR3 Pro250Arg mutation in two Dutch families.	137
<b>V.</b>	<b>General discussion</b>	<b>157</b>
<b>VI.</b>	<b>Summary</b>	<b>173</b>
<b>VII.</b>	<b>Samenvatting</b>	<b>177</b>

<b>Publications used in this thesis</b>	183
<b>Publications related to this thesis</b>	185
<b>Other publications</b>	187
<b>Curriculum vitae</b>	188



## I. INTRODUCTION

Prior to the discovery of the genetic background of craniosynostosis, its classification was purely based on clinical features. This classification system did however have its pitfalls which became more obvious after comparing it with the detected genetic mutations. Because this classification has been the basis for clinical practice for years and still is applied world wide, this chapter will begin by giving a historical and clinical view on craniosynostosis before discussing the genetic aspects.

### I.1. Historical and clinical perspectives on craniosynostosis

#### *Definition, classification, and incidence*

Craniosynostosis is generally defined as the premature (pre- or postnatally) closure of one or more cranial suture(s). This condition can arise primarily as a congenital malformation, and secondary to certain metabolic disorders (e.g., hyperthyroidism, rickets, and mucopolysaccharidoses), hematological disorders (e.g., thalassemia, sickle cell anemia, and polycythemia vera), holoprosencephaly, and microcephaly, or have iatrogenic origin such as following ventricular shunting. The focus of this thesis is on congenital craniosynostosis.

Figure 1a depicts the cranial sutures. The sutures are the sites at which the skull can expand to accommodate itself to the enlarging brain. Growth takes place in the direction perpendicular to the suture. For example, the coronal sutures allow the skull to grow in the

anteroposterior direction, while the sagittal suture offers the potential to expand in the bilateral direction. Most volume expansion of the skull occurs in utero and within the first two years of life, although most sutures do not ossify before adulthood. Ossification of the coronal suture, for instance, starts at about 24 years of age (Kokich, 1986).

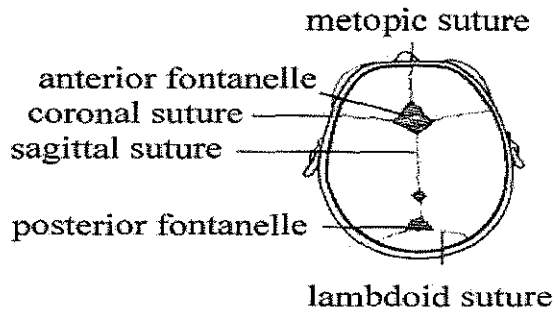


Figure 1a. The cranial sutures as seen from a birds' eye view.

Premature closure of a suture will cause the cessation of growth within the associated direction. Subsequently, compensatory growth is observed in the remaining sutures. If the coronal sutures were to be synostotic, insufficient growth in the anteroposterior direction would occur and additional growth takes place at the non-affected sutures, thus resulting in a broad skull with reduced anteroposterior dimensions. Figure 1b illustrates the associated skull configurations for each synostotic suture and the commonly applied nomenclature.



Although the lambdoid sutures can be synostotic too, this is a very rare condition (Huang et al., 1996). Most patients presenting with a flattened occiput do not suffer from craniosynostosis. This dysmorphology appears to be induced by the commonly advised supine position for neonates to sleep in, and seems to reflect a molding effect rather than an intrinsic abnormality of the lambdoid suture. The most severe skull deformity in syndromic craniosynostosis is the cloverleaf skull, referring to the image seen on X-ray (fig. 1c). This is often a life-threatening condition due to respiratory failure. In most cases, all cranial suture have fused.

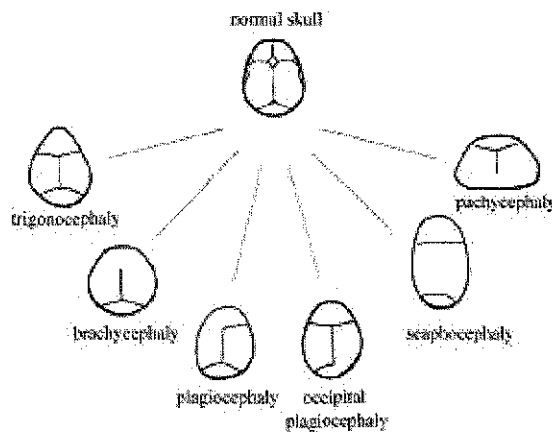


Figure 1b. The associated skull configurations resulting from specific synostotic sutures and the commonly applied nomenclature.

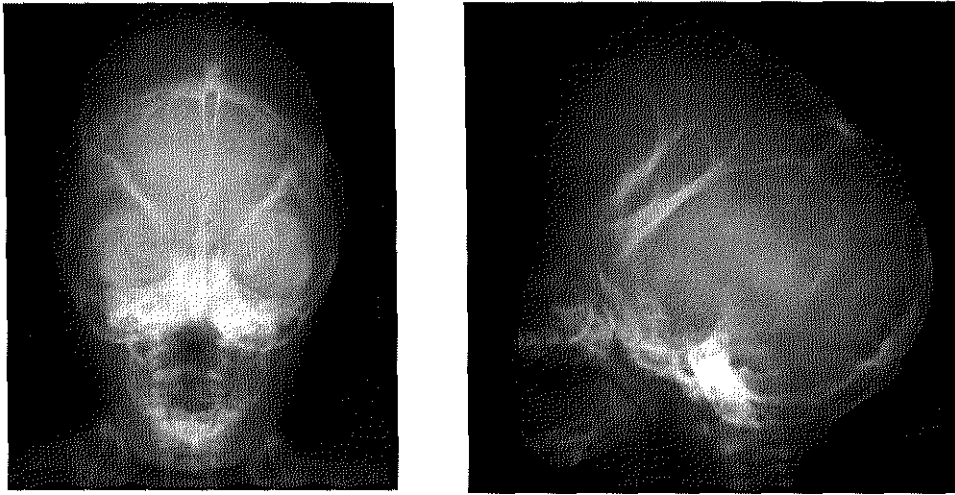


Figure 1c. X-ray of a patient with a cloverleaf skull. In anteroposterior direction the skull has the shape of the three leaves of a clover, formed by the bulging temporal bones bilaterally. The lateral view shows impressioes digitatae, suggestive of increased intracranial pressure.

One of the major distinctions that is made in craniosynostosis is whether or not this anomaly arises solitarily, i.e. isolated, or combined with other congenital malformations, constituting a craniosynostosis syndrome. Sagittal suture synostosis or scaphocephaly represents the most common isolated form of craniosynostosis with a male: female ratio of 3.5:1, showing the male predominance (Lajeunie et al., 1996). Very rarely, familial cases with 2 or more affected scaphocephalic members occur (Hunter and Rudd, 1976; Berant and Berant, 1973; Lajeunie et al., 1996). In 1996, a new designated autosomal dominant craniosynostosis syndrome was suggested, being the Philadelphia

type, which is characterized by sagittal synostosis and soft tissue syndactyly of the fingers and toes (Robin et al., 1996).

Isolated synostosis of either the metopic suture, i.e., trigonocephaly, or one or both coronal sutures, i.e., plagiocephaly or brachycephaly respectively, does occur but one needs to rule out an underlying syndrome (chapter I.2). Analysis of a series of 237 patients with trigonocephaly resulted in 184 cases with an isolated synostosis and 53 cases with a syndromic form (Lajeunie et al., 1998). Of these 53, 13 concerned well-delineated syndromes, while the remaining 40 couldn't be assigned to any of the known syndromes. As with isolated sagittal suture synostosis, an increased incidence of twinning (7.8 %, both monozygotic and dizygotic) was observed, up to about three times higher compared to the normal population (Lajeunie et al., 1998). Of the monozygotic twins two were concordant and three were discordant for synostosis.

In craniosynostosis syndromes, the coronal sutures are usually affected and the most commonly associated malformations involve the upper and lower extremities. Limb abnormalities can be as subtle as unusually shaped phalangeal bones without any functional impairment but can also be as severe as complex syndactyly, involving bone, nails, and soft tissue fusion, of all fingers and toes.

A large number of craniosynostosis syndromes have been depicted (Cohen, 1986), with their nomenclature often referring to the authors who were first to describe them. Here, a short overview is given of the common syndromes.

Apert syndrome has the most consistent presentation and was initially reported as acrocephalosyndactyly by Apert in 1906. The following hallmarks are nearly always present: bilateral coronal suture synostosis, a wide open gap between the frontal bones instead of the frontal suture at birth, exorbitism, strabismus, midfacial hypoplasia, joint ankylosis, and symmetrical, complex syndactyly of the hands and feet (Cohen and Kreiborg, 1993a; Cohen and Kreiborg, 1995). Mental retardation is a common finding.

First described by Crouzon in 1912, the Crouzon syndrome is characterized by craniosynostosis, although not always present at birth, in which eventually all calvarial sutures can be involved (pansynostosis), midfacial hypoplasia, exorbitism, epilepsy, and seemingly unaffected limbs. Its diagnosis is mainly founded on the absence of overt deformities of the hands and feet. Recently, however, subtle radiographic abnormalities like carpal fusion have been found in patients with Crouzon syndrome (Anderson et al., 1997; Murdoch-Kinch and Ward, 1997).

Both H. Saethre (1931) and F. Chotzen (1932) have established the Saethre-Chotzen syndrome. Typical characteristics are considered to be bilateral coronal synostosis, hypertelorism, unilateral or bilateral ptosis of the eyelids, low-set hairline, hearing loss, brachydactyly, and soft tissue syndactyly.

R.A. Pfeiffer depicted another type of craniosynostosis in 1964, although he referred to this condition as a weak form of Apert acrocephalosyndactyly. Clinical presentation of this syndrome

involves besides bicoronal synostosis broad and deviated thumbs and halluces, and hypertelorism (Cohen, 1993b).

The description of Jackson-Weiss syndrome was based on one extremely large Amish family (Jackson et al., 1976). This syndrome was considered to be different from the classical Pfeiffer syndrome because evident thumb abnormalities were lacking. The phenotypic presentation ranged from just radiological abnormalities of the feet to craniosynostosis, hypertelorism, exorbitism, midface hypoplasia, and deviated great toes with deformed proximal phalanges and first metatarsals. This was the first report presenting an impressive number of patients with at least 88 affected siblings and possibly another 50. The autosomal dominant inheritance pattern was clearly outlined in this family, showing variable expression. The authors stated that individual evaluation of some of these family members could result in either the diagnoses Pfeiffer or Crouzon syndrome. Because distinction between Jackson-Weiss and these syndromes is so difficult, the value of the Jackson-Weiss entity, besides for the original family members, is under increasing doubt (Reardon and Winter, 1995).

Beare-Stevenson syndrome is much more rare and characterized by severe craniosynostosis (mostly a cloverleaf skull), cutis gyrata and acanthosis nigricans, digital anomalies, external ear defects, anogenital anomalies, skin tags, prominent umbilical stump, and early death (Beare et al., 1969; Stevenson et al., 1978; Hall et al., 1992).

In short, classification of syndromic craniosynostosis is mainly based on the associated craniofacial features and limb abnormalities,

although these are seldom pathognomonic for a certain diagnosis. Due to the overlapping features little consistency exists in diagnosing patients with a craniosynostosis syndrome, proving the existing classification system to be insufficient. The drawbacks of this traditional classification system are further discussed in part 2 of this chapter.

Especially since the discovery of genetic mutations in craniosynostosis syndromes (chapter I.2), an increasing number of cases originally diagnosed as isolated craniosynostosis had to be redefined. Subsequently, mutation carriers who are mildly affected were recognized, causing a rise in the incidence number of craniosynostosis. The most recent number states a frequency of 1 in 2,000-2,500 live births for craniosynostosis, including isolated and syndromic cases (Lajeunie et al., 1995a).

### *Diagnosis and treatment*

The diagnosis of craniosynostosis is made by the clinical presentation of the patients with the characteristic skull deformation indicating which suture(s) is (are) affected (fig. 1b). A skull X-ray is used to confirm this diagnosis, for which routinely photographs in three directions are taken: in anteroposterior direction to visualize the frontal and sagittal sutures, the lateral view reveals the coronal sutures, and a Tschebull or Towne's X-ray is indicated to assess the lambdoid sutures. Open sutures are visible as black lines. In case of a synostotic suture, it will be reflected as a white line on the film (fig. 2), due to the presence of bone at that site. In case of a coronal suture synostosis, an additional radiographic sign can be seen, the Harlequins' eye. Because of the secondary displacement of the sphenoid's lesser wing the orbit is deformed, presenting in a characteristic way on the X-ray (fig. 2).

Besides the malformations of the cranium, face and extremities, patients with craniosynostosis can present with numerous other congenital malformations. The most common ones are dilated ventricles or hydrocephalus with or without increased intracranial pressure (Hanieh et al., 1989), corpus callosum agenesis, Arnold-Chiari malformation (herniation of the cerebellar tonsils through the foramen magnum), mental retardation, epilepsy, strabismus, obstructive respiratory problems (Gonzalez et al., 1997), cleft palate, malocclusion, hearing difficulties, skin disorders, and heart malformations.

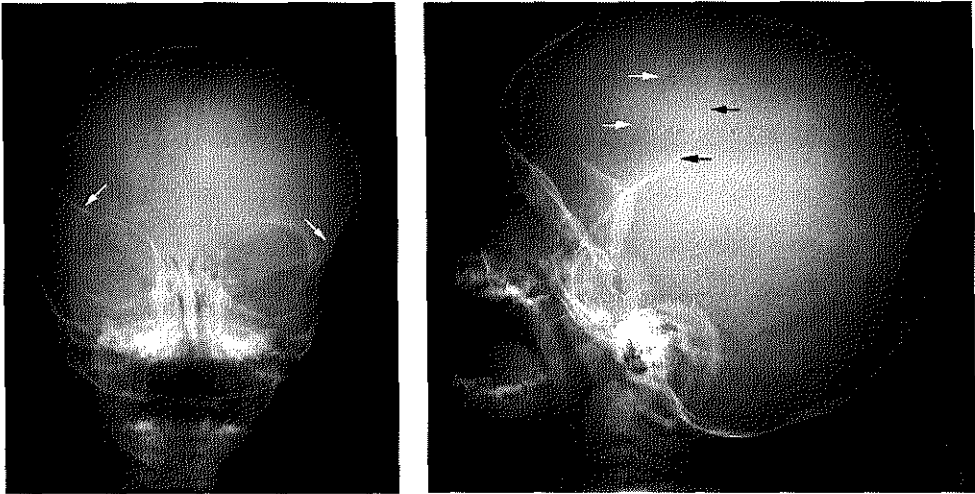


Figure 2. X-ray of unilateral coronal suture synostosis seen from a frontal and a lateral view. On the frontal view the orbit on the synostotic side has an altered shape, referred to as Harlequins' eye, due to the displacement of the sphenoid wing (indicated on both sides by arrows). From the side, the coronal suture on the affected side is visible as a white line (black arrows), while the non-synostotic suture is reflected as a black line (white arrows).

Besides these inborn malformations, patients are also at risk for developing secondary abnormalities as a result of the craniosynostosis. For example, exorbitism with inadequate eyeball protection can cause corneal lesions, with secondary vision loss (Buncic, 1991). Likewise, an increased intracranial pressure may cause compression of the cerebrum and optic nerves (Renier et al., 1982; Gault et al. 1992; Stavrou et al., 1997). Because the spectrum of



problems of these children is so broad, they require treatment in a multidisciplinary craniofacial team.

The main method of treatment for craniosynostosis remains surgery (McCarthy et al., 1995a; McCarthy et al., 1995b). Initiated by dr. Paul Tessier in the early 60's, the basic principles of operation have stayed the same. The aim of surgery is to correct the primary skull deformities to prevent the induction of secondary malformations, and to normalize the patients' appearance. A variety of surgical methods can be applied, depending on the clinical presentation. For instance, operative treatment for the scaphocephalic skull focuses on broadening of the skull by allowing the parietal bone to bulge sideways through certain osteotomies. In most syndromic cases, retrusion of the forehead and shallow orbits are routinely corrected by performing a fronto-orbital advancement, in which the frontal bones and supraorbital rim are taken out, remodeled and inserted in a more anterior and caudal position. The cranial corrections give the calvaria its growth in one stage, which is normally offered by the sutures in years. For this reason, some overcorrection is applied during the procedures, as in time the achieved "growth" will be surpassed. In general, these operations are scheduled within the first year of life of the patient.

Other corrections are the Le Fort I, II and III osteotomies, referring to the level of osteotomies of the facial skeleton, to advance the maxilla and/or midface. These interventions improve occlusion, reduce breathing difficulties and normalize the patients' appearance. The policy in the craniofacial center of Rotterdam is to postpone these

operations until the age of 18 years when growth of the upper and lower jaw has taken place. In that way, the intrinsic growth capacity of these bones is not further restricted because of the surgical intervention. On top of that, a more reliable result can be achieved in young adults because the jaws can be brought to their definitive position, reducing the risk of having to do this high-risk surgery again. A second procedure in scarred tissue is technically much more difficult and associated with a higher complication rate. Of course, psychosocial problems may make it desirable to perform the operation at an earlier stage. The younger the patient is at the time of surgery, the more likely it is that a second operation (LeFort I) later in life is required. In the most extended method of reconstruction, the monoblock procedure, a fronto-orbital advancement is combined with a Le Fort III. This type of surgery is usually only indicated for those infants who present with very severe upper airway obstruction and/or severe exorbitism.

The latest development in surgical treatment of craniosynostosis is gradual distraction of the facial skeleton according to the principles of Ilizarov (McCarthy et al., 1992). Instead of advancing the facial bones in one step during surgery - with the overlying soft tissue restricting the obtainable degree of advancement - a distraction device is inserted at the sites of the osteotomies. Lengthening of the bones is achieved at a rate of 1 mm a day, until the desired advancement is obtained. In this way the soft tissue is stretched too at a limited speed rate, and eventually more advancement can be obtained.

### *Literature overview on pathogenesis*

The earliest publications on the underlying cause of craniosynostosis described some sort of infection, mostly syphilis (Virchow, 1852).

Another explanation, persistently appearing in the literature in a variety of ways, is that of mechanical constraint. In 1918, Thoma stated that the cranial deformity in craniosynostosis is the result of intrauterine compression. This theory is still used to explain the higher incidence of dizygotic twins with isolated craniosynostosis, compared to the normal population (Lajeunie et al., 1996). Burke et al. (1995) stated that normally mechanical forces are necessary to remove developing bone microspicules that are bridging the sutures. Synostosis would be the result of bony bridges being too strong or fracturing forces being too weak, for instance because of reduced fetal activity or intrauterine constraint of the head.

A biomechanical explanation with the defect located at the skull base resulting in synostosis has been indicated by Moss (1975). This hypothesis suggests that through an unspecified dysostosis of the cranial base the location and the tensile forces between the cranial base and the neurocranium – transmitted by the dura- are altered, resulting in premature fusion of the sutures. Although there has been no scientific basis for this theory, it is the one most frequently referred in literature. Ozaki et al. (1998) also suggested biomechanical forces as component of the pathophysiology of sagittal synostosis. Evidence for this theory was supposed to be given by statistical differences of a number of measurements on bone biopsies of sagittal sutures obtained during surgery. However, at that time one is dealing with the

secondary effects of the synostosis that has taken place prenatally (chapter II.2). Therefore, it is no surprise that microscopically an alteration in bone architecture arises. Johnson et al. (2000) reported three family members with a mutation in the FGFR2 gene, commonly found in craniosynostosis (chapter I.2), of whom only one had a unicoronal suture synostosis. The obstetric history of this girl revealed a persistent breech presentation with apparent skull compression at the time of delivery by Caesarean section. The authors proposed an interaction between the genetic mutation and intrauterine constraint, leading to craniosynostosis. Other investigations have disputed the biomechanical models, such as the following. In a sheep fetus, excising the coronal suture and packing this site with bone powder through ex utero surgery induced coronal synostosis. After this manipulation, skull base deformations arose, suggesting these to be secondary to the suture pathology (Stelnicki et al., 1998a). The occurrence of these secondary deformities of the skull base could even be prevented when the suture was re-opened, further substantiating the theory that the primary site of craniosynostosis lies within the suture itself (Stelnicki et al., 1998b).

In conclusion, no convincing evidence for a mechanical factor involved in the initiation of craniosynostosis has yet been given.

Minchin (1856) and Fridolin (1885) supported the “unituberal theory”. This theory states that the two fused bones of the skull have actually arisen out of one single bone center (i.e., tuber) during skull development, instead of separate bone centers. In other words, no suture was ever developed. Wyman (1868) proved this theory to be

wrong by demonstrating a scaphocephalic skull in which only part of the sagittal suture was synostotic, which is incompatible with the unituberal hypothesis. Morselli (1875) suggested that scaphocephaly could arise because the ossification centers of the parietal bones had approached one another. Likewise, Rieping (1919) described how the bone centers were displaced toward the synostotic coronal suture and appeared to have united into one single ossification center. This implies that initially there were separate frontal and parietal bone centers. Park and Powers (1920) considered the defective development to have arisen in the specialized suture tissue (the blastema) with the ossification and bone center displacement going wrong secondarily.

Indeed, a characteristic displacement of the involved bone centers can be seen on the calvaria of craniosynostotic patients, as described by our group (chapter II.1). Our initial theory stated that the involved bone centers had arisen on an abnormal position during skull development, resulting in fusion of the two outgrowing bones instead of suture formation. However, following the discovery of the underlying genetic mutations in craniosynostosis syndromes and a study on bone center positions in rabbit embryos suffering from craniosynostosis (Dechant et al., 1999) our ideas have been adjusted. We now consider the observed displacement of bone centers to be the result of premature bone differentiation within the suture, with subsequent suture ossification and bone fusion (chapter II.2).

The discovery of the genetic background of craniosynostosis syndromes has shed a new light on its pathogenesis and classification.

Research on the pathogenesis of craniosynostosis has benefited highly from the successes of genetic research. By studying the normal expression patterns and functions of the genes involved during skull development, a more profound idea on their impact when mutated is given. Current knowledge on genes in craniosynostosis, their expression and function during skull development and how they induce craniosynostosis when mutated are discussed in the following sections.

## **I.2. Genetic background of syndromic craniosynostosis**

### *Genes and craniosynostosis*

The genes first associated with craniosynostosis were the Gli3 gene (chromosome 7) causing Greig syndrome (Brueton et al., 1988) and the MSX-1 gene (chromosome 5) causing Boston type craniosynostosis in a single family (Jabs et al., 1993). These two syndromes, however, are rare forms of craniosynostosis and are for that reason left out of the focus of this thesis.

For most craniosynostosis syndromes an autosomal dominant inheritance pattern has been observed but it was not before 1994 that the first report on identified gene mutations causing common syndromic craniosynostosis came out. It described mutations in the gene encoding the fibroblast growth factor receptor 2 (FGFR), located on chromosome 10, in patients with Crouzon syndrome (Reardon et al., 1994). Shortly after, additional mutations in FGFR2, FGFR1 (chromosome 8), FGFR3 (chromosome 4) and TWIST (chromosome 7) were reported (table 1). All the disorders caused by these mutations show an autosomal dominant inheritance pattern and thus carriers have a 50% chance of transmitting the mutation. Homozygosity has never been encountered and is perhaps a lethal condition.

So far, four fibroblast growth factor receptors (FGFR1 to 4) are known with at least 20 ligands, the fibroblast growth factors (FGFs). The amino acid sequences of the FGFRs are highly conserved among vertebrate species (Wilkie et al. 1995a; Twigg et al., 1998). The FGFs and FGFRs have their own distinct pattern of expression during

development, although little is known with respect to their expression during skull development. Mutations in FGFR4 have never been detected in craniosynostosis (Gaudenz et al., 1998), and since its expression pattern during embryogenesis does not include the skeleton (Stark et al., 1991; Iseki et al., 1999) FGFR4 will probably not be involved in craniosynostosis. For this reason, aspects on FGFR4 are left out of this section.

FGFRs consist of an extracellular part with the FGF binding capacity, a hydrophobic transmembrane part and an intracellular tyrosine kinase domain (fig. 3). The extracellular domain is made up of three immunoglobulin-like domains (IgI, II, and III) of which only the second and third is essential for ligand binding. Normally, the IgIII is stabilized through intramolecular disulfide bonding. For FGFR2 this disulfide bridge is formed between Cys-278 and Cys-342 (Robertson et al., 1998). When the ligand binds in the presence of heparan sulfate proteoglycans the receptors dimerize and kinase activation results in the intracellular domain.

Through alternative splicing of the FGFR mRNA transcripts, different splice forms of the FGFR are synthesized, thus increasing structural diversity and selective responsiveness amongst the receptors (Twigg et al., 1998). Some exons of the gene are coding for a specific domain of the receptor. Exon 10 encodes the transmembrane domain while exon IIIa encodes a portion of the linker region between the IgII domain and the first half of the third Ig domain. The second half of the IgIII domain is either transcribed by exon IIIb or IIIc. Either of them is exclusively expressed in one specific receptor splice form (Miki et



al., 1992). For FGFR2, the two resulting splice forms are KGFR (keratinocyte growth factor receptor, including IIIb) and BEK (bacterially expressed kinase, including IIIc). The two alternative gene products are identical except for a 49-amino acid sequence (Reardon et al., 1994), and have their own expression pattern and specificity for the ligands. How FGFR2 gene transcription and alternative splicing is normally regulated is unknown, let alone what the effect of a mutation may be.




Figure 3. Schematic structure of FGFR2, consisting of the leader sequence (L), three extracellular Ig-like domains (I, II, III), acidic domain (A), transmembrane region (TM), and intracellular tyrosine kinase domains (TK1, TK2). Either domain IIIb or domain IIIc is present because of alternative splicing (KGFR and BEK form of FGFR2, respectively).

Most genetic mutations in craniosynostosis have been identified in exon IIIc of the FGFR2 gene, thus affecting the BEK isoform.

The TWIST gene contains two exons and encodes a transcription factor with a basic helix-loop-helix (bHLH) motif. The HLH motif is

important for dimerization, whereas the basic domain is essential for binding of the dimer complex to a target DNA-binding sequence.

Most probably, FGFRs are downstream targets of TWIST (Howard et al., 1997). Shishido et al. (1993) demonstrated the necessity of TWIST for expression of DFR1, a FGFR homologue of *Drosophila*.

A striking phenomenon during the discovery of genetic mutations in craniosynostosis was the fact that identical mutations (the same replacement of one amino acid for the other, on exactly the same position) were traced in patients with different clinical diagnoses (table 1). In addition, a specific clinically depicted syndrome was related to a range of mutations, even within different genes (table 1). These findings clearly show that the classical classification based on phenotype does not cover the genotype. Some aspects of the FGFR and TWIST mutations are discussed below.

#### *FGFR1 mutations*

In 1994, Robin et al. linked five families with a craniosynostosis syndrome to chromosome 8. Clinically, they were diagnosed as having Pfeiffer syndrome. In these linked families a missense mutation within exon IIIa of the FGFR1 gene was later identified, resulting in a Pro252Arg substitution in the FGFR1 protein (Muenke et al., 1994) at the linker stretch between the second and third Ig-like domain. Several individuals of a family positive for the Pro252Arg mutation did not exhibit the characteristic broad thumbs of Pfeiffer syndrome but only the broad halluces (Rutland et al., 1995).

Comparing craniosynostosis patients with the FGFR1 mutation to those with a FGFR2 mutation suggested that the FGFR1 mutation induces a milder phenotype, both for hand anomalies and degree of exorbitism (Robin et al., 1998a).

Besides the Pro252Arg, no other mutations in the FGFR1 gene have been reported so far. Given the low frequency of reports on this Pro252Arg mutation, it seems to be a relatively uncommon mutation within the spectrum of FGFR-related craniosynostosis. However, the relatively mild presentation caused by this FGFR1 mutation can make it more difficult to recognize affected persons, thus contributing to a low reported frequency.

#### *FGFR2 mutations*

Mutation in the FGFR2 gene have been related to the following clinical diagnoses: Apert syndrome, Crouzon syndrome, Pfeiffer syndrome, Saethre-Chotzen syndrome, Jackson-Weiss syndrome, Beare-Stevenson syndrome, and unclassified craniosynostosis (table 1). Clinically, no distinction could be made between a mutation located in the IIIa or IIIc exon (Oldridge et al., 1995). This finding suggests that the FGFR2 BEK (IIIa-IIIc) variant and not the KGFR (IIIa-IIIb) generates most influence on craniofacial morphology.

The effect of the mutations can be explained by assuming that the FGFR mutations give rise to a new function, a so called gain of function. A distinction can be made in the inducing mechanism:

- (I) Mutations causing increased receptor activity through abnormal disulfide bond formation, and

- (II) Mutations causing structural alterations of the receptors which affect their binding kinetics for the FGFs.

Ad I. The group of mutations affecting disulfide bond formation is further subdivided in (a) cysteine mutations and (b) noncysteine mutations.

- a. An example of a cysteine mutation causing increased receptor activity is Cys342Tyr, which was shown to promote activation of the mutant receptor in the absence of ligand (Neilson and Friesel, 1995). The cysteine mutations either create or replace a free cysteine residue in the IgIII domain of FGFR2 which can form an intermolecular disulfide bond with another receptor molecule and thus cause receptor dimerization and activation (Neilson and Friesel, 1995; Mangasarian et al., 1997).
- b. The noncysteine mutations can not be distinguished clinically from the cysteine mutations and it was thus thought that a similar activation mechanism had to be the result of these mutations. These mutations can be divided in two subgroups. One group is centered around Trp290, altering the local structure of the normal disulfide bonded cysteines C278 and C342, essential for stabilizing the IgIII domain. The other group is situated near Thr341 and causes a displacement of Cys342, moving it out of bonding range with Cys278 and thus making Cys342 available for intermolecular binding instead of intramolecular binding (Robertson et al., 1998).

Ad II. The mutations Ser252Trp and Pro253Arg alter the relative orientation of the IgII and IgIII domains. This results in a reduced dissociation of FGF2 from FGFR2 constructs containing either of these two mutations compared to wild-type, while the association rate was unaffected (Anderson et al., 1998). Dissociation rate from Ser252Trp was slowest, matching the more severe craniofacial dysmorphology associated with this genotype. The altered dissociation rate turned out to be specific for FGF2, while FGF1, FGF4 or FGF6 binding kinetics were not altered. This specificity for FGF2 could explain why a generalized defect in FGFR2 results in tissue-specific abnormalities.

There remain a number of mutations for which the effect on the receptor is unclear.

Matching the traditional classification of craniosynostosis syndromes and the detected genetic mutations was unsuccessful. Patients with an identical genetic mutation showed considerable variation in phenotype, while a particular clinical craniosynostosis syndrome was related to a list of mutations, even within different genes (table 1). Clinical diagnosis in syndromic craniosynostosis is made by the presence of additional features which are hardly ever pathognomonic (Mulvihill, 1995) and which often overlap for the different syndromes. The reported clinical diagnosis for a particular patient and thus for the detected genetic mutation can therefore be questioned and partially

explain why a certain mutation is said to be associated with numerous craniosynostosis syndromes. For example, the Ala344Gly mutation, detected in the original Jackson-Weiss family, has also been reported in Crouzon patients (Gorry et al., 1995). An important feature of this mutation is extreme intrafamilial variability of phenotype in which features of all other craniosynostosis syndromes are represented.

On the other hand, some consistencies between the clinical and genetic classification exists. For instance, the consistent presentation of Apert syndrome is reflected in the genetic pattern (Wilkie et al., 1995b), with about 99% (190/192 patients, Anderson et al., 1998) of the patients having either a Ser252Trp (64%) or Pro253Arg mutation (36%) (Slaney et al., 1996). Even the subtle subdivisions that can be made within the group of Apert patients appear to be mirrored in the mutation, with the Pro253Arg mutation associated with more severe complex syndactyly of the hands and feet compared to the Ser252Trp mutation (Slaney et al., 1996; Lajeunie et al., 1999b; Von Gernet et al., 2000).

Nearly all cases of Apert syndrome are due to *de novo* mutations and a clear correlation with increased paternal age was demonstrated in 1987 (Risch et al.). The origin of these *de novo* mutations has been shown to be exclusively paternal (Moloney et al., 1996). Although the recurrence risk for these elderly fathers is assumed to be low, Oldridge et al. (1997) have speculated that several of the FGFR mutations could have a selective advantage during spermatogenesis, in which the FGF2/FGFR signalling pathway appears to play an important role (Van Dissel-Emiliani et al., 1996). In rare cases a germ-line

mosaicism could underlie the transmission of the mutation and only for these fathers the recurrence risk is not as extremely low as for the others (Moloney et al., 1996; Plomp et al., 1998). Recently, 11 different de novo mutations in FGFR2 causing Crouzon syndrome and Pfeiffer syndrome were also found to be of paternal origin (Glaser et al., 2000).

In order to reach a new clinically relevant classification based upon the genetic mutation analysis, all possible clinical presentations of each mutation should be collected. Because nearly all patients with a craniosynostotic syndrome are currently tested, the number of detected mutations is increasing. Perhaps this results in recognising additional phenotypical consistencies of other mutations. Of course, the most pronounced manifestations will be distinguished first, as has been observed for the Ser351Cys mutation (chapter IV.1; Gripp et al., 1998a). Further consideration on this subject are given in the general discussion (chapter V).

### *FGFR3 mutations*

Genetic alterations within the FGFR3 gene were already known to be associated with the skeletal disorders achondroplasia, hypochondroplasia, and thanatophoric dysplasia (reviewed by Muenke and Schell 1995; Webster and Donoghue, 1997; Gorlin, 1997).

The first two papers (Meyers et al., 1995, Wilkes et al., 1996) on FGFR3 mutation-related craniosynostosis concerned patients with Crouzon syndrome and acanthosis nigricans. The patients were found

to carry the Ala391Glu transmembrane domain mutation. An intriguing observation is the fact that acanthosis nigricans in Crouzon and Beare-Stevenson syndromes is linked to both FGFR2 and FGFR3 gene mutations, suggesting that FGFR2 and FGFR3 interact or have redundant functions (Przylepa et al., 1996).

Somewhat later, another site of amino acid substitution within the FGFR3 gene was traced (Bellus et al., 1996), being the Pro250Arg in the extracellular domain. By presenting 61 persons from 20 unrelated families with this point mutation this craniosynostosis syndrome was delineated by Muenke et al. (1997). It is because of their paper that the FGFR3 mutation Pro250Arg related craniosynostosis is now often referred to as Muenke syndrome. The majority of the described patients were initially diagnosed as Pfeiffer syndrome (Robin et al., 1994), while others were referred to as having Crouzon syndrome, Saethre-Chotzen syndrome, craniosynostosis-brachydactyly syndrome (Glass et al., 1994) or non-syndromic craniosynostosis. From the study by Muenke et al. (1997) it became clear that carriers of the Pro250Arg mutation could present with an extremely variable phenotype, which is described in detail in chapter IV.2. The variable phenotype was observed both between families as well as within one family. Hollway et al. (1998) recommended to test all patients with uni- or bilateral coronal suture synostosis that lack the classical presentation of other craniosynostosis syndromes for this mutation first. This screening should also include the at risk relatives of confirmed cases, given the mild manifestations or even completely normal phenotype that can occur with this mutation (Gripp et al.,



1998b; Robin et al., 1998b). The effect of the Pro250Arg mutation seems to result in a more severe phenotype in females than in males (Lajeunie et al., 1999a). This sex related presentation points to the possible implication of modifying genes in this syndrome. The Pro250Arg mutation in the FGFR3 gene now appears to be the most common one causing craniosynostosis. Based upon a study done by Moloney et al. (1997) the mutation rate at this nucleotide was even shown to be one of the highest described in the human genome.

The Ala391Glu substitution in FGFR3 has been reported to activate receptor functioning presumably through stabilization of dimers due to hydrogen bonding (Webster and Donoghue, 1997). The Pro250Arg mutation in FGFR3 gene is considered to be equivalent to the Pro253Arg mutation in FGFR2, which results in a ligand-dependent constitutively activated receptor (Anderson et al., 1998).

In summary, all mutations in the FGFR genes appear to cause increased signalling of the receptor, through different mechanisms. The fact that phenotypically related craniosynostosis syndromes can arise from mutations in three different FGFR genes suggests an overlap in their functioning in skull development (Webster and Donoghue, 1997). Indeed, FGFR1, 2 and 3 have been located within the sutural territory during skull development (Iseki et al., 1999; this chapter).

#### *TWIST mutations*

The locus for Saethre-Chotzen syndrome was initially mapped to the short arm of chromosome 7 (Brueton et al., 1992). Howard et al.

(1997) and El Ghouzzi et al. (1997a) found mutations in and near the TWIST gene, with more papers and additional mutations to follow (table 1).

The TWIST mutations listed in table 1 are of various types. Frameshift mutations are mutations that arise by deletions or insertions that are not a multiple of 3 base pairs. They change the frame in which triplets are translated into protein. A missense mutation is a single DNA base change that leads to a codon that specifies a different amino acid. A nonsense or stop mutation is any change in DNA that causes a (termination) codon to replace a codon representing an amino acid.

Besides intragenic mutations, a substantial number of mutations concern translocations and/or deletions. A practical problem associated with genetic analysis for TWIST mutations is the fact that cytogenetically invisible deletions of the gene may account for Saethre-Chotzen phenotype (Johnson et al., 1998). In these cases, screening the coding region will reveal no abnormalities with only the wild type copy being present. This could at least partially explain the limited number of detected TWIST mutations in Saethre-Chotzen syndrome. Johnson et al. (1998) tested this pitfall and found microdeletions in 4 patients, of which only one would have been suspected based on conventional cytogenetic analysis. By applying additional techniques, the sensitivity of recognizing TWIST deletions approached 100% (Zackai and Stolle, 1998).

El Ghouzzi et al. (2000) demonstrated that TWIST mutations cause loss of TWIST protein function through at least two distinct mechanisms:

1. nonsense mutations which result in the synthesis of truncated, unstable proteins that are rapidly degraded.
2. an abnormal cytoplasmic localization of the TWIST mutant protein which may account for its inability to bind DNA.

This would imply that in normal development TWIST acts as a down-regulator of FGFR transcription, as has been suggested for the *Drosophila* (Shishido et al., 1993).

The fact that clinically one cannot easily distinguish between a TWIST or FGFR mediated craniosynostosis also points out the likelihood that these genes interact and that their mutations probably result in a similar disturbance of biological processes. Paznekas et al. (1998) detected all sorts of TWIST mutations in 17 of 37 patients suspected for Saethre-Chotzen syndrome (46%). Besides those in the TWIST gene, mutations were also found in the FGFR2 gene (1 patient) and in the FGFR3 gene (7 patients), while no mutations were detected in the remaining 12 patients. Likewise, El Ghouzzi et al. (1997b) reported patients classified as Saethre-Chotzen to have the FGFR3 Pro250Arg mutation but noticed the milder phenotype in these patients as compared to TWIST ones. It was therefore concluded that TWIST mutations are specific to Saethre-Chotzen syndrome. Given the overlapping clinical features of the different craniosynostosis syndromes it indeed seems more sensible to rediagnose these FGFR3 Pro250Arg patients. With nearly half of the patients matching the

classical description of Saethre-Chotzen having a TWIST mutation, this genetic alteration could be a pathognomonic criterion for Saethre-Chotzen syndrome, or to rename this condition as TWIST-craniosynostosis syndrome. The phenotype of TWIST-mediated Saethre-Chotzen syndrome consists of coronal suture synostosis (uni- or bilateral), facial asymmetry, low frontal hairline, and eyelid ptosis besides syndactyly of the second and third fingers, duplicated halluces, prominent ear crura, and small, posteriorly rotated ears (Johnson et al., 1998; Zackai and Stolle, 1998). These features could not be correlated to particular mutations within TWIST (El Ghouzzi et al., 1999), but perhaps with a higher number of patients this group can be further subdivided in future. In some cases, metopic suture synostosis was observed, although always associated with other typical features of Saethre-Chotzen (Paznekas et al., 1998; Johnson et al., 1998). In the cases with a deletion of 7p21.1 the three patients with large (> 3 Mb) deletions had significant learning difficulties which is relatively uncommon in TWIST positive patients, suggesting that haploinsufficiency of the genes that neighbor TWIST contributes to mental handicap (Johnson et al., 1998).

Table 1. List of published mutations in the FGFR1, FGFR2, FGFR3, and TWIST genes related to craniosynostosis.

Abbreviations: A = Apert; AN = acanthosis nigricans; BS = Beare-Stevenson; C = Crouzon; JW = Jackson-Weiss; N = normal; NS = non-syndromic craniosynostosis; P = Pfeiffer; RS = Robinow-Sorauf; SCh = Saethre-Chotzen; U = unclassified.

When author's names are separated by a "/" this means that both have reported the same associated clinical diagnosis more or less simultaneously.

### **FGFR1**

<u>Source</u>	<u>mutation</u>	<u>diagnosis</u>
Muenke (1994)	Pro252Arg	P

### **FGFR2**

<u>Source</u>	<u>mutation</u>	<u>diagnosis</u>
<b>Exon IIIa</b>		
Pulleyn (1996)	Tyr105Cys	C
Wilkie (1995b)	Ser252Trp	A
Passos-Bueno (1998b)	"	P
Oldridge (1997)	Ser252Phe	A
Oldridge (1997)	Ser252Leu	C,N
Oldridge (1997)	Ser252Phe/Pro253Ser	P
Wilkie (1995b)	Pro253Arg	A
Oldridge (1995)	Ser267Pro	C
Cornejo-Roldan (1999)	"	P
Meyers (1996)	Thr268ThrGly	C
Paznekas (1998)	ValVal269-270del	SCh
Steinberger (1998)	Phe276Val	C
Cornejo-Roldan (1999)	"	P
Oldridge (1995)	Cys278Phe	C
Meyers (1996)	"	P

<u>Source</u>	<u>mutation</u>	<u>diagnosis</u>
Passos-Bueno (1998a)	Cys278Phe	JW
Oldridge (1995)	delHisIleGln 287-289	C
Cornejo-Roldan (1999)	Ile288Met and 289-294Δ	P
Oldridge (1995)/Gorry (1995)	Gln289Pro	C
Meyers (1996)	“	JW
Park (1995)	Trp290Gly	C
Oldridge (1995)	Trp290Arg	C
Tartaglia (1997a)	Trp290Cys (G→C)	P
Wilkie (1997)/Schaefer (1998)	Trp290Cys (G→T)	P
Steinberger (1997)	Lys292Glu	C
Steinberger (1998)	Tyr301Cys	C

### **Exon IIIc**

Steinberger (1998)	Ala314Ser	U
Lajeunie (1995b)	Asp321Ala	P
Jabs (1994)	Tyr328Cys	C
Steinberger (1996b)	Asn331Ile	C
Steinberger (1996b)	dup336-337	C
Passos-Bueno (1998a)	Ala337Pro	C
Gorry (1995)	Gly338Arg	C
Pulleyn (1996)	Gly338Glu	C
Reardon (1994)	Tyr340His	C
Cornejo-Roldan (1999)	Tyr340Cys	P
Rutland (1995)	Thr341Pro	P
Reardon (1994)	Cys342Tyr	C
Rutland (1995)	“	P
Reardon (1994)	Cys342Arg	C
Schell (1995)/Rutland (1995)	“	P
Park (1995)	“	JW
Reardon (1994)	Cys342Ser (T→A)	C

<u>Source</u>	<u>mutation</u>	<u>diagnosis</u>
Meyers (1996)	Cys342Ser (T→A)	P
Tartaglia (1997b)	“	JW
Gorry (1995)	Cys342Ser (G→C)	C
Meyers (1996)	“	P
Tartaglia (1997b)	“	JW
Cornejo-Roldan (1999)	Cys342Ser (GC→CT)	P
Oldridge (1995)	Cys342Phe	C
Park (1995)/Ma (1995)/Steinberger (1995)	Cys342Trp	C
Hollway (1997)	“	P
Cornejo-Roldan (1999)	Cys342Gly	P
Meyers (1996)	Ala344Pro	P
Jabs (1994)	Ala344Gly	JW
Gorry (1995)	“	C
Reardon (1994)	Ala344Ala	C
	(new donor splice site)	
Steinberger (1996a)	“	U
Meyers (1996)	“	P
Jabs (1994)	Ser347Cys	C
Oldridge (1999)	1041-1042 ins Alu	A
Pulleyn (1996)	Ser351Cys	U
Gripp (1998a)/Mathijssen (1998)	“	P
Reardon (1994)	Ser354Cys	C
Meyers (1996)	Val359Phe	P
Steinberger (1996b)	del1078-1086	C
Cornejo-Roldan (1999)	1084+3A→G	P
Schell (1995)	940-3T→G	P
Schell (1995)/Lajeunie (1995b)	940-2A→G	P
Cornejo-Roldan (1999)	940-1G→A	P
Hollway (1997)	940-1G→C	P

<u>Source</u>	<u>mutation</u>	<u>diagnosis</u>
Schell (1995)	1119+1G→T	P
Oldridge (1999)	1119-3- -4insAlu	A

#### **Transmembrane domain (exon 10)**

Przylepa (1996)	Ser372Cys	BS
Przylepa (1996)	Tyr375Cys	BS
Pulleyn (1996)	Gly384Arg	U

### **FGFR3**

<u>Source</u>	<u>mutation</u>	<u>diagnosis</u>
Bellus (1996)	Pro250Arg	NS,P,C,SCh
Meyers (1995)	Ala391Glu	C+AN

### **TWIST**

<u>Source</u>	<u>mutation</u>	<u>diagnosis</u>
<b>Upstream of DNA binding</b>		
Gripp (2000)	Gln28STOP	SCh
Rose (1997)	Gly61STOP	SCh
Rose (1997)	Glu65STOP	SCh
Johnson (1998)	Lys77Ser + frameshift	SCh
Gripp (2000)	Gly88Ala + 36aa to stop	SCh
Kasparcova (1998)	GAGGGGG92-92ins	SCh
Kasparcova (1998)	Ser93Gly + 198aa to stop	SCh
Howard (1997)	Tyr103STOP (308insA)	SCh
El Ghouzzi (1997a)	Tyr103STOP (309C→A)	SCh
Paznekas (1998)	Tyr103STOP (309C→G)	SCh
El Ghouzzi (1997b)	Glu104STOP	SCh



<u>Source</u>	<u>mutation</u>	<u>diagnosis</u>
<b>DNA binding</b>		
Paznekas (1998)	Arg116Trp	SCh
El Ghouzzi (1997b)	Arg118Gln/Arg118del	SCh
Rose (1997)	Arg118His	SCh
El Ghouzzi (1999)	Arg118His (del 8 bp)	SCh
Ray (1997)	Gln119Pro	SCh
Kasparcova (1998)	Arg120Pro	SCh
<b>Helix I</b>		
Paznekas (1998)	Gln122STOP	SCh
El Ghouzzi (1997a)	Ser123STOP	SCh
Johnson (1998)	Ser123Trp	SCh
El Ghouzzi (1997a)	Glu126STOP	SCh
Gripp (2000)	Ala127Val	SCh
Paznekas (1998)	Ala129Arg + 159aa to stop	SCh
El Ghouzzi (1997a)	Leu131Pro	SCh
Paznekas (1998)	Arg132Pro	SCh
Rose (1997)	Ile134Met	SCh
Howard (1997)	AALRKII135-136ins	SCh
Johnson (1998)	Pro136Leu	U
<b>Loop</b>		
El Ghouzzi (1997a)/Howard (1997)	KIIPTLP139-140ins (416dup21)	SCh
El Ghouzzi (1997a)	KIIPTLP139-140ins (417dup21)	SCh
Rose (1997)	Pro139STOP (419dup21)	SCh
Paznekas (1998)	Pro139Ser	SCh
Rose (1997)	Ser140STOP	SCh
Rose (1997)	IIPTLPS140-141ins	SCh

<u>Source</u>	<u>mutation</u>	<u>diagnosis</u>
Paznekas (1998)	Asp141Tyr	SCh
Rose (1997)	Asp141Gly	SCh
El Ghouzzi (1999)	DHPHAALG141-142ins	SCh
El Ghouzzi (1999)	Ser144Arg	SCh
Rose (1997)	Lys145Asn	SCh
El Ghouzzi (1997b)	Lys145Glu + 135aa to stop	SCh
Howard (1997)	Lys145Gly	SCh
Ray (1997)	Thr148Asn	SCh
Kasparcova (1998)	Thr148Ala	SCh
Paznekas (1998)	Leu149Phe	SCh
Paznekas (1998)	Ala152Val	SCh

### **Helix II**

Rose (1997)	Arg154Gly	SCh
Kunz (1999)	Arg154Lys	RS/SCh
El Ghouzzi (1999)	Tyr155STOP	SCh
El Ghouzzi (1997b)	Leu159Phe	SCh
Kasparcova (1998)	Tyr160stop	SCh
El Ghouzzi (1997b)	Gln161STOP	SCh
El Ghouzzi (1999)	Leu163Phe	SCh
Gripp (2000)	Gln165STOP	SCh
Gripp (1999)	Glu181STOP	SCh

*Expression and function of FGFRs and TWIST during skull development*

Before the involvement of FGFRs and TWIST in skull development through craniosynostosis was recognized studies on their expression pattern and function only focused on the early stages of embryogenesis. Currently, these data are partially gathered for the FGFRs (Iseki et al., 1997; Kim et al., 1998; Mehrara et al., 1998; Iseki et al., 1999). Within the coronal suture of murine embryos aged 15 days post conception (E15), FGFR1 expression was detected in the osteogenic fronts of the calvarial bone (Rice et al., 2000). From E15 on, FGFR2 was expressed by osteogenic precursor cells at the extensions of the frontal and parietal osteogenic fronts (Iseki et al., 1997). Towards the osteogenic fronts the cells were more differentiated with subsequent down-regulation of FGFR2 and up-regulation of FGFR1 (Iseki et al., 1999). Functionally, FGFR2 expression correlated with a high proliferation rate, while FGFR1 expression indicated bone differentiation. When differentiation of these cells was even more advanced FGFR1 was no longer expressed, indicating that FGFR1 is only taking part in the osteogenic differentiation process and not in maintaining the differentiated state (Iseki et al., 1999). FGFR3 expression can be traced within the cartilage situated underneath the coronal suture as well as in osteogenic cells of the suture. Within the suture, FGFR3 had a similar localisation to that of FGFR2 and a co-operative role between FGFR2 and FGFR3 in osteogenic cell proliferation has been suggested (Iseki

et al., 1999). Figure 4 summarizes the expression patterns in the coronal suture at E16.

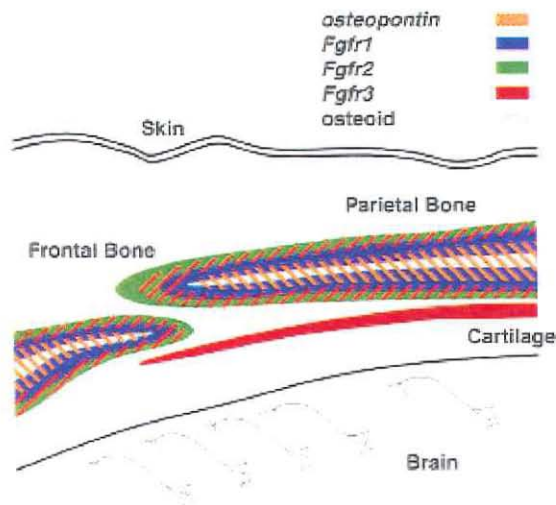


Figure 4. Schematic drawing of a coronal suture of a mouse embryo 16 days post conception, indicating the expression of FGFR1, 2 and 3.

The function of FGFR3 detected in a plate of cartilage underlying the coronal suture is unclear, just like the fate of the cartilage itself. Within the coronal suture, a balance between proliferation (FGFR2, FGFR3) and bone differentiation (FGFR1) appears to be kept to ensure its function.

FGF2 is nearly absent in the center of the suture, while its concentration rises towards the osteogenic fronts being highest in the osteoid. FGF9 is also detected in this region (Kim et al., 1998) while FGF4 (Kim et al., 1998; Iseki et al., 1997) and FGF8 (Yoshiura et al., 1997) are not. So it appears that FGF2 might be one of the factors regulating the proliferation/differentiation balance. A limited number

of studies concerning the FGFRs expression have been performed on human tissues. Delezoide et al. (1998) detected FGFR1 and FGFR2 expression prior to the onset of ossification within the mesenchyme of the presumptive skull bones. Likewise, Chan and Thorogood (1999) traced FGFR2 in the membrane bones of the skull in a human embryo of 12 weeks postfertilization, while FGFR1 was mainly expressed in the periosteum. Data on FGFR3 or TWIST patterns in human material are lacking.

TWIST expression during skull development in mouse embryos is confined to the calvarial mesenchyme (mesenchymal cells and osteoprogenitor cells) in between the frontal and parietal bones, with its strongest expression directly neighboring the osteogenic fronts (Rice et al., 2000). This pattern is clearly outlined starting from E14. TWIST has been shown to regulate FGFR, functioning upstream of FGFR/FGF signalling (Rice et al., 2000).

Another process that might be involved in maintaining the proliferation/differentiation balance is programmed cell death or apoptosis (Rice et al., 1999). In 1977, Ten Cate and coauthors reported on the presence of apoptotic cells in the suture of newborn rats. Furtwängler and others (1985) considered apoptosis to be a mechanism that prevented fusion of bones, a hypothesis that we also believed to be true initially. Further studies on the involvement of apoptosis in the pathogenesis of craniosynostosis are presented in chapter III.1 and III.2.

Another unresolved aspect in suture biology is the function of the dura mater. It has been established that presence of the dura is essential to

keep the suture open (Opperman et al., 1993; Opperman et al., 1995; Opperman et al., 1996; Opperman et al., 1997; Opperman et al. 1998) probably through secretion of certain unidentified factors.

### **I.3. Aim of this study**

While craniosynostosis has been treated for almost thirty years a number of dilemmas are still encountered, related to clinical practice and fundamental knowledge.

The first problem is that of correct diagnosis. A distinction should be made between a true isolated case of craniosynostosis and a syndromic form. In clinical practice a case is considered to be isolated when the suture synostosis is the only malformation present. Most commonly, these patients are the only affected individual within the family. In the presence of overt deformities of the face and/or extremities a syndromic form is easily recognized. The apparent isolated cases of craniosynostosis are the challenging ones, in whom a syndrome may be difficult to distinguish (Tartaglia et al., 1999). Once a syndromic form is acknowledged the difficulty in designating the most appropriate syndrome within the classical classification system remains, for which the pitfalls have been discussed earlier (chapter I.1). Given the possible impact of the diagnosis on care, a conclusive classification is desirable which covers both phenotype and genotype.

The second problem concerns the pathogenesis of this congenital malformation about which little is known. A wide range of suggested causes have been reported but none could be proven. The discovery of genetic defects that underlie craniosynostosis syndromes has shed some light on its etiology, although it generated even more questions.

Given these two dilemmas, our research set out to deal with the first and most basic problem, that of classification. At that time the first gene defect related to craniosynostosis was located (Reardon et al., 1994). Our approach was that of a morphological study of the cranium (chapter II.1; Vaandrager et al., 1995). Although the morphometric data did not bring a guideline for classification they did direct us towards the pathoembryogenesis of craniosynostosis. Based upon these results a hypothesis was developed on bone center displacement during skull development being the primary defect in craniosynostosis. However, testing this theory in a rabbit strain suffering from inborn coronal suture synostosis showed this theory to be wrong (Dechant et al., 1998; Mooney et al., 1998; Dechant et al., 1999). Bone centers arose at their normal position and it was not before the onset of suture ossification, i.e., bone fusion that the bone centers became displaced.

Based on observations done on normal human fetal skulls the timing and pattern of metopic, coronal, sagittal and lambdoid sutures development was described. In our patients the distance between the bone centers of the fused bones correlated directly to the fetal stage at which craniosynostosis arose (chapter II.2). Although this may be of clinical relevance such as prenatal screening through ultrasound, no relevant classification could be extracted from these data. Meanwhile, the first mutated genes in craniosynostosis were located, revealing the involvement of the FGFRs and TWIST in the development of the skull.



With the advances made in the genetic field on craniosynostosis, a new basis for classification was thought to be found. Unfortunately, the correlation between genotype and phenotype for most mutations was not as strict as hoped for. Even so, this correlation is of clinical relevance because it might offer the possibility to screen and treat patients more accurately, while genetic counseling is more accurate. This, however, needs to be substantiated by further analysis. In this respect, we reported the clinical findings in one patient with the Ser351Cys mutation in FGFR2 (chapter IV.1) and those of two families with the Pro250Arg mutation in FGFR3 (chapter IV.2).

Besides the studies undertaken for classification purposes, our research was also directed towards the pathogenesis of craniosynostosis. Until recently, studies on suture development and biology were hardly available (Pritchard et al., 1956; Markens 1975; Decker and Hall, 1985). Understanding how a congenital disorder is initiated requires full understanding of normal development. For this reason we analyzed histological samples of coronal sutures of murine fetuses and embryos (chapter III.1). The coronal suture was chosen since this suture is most commonly affected in syndromic cases of craniosynostosis. Because apoptosis is known to be of vital importance during normal embryogenesis and disturbances of this process have been implicated in congenital malformations such as syndactyly, the focus was on the occurrence of this process during suture development. Our next investigation was to evaluate the consequences of the FGFR mutations on the developmental biology of

the coronal suture. Unfortunately, no animal with a comparable FGFR mutation is known. The craniosynostotic rabbits from Pittsburgh might carry a FGFR mutation but this has not been confirmed. Therefore, an alternative model was needed. A number of reports had shown most of the FGFR mutations to result in an up-regulation of the receptor function. We mimicked this effect in an in vivo mouse-model by injection of FGF4 or FGF2, ligands of FGFR2, locally near the developing coronal suture through ex utero surgery (Mathijssen et al., 1999; chapter III.2).

In short, we had high set goals at the start of this study by trying to establish a conclusive classification for craniosynostosis. Due to the developments in the genetic field and as a result of our initial study, our focus shifted towards the pathogenesis of craniosynostosis. The potential of genetic mutation analysis for being the basis of a new classification was explored, to which we contributed in describing the geno-phenotypic relationship for 2 mutations (chapters IV.1 en IV.2).

## **References**

- Anderson PJ, Hall CM, Evans RD, Jones BM, Hayward RD.** Hand anomalies in Crouzon syndrome. *Skeletal Radiol.* 26: 113-115, 1997.
- Anderson J, Burns HD, Enriquez-Harris P, Wilkie AOM, Heath JK.** Apert syndrome mutations in fibroblast growth factor receptor 2 exhibit increased affinity for FGF ligand. *Hum. Molec. Genet.* 7: 1475-1483, 1998.
- Apert E.** De l'acrocéphalosyndactylie. *Bull. Soc. Méd. (Paris)* 23: 1310-1330, 1906.

- Beare JM, Dodge JA, Nevin NC.** Cutis gyratum, acanthosis nigricans and other congenital anomalies. *Br. J. Derm.* 81: 241-247, 1969.
- Bellus GA, Gaudenz K, Zackai EH, Clarke LA, Sazbo J, Francomano CA, Muenke M.** Identical mutations in three different fibroblast growth factor receptor genes in autosomal dominant craniosynostosis syndromes. *Nat. Genet.* 14: 174-176, 1996.
- Berant M, Berant N.** Radioulnar synostosis and craniosynostosis in one family. *J. Pediatr.* 83: 88-90, 1973.
- Brueton LA, Huson SM, Winter RM, Williamson R.** Chromosomal localisation of a developmental gene in man: Direct DNA analysis demonstrates that Greig cephalopolysyndactyly maps to 7p13. *Am. J. Med. Genet.* 31: 799-804, 1988.
- Brueton LA, Van Herwerden L, Chotai KA, Winter RM.** The mapping of a gene for craniosynostosis: Evidence for linkage of the Saethre-Chotzen syndrome to distal chromosome 7p. *J. Med. Genet.* 29: 681-685, 1992.
- Buncic JR.** Ocular aspects of Apert syndrome. *Clin. Plast. Surg.* 18: 315-319, 1991.
- Burke MJ, Winston KR, Williams S.** Normal sutural fusion and the etiology of single sutural craniosynostosis: The microspicule hypothesis. *Pediatr. Neurosurg.* 22: 241-247, 1995.
- Chan CTJ, Thorogood P.** Pleiotropic features of syndromic craniosynostoses correlate with differential expression of fibroblast growth factor receptors 1 and 2 during human craniofacial development. *Ped. Res.* 45: 46-53, 1999.
- Chotzen F.** Eine eigenartige familiäre Entwicklungsstörung (Akrocephalosyndaktylie, Dysostosis craniofacialis und Hypertelorismus.). *Monatschr. Kinderheilk.* 55: 97-122, 1932.
- Cohen MM Jr.** History, terminology, and classification of craniosynostosis. Cohen MM Jr. (ed.). In: *Craniosynostosis: Diagnosis, evaluation, and management.* New York. Raven Press, 1986.
- Cohen MM Jr., Kreiborg S.** An updated pediatric perspective on the Apert syndrome. *Am. J. Dis. Child.* 147: 989-993, 1993a.
- Cohen MM Jr.** Pfeiffer syndrome update, clinical subtypes, and guidelines for differential diagnosis. *Am. J. Med. Genet.* 45: 300-307, 1993b.

- Cohen MM Jr., Kreiborg S.** Hands and feet in the Apert syndrome. *Am. J. Med. Genet.* 57: 82-96, 1995.
- Cornejo-Roldan LR, Roessler E, Muenke M.** Analysis of the mutational spectrum of the FGFR2 gene in Pfeiffer syndrome. *Hum. Genet.* 104: 425-431, 1999.
- Crouzon O.** Dysostose craniofaciale héréditaire. *Bull. Med. Soc. Med. Hop. (Paris)* 33: 545-555, 1912.
- Dechant JJ, Mooney MP, Cooper GM, Smith TD, Burrows AM, Losken HW, Mathijssen IMJ, Siegel MI.** Positional changes in the frontoparietal ossification centers in perinatal craniosynostotic rabbits. *Abstract. Am. J. Phys. Anthropol. Suppl.* 26: 75, 1998.
- Dechant JJ, Mooney MP, Cooper GM, Smith TD, Burrows AM, Losken HW, Mathijssen IMJ, Siegel MI.** Positional changes of the frontoparietal ossification centers in perinatal craniosynostotic rabbits. *J. Craniofac. Gen. Dev. Biol.* 19: 64-74, 1999.
- Decker JD, Hall SH.** Light and electron microscopy of the new born sagittal suture. *Anat. Rec.* 212: 81-89, 1985.
- Delezoide AL, Benoist-Lasselain C, Legeai-Mallet L, Le Merrer M, Munnich A, Vekemans M, Bonaventure J.** Spatio-temporal expression of FGFR1, 2 and 3 genes during human embryo-fetal ossification. *Mech. Development* 77: 19-30, 1998.
- El Ghouzzi V, Le Merrer M, Perrin-Schmitt F, Lajeunie E, Benit P, Renier D, Bourgeois P, Bolcato-Bellemin AL, Munnich A, Bonaventure J.** Mutations of the TWIST gene in the Saethre-Chotzen syndrome. *Nature Genet.* 15: 42-46, 1997a.
- El Ghouzzi V, Lajeunie E, Le Merrer M, Cormier V, Renier D, Munnich A, Bonaventure J.** TWIST mutations disrupting the b-HLH domain are specific to Saethre-Chotzen syndrome. *Abstract. Am. J. Hum. Genet. Suppl.* 61: A332, 1997b.
- El Ghouzzi V, Lajeunie E, Le Merrer M, Cormier-Daire V, Renier D, Munnich A, Bonaventure J.** Mutations within or upstream of the basic helix-loop-helix domain of the TWIST gene are specific to Saethre-Chotzen syndrome. *Eur. J. Hum. Genet.* 7: 27-33, 1999.
- El Ghouzzi V, Legeai-Mallet L, Aresta S, Benoist C, Munnich A, De Gunzburg J, Bonaventure J.** Saethre-Chotzen mutations cause TWIST protein degradation or impaired nuclear location. *Hum. Molec. Genet.* 9: 813-819, 2000.

- Fridolin J.** Studien über frühzeitige Schädeldeformitäten. Arch. Path. Anat. 100: 266, 1885.
- Furtwängler JA, Hall SH, Koskinen-Moffett LK.** Sutural morphogenesis in the mouse calvaria: The role of apoptosis. Acta Anat. 124: 74-80, 1985.
- Gaudenz K, Roessler E, Vainikka S, Alitalo K, Muenke M.** Analysis of patients with craniosynostosis syndromes for a Pro246Arg mutation in FGFR4. Molec. Genet. Metabol. 64: 76-79, 1998.
- Gault DT, Renier D, Marchac D, Jones BM.** Intracranial pressure and intracranial volume in children with craniosynostosis. Plast. Reconstr. Surg. 90: 377-381, 1992.
- Glaser RL, Jiang W, Boyadjiev A, Tran AK, Zachary AA, Van Maldergem L, Johnson D, Walsh S, Oldridge M, Wall SA, Wilkie AOM, Jabs EW.** Paternal origin of FGFR2 mutations in sporadic cases of Crouzon syndrome and Pfeiffer syndrome. Am. J. Hum. Genet. 66: 768-777, 2000.
- Glass IA, Chapman S, Hockley AD.** A distinct autosomal dominant craniosynostosis-brachydactyly syndrome. Clin. Dysmorphol. 3: 215-223, 1994.
- Gonzalez S, Hayward R, Jones B, Lane R.** Upper airway obstruction and raised intracranial pressure in children with craniosynostosis. Eur. Respir. J. 10: 367-375, 1997.
- Gorlin RJ.** Fibroblast growth factors, their receptors and receptor disorders. J. Cranio-Maxillofac. Surg. 25: 69-79, 1997.
- Gorry MC, Preston RA, White GJ, Zhang Y, Singhal VK, Losken HW, Parker MG, Nwokoro NA, Post JC, Ehrlich GD.** Crouzon syndrome: Mutations in two spliceoforms of FGFR2 and a common point mutation shared with Jackson-Weiss syndrome. Hum. Molec. Genet. 4: 1387-1390, 1995.
- Gripp KW, Stolle CA, McDonald-McGinn DM, Markowitz RI, Bartlett SP, Katowitz JA, Muenke M, Zackai EH.** Phenotype of the fibroblast growth factor receptor 2 Ser351Cys mutation: Pfeiffer syndrome type III. Am. J. Med. Genet. 78: 356-360, 1998a.
- Gripp KW, McDonald-McGinn DM, Gaudenz K, Whitaker LA, Bartlett SP, Glat PM, Cassileth LB, Mayro R, Zackai EH, Muenke M.** Identification of a genetic cause for isolated unilateral coronal synostosis: A unique mutation in the fibroblast growth factor receptor 3. J. Pediatr. 132: 714-716, 1998b.

- Gripp KW, Stolle CA, Celle L, McDonald-McGinn DM, Whitaker LA, Zackai EH.** TWIST gene mutation in a patient with radial aplasia and craniosynostosis: further evidence for heterogeneity of Baller-Gerold syndrome. *Am. J. Med. Genet.* 82: 170-176, 1999.
- Gripp KW, Zackai EH, Stolle CA.** Mutations in the human TWIST gene. *Hum. Mut.* 15: 150-155, 2000.
- Hall BD, Cadle RG, Golabi M, Morris CA, Cohen MM Jr.** Beare-Stevenson cutis gyrata syndrome. *Am. J. Med. Genet.* 44: 82-89, 1992.
- Hanieh A, Sheen R, David DJ.** Hydrocephalus in Crouzon's syndrome. *Child's Nerv. Syst.* 5: 188-189, 1989.
- Hollway GE, Suthers GK, Haan EA, Thompson E, David DJ, Gez J, Mulley JC.** Mutation detection in FGFR2 craniosynostosis syndromes. *Hum. Genet.* 99: 251-255, 1997.
- Hollway GE, Suthers GK, Battese KM, Turner AM, David DJ, Mulley JC.** Deafness due to Pro250Arg mutation of FGFR3. *Lancet* 351: 877-878, 1998.
- Howard TD, Paznekas WA, Green ED, Chiang LC, Ma N, Ortiz De Luna RI, Delgado CG, Gonzalez-Ramos M, Kline AD, Jabs EW.** Mutations in TWIST, a basic helix-loop-helix transcription factor, in Saethre-Chotzen syndrome. *Nature Genet.* 15: 36-41, 1997.
- Huang MHS, Gruss JS, Clarren SK, Mouradian WE, Cunningham ML, Roberts TS, Loeser JD, Cornell CJ.** The differential diagnosis of posterior plagiocephaly: True lambdoid synostosis versus positional molding. *Plast. Reconstr. Surg.* 98: 765-774, 1996.
- Hunter AGW, Rudd NL.** Craniosynostosis. I. Sagittal synostosis; Its genetics and associated clinical findings in 214 patients who lacked involvement of the coronal suture(s). *Teratology* 14: 185-194, 1976.
- Iseki S, Wilkie AOM, Heath JK, Ishimaru T, Eto K, Morriss-Kay GM.** FGFR2 and osteopontin domains in the developing skull vault are mutually exclusive and can be altered by locally applied FGF2. *Development* 124: 3375-3384, 1997.
- Iseki S, Wilkie AOM, Morriss-Kay GM.** FGFR1 and FGFR2 have distinct differentiation- and proliferation-related roles in the developing mouse skull vault. *Development* 126: 5611-5620, 1999.

- Jabs EW, Myller U, Li X, Ma L, Luo W, Haworth IS, Klisak I, Sparkes R, Warman ML, Mulliken JB, Snead ML, Maxson R.** A mutation in the homeodomain of the human MSX2 gene in a family affected with autosomal dominant craniosynostosis. *Cell* 75: 443-450, 1993.
- Jabs EW, Li X, Scott AF, Meyers G, Chen W, Eccles M, Mao J, Charnas LR, Jackson CE, Jaye M.** Jackson-Weiss and Crouzon syndromes are allelic with mutations in fibroblast growth factor receptor 2. *Nature Genet.* 8: 275-279, 1994.
- Jackson CE, Weiss L, Reynolds WA, Forman TF, Peterson JA.** Craniosynostosis, midfacial hypoplasia, and foot abnormalities: An autosomal dominant phenotype in a large Amish kindred. *J. Pediatr.* 88: 963-968, 1976.
- Johnson D, Horsley SW, Moloney DM, Oldridge M, Twigg SRF, Walsh S, Barrow M, Njølstad PR, Kunz J, Ashworth GJ, Wall SA, Kearney L, Wilkie AOM.** A comprehensive screen for TWIST mutations in patients with craniosynostosis identifies a new microdeletion syndrome of chromosome band 7p21.1. *Am. J. Hum. Genet.* 63: 1282-1293, 1998.
- Johnson D, Wall SA, Mann S, Wilkie AOM.** A novel mutation, Ala315Ser, in FGFR2: a gene-environment interaction leading to craniosynostosis? *Eur. J. Hum. Genet.* 8: 571-577, 2000.
- Kasparcova V, Stolle CA, Gripp KW, Celle L, McDonald-McGinn D, Bartlett S, Whitaker L, Zackai EH.** Molecular analysis of patients with Saethre-Chotzen syndrome: Novel mutations and polymorphisms in the TWIST gene. *Am. J. Hum. Genet. Suppl.* 63: A367, 1998.
- Kim HJ, Rice DPC, Kettunen PJ, Thesleff I.** FGF-, BMP- and Shh-mediated signalling pathways in the regulation of cranial suture morphogenesis and calvarial bone development. *Development* 125: 1241-1251, 1998.
- Kokich VG.** Biology of sutures. In: *Craniosynostosis: Diagnosis, evaluation, and management.* Cohen MM Jr. (Ed.). New York. Raven Press, 1986.
- Kunz J, Hudler M, Fritz B, Gillessen-Kaesbach G, Passarge E.** Identification of a frameshift mutation in the gene TWIST in a family affected with Robinow-Sorauf syndrome. *J. Med. Genet.* 36: 650-652, 1999.

- Lajeunie E, Le Merrer M, Bonaïti-Pellie C, Marchac D, Renier D.** Genetic study of nonsyndromic coronal craniosynostosis. *Am. J. Med. Genet.* 55: 500-504, 1995a.
- Lajeunie E, Ma HW, Bonaventure J, Munnich A, Le Merrer M.** FGFR2 mutations in Pfeiffer syndrome. *Nature Genet.* 9: 108, 1995b.
- Lajeunie E, Le Merrer M, Bonaïti-Pellie C, Marchac D, Renier D.** Genetic study of scaphocephaly. *Am. J. Med. Genet.* 62: 282-285, 1996.
- Lajeunie E, Le Merrer M, Marchac D, Renier D.** Syndromal and nonsyndromal primary trigonocephaly: Analysis of a series of 237 patients. *Am. J. Med. Genet.* 75: 211-215, 1998.
- Lajeunie E, El Ghouzzi V, Le Merrer M, Munnich A, Bonaventure J, Renier D.** Sex related expressivity of the phenotype in coronal craniosynostosis caused by the recurrent P250R FGFR3 mutation. *J. Med. Genet.* 36: 9-13, 1999a.
- Lajeunie E, Cameron R, El Ghouzzi V, De Parseval N, Journeau P, Gonzales M, Delezoide AL, Bonaventure J, Le Merrer M, Renier D.** Clinical variability in patients with Apert's syndrome. *J. Neurosurg.* 90: 443-447, 1999b.
- Ma HW, Lajeunie E, Le Merrer M, De Parseval N, Serville F, Weissenbach J, Munnich A, Renier D.** No evidence of genetic heterogeneity in Crouzon craniofacial dysostosis. *Hum. Genet.* 96: 731-735, 1995.
- Mangasarian K, Li Y, Mansukhani A, Basilico C.** Mutation associated with Crouzon syndrome causes ligand-independent dimerization and activation of FGF receptor-2. *J. Cell. Physiol.* 172: 117-125, 1997.
- Markens IS.** Embryonic development of the coronal suture in man and rat. *Acta Anat.* 93: 257-273, 1975.
- Mathijssen IMJ, Vaandrager JM, Hoogeboom AJM, Hesselings-Janssen ALW, Van Den Ouweland AMW.** Pfeiffer's syndrome resulting from a Ser351Cys mutation in the fibroblast growth factor receptor-2 gene. *J. Craniofac. Surg.* 9: 207-209, 1998.
- Mathijssen IMJ, Vermeij-Keers Chr, Hovius SER, Vaandrager JM.** The role of programmed cell death in the pathogenesis of craniosynostosis. Abstract. *Eur. J. Plast. Surg.* 22: 344, 1999.



- McCarthy JG, Schreiber J, Karp N, Thorne CH, Grayson BH.** Lengthening the human mandible by gradual distraction. *Plast. Reconstr. Surg.* 89: 1-8, 1992.
- McCarthy JG, Glasberg SB, Cutting CB, Epstein FJ, Grayson BH, Ruff G, Thorne CH, Wisoff J, Zide BM.** Twenty-year experience with early surgery for craniosynostosis: I. Isolated craniofacial synostosis - Results and unsolved problems. *Plast. Reconstr. Surg.* 96: 272-283, 1995a.
- McCarthy JG, Glasberg SB, Cutting CB, Epstein FJ, Grayson BH, Ruff G, Thorne CH, Wisoff J, Zide BM.** Twenty-year experience with early surgery for craniosynostosis: II. The craniofacial synostosis syndromes and pansynostosis – Results and unsolved problems. *Plast. Reconstr. Surg.* 96: 284-295, 1995b.
- Mehrara BJ, Mackool RJ, McCarthy JG, Gittes GK, Longaker MT.** Immunolocalization of basic fibroblast growth factor and fibroblast growth factor receptor-1 and receptor-2 in rat cranial sutures. *Plast. Reconstr. Surg.* 102: 1805-1817, 1998.
- Meyers GA, Orlow SJ, Munro IR, Przylepa KA, Jabs EW.** Fibroblast growth factor receptor 3 (FGFR3) transmembrane mutation in Crouzon syndrome with acanthosis nigricans. *Nature Genet.* 11: 462-464, 1995.
- Meyers GA, Day D, Goldberg R, Daentl DL, Przylepa KA, Abrams LJ, Graham JM Jr., Feingold M, Moeschler JB, Rawnsley E, Scott AF, Jabs EW.** FGFR2 exon IIIa and IIIc mutations in Crouzon, Jackson-Weiss, and Pfeiffer syndromes: Evidence for missense changes, insertions, and a deletion due to alternative RNA splicing. *Am. J. Hum. Genet.* 58: 491-498, 1996.
- Miki T, Bottaro DP, Fleming TP, Smith CL, Burgess WH, Chan AML, Aaronson SA.** Determination of ligand-binding specificity by alternative splicing: Two distinct growth factor receptors encoded by a single gene. *Proc. Natl. Acad. Sci.* 89: 246-250. 1992.
- Minchin H.** Contributions to craniology. *Quart. J. Med. Sc.* 22: 350-375, 1856.
- Moloney DM, Slaney SF, Oldridge M, Wall SA, Sahlin P, Stenman G, Wilkie AOM.** Exclusive paternal origin of new mutations in Apert syndrome. *Nat. Genet.* 13: 48-53, 1996.
- Moloney DM, Wall SA, Ashworth GJ, Oldridge M, Glass IA, Francomano CA, Muenke M, Wilkie AOM.** Prevalence of

- Pro250Arg mutation of fibroblast growth factor receptor 3 in coronal craniosynostosis. *Lancet* 349: 1059-1062, 1997.
- Mooney MP, Dechant JJ, Cooper GM, Smith TD, Burrows AM, Losken HW, Mathijssen IMJ, Siegel MI.** Frontoparietal bone ossification center location in craniosynostotic rabbits. Abstract. *Am. J. Dental Res.*: 77: 185, 1998.
- Morselli E.** Sur la scaphocéphalie. *Bull. Soc. d'Anthrop. Par.* 10: 443, 1875.
- Moss LM.** Functional anatomy of cranial synostosis. *Child's Brain* 1: 22-33, 1975.
- Muenke M, Schell U, Hehr A, Robin NH, Losken HW, Schinzel A, Pulleyn LJ, Rutland P, Reardon W, Malcolm S, Winter RM.** A common mutation in the fibroblast growth factor receptor 1 gene in Pfeiffer syndrome. *Nature Genet.* 8: 269-274, 1994.
- Muenke M, Schell U.** Fibroblast-growth-factor receptor mutations in human skeletal disorders. *TIG* 11: 308-313, 1995.
- Muenke M, Gripp KW, McDonald-McGinn DM, Gaudenz K, Whitaker LA, Bartlett SP, Markowitz RI, Robin NH, Nwokoro N, Mulvihill JJ, Losken HW, Mulliken JB, Guttmacher AE, Wilroy RS, Clarke LA, Hollway G, Adès LC, Haan EA, Mulley JC, Cohen MM Jr., Bellus GA, Francomano CA, Moloney DM, Wall SA, Wilkie AOM, Zackai EH.** A unique point mutation in the fibroblast growth factor receptor 3 gene (FGFR3) defines a new craniosynostosis syndrome. *Am. J. Hum. Genet.* 60: 555-564, 1997.
- Mulvihill JJ.** Craniofacial syndromes: No such thing as a single gene disease. *Nat. Genet.* 9: 101-103, 1995.
- Murdoch-Kinch CA, Ward RE.** Metacarpophalangeal analysis in Crouzon syndrome: Additional evidence for phenotypic convergence with the acrocephalosyndactyly syndromes. *Am. J. Med. Genet.* 73: 61-66, 1997.
- Neilson KM, Friesel R.** Constitutive activation of fibroblast growth factor receptor-2 by a point mutation associated with Crouzon syndrome. *J. Biol. Chem.* 270: 26037-26040, 1995.
- Oldridge M, Wilkie AOM, Slaney SF, Poole MD, Pulleyn LJ, Rutland P, Hockley AD, Wake MJC, Goldin JH, Winter RM, Reardon W, Malcolm S.** Mutations in the third immunoglobulin domain of the fibroblast growth factor receptor-2 gene in Crouzon syndrome. *Hum. Molec. Genet.* 4: 1077-1082, 1995.

- Oldridge M, Lunt PW, Zackai EH, McDonald-McGinn DM, Muenke M, Moloney DM, Twigg SRF, Heath JK, Howard TD, Hoganson G, Gagnon DM, Jabs EW, Wilkie AOM.** Genotype-phenotype correlation for nucleotide substitutions in the IgII-IgIII linker of FGFR2. *Hum. Molec. Genet.* 6: 137-143, 1997.
- Oldridge M, Zackai EH, McDonald-McGinn DM, Iseki S, Morriss-Kay GM, Twigg SRF, Johnson D, Wall SA, Jiang W, Theda C, Jabs EW, Wilkie AOM.** De novo alu-element insertions in FGFR2 identify a distinct pathological basis for Apert syndrome. *Am. J. Hum. Genet.* 64: 446-461, 1999.
- Opperman LA, Sweeney TM, Redmon J, Persing JA, Ogle RC.** Tissue interactions with underlying dura mater inhibit osseous obliteration of developing cranial sutures. *Dev. Dynam.* 198: 312-322, 1993.
- Opperman LA, Passarelli RW, Morgan EP, Reintjes M, Ogle RC.** Cranial sutures require tissue interactions with dura mater to resist osseous obliteration in vitro. *J. Bone Min. Res.* 10: 1978-1987, 1995.
- Opperman LA, Passarelli RW, Nolen AA, Gampper TJ, Lin KL, Ogle RC.** Dura mater secretes soluble heparin-binding factors required for cranial suture morphogenesis. *In Vitro Cell. Dev. Biol.* 32: 627-632, 1996.
- Opperman LA, Nolen AA, Ogle RC.** TGF $\beta$ 1, TGF $\beta$ 2, and TGF $\beta$ 3 exhibit distinct patterns of expression during cranial suture formation and obliteration in vivo and in vitro. *J. Bone Miner. Res.* 12: 301-310, 1997.
- Opperman LA, Chhabra A, Nolen AA, Bao Y, Ogle RC.** Dura mater maintains rat cranial sutures in vitro by regulating suture cell proliferation and collagen production. *J. Craniofac. Genet. Dev. Biol.* 18: 150-158, 1998.
- Ozaki W, Buchman SR, Muraszko KM, Coleman D.** Investigation of the influences of biomechanical force on the ultrastructure of human sagittal craniosynostosis. *Plast. Reconstr. Surg.* 102: 1385-1394, 1998.
- Park EA, Powers GF.** Acrocephaly and scaphocephaly with symmetrically distributed malformations of the extremities. *Am. J. Dis. Childr.* 20: 234-315, 1920.

- Park WJ, Meyers GA, Li X, Theda C, Day D, Orlow SJ, Jones MC, Jabs EW.** Novel FGFR2 mutations in Crouzon and Jackson-Weiss syndromes show allelic heterogeneity and phenotypic variability. *Hum. Molec. Genet.* 4: 1229-1233, 1995.
- Passos-Bueno MR, Sertié AL, Richieri-Costa A, Alonso LG, Zatz M, Alonso N, Brunoni D, Ribeiro SFM.** Description of a new mutation and characterization of FGFR1, FGFR2, and FGFR3 mutations among Brazilian patients with syndromic craniosynostosis. *Am. J. Med. Genet.* 78: 237-241, 1998a.
- Passos-Bueno MR, Richieri-Costa A, Sertié AL, Kneppers A.** Presence of the Apert canonical S252W FGFR2 mutation in a patient without severe syndactyly. *J. Med. Genet.* 35: 677-679, 1998b.
- Paznekas WA, Cunningham ML, Howard TD, Korf BR, Lipson MH, Grix AW, Feingold M, Goldberg R, Borochowitz Z, Aleck K, Mulliken J, Yin M, Jabs EW.** Genetic heterogeneity of Saethre-Chotzen syndrome, due to TWIST and FGFR mutations. *Am. J. Hum. Genet.* 62: 1370-1380, 1998.
- Pfeiffer RA.** Dominant erbliche Akrocephalosyndactylie. *Z. Kinderheilkd.* 90: 310-320, 1964.
- Plomp AS, Hamel BCJ, Cobben JM, Verloes A, Offermans JPM, Lajeunie E, Fryns JP, De Die-Smulders CEM.** Pfeiffer syndrome type 2: Further delineation and review of the literature. *Am. J. Med. Genet.* 75: 245-251, 1998.
- Pritchard JJ, Scott JH, Girgis FG.** The structure and development of cranial and facial sutures. *J. Anat.* 90: 73-86, 1956.
- Przylepka KA, Paznekas W, Zhang M, Golabi M, Bias W, Bamshad MJ, Carey JC, Hall BD, Stevenson R, Orlow SJ, Cohen MM Jr., Jabs EW.** Fibroblast growth factor receptor 2 mutations in Beare-Stevenson cutis gyrata syndrome. *Nat. Genet.* 13: 492-494, 1996.
- Pulley LJ, Reardon W, Wilkes D, Rutland P, Jones BM, Hayward R, Hall CM, Brueton L, Chun N, Lammer E, Malcolm S, Winter RM.** Spectrum of craniosynostosis phenotypes associated with novel mutations at the fibroblast growth factor receptor 2 locus. *Eur. J. Hum. Genet.* 4: 283-291, 1996.

- Ray PN, Siegel-Bartelt J, Chun K.** A unique mutation in TWIST causes Saethre-Chotzen syndrome. Abstract. Am. J. Hum. Genet. Suppl. 61: A344, 1997.
- Reardon W, Winter RM, Rutland P, Pulleyn LJ, Jones BM, Malcolm S.** Mutations in the fibroblast growth factor 2 gene cause Crouzon syndrome. Nature Genet. 8: 98-103, 1994.
- Reardon W, Winter RM.** The molecular pathology of syndromic craniosynostosis. Molec. Med. Today 1: 432-437, 1995.
- Renier D, Sainte-Rose C, Marchac D, Hirsch JF.** Intracranial pressure in craniostenosis. J. Neurosurg. 57: 370-377, 1982.
- Rice DPC, Åberg T, Chan Y-S, Tang Z, Kettunen PJ, Pakarinen L, Maxson RE, Thesleff I.** Integration of FGF and TWIST in calvarial bone and suture development. Development 127: 1845-1855, 2000.
- Rieping A.** Zur Pathogenese des Turmschädels. Dtsch. Zeitschr. Chir. 148: 1-51, 1919.
- Risch N, Reich EW, Wishnick MM, McCarthy JG.** Spontaneous mutation and parental age in humans. Am.J. Hum. Genet. 41: 218-248, 1987.
- Robertson SC, Meyer AN, Hart KC, Galvin BD, Webster MK, Donoghue DJ.** Activating mutations in the extracellular domain of the fibroblast growth factor receptor 2 function by disruption of the disulfide bond in the third immunoglobulin-like domain. Proc. Nat. Acad. Sci. 95: 4567-4572, 1998.
- Robin NH, Feldman GJ, Mitchell HF, Lorenz P, Wilroy RS, Zackai EH, Allanson JE, Reich EW, Pfeiffer RA, Clarke LA, Warman ML, Mulliken JB, Brueton LA, Winter RM, Price RA, Gasser DL, Muenke M.** Linkage of Pfeiffer syndrome to chromosome 8 centromere and evidence for genetic heterogeneity. Hum. Molec. Genet. 3: 2153-2158, 1994.
- Robin NH, Segel B, Carpenter G, Muenke M.** Craniosynostosis, Philadelphia type: A new autosomal dominant syndrome with sagittal craniosynostosis and syndactyly of the fingers and toes. Am. J. Med. Genet. 62: 184-191, 1996.
- Robin NH, Scott JA, Arnold JE, Goldstein JA, Shilling BB, Marion RW, Cohen MM Jr.** Favorable prognosis for children with Pfeiffer syndrome types 2 and 3: Implications for classification. Am. J. Med. Genet. 75: 240-244, 1998a.

- Robin NH, Scott JA, Cohen AR, Goldstein JA.** Nonpenetrance in FGFR3-associated coronal synostosis syndrome. *Am. J. Med. Genet.* 80: 296-297, 1998b.
- Rose CSP, Patel P, Reardon W, Malcolm S, Winter RM.** The TWIST gene, although not disrupted in Saethre-Chotzen patients with apparently balanced translocations of 7p21, is mutated in familial and sporadic cases. *Hum. Mol. Genet.* 6: 1369-1373, 1997.
- Rutland P, Pulleyn LJ, Reardon W, Baraitser M, Hayward R, Jones B, Malcolm S, Winter RM, Oldridge M, Slaney SF, Poole MD, Wilkie AOM.** Identical mutations in the FGFR2 gene cause both Pfeiffer and Crouzon syndrome phenotypes. *Nature Genet.* 9: 173-176, 1995.
- Saethre H.** Ein Beitrag zum Turmschädelproblem (Pathogenese, Erbllichkeit und Symptomologie). *Deut. Zeitschr. Nervenheilk.* 117: 533-555, 1931.
- Schaeffer F, Anderson C, Can B, Say B.** Novel mutation in the FGFR2 gene at the same codon as the Crouzon syndrome mutations in a severe Pfeiffer syndrome type 2 case. *Am. J. Med. Genet.* 75: 252-255, 1998.
- Schell U, Hehr A, Feldman GJ, Robin NH, Zackai EH, De Die-Smulders C, Viskochil DH, Stewart JM, Wolff G, Ohashi H, Price RA, Cohen MM Jr., Muenke M.** Mutations in FGFR1 and FGFR2 cause familial and sporadic Pfeiffer syndrome. *Hum. Molec. Genet.* 4: 323-328, 1995.
- Shishido E, Higashijima S, Emori Y, Saigo K.** Two FGF-receptor homologues of Drosophila: One is expressed in mesodermal primordium in early embryos. *Development* 117: 751-761, 1993.
- Slaney SF, Oldridge M, Hurst JA, Morriss-Kay GM, Hall CM, Poole MD, Wilkie AOM.** Differential effects of FGFR2 mutations on syndactyly and cleft palate in Apert syndrome. *Am. J. Hum. Genet.* 58: 923-932, 1996.
- Starck KL, McMahon JA, McMahon AP.** FGFR-4, a new member of the fibroblast growth factor receptor family, expressed in the definitive endoderm and skeletal muscle lineages of the mouse. *Development* 113: 641-651, 1991.
- Stavrou P, Sgouros S, Willshaw HE, Goldin JH, Hockley AD, Wake MJC.** Visual failure caused by raised intracranial pressure in craniosynostosis. *Child's Nerv. Syst.* 13: 64-67, 1997.

- Steinberger D, Reinhartz T, Unsöld R, Müller U.** FGFR2 mutation in clinically nonclassifiable autosomal dominant craniosynostosis with pronounced phenotypic variation. *Am. J. Med. Genet.* 66: 81-86, 1996a.
- Steinberger D, Mulliken JB, Müller U.** Crouzon syndrome: Previously unrecognized deletion, duplication, and point mutation within FGFR2 gene. *Hum. Mutation* 8: 386-390, 1996b.
- Steinberger D, Collmann H, Schmalenberger B, Müller U.** A novel mutation (A886G) in exon 5 of FGFR2 in members of a family with Crouzon phenotype and plagiocephaly. *J. Med. Genet.* 34: 420-422, 1997.
- Steinberger D, Vriend G, Mulliken JB, Müller U.** The mutations in FGFR2-associated craniosynostoses are clustered in five structural elements of immunoglobulin-like domain III of the receptor. *Hum. Genet.* 102: 145-150, 1998.
- Stelnicki EJ, Vanderwall K, Hoffman WY, Harrison MR, Glowacki J, Longaker MT.** A new in utero sheep model for unilateral coronal craniosynostosis. *Plast. Reconstr. Surg.* 101: 278-286, 1998a.
- Stelnicki EJ, Vanderwall K, Harrison MR, Longaker MT, Kaban LB, Hoffman WY.** The in utero correction of unilateral coronal craniosynostosis. *Plast. Reconstr. Surg.* 101: 287-296, 1998b.
- Stevenson RE, Ferlauto GJ, Taylor HA.** Cutis gyratum and acanthosis nigricans associated with other anomalies: A distinctive syndrome. *J. Pediatr.* 92: 950-952, 1978.
- Tartaglia M, Valeri S, Velardi F, Di Rocco C, Battaglia PA.** Trp290Cys mutation in exon IIIa of the fibroblast growth factor receptor 2 (FGFR2) gene is associated with Pfeiffer syndrome. *Hum. Genet.* 99: 602-606, 1997a.
- Tartaglia M, Di Rocco C, Lajeunie E, Valeri S, Velardi F, Battaglia PA.** Jackson-Weiss syndrome: Identification of two novel FGFR2 missense mutations shared with Crouzon and Pfeiffer craniosynostotic disorders. *Hum. Genet.* 101: 47-50, 1997b.
- Tartaglia M, Bordoni V, Velardi F, Basile RT, Saulle E, Tenconi R, Di Rocco C, Battaglia PA.** Fibroblast growth factor receptor mutational screening in newborns affected by metopic synostosis. *Child's Nerv. Syst.* 15: 389-394, 1999.

- Ten Cate AR, Freeman E, Dickinson JB.** Sutural development: Structure and its response to rapid expansion. *Am. J. Orthod.* 71: 622-636, 1977.
- Thoma R.** *Virchow's Arch.* 225: 97, 1918.
- Twigg SRF, Burns HD, Oldridge M, Heath JK, Wilkie AOM.** Conserved use of a non-canonical 5' splice site (/GA) in alternative splicing by fibroblast growth factor receptors 1, 2 and 3. *Hum. Molec. Genet.* 7: 685-691, 1998.
- Vaandrager JM, Mathijssen IMJ, Vermeij-Keers Chr.** Embryopathogenesis of craniosynostosis: A concept of bone center malpositioning. In: *Proceedings of the Sixth International Congress of the International Society of Craniofacial Surgery.* Bologna. Monduzzi Editore, p. 91-92, 1995.
- Van Dissel-Emiliani FMF, De Boer-Brouwer M, De Rooij DG.** Effects of fibroblast growth factor-2 on Sertoli cells and gonocytes in coculture during the perinatal period. *Endocrinol.* 137: 647-654, 1996.
- Virchow R.** Über den Cretinismus, namentlich in Franken, und über pathologische Schadelformen. *Verh. Phys. Med. Gesamte Würzburg* 2: 230, 1852.
- Von Gernet S, Golla A, Ehrenfels Y, Schuffenhauer S, Fairley JD.** Genotype-phenotype analysis in Apert syndrome suggests opposite effects of the two recurrent mutations on syndactyly and outcome of craniofacial surgery. *Clin. Genet.* 57: 137-1349, 2000.
- Webster MK, Donoghue DJ.** FGFR activation in skeletal disorders: Too much of a good thing. *TIG* 13: 178-182, 1997.
- Wilkes D, Rutland P, Pulleyn LJ, Reardon W, Moss C, Ellis JP, Winter RM, Malcolm S.** A recurrent mutation, Ala391Glu, in the transmembrane region of FGFR3 causes Crouzon syndrome and acanthosis nigricans. *J. Med. Genet.* 33: 744-748, 1996.
- Wilkie AOM, Morriss-Kay GM, Jones EY, Heath JK.** Functions of fibroblast growth factors and their receptors. *Curr. Biol.* 5: 500-507, 1995a.
- Wilkie AOM, Slaney SF, Oldridge M, Poole MD, Ashworth GJ, Hockley AD, Hayward RD, David DJ, Pulleyn LJ, Rutland P, Malcolm S, Winter RM, Reardon W.** Apert syndrome results from localized mutations of FGFR2 and is allelic with Crouzon syndrome. *Nature Genet.* 9: 165-172, 1995b.



- Wilkie AOM.** Craniosynostosis: Genes and mechanisms. *Hum. Mol. Genet.* 6: 1647-1656, 1997.
- Wyman J.** Observations on Crania. *Proc. Bost. Soc. Nat. Hist.* 11, 1868.
- Yoshiura K, Leysens NJ, Chang J, Ward D, Murray JC, Muenke M.** Genomic structure, sequence, and mapping of human FGF8 with no evidence for its role in craniosynostosis/limb defect syndromes. *Am. J. Med. Genet.* 72: 354-362, 1997.
- Zackai EH, Stolle CA.** A new TWIST: Some patients with Saethre-Chotzen syndrome have a microdeletion syndrome. *Am. J. Hum. Genet.* 63: 1277-1281, 1998.



**II. MORPHOLOGIC STUDY OF THE HUMAN CALVARIA  
IN CRANIOSYNOSTOSIS**



**II.1. The role of bone centers in the pathogenesis of  
craniosynostosis: An embryologic approach using CT  
measurements in isolated craniosynostosis and Apert and  
Crouzon syndromes.**

Mathijssen IMJ, Vaandrager JM, Van Der Meulen JC,  
Pieterman H, Zonneveld FW, Kreiborg S, Vermeij-Keers Chr.

*Plastic and Reconstructive Surgery 98: 17-26, 1996.*



# The Role of Bone Centers in the Pathogenesis of Craniosynostosis: An Embryologic Approach Using CT Measurements in Isolated Craniosynostosis and Apert and Crouzon Syndromes

Irene M. J. Mathijssen, M.D., J. M. Vaandrager, M.D., J. C. van der Meulen, M.D., Ph.D.,  
H. Pieterman, M.D., F. W. Zonneveld, Ph.D., S. Kreiborg, D.M.D., Ph.D.,  
and C. Vermeij-Keers, M.D., Ph.D.

*Rotterdam and Utrecht, The Netherlands, and Copenhagen, Denmark*

This paper describes the role of the displacement of bone centers, i.e., the tubers, in the pathogenesis of craniosynostosis. This displacement was studied in 54 patients with isolated or syndromic craniosynostosis in the form of CT scans as well as in two dry neonate skulls with Apert syndrome. For comparison, 49 fetal and 8 normal infant dry skulls were studied. Our investigation was restricted to the coronal and metopic sutures. The results showed a significantly more occipital localization of the frontal bone center and a more frontal localization of the parietal bone center at the side of a synostotic coronal suture in the isolated form as well as in Apert syndrome. In contrast, this was not the case in Crouzon syndrome, thus showing that these two syndromes have a different pathogenesis. For trigonocephaly, a more anteromedial localization of the frontal bone centers was found. (*Plast. Reconstr. Surg.* 98: 17, 1996.)

Craniosynostosis is generally considered as a premature closure of cranial sutures resulting in cranial deformity.<sup>1</sup> One of the classifications of craniosynostosis designates the isolated and the syndromic craniosynostoses.<sup>2</sup> In the isolated form, no other abnormalities, except those which may occur secondary to early sutural obliteration, are found, e.g., unilateral or bilateral coronal suture synostosis and metopic suture synostosis. In syndromic craniosynostosis, other primary defects of morphogenesis occur. The Apert and Crouzon syndromes are examples of this latter group.

From the Departments of Plastic and Reconstructive Surgery and Radiology at the Academic Hospital Rotterdam, the Department of Radiology at the Academic Hospital Utrecht, and the Department of Pediatric Dentistry at the University of Copenhagen. Received for publication July 19, 1995.

Little is known about the pathogenesis of craniosynostosis. Genetics plays an important role, and recently, the genes for Apert, Crouzon, Pfeiffer, and Saethre-Chotzen syndromes have been located.<sup>3-6</sup> Craniosynostosis is considered to be a late developmental defect during embryogenesis ( $\geq 17$  mm crown-rump length).<sup>7-9</sup> Our goal in this study was to explain the etiology of coronal and metopic suture synostosis from an embryologic point of view in both the isolated and the syndromic forms.

## EMBRYOLOGY

During normal development of the skull, the frontal bone and both parietal bones are formed by ossification of membrane anlagen. The frontal bone starts to ossify in a pair of bone centers, one left and one right, and each parietal bone in two fusing bone centers.<sup>10,11</sup> According to several authors, the frontal bone centers arise in the developmental stage of 26 to 35 mm crown-rump length,<sup>9,12-15</sup> and the parietal bone centers arise in stage 31 to 45 mm crown-rump length.<sup>9,12-14</sup> Subsequently, ossification extends radially toward the margins with the tubers, being the most prominent portion of the bone, situated in the center of the thus formed radiating growth pattern of the bone.<sup>11,16</sup> According to *Gray's Anatomy*<sup>16</sup> and

Trotter and Peterson,<sup>17</sup> the original position of the frontal and parietal bone centers is represented by the frontal and parietal tubers, respectively, while Inman and Saunders,<sup>11</sup> Starck,<sup>14</sup> Hinrichsen,<sup>18</sup> and Macklin<sup>19</sup> do not adhere to this statement. Inman and Saunders,<sup>11</sup> for example, situated the frontal bone centers in the superciliary region.

Normally, the metopic suture, formed by the frontal bone centers, ossifies during the second year of life. The coronal suture, developed bilaterally by the frontal and fused parietal bone centers, begins to close at 24 years of age.<sup>20</sup> Apoptosis (programmed cell death) appears to prevent fusion of bone centers and therefore causes the existence of the sutures.<sup>9,21</sup>

On abnormal development of the skull, the literature reports agenesis of the bone centers with subsequent agenesis of the involved bone<sup>7,22-25</sup> and failure of bone centers to fuse where they normally do, resulting in the formation of an extra suture, e.g., the bipartite parietal bone.<sup>26-28</sup> An extra bone center within one bone also can cause an extra suture, as is seen in the bipartite zygomatic bone.<sup>8,9</sup> Trigonoccephaly was described as the result of the frontal bone developing from one single bone center.<sup>8</sup> Moreover, Vermeij-Keers<sup>9</sup> has suggested that craniosynostosis could be caused during embryogenesis by direct fusion of bone centers. Describing the infant Apert skull, Kreiborg and Cohen<sup>29</sup> mentioned that proper sutures do not form in the coronal or sagittal areas. Because of this sutural agenesis, adjacent centers of ossification would no longer be prevented from coalescing, resulting in bony fusion across coronal suture areas. Furthermore, Wrete<sup>30</sup> noted the lack of both the frontal and parietal tubers in bilateral synostosis of the coronal suture and the lack of frontal tubers in trigonoccephaly, but without drawing any conclusions from his finding.

It is postulated here that during embryogenesis, adjacent bone centers, being displaced toward the synostotic suture, can undergo direct fusion of these bone centers. Subsequently, there is no development of the coronal suture, for example, at this level. This malformation can occur unilaterally in unilateral coronal suture synostosis and bilaterally in bilateral coronal suture synostosis and in Apert syndrome. Basically the same mechanism occurs when both bone centers of the frontal bone are located more anteromedially. Direct fusion between them takes place, without formation of

the metopic suture, giving rise to a trigonoccephalic skull.

#### COMPUTED TOMOGRAPHY

Computed tomography (CT) has been shown to be a very sensitive method for detecting craniosynostosis.<sup>31</sup> Sutures of the calvaria are most accurately identified on high-resolution CT scans, using 1.5- or 2.0-mm-thick sections,<sup>32</sup> depending on the type of scanner. Three-dimensional reconstruction from CT images is of great value in understanding the pathologic morphology of the patient and in the preparation for craniofacial surgery.<sup>33-35</sup>

Craniofacial measurements obtained from CT scans are accurate and reproducible.<sup>36,37</sup> The technique is easy to master, and the objective data obtained can be used to assist in diagnosis, guide preoperative planning, and document results after surgical correction.<sup>37-41</sup> Waitzman et al.<sup>42</sup> created a base of normative CT data for the upper part of the craniofacial skeleton. Carr et al.<sup>43</sup> compared these values with measurements derived from patients with Apert and Crouzon syndromes under the age of 1 year and in addition compared Apert with Crouzon syndrome. Data from their study, however, did not show major differences between patients with the Apert and Crouzon syndromes despite morphologic differences. According to Carr et al.<sup>43</sup> and Kreiborg and Pruzansky,<sup>44</sup> measurements in other planes or of other structures are necessary to differentiate the morphology of these syndromes quantitatively.

By studying dry skulls, dry-skull CT scans, and CT scans derived from patients with craniosynostosis, we have evaluated the relationship between tubers and bone centers, as well as their involvement in coronal and metopic suture synostosis in the isolated form, in Apert and Crouzon syndromes. New CT measurements, based on our suggested embryologic etiology for coronal and metopic suture synostosis, are introduced.

#### MATERIALS AND METHODS

##### *Subjects*

In order to study the involvement of the frontal and parietal tubers and bone centers in coronal and metopic suture synostosis compared with normal, macroscopic observations were performed of 49 normal fetal dry skulls (ranging in age from 15 to 40 weeks), eight normal dry skulls of infants (estimated age 1 to 4 years),



and two dry neonatal Apert skulls of the teratologic collection of the Museum of Anatomy of Leiden University. Unfortunately, no infant dry Crouzon skulls were available.

To trace the tubers on a CT scan in an anteroposterior direction, we first marked the frontal and parietal tubers with clay before taking the axial CT scan. This procedure was done for one normal fetal skull (approximately 6.5 months) and for the two Apert skulls. Based on the findings of these scans, we developed new CT measurements for locating the tubers. This enabled us to locate the frontal and parietal tubers on CT scans of our patients.

To validate this method, a comparison of the results of locating the tubers on the dry-skull CT scans using our new measurements with identifying them by clay marking was made.

A retrospective study of CT scan series of 54 patients with an isolated or syndromic cranio-synostosis was undertaken using our new variables. Only complete, good-quality CT series of unoperated children, ranging in age from 1 month to 20 years, were selected. The age and gender distributions of the samples under study are outlined in Table I.

The scans had been made for the purpose of three-dimensional imaging. The population under study was classified according to the synostotic sutures, with Apert and Crouzon syndromes kept separate, the metopic suture being considered synostotic only if it had resulted in a trigonocephalic configuration of the skull (Table II).

In order to compare the measurements for the synostotic with those for open coronal and metopic sutures, each suture was classified as being open, synostotic, or uncertain. Four of the 54 patients had a synostotic metopic suture,

TABLE I  
Age and Gender Distribution of Patients

Age Category	Females	Males	Total
0-3 months	6	5	11
4-6 months	5	8	13
7-9 months	2	3	5
10-11 months	2	5	7
1 years	5	4	9
2 years	2	1	3
3 years	-	1	1
4 years	-	1	1
5 years	1	-	1
7 years	1	-	1
13 years	-	1	1
20 years	1	-	1
TOTAL	25	29	54

TABLE II  
Population Under Study, Classified According to the Synostotic Sutures, Apart from Apert and Crouzon Syndromes

Synostotic Suture(s)	No. of Patients	Syndrome Involved
	9	Apert
	7	Crouzon
Coronal, unilateral	10	
Coronal, bilateral	8	
Sagittal	10	
Lambdoid	6	
Metopic	3	
Lambdoid + metopic	1	
TOTAL	54	

resulting in a trigonocephalic skull. Of the remaining 50 patients, 100 coronal sutures were classified; 42 were synostotic, 43 were open, and for 15 ossification was uncertain (Table III). Since no CT scans obtained by the same procedures were available of normal, age-matched controls, we compared open with synostotic sutures within our population of patients.

#### Computed Tomographic Procedures

The axial CT scans of the dry skulls were taken with a Siemens Somatom Plus VD30 CT scanner using 2.0-mm slices (Department of Radiology, University of Rotterdam). Axial CT scans of the patients were obtained with a Philips Tomoscan LX CT scanner and a Philips Tomoscan 350 using 1.5-mm contiguous slices. General anesthesia was used for children under age 12 (Department of Radiology, University of Utrecht).

#### Measurements

The four new variables in the cranial region (Table IV) were measured and standardized with reference to the 5-cm scale bar on each film. For that purpose, we first made a copy of the required slice in order to measure more precisely. To obtain data, the slice transecting the most anterolateral points of the lateral ven-

TABLE III  
Classification of the Studied Coronal Sutures after Separating Patients with Trigonocephaly (n = 100)

	Synostotic	Open	Uncertain
Apert	18	-	-
Crouzon	3	5	6
Other	21	38	9
TOTAL	42	43	15

TABLE IV  
Computed Tomographic Measurements of the Bone Centers

Measurement	Description
Frontal bone center angle	Sharpest angle, left and right sides, at the frontal bone (see Fig. 4a)
Frontal bone center distance	Distance between the frontal bone center angle and the most frontal point of the outer table of the skull (see Fig. 4b)
Parietal bone center angle	Sharpest angle, left and right sides, at the parietal bone (see Fig. 4c)
Parietal bone center distance	Distance between the parietal bone center angle and the most frontal point of the outer table of the skull (see Fig. 4d)

tricles and the occiput above theinion was used, according to Waitzman et al.<sup>42</sup>

Measurements of the four variables were repeated by the same person on two separate occasions to check intraobserver reproducibility.

#### Statistical Analysis

Statistical differences between group means were tested by Student's *t* test. Group means, standard deviations, and 95 percent confidence intervals were calculated for the measurement variables. Test statistics associated with probabilities of 0.05 or less were considered significant, and all probability (*p*) values were two-sided.

### RESULTS

#### Macroscopic Observations

Macroscopic observations of the fetal and infant skulls clearly showed the radiating growth

pattern of the frontal and parietal bones with, respectively, the frontal and parietal tubers in the center, as can be seen in Figure 1. This radiation was seen best in the fetal skulls, remaining visible until the age of approximately 1½ years with respect to the frontal bone and 4 years for the parietal bones. The position of the tubers, however, was very consistent.

Both Apert skulls clearly showed an abnormal radiating growth pattern of both frontal and parietal bones (Fig. 2) and a displacement of the tubers, being situated in the center of this pattern. The frontal tuber is situated more posterocaudally and the parietal tuber more anterocaudally. In between the frontal and parietal tubers the radiating growth pattern is absent, and fusion of the bones took place, instead of the expected normal development of the coronal suture. The coronal suture was formed cranial and, to a much lesser extent,




FIG. 1. Dry skull of a fetus showing the radiating growth pattern of the frontal and parietal bones with the frontal and parietal tubers in the center.

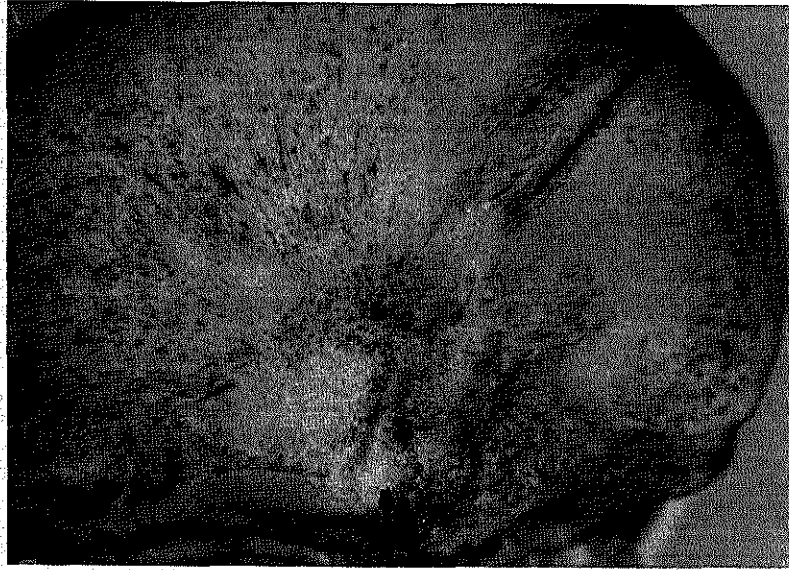

FIG. 2. Dry skull of Apert syndrome. Note the abnormal radiating growth pattern of both frontal and parietal bones in the Apert skull compared with normal (Fig. 1). The coronal suture had been developed only cranial and caudal to the side of fusion (arrows).

caudal to the locus of fusion. All abnormalities described were seen bilaterally.

#### *Computed Tomography*

On all scans of the three dry skulls, the clay-marked tuber, i.e., bone center, was found near the sharpest angle of the bone concerned (Fig. 3). This suggests that the frontal and parietal tubers can be located on a CT scan at the site of the sharpest angle of the frontal bone and the parietal bone, respectively, on the left and right sides. We measured this *bone center angle* as well as the distance between this point and the most frontal point of the outer table of the skull, the *bone center distance* (see Table IV).

In order to validate this method of measurement for locating the bone centers, the distance between the clay and the most frontal point of the outer table of the skull also was measured on the CT scan and compared with the previously described bone center distance (Table V).

The preceding comparison between both methods of measurement resulted in a mean difference of 0.3 mm with a 95 percent confidence limit of  $-1.2$  to  $1.9$ . This indicates that by identifying the bone center angle on CT scan, a good method for marking the position of the bone center in the anteroposterior direction has been obtained. These variables enabled us

to locate the bone centers on the CT scans of our 54 patients.

Figure 4 shows how measurements were taken from the CT scans of patients with isolated unilateral synostosis of the coronal suture (4.1), Apert syndrome (4.2), Crouzon syndrome (4.3), and isolated synostosis of the metopic suture (4.4).

Means and standard deviations were computed for each variable for gender. There were no significant differences for gender; with respect to the frontal bone center distance, the mean difference was 4.2 mm with 95 percent confidence limits of  $-0.7$  to  $9.1$ , and for the parietal bone center distance, the mean difference was 5.5 mm with 95 percent confidence limits of  $-2.3$  to  $13.3$ , so data were pooled.

The mean frontal bone center angle was 157 degrees, and the mean parietal bone center angle was 164 degrees. Intraobserver measurements of the frontal bone center distance resulted in a mean difference of 0.4 mm with a 95 percent confidence interval of 0.0 to 0.9. For the parietal bone center distance we found a mean difference of 0.2 mm with a 95 percent confidence interval of  $-0.4$  to  $0.8$ . Bone center distances and age did not correlate.

There was no statistical difference found between isolated synostotic coronal sutures and

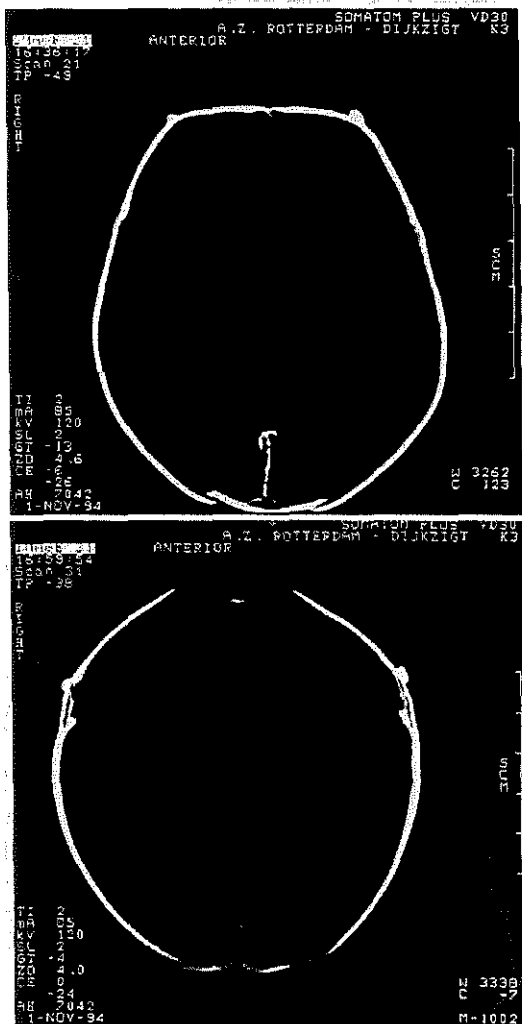


FIG. 3. CT scans taken from a normal fetal dry skull (above) and an Apert dry skull (below) with the clay indicating the frontal tuber, i.e., bone center.

Apert syndrome for both mean frontal and mean parietal bone center distances (the 95 percent confidence interval of the mean difference in frontal bone center distance was  $-0.6$  to  $+11.0$  mm; for parietal bone center distances the confidence interval was  $-3.1$  to  $+20.1$  mm). Therefore, data on isolated synostotic coronal sutures and Apert syndrome were pooled, collectively forming the synostotic group (Table VI).

Table VI presents the mean values for measurements of the frontal and parietal bone centers. The 95 percent confidence intervals for

the frontal and parietal bone center distances for synostotic coronal sutures were not overlapping with those for open coronal sutures. This implies a statistically significant more posterior localization of the frontal bone center and a more anterior localization of the parietal bone center at the side of the synostotic coronal suture in the isolated form as well as in Apert syndrome. In contrast, this was not the case in Crouzon syndrome. The observed synostosis of the coronal sutures in Crouzon syndrome can therefore not be explained by a displacement of the bone centers.

For trigonocephaly, a more medial localization of the frontal bone centers was found, with a normal position of the parietal bone centers in an anteroposterior direction.

#### DISCUSSION

The combination of an abnormal radiating growth pattern and displaced tubers together with fusion of the frontal and parietal bones in between these tubers instead of coronal suture development, found bilaterally on the dry Apert skulls, shows a close relationship between the localization of the tubers and bone centers involved. This finding suggests that the tubers do indicate the original position of the bone centers, as was stated in *Gray's Anatomy*<sup>16</sup> and by Trotter and Peterson.<sup>17</sup>

The presented CT measurements enabled us to locate the frontal and parietal bone centers on CT scans in an anteroposterior direction. The results of these measurements are in line with our theory that synostosis of coronal and metopic sutures can be explained by an abnormal localization of the bone centers involved.

Because of this displacement, the bone centers fuse, and subsequently, no suture is formed at this level. The partially developed suture, cranial and caudal to the site of fusion, ossifies gradually. Rather than premature ossification of an established suture, as is implied by the term *synostosis*, this process is the result of a direct fusion of adjacent bone centers. *Sutural agenesis*, a term used previously by Kokich,<sup>20</sup> Furtwängler et al.,<sup>21</sup> and Kreiborg and Cohen,<sup>29</sup> seems to be a more accurate description.

In both the isolated form of coronal suture synostosis and Apert syndrome, in which bilateral coronal suture synostosis is a constant finding,<sup>29,45</sup> a more posterior position of the frontal bone centers and a more anterior position of the parietal bone centers were found. In trigonocephalic skulls, the bone centers of the

TABLE V  
 Computed Tomographic Measurements of Bone Center Distance (mm) by Means of Clay Localization Compared with Bone Center Angle Localization

	Apert Dry Skull 1		Apert Dry Skull 2		Normal Fetal Dry Skull	
	Clay	Angle	Clay	Angle	Clay	Angle
Frontal bone center distance left	20	20	21.3	20	2.2	2.7
Frontal bone center distance right	25	22.5	17.5	15	2.2	2.2
Parietal bone center distance left	33.8	35.6	38.8	36.3	54.3	58.7
Parietal bone center distance right	38.8	38.8	35.0	37.5	53.3	48.9

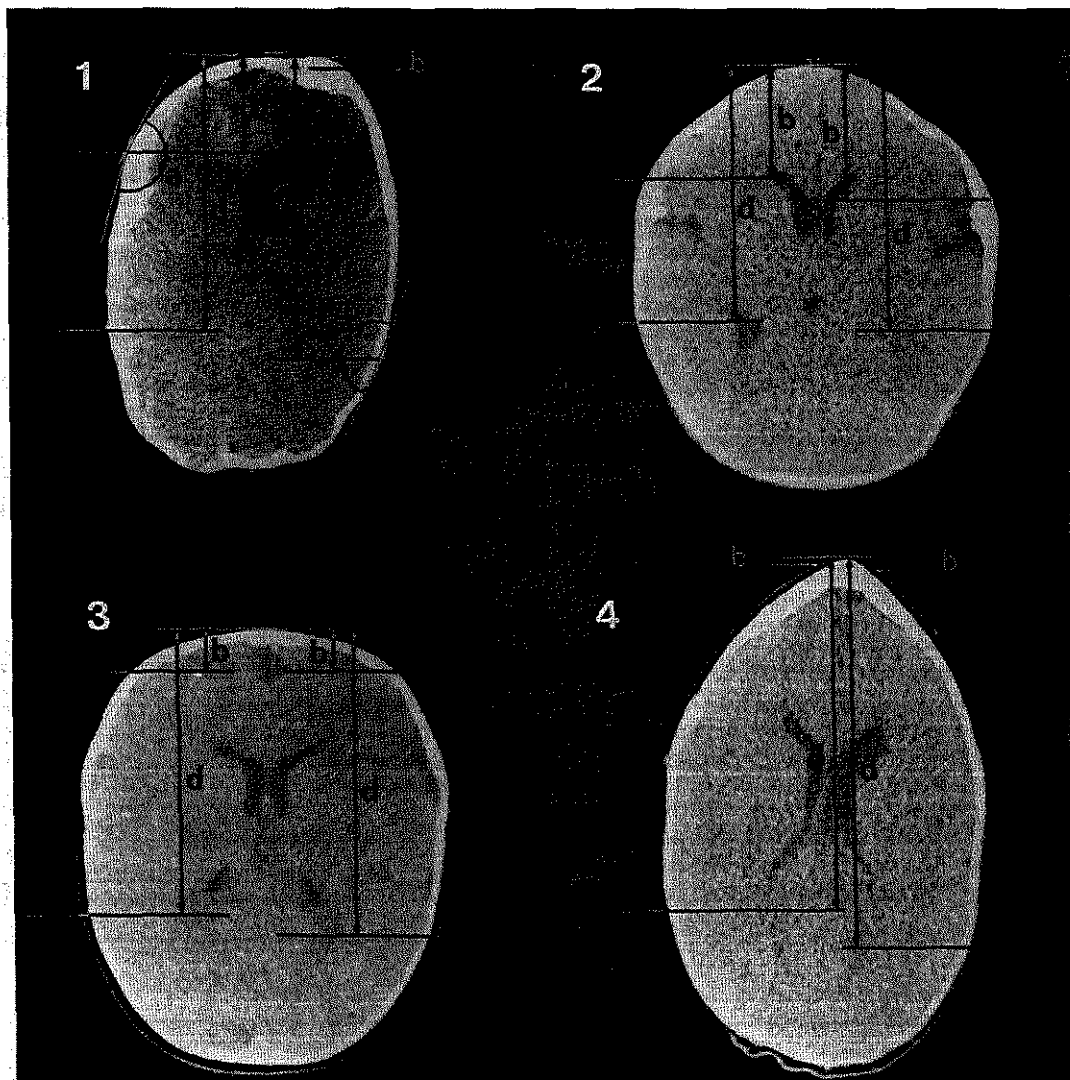


FIG. 4. Bone center measurements from axial CT scans: (4.1) plagiocephaly; (4.2) Apert; (4.3) Crouzon; (4.4) trigonocephaly. (a) Frontal bone center angle; (b) frontal bone center distance; (c) parietal bone center angle; (d) parietal bone center distance.

TABLE VI  
Measurements of the Frontal and Parietal Bone Center Distance

	Open* (n = 38)‡	Synostotic* (n = 39)‡	Crouzon (n = 14)‡	Trigonocephaly (n = 8)‡
Frontal bone center distance				
Mean (mm)	7.2	30.6	9.7	1.9
SD	3.3	9.1	5.4	2.2
95% CI (mm)	6.1-8.3	27.7-33.6	6.6-12.8	0.0-3.7
Parietal bone center distance				
Mean (mm)	95.0	71.6	98.3	103.1
SD	13.5	22.5	23.2	10.5
95% CI (mm)	90.5-99.4	64.3-78.9	84.9-111.7	94.3-111.9

\* Coronal suture.

† Metopic suture.

‡ Number of measurements.

CI = confidence interval.

frontal bone are localized almost completely in the median plane.

Apart from a displacement in the anteroposterior direction of the bone centers, our macroscopic inspection of the two dry Apert skulls also suggests a more caudal dispositioning. Measuring the bone center distances in this direction requires coronal reformatting of the scans, which we are currently working on. We suggest that the same principle of dislocated bone centers applies to other types of craniosynostosis, which will be studied in subsequent research.

Progressive calcification and fusion of the bones of the hands, feet, and cervical spine are known to occur in Apert syndrome.<sup>46,47</sup> Harris et al.<sup>48</sup> found abnormal epiphyseal ossification centers of the humerus and femur, fusion of calcaneus with cuboid, and fusion of the second and third metatarsal bones with other small bones in Apert syndrome and therefore suggested a more generalized involvement of enchondral ossification. Cohen<sup>49</sup> postulated that the same mechanism responsible for progressive calcification throughout the body is also responsible for the associated craniosynostosis in Apert syndrome. Our findings of a displacement of the ossification centers of the frontal and parietal bones in Apert syndrome make it seem likely that there is one basic ossification disorder for both enchondral and intramembranous ossification in this syndrome, probably leading to all the skeletal abnormalities observed.

The same abnormal localization of the frontal and parietal bone centers in the horizontal plane present in Apert syndrome was found in isolated coronal suture synostosis. However, these patients do not present the calvarial midline defect that is so characteristic of Apert syn-

drome. The caudal displacement of the bone centers observed in Apert dry skulls combined with true megalencephaly<sup>50</sup> could possibly distinguish and explain the difference in phenotype.

Whereas Carr et al.,<sup>43</sup> using their technique, did not detect any major differences between patients with Crouzon and those with Apert syndrome, our measurements of the new variables presented enabled us to find a distinction. In contrast to Apert syndrome, the bone centers in Crouzon patients were found not to be located significantly different from their normal position, indicating that there is a different pathogenesis involved in causing premature closure of the sutures in Crouzon syndrome. In conclusion, the CT data presented here, differentiating the morphology of the Apert and Crouzon syndromes, show a clear distinction in the pathogenesis of these two syndromes.

*Chr. Vermeij-Keers, M.D., Ph.D.*

*Department of Anatomy/Plastic and Reconstructive Surgery*

*Academic Hospital Rotterdam*

*Postbus 1738*

*3000 DR Rotterdam*

*The Netherlands*

#### ACKNOWLEDGMENTS

We thank Prof. R. van Strik for his advice concerning the statistics in this study and A. J. van Dam, curator of the Museum of Anatomy of Leiden University, for providing access to the skulls.

#### REFERENCES

1. Laitinen, L. Craniosynostosis: Premature fusion of the cranial sutures. An experimental, clinical, and histological investigation with particular reference to the pathogenesis and etiology of the disease. *Ann. Paediatr. Fenn.* 2(Suppl. 6): 1956.
2. Cohen, M. M., Jr. History, Terminology, and Classifica-

- tion of Craniosynostosis. In M. M. Cohen, Jr. (Ed.), *Craniosynostosis: Diagnosis, Evaluation, and Management*. New York: Raven Press, 1986.
3. Wilkie, A. O. M., Slaney, S. F., Oldridge, M., et al. Apert syndrome results from localized mutations of FGFR2 and is allelic with Crouzon syndrome. *Nat. Genet.* 9: 165, 1995.
  4. Preston, R. A., Post, J. C., Keats, B. J. B., et al. A gene for Crouzon craniofacial dysostosis maps to the long arm of chromosome 10. *Nature Genet.* 7: 149, 1994.
  5. Rutland, P., Pulleyn, L. J., Reardon, W., et al. Identical mutations in the FGFR2 gene cause both Pfeiffer and Crouzon syndrome phenotypes. *Nature Genet.* 9: 173, 1995.
  6. Feldman Lewanda, A., Cohen, M. M., Jr., Jackson, C. E., et al. Genetic heterogeneity among craniosynostosis syndromes: Mapping the Saethre-Chotzen syndrome locus between D7S513 and D7S516 and exclusion of Jackson-Weiss and Crouzon syndrome loci from 7p. *Genomics* 19: 115, 1994.
  7. van der Meulen, J. C., Mazzola, R., Vermeij-Keers, C., et al. A morphogenetic classification of craniofacial malformations. *Plast. Reconstr. Surg.* 71: 560, 1983.
  8. Vermeij-Keers, C., Mazzola, R. F., van der Meulen, J. C., and Stricker, M. Cerebrocraniofacial and craniofacial malformations: An embryological analysis. *Cleft Palate J.* 20: 128, 1983.
  9. Vermeij-Keers, C. Craniofacial Embryology and Morphogenesis: Normal and Abnormal. In M. Stricker, J. C. van der Meulen, B. Raphael, R. Mazzola, D. E. Tolhurst, and J. E. Murray (Eds.), *Craniofacial Malformations*. Edinburgh: Churchill-Livingstone, 1990.
  10. Toldt, C. Über die Entwicklung des Scheitelbeines des Menschen. *Z. Heilkd.* 4: 83, 1883.
  11. Inman, V. T., and Saunders, J. B. de C. M. The ossification of the human frontal bone: With special reference to its presumed pre- and postfrontal elements. *J. Anat.* 71: 383, 1937.
  12. Mall, E. P. On ossification centers in human embryos less than one hundred days old. *Am. J. Anat.* 5: 433, 1906.
  13. Noback, C. R., and Robertson, G. G. Sequences of appearance of ossification centers in the human skeleton during the first five prenatal months. *Am. J. Anat.* 89: 1, 1951.
  14. Starck, D. *Embryologie*. Stuttgart: Thieme-Verlag, 1965.
  15. O'Rahilly, R., and Gardner, E. The initial appearance of ossification in staged human embryos. *Am. J. Anat.* 134: 291, 1972.
  16. Osteology. In P. L. Williams, R. Warwick, M. Dyson, and L. H. Bannister (Eds.), *Gray's Anatomy*. Edinburgh: Churchill-Livingstone, 1989.
  17. Trotter, M., and Peterson, R. R. Osteology. In B. J. Anson (Ed.), *Morris' Human Anatomy*. New York: McGraw-Hill, 1966.
  18. Hinrichsen, K. V. Schädelentwicklung. In K. V. Hinrichsen (Ed.), *Humanembryologie*. Berlin: Springer-Verlag, 1990.
  19. Macklin, C. C. The skull of a human fetus of 40 mm. *Am. J. Anat.* 16: 317, 1914.
  20. Kokich, V. G. Biology of Sutures. In M. M. Cohen, Jr. (Ed.), *Craniosynostosis: Diagnosis, Evaluation, and Management*. New York: Raven Press, 1986.
  21. Furtwängler, J. A., Hall, S. H., and Koskinen-Moffett, L. K. Sutural morphogenesis in the mouse calvaria: The role of apoptosis. *Acta Anat.* 124: 74, 1985.
  22. Chakraborty, S., Oi, S., Suzuki, H., et al. Congenital frontal bone defect with intact overlying scalp. *Childs Nerv. Syst.* 9: 485, 1993.
  23. Dunn, R., Stout, S. D., and Dix, J. A unique case of congenital absence of parietal bones in a neonate. *J. Forensic Sci.* 36: 593, 1991.
  24. Sela, M., Sahar, A., and Lewin-Epstein, J. Agnesis of parietal bones with restoration of the cranial vault: Case report. *J. Neurosurg.* 50: 674, 1979.
  25. Sharma, N. K., Garg, P., and Gupta, A. K. Agnesis of frontal bone. *Ind. Pediatr.* 29: 125, 1992.
  26. Nickel, B. The parietal sagittal suture. *Neuroradiology* 3: 36, 1971.
  27. Shapiro, R. Anomalous parietal sutures and the bipartite parietal bone. *A.J.R.* 115: 569, 1972.
  28. Cameron, J. M., and Rae, L. J. *Atlas of the Battered Child Syndrome*. Edinburgh: Churchill-Livingstone, 1955.
  29. Kreiborg, S., and Cohen, M. M., Jr. Characteristics of the infant Apert skull and its subsequent development. *J. Craniofac. Genet. Dev. Biol.* 10: 399, 1990.
  30. Wrethe, M. *Die kongenitalen Missbildungen, ihre Ursachen und Prophylaxe*. Stockholm: Almqvist and Wiksell, 1955.
  31. Furuya, Y., Edwards, M. S. B., Alpers, C. E., et al. Computerized tomography of cranial sutures: 2. Abnormalities of sutures and skull deformity in craniosynostosis. *J. Neurosurg.* 61: 59, 1984.
  32. Furuya, Y., Edwards, M. S. B., Alpers, C. E., et al. Computerized tomography of cranial sutures: 1. Comparison of suture anatomy in children and adults. *J. Neurosurg.* 61: 53, 1984.
  33. Zonneveld, F. W., van der Meulen, J. C., van Akkerveenen, P. F., Koorneef, L., et al. Three-dimensional imaging and manipulation of CT data: II. Clinical applications in orthopaedic and craniofacial surgery. *Medicamundi* 32: 99, 1987.
  34. Zonneveld, F. W., Lobregt, S., van der Meulen, J. C., and Vaandrager, J. M. Three-dimensional imaging in craniofacial surgery. *World J. Surg.* 13: 328, 1989.
  35. Zonneveld, F. W., and Fukuta, K. A decade of clinical three-dimensional imaging: A review. 2. Clinical applications. *Invest. Radiol.* 29: 574, 1994.
  36. McCullough, E. C. Factors affecting the use of quantitative information from a CT scanner. *Radiology* 124: 99, 1977.
  37. Waitzman, A. A., Posnick, J. C., Armstrong, D. C., and Pron, G. E. Craniofacial skeletal measurements based on computed tomography: I. Accuracy and reproducibility. *Cleft Palate Craniofac. J.* 29: 112, 1992.
  38. Coates, D. B. Computed tomography normative values: Allowing new insights into the craniofacial complex (Abstract). *J. Oral Maxillofac. Surg.* 47(8 Suppl. 1): 124, 1989.
  39. Posnick, J. C., Lin, K. Y., Jhavar, B. J., and Armstrong, D. Crouzon syndrome: Quantitative assessment of presenting deformity and surgical results based on CT scans. *Plast. Reconstr. Surg.* 92: 1027, 1993.
  40. Posnick, J. C., Lin, K. Y., Chen, P., and Armstrong, D. C. Metopic synostosis: Quantitative assessment of presenting deformity and surgical results based on CT scans. *Plast. Reconstr. Surg.* 93: 16, 1994.
  41. Posnick, J. C., Lin, K. Y., Jhavar, B. J., and Armstrong, D. C. Apert syndrome: Quantitative assessment by CT scan of presenting deformity and surgical results after first-stage reconstruction. *Plast. Reconstr. Surg.* 93: 489, 1994.

42. Waitzman, A. A., Posnick, J. C., Armstrong, D. C., and Pron, G. E. Craniofacial skeletal measurements based on computed tomography: II. Normal values and growth trends. *Cleft Palate Craniofac. J.* 29: 118, 1992.
43. Carr, M., Posnick, J. C., Pron, G., and Armstrong, D. Cranio-orbito-zygomatic measurements from standard CT scans in unoperated Crouzon and Apert infants: Comparison with normal controls. *Cleft Palate Craniofac. J.* 29: 129, 1992.
44. Kreiborg, S., and Pruzansky, S. Craniofacial growth in premature craniofacial synostosis. *Scand. J. Plast. Reconstr. Surg.* 15: 171, 1981.
45. Kreiborg, S., Marsh, J. L., Cohen, M. M., Jr., et al. Comparative three-dimensional analysis of CT scans of the calvaria and cranial base in Apert and Crouzon syndromes. *J. Craniomaxillofac. Surg.* 21: 181, 1993.
46. Cohen, M. M., Jr., and Kreiborg, S. Skeletal abnormalities in the Apert syndrome. *Am. J. Med. Genet.* 47: 624, 1993.
47. Kreiborg, S., Barr, M., Jr., and Cohen, M. M., Jr. Cervical spine in the Apert syndrome. *Am. J. Med. Genet.* 43: 704, 1992.
48. Harris, V., Belligere, N., and Pruzansky, S. Progressive generalized bony dysplasia in Apert syndrome. *Birth Defects* 14(6B): 175, 1977.
49. Cohen, M. M., Jr. Syndromology's message for craniofacial biology. *J. Maxillofac. Surg.* 7: 89, 1979.
50. Cohen, M. M., Jr., and Kreiborg, S. The central nervous system in the Apert syndrome. *Am. J. Med. Genet.* 35: 36, 1990.



**II.2. Tracing craniosynostosis to its developmental stage through bone center displacement.**

Mathijssen IMJ, Van Splunder J, Vermeij-Keers Chr, Pieterman H, De Jong R, Mooney MP, Vaandrager JM.

*Journal of Craniofacial Genetics and Developmental Biology*  
19: 57-63, 1999.



# Tracing craniosynostosis to its developmental stage through bone center displacement

Mathijssen IMJ, van Splunder J, Vermeij-Keers Chr, Pieterman H, de Jong THR, Mooney MP, Vaandrager JM. Tracing craniosynostosis to its developmental stage through bone center displacement. *J Craniofac Genet Dev Biol* 1999; 19:57-63. © Munksgaard, Copenhagen

**Abstract:** In metopic and coronal suture synostosis, the involved bone centers are abnormally situated just next to the affected suture. Bone centers are the starting point of ossification during embryogenesis from which bone growth spreads radially. In this paper, we describe a similar observation for sagittal suture synostosis, with both parietal bone centers located almost completely cranially. The (reduced) distance between the bone centers of a synostotic suture reflects the time during embryogenesis at which fusion took place. We suggest that in craniosynostosis the bone centers arise in their normal position, and initial outgrowth is undisturbed until the bone fronts meet. It is during this developmental stage that fusion occurs instead of suture formation. Due to the fusion, growth can only occur at the free bony rims from then on. The bone centers remain located at a fixed distance from one another in the middle of the fused bones, becoming relatively more displaced with time. This implies that the distance between the involved bone centers directly indicates the developmental period during which sutural growth was arrested. The same phenomenon of bone center displacement is found in types of craniosynostosis with and without fibroblast growth factor receptor (FGFR) or TWIST gene mutations.

**Irene M.J. Mathijssen<sup>1</sup>, J. van Splunder<sup>1</sup>, Chr. Vermeij-Keers<sup>1</sup>, H. Pieterman<sup>2</sup>, T.H.R. de Jong<sup>3</sup>, M.P. Mooney<sup>4</sup> and J.M. Vaandrager<sup>1</sup>**

<sup>1</sup>Institute of Plastic Surgery and the Department of Plastic and Reconstructive Surgery, <sup>2</sup>Department of Radiology, and <sup>3</sup>Department of Neurosurgery, Erasmus Medical Center Rotterdam, The Netherlands; <sup>4</sup>Department of Anatomy and Histology, University of Pittsburgh, PA

**Key words:** embryogenesis - pathogenesis - cranium - birth defect - craniofacial

Address reprint requests to Irene M.J. Mathijssen, Institute of Plastic Surgery, Room Ee 1257, Erasmus Medical Center Rotterdam, PO Box 1738, 3000 DR Rotterdam, The Netherlands.

## Introduction

Bone centers are the locus of first ossification of a certain bone during embryogenesis, arising on a specific position and at a specific time [Vermeij-Keers, 1990]. Ossification spreads from the calvarial bone centers on, in a radial manner, giving rise to the radiating growth pattern of the bone plates. The original position of these bone centers is represented by the tubers, situated in the middle of the radiating growth pattern [Mathijssen et al., 1996; Richtsmeier et al., 1998].

In our former study on calvarial morphology in craniosynostosis, we demonstrated bone center displacement to be present in isolated metopic and coronal suture synostosis, and in Apert syndrome [Mathijssen et al., 1996]. In metopic suture synostosis, both frontal bone centers were located near the median. In isolated coronal suture synostosis and Apert syndrome, the frontal and parietal bone centers of the affected side(s) were situated near the affected suture(s). These findings on bone center position were demonstrated by macroscopic

observations on dry skulls, as well as by measurements taken on computerized tomography (CT) scans of patients suffering from craniosynostosis.

An increasing number of gene mutations have been related to craniosynostosis. Mutations in the fibroblast growth factor receptor (FGFR) genes 1, 2, and/or 3 have been associated with Apert [Wilkie et al., 1995], Crouzon [Reardon et al., 1994], Pfeiffer [Rutland et al., 1995; Schell et al., 1995], and Jackson-Weiss syndromes [Gorry et al., 1995] and also with cases of non-syndromic coronal suture synostosis [Moloney et al., 1997; Muenke et al., 1997]. For Saethre-Chotzen syndrome, mutations in the TWIST [El Ghouzzi et al., 1997; Howard et al., 1997] and FGFR3 genes [Paznekas et al. 1998] have been described.

At present, it is unclear which developmental processes are affected by the products of these altered FGFR or TWIST genes and how craniosynostosis is the ultimate result [Wilkie and Wall, 1996]. By studying embryologic landmarks, such as the bone centers, some aspects of these

processes can be elucidated. In our previous study on bone center positions in humans, we suggested that their displacement could be the primary defect, inducing the synostosis. However, investigations on bone center positions during cranial development in rabbits suffering from coronal suture synostosis showed this not to be the case [Dechant et al., 1998, 1999; Mooney et al., 1998]. Frontal and parietal bone centers had similar locations to those in non-affected animals up to the time of synostosis onset. Only afterwards the bone centers became displaced.

Although not indicating the primary defect, in the present study, we demonstrate that data on bone center positions can direct us towards the developmental period in which craniosynostosis originates. Comparison of the distance between the involved bone centers in the case of a synostotic suture and normal distances at different human developmental stages indicate the stage during which growth at the sutural area or suture was arrested. At that specific period, no suture was developed or the existing suture was obliterated and the bone plates fused. As a consequence, the distance between the bone centers was fixated and growth potential in that area was lacking. From then on, these bone plates started functioning as one solitary bone and growth could only take place at the free rims, thus adding to the relative degree of bone center displacement. This hypothesis incorporates the fact that in craniosynostosis the distance between the bone centers is constant, not subject to the age of the patient, and reflects the developmental stage at which the fusion occurred. To substantiate our theory, interbone center measurements were undertaken in normal fetal dry skulls of various stages and in a patient population with isolated and syndromic coronal suture synostosis. In addition, observations on bone center positioning during surgery are reported for both coronal and sagittal suture synostosis.

## Materials and methods

### Dry skulls

For both sides, the distance between the frontal bone center and ipsilateral parietal bone center was determined by taking measurements directly on the dry skulls of seven normal human fetuses ranging in age from 15 to 23 weeks of gestation. Age determination was based on the crown-heel length of the fetal skeletons. The bone centers were identified in the midpoint of the radiating patterns of the bones. Measurements were taken on both sides using vernier callipers and referred to as the interbone center distance (IBCD). The

same measurements were performed on two dry neonatal Apert skulls with bilateral coronal suture synostosis.

### Perioperative

Bone center positions were determined semiquantitatively during each primary craniotomy performed for correction of coronal or sagittal suture synostosis. Bone centers can easily be traced during surgery by locating the center of the radiating growth pattern of the bone, which remains clearly visible in the infant. In total, observations were performed during 44 operations (one Apert, five Saethre-Chozen, one Pfeiffer, 14 unilateral coronal suture synostosis, 23 sagittal suture synostosis).

### Computerized tomography scans

*Patients.* The axial CT scans were taken with a Siemens Somatom Plus VD30 CT scanner using 2.0-mm slices. Only complete, good quality CT series of unoperated patients with isolated or syndromic coronal suture synostosis were included. The CT scans of 54 patients were studied, classified according to their clinical diagnoses (12 Apert, 12 Saethre-Chozen, 2 Pfeiffer syndromes, 18 unilateral and ten bilateral coronal suture synostosis). Measurements were taken from the scans, selecting the slice that transects the most anterolateral points of the lateral ventricles, according to Waitzman et al. [1992]. The applied CT scan measurements, locating the frontal and parietal bone centers in the horizontal plane, have previously been described and shown to be valid [Mathijssen et al., 1996]. Briefly, the frontal and parietal bone centers, being the prominences or tubers of the respective bones, are identified by the sharpest angle of their bone on axial slices. The anteroposterior distance between this point and the most frontal point of the skull is measured, constituting the frontal (FBCD) and parietal bone center distances (PBCD), respectively. All measurements were standardized with reference to the 5-cm scale bar on each film. After obtaining the FBCD and PBCD, the IBCD was calculated by subtracting the FBCD from the PBCD. The mean, standard deviation, and 95% confidence interval were calculated for the IBCD ( $P=0.05$ , two-sided). The obtained data on IBCD were plotted against patients' age at the time of taking the CT scan.

Application of this method for detection of the parietal bone centers in cases with sagittal suture synostosis was not undertaken for the following

TABLE 1. Distance between frontal and parietal bone centers, the interbone center distance (IBCD), taken on both sides of seven dry skulls of normal human fetuses ranging in age from 15 to 23 weeks of gestation

Age (weeks of gestation)	IBCD right (mm)	IBCD left (mm)
15	16	16.5
16	22	20
17	24	26
18	29	28
19	32	31.5
21	42	38
23	51	60.5

reason. The sharpest angle of the parietal bones, i.e., the parietal bone centers, were found on the most cranial slices of these patients' CT scans. These slices obviously miss out the applied reference point, as mentioned above, to which the bone center distance is related. Furthermore, the quality of these last slices of the CT scan is often inferior. To overcome these drawbacks, one should apply CT scans taken in the coronal plane, with an appropriate reference point. Data for a normal population should be gathered for comparison with the data for sagittal suture synostosis. However, these 2-mm coronal CT scans are not available for either the normal population or scaphocephalic patients at present.

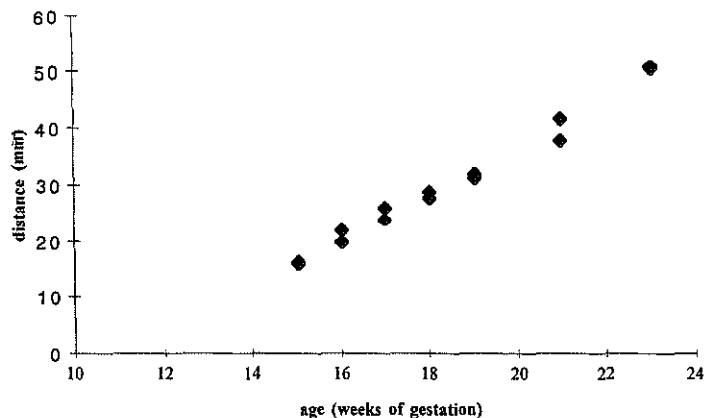
*Dry skulls.* For comparison with the actual distance, as measured directly on the dry Apert skulls, the IBCD was also calculated, based upon the FBCD and PBCD taken from their CT scans.

## Results

### Dry skulls

Table 1 outlines the data set on IBCD in relation to age during normal prenatal development. During undisturbed development of the cranium, the distance between the frontal and parietal bone centers increases with age because the coronal suture allows growth between these centers (Table 2). The reported data could be somewhat underestimated, since some shrinkage of the specimens may have occurred, particularly in the younger specimens, in which there is still a membrane linking the bone plates. The older dry skulls had some degree of moulage, thus reducing the actual distance. At 16 weeks of gestation, the first onset of the coronal suture seen was situated exactly in line with the frontal and parietal bone centers (Fig. 1). Because it is at this locus that the distance for both bone plates to overcome is the least, it is no surprise that first contact, and thus suture initiation, is made here. Subsequently, the formation of the coronal suture progressed in both cranial and caudal directions. At 18 weeks, the coronal suture appeared to have been established along its entire length, while the sagittal suture had just begun its development. Similarly, first onset of the metopic (15 weeks), lambdoid (16 weeks), and sagittal sutures (18 weeks) were seen at the point where the suture crosses the line connecting both contributing bone centers. Despite a slight difference in age, the IBCD on both sides of the two neonatal Apert skulls measured 16 mm.

TABLE 2. Scattergram of interbone center distance (IBCD) in relation to age of human fetuses



Due to growth within the (future) coronal suture, the distance between the frontal and parietal bone center increases with age.

## Perioperative

Perioperatively, both parietal bone centers in scaphocephalic children were noticed to be situated near the median (Fig. 2), i.e., towards the synostotic sagittal suture. In other words, the parietal bone centers were displaced upwards. In cases with coronal suture synostosis, the frontal and parietal bone centers were seen to be situated next to the synostotic suture.

## Computerized tomography scans

**Patients.** The mean IBCD at the unaffected side of patients with a unilateral coronal suture synostosis ( $N = 18$ ) was 79.6 mm (range 53.6–97.2 mm), with a standard deviation of 10.7 and a confidence of 4.9 ( $P = 0.05$ ). The average age of this subpopulation was 11 months. The scattergram of these data (Table 3) shows an increase in IBCD in relation to age, caused by growth of the skull at the coronal suture.

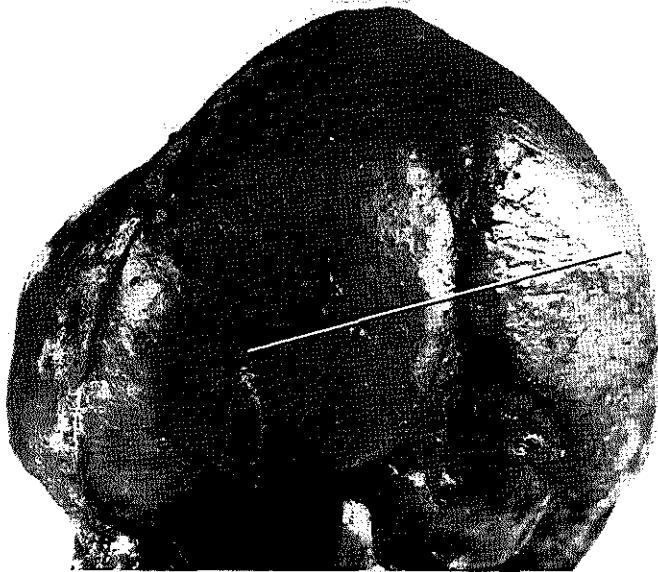
In contrast, the mean IBCD for all the synostotic coronal sutures ( $N = 90$ ) was 43.7 mm (range 11.2–63.9 mm), with a standard deviation of 12.5 and a confidence of 2.6 ( $P = 0.05$ ). The age of the patients at the time of scanning ranged from less than 1 month to 4 years of age (average 8 months). Indeed, no correlation was found between IBCD and age ( $-0.24$ ), as is illustrated in Table 4.

Correlating the synostotic IBCD to the normal IBCD in human fetuses places this congenital malformation near the stage of 21 weeks of gestation. Just prior to this developmental stage, the coronal suture is normally formed. Therefore, it is not likely that in craniosynostosis the bone centers arise primarily on an abnormal position. This data analysis implies that the bone center displacement occurs secondary to the fusion of the bone plates.

**Dry skulls.** The right- and left-sided IBCD of the two Apert skulls, determined by CT scan measurements, are 16.3 and 15.6, respectively, and 22.5 and 16.3, respectively, closely approaching the actual distances of 16 mm.

## Discussion

The fact that in coronal suture synostosis the frontal and parietal bone centers are located at a fairly constant, reduced distance from each other suggests that the initial development of the skull bones was undisturbed, allowing some degree of outgrowth. Bone center position is most accurately determined by judging their position, based upon the radiating pattern. Therefore, the IBCD obtained by direct measurement on the patients' calvariae and dry skulls – which no longer have a membrane between the bones – are more realistic than those obtained from CT scans. In particular, with the bony tubers getting less prominent with



*Fig. 1.* Photograph in lateral view of dry skull of human fetus with an estimated age of 16 weeks of gestation, comparable to the schematic illustration in Figure 3. Notice that the onset of the coronal suture is located where the line connecting the frontal and parietal bone centers crosses the sutural area.

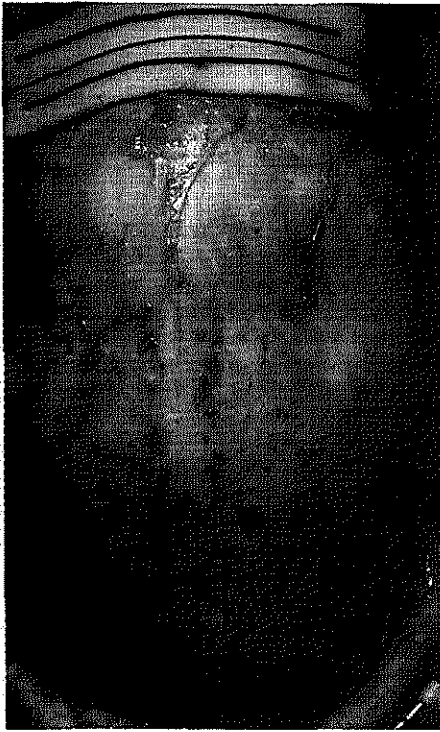
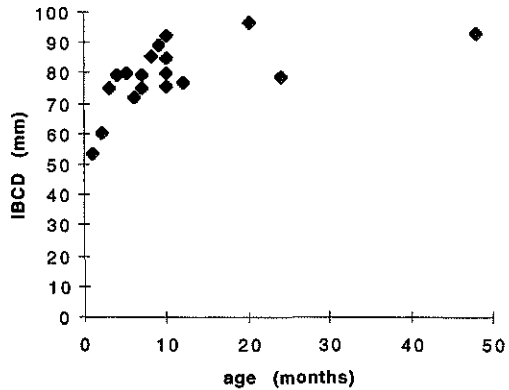


Fig. 2. Perioperative view of a patient suffering from sagittal suture synostosis seen from above with the frontal bone at the top. Determined by the radiating pattern, both parietal bone centers (arrowheads) can be identified near the affected suture.

age, the error in CT measurements of the bone centers will probably increase. But the trend of a constant value between the frontal and parietal bone centers irrespective of age, as shown by the CT measurements, does contribute to our following hypotheses. With respect to the Apert dry skulls, coronal suture formation was prohibited and fusion took place at the time during embryogenesis when the distance between the frontal and parietal bone centers measured about 16 mm. From that moment on, growth of the fused frontal and parietal bone complex could only take place at the free margins, with the coronal suture missing. As a result of this growth, the observed malposition of the involved bone centers becomes relatively more severe in time (Fig. 3). The observed range in IBCDs of the craniosynostotic patients could represent a slightly different timing of sutural closure in each individual. Perhaps a certain IBCD can be related to a given genetic mutation. For this we need the most accurate data on IBCD and thus need to measure this distance during surgery, which is currently being under-

TABLE 3. Scattergram of interbone center distance (IBCD) at the unaffected side of patients with coronal suture synostosis in relation to age

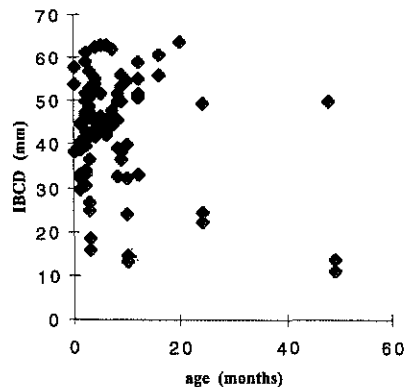


With age, the distance between the frontal and parietal bone centers increases due to growth at the coronal suture.

taken at our department. Because normal development of the sagittal suture occurs some stages later than that of the coronal suture, the sagittal suture synostosis will correspondingly arise later during embryogenesis.

In our clinical practice, a limited number of patients, most often clinically diagnosed as Crouzon syndrome, present with a late (postnatal) onset of sutural closure. At first the sutures are open, but in time a progressive ossification is observed. We described normal bone center positions in all seven of these patients in our former paper [Mathijssen et al., 1996]. Indeed, outgrowth of the individual bone plates was undisturbed up to the age of synostosis onset, and the sutures did have

TABLE 4. Scattergram of interbone center distance (IBCD) in relation to age of patients suffering from coronal suture synostosis, revealing no correlation between the two parameters



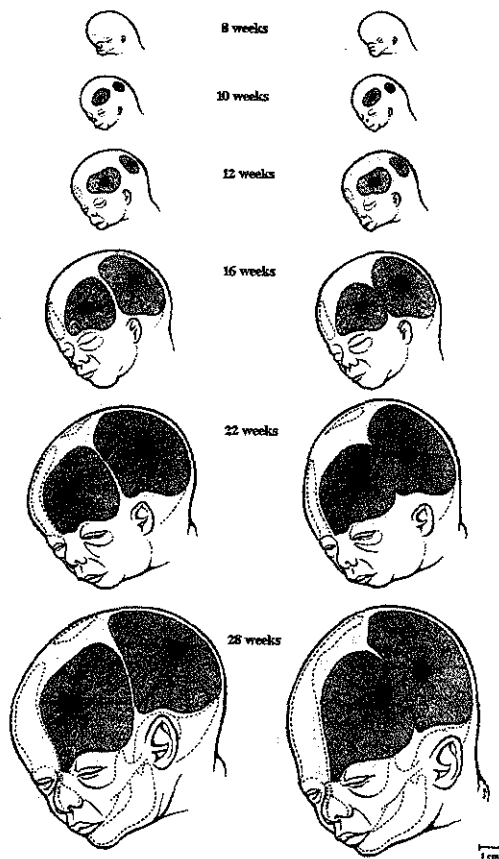


Fig. 3. Schematic drawing of the normal human development of frontal and parietal bones and the coronal suture between (left), and the development of coronal suture synostosis with secondary bone center dispositioning (right). Embryogenesis is undisturbed until the age of 16 weeks of development. Bone centers arise in their normal position and grow out in a radial manner, approaching one another. At about 16 weeks, bony fusion takes place at the site where coronal suture formation was supposed to start off. From then on, the distance between the frontal and parietal bone centers is fixed, and growth only occurs at the free edges of the bone plates. With growth occurring, the bone centers appear more and more displaced toward the affected suture.

the chance to develop. Because this onset is relatively late, the bone centers have assumed a near normal position. So again, even in these cases, the IBCD can be directly related to the onset of suture closure.

In this study, the same principle of malposition of bone centers toward the affected suture has been established for sagittal suture synostosis, as was done earlier for metopic and coronal suture synostosis. This is in contrast to findings published earlier by Richtsmeier et al. [1998]. According to

their findings, tracings of the parietal bone centers in sagittal suture synostosis were inferior compared to normals. For their analysis, 3-D reconstructions were used, on which an observer marked a prominence of each parietal bone supposedly representing the parietal bone center. In our clinical experience, we find it hard to distinguish the parietal bone centers as being a prominence in cases with sagittal suture synostosis, both during surgery and on CT scans, because they are located almost completely cranially next to the ridging sagittal suture. Therefore, their position can be most accurately determined, based on the radiating growth pattern, e.g., during surgery.

We no longer consider the displacement of bone centers in craniosynostosis to be the causative factor. As demonstrated in a study on positional changes of the bone centers during embryogenesis of rabbits suffering from coronal suture synostosis, frontal and parietal bone center positions for the wild type and affected animals were identical up until the time of synostosis onset [Dechant et al., 1998, 1999; Mooney et al., 1998]. From this stage on, the bone centers became displaced in the animals suffering from coronal suture synostosis. Having traced craniosynostosis to its developmental stage through bone center displacement, we have further substantiated the timing after which an ultrasound should be able to visualize this congenital malformation prenatally [Van Der Ham et al., 1995].

#### Acknowledgments

We thank Dries van Dam, curator at the Museum of Anatomy of Leiden University, for providing access to the skulls, Jan Lens for photography of the skulls, and Frits Wilbrink for the illustrations. This study was supported by the Dutch Association for Scientific Research, AGIKO grant number AGI 920-03-011.

#### References

- DECHANT JJ, MOONEY MP, COOPER GM, SMITH TD, LOSKEN HW, MATHUSSEN IMJ, SIEGEL MI: Positional changes in the frontoparietal ossification centers in perinatal craniosynostosis rabbits. *Am J Phys Anthropol Suppl* 26:75, 1998.
- DECHANT JJ, MOONEY MP, COOPER GM, SMITH TD, BURROWS AM, LOSKEN HW, MATHUSSEN IMJ, SIEGEL MI: Positional changes of the frontoparietal ossification centers in perinatal craniosynostotic rabbits. *J Craniofac Genet Dev Biol* 19: 64-74, 1999.
- EL GHOZZI V, LE MERRE M, PERRIN-SCHMITT F, LAJEUNIE E, BENIT P, RENIER D, BOURGEOIS P, BOLCATO-BELLEMIN AL, MUNNICH A, BONAVENTURA J: Mutations of the TWIST gene in the Saethre-Chatzen syndrome. *Nat Genet* 15:42-46, 1997.



- GORRY MC, PRESTON RA, WHITE GJ, ZHANG Y, SINGHAL VK, LOSKEN HW, PARKER MG, NWOKORO NA, POST JC, EHRlich GD: Crouzon syndrome: Mutations in two splice-*of*forms of FGFR2 and a common point mutation shared with Jackson-Weiss syndrome. *Hum Mol Genet* 4:1387-1390, 1995.
- VAN DER HAM LI, COHEN-OVERBEEKE TE, PAZ Y GEUZE HD, VERMEIJ-KEERS CHR: The ultrasonic detection of an isolated craniosynostosis. *Pren Diagn* 15:1189-1192, 1995.
- HOWARD TD, PAZNEKAS WA, GREEN ED, CHIANG LC, MA N, ORTIZ DE LUNA RI, DELGADO CG, GONZALEZ-RAMOS M, KLINE AD, WANG JABS E: Mutations in the TWIST, a basic helix-loop-helix transcription factor, in Saethre-Chotzen syndrome. *Nat Genet* 15:36-41, 1997.
- MATHUSSEN IMJ, VAANDRAGER JM, VAN DER MEULEN JC, PIETERMAN H, ZONNEVELD FW, KREIBORG S, VERMEIJ-KEERS CHR: The role of bone centers in the pathogenesis of craniosynostosis: An embryologic approach using CT measurements in isolated craniosynostosis, Apert and Crouzon syndromes. *Plast Reconstr Surg* 98:17-26, 1996.
- MOLONEY DM, WALL SA, ASHWORTH GJ, OLDRIDGE M, GLASS IA, FRANCOMANO CA, MUENKE M, WILKIE AOM: Prevalence of Pro250Arg mutation of fibroblast growth factor receptor 3 in coronal craniosynostosis. *Lancet* 349:1059-1062, 1997.
- MOONEY MP, DECHANT JJ, COOPER GM, SMITH TD, LOSKEN HW, MATHIJSSEN IMJ, SIEGEL MI: Frontoparietal bone ossification center location in craniosynostotic rabbits. *Am J Dent Res* 77:185, 1998.
- MUENKE M, GRIPP KW, McDONALD-McGINN DM, GAUDENZ K, WHITAKER LA, BARTLETT SP, MARKOWITZ RI, ROBIN NH, NWOKORO N, MULVIHILL JJ, LOSKEN HW, MULLIKEN JB, GUTTMACHER AE, WILROY RS, CLARKE LA, HOLLOWAY G, ADES LC, HAAN EA, MULLEY JC, COHEN MM, JR, BELLUS GA, FRANCOMANO CA, MOLONEY DM, WALL SA, WILKIE AOM, ZACKAI EH: A unique point mutation in the fibroblast growth factor receptor 3 gene (FGFR3) defines a new craniosynostosis syndrome. *Am J Hum Genet* 60:555-564, 1997.
- PAZNEKAS WA, CUNNINGHAM ML, HOWARD TD, KORF BR, LIPSON MH, GRIX AW, FEINGOLD M, GOLDBERG R, BOROCHOWITZ Z, ALECK K, MULLIKEN J, YIN M, JABS EW: Genetic heterogeneity of Saethre-Chotzen syndrome, due to TWIST and FGFR mutations. *Am J Hum Genet* 62:1370-1380, 1998.
- REARDON W, WINTER RM, RUTLAND P, PULLEYN LJ, JONES BM, MALCOLM S: Mutations in the fibroblast growth factor receptor 2 gene cause Crouzon syndrome. *Nat Genet* 8:93-103, 1994.
- RICHTSMEIER JT, COLE TM III, KROVITZ G, VALERI CJ, LELE S: Preoperative morphology and development in sagittal suture synostosis. *J Craniofac Genet Dev Biol* 18:64-78, 1998.
- RUTLAND P, PULLEYN LJ, REARDON W, BARAITSER M, HAYWARD R, JONES B, MALCOLM S, WINTER RM, OLDRIDGE M, SLANEY SF, POOLE MD, WILKIE AOM: Identical mutations in the FGFR2 gene cause both Pfeiffer and Crouzon syndrome phenotypes. *Nat Genet* 9:173-176, 1995.
- SHELL U, HEHER A, FELDMAN GJ, ROBIN NH, ZACKAI EH, DE DIE-SMULDERS CH, VISKOCHIL DH, STEWART JM, WOLFF G, OHASHI H, PRICE RA, COHEN MM, JR, MUENKE M: Mutations in FGFR1 and FGFR2 cause familial and sporadic Pfeiffer syndrome. *Hum Mol Genet* 4:323-328, 1995.
- VERMEIJ-KEERS CHR: Craniofacial embryology and morphogenesis: Normal and abnormal. In Stricker M, van der Meulen JC, Raphael B, Mazzola R, Tolhurst DE, Murray JE, eds: "Craniofacial Malformations". Edinburgh: Churchill-Livingstone, pp. 27-60, 1990.
- WAITZMAN AA, POSNICK JC, ARMSTRONG DC, PRON GE: Craniofacial skeletal measurements based on computed tomography: II. Normal values and growth trends. *Cleft Palate Craniofac J* 29:118-128, 1992.
- WILKIE AOM, SLANEY SF, OLDRIDGE M, POOLE MD, ASHWORTH GJ, HOCKLEY D, HAYWARD RD, DAVID DJ, PULLEYN LJ, RUTLAND P, MALCOLM S, WINTER RM, REARDON W: Apert syndrome results from localized mutations of FGFR2 and is allelic with Crouzon syndrome. *Nat Genet* 9:165-172, 1995.
- WILKIE AOM, WALL SA: Craniosynostosis: Novel insights into pathogenesis and treatment. *Curr Opin Neurol* 9:146-152, 1996.



**III. HISTOLOGIC STUDY OF THE DEVELOPING MURINE  
CORONAL SUTURE: NORMAL AND ABNORMAL**



**III.1. Apoptotic cell death during normal embryogenesis of the coronal suture: Early detection of apoptosis in mice using Annexin V.**

Bourez RLJH, Mathijssen IMJ, Vaandrager JM, Vermeij-Keers Chr.

*Journal of Craniofacial Surgery 8: 441-445, 1997.*



# Apoptotic Cell Death During Normal Embryogenesis of the Coronal Suture: Early Detection of Apoptosis in Mice Using Annexin V

R. L. J. H. Bourez  
I. M. J. Mathijssen, MD  
J. M. Vaandrager, MD  
C. Vermeij-Keers, PhD, MD

*Rotterdam, The Netherlands*

**Regulation of programmed cell death (apoptosis) is crucial for normal development and growth, both prenatally and postnatally. If its role during normal embryogenesis of a given structure is established, a number of related congenital disorders can be explained by a (local) deregulation of apoptosis. In this study, apoptotic cell death patterns during normal development of the murine coronal suture were investigated. Detection of apoptotic cells was undertaken by labeling with Annexin V. Results showed apoptosis occurring at the same time and place as suture initiation. Apoptotic cells are located along the entire established part of the suture and its developing part. Because apoptosis is shown to be highly associated with sutural genesis, the theory of craniosynostosis being the equivalent of deregulation at this locus seems in line with these findings.**

*Key Words:* Apoptosis, Annexin V, suture, embryogenesis, craniosynostosis

**I**n the extensive literature on sutural development and histology, few reports exist on the role of apoptotic (programmed) cell death. Yet apoptosis is known to be a crucial process in normal growth and development [1]. Apart from its

role in embryogenesis, apoptosis constitutes an important defense mechanism against viral infections and cancer. Different kinds of diseases can be explained by a deregulation in apoptotic cell death. In particular, the occurrence of a number of congenital defects can be explained by a deficiency or an abundance of apoptosis (e.g., syndactyly and cryptophthalmos, respectively). To understand their pathoembryogenesis, the exact role of apoptosis in normal embryogenesis needs to be established.

Because apoptosis is considered to be involved in keeping cranial sutures patent [2], craniosynostosis (premature suture closure or sutural agenesis) seems to be the equivalent of a shortage of apoptosis at this specific point [3].

One of the first authors to report on the occurrence of cell death at the level of sutures was Ten Cate and others in 1977 [4]. They recognized cell death—taking place in the central area of the suture—by characteristic morphological changes of the involved cells: shrinkage, nuclear condensation, and blebbing of cell membrane. This observation was made in the sutures of young rats at the ages of 1 and 2 days postnatally. Beyond this age, cell death was no longer detected. No prenatal stages of development were investigated. It was speculated that mesenchymal cell death in the suture separates the bones of the developing suture. In 1981, Albright and Byrd [5] postulated that craniosynostosis represents failure of calvarial bones to stop growing rather than premature closure of a suture, because normal suture closure never involves bony fusion. Furtwängler and associates [6] considered the cause of craniosynostosis to be explained by the failure of an undetermined mechanism that prevents contact and fusion of adjacent bone territories. In their study on sutural mor-

From the Department of Plastic and Reconstructive Surgery, University Hospital Rotterdam, The Netherlands.

R. L. J. H. Bourez and I. M. J. Mathijssen contributed equally to this article.

Address correspondence to Dr Mathijssen, Department of Plastic and Reconstructive Surgery, Ee 1253, Hoboken, PO Box 1738, 3000 DR Rotterdam, The Netherlands.

phogenesis in mice, they described a histological picture "strongly suggestive of a form of cell death called apoptosis," classifying cells as being apoptotic by their morphological changes, in accordance with Ten Cate and others [4]. Although mice ranging in age from 16 to 34 days postconception (PC) were used, apoptosis was only seen postnatally (22–26 days PC). Apoptosis was described as occurring whenever the approaching bones of the involved suture failed to overlap one another. As in the study by Ten Cate and colleagues [4], apoptosis was concluded to be "a morphogenetic mechanism that may function in preventing physical contact and resultant fusion of adjacent mineralized zones."

During normal human development of the calvaria, the frontal and parietal bones are formed by ossification of the membranous anlagen. The starting points of bony deposition are called bone centers (i.e., tubers). Ossification extends radially from these bone centers toward the margins, with the bones approaching each other [7,8]. The position of sutures appears to be determined by the meeting of the bones [7,9]. Our previous study on the pathoembryogenesis of craniosynostosis showed a dispositioning of bone centers toward the synostotic suture in isolated coronal and metopic suture synostosis and in coronal suture synostosis in Apert's syndrome [10]. Sutural synostosis is known to start off at a specific locus from which fusion progresses along the suture [2,5]. This locus was shown to be situated exactly between the two dispositioned bone centers [10]. On the basis of these observations, we postulated that craniosynostosis is associated with a deficit of apoptosis at the site where the outgrowing, displaced bone centers meet during embryogenesis. As a result, bony fusion (i.e., sutural agenesis) occurs locally and spreads from here across the suture. To substantiate this hypothesis in research, the apoptotic patterns in suture formation during normal mammalian development need to be established.

In our study, apoptotic cell death during murine embryogenesis was detected by labeling with Annexin V. In vivo, phosphatidylserine (PS) is expressed on the inner side of the plasma membrane in virtually all cell types [11]. In the early stages of apoptosis, PS is translocated to the outer layer of the membrane (i.e., the external surface of the cell), while the cell maintains its membrane integrity. The exposed PS mediates recognition and uptake by phagocytes [12]. Because Annexin V is a  $Ca^{2+}$ -dependent phospholipid-binding protein with a high affinity for PS [13], this protein can be used for detection of PS exposure (i.e., cells in early to late phases of apoptosis) [11]. This technique was applied to study apop-

osis in the normal development of cranial sutures, namely the coronal suture.

## MATERIALS AND METHODS

For this study, the FVB mouse was used. According to Theiler's calculation [14], the morning after mating (determined by the presence of a vaginal plug) was called day 0. The mouse was killed by cervical dislocation after sedation using ether inhalation. The uterus was extirpated, and the extra embryonic membranes were removed. A total of 77 FVB mouse embryos (prenatal) and fetuses (postnatal), ranging in age from 13 to 25 days PC, were collected (Table 1).

### Macroscopic Investigations

Whole embryos and fetuses of the different ages were stained for cartilage and bone ( $n = 19$ ) using alcian blue 8GX (Sigma A 3157) and alizarin red (Sigma A 5533).

### Microscopic Investigations

For apoptosis detection, specimens were injected with Annexin V Biotin (AV-B, 500  $\mu$ g/ml; APOPTEST-

### Number of Murine Embryos and Fetuses for Each Given Age Used for Bone and Cartilage Staining, Apoptosis Detection, Injected Controls, and Noninjected Controls

Age <sup>a</sup>	AIB/AIR hr <sup>b</sup>	AV-B hr <sup>c</sup>	AV-XB hr <sup>d</sup>	Controls <sup>e</sup>	Total
13	—	2 <sup>f</sup>	1 <sup>f</sup>	1	4
13.5	1	1	1	—	3
14	—	2 <sup>f</sup>	1 <sup>f</sup>	1	4
14.5	1	1	—	—	2
15	1	3	—	3	7
16	1	2	—	1	4
17	1	2	—	1	4
17.5	1	2	—	1	4
18	6	2	1	1	10
19	1	2	1	1	5
20	1	2	1	1	5
21	1	2	1	1	5
22	1	2	1	1	5
23	1	2	1	1	5
24	1	2	1	1	5
25	1	2	1	1	5
Total					77

<sup>a</sup>Days postconception.

<sup>b</sup>Alcian Blue/Alizarin Red.

<sup>c</sup>Annexin V Biotin.

<sup>d</sup>Heat-inactivated Annexin V Biotin.

<sup>e</sup>Noninjected.

<sup>f</sup>Injected intracardial.



biotin kit, NeXins Research BV, The Netherlands) using a Hamilton-Syringe pipetting system with glass needles (25–50  $\mu\text{m}$  in diameter). A few of the youngest embryos were injected intracardially, which results in distribution of AV-B throughout the body (see Table 1). A survival period of the specimens of approximately 30 minutes culture is required for this technique. The older animals were injected subcutaneously (SC) at the site of the (future) coronal suture: embryos aged up to 16 days PC were injected SC with 0.5 to 1.0  $\mu\text{l}$ ; embryos of 17 days PC and older were injected SC with 1.0 to 2.0  $\mu\text{l}$ . Before injection, ether sedation was administered to the viable specimens. Several embryos and fetuses were accordingly injected with heat-inactivated AV-B (AV-XB, 10 minutes at 56°C) to serve as a control for aspecific binding of Annexin V [15]. Furthermore, controls for each given age that were not given any injection were obtained. Apoptosis detection for these two control groups was based on changes in cellular morphology, typical for apoptosis.

The embryos of 13.5 to 16 days PC were collected in a Hepes solution (7.72 gm sodium chloride, 0.45 gm potassium chloride, 0.28 gm calcium chloride, 0.25 gm magnesium sulfate, 0.21 gm  $\text{K}_2\text{HPO}_4$  (potassium monohydrogen phosphate), 0.99 gm glucose, 4.77 gm Hepes, 5.0 gm bovine serum albumin in 1 L AquaDest, pH 7.0–7.4) at 35 to 36°C. Older animals (> 17 days PC) were kept at room temperature. After 30 to 60 minutes of survival, the specimens were killed by decapitation. To increase time of survival by stimulation of breathing, the umbilical cord of embryos at the age of 17 days PC were ligated. All subjects beyond the age of 14 days PC were decalcified with disodium ethylenediaminetetraacetic acid salt (Sigma ED2SS) for 4 days, processed for paraffin embedding, and serially sectioned in the sagittal plane at 5 to 20  $\mu\text{m}$ . The sections were mounted on slides, previously coated with 2% 3-aminopropyltriethoxysilane to prevent background staining. Bound AV-B was visualized using the avidin-biotin complex method with horseradish peroxidase-conjugated avidin. After washing with phosphate-buffered saline (PBS), staining was developed with 3,3'-diaminobenzidine tetrahydrochloride and counterstained with hematoxylin. The sections were examined light microscopically.

## RESULTS

### Macroscopic Investigations

**B**one and cartilage staining revealed the appearance of frontal and parietal bone centers in the membranous anlagen at the age of 13 and 14 days,

respectively. Bone formation spreads radially from these centers on, with the skull bones approaching each other. At the age of 16 days PC at the most lateral site of the skull, the frontal and parietal bones meet first initiating the coronal suture formations. Suture development progresses from here on both cranially and caudally.

### Microscopic Investigations

Apoptotic cell death is first noticed at the age of 16 days PC at the most lateral site of the skull (Fig 1A). Its distribution exceeds the zone of suture initiation (Fig 1B) in both the cranial and caudal directions. One day later (17 days PC), the number of labeled cells has increased. Apoptotic cells are distributed alongside the established and developing part of the suture and the adjacent area where the outgrowing bones have not met yet. At the age of 18 days PC, coronal suture formation is complete, with apoptotic cells lining its entire span.

Until 18 days PC, the frontal and parietal bones were lying within the same dorsoventral plane, but they now start to overlap. The frontal bone overlaps the parietal bone at the lateral side of the skull, and medial to this locus the parietal bone overlaps the frontal bone (Fig 1C). At this transition, the edge of the frontal bone starts to splice. Because of the overlap, there seem to be two sutural areas between the frontal and parietal bones within one plane (see Fig 1C).

In time, the splicing of the frontal bone is extended, with apoptotic cells located between its two layers (Fig 1D). With the increasing degree of overlap in consecutive stages, the observation of two sutural areas in one plane becomes more evident. In both sutural areas apoptotic cells were found (Fig 1E).

The number of apoptotic cells, determined semi-quantitatively, increases during the subsequent developmental stages, until the age of 23 days PC, when the number declines. The number of apoptotic cells in the animals injected with AV-XB and in the noninjected animals, detected by their morphological appearance only, was much less.

## DISCUSSION

**C**raniosynostosis is said to result from a deregulated coordination between osteoblastic differentiation within the suture and subsequent bone deposition on one hand and skull growth and timing of suture closure on the other hand [16]. We consider apoptosis, occurring time and place dependent, to be one of the processes essential in maintaining this bal-

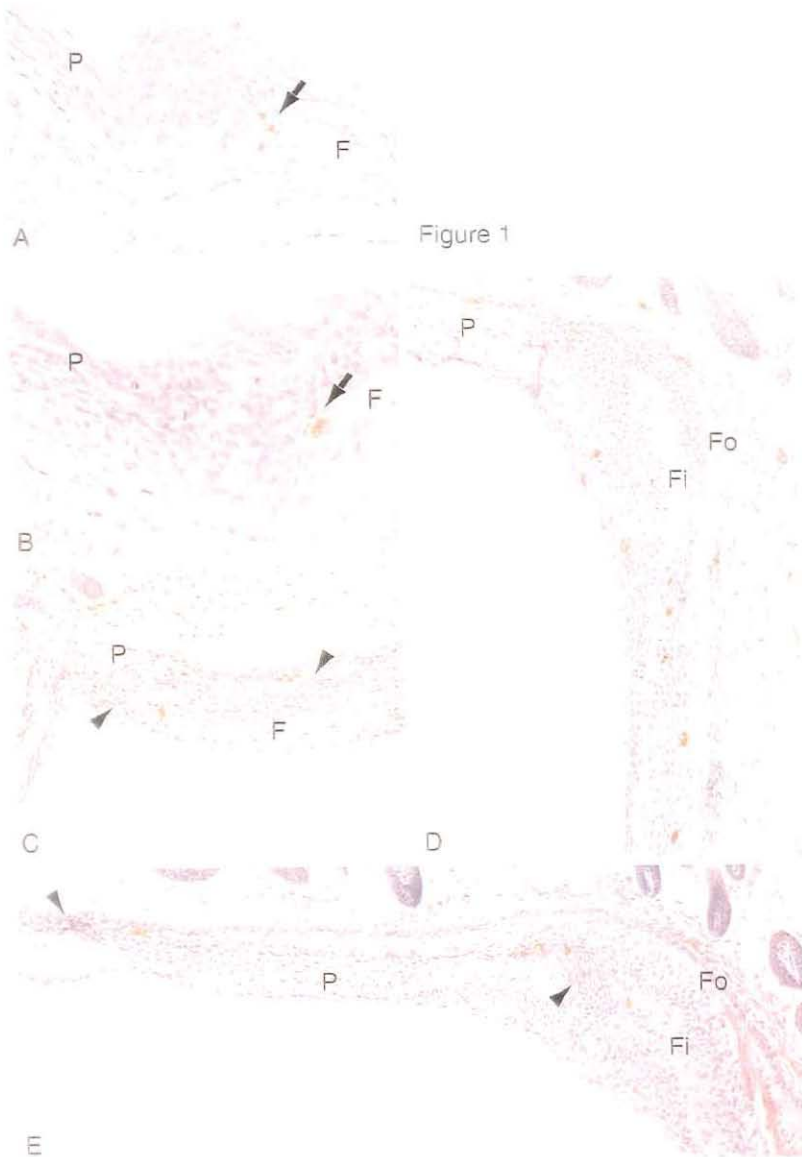


Figure 1

**Fig 1** All photographs concern sagittal sections with the fetus or embryo facing the right. (A) First occurrence of apoptotic cells (*arrow*) at the site of coronal suture initiation. F = frontal bone; P = parietal bone (16 days postconception [PC], Annexin V, avidin-horseradish peroxidase [HRP]-diaminobenzidine tetrahydrochloride [DAB], and hematoxylin, original magnification  $\times 20$ ). (B) Apoptotic cell (*arrow*) in the area just caudal to the zone of suture initiation. F = frontal bone; P = parietal bone (16 days PC, Annexin V, avidin-HRP-DAB, and hematoxylin, original magnification  $\times 20$ ). (C) The parietal bone (P) overlaps the frontal bone (F), giving rise to two sutural areas within one plane (*arrowheads*) (18 days PC, Annexin V, avidin-HRP-DAB, and hematoxylin, original magnification  $\times 10$ ). (D) The frontal bone is spliced into an inner (Fi) and an outer (Fo) layer, with apoptotic cells located in between. P = parietal bone (22 days PC, Annexin V, avidin-HRP-DAB, and hematoxylin, original magnification  $\times 10$ ). (E) Apoptotic cells located in both sutural areas (*arrowheads*). Fi = inner layer of frontal bone; Fo = outer layer of frontal bone; P = parietal bone (23 days PC, Annexin V, avidin-HRP-DAB, and hematoxylin, original magnification  $\times 10$ ).

ance during normal development. The study presented here demonstrates that apoptosis takes place at the site of coronal suture initiation, even before actual formation, indicating that apoptosis is highly associated with suture development. So far, apoptotic cell death was believed to occur in cranial sutures postnatally only [4, 6]. It seems justified to state that apoptosis is involved in establishing sutures as well as keeping them patent. These results imply that lack of apoptosis at this site could result in craniosynostosis. Because suture formation does occur in craniosynostosis, namely cranial and caudal to the fused bone centers [10], it is to be expected that apoptosis initially takes place at these locations. In time, the process of programmed cell death seems to be overruled by the stimulus to ossify, originating from the fused bone centers.

The complete cascade leading to apoptosis and the triggers for its pathways are not fully mapped [17]. Albright and Byrd [5] suggested contact of the outgrowing bones and skull molding during delivery to be such triggers. They substantiated this theory by remarking that apoptosis was only seen postnatally. With our ability to detect cells in the early and late stages of apoptosis using Annexin V, we demonstrated it to also take place prenatally, at the time of first suture initiation. This excludes the suggested triggers but does not indicate which factors are involved.

Because mutations in fibroblastic growth factor receptor (FGFR) genes in craniosynostosis syndromes [18–20] have been discovered, perhaps the apoptotic cascade is influenced by their products. Apoptosis could be one of the processes linking the genetic defect to the resulting morphological appearance. Isolated craniosynostosis seems to result from the same local disturbance of regulation of apoptotic cell death, because it has been shown to involve dispositioned bone centers similar to that in Apert's syndrome [10]. However, no mutations in the FGFRs have been described in the isolated types to date. Apparently, in isolated craniosynostosis another pathway is disturbed, meeting the syndromic ones at the end of the road, namely inhibition of apoptosis.

---

This work was supported in part by Dutch Association for Scientific Research AGIKO Grant AGI 920-03-011.

Part of the results of this study were presented at the Dutch Association for Anatomists, Lunteren, The Netherlands, January 4, 1997, and at the 8th European Association of Plastic Surgeons Meeting, Amsterdam, May 15, 1997.

---

## REFERENCES

- White E. Life, death, and the pursuit of apoptosis. *Genes Dev* 1996;10:1–15
- Cohen MM Jr. Sutural biology and the correlates of craniosynostosis. *Am J Med Genet* 1993;47:581–616
- Vermeij-Keers C. Craniofacial embryology and morphogenesis: normal and abnormal. In: Stricker M, van der Meulen J, Raphael B, Mazzola R, eds. *Craniofacial malformations*. Edinburgh: Churchill Livingstone, 1990:27–60
- Ten Cate AR, Freeman E, Dickinson JB. Sutural development: structure and its response to rapid expansion. *Am J Orthod* 1977;71:622–636
- Albright AL, Byrd RP. Suture pathology in craniosynostosis. *J Neurosurg* 1981;54:384–387
- Furtwängler JA, Hall SH, Koskinen-Moffett LK. Sutural morphogenesis in the mouse calvaria: the role of apoptosis. *Acta Anat* 1985;124:74–80
- Pritchard JJ, Scott JH, Gargis FG. The structure and development of cranial and facial sutures. *J Anat* 1956;90:73–86
- Silau AM, Fisher Hansen B, Kjaer I. Normal prenatal development of the human parietal bone and interparietal suture. *J Craniofac Genet Dev Biol* 1995;15:81–86
- Johansen VA, Hall SH. Morphogenesis of the mouse coronal suture. *Acta Anat* 1982;114:58–67
- Mathijssen IMJ, Vaandrager JM, van der Meulen JC, et al. The role of bone centers in the pathogenesis of craniosynostosis: an embryologic approach using CT measurements in isolated craniosynostosis and Apert and Crouzon syndromes. *Plast Reconstr Surg* 1996;98:17–26
- Van den Eijnde SM, Boshart L, Reutelingsperger CPM, et al. Phosphatidylserine plasma membrane asymmetry in vivo: a pancellular phenomenon which alters during apoptosis. *Cell Death Diff* 1997;4:311–316
- Fadok VA, Voelker DR, Campbell PA, et al. Exposure of phosphatidylserine on the surface of apoptotic lymphocytes triggers specific recognition and removal by macrophages. *J Immunol* 1992;148:2207–2216
- Vermes I, Haanen C, Steffens-Nakken H, Reutelingsperger CPM. A novel assay for apoptosis. Flow cytometric detection of phosphatidylserine expression on early apoptotic cells using fluorescein labelled Annexin V. *J Immunol Methods* 1995; 184:39–51
- Theiler K. *The house mouse: atlas of embryonic development*, 2nd ed. New York: Springer-Verlag, 1989
- Reutelingsperger CPM, Hornstra G, Hemker HC. Isolation and partial purification of a novel anticoagulant from arteries of human umbilical cord. *Eur J Biochem* 1985;151:625–629
- Erlebacher A, Filvaroff EH, Gitelman SE, Derjanc R. Toward a molecular understanding of skeletal development. *Cell* 1995; 80:371–378
- Martin SJ, Green DR, Cotter TG. Deciding with death: dissecting the components of the apoptosis machinery. *TIBS* 1994;19: 26–30
- Wilkie AOM, Slaney SF, Oldridge M, et al. Apert syndrome results from localized mutations of FGFR2 and is allelic with Crouzon syndrome. *Nature Genet* 1995;9:165–172
- Rutland P, Puleyn LJ, Reardon W, et al. Identical mutations in the FGFR2 gene cause both Pfeiffer and Crouzon syndrome phenotypes. *Nature Genet* 1995;9:173–176
- Heutink P, Vermeij-Keers C, Oostra BA. The genetic background of craniosynostosis syndromes. *Eur J Hum Genet* 1995;3:312–323



**III.2. Simultaneous induction of apoptosis, collagen type I expression and mineralization in the developing coronal suture following FGF4 and FGF2 application.**

Mathijssen IMJ, Van Leeuwen JPTM, Vermeij-Keers Chr.

*Submitted.*



**Simultaneous induction of apoptosis, collagen type I expression and mineralization in the developing coronal suture following FGF4 and FGF2 application.**

I.M.J. Mathijssen<sup>1</sup>, J.P.T.M. van Leeuwen<sup>2</sup>, Chr. Vermeij-Keers<sup>1</sup>

<sup>1</sup>Institute of Plastic Surgery at the Erasmus University Rotterdam and

<sup>2</sup>Department of Internal Medicine III at the University Hospital Rotterdam, The Netherlands

**Abstract**

This study aimed at evaluating the disturbances in normal coronal suture development resulting in craniosynostosis, a congenital disorder in which the calvarial sutures close prematurely. Craniosynostosis syndromes can be caused by mutations in the genes encoding for the fibroblast growth factor receptors (FGFR) 1, 2, and 3. These gain-of-function mutations cause the transcribed receptor to be constitutively activated. To mimic this genetic defect fibroblast growth factor (FGF) 2 or 4, with a high affinity for FGFR2, was administered near the developing coronal suture in normal mouse embryos through ex utero surgery. The effect on apoptosis and bone differentiation, as collagen type I expression and mineralization, within the FGF-exposed coronal suture was investigated through (immuno)histochemical staining. An increase in the number of apoptotic cells together with ectopic collagen type I expression within

the suture and accelerated mineralization followed fibroblast growth factor application. Macroscopically this presented as a synostotic coronal suture. These results suggest that both apoptosis and differentiation are two processes that are simultaneously implicated in synostosis of the coronal suture in case of a fibroblast growth factor receptor-related craniosynostosis.

## **Introduction**

Growth of the skull normally occurs at the site of the calvarial sutures. Craniosynostosis is a congenital malformation in which one or more calvarial sutures have fused prematurely (most often prenatally) or haven't been established at all, arising in approximately 1 in 2,500 live births. Skull development is restricted and as a result the head shape becomes distorted. This condition may be associated with additional abnormalities, mostly involving the limbs, thus constituting a craniosynostosis syndrome. In approximately 50% of the syndromic cases mutations in fibroblast growth factor receptor (FGFR) 1, 2 or 3 genes or TWIST gene can be detected (Wilkie, 1997). A mutual feature of patients with a craniosynostosis syndrome is synostosis of one or both coronal sutures. With respect to most FGFR2 mutations causing craniosynostosis, the transcribed receptor itself is constitutively activated, independent of the presence of its FGF ligands (Neilson and Friesel, 1995; Neilson and Friesel, 1996; Galvin et al., 1996; Mangasarian et al., 1997; Robertson et al., 1998). So far, only the FGFR2 mutations Ser252Trp and Pro253Arg causing Apert syndrome have been found to be dependent on the availability of



FGF2 for which the mutant receptors have a lowered dissociation rate, promoting increased signalling activity (Anderson et al., 1998).

The craniosynostosis syndromes have highlighted the importance of FGFRs in craniofacial development and in particular the cranial sutures. Iseki and coauthors studied the expression and function of FGFR1 and FGFR2 during skull development. They found FGFR2 to be expressed by proliferating osteogenic precursor cells, situated at the extensions of the frontal and parietal bones (Iseki et al., 1997). Closer to the osteogenic fronts of the frontal and parietal bones, FGFR2 expression was down-regulated and FGFR1 expression up-regulated, preceding the onset of bone differentiation. Signalling through FGFR1 was shown to regulate osteogenic differentiation whereas signalling through FGFR2 regulates proliferation. One of the local factors that seemed to have a modulating function in keeping this balance was fibroblast growth factor 2 (FGF2) (Iseki et al., 1997; Kim et al., 1998). Within the center of the suture FGF2 was hardly detectable, while its concentration rose towards the osteogenic fronts, being highest in the osteoid (Iseki et al., 1997). In general, the pattern of FGF2 distribution was the reverse of that for FGFR2. Whilst this provides some insight into the mechanism for normal calvarial development it remains uncertain how these processes are affected by mutated FGFRs.

It has been suggested that apoptosis, i.e., programmed cell death, is important in the pathogenesis of skeletal disorders and in particular craniosynostosis (Bourez et al., 1997; Hughes and Boyce, 1997; Rice, Kim and Thesleff, 1999). Likewise, derangement in the extent of

apoptosis has been associated with numerous other congenital malformations, for example complete cleft lip/alveolus/palate (Vermeij-Keers et al., 1983) and interdigital webbing (Van Der Hoeven et al., 1994). In normal adult human bone a number of differentiating bone cells appear to be lost via apoptosis (Parfitt, 1994; McCabe et al., 1995). In the developing coronal suture of mouse embryos, apoptotic cells have been located exclusively near to the osteogenic fronts of the frontal and parietal bones (Bourez et al., 1997; Rice, Kim and Thesleff, 1999).

The main purpose of this study was to assess changes in apoptosis and osteoblast differentiation during embryogenesis in FGFR2-related craniosynostosis. In the absence of an animal model for FGFR mutation-mediated craniosynostosis, injection of FGF2 or FGF4 in the vicinity of the coronal suture in mouse embryos has been used to mimic increased FGFR2 signalling. Initially, FGF4 was chosen because of its high affinity for FGFR2 (Goldfarb, 1996) and additionally FGF2 was used because of its natural occurrence in the developing skull. Analysis of this model involves immunohistological localization of apoptosis and bone differentiation through collagen type I production and mineralization.

## **Materials and methods**

### **Animal model**

For this study, the F.V.B. mouse was used. E0 was determined as the morning after mating (presence of a vaginal plug). Embryos ranging

in age from E14 to E18 at the time of surgery were included in this study, with a total number of 106 specimens (table I).

	Aliz. Red	V. Kossa	Coll. type I	Annex.	Tunel	double labeling
E14/FGF4/24h				6		
E15/FGF4/24h				7		
E15/FGF4/48h				9		
E16/FGF4/24h				10		
E17/FGF4/7.5h	2			4		
E17/FGF4/10h	2			2		
E17/FGF4/24h	20	3	3	10	3	2
E17/FGF2/24h	1	3		6		
E17/X-FGF4/24h	2			2		
E17/PBS/24h	2			3		
E18/FGF4/24h	4					
TOTAL (106)	33	6	3	59	3	2

Table I. Number of examined specimens for age, treatment, survival period and staining method.

Development of the coronal suture was initiated at the age of E16 and was complete at E18 (Bourez et al., 1997). Surgery on pregnant mice of the required age was undertaken after applying general anesthesia through inhalation (Halothane/O<sub>2</sub>/N<sub>2</sub>O). The uterus and embryos were exposed via a median abdominal incision and approximately 1.0 µl FGF2 (human recombinant basic FGF, Sigma-Aldrich Chemie BV, Zwijndrecht, The Netherlands) or FGF4 (human recombinant FGF4,

Sigma-Aldrich Chemie BV, Zwijndrecht, The Netherlands) from stocks of 10 µg/ml or 100 µg/ml respectively in PBS, was injected unilaterally using a pressure injector (1 bar) and a glass needle (diameter 25-30 µm) near the (presumptive) coronal suture of the embryos. The contralateral untreated coronal suture within the same specimen was used as control. Also, a control group was injected similarly with either heat inactivated FGF4 (X-FGF4, 10 minutes at 56°C) or PBS only. After the injections were administered the uterus wall was partially incised to prevent premature delivery, leaving the embryonic membranes intact. The uterus was then repositioned into the abdomen and the abdominal wall was closed in layers.

### **Detection of apoptosis**

After periods ranging from 7.5 hours up to 48 hours post injection (p.i.) the mouse was sacrificed and all viable embryos were removed from the uterus and kept at 37° C. The applied marker for apoptosis was Annexin V-biotin (APOPTEST™-biotin kit 500 µg/ml, NeXins Research BV, Maastricht, The Netherlands). This is an in vivo marker of the early phase of apoptosis onwards, which binds to phosphatidylserine (PS) (Van Den Eijnde et al., 1997a). Annexin V was injected subcutaneously near to both coronal sutures and the animals were decapitated 30 minutes later. Specimens were fixed overnight in a 4% formaldehyde solution, decalcified with EDTA (Sigma-Aldrich Chemie BV, Zwijndrecht, The Netherlands), processed for paraffin embedding, and serially sectioned in the transversel or occasionally the parasagittal plane at 5-7 µm. Sections

were mounted on slides, previously coated with 2% 3-aminopropyltriethoxysilane to prevent background staining. Bound Annexin V-biotin was visualized using the avidin-biotin complex method with horse-radish peroxidase conjugated avidin and DAB, counterstained with the PAS-reaction (Schiff-reagent) and haematoxylin.

A few exceptions are known of cells that label Annexin V because of PS presentation without being apoptotic (Van Den Eijnde et al., 1997a). These exceptions concern the megakaryoblasts and megakaryocytes at the time of formation of and disintegration into blood platelets, and myotubules during their cell fusion process. To ascertain the fact that the Annexin labeled cells within the suture are indeed apoptotic, additional TUNEL staining (Boehringer Ingelheim BV, Alkmaar, The Netherlands) was performed. TUNEL staining detects DNA cleavage sites and only marks cells in the late phase of apoptosis in contrast to Annexin V, as shown previously by double labeling experiments (Van Den Eijnde et al., 1997b). In situ cell death detection was performed by applying the TUNEL reaction mixture (deoxynucleotidyl transferase and nucleotide mixture), visualized with Converter-POD (anti-fluorescein antibody conjugated with horse-radish peroxidase) and DAB, counterstained with Schiff-reagent and haematoxylin.

### **Collagen type I expression and mineralization**

Anti-collagen type I immunohistochemical staining was performed on E17 embryos 24 hours after FGF administration to identify the

ongoing differentiation of cells within the coronal suture. Collagen type I is an early major component of osteoid. It is produced by osteoblasts during bone development (Aubin and Liu, 1996), and fundamental to the formation of mineralized matrix (Lynch et al., 1995). Sections for immunohistochemical staining with monoclonal anti-collagen type I (Sigma-Aldrich Chemie BV, Zwijndrecht, The Netherlands) were pretreated with pronase for 10 minutes and stained using a primary antibody titer of 1:2,000. Counterstaining was identical to that for Annexin.

Double labeling for apoptosis and collagen type I was performed on FGF4 treated embryos, after 24 hours of survival. This was performed by injecting Annexin V-FITC near the coronal sutures in the embryos prior to decapitation. The aim here was to determine whether or not the Annexin V labeled (apoptotic) cells and the collagen type I labeled cells belonged to two separate cell populations. Sections obtained from these specimens were stained immunohistochemically with the previously described anti-collagen type I antibody and visualized with a second antibody labeled with TRITC. Specimens were viewed using a fluorescence microscope and photographed.

Identification of mineralization sites was carried out using the Von Kossa method (2% Silver nitrate for 60 minutes in broad daylight), according to Bancroft and Cook (Bancroft and Cook, 1984), on sections of E17 embryos treated with FGF for 24 hours. In addition, E17 skulls were stained in toto for calcification to detect macroscopic changes of the coronal suture. Following removal of the skin and

treatment with a solution of alcohol, acetic acid and H<sub>2</sub>O<sub>2</sub> to decolourize, the tissues was macerated with a 1% KOH-solution and stained with Alizarin Red.

All illustrated sections were taken at an identical site of the cranial part of the suture (fig. 1). Within a single specimen, the FGF-injected side was compared with the equivalent part of the non-injected suture. Differences between the FGF-treated suture and the age-matched X-FGF4 or PBS-injected controls were determined semi-quantitatively through comparison of the number of labeled cells in representative sections and through analysis of the distribution of this labeling. For a representative FGF4 exposed E17 suture the number of Annexin V labelled cells 24 hours p.i. was determined for each individual section including the control suture. In order to estimate the length of the suture that was affected by the FGF exposure the number of sections with an altered structure was determined for different developmental stages and variable FGF-exposure time.




Figure 1. Schematic drawing of an E17 mouse head showing the level of sectioning. The coronal suture is situated between the frontal (f) and parietal (p) bone.

## Results

### Apoptosis

An increased number of Annexin labeled cells within the FGF4-exposed suture of E17 embryos compared to controls were found as early as seven and a half hours after the injection (fig. 2B and compare with fig. 2A). These apoptotic cells were situated at the extensions of the frontal and parietal bones, while at the control side only a few apoptotic cells could be traced exclusively near the osteogenic fronts. This increase in apoptosis was even more overt twenty-four hours after injection with FGF4 (fig. 2D and compare with fig. 2C). The labeled cells at this stage covered the entire sutural area transversely from the edge of the frontal bone to the edge of the parietal bone, and also involved a more extended part of the length of the suture. Table II illustrates the number of Annexin V labelled cells in each consecutive section of a treated and its contralateral control suture of an E17 embryo 24 hours p.i. In the FGF-exposed suture a mean number of 7 Annexin V labeled cells per section (range 2-18) was detected, while contralaterally this number was 1 (range 0-4).

The FGF-treated suture of E15 embryos showed numerous apoptotic cells near the osteogenic fronts, while labeled cells lining the osteogenic fronts of non-injected sutures at twenty-four hours p.i. were seen only occasionally (data not shown). In contrast to the E17 and E18 injected sutures, the center of the suture remained free of apoptotic cells. No increase in apoptotic cells was seen within the sutural area of treated E14 embryos, which were allowed to develop into the E15 stage.



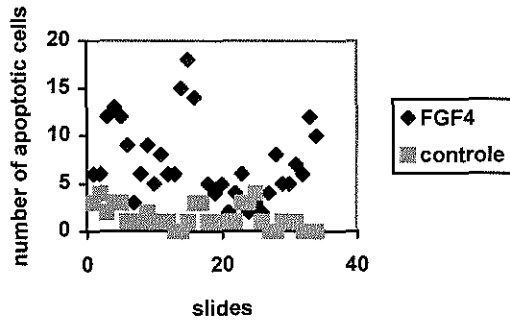


Table II. Number of apoptotic cells within the treated and untreated coronal suture of an E17 embryo 24 hours p.i., determined for consecutive sections of the affected area and the matching contralateral area.

Normally, apoptosis at the sutural site is first detected at E16 with one or two apoptotic cells lining the frontal and parietal osteogenic fronts along a very limited segment of the established suture (Bourez et al., 1997). Apparently FGF application did not advance the onset of apoptosis since no changes were seen in the pre-apoptotic stages (i.e. E14). The length of affected suture increased with the age of the embryo at the time of injection and with the allotted survival time (table III).

Similar induction of apoptosis followed injection with both 10  $\mu\text{g/ml}$  and 100  $\mu\text{g/ml}$ , though the length of altered suture was shorter with 10  $\mu\text{g/ml}$  treatment (259  $\mu\text{m}$  compared to 686  $\mu\text{m}$  for E17, 24 hours p.i.).

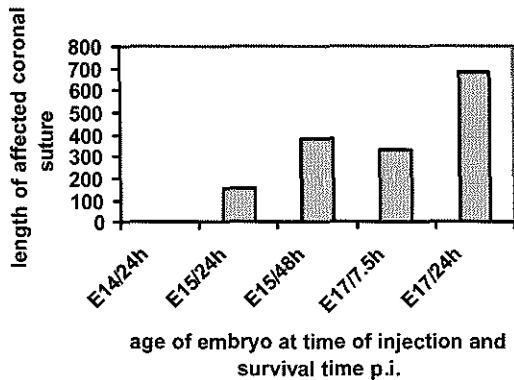


Table III. Scattergram of the sutural length (in  $\mu\text{m}$ ) along which an increased number of Annexin positive cells were detected in relation to age of the embryo and allotted survival time.

Although both FGFs induced an increase in apoptosis this increase was greater with FGF4 than with FGF2 (fig. 2D compare with fig. 2E). Following FGF exposure, there was an increase in the number of apoptotic cells throughout the sutural area, and apoptosis occurred along a more extended part of the suture.

The findings in sutures injected with X-FGF4 or PBS were comparable to the normal unaffected pattern of apoptosis in the uninjected control sides of the FGF-treated animals (fig. 2A,C).

Tunel staining revealed a similar distribution pattern of apoptotic cells within the control and injected sutures, substantiating the fact that the Annexin labeled cells are indeed apoptotic. As to be expected, the number of labeled cells with Tunel was lower than with Annexin V (fig. 3A,B) (Van Den Eijnde et al., 1997b).

### **Collagen type I expression and mineralization**

At the control side, collagen type I was found within the frontal and parietal bones with no staining in the coronal suture area (fig. 4A). In contrast, collagen type I expression at the injected side was also found within the suture, along a track corresponding to that of the induced apoptosis (fig. 4B). This finding indicates the presence of collagen type I producing osteoblasts which are probably adjacent to the apoptotic cells. This was confirmed by double labeling with Annexin-FITC and anti-collagen type I-TRITC which showed apoptotic cells and collagen type I-producing cells to be two separate, but co-distributed cell populations, showing no overlap in expression (fig. 5). At the treated side Von Kossa method demonstrated mineralization of both the frontal and parietal bones with intense staining peripherally, including their osteogenic fronts (fig. 6D-G). In contrast, these parts of the bone plates showed hardly any staining at the control side, i.e., there was little mineralization (fig. 6A-C). Furthermore, at the injected suture the frontal and parietal osteogenic fronts were closer to each other in comparison with the control side (fig. 6D-G and compare with fig. 6A-C respectively), whilst thickness of the frontal and parietal bones appeared to have increased by FGF treatment. Alizarin Red staining of the complete skulls identified enhanced mineralization of the coronal suture in E17 and E18 embryos following FGF4 injection 24 hours (fig. 7B) p.i. This was only seen 24 hours p.i. while the specimens of 7.5 or 10 hours p.i. were comparable to the controls. In addition, heat-inactivated FGF4 or PBS injected controls did not differ microscopically nor macroscopically from untreated controls.

Figure 2. Apoptotic cell pattern in the control and FGF-treated coronal sutures visualized with Annexin V.

Sections through the coronal sutures of E17 specimens, control side (left column), injected side with FGF4 or FGF2 (right column), after a variable survival time. Magnification 400x. F = frontal bone plate, P = parietal bone plate, S = skin, M = myotubuli.

A,B. Parasagittal sections through the coronal sutures of a E17 embryo, injected with FGF4 unilaterally, survival time 7.5 hours.

A) The control suture demonstrates a limited number of brown-stained apoptotic cells (arrowhead), situated in the vicinity of the frontal osteogenic front.

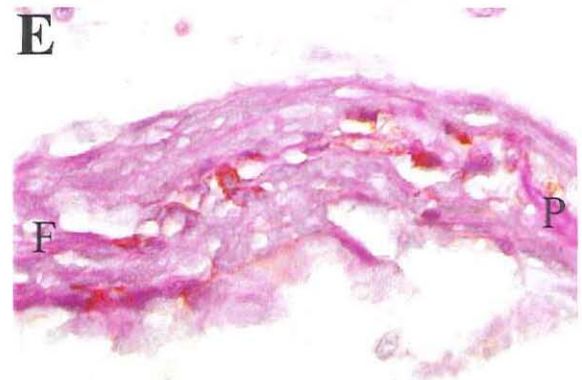
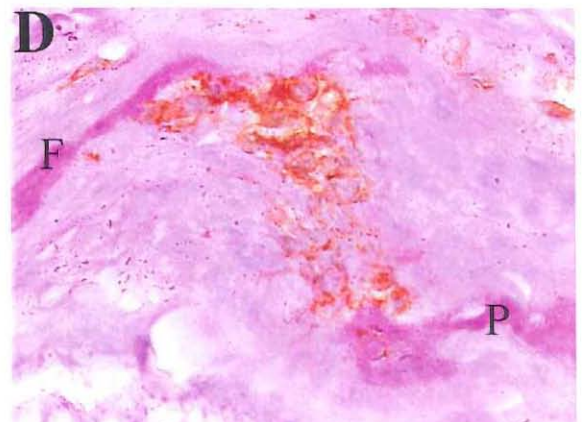
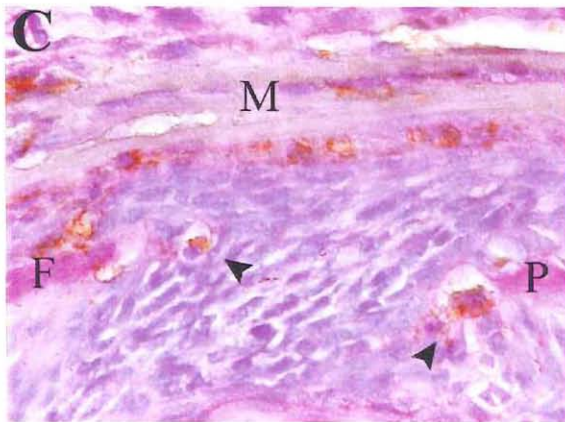
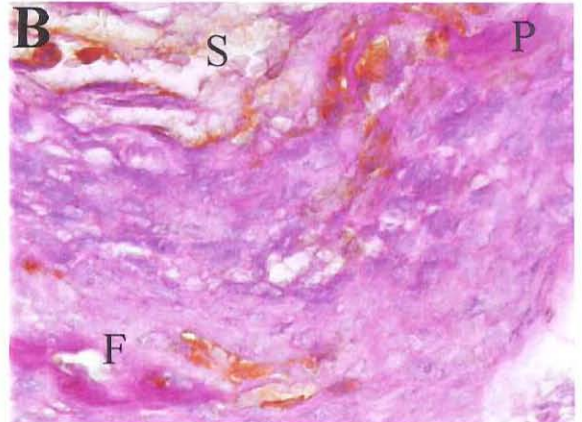
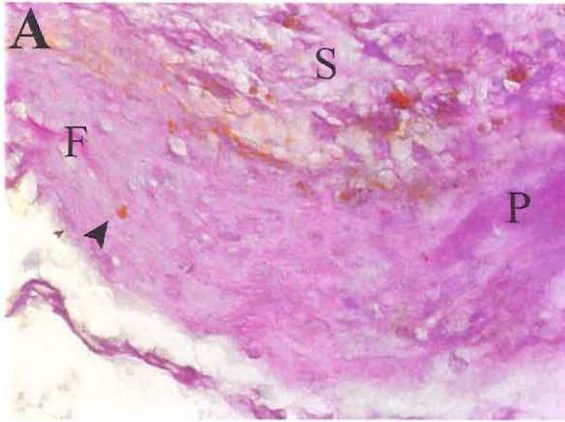
B) The suture exposed to FGF4 contains an increased number of Annexin labeled apoptotic cells, extending from the bony rims towards the sutural area, while the osteogenic fronts are in a near to normal position.

C,D. Transversel sections through the coronal sutures of E17 embryos, injected with FGF4 unilaterally, survival time 24 hours.

C) Apoptotic cells at the uninjected, control side are exclusively located near the rims of the bone plates. The line of Annexin labeled cells above the suture (M) are fusing myotubuli, known to bind Annexin V because of PS exposure, without being apoptotic.

D) Following FGF4 exposure, a large number of apoptotic cells are situated throughout the injected suture, combined with an advanced approximation of the osteogenic fronts.

E) Transversel section through the coronal sutures of an E17 embryo, injected with FGF2, survival time 24 hours. Apoptotic cells cover the entire suture, from frontal to parietal osteogenic front. The number of labeled cells is however smaller in comparison to the FGF4 treated suture (Fig. 2D).



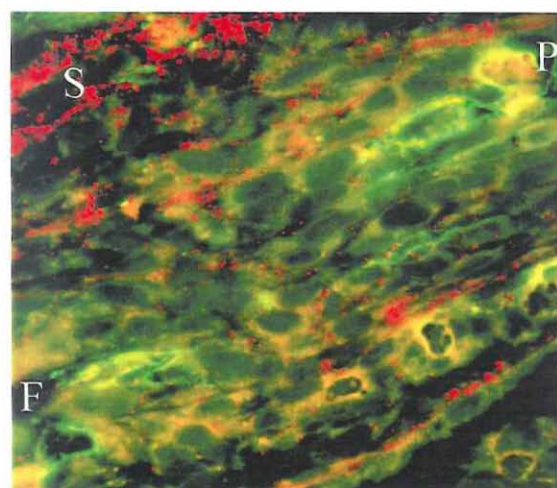
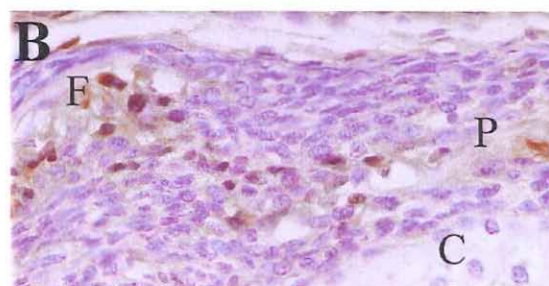
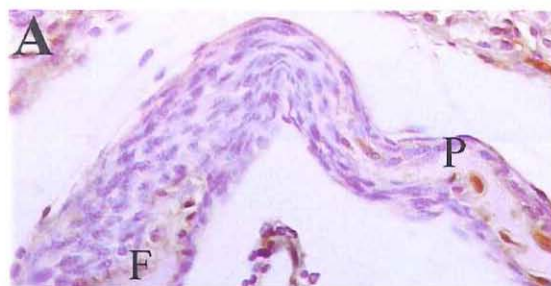
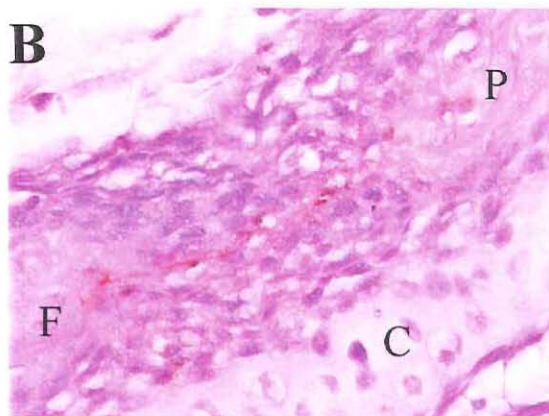
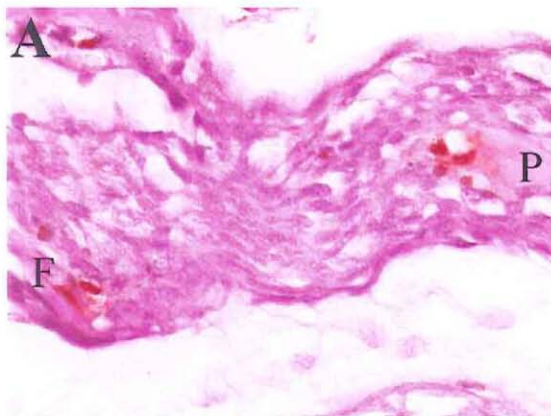


Figure 3. Apoptotic cell pattern in the control and FGF-treated coronal sutures visualized with TUNEL.

Transversal sections through the coronal sutures of an E17 embryo, injected with FGF4 unilaterally, survival time 24 hours. A. control side; B. injected side. Magnification 400x. F = frontal bone, P = parietal bone, C = cartilage.

A,B) TUNEL staining matches the distribution of brown-stained apoptotic cells as detected with Annexin V for both the control side and the FGF exposed suture (compare Fig. 2C, D respectively). A lesser number of cells is labeled due to the fact that Annexin V also labels apoptotic cells in the early phases of apoptosis.

Figure 4. Collagen type I expression in the control and FGF-treated coronal sutures.

Transversal sections through the coronal sutures of a E17 specimen, injected with FGF4 unilaterally and surviving for 24 hours. Magnification 400x. F = frontal bone plate, P = parietal bone plate, C = cartilage.

A) Control side. Labeled cells, indicating the presence of collagen type I producing osteoblasts, are normally lining the bone plates, leaving the sutural area free.

B) Injected side. In the FGF-treated suture, collagen type I expression is also found within the suture, indicating the advanced differentiation at this site.

Figure 5. Distribution of apoptosis and collagen type I expression in a FGF-treated coronal suture.

Transversal sections through the coronal sutures of a E17 specimen, injected with FGF4 after 24 hours of survival. Double labeling with Annexin V-FITC (green) and anti-collagen type I-TRITC (red). Magnification 400x. F = frontal bone plate, P = parietal bone plate, S = skin. Orientation matches that of figures 2 to 4. At the left top, intense staining for collagen type I marks the skin (S) overlying the coronal suture. The staining for apoptosis and collagen type I within the suture is not overlapping, showing both cell types to be two different cell populations.

Figure 6. Mineralization in the control and FGF-treated coronal sutures.

Transversel sections through the coronal sutures of a E17 specimen, control side (A,B,C), injected with FGF4 (D,E) or FGF2 (F,G), surviving for 24 hours. Detection of mineralization with the Von Kossa method. Right column shows details of pictures in left column at higher magnification. Magnification left column 200x; right column 400x. F = frontal bone plate, P = parietal bone plate, S = skin.

A) Overview of the coronal suture at the control side. No mineralization is detected at the peripheral parts or at the osteogenic fronts of the frontal or parietal bones.

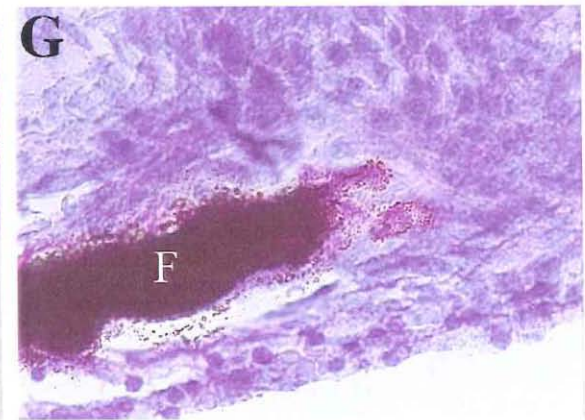
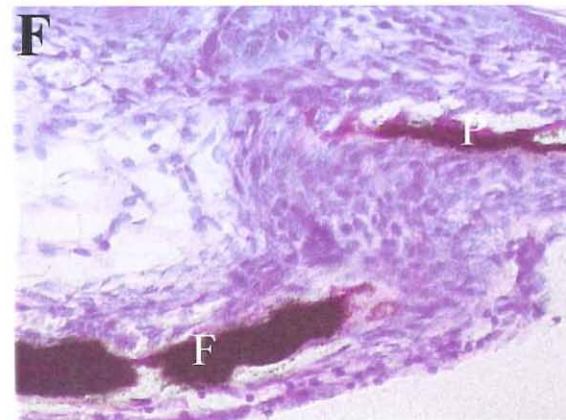
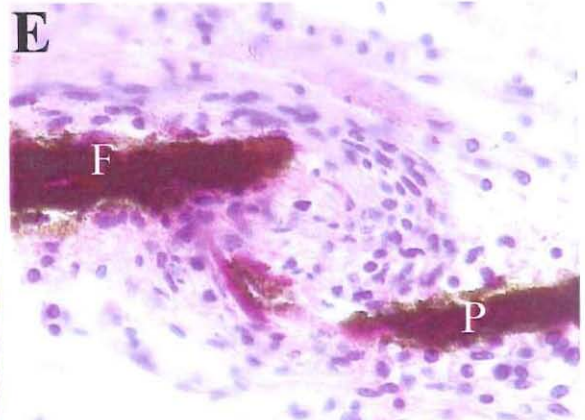
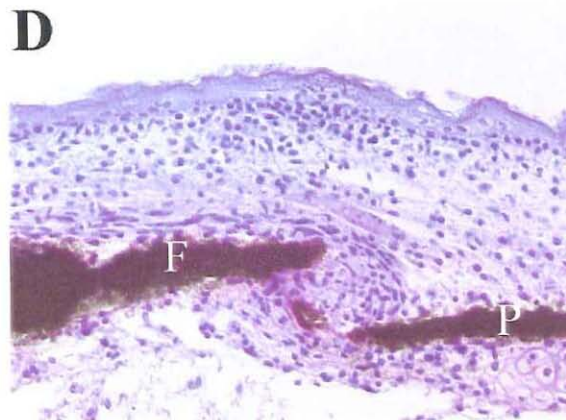
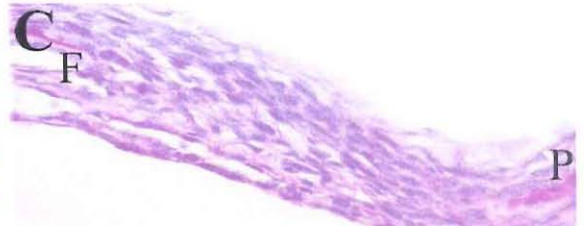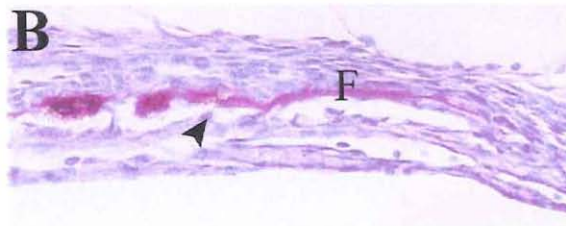
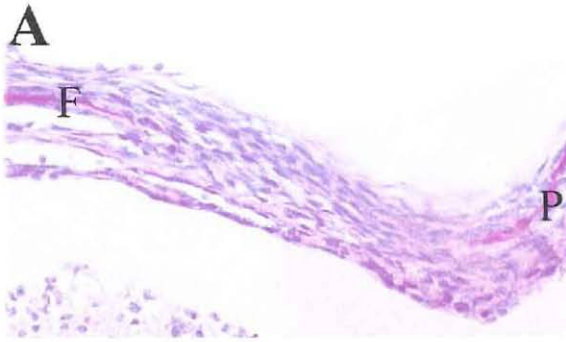
B) Same suture as is depicted in A, showing mineralization of the frontal bone at the control side only involving the central part (arrowhead indicates the border between mineralized and unmineralized bone).

C) Coronal suture at the control side at higher magnification, again showing no signs of mineralization of the osteogenic fronts.

D,E) Following FGF4 exposure, the mineralization of the frontal and parietal bones has extended peripherally, including the entire osteogenic fronts. Furthermore, these osteogenic fronts are in closer approximation, as compared to normal (A,B,C). The bone plates themselves appear to have an increased thickness.

F,G) After FGF2 injection, comparable effects as for FGF4 are obtained with respect to enhanced mineralization.





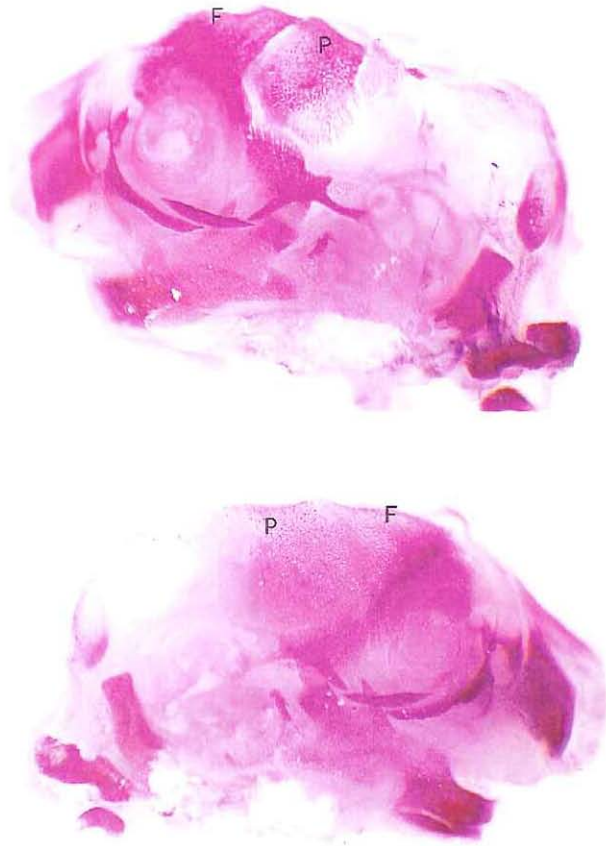


Figure 7. Mineralization of the skull after unilateral injection with FGF near the coronal suture.

Detection of mineralization with Alizarin Red staining of a skull of a E17 specimen, injected with FGF4 and surviving 24 hours.

A. Control side. Between the frontal (F) and parietal (P) bone plates, the coronal suture is seen as a mineralization-free line.

B. Injected side. Twenty four hours after FGF injection, enhanced mineralization of the coronal suture can be seen.

## **Discussion**

The present study has clearly shown that exposure of the developing coronal suture to FGF4 or FGF2 enhances the entire developmental process from osteogenic precursor cell to mature osteoblast, as demonstrated by collagen type I expression, advanced mineralization and increased apoptosis. Both FGF4 and FGF2 are known to bind to FGFR2 (Ornitz et al., 1996), although FGF4 has a higher affinity (Goldfarb, 1996) and this could explain the stronger effect of FGF4 in this study compared to FGF2. The effect of FGF4 on apoptosis has been shown to be dependent of the embryonic stage at the time of injection, exposure time, and FGF-concentration.

The fact that apoptotic cells and collagen type I producing cells were situated throughout the suture following FGF injection suggests that precursor cells at various differential stages, i.e. preosteoblasts, osteogenic precursor cells and perhaps poorly committed stem cells, were involved. Since apoptotic and collagen type I expressing cells were two different co-distributed populations that appeared simultaneously, it is hypothesized that both the apoptotic and collagen type I expressing cells are the product of the final cell division of osteogenic cells. This has been reported in osteogenic differentiation of chondrocytes and referred to as 'asymmetric cell division' (26). This theory, however, needs further investigation.

It appears that the increase in apoptosis precedes enhanced mineralization, given the finding that 7.5 and 10 hours post injection there was an increased number of apoptotic cells but no detectable change in the extent of mineralization.

Extrapolating these findings to the clinical problem the following concept is proposed. During embryogenesis of the cranial vault the FGFR2 gene is expressed by proliferating osteogenic precursor cells within coronal sutures which offer growth potential to the skull. Normally, a balance is kept between the degree of proliferation, differentiation, and apoptosis of osteogenic (precursor) cells. Apoptosis seems to be key in this respect first by limiting both the number of osteoblasts (Parfitt, 1994) and their precursors (Rice, Kim and Thesleff, 1999) which become differentiated osteocytes and second by contributing to mineralization of the osteoid (Lynch et al., 1998), supposedly by releasing previously stored huge amounts of calcium (Zimmermann, 1992). Apoptosis in bone tissue has been previously reported at the sites of osteogenesis, both during bone development and fracture repair, supporting the hypothesis that apoptosis is functionally related to mineralization (Ferguson et al., 1998; Landry et al., 1997).

FGF2 is at least one of the local factors which influences the balance between proliferation, differentiation, and apoptosis near to the coronal suture (Iseki et al., 1997; Iseki, Wilkie and Morriss-Kay, 1999; Kim et al., 1998). In cases of a FGFR2 mutation-linked craniosynostosis, an increase in receptor-signalling results (Neilson and Friesel, 1995; Neilson and Friesel, 1996; Galvin et al., 1996; Mangasarian et al., 1997; Robertson et al., 1998). Because of this, the FGFR2-expressing osteogenic precursor cells are forced to undergo premature bone differentiation (Iseki, Wilkie and Morriss-Kay, 1999) or to undergo apoptosis at an earlier stage at the expense of

proliferation. Both cells appear to deliver elements for craniosynostosis development; osteoblasts by producing osteoid and apoptotic cells by enhancing mineralization. As a result the proliferating cell population is exhausted and the gap between the frontal and parietal bones is filled with mature bone cells, eventually leading to suture obliteration. Indeed, Lomri et al. (1998) found an increase in maturation of the preosteoblastic calvarial cells derived from Apert patients and fetuses, leading to increased matrix formation and premature calvaria ossification.

Although the FGFR2 gene is most commonly associated with craniosynostosis syndromes, it is interesting to theorize on how mutations in the FGFR1, FGFR3 or TWIST genes also lead to similar effects in developing sutures. FGFR1 transcripts appear to be expressed by more differentiated bone cells compared to FGFR2 (Iseki, Wilkie and Morriss-Kay, 1999). This might suggest a similar pathogenesis for FGFR1 mutations, in which a later onset of disturbance of development would be expected. Besides expression comparable to that of FGFR2, FGFR3 transcripts have also been found within chondrocytes situated underneath the coronal suture (Iseki, Wilkie and Morriss-Kay, 1999) but its interaction with the suture is unknown. Consistent with our results, FGFR3 mutations resulting in thanatophoric dysplasia through ligand-independent receptor activation have been reported to induce premature apoptosis of chondrocytes (Legeai-Mallet et al., 1998).

This study has made some contribution in understanding sutural biology and the disturbances leading to craniosynostosis, but many

features of the suture and the congenital malformation remain unraveled.

### **Acknowledgments**

The authors wish to thank professor G.M. Morriss-Kay, dept. of Human Anatomy and Genetics at Oxford, for her very helpful discussions, Hans van der Burg for his technical support during the experiments, Pieter Derckx and Katerina Pispili for their contribution in preparing the histological samples, Adriaan Houtsmuller and Alex Nigg for assistance with the fluorescence photography, and Robert Brown for reviewing the article.

### **References**

- ANDERSON J, BURNS HD, ENRIQUEZ-HARRIS P, WILKIE AOM, HEATH JK: Apert syndrome mutations in fibroblast growth factor receptor 2 exhibit increased affinity for FGF ligand. *Hum Molec Genet* 7:1475-1483, 1998.
- AUBIN JE, LIU F: The osteoblast lineage. In Bilezikian JP, Raisz LG, Rodan GA (eds): "Principles of bone biology," San Diego: Academic Press, pp. 51-67, 1996.
- BANCROFT J, COOK A: "Manual for histological techniques," New York: Churchill Livingstone, 1984.
- BOUREZ RLJM, MATHIJSEN IMJ, VAANDRAGER JM, VERMEIJ-KEERS CHR: Apoptotic cell death during normal embryogenesis of the coronal suture: Early detection of apoptosis in mice using Annexin V. *J Craniofac Surg* 8:441-445, 1997.
- FERGUSON CM, MICLAU T, HU D, ALPERN E, HELMS JA: Common molecular pathways in skeletal morphogenesis and repair. *Ann N Y Acad Sci* 857:33-42, 1998.
- GALVIN BD, HART KC, MEYER AN, WEBSTER MK, DONOGHUE DJ: Constitutive receptor activation by Crouzon syndrome mutations

- in fibroblast growth factor receptor (FGFR) 2 and FGFR2/Neu chimeras. *Proc Natl Acad Sci* 93:7894-7899, 1996.
- GOLDFARB M: Functions of fibroblast growth factors in vertebrate development. *Cytok Growth Factor Rev* 7:311-325, 1996.
- HUGHES DE, BOYCE BF: Apoptosis in bone physiology and disease. *J Clin Pathol: Mol Pathol* 50:132-137, 1997.
- ISEKI S, WILKIE AOM, HEATH JK, ISHIMARU T, ETO K, MORRIS-KAY GM: FGFR2 and osteopontin domains in the developing skull vault are mutually exclusive and can be altered by locally applied FGF2. *Development* 124:3375-3384, 1997.
- ISEKI S, WILKIE AOM, MORRIS-KAY GM: FGFR1 and FGFR2 have distinct differentiation- and proliferation-related roles in the developing mouse skull vault. *Development* 126:5611-5620, 1999.
- KIM HJ, RICE DPC, KETTUNEN PJ, THESLEFF I: FGF-, BMP- and Shh-mediated signalling pathways in the regulation of cranial suture morphogenesis and calvarial bone development. *Development* 125:1241-1251, 1998.
- LANDRY P, SADASIVAN K, MARIONO A, ALBRIGHT J: Apoptosis is coordinately regulated with osteoblast formation during bone healing. *Tissue Cell* 29:413-419, 1997.
- LEGEAI-MALLET L, BENOIST-LASSELIN C, DELEZOIDE AL, MUNNICH A, BONAVENTURE J: Fibroblast growth factor receptor 3 mutations promote apoptosis but do not alter chondrocyte proliferation in thanatophoric dysplasia. *J Biol Chem* 273:13007-13014, 1998.
- LOMRI A, LEMONNIER J, HOTT M, DE PARSEVAL N, LAJEUNIE E, MUNNICH A, RENIER D, MARIE PJ: Increased calvaria cell differentiation and bone matrix formation induced by fibroblast growth factor receptor 2 mutations in Apert syndrome. *J Clin Invest* 101:1310-1317, 1998.
- LYNCH MP, STEIN JL, STEIN GS, LIAN JB: The influence of type I collagen on the development and maintenance of the osteoblast phenotype in primary and passaged rat calvarial osteoblasts: Modification of expression of genes supporting cell growth, adhesion, and extracellular matrix mineralization. *Exp Cell Res* 216:35-45, 1995.

- LYNCH MP, CAPPARELLI C, STEIN JL, STEIN GS, LIAN JB: Apoptosis during bone-like tissue development in vitro. *J Cell Biochem* 68:31-49, 1998.
- MANGASARIAN K, LI Y, MANSUKHANI A, BASILICO C: Mutation associated with Crouzon syndrome causes ligand-independent dimerization and activation of FGF receptor-2. *J Cell Physiol* 172:117-125, 1997.
- MCCABE LR, KOCKX M, LIAN J, STEIN J, STEIN G: Selective expression of fos- and jun-related genes during osteoblast proliferation and differentiation. *Exp Cell Res* 218:255-262, 1995.
- NEILSON KM, FRIESEL RE: Constitutive activation of fibroblast growth factor receptor-2 by a point mutation associated with Crouzon syndrome. *J Biol Chem* 270:26037-26040, 1995.
- NEILSON KM, FRIESEL RE: Ligand-independent activation of fibroblast growth factor receptors by point mutations in the extracellular, transmembrane, and kinase domains. *J Biol Chem* 271:25049-25057, 1996.
- ORNITZ DM, XU J, COLVIN JS, McEWEN DG, MACARTHUR CA, COULIER F, GAO G, GOLDFARB M: Receptor specificity of the fibroblast growth factor family. *J Biol Chem* 271:15292-15297, 1996.
- PARFITT AM: Osteonal and hemi-osteonal remodeling: The spatial and temporal framework for signal traffic in adult human bone. *J Cell Biochem* 55:273-286, 1994.
- RICE D, KIM H, THESLEFF I: Apoptosis in murine calvarial bone and suture development. *Eur J Oral Sci* 107:265-275, 1999.
- ROACH HI, ERENPREISA J, AIGNER T: Osteogenic differentiation of hypertrophic chondrocytes involves asymmetric cell divisions and apoptosis. *J Cell Biol* 131:483-494, 1995.
- ROBERTSON SC, MEYER AN, HART KC, GALVIN BD, WEBSTER MK, DONOGHUE DJ: Activating mutations in the extracellular domain of the fibroblast growth factor receptor 2 function by disruption of the disulfide bond in the third immunoglobulin-like domain. *Proc Natl Acad Sci* 95:4567-4572, 1998.
- VAN DEN EIJNDE SM, BOSHAART L, REUTELINGSPERGER CPM, DE ZEEUW CI, VERMEIJ-KEERS CHR: Phosphatidylserine plasma membrane asymmetry in vivo: A pancellular phenomenon which alters during apoptosis. *Cell Death Diff* 4:311-316, 1997a



- VAN DEN EIJNDE SM, LUIJSTERBURG AJM, BOSCHART L, DE ZEEUW CI, REUTELINGSPERGER CPM, VERMEIJ-KEERS CHR: In situ detection of apoptosis during embryogenesis with annexin V: From whole mount to ultrastructure. *Cytometry* 29:313-320, 1997b.
- VAN DER HOEVEN F, SCHIMMANG T, VOLKMANN A, MATTEI M-G, KYEWSKI B: Programmed cell death is affected in the novel mouse mutant Fused toes (Ft). *Development* 120:2601-2607, 1994.
- VERMEIJ-KEERS CHR, MAZZOLA RF, VAN DER MEULEN JC, STRICKLER M: Cerebrocraniofacial and craniofacial malformations: An embryological analysis. *Cleft Palate J* 20:128-145, 1983.
- WILKIE AOM: Craniosynostosis: Genes and mechanisms. *Hum Mol Genet* 6:1647-1656, 1997.
- ZIMMERMANN B: Degeneration of osteoblasts involved in intramembranous ossification of fetal rat calvaria. *Cell Tissue Res* 267:75-84, 1992.



#### **IV. FGFR-MUTATIONS AND THEIR PHENOTYPES**



**IV.1. Pfeiffer syndrome resulting from a Ser351Cys mutation in the fibroblast growth factor receptor-2 gene.**

Mathijssen IMJ, Vaandrager JM, Hoogeboom AJM, Hesseling-Janssen ALW, Van Den Ouweland AMW.

*Journal of Craniofacial Surgery 9: 207-209, 1998.*

Note: Okajima et al. (1999) further described the severe phenotype of the Ser351Cys mutation, in particular the associated ocular anterior chamber dysgenesis.



# Pfeiffer's Syndrome Resulting From an S351C Mutation in the Fibroblast Growth Factor Receptor-2 Gene

I. M. J. Mathijssen, MD\*  
J. M. Vaandrager, MD\*  
A. J. M. Hoogeboom, PhD, MD†  
A. L. W. Hesselink-Janssen, MSc†  
A. M. W. van den Ouweland, PhD†

Rotterdam, The Netherlands

For four of the most well-known craniosynostosis syndromes—Apert's, Crouzon's, Pfeiffer's, and Jackson-Weiss' syndromes—mutations in the fibroblast growth factor receptors (FGFRs) have been described. These substitutions arise mainly in the FGFR-2 gene and to a much lesser degree in the FGFR-1 and FGFR-3 genes. We present a patient with an apparently sporadic type of Pfeiffer's syndrome, exhibiting nearly all associated features of this syndrome. A mutation in the FGFR-2 gene was found, namely serine351-cysteine. This mutation has been reported in only one patient so far, whose phenotype could match both Crouzon's and Pfeiffer's syndromes.

**Key Words:** Fibroblast growth factor receptor, Pfeiffer's syndrome, genetics

**C**raniosynostosis can be defined as the premature fusion or agenesis of cranial sutures, resulting in an abnormal morphology of the skull. This feature can be either solitary (i.e., isolated or nonsyndromic craniosynostosis) or in combination with other congenital disorders (i.e., syndromic craniosynostosis).<sup>1</sup> In syndromic cases, the associated anomalies are primarily those of the hand and feet. The best known syndromic types of craniosynostoses are Apert's, Crou-

zon's, Pfeiffer's, Saethre-Chotzen, and Jackson-Weiss' syndromes. Only Apert's syndrome can clinically be diagnosed with great certainty because these patients exhibit symmetrical complex (bone and soft tissue) syndactyly of both hands and feet, apart from the synostotic coronal sutures and a wide gap in the skull at the site of the metopic suture at birth. Crouzon's syndrome is diagnosed by the presence of bilateral exophthalmos and maxillary hypoplasia, with the absence of hand and feet anomalies. At birth the calvarial sutures are patent in most cases; pansynostosis (closure of all cranial sutures) develops with time. Pfeiffer's and Saethre-Chotzen syndrome patients demonstrate bilateral involvement of the coronal suture, like Apert's syndrome patients. In addition, Pfeiffer's syndrome is characterized by broad thumbs or broad halluces, whereas in Saethre-Chotzen syndrome patients usually present with a simple (soft tissue) incomplete syndactyly of hands or feet apart from eyelid ptosis and a low-set hairline. Jackson-Weiss' syndrome reveals the facial characteristics of Pfeiffer's and Saethre-Chotzen syndrome but is only associated with foot abnormalities, such as broad first metatarsals and fused tarsal bones. Saethre-Chotzen syndrome is the only one of these five in which the mutation was traced not in the FGFR genes but in the TWIST gene. A review of all published mutations in craniosynostosis was presented by Wilkie.<sup>2</sup> The mutation S351C identified in our patient with Pfeiffer's syndrome has been reported once in a patient with an unclassified type of craniosynostosis.<sup>3</sup>

## PATIENT

**A**t birth, a female infant, the firstborn of her parents, presented with multiple congenital malformations, namely bilateral synostosis of the coronal

From the \*Departments of Plastic and Reconstructive Surgery, University Hospital Rotterdam, and †Clinical Genetics, Erasmus University, Rotterdam, The Netherlands.

Address correspondence to Dr. Mathijssen, Department of Plastic and Reconstructive Surgery, Erasmus University Rotterdam, Room Ee 1257, Hoboken, PO Box 1738, 3000 DR Rotterdam, The Netherlands.

sutures, exophthalmos, hypertelorism, coloboma of the left eye, hypoplasia of the maxilla, choanal atresia, depressed nasal bridge, protrusion of the tongue, high arched palate, and an enlarged frontal fontanelle. Furthermore, vision and hearing were impaired. Because she suffered from progressive airway obstruction, necessitating a tracheotomy at the age of 2 months, she was referred to our children's hospital.

At examination, broad thumbs and halluces were evident, pathognomonic for Pfeiffer's syndrome. X-ray films of her hands and feet confirmed broad distal phalanges of both thumbs and broad halluces. The patient suffered from epilepsy, and a computed tomographic scan revealed a mild hydrocephalus. Magnetic resonance imaging showed Dandy-Walker complex type B, a retrocerebellar arachnoidal cyst, cerebellar hypoplasia, corpus callosum aplasia, and hypoplasia of the optic nerves. A monobloc procedure was undertaken at the age of 3 months. As intracranial pressure raised, a ventriculoperitoneal drain was inserted. To ascertain the diagnosis of Pfeiffer's syndrome, blood samples for deoxyribonucleic acid (DNA) analysis were taken from the patient and her parents, who were seemingly unaffected.

## MATERIALS AND METHODS

DNA was isolated from peripheral blood cells according to standard procedures.

### Exon Amplification

To identify the mutation, polymerase chain reaction (PCR) analysis was performed of exon 5 of the fibroblast growth factor receptor (FGFR)-1 gene and exon 9 of the FGFR-2 gene. PCR primers for amplification of exon 9 of FGFR-2 were forward: 5'-CACAAATCATTCCTGTGTCGT-3' and extended at the 5' end with the -21M13 FOR primer and the reverse primer: 5'-AACCCAGAGAGAAAGAACAGT-3' with an extension at the 5' end with the -29M13 REV primer. The length of the normal PCR product is 225 bp (without M13 sequence extension).

PCR conditions for 100  $\mu$ l were 1 mM MgCl<sub>2</sub>, 0.5 mM spermidine, 34 pmol of each primer, 200  $\mu$ mol mix of dATP, dCTP, dGTP, and dTTP, 0.05% W-1, 2 U Taq polymerase (Gibco BRL), 800 ng genomic DNA. Thermal cycle conditions were 10 minutes at 95°C, followed by 35 cycles of 30 seconds at 95°C, 30 seconds at 55°C, 90 seconds at 72°C, with a final elongation of 10 minutes at 72°C.

## Sequence Analysis

For direct sequence analysis of the PCR products, 100  $\mu$ l of PCR product was purified with the Qiaquick PCR purification kit (Qiagen). The ready reaction dye primer cycle sequencing kit -21M13 and M13 reverse AmpliTaqFS (Perkin Elmer) was used.

### Allele-Specific Oligonucleotide Hybridization

For the allele-specific oligonucleotide (ASO) hybridization, the sequence of the "normal" oligonucleotide was 5'-GGGATATCCTTTCAC-3' and for the "mutant" oligonucleotide 5'-GGGATATGCTTTCAC-3'. Hybridization was performed at 37°C for 60 minutes. Filters were washed to 0.1  $\times$  SSC + 0.1% SDS for 5 minutes at 37°C.

## RESULTS

Direct sequence analysis of PCR products of exon 5 of the FGFR-1 gene did not reveal any mutation. Sequence analysis of exon 9 of the FGFR-2 gene identified the nucleotide substitution C into G at position 1064, resulting in the amino acid substitution of serine at position 351 into cysteine. Using ASO hybridization, the presence of the S351C mutation was confirmed in DNA of the patient and was absent in DNA isolated from peripheral blood cells of her parents.

## DISCUSSION

We describe a mutation associated with a sporadic case of Pfeiffer's syndrome, which was previously found in a patient presenting with a Crouzon's and Pfeiffer's syndrome-like appearance.<sup>3</sup> Both the type of substitution (cys for ser) and its locus were considered to favor the classification of Crouzon's syndrome. In our patient, all malformations are consistent with Pfeiffer's syndrome, relating this clinically depicted syndrome to the S351C mutation. So far, no correlation could be established between phenotypic features and specific FGFR gene mutations. Probably all these slightly different alterations in the FGFRs result in a basically similar biochemical effect, affecting both skull and hand development. The varying clinical presentations could possibly be caused by different genetic background (e.g., modifying genes) of each individual. These modifying genes could, for instance, cause a different time of onset of the mutated gene or cause a varying degree of its expression. The influence of the genetic background can thus be reflected in the observed outcome and alter the resulting phenotype.



The FGFR-2 gene is the only one of the involved FGFR genes for which the expression pattern during skull development has been established.<sup>4</sup> Its transcripts are mainly located in the region of the future coronal suture, whereas no FGFR-2 expression was found in other presutural regions in the examined developmental stages. The altered FGFRs appear to result in ligand-independent signaling.<sup>4,5</sup> Mimicking this increase in function by applying FGF during coronal suture development in the mouse (15 days postconception) resulted in premature differentiation of osteogenic stem cells in the sutural area.<sup>4</sup> However, no true synostosis was observed. Currently, we are investigating the role of apoptotic (programmed) cell death in craniosynostosis, because this process is partially regulated by the FGFs and their receptors.<sup>6</sup> An earlier study demonstrated apoptosis to take place during normal embryogenesis of cranial sutures.<sup>7</sup> Inhibition of apoptosis through enhanced FGF/FGFR signaling appears to contribute to the development of craniosynostosis, as injection of FGF during the developmental stage in which apoptosis takes place (starting from 16 days postconception) led to true fusion of the murine suture.<sup>8</sup> At this stage, the exact role of apoptotic cell death in the pathogenesis of craniosynostosis is still under investigation.

Although DNA isolated from peripheral blood cells of the parents is negative for the S351C mutation, this does not exclude the possibility that one of the parents is a germline mosaic. Therefore, for the parents of our patient, the recurrence risk of having another affected child might be up to 50%. On the other hand, a correlation between increased paternal age and the high rate of mutations in FGFRs appears to exist.<sup>9</sup> The father of our patient was 42 years of age at the time of the patient's birth; he had two older, healthy children from a previous marriage.

Apart from the contribution of DNA analysis in family counseling and prenatal diagnostics for craniosynostosis syndromes, the use of genotypic-phenotypic characterization as a classification tool for craniosynostosis is not yet conclusive. Such a classification is to be expected once the interactions of the genetic package are understood.

---

We thank Dr Christl Vermeij-Keers for critically reviewing this article.

---

#### REFERENCES

1. Cohen MM Jr, ed. Craniosynostosis. Diagnosis, evaluation, and management. New York: Raven Press, 1986
2. Wilkie AOM. Craniosynostosis: genes and mechanisms. *Hum Molec Genet* 1997;6:1647-1656
3. Pulleyn LJ, Reardon W, Wilkes D, et al. Spectrum of craniosynostosis phenotypes associated with novel mutations at the fibroblast growth factor receptor 2 locus. *Eur J Hum Genet* 1996;4:283-291
4. Iseki S, Wilkie AOM, Heath JK, et al. FGFR2 and osteopontin domains in the developing skull vault are mutually exclusive and can be altered by locally applied FGF2. *Development* 1997; 124:3375-3384
5. Galvin BD, Hart KC, Meyer AN, et al. Constitutive receptor activation by Crouzon syndrome mutations in fibroblast growth factor receptor (FGFR) 2 and FGFR2/Neu chimeras. *Proc Natl Acad Sci* 1996;93:7894-7899
6. Jung M, Kern FG, Jorgensen TJ, et al. Fibroblast growth factor-4 enhanced G<sub>2</sub> arrest and cell survival following ionizing radiation. *Cancer Res* 1994;54:5194-5197
7. Bourez RLJH, Mathijssen IMJ, Vaandrager JM, Vermeij-Keers C. Apoptotic cell death during normal embryogenesis of the coronal suture: early detection of apoptosis in mice using Annexin V. *J Craniofac Surg* 1997;8:441-445
8. Mathijssen IMJ, Vermeij-Keers C, Vaandrager JM. The role of apoptotic cell death during normal sutural embryogenesis in mice; inhibition through FGF4 application results in synostosis. In: *Proceedings of the VIIth Congress of the International Society of Craniofacial Surgery*, Santa Fe, NM, 1997
9. Moloney DM, Slaney SF, Oldridge M, et al. Exclusive paternal origin of new mutations in Apert syndrome. *Am J Hum Genet* 1996;58:923-932



**IV.2. Additional phenotypic features of the FGFR3 Pro250Arg mutation in two Dutch families.**

Mathijssen IMJ, Kwee HL, Janssen ALW, Van Den Ouweland AMW, Vaandrager JM, Algra PR, Hooigeboom AJM.

*Submitted.*



## **Additional phenotypic features of the FGFR3 Pro250Arg mutation in two dutch families**

Mathijssen I.M.J.<sup>1</sup>, Kwee H.L.<sup>2</sup>, Janssen A.L.W.<sup>2</sup>, Van Den Ouweland A.M.W.<sup>2</sup>, Vaandrager J.M.<sup>3</sup>, Algra P.R.<sup>4</sup>, Hoogeboom A.J.M.<sup>2</sup>

<sup>1</sup> Institute of Plastic Surgery, Erasmus University Rotterdam;

<sup>2</sup> Department of Clinical Genetics, Erasmus University Rotterdam;

<sup>3</sup> Department of Plastic Surgery, University Hospital Rotterdam;

<sup>4</sup> Department of Radiology, Medical Center Alkmaar, The Netherlands

### **Abstract**

In about 50% of cases with syndromic craniosynostosis a genetic mutation can be traced. For the purpose of adequate genetic counseling and treatment of these patients the full spectrum of clinical findings for each specific mutation needs to be appreciated. The Pro250Arg mutation in the FGFR3 gene is one of the most frequently encountered mutations in craniosynostosis syndromes. A number of studies on relationship between genotype and phenotype concerning this specific mutation have been published. Two Dutch families with the Pro250Arg mutation were screened for the reported characteristics of this syndrome and for additional features. New phenotypical findings of the Pro250Arg mutation were hypoplasia of the frontal sinus, strabismus with vision impairment, dysplastic elbow joints with restricted elbow motion, and mild cutaneous syndactyly. Incidentally,

polydactyly, severe ankylosis of the elbow and fusion of cervical vertebrae were found. Of carpal and tarsal fusion, suggested to be pathognomonic for the Pro250Arg syndrome, only the latter was confirmed to be a hallmark in one family.

## **Introduction**

Genetic mutations related to craniosynostosis syndromes can be traced in the genes encoding for the fibroblast growth factor receptor (FGFR) 1, FGFR2, FGFR3 and in the TWIST gene. The Pro250Arg mutation within the FGFR3 gene (first reported by Bellus et al., 1996) is probably the most common mutation in genetic craniosynostosis. Moloney et al. (1997) demonstrated that the mutation rate at this locus is one of the highest known in the human genome. During the last few years this mutation has been found in cases with apparent isolated coronal synostosis and in families that initially were diagnosed with craniosynostosis-brachydactyly syndrome (Glass et al., 1994), Saethre-Chotzen syndrome (Von Gernet et al., 1996; Paznekas et al., 1998), Jackson-Weiss syndrome (Adès et al., 1994) and Adelaide type craniosynostosis (Hollway et al., 1995). This illustrates how difficult it can be to distinguish the different craniosynostosis syndromes from one another given their overlapping characteristics (Passos-Bueno et al., 1999). Traditionally, the associated malformations of the face and extremities are the hallmarks for syndrome delineation. With the discovery of genetic mutations in craniosynostosis a new tool for classification seemed to be at hand. Therefore, the relationship between genotype and phenotype became relevant. Recognition of the

entire spectrum of a given mutation is of importance for genetic counseling and patient care. Of course, genotype/phenotype correlation for mutations causing a very consistent and/or severe clinical presentation is most easily recognized. An example of such a consistent phenotype is the Apert syndrome, with full penetrance and a dramatic phenotype. The number of mutations that are known to cause Apert syndrome is limited to five (Wilkie et al., 1995; Oldridge et al., 1997; Oldridge et al., 1999), although 99% of the cases suffer from either Ser252Trp or Pro253Arg mutations in FGFR2 (Anderson et al., 1998). Another mutation of which all carriers are severely affected in a rather uniform way is the Ser351Cys mutation of the FGFR2 gene (Pulleyn et al., 1996; Gripp et al., 1998a; Mathijssen et al., 1998; Okajima et al., 1999). However, for most craniosynostosis causing mutations, especially those in FGFR2, the phenotypes are heterogeneous. Perhaps consistencies between genotype and phenotype are yet undiscovered for some mutations because of the limited number of patients for each specific mutation within a craniofacial center. With respect to the FGFR3 Pro250Arg mutation and its clinical features several patients have been described. Combining these papers has resulted in a rather detailed description of abnormalities that may be encountered in carriers. Pro250Arg carriers can present with a wide range of cranial features, from normocephaly to macrocephaly, uni- or bilateral coronal synostosis or even a cloverleaf skull (Golla et al., 1997). Facial characteristics may include midfacial hypoplasia, malocclusion, a high arched palate, downslanting palpebral fissures, hypertelorism, and ptosis. Other

encountered findings can be developmental delay or learning problems, congenital bilateral sensorineural hearing loss, broad thumbs and halluces without deviation, brachydactyly, and clinodactyly. X-rays of the extremities may show broad and thimble-like midphalanges, short metacarpal bones and midphalanges, absent or fused midphalanges, hypoplasia of the mid- and distal phalanges, cone-shaped epiphyses, and carpal (capitate-hamate) or tarsal (calcaneo-cuboidal or calcaneo-navicular) fusion (Reardon et al., 1997; Muenke et al., 1997; Gripp et al., 1998b; Graham et al., 1998; Hollway et al., 1998). Anomalies of the hand mostly involve the fifth ray. Incidentally, strabismus and slight partial syndactyly of the second and third toes or of the third and fourth fingers are reported (Von Gernet et al., 1996). But even a normal aspect of the skull, face and limbs with normal intelligence is part of the spectrum (Robin et al., 1998). Lajeunie et al. (1999) demonstrated that females were significantly more severely affected than males. In two families within our craniosynostosis population new features of this mutation were detected, while the presence of previously reported malformations was either confirmed or absent. Here the clinical presentation of two families is brought, with 8 and 4 affected members respectively.

## **Material and Methods**

### **DNA analysis**

DNA was isolated from peripheral blood cells according to standard procedures.



To identify the mutation P250R in exon 7 of the FGFR3 gene, allele specific oligonucleotide hybridization was undertaken. PCR primers used to amplify exon 7 were forward: 5'-

TCGGCAGTGACGGTGGTGG-3' and the reverse primer: 5'-GGAGCCCCAGCGGCGGC-3'. The length of the PCR product is 296bp.

PCR conditions for 100 µl reactions were 1mM MgCl<sub>2</sub>, 66 pmol of each primer, 200 µmol mix of dATP, dCTP, dGTP and dTTP, 0.05% W-1, 4U Taq polymerase (Gibco BRL), 800ng genomic DNA.

Thermal cycle conditions were 10 minutes at 95°C followed by 35 cycles of 45 seconds at 95°C, 45 seconds at 60°C, 90 seconds at 72°C, with a final elongation of 10 minutes at 72°C.

The sequence of the "normal" oligonucleotide was 5'-GAGCGCTCCCCGC-3' and for the "mutant" oligonucleotide 5'-GCTCCCGGCACCG-3'. Hybridization was performed at 40°C for 60 minutes. Filters were washed to 0.3 X SSC + 0.1% SDS for 5 minutes at 40°C.

### **Family 1**

Of this three generation family 12 persons were available for screening (fig. 1, table 1). Looking at their family albums, it is very likely that the mother of I:2 was affected as well, just like at least three of her 12 other children (7 females, 5 males; not illustrated in fig. 1). Two of these three daughters appear to have had affected daughters themselves, although not confirmed genetically.

Only one girl (III:2) in this family was recognized to be affected with craniosynostosis and operated on. Eight persons (4 men, 4 women) were carriers of the Pro250Arg mutation. Five mentioned recurrent otitis media, one had recurrent frontal sinusitis (II:1), two suffered from epilepsy requiring medication, one complained about frequent headaches, one was diagnosed with benign neoplasias of the vocal cords, and one had a benign process near the right mandible surgically removed. All were within the normal range for length and weight. Three (II:4, II:5, III:3) had developmental delay necessitating special schooling. Head circumferences ranged from below p3 (n=1), p10 (n=1), between p10 and p25 (n=1), and between p50 and p75 (n=5). Midfacial hypoplasia was observed in three. All carriers had a narrow and high arched palate. Other abnormalities concerning the eyes, orbits, sight and hearing are enlisted in table 1. X-rays of the skull indicated hypoplasia of the frontal sinus in five (fig. 2) possibly six, but the hypoplasia in this patient (III:2) could also be the result of her supraorbital advancement. One affected girl (III:3) suffered from fusion of the spinous processes of the second and third cervical vertebrae. Furthermore, she had a severe loss of extension of her elbows due to dysplastic elbow joints (fig. 3) combined with slight bowing of the radius.

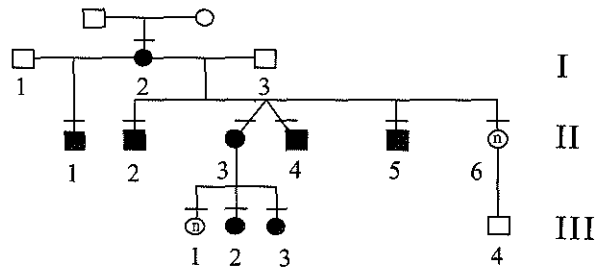
Mild cutaneous syndactyly of the hands between digits III and IV was noticed in five family members, and brachydactyly in six (3 affecting all digits, 3 only of the little finger; table 1). Never did we detect carpal fusion on the X-rays of these 8 carriers. The encountered feet

anomalies are reported in table 1. X-rays of the feet were only available in two, in whom tarsal fusion was noticed once.

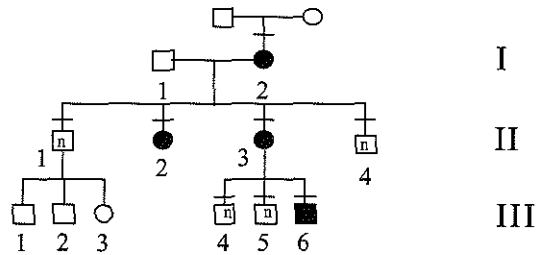
## **Family 2**

Based on pictures of her parents, brothers and sisters, the grandmother I:2 appeared to be the one in whom the mutation arose de novo. Four persons were proven to be carriers of the Pro250Arg mutation (fig. 1). With the exception of the youngest of the family (III:6) no one had undergone any form of craniofacial surgery. During childhood one (II:2) was operated for correction of her strabismus and two (II:2, II:3) had ventilation tubes placed to treat their deafness. The grandmother and her two affected daughters were all wearing glasses ever since childhood. Having missed the diagnosis of craniosynostosis, helmet treatment was applied to correct the head asymmetry in daughter II:3 during the period of one to four years of age. All were within the normal range for length and weight. Those positive for the mutation had significant learning difficulties requiring special schooling. Head circumferences were near p10 (n=1), p50 (n=2), and p75 (n=1). Confirmed hallmarks of the Pro250Arg syndrome in this family were plagio- or brachycephaly, hypertelorism, deafness, and brachydactyly, while restricted elbow extension, strabismus with reduced vision were new related features (table 2). None of the carriers had midfacial hypoplasia but all had a high arched palate that was narrow in front. For this malformation the grandmother was treated with a palatal brace when she was a child. Each of the three adult carriers had numerous teeth extracted because of crowding and ad random

positioning. The hair was noticed to be thick and abundantly present, having a characteristic distribution with the hair directed anteriorly and upward. Hypoplasia of the frontal sinus was again frequently encountered. In all three available X-rays of the feet synostosis of the navicular and cuboid bones was found. The grandmother had a 20° extension deficit of the right elbow and the X-rays of both her elbows indeed only showed ankylosis on the right side. Her first daughter (II:2) had an extension deficit of both elbows with dysplastic elbow joints on X-ray, while in the grandson (III:6) pronation was limited. Quite surprisingly, II:4 turned out negative for the Pro250Arg mutation four times, using four blood samples which were obtained on two separate occasions, although he shared numerous craniofacial characteristics with his sibs. His head was brachycephalic with a marked retrusion and elongation of the forehead. Besides a long face, his upper and lower jaw were normal developed and adequately positioned. There was hypertelorism and he had undergone surgical correction for strabismus on one eye. Ever since he was a child he wore glasses, but his hearing was undisturbed. He also suffered from significant learning difficulties. Nearly all his teeth had been removed as they were numerous and at random positioned. His palate was high but not narrowed. While his hands and elbows were clinically normal, his feet revealed small digits V. X-rays of his hands were normal but those of his feet showed navicular-cuboid fusion on both sides.



Family 1



Family 2

Figure 1. Pedigrees of family 1 and 2 with respectively eight and four genetically proven carriers of the Pro250Arg mutation (■ and ●). Persons that were shown not to carry the Pro250Arg mutation are indicated with (n). Member II:4 of family 2 is suspected to carry the mutation although this has not been proven yet.

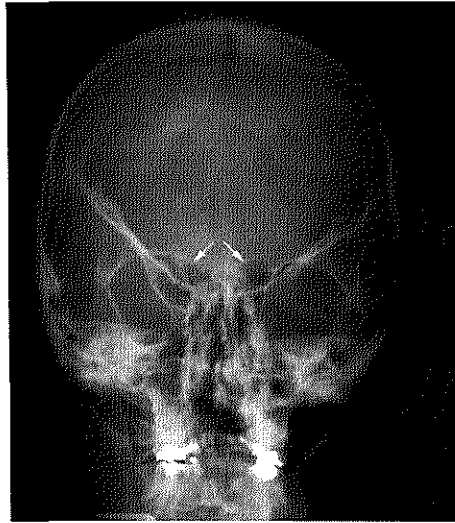


Figure 2. Skull X-ray of member II:2 of family 2 at age 34 showing hypoplasia of the frontal sinus.

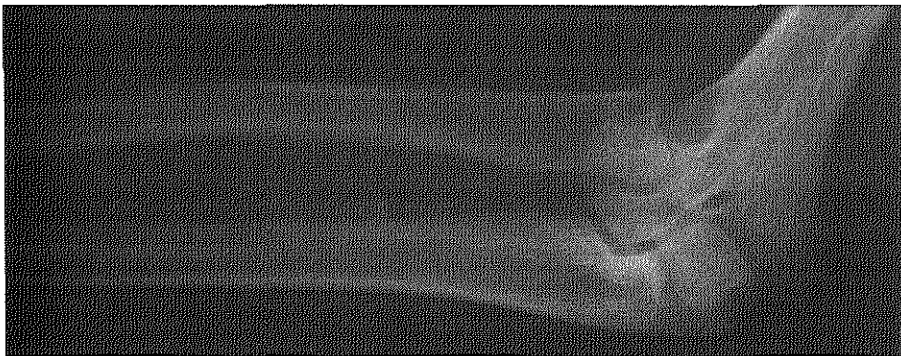


Figure 3. X-ray of the right elbow of member III:2 of family 1 at age 13 revealing a dysplastic elbow joint.

Patient	head	X-skull	eyes and orbits	sight	hearing	hands/elbows	X-hand	feet	X-feet
I:2	brachy	hypoplasia frontal sinus	supraorb. depr. telecanthus	glasses	↓	normal	normal	normal	-
II:1	brachy	hypoplasia frontal sinus, diastasis C2	supraorb. depr. hypertelorism	normal	↓	cut. syndactyly	normal	polyd., cut.syn- dactyly	dyspl. PPh, fusion MPh- DPh dig V
II:2	normal	normal	normal	normal	normal	cut. syndactyly, brachyd. of all digits	normal	hypopl. dig III	-
II:3	brachy	hypoplasia frontal sinus	orb. dystopia, exorbitism	glasses	↓↓	cut. syndactyly, brachyd. dig V	hypopl. MPh V	normal	-
II:4	brachy	hypoplasia frontal sinus	strabismus, iris coloboma, supraorb. depr., orbital dystopia, hypertelorism nystagmus	glasses	↓	cut. syndactyly	normal	normal	-
II:5	plagio	hypoplasia frontal sinus	strabismus, orb. dystopia	normal	normal	brachyd. of all digits	normal	normal	calcaneo- naviculare fusion

Patient	head	X-skull	eyes and orbits	sight	hearing	hands/elbows	X-hand	feet	X-feet
III:2	plagio	frontal sinus?	strabismus, orb. dystopia, downslant eyelids	glasses	normal	cut. syn-, dactyly, brachyd. dig V	hypopl. MPh V	cut.syn- dactyly	-
III:3	normal	fusion sp.proc.C2-C3	strabismus, hypertelorism upslant eyelids	glasses	↓↓	brachyd. dig V, flex.contracture elbows	hypopl. MPh V	hypopl. dig III	-

Table 1. Phenotypes of the Pro250Arg mutation carriers in family 1.

Abbreviations: CS = coronal suture synostosis; orb. = orbital; supraorb. depr. = supraorbital depression; sp.proc. = spinous processes; brachyd. = brachydactyly; cut. = cutaneous; dyspl. = dysplasia; DPh = distal phalanx; MPh = midphalanx; PPh = proximal phalanx; hypopl. = hypoplasia; polyd. = polydactyly; flex. = flexion.



Patient	head	X-skull	eyes and orbits	sight	hearing	hands/elbows	X-hand	feet	X-feet
I:2	brachy		hypertelorism	glasses	↓	20° ext. deficit r-elbow	normal	normal	N-C fusion
II:2	brachy	hypoplasia frontal sinus	strabismus, hypertelorism	glasses	↓↓	20° ext. deficit r/l-elbow	normal	normal	N-C fusion
II:3	plagio	unilateral hypoplasia frontal sinus	strabismus, orb. dystopia, hypertelorism	glasses	↓	brachyd. of all digits, esp. dig V	hypopl. MC's + phalanges	normal	N-C fusion
III:6	brachy	bilateral CS	hypertelorism	n?	↓↓	brachyd. of all digits; limited pronation	pseudo- epiphyses PPh II, cone-shaped MPh's	normal	-

Table 2. Phenotypes of the Pro250Arg mutation carriers in family 2.

Abbreviations: CS = coronal suture synostosis; orb. = orbital;  
brachyd. = brachydactyly; hypopl. = hypoplasia; MPh = midphalanx; PPh = proximal phalanx;  
MC = metacarpal bone; MT = metatarsal bone; N-C = navicular-cuboid bones;  
ext. = extension; l = left; r = right.

## **Discussion**

The known variation in head shape in Pro250Arg mutation carriers was represented in our families, together with most of the facial characteristics. Developmental delay and hearing problems were also frequently encountered. However, none of the affected members suffered from carpal fusion although this was a consistent finding in the two families reported by Graham et al. (1998). Another reported common feature is the reduced length of the little finger. In the families described by Graham et al. (1998) a reduced length of the fifth metacarpal, with or without involvement of the middle and/or distal phalanges was in most cases the underlying cause. Our patients mainly had a shortened and dysplastic middle phalanx of the fifth finger. Applying the presence of hand abnormalities as predictor for carriership was very reliable in the first family, but not in the second (8/8 versus 2/4). Tarsal fusion, seen as navicular-cuboid fusion, appeared to be the most consistent presentation in the second family. New features that were commonly present in our families are hypoplasia of the frontal sinus, strabismus with vision impairment, dysplastic elbow joints with limited elbow motion, and mild cutaneous syndactyly. New but possibly incidental findings are polydactyly, and fusion of spinous processes of cervical vertebra.

Interestingly, the carriership of one clinically evidently affected person in family 2 could not be proven. A possible explanation for this finding could be that he is carrying another mutation in the vicinity of position 250 in the FGFR3 gene, which disturbs the functioning of the applied primer. Further analysis is therefore being conducted.

Given the high prevalence of the Pro250Arg FGFR3 mutation it seems appropriate to start analysis for this specific mutation, especially when there are no overt manifestations of other syndromic forms. Clinical recognition can be relatively easy if carpal or tarsal fusion is present but one should not reject the possibility of Pro250Arg carriership in its absence. Furthermore, there are no data on the incidence of carpal/tarsal fusion in other craniosynostosis syndromes. Being familiar with the variable presentation of this syndrome helps to recognize patients as such, although the genetic analysis remains essential. Once the Pro250Arg mutation is detected genetic analysis should be offered to all family members at risk.

## References

- Adès LC, Mulley JC, Senga IP, Morris LL, David DJ, Haan EA.** Jackson-Weiss syndrome: Clinical and radiological findings in a large kindred and exclusion of the gene from 7p21 and 5qter. *Am. J. Med. Genet.* 51: 121-130, 1994.
- Anderson J, Burns HD, Enriquez-Harris P, Wilkie AOM, Heath JK.** Apert syndrome mutations in fibroblast growth factor receptor 2 exhibit increased affinity for FGF ligand. *Hum. Molec. Genet.* 7: 1475-1483, 1998.
- Bellus GA, Gaudenz K, Zackai EH, Clarke LA, Sazbo J, Francomano CA, Muenke M.** Identical mutations in three different fibroblast growth factor receptor genes in autosomal dominant craniosynostosis syndromes. *Nat. Genet.* 14: 174-176, 1996.
- Glass IA, Chapman S, Hockley AD.** A distinct autosomal dominant craniosynostosis-brachydactyly syndrome. *Clin. Dysmorphol.* 3: 215-223, 1994.
- Golla A, Lichtner P, Gernet S von, Winterpacht A, Fairley J, Murken J, Schuffenhauer S.** Phenotypic expression of the

- fibroblast growth factor receptor 3 (FGFR3) mutation P250R in a large craniosynostosis family. *J. Med. Genet.* 34: 683-684, 1997.
- Graham JM Jr, Braddock SR, Mortier GR, Lachman R, Van Dop C, Jabs EW.** Syndrome of coronal craniosynostosis with brachydactyly and carpal/tarsal coalition due to Pro250Arg mutation in FGFR3 gene. *Am. J. Med. Genet.* 77: 322-329, 1998.
- Gripp KW, Stolle CA, McDonald-McGinn DM, Markowitz RI, Bartlett SP, Katowitz JA, Muenke M, Zackai EH.** Phenotype of the fibroblast growth factor receptor 2 Ser351Cys mutation: Pfeiffer syndrome. *Am. J. Med. Genet.* 78: 356-360, 1998a.
- Gripp KW, McDonald-McGinn DM, Gaudenz K, Whitaker LA, Bartlett SP, Glat PM, Cassileth LB, Mayro R, Zackai EH, Muenke M.** Identification of a genetic cause for isolated unilateral coronal synostosis: A unique mutation in the fibroblast growth factor receptor 3. *J. Pediatr.* 132: 714-716, 1998b.
- Hollway GE, Phillips HA, Adès LC, Haan EA, Mulley JC.** Localization of craniosynostosis Adelaide type to 4p16. *Hum. Molec. Genet.* 4: 681-683, 1995.
- Hollway GE, Suthers GK, Battese KM, Turner AM, David DJ, Mulley JC.** Deafness due to Pro 250 Arg mutation of FGFR3. *Lancet* 351: 877-878, 1998.
- Lajeunie E, El Ghouzzi V, Le Merrer M, Munnich A, Bonaventure J, Renier D.** Sex related expressivity of the phenotype in coronal craniosynostosis caused by the recurrent P250R FGFR3 mutation. *J. Med. Genet.* 36: 9-13, 1999.
- Mathijssen IMJ, Vaandrager JM, Hoogeboom AJM, Hesselings-Janssen ALW, Van Den Ouweland AMW.** Pfeiffer syndrome resulting from a serine351cystein mutation in the fibroblast growth factor receptor 2 gene. *J. Craniofac. Surg.* 9: 207-209, 1998.
- Moloney DM, Wall SA, Ashworth GJ, Oldridge M, Glass IA, Francomano CA, Muenke M, Wilkie AO.** Prevalence of Pro250Arg mutation of fibroblast growth factor receptor 3 in coronal craniosynostosis. *Lancet* 349: 1059, 1997.
- Muenke M, Gripp KW, McDonald-McGinn DM, Gaudenz K, Whitaker LA, Bartlett SP, Markowitz RI, Robin NH, Nwokoro N, Mulvihill JJ, Losken HW, Mulliken JB, Guttmacher AE, Wilroy RS, Clarke LA, Hollway G, Adès LC, Haan EA, Mulley JC, Cohen MM Jr., Bellus GA, Francomano CA, Moloney DM, Wall SA, Wilkie AO, et al.** A unique point mutation in the

- fibroblast growth factor receptor 3 gene (FGFR3) defines a new craniosynostosis syndrome. *Am. J. Hum. Genet.* 60: 555, 1997.
- Okajima K, Robinson LK, Hart MA, Abuelo DN, Cowan LS, Hasegawa T, Maumenee IH, Jabs EW.** Ocular anterior chamber dysgenesis in craniosynostosis syndromes with a fibroblast growth factor receptor 2 mutation. *Am. J. Med. Genet.* 85: 160-170, 1999.
- Oldridge M, Lunt PW, Zackai EH, McDonald-McGinn DM, Muenke M, Moloney DM, Twigg SRF, Heath JK, Howard TD, Hoganson G, Gagnon DM, Wang Jabs E, Wilkie AOM.** Genotype-phenotype correlation for nucleotide substitutions in the IgII-IgIII linker of FGFR2. *Hum. Molec. Genet.* 6: 137-143, 1997.
- Oldridge M, Zackai EH, McDonald-McGinn DM, Iseki S, Morriss-Kay GM, Twigg SRF, Johnson D, Wall SA, Jiang W, Theda C, Jabs EW, Wilkie AOM.** De novo alu-element insertions in FGFR2 identify a distinct pathological basis for Apert syndrome. *Am. J. Hum. Genet.* 64: 446-461, 1999.
- Passos-Bueno MR, Wilcox WR, Jabs EW, Sertié AL, Alonso LG, Kitoh H.** Clinical spectrum of fibroblast growth factor receptor mutations. *Hum. Mutat.* 14: 115-125, 1999.
- Paznekas WA, Cunningham ML, Howard TD, Korf BR, Lipson MH, Grix AW, Feingold M, Goldberg R, Borochowitz, Aleck K, Mulliken J, Yin M, Jabs EW.** Genetic heterogeneity of Saethre-Chotzen syndrome, due to TWIST and FGFR mutations. *Am. J. Hum. Genet.* 62: 1370-1380, 1998.
- Pulleyn LJ, Reardon W, Wilkes D, Rutland P, Jones BM, Hayward R, Hall CM, Brueton L, Chun N, Lammer E, Malcolm S, Winter RM.** Spectrum of craniosynostosis phenotypes associated with novel mutations at the fibroblast growth factor receptor 2 locus. *Eur. J. Hum. Genet.* 4: 283-291, 1996.
- Reardon W, Wilkes D, Rutland P, Pulleyn LJ, Malcolm S, Dean JCS, Evans RD, Jones BM, Hayward R, Hall CM, Nevin NC, Baraitser M, Winter RM.** Craniosynostosis associated with FGFR3 pro250arg mutation results in a range of clinical presentations including unsutural sporadic craniosynostosis. *J. Med. Genet.* 34: 632-636, 1997.
- Robin NH, Scott JA, Cohen AR, Goldstein JA.** Nonpenetrance in FGFR3-associated coronal synostosis syndrome. *Am. J. Med. Genet.* 80: 296-297, 1998.

- Von Gernet S, Schuffenhauer S, Golla A, Lichtner P, Balg S, Mühlbauer, Murken J, Fairley J, Meitinger T.** Craniosynostosis suggestive of Saethre-Chotzen syndrome: Clinical description of a large kindred and exclusion of candidate regions on 7p. *Am. J. Med. Genet.* 63: 177-184, 1996.
- Wilkie AOM, Slaney SF, Oldridge M, Poole MD, Ashworth GJ, Hockley AD, Hayward RD, David DJ, Pulleyn LJ, Rutland P, Malcolm S, Winter RM, Reardon W.** Apert syndrome results from localized mutations of *FGFR2* and is allelic with Crouzon syndrome. *Nature Genet.* 9: 165-172, 1995.

## GENERAL DISCUSSION

### *Classification of craniosynostosis*

The clinical classification of craniosynostosis syndromes, based upon associated malformations of the face and extremities, was shown to be insufficient (chapter I.1). Often no conclusive diagnosis can be made due to overlapping features, which is a major drawback given the impact on care. For example, comparison of surgical outcomes can only be undertaken when consensus exists on diagnosis. Our first morphological study (chapter II.1) was undertaken for classification purposes but eventually did not meet its goal. The genetic basis of craniosynostosis syndromes was thought to be a reliable and objective foundation for a new classification system. Disappointingly, genotype and phenotype often do not match. One mutation can give rise to a variety of abnormalities in various degrees (chapter IV.2), while a similar phenotype can be caused by numerous mutations, even in different genes (chapter I.2). Nonetheless, the analysis of genotype-phenotypic correlation is undertaken and being reported because of the possible clinical importance (below). A number of similar articles describe the various types of mutations found in a certain clinically designated syndrome instead of vice versa. It would be more sensible to describe the phenotypic spectrum for individual mutations. Ultimately, a classification system for craniosynostosis with implications for specific care should be developed. Whether or not genetics will be the foundation remains to be seen. At present, we are still far off from a classification that can be implemented clinically. Until such a classification is introduced, we suggest to designate

patients according to the traditional classification combined with the mutation if detected. The clinical diagnosis should be applied as guideline for genetic analysis, pointing out the most likely mutation site. The coinciding of, for example, the clinical diagnosis of Saethre-Chotzen syndrome with the TWIST mutations can highly increase the efficiency of genetic screening. For the whole Saethre-Chotzen group with TWIST mutations a rather circumscribed clinical presentation is outlined, which currently can not be specified to type of mutation. It does seem to be justified to reserve the diagnosis of Saethre-Chotzen syndrome only for those patients with a proven TWIST mutation and to reclassify those with a FGFR mutation. A substantial number of patients suggestive for Saethre-Chotzen syndrome remain, in whom no mutation is detected yet. These groups should be separated by adding 'TWIST-positive or TWIST-negative' to the diagnosis of Saethre-Chotzen syndrome.

The number of mutations in FGFR1 and FGFR3 are limited and their phenotypes are fairly precisely mapped. This makes it more informative to speak of a FGFR1-Pfeiffer syndrome, indicating a mild presentation, instead of just Pfeiffer syndrome. FGFR3 Pro250Arg syndrome still requires an indication of the individual's phenotype given the associated wide range of presentation. This mainly leaves us with the patients with a FGFR2 mutation, in whom the largest spread in presentation is found. Particularly in these patients one needs to be cautious in labeling them with only the classical diagnoses such as Pfeiffer, Crouzon or Jackson-Weiss syndromes. Especially the last syndrome seems to be exclusively related to the Ala344Gly mutation.



Future geno-phenotypical analysis should be focused on FGFR2 mutations. In half of the number of patients no mutation can be detected at present, leaving them with just diagnoses of the classical classification. Of course this does offer the clinician a guideline by which patients have been treated for over thirty years now. The current knowledge on the relationship between genotype and phenotype can however be applied directly, in both pre- and postnatal care.

In a pregnancy with known carriership of a craniosynostosis mutation in one of the parents, amniotic fluid puncture or chorion villus biopsy may exclude or confirm carriership of the child. If the range of phenotypic presentation is established for the mutation in question, more specific genetic counseling can be offered. In case of a consistent relationship between genotype and phenotype, such as the FGFR2 mutation Ser351Cys (chapter IV.1), a reliable prediction on mental and physical status can be given. However, if it for instance concerns the most commonly encountered mutation Pro250Arg in FGFR3, predicting the phenotype becomes a wild guess (chapter IV.2). The presence or absence of craniosynostosis in the infant can then only be determined prenatally through an additional ultrasound. Because ultrasound doesn't have any of the associated risks that punctures or biopsies have, this test might even be considered instead of prenatal mutation analysis in specific cases such as the Pro250Arg mutation. New developments in the field of 3-dimensional ultrasound may further enhance the possibility to detect craniosynostosis and other congenital malformations, also in the non-genetic cases.

### *Skull development*

The morphological studies of the cranium enabled us to trace the developmental stage during which the synostosis was initiated (chapter II.2). For each suture the period of development was stated and thus can its synostosis be detected from that time on. The metopic suture is the first of the cranial sutures to develop at about 15 weeks of gestation, soon followed by the coronal sutures. Theoretically, the fusion between the frontal and parietal bones in coronal suture synostosis can be visualized ultrasonically from 16 weeks of gestation onwards. Routine prenatal screening by ultrasound for congenital malformations does however not include the search for craniosynostosis. This is questionable given the estimated frequency of 1 in 2,000-2,500 births that makes craniosynostosis everything but the rare disorder it is generally thought to be. Other associated malformations besides those of the extremities such as deafness, mental retardation and visual impairment can at present not be tested prior to birth.

Once the child is born, specific screening and treatment should be performed in relation to the mutation. For instance, outcome of craniofacial intervention in patients with the Pro250Arg mutation in FGFR3 has been shown to be worse compared to patients without mutation (Renier et al., 2000). This is mainly due to the associated severe bulging of the temporal fossae, which should thus be addressed during surgery.

Given our limited knowledge on geno-phenotypic relations, unknown associated malformations will remain undetected. In light of this, there is the need to keep reporting additional clinical findings. Furthermore, screening of patients should at present be performed more extensively to further delineate the mutation specific phenotypic spectrum.

Another aspect of the discovery of the FGFR and TWIST mutations in craniosynostosis is the detection of mutations in patients who were originally diagnosed as isolated cases of craniosynostosis. Subsequently, mutation carriers were identified who were very mildly affected or normal. This is of major importance given their 50% risk of passing the mutation on to their offspring. Generally, it is recommended to screen all patients with uni- or bilateral coronal suture synostosis in particular for the Pro250Arg mutation in FGFR3. Also in cases where the metopic suture is involved, one should always be alert for an underlying syndrome (Lajeunie et al., 1998).

#### *Pathoembryogenesis of craniosynostosis*

Our initial hypothesis of bone center displacement being a causal factor in craniosynostosis (Vaandrager et al., 1995; chapter II.1, Mathijssen et al., 1997a; Mathijssen et al., 1997b) was later proven to be wrong. Studies on the calvarial morphology of rabbit embryos suffering from coronal suture synostosis showed the bone center displacement to occur following the suture ossification (Mooney et al., 1998; Dechant et al., 1998; Dechant et al., 1999). By studying both normal (chapter III.1) and abnormal development of the murine coronal suture (chapter III.2), we attempted to disclose some aspects

of the pathogenesis. The focus was on the occurrence of apoptosis since we anticipated involvement of this process in the pathogenesis of craniosynostosis (chapter III.1). During normal development apoptotic cells were traced near the osteogenic fronts of the frontal and parietal bones at the sites where they were in approximation. The sutural area itself remained free from apoptosis. The first apoptotic cells were detected in murine embryos of 16 days post conception. Rice and others (1999) later confirmed the timing and distribution of apoptotic cells we described. Combining these observations with the studies done by Iseki et al (1997; 1999) it appears that apoptosis is directly related to bone differentiation. Functionally, apoptosis may be involved in keeping the balance between proliferation and differentiation within the suture by reducing the number of cells that reach the stage of the osteocyte. Otherwise, it may well be that the remnants of the apoptotic cells contribute to the mineralization of the osteoid (Landry et al., 1997; Ferguson et al., 1998). Next, we tried to mimic the increased signalling of the FGFR2 mutations by exposing the developing murine suture to extra FGF4 or FGF2 (chapter III.2). Twenty four hours after the injection the sutures showed obliteration macroscopically. Initially, we reported this finding to be probably due to inhibition of apoptosis (Mathijssen et al., 1999a) because this effect of FGF4 had been reported in literature (Jung et al., 1994; Chow et al., 1995; Macias et al., 1996). When histological samples became available quite the opposite appeared to be true. The number of apoptotic cells was markedly increased and these cells were located throughout the sutural area, from the frontal bone to the parietal bone

(chapter III.2. Mathijssen et al., 1999b). Bone differentiation, visualized by collagen type I expression, was enhanced simultaneously. The degree and extent of mineralization both increased, resulting in thicker bones which were in closer vicinity to each other at the sutural site. Using a similar mouse model, Iseki and coauthors (1999) also demonstrated enhanced bone differentiation at the expense of proliferation within FGF2 exposed coronal sutures. Cultured osteoblastic cells derived from fused sutures from infants with craniosynostosis showed an increased maturation, matching the animal studies (De Pollack et al. 1996). Likewise, human calvarial cells with the Ser252Trp mutation in FGFR2 underwent premature osteoblast differentiation (Lomri et al., 1998), which was associated with a down-regulation of FGFR2 in these cells (Lemonnier et al., 2000). The rate of proliferation of mesenchymal cells, preosteoblasts or osteoblasts was however not altered (Lemonnier et al., 2000). Fragale et al. (1999) grew osteoblasts positive for either the Pro253Arg or Cys342Arg FGFR2 mutation and osteoblasts from patients with a isolated craniosynostosis. All three celltypes revealed a lower proliferation rate and a marked differentiated phenotype in comparison to normal osteoblasts.

Once the suture is ossified, causing fusion of the neighboring bone plates, growth of the skull can no longer take place at the affected suture but only at the remaining ones, giving rise to the characteristic distorted skull shape. Because growth within the suture has ceased, the bone centers get fixed at a certain distance from one another. This can be visualized as bone center displacement (chapter II.2) on dry skulls,

during operation and on CT scans of the skull. In retrospect, the theory of Park and Powers described in 1920 matches best with the view we currently have on the pathoembryogenesis of craniosynostosis.

Given the still limited knowledge on normal suture biology, one can only try to explain the occurrence of craniosynostosis. All animal models, including our in vivo mouse model, are attempts to reproduce the human FGFR mutations. A normal FGF receptor exposed to an excess of ligand can not be expected to act identically to a mutated FGF receptor. Clarity on the remaining questions may come in the near future if the efforts to introduce FGFR mutations in a mouse will be successful, offering a more reliable craniosynostosis-model.

*Considerations and recommendations for future research and treatment*

Within the FGFR-related craniosynostosis syndromes the severity of disease may be related to the timing and degree of FGFR expression. Each mutation may have its own effect on the degree of receptor activation and thus on the degree of disturbance of the proliferation/differentiation balance, the amount of transcripts of the involved gene and on the ratio of isoforms. Of course, environmental effects and genetic background (Park et al., 1995) influence the final outcome. In particular, subtle differences in local expression of FGFs might ultimately determine the severity of the phenotype.

It is unclear why the sagittal suture is so rarely involved in the syndromic cases, although it is known to express FGFR2 at its osteogenic fronts during development (Kim et al., 1998; Mehrara et

al., 1998). Obviously, one cannot merely translate the findings for the coronal suture to the other sutures. Pathogenesis of the isolated forms of craniosynostosis, which is much more common than syndromic ones, remains obscure. Other sutures have been left out of the focus of this study, such as the squamosal suture. These aspects, including the associated congenital defects, will be a main topic of research for the coming years.

The following two suggestions for alternative treatment in the future have been reported, which are both in my view unrealistic:

1. The development of a specific inhibitors of FGFR signalling to inhibit receptor signalling in the involved patients during postnatal development (De Moerlooze and Dickson, 1997). Setting the technical abilities to construct such an inhibitor aside, this postnatal interference will probably be too late. In most cases, the erroneous FGFR signalling within the human coronal suture and resulting fusion already took place prenatally, just like the majority of its consequences on skull growth. Applying the imaginary FGFR inhibitors at the appropriate prenatal periods should bring the solution, but would first require studies on the teratologic effects they might have.

2. Surgical correction in utero. In a sheep model in utero surgical correction of the synostosis has been shown to fully correct or prevent the secondary malformations (Stelnicki et al., 1998b). However, for the human situation the risks associated with intrauterine surgery don't outweigh the advantages of early correction postnatally for

craniosynostosis and is therefore not likely to be carried out for this indication in the near future.

A somewhat more realistic alternative treatment for craniosynostosis could consist of transplanting bony stem cells into the reopened sutural area of the infant to replace the cells that were lost due to the genetic defect. A major drawback of this intervention is that probably environmental factors such as those produced by the dura mater are involved in sustaining this mitogenic population. Without the necessary input from its surroundings this newly grafted suture will probably ossify too. Again, this shows the need for more knowledge on how normal suture biology functions, in order to make a therapeutically application possible.

Reviewing the dilemmas that existed concerning craniosynostosis and the result of our studies and those of others, a number of recommendations for future research can be made. In 50% of the patients with a clearly syndromic form of craniosynostosis still no mutation can be detected. Perhaps their genetic defects are within the known genes, but are yet undiscovered because of technical limitations. The reported number of new mutations within the FGFR and TWIST genes are however declining, making it more likely that other genes carry the mutation, most probably those that are involved in the same signalling network, given the similar phenotype. One suggested group of genes is for instance that encoding for the FGFs. In light of the genetic research, the gathering of blood samples of every patient with a possible syndromic form of craniosynostosis and



no detectable mutation so far is recommended. This may speed up the rate at which new candidate genes for craniosynostosis can be traced. In most craniofacial centers, like in ours, it is now protocol to undertake genetic mutation analysis for each new patient with (suspected) syndromic craniosynostosis. Our elderly patients with syndromic craniosynostosis have also been offered the opportunity to undergo this genetic consultation. Most individual craniofacial centers will still have a restricted number of patients for each specific mutation. In this light, a European study could enhance the search for genotype/phenotype correlations highly. The current estimate on the incidence of craniosynostosis states 1 in 2,000-2,500 live births (Lajeunie et al., 1995a). Management of care for patients with craniosynostosis on a (inter)national level should be based on these numbers. In The Netherlands there is at present only one craniofacial center with a complete craniofacial team functioning according to the standards set by the American Cleft Palate and Craniofacial Society (1993) for a population of 15 million people. With nearly 200,000 births a year, a total of 80 to 100 patients with craniosynostosis will be born every year. Given the restrictions regarding outpatient clinics, admitted surgical time and restricted capacity of the intensive care unit (ICU) at the Craniofacial Center Rotterdam, a bottleneck is already there. At present, this results in rather long waiting lists not only for craniofacial intervention but also, for instance, for treatment of hand malformations. In light of these perspectives, ICU capacity and the number of trainees in craniofacial surgery should be expanded, just like the number of craniofacial centers. It is however of

the essence that quality of care meets the required standards, especially for the complex disorder craniosynostosis.

## References

- American Cleft Palate and Craniofacial Society.** Parameters for evaluation and treatment of patients with cleft lip/palate or other craniofacial anomalies. *Cleft Palate-Craniofac. J.* 30: suppl.1, 1993.
- Chow RL, Diez Roux G, Roghani M, Palmer MA, Rifkin DB, Moscatelli DA, Lang RA.** FGF suppresses apoptosis and induces differentiation of fibre cells in the mouse lense. *Development* 121: 4383-4393, 1995.
- De Moerlooze L, Dickson C.** Skeletal disorders associated with fibroblast growth factor receptor mutations. *Curr. Opin. Genet. Dev.* 7: 378-385, 1997.
- De Pollack C, Renier D, Hott M, Marie PJ.** Increased bone formation and osteoblastic cell phenotype in premature cranial suture ossification (craniosynostosis). *J. Bone Miner. Res.* 11: 401-407, 1996.
- Dechant JJ, Mooney MP, Cooper GM, Smith TD, Burrows AM, Losken HW, Mathijssen IMJ, Siegel MI.** Positional changes in the frontoparietal ossification centers in perinatal craniosynostotic rabbits. *Abstract. Am. J. Phys. Anthropol. Supp.* 26: 75, 1998.
- Dechant JJ, Mooney MP, Cooper GM, Smith TD, Burrows AM, Losken HW, Mathijssen IMJ, Siegel MI.** Positional changes of the frontoparietal ossification centers in perinatal craniosynostotic rabbits. *J. Craniofac. Gen. Dev. Biol.* 19: 64-74, 1999.
- Ferguson CM, Miclau T, Hu D, Alpern E, Helms JA.** Common molecular pathways in skeletal morphogenesis and repair. *Ann. N. Y. Acad. Sci.* 857: 33-42, 1998.
- Fragale A, Tartaglia M, Bernardini S, Di Stasi AMM, Di Rocco C, Velardi F, Teti A, Battaglia PA, Migliaccio S.** Decreased proliferation and altered differentiation in osteoblasts from genetically and clinically distinct craniosynostotic disorders. *Am. J. Path.* 154: 1465-1477, 1999

- Iseki S, Wilkie AOM, Heath JK, Ishimaru T, Eto K, Morriss-Kay GM.** FGFR2 and osteopontin domains in the developing skull vault are mutually exclusive and can be altered by locally applied FGF2. *Development* 124: 3375-3384, 1997.
- Iseki S, Wilkie AOM, Morriss-Kay GM.** FGFR1 and FGFR2 have distinct differentiation- and proliferation-related roles in the developing mouse skull vault. *Development* 126: 5611-5620, 1999.
- Jung M, Kern FG, Jorgensen TJ, McLeskey SW, Blair OC, Dritschilo A.** Fibroblast growth factor-4 enhanced G2 arrest and cell survival following ionizing radiation. *Cancer Res.* 54: 5194-5197, 1994.
- Kim HJ, Rice DPC, Kettunen PJ, Thesleff I.** FGF-, BMP- and Shh-mediated signalling pathways in the regulation of cranial suture morphogenesis and calvarial bone development. *Development* 125: 1241-1251, 1998.
- Lajeunie E, Le Merrer M, Marchac D, Renier D.** Syndromal and nonsyndromal primary trigonocephaly: Analysis of a series of 237 patients. *Am. J. Med. Genet.* 75: 211-215, 1998.
- Landry P, Sadasivan K, Marino A, Albright J.** Apoptosis is coordinately regulated with osteoblast formation during bone healing. *Tissue & Cell* 29: 413-419, 1997.
- Lemonnier J, Delannoy Ph, Hott M, Lomri A, Modrowski D, Marei PJ.** The Ser252Trp fibroblast growth factor receptor-2 (FGFR2) mutation induces PKC-independent down-regulation of FGFR-2 associated with premature calvaria osteoblast differentiation. *Exp. Cell Res.* 256: 158-167, 2000.
- Lomri A, Lemonnier J, Hott M, De Parseval N, Lajeunie E, Munnich A, Renier D, Marie PJ.** Increased calvaria cell differentiation and bone matrix formation induced by fibroblast growth factor receptor 2 mutations in Apert syndrome. *J. Clin. Invest.* 101: 1310-1317, 1998.
- Macias D, Gañan Y, Ros MA, Hurle JM.** In vivo inhibition of programmed cell death by local administration of FGF-2 and FGF-4 in the interdigital areas of the embryonic leg bud. *Anat. Embryol.* 193: 533-541, 1996.
- Mathijssen IMJ, Bourez RLJH, Vaandrager JM, Vermeij-Keers Chr, Hovius SER.** The pathoembryogenesis of craniosynostosis. Abstract. *Eur. J. Morphol.* 35: 368, 1997a.

- Mathijssen IMJ, Vaandrager JM, Vermeij-Keers Chr.** The pathoembryogenesis of craniosynostosis: Bone centre positioning in isolated craniosynostosis, Apert, Crouzon, Saethre-Chotzen, and Pfeiffer syndromes. In: Transactions of the 8th International Congress on Cleft Palate and Related Craniofacial Anomalies. Lee ST (Ed.). Singapore. Uitgever, p. 336-338, 1997b.
- Mathijssen IMJ, Vermeij-Keers Chr, Vaandrager JM.** The role of apoptotic cell death during normal sutural embryogenesis in mice; inhibition through FGF4 application results in synostosis. In: Proceedings of the Seventh International Congress of the International Society of Craniofacial Surgery. Whitaker LA (Ed.). Bologna. Monduzzi Editore. p. 7-8, 1999a
- Mathijssen IMJ, Vermeij-Keers Chr, Hovius SER, Vaandrager JM.** The role of programmed cell death in the pathogenesis of craniosynostosis. Abstract. Eur. J. Plast. Surg. 22: 344, 1999b.
- Mehrrara BJ, Mackool RJ, McCarthy JG, Gittes GK, Longaker MT.** Immunolocalization of basic fibroblast growth factor and fibroblast growth factor receptor-1 and receptor-2 in rat cranial sutures. Plast. Reconstr. Surg. 102: 1805-1817, 1998.
- Mooney MP, Dechant JJ, Cooper GM, Smith TD, Burrows AM, Losken HW, Mathijssen IMJ, Siegel MI.** Frontoparietal bone ossification center location in craniosynostotic rabbits. Abstract. Am. J. Dental Res.: 77: 185, 1998.
- Park EA, Powers GF.** Acrocephaly and scaphocephaly with symmetrically distributed malformations of the extremities. Am. J. Dis. Childr. 20: 234-315, 1920.
- Park WJ, Bellus GA, Jabs EW.** Mutations in fibroblast growth factor receptors: Phenotypic consequences during eukaryotic development. Am. J. Hum. Genet. 57: 748-754, 1995.
- Renier D, El Ghouzzi V, Bonaventure J, Le Merrer M, Lajeunie E.** Fibroblast growth factor receptor 3 mutation in nonsyndromic coronal synostosis: Clinical spectrum, prevalence, and surgical outcome. J. Neurosurg. 92: 631-636, 2000.
- Rice D, Kim H, Thesleff I.** Apoptosis in murine calvarial bone and suture development. Eur. J. Oral Sci. 107: 265-275, 1999.
- Stelnicki EJ, Vanderwall K, Harrison MR, Longaker MT, Kaban LB, Hoffman WY.** The in utero correction of unilateral coronal craniosynostosis. Plast. Reconstr. Surg. 101: 287-296, 1998b.

**Vaandrager JM, Mathijssen IMJ, Vermeij-Keers Chr.**  
Embryopathogenesis of craniosynostosis: A concept of bone center malpositioning. In: Proceedings of the Sixth International Congress of the International Society of Craniofacial Surgery. Bologna. Monduzzi Editore, p. 91-92, 1995.



## V. SUMMARY

Because of the insufficiency of the traditional classification system for craniosynostosis syndromes (chapter I.1) an attempt was made to develop a new classification based on, amongst others, morphologic analysis of the calvaria and, later on, the genetic background of craniosynostosis. The morphologic studies of normal human fetuses describe the macroscopic development of the frontal and parietal bones with the coronal, metopic and sagittal sutures arising in between (chapters II.1 and II.2). The tubers mark the locus at which the frontal and parietal bones started to ossify, i.e. the frontal and parietal bone centers. Growth of the bones spreads in a concentric manner from the bone centers on, which can be seen as a radiating pattern of the bones. Each suture is found to develop at a highly consistent period during the fetal period of embryogenesis, in a characteristic pattern. At 16 weeks of gestation the first onset of the coronal suture can be seen, situated exactly in line with the frontal and parietal bone centers. It is at this locus that the frontal and parietal bones get in close contact first. Coronal suture development spreads from here on in both cranial and caudal direction. The metopic suture is formed from 15 weeks of gestation on and the sagittal suture development starts at 18 weeks. Observations done on dry fetal skulls and patients' skulls during surgery, or on their CT scans revealed typical displacement of the frontal and/or parietal bone centers for affected coronal, metopic or sagittal sutures. The associated bone centers were located just next to the synostotic suture and the radiating pattern of the bones was

disrupted. The altered positions of the bone centers point out the developmental stage at which the synostosis was initiated. The distance between the two bone centers correlates into the developmental stage at which the bone centers are physiologically positioned from one another and further growth between the bone centers was arrested due to synostosis of the suture. For the coronal suture this period was determined at about 16 weeks of gestation, the time at which the first onset of the suture arises. These results can be translated to the appropriate timing for prenatal screening for craniosynostosis through ultrasound. Although the findings of these morphological studies did result in clinically relevant findings, no new classification for craniosynostosis came from it.

The genetic background of craniosynostosis appeared to be a better foundation for such a classification. This requires the mapping of phenotypic variations associated with each specific mutation. In a pilot study we analyzed this relation for all our patients with craniosynostosis for whom the mutation was known. For most mutations the number was too limited to allow meaningful analysis. We reported the clinical findings in a patient with the Ser351Cys mutation in FGFR2 in view of the very severe phenotype (chapter IV.1). This phenotype is very similar to that of other individually described patients, indicating a strong relationship between genotype and phenotype for the Ser351Cys mutation. Furthermore, the FGFR3 mutation Pro250Arg was highlighted because of its high incidence and the detection of additional findings in its phenotype within our population (chapter IV.2). At the present, a clinically fulfilling



classification based on genetics can still not be developed. This is caused by a. the fact that in only half of the patients with a craniosynostosis syndrome a genetic mutation is traced, b. the number of patients for each individual mutation is very low, and c. the inconsistent interactions between genotype and phenotype for most mutations.

The discovery of genes involved in craniosynostosis gave a new impulse to the research on its pathogenesis. Their expression and function during normal suture development are largely unknown, making it even more difficult to understand the mechanism through which they induce craniosynostosis. For this reason, the first experimental study concerned normal development of the coronal suture in mice (chapter III.1). This study focused on the occurrence of programmed cell death, i.e., apoptosis, since this process is known to be essential during embryogenesis and is involved in the pathogenesis of numerous congenital malformations. Apoptosis during coronal suture development was shown to take place from a specific stage on, 16 days post conception, and at a restricted site, the osteogenic fronts of the frontal and parietal bones where these bones are in close vicinity. To study the biological processes resulting in premature suture ossification, a mouse model was developed in which the craniosynostosis associated fibroblast growth factor receptor (FGFR) 2 gene mutation was mimicked (chapter III.2). Exposing the coronal suture of a mouse embryo to an ectopic dose of fibroblast growth factor (FGF) 2 or 4 through ex utero surgery achieved this. Results showed that bone precursor cells within the suture underwent bone

differentiation and apoptosis prematurely with enhanced mineralization of the osteoid. An attempt is made to translate the results of these studies to the human situation. It appears that the mutated receptor forces the expressing cells within the developing suture to undergo bone differentiation prematurely, at the expense of proliferation. As a result, ossification is enhanced while growth within the suture is restricted. Circumstantial evidence on the involvement of apoptosis in bone differentiation and mineralization is given by the associated increase of apoptotic cells within the treated murine suture. Thus, the genetic mutations in craniosynostosis cause a shift in the balance between proliferation and differentiation – including apoptosis - in the suture towards the latter. Given the similar morphological aspects of the calvaria in isolated and syndromic craniosynostosis, a comparable disturbance in developmental biology of the suture might underlie these congenital malformations.

This study has dealt with aspects of classification, morphology, genetics, and pathogenesis of craniosynostosis. Although relevant findings resulted of both clinical as well as fundamental character, numerous unsolved features remain for which recommendations are given for future research (chapter V).

## VI. SAMENVATTING

Aangezien het klassieke classificatie systeem voor craniosynostosis syndromen tekortschiet (hoofdstuk I.1) werd gepoogd een nieuwe classificatie op te zetten, gebaseerd op onder meer morfologische analyse van de schedel en later op de genetische achtergrond van craniosynostosis. De morfologische studies van normale humane foetussen beschrijven de macroscopische ontwikkeling van de frontale en parietale beenderen waartussen zich de corona naad, de metopica naad en de sagittaal naad vormen (hoofdstukken II.1 en II.2). De plaats waar de eerste ossificatie van de frontale en parietale botten optreedt, de zogenaamde frontale en parietale botcentra of botkernen, wordt gemarkeerd door de tubers. Vanuit de botcentra verspreidt de ossificatie zich in een concentrische manier, waardoor een radiaal patroon in de botten ontstaat. Elke sutuur ontwikkelt zich binnen een zeer constante periode en in een karakteristiek patroon. De eerste aanzet van de corona sutuur is zichtbaar bij een gestatieduur van 16 weken, ter plaatse van een denkbeeldige lijn welke de frontale en parietale botkernen verbindt. Op deze plaats naderen de frontale en parietale botten elkaar voor het eerst. De ontwikkeling van de corona naad verloopt vervolgens van hieruit naar zowel craniaal als caudaal. De aanleg van de metopica naad start bij 15 weken gestatie, terwijl de sagittaal naad begint bij 18 weken.

Aan het schedeldak van droge foetale schedels en van patiënten tijdens operatie of op de schedel-CT scan, kan een typische verplaatsing van de frontale en/of parietale botcentra worden gezien in

geval van aangedane corona, metopica of sagittaal naden. De betrokken botcentra zijn direct naast de synostotische suturen gepositioneerd en het radiaire patroon van de botten is verstoord. De veranderde positie van de botcentra is een indirecte verwijzing naar het ontwikkelingsstadium tijdens welke de synostosis is ontstaan. De afstand tussen de twee botcentra correleert met het ontwikkelingsstadium waarin de botcentra fysiologisch op deze afstand van elkaar verwijderd liggen. Verdere groei tussen de botcentra wordt verhinderd door synostosis van de suturen. Deze periode ligt rond de 16 weken gestatieduur voor de corona naad, het moment waarop de eerste aanzet van deze suturen ontstaat. Bovenstaande resultaten kunnen worden vertaald naar een geschikte tijd om prenatale screening op craniosynostosis middels echografie te verrichten. Alhoewel de resultaten van deze morfologische studies enkele klinisch relevante gegevens hebben opgeleverd hebben zij niet geleid tot een nieuwe classificatie voor craniosynostosis.

De genetische achtergrond van craniosynostosis leek een geschiktere basis voor een dergelijke classificatie. Een vereiste hiervoor is het in kaart brengen van de variaties in fenotype voor elke specifieke mutatie. In een pilot-studie werd een analyse verricht naar deze relatie bij onze patiënten met craniosynostosis van wie de mutatie bekend was. Voor de meeste mutaties was het aantal patiënten te klein om een zinvolle analyse toe te laten. Een patiënte met de Ser351Cys mutatie in FGFR2 werd door ons gepresenteerd gezien het zeer ernstige fenotype. Dit fenotype komt sterk overeen met dat van andere individueel beschreven patiënten, passend bij een zeer sterke relatie

tussen genotype en fenotype voor de Ser351Cys mutatie (hoofdstuk IV.1). De Pro250Arg mutatie in FGFR3 werd nader geanalyseerd gezien de hoge incidentie en het vinden van additionele karakteristieken voor dit syndroom binnen onze populatie (hoofdstuk IV.2). Een klinisch relevante classificatie op basis van de genetica kan op dit moment nog niet ontwikkeld worden. Factoren die hiervoor bepalend zijn, zijn: a. het feit dat bij slechts de helft van de patiënten met een syndromale craniosynostosis een mutatie wordt gevonden, b. het aantal patiënten per individuele mutatie laag is en c. de soms zeer wisselende correlatie tussen genotype en fenotype.

Door het ontdekken van de betrokken genen in craniosynostosis werd een nieuwe impuls gegeven aan het onderzoek naar de pathogenese. De expressie en functie van deze genen tijdens de normale sutuurontwikkeling zijn voor het grootste deel onbekend, waardoor het extra moeilijk is om het mechanisme waarlangs synostosis wordt geïnduceerd te doorgronden. Om deze reden betrof ons eerste experimentele onderzoek een studie naar de normale ontwikkeling van de corona naad in de muis (hoofdstuk III.1). De nadruk lag hierbij op het optreden van geprogrammeerde celdood oftewel apoptosis, aangezien dit proces essentieel is tijdens normale embryogenese en betrokken is in de pathogenese van diverse congenitale afwijkingen. Tijdens de ontwikkeling van de corona naad treedt apoptosis op vanaf een specifieke periode, namelijk 16 dagen post conceptie, en wel over een zeer beperkt gebied, te weten de osteogene regio van de frontale en parietale botten waar deze elkaar naderen.

Om de diverse ontwikkelingsprocessen welke tot synostosis leiden te kunnen bestuderen werd een muis model ontwikkeld waarin de craniosynostosis gerelateerde FGFR2 mutatie werd nagebootst (hoofdstuk III.2). Hiertoe werd de corona naad van een muizenembryo blootgesteld aan een ectopische dosis fibroblast groeifactor (FGF) 2 of 4 door middel van ex utero chirurgie. Aangetoond werd dat botvoorlopercellen binnen de sutuur voortijdig botdifferentiatie of apoptosis ondergingen gecombineerd met versterkte mineralisatie van het osteoid. Gebaseerd op de resultaten van deze en andere studies uit de literatuur wordt een poging gewaagd deze te vertalen naar de humane situatie. Het lijkt dat de cellen in de sutuur welke de gemuteerde receptor tot expressie brengen gedwongen worden tot voortijdige botdifferentiatie, ten koste van proliferatie. Hierdoor is de ossificatie versterkt terwijl de groei binnen de sutuur beperkt is. Apoptosis is mogelijk betrokken bij de botdifferentiatie en mineralisatie aangezien er een gelijktijdige toename van apoptotische cellen binnen de behandelde muizensutuur werd gezien. De genetische mutaties in craniosynostosis lijken een verplaatsing van de balans tussen proliferatie en differentiatie – inclusief apoptosis – binnen de sutuur te veroorzaken in de richting van de laatste. Aangezien de morfologische karakteristieken van een schedeldak in geval van een geïsoleerde en een syndromale craniosynostosis nagenoeg gelijk zijn, lijkt een vergelijkbare verstoring van de ontwikkelingsprocessen van de sutuur aan beide ten grondslag te liggen.

Deze studie omvat aspecten van classificatie, morfologie, genetica en pathogenese van craniosynostosis. Alhoewel relevante bevindingen

resulteerden van zowel klinische als fundamentele aard, blijven er meerdere aspecten onopgelost waarvoor aanbevelingen voor toekomstig onderzoek worden gedaan in hoofdstuk V.





## **PUBLICATIONS USED IN THIS THESIS**

- Mathijssen IMJ, Vaandrager JM, Van Der Meulen JC, Pieterman H, Sonneveld JW, Kreiborg S, Vermeij-Keers Chr. The role of bone centers in the pathogenesis of craniosynostosis: An embryologic approach using CT measurements in isolated craniosynostosis and Apert and Crouzon syndromes. *Plast. Reconstr. Surg.* 98: 17-26, 1996.
- Bourez RLJH, Mathijssen IMJ, Vaandrager JM, Vermeij-Keers Chr. Apoptotic cell death during normal embryogenesis of the coronal suture: Early detection of apoptosis in mice using Annexin V. *J. Craniofac. Surg.* 8: 441-445, 1997.
- Mathijssen IMJ, Vaandrager JM, Hoogeboom AJM, Hesseling-Janssen ALW, Van Den Ouweland AMW. Pfeiffer's syndrome resulting from a S351C mutation in the fibroblast growth factor receptor-2 gene. *J. Craniofac. Surg.* 9: 207-209, 1998.
- Mathijssen IMJ, Van Splunder J, Vermeij-Keers Chr, Pieterman H, De Jong THR, Mooney MP, Vaandrager JM. Tracing craniosynostosis to its developmental stage through bone center displacement. *J. Craniofac. Genet. Dev. Biol.* 19: 57-63, 1999.
- Mathijssen IMJ, Van Leeuwen JPTM, Vermeij-Keers Chr. Simultaneous induction of apoptosis, collagen type I expression and mineralization in the developing coronal suture following FGF4 and FGF2 application. Submitted.
- Mathijssen IMJ, Kwee S, Janssen ALW, Van Den Ouweland AMW, Vaandrager JM, Algra PR, Hoogeboom AJM. Additional

phenotypic features of the FGFR3 Pro250Arg mutation in two Dutch families. Submitted.

## **PUBLICATIONS RELATED TO THIS THESIS**

- Dechant JJ, Mooney MP, Cooper GM, Smith TD, Burrows AM, Losken HW, Mathijssen IMJ, Siegel MI. Positional changes in the frontoparietal ossification centers in perinatal craniosynostotic rabbits. Abstract. Am. J. Phys. Anthropol.: Supp.26: 75, 1998.
- Dechant JJ, Mooney MP, Cooper GM, Smith TD, Burrows AM, Losken HW, Mathijssen IMJ, Siegel MI. Positional changes of the frontoparietal ossification centers in perinatal craniosynostotic rabbits. J. Craniofac. Genet. Dev. Biol. 19: 64-74, 1999.
- Mathijssen IMJ, Bourez RLJH, Vaandrager JM, Vermeij-Keers Chr, Hovius SER. The pathoembryogenesis of craniosynostosis. Abstract. Eur. J. Morphol. 35: 368, 1997.
- Mathijssen IMJ, Vaandrager JM, Vermeij-Keers Chr. The pathoembryogenesis of craniosynostosis: Bone centre positioning in isolated craniosynostosis, Apert, Crouzon, Saethre-Chotzen, and Pfeiffer syndromes. In: Transactions of the 8th International Congress on Cleft Palate and Related Craniofacial Anomalies. Lee ST (Ed.). Singapore. Stamford Press Pte Ltd, p. 336-338, 1997.
- Mathijssen IMJ, Vermeij-Keers Chr, Hovius SER, Vaandrager JM. The role of programmed cell death in the pathogenesis of craniosynostosis. Abstract. Eur. J. Plast. Surg. 22: 344, 1999.
- Mathijssen IMJ, Vermeij-Keers Chr, Vaandrager JM. The role of apoptotic cell death during normal sutural embryogenesis in mice; Inhibition through FGF4 application results in synostosis. In: Proceedings of the Seventh International Congress of the

International Society of Craniofacial Surgery. Whitaker LA (Ed.). Bologna. Monduzzi Editore, p. 7-8, 1999.

Mathijssen IMJ, Van Leeuwen JPTM, Vaandrager JM, Vermeij-Keers Chr. FGF4 or FGF2 injection near the developing coronal suture enhances apoptosis and collagen type I production simultaneously. In: Proceedings of the Eight International Congress of the International Society of Craniofacial Surgery. Chen YR (Ed.). Bologna. Monduzzi Editore, in press.

Mooney MP, Dechant JJ, Cooper GM, Smith TD, Burrows AM, Losken HW, Mathijssen IMJ, Siegel MI. Frontoparietal bone ossification center location in craniosynostotic rabbits. Abstract. J. Dental Res.: 77: 185, 1998.

Vaandrager JM, Mathijssen IMJ, Vermeij-Keers Chr. Embryopathogenesis of craniosynostosis: A concept of bone center malpositioning. In: Proceedings of the Sixth International Congress of the International Society of Craniofacial Surgery. Marchac D (Ed.). Bologna. Monduzzi Editore, p. 91-92, 1995.

## **OTHER PUBLICATIONS**

- Pediatric Plastic Surgery. Course book. Van Adrichem LNA and Mathijssen IMJ (Red.). 8th Esser Course, 1997.
- Vermeij-Keers Chr, Mathijssen IMJ, Vaandrager JM. The pathoembryogenesis of rare facial clefts. In: Transactions of the 8th International Congress on Cleft Palate and Related Craniofacial Anomalies. Lee ST (Ed.). Singapore. Stamford Press Pte Ltd, 102-106, 1997.
- Vaandrager JM, Zonneveld FW, Mathijssen IMJ, Hovius SER. First generation 3D model of a noma patient. A case report: Planning and surgery. Phidias Newsletter 1: 6-7, 1998.
- Orbital/Peri-orbital lesions. Course book. Mathijssen IMJ (Red.). 9th Esser Course/7th Rotterdam International Skull Base Day, 1999, Rotterdam, the Netherlands. ISBN 90-76563-01-2.
- Goossens DPM, Mathijssen IMJ, Van Not HP. Eerste resultaten van borstreconstructie met behulp van het biodimensional system. Abstract. Ned. Tijdschr. Geneesk. 144: 637, 2000.

## CURRICULUM VITAE

Irene Margreet Jacqueline Mathijssen, born April 11th 1969 in Breda.

- 1981-1987: V.W.O., Onze Lieve Vrouwe Lyceum, Breda.
- 1987-1994: Medical school, Erasmus Universiteit Rotterdam
- 16.12.94: Medical degree
- 1.3.95-1.9.96: AGNIO, department of Plastic and  
Reconstructive Surgery, University Hospital  
Rotterdam, head of the department prof.dr. S.E.R.  
Hovius
- 1.9.96-1.3.99: AGIKO research project “Morphology and  
pathoembryogenesis of craniosynostosis  
syndromes: A new classification”, granted by  
NWO
- 1-3-99-present: General surgical training as part of the training  
for plastic surgery, Sint Franciscus Gasthuis  
Rotterdam, head of the department dr. J.C.J.  
Wereldsma and per 1.4.2000 dr. C.H.A. Wittens