



Do magnetic resonance imaging-detected erosions predict progression to rheumatoid arthritis in patients presenting with clinically suspect arthralgia? A longitudinal study

F Wouters , XME Matthijssen , DM Boeters , RM Ten Brinck , AHM Van Der Helm-Van Mil & E Niemantsverdriet

To cite this article: F Wouters , XME Matthijssen , DM Boeters , RM Ten Brinck , AHM Van Der Helm-Van Mil & E Niemantsverdriet (2020): Do magnetic resonance imaging-detected erosions predict progression to rheumatoid arthritis in patients presenting with clinically suspect arthralgia? A longitudinal study, Scandinavian Journal of Rheumatology, DOI: [10.1080/03009742.2020.1737221](https://doi.org/10.1080/03009742.2020.1737221)

To link to this article: <https://doi.org/10.1080/03009742.2020.1737221>



© 2020 The Author(s). Published by Informa UK Limited, trading as Taylor & Francis Group.



[View supplementary material](#)



Published online: 02 Jun 2020.



[Submit your article to this journal](#)



Article views: 127



[View related articles](#)



[View Crossmark data](#)

Do magnetic resonance imaging-detected erosions predict progression to rheumatoid arthritis in patients presenting with clinically suspect arthralgia? A longitudinal study

F Wouters¹, XME Matthijssen¹, DM Boeters¹, RM Ten Brinck¹, AHM Van Der Helm-Van Mil^{1,2*}, E Niemantsverdriet^{1*}

¹Department of Rheumatology, Leiden University Medical Centre, Leiden, The Netherlands

²Department of Rheumatology, Erasmus University Medical Centre, Rotterdam, The Netherlands

Objective: Radiographic joint erosions are a hallmark of rheumatoid arthritis (RA). Magnetic resonance imaging (MRI) is more sensitive than radiographs in detecting erosions. It is unknown whether MRI-detected erosions are predictive for RA development in patients with clinically suspect arthralgia (CSA). Therefore, we investigated the prognostic value of MRI-detected erosions, defined as any MRI erosion, or MRI erosion characteristics that were recently identified as specific for RA in patients with evident arthritis.

Method: Patients presenting with CSA (n = 490) underwent contrast-enhanced 1.5 T MRI of the wrist, metacarpophalangeal (MCP) and metatarsophalangeal (MTP) joints. MRIs were scored according to the Rheumatoid Arthritis Magnetic Resonance Imaging Scoring system (RAMRIS). Presence of any MRI erosion (present in < 5% of symptom-free controls) and RA-specific erosion characteristics as identified previously (grade ≥ 2 erosions, erosions in MTP5, erosions in MTP1 if aged < 40 years) were studied with clinically apparent inflammatory arthritis development as outcome. Analyses were corrected for age and MRI-detected subclinical inflammation.

Results: Erosions were present in 20%. Presence of any MRI erosion was not associated with arthritis development [multivariable analysis hazard ratio (HR) 0.97 (95% confidence interval 0.59–1.59)]. The different RA-specific erosion characteristics were not predictive [grade ≥ 2 HR 1.05 (0.33–3.34), erosions in MTP5 HR 1.08 (0.47–2.48), and MTP1 if aged < 40 years HR 1.11 (0.26–4.70)]. Erosion scores were higher in anti-citrullinated protein antibody (ACPA)-positive than in ACPA-negative patients (median 2.0 vs 1.0, p = 0.002), and related to more subclinical inflammation. Within both subgroups, MRI erosions were not predictive.

Conclusions: MRI-detected erosions in hands and feet were not predictive for inflammatory arthritis development. Therefore, evaluating MRI for erosions in addition to subclinical inflammation does not provide added clinical value in CSA.

Rheumatoid arthritis (RA) is characterized by inflammation of synovial joints and subsequent bone damage. Bone erosions are frequently detectable on radiographs, even in the early disease phase (1). Currently, a lot of effort is being undertaken to diagnose RA very early and imaging is increasingly being used in the prompt identification of RA. Moreover, the focus in research is shifting towards the identification of patients who will progress to RA already in the phase of arthralgia. Magnetic resonance imaging (MRI) is sensitive in detecting subclinical joint inflammation (2), which is an

established predictor for RA development (3). The value of different types of inflammatory features (synovitis, tenosynovitis, and bone marrow oedema) has been investigated; of these, tenosynovitis has been shown to be most predictive for disease progression (3). MRI also provides information on bone erosions. Thus far, it is unknown whether MRI-detected erosions are also predictive for progression to clinically apparent inflammatory arthritis and RA. However, we hypothesize that erosions may reflect previous episodes of early subclinical inflammation and thereby possibly provide additional value for the prediction of inflammatory arthritis and RA development.

The sensitivity of MRI to depict erosions is higher than that of radiographs (4). A recent study revealed that small MRI-detected erosions in hand and foot joints are also present in symptom-free persons from the

*These authors contributed equally to this work.

Fenne Wouters, Department of Rheumatology, Leiden University Medical Centre, PO Box 9600, 2300 RC Leiden, The Netherlands

E-mail: f.wouters@lumc.nl

Accepted 27 February 2020

© 2020 The Author(s). Published by Informa UK Limited, trading as Taylor & Francis Group.

This is an Open Access article distributed under the terms of the Creative Commons Attribution-NonCommercial-NoDerivatives License (<http://creativecommons.org/licenses/by-nc-nd/4.0/>), which permits non-commercial re-use, distribution, and reproduction in any medium, provided the original work is properly cited, and is not altered, transformed, or built upon in any way.

DOI: 10.1080/03009742.2020.1737221

www.scandjrheumatol.se

general population (5), underlining the need to differentiate generally occurring bone erosions from disease-associated bone erosions. A subsequent case-control study compared MRI erosions of early RA patients to MRI erosions of symptom-free volunteers and patients with early arthritides other than RA. This study identified several erosion characteristics with a high specificity for RA, as these almost never occurred in both reference groups: grade ≥ 2 erosions, erosions in metatarsophalangeal joint 5 (MTP5), and erosions in MTP1 in persons aged < 40 years (6).

With the ultimate aim of determining whether the prognostic value of MRI could be improved by evaluating MRI-detected erosions, this study investigated whether MRI-detected erosions are predictive for RA development in patients with clinically suspect arthralgia (CSA) and whether the prognostic accuracy of MRI could be improved by assessing MRI-detected erosions in addition to subclinical inflammation. We evaluated both the presence of any MRI erosion and the presence of MRI erosion characteristics that were recently identified as RA specific. Because it has been shown that erosions occur early in anti-citrullinated protein antibody (ACPA)-positive patients in particular (7–9), the analyses were stratified for ACPA.

Method

Patients

Between April 2012 and October 2018, 613 patients were included in the Leiden CSA cohort. CSA patients had recent-onset (< 1 year) arthralgia in the small joints, which was likely to progress to RA based on the clinical expertise of the rheumatologist. By definition, patients were excluded if arthritis was detected upon physical examination or if a different explanation for the joint pain was more likely. The baseline visit consisted of physical examination, questionnaires, blood sampling, and MRI. Follow-up visits were scheduled at 4, 12, and 24 months. When necessary, for instance in case of an increase in symptoms or when patients experienced joint swelling, additional visits were planned. Follow-up ended when patients developed arthritis, or after 2 years. The cohort has been described in detail previously (10).

All patients gave written informed consent. The study was approved by the local medical ethics committee.

MRI

Within 2 weeks after inclusion, CSA patients underwent contrast-enhanced 1.5 T MRI of wrist, second to fifth metacarpophalangeal (MCP) and first to fifth MTP joints of the more painful side (in case of equally severe symptoms on both sides, the dominant side was scanned). For a detailed scanning protocol, see Supplementary file S1. Erosions, bone marrow oedema, and synovitis were scored

according to the Rheumatoid Arthritis Magnetic Resonance Imaging Scoring system (RAMRIS) (11), and tenosynovitis according to Haavardsholm et al (12). Scoring was performed independently by two trained readers. Interreader and intrareader intraclass correlation coefficients were ≥ 0.91 and ≥ 0.92 , respectively (Supplementary file S2).

MRI erosion characteristics

Mean total erosion scores were studied, calculated by summation of mean erosion scores from both readers from all individual bones.

Next, as MRI erosions can also be present in the general population, scores were dichotomized with MRI erosion data of symptom-free controls as a reference ($n = 193$, as published previously) (5). Then, patients were considered positive for MRI erosions if they had at least one erosion that is uncommon in symptom-free controls, i.e. present in $< 5\%$ of symptom-free controls in the same bone and in the same age category (< 40 , $40\text{--}59$, ≥ 60 years).

Lastly, erosion characteristics recently identified as RA specific were evaluated: presence of grade ≥ 2 erosions, MTP5 erosions, and MTP1 erosions when aged < 40 years.

Outcome

The main outcome was development of inflammatory arthritis, determined by the rheumatologist at physical examination (66 swollen joint count ≥ 1). The secondary outcome was RA development (fulfilment of 1987 or 2010 criteria) (13, 14).

During follow-up (and before the main outcome was reached), treatment with disease-modifying anti-rheumatic drugs (DMARDs) (including steroids) was not allowed. Since April 2015, CSA patients with MRI-detected subclinical inflammation could participate in a randomized double-blind placebo-controlled trial (RCT; TREAT EARLIER), studying the effect of methotrexate in preventing RA development. This RCT is still ongoing; patients enrolled in this trial ($n = 89$) were excluded from the present study because of their 50% chance of DMARD use.

Statistics

Total erosion scores and prevalence of MRI erosions were evaluated with Mann-Whitney U and chi-squared tests. Cox proportional hazards regression was used to investigate predictive value. Multivariable models were adjusted for age and presence of MRI-detected subclinical inflammation (defined as synovitis, tenosynovitis, and/or bone marrow oedema present in $< 5\%$ of symptom-free controls in the same bone and in the same age category). Here, all follow-up data were used. Analyses were stratified for ACPA. After 1 year follow-up, the area under the curve

Table 1. Erosion scores, prevalence, and association with development of inflammatory arthritis in patients with clinically suspect arthralgia.

	No arthritis (n = 407)	Arthritis (n = 83)	Univariable Cox regression	Multivariable Cox regression*
Continuous MRI erosion data				
Total erosion score	Erosion score, median (IQR) 1.0 (0.5–2.5)	1.5 (0.5–3.5)	HR (95% CI) 1.12 (1.01–1.23)	HR (95% CI) 0.97 (0.85–1.10)
Dichotomized MRI erosion data				
Presence of ≥ 1 erosion with symptom-free controls as reference	Prevalence, n (%) 78 (19.2)	22 (26.5)	HR (95% CI) 1.40 (0.86–2.28)	HR (95% CI) 0.97 (0.59–1.59) †
Erosion characteristics previously determined as RA specific				
Grade ≥ 2 erosion	Prevalence, n (%) 7 (1.7)	3 (3.6)	HR (95% CI) 1.84 (0.58–5.84)	HR (95% CI) 1.05 (0.33–3.34)
MTP5 erosion	23 (5.7)	6 (7.2)	1.28 (0.56–2.95)	1.08 (0.47–2.48)
MTP1 erosion if age < 40 years (n = 192)	11 (6.7)	2 (7.4)	1.16 (0.28–4.92)	1.11 (0.26–4.70) †
			p	p
			0.033	0.61
			0.18	0.90
			0.30	0.94
			0.56	0.86
			0.84	0.89

*Adjusted for age and presence of subclinical inflammation.

†Adjusted for presence of subclinical inflammation.

IQR, interquartile range; HR, hazard ratio; CI, confidence interval; RA, rheumatoid arthritis; MTP, metatarsophalangeal joint.

(AUC) and the net reclassification index (NRI; the added value of MRI-detected erosions to subclinical inflammation) were determined.

Three subanalyses were performed. First, subanalyses were performed with the secondary outcome RA development. Secondly, analyses were performed in the subgroup of CSA patients who fulfilled the European League Against Rheumatism (EULAR) definition of arthralgia suspicious for progression to RA (three or more out of seven items present) (15), to study the results in a more homogeneous CSA population. Lastly, analyses were performed in patients included between April 2012 and April 2015, i.e. before the start of the RCT, to investigate whether excluding patients with subclinical inflammation affected the results.

A p-value < 0.05 was considered statistically significant. IBM SPSS Statistics version 23 (IBM Corp., Armonk, NY, USA) was used.

Results

Patients

Of 613 included patients, 123 were excluded (no MRI, participation in RCT) (Supplementary file S3). Baseline characteristics are shown in Supplementary table S1. In total, 83 patients developed inflammatory arthritis after a median follow-up of 14 weeks [interquartile range (IQR) 3–23 weeks]. The median follow-up duration of patients who did not progress to inflammatory arthritis (n = 407) was 103 weeks [IQR 51–113 weeks].

Total erosion scores and arthritis development

The median total erosion score in patients who progressed to inflammatory arthritis was 1.5 versus 1.0 in patients who did not progress. Erosion scores were associated with arthritis development in univariable analysis [hazard ratio (HR) 1.12 (95% confidence interval 1.01–1.23)], but not after adjustments for age and subclinical inflammation [HR 0.97 (0.85–1.10)] (Table 1).

Presence of MRI erosion and arthritis development

Next, only those erosions present in < 5% of the general population in the same bone and age category were considered. These MRI erosions were present in 20% of CSA patients. In 60% of these patients subclinical inflammation was also present, while in 40% there was no subclinical inflammation. The presence of MRI-detected erosions was not associated with arthritis development in univariable analysis [HR 1.40 (0.86–2.28)] or in multivariable analysis adjusted for age and subclinical inflammation [HR 0.97 (0.59–1.59)] (Table 1, Figure 1).

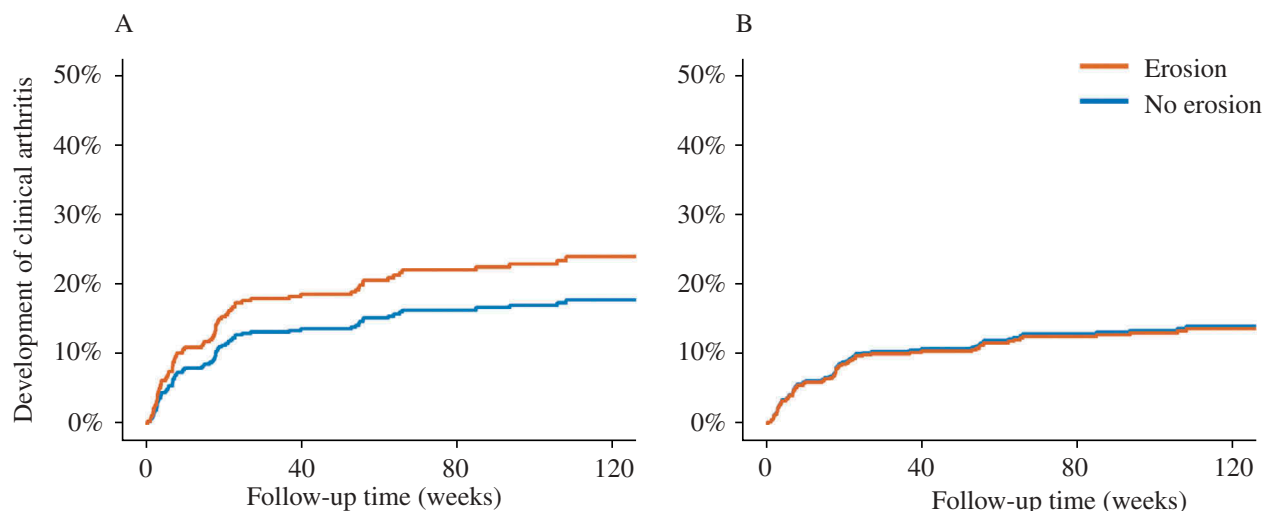


Figure 1. Development of inflammatory arthritis in presence/absence of erosions in (A) univariable and (B) multivariable analyses. Erosions were considered present if the magnetic resonance imaging (MRI) erosion was uncommon in symptom-free controls, i.e. present in < 5% of symptom-free controls at the same location and in the same age category (< 40, 40–59, ≥ 60 years). Multivariable models were adjusted for the presence of subclinical inflammation. The hazard ratios (95% confidence intervals) for univariable and multivariable analyses were 1.40 (0.86–2.28) and 0.97 (0.59–1.59), respectively.

RA-specific erosion characteristics and arthritis development

Subsequently, we studied the predictive value of erosion characteristics previously defined as RA specific. Grade ≥ 2 erosions, MTP5 erosions, and MTP1 erosions in patients aged < 40 years were not associated with progression to inflammatory arthritis [multivariable HR 1.05 (0.33–3.34), 1.08 (0.47–2.48), and 1.11 (0.26–4.70), respectively] (Table 1).

Analyses of ACPA-positive and ACPA-negative patients

As ACPA-positive and ACPA-negative RA are different subsets, analyses were stratified for ACPA. ACPA-positive patients had significantly higher erosion scores than ACPA-negative patients (median 2.0 vs 1.0, $p = 0.002$) (Figure 2A). However, when subclinical inflammation was also considered, this difference was only seen in patients with subclinical inflammation but not in ACPA-positive CSA patients without subclinical inflammation (Figure 2B). Thus presence of ACPA without inflammation did not result in a higher erosion score.

Subsequently, the predictive value of presence of MRI erosions was assessed within each ACPA subset, and neither the presence of any MRI erosion nor RA-specific erosions were predictive for arthritis development in univariable and multivariable analyses (Supplementary tables S2 and S3).

Prognostic accuracy of MRI erosions when added to MRI inflammation

After 1 year follow-up ($n = 434$), the AUC of any MRI erosion to predict inflammatory arthritis development

was 0.54. For comparison, the AUC of MRI-detected subclinical inflammation was 0.73. The AUC of both erosions and subclinical inflammation was also 0.73. To determine whether MRI erosions improved the prognostic accuracy, the NRI was also determined. When erosion data were added to the presence of subclinical inflammation, 35 patients (8.1%) were reclassified, two correctly and 33 incorrectly. This resulted in an NRI of -5.8 , revealing no improved prognostic accuracy. Thus, the prognostic accuracy of MRI-detected subclinical inflammation did not improve, but rather created a high number of false-positive predictions, when MRI-detected erosions were also assessed.

Subanalyses

MRI erosions were not predictive with the outcome RA development ($n = 490$), within CSA patients who fulfilled the EULAR definition ($n = 317$), and in patients included before the start of the RCT ($n = 225$) (Supplementary tables S4–S6).

Discussion

This study investigated whether MRI-detected erosions in CSA patients are predictive for development of inflammatory arthritis or RA. No association was found and MRI-detected erosions did not improve the prognostic accuracy of MRI-detected subclinical inflammation. This implies that evaluating MRI erosions of CSA patients is superfluous if MRI-detected subclinical inflammation is assessed.

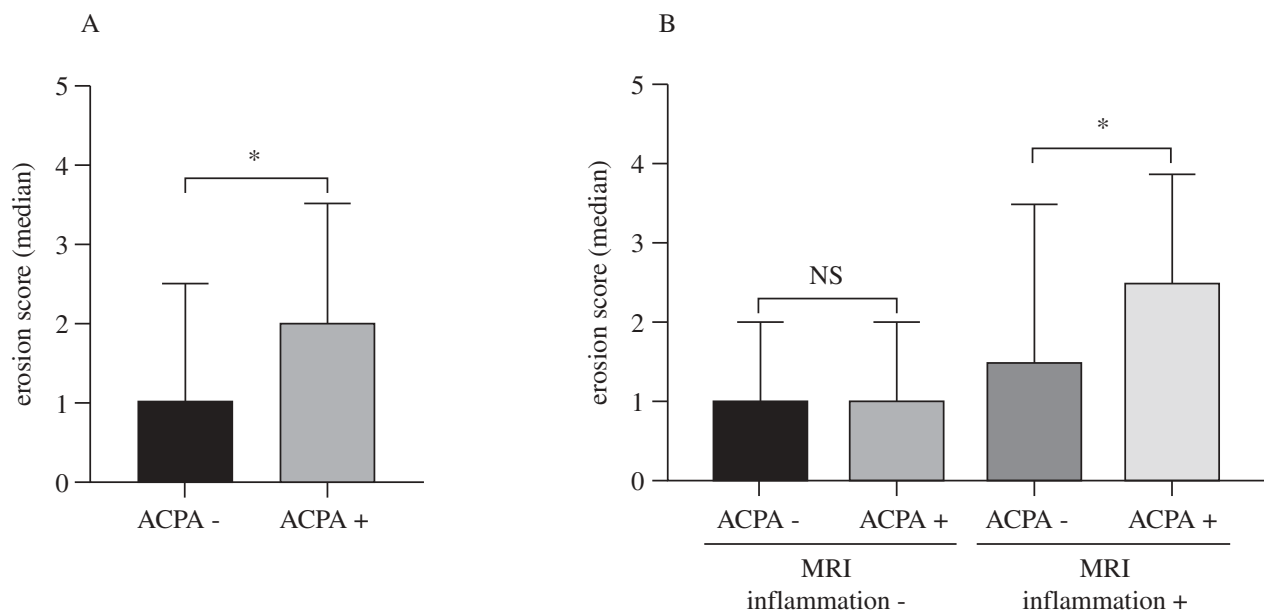


Figure 2. Erosion scores in anti-citrullinated protein antibody (ACPA)-positive and ACPA-negative patients with and without concurrent subclinical inflammation. (A) Total erosion scores in ACPA-positive and ACPA-negative patients; (B) erosion scores stratified for the presence of magnetic resonance imaging (MRI)-detected subclinical inflammation. * $p < 0.05$; NS, not significant.

Until now, the predictive value of MRI-detected erosions in CSA has not been studied longitudinally. A recent longitudinal study in patients presenting with undifferentiated arthritis (UA) showed that also in these patients MRI erosions were not predictive for RA development (16). The frequencies of any MRI erosion or RA-specific erosions found in UA were quite similar as currently observed in CSA. Although we did not determine the frequency of the presence of any MRI erosions during inflammatory arthritis development, the finding of similar prevalences in UA and CSA suggests that the frequency of erosions did not increase over time. This would be in line with results from a previous study showing that the total MRI erosion score did not increase during progression from CSA to RA (17). Most importantly, the data together demonstrate that MRI erosions in CSA and UA are not predictive for progression to the disease stage of RA. This result is different from previous findings on radiographic erosions in early RA, which are highly predictive for further radiographic progression.

Previous studies identified 'RA-specific erosions' by comparing patients with RA with other early arthritides. The present study revealed that RA-specific erosions (which were identified in the phase of clinically apparent arthritis) are infrequent in the CSA phase and not prognostically valuable.

Even though MRI-detected erosions were not associated with RA development, higher erosion scores were present in ACPA-positive compared to ACPA-negative patients, which is similar to our previous finding in the same cohort (7). In our view, these data suggest that the presence of subclinical inflammation

in ACPA-positive arthralgia is mediating the development of erosions. Whether ACPA can directly induce erosions, without an intermediary effect of inflammation, remains questionable and our data could not find support for this notion. Furthermore, this study added novel data to the field by demonstrating that MRI erosions were not associated with progression to RA within ACPA-positive CSA patients or within ACPA-negative CSA patients.

Mouse models have suggested that osteoclast formation occurs early in the preclinical phase and before the development of inflammatory arthritis (18). In the present cohort, of the CSA patients with erosions (20%), 40% had no concomitant subclinical inflammation. This concerned both ACPA-positive and ACPA-negative patients (Figure 2). It can be speculated that erosions in these patients were the result of preceding subclinical inflammation. However, in the absence of subclinical inflammation, RA development was low (3). This suggests that the presence of grade 1 MRI-detected erosions, without subclinical inflammation, is often not a feature of imminent RA. Perhaps additional stimuli needed for progression were lacking.

Since April 2015, CSA patients with MRI-detected subclinical inflammation could participate in an RCT studying methotrexate. Patients who entered this trial were excluded from the present analyses (Supplementary file S3). The patients in the present study who were included after April 2015 less often had subclinical inflammation than patients included before April 2015 (33% vs 51%), demonstrating that some of the patients with subclinical inflammation, a risk factor for arthritis development, had been excluded. This may have

resulted in overestimation or underestimation of the association between erosions and arthritis development. Although the frequency of subclinical inflammation was lower since the start of the RCT, the ratio of erosion presence within strata of patients with or without subclinical inflammation generally remained unchanged. In addition, known risk factors for arthritis development were comparable for patients with subclinical inflammation who did and did not participate in the RCT. Hence, a possible influence on the effect in the total cohort can be eliminated by stratifying for subclinical inflammation; also then MRI erosions were not predictive (Supplementary tables S7 and S8). Furthermore, subanalyses evaluating only patients included before April 2015 revealed similar results. Therefore, we consider it unlikely that exclusion of patients because of the RCT caused false-negative results.

Conclusion

This large longitudinal study showed that MRI-detected erosions in the hands and feet of patients with CSA are not predictive for arthritis development. Therefore, evaluating MRI for erosions in addition to subclinical inflammation does not provide added prognostic value in CSA.

Acknowledgements

This work was supported by the European Research Council (ERC) under the European Union's Horizon 2020 research and innovation programme (starting grant, agreement no. 714312), and the Dutch Arthritis Society.

Disclosure statement

No potential conflict of interest was reported by the authors.

References

1. van der Heijde DM. Joint erosions and patients with early rheumatoid arthritis. *Br J Rheumatol* 1995;34(Suppl 2):74–8.
2. Krabben A, Stomp W, Huizinga TW, van der Heijde D, Bloem JL, Reijnders M, et al. Concordance between inflammation at physical examination and on MRI in patients with early arthritis. *Ann Rheum Dis* 2015;74:506–12.
3. van Steenberg HW, Mangnus L, Reijnders M, Huizinga TWJ, van der Helm-van Mil AHM. Clinical factors, anticitrullinated peptide antibodies and MRI-detected subclinical inflammation in relation to progression from clinically suspect arthralgia to arthritis. *Ann Rheum Dis* 2016;75:1824–30.
4. Ejbjerg BJ, Vestergaard A, Jacobsen S, Thomsen H, Ostergaard M. Conventional radiography requires a MRI-estimated bone volume

loss of 20% to 30% to allow certain detection of bone erosions in rheumatoid arthritis metacarpophalangeal joints. *Arthritis Res Ther* 2006;8:R59.

5. Mangnus L, van Steenberg HW, Reijnders M, van der Helm-van Mil AH. Magnetic resonance imaging-detected features of inflammation and erosions in symptom-free persons from the general population. *Arthritis Rheumatol* 2016;68:2593–602.
6. Boeters DM, Nieuwenhuis WP, van Steenberg HW, Reijnders M, Landewe RBM, van der Helm-van Mil AHM. Are MRI-detected erosions specific for RA? A large explorative cross-sectional study. *Ann Rheum Dis* 2018;77:861–8.
7. Ten Brinck RM, Toes REM, van der Helm-van Mil AHM. Inflammation functions as a key mediator in the link between ACPA and erosion development: an association study in Clinically Suspect Arthralgia. *Arthritis Res Ther* 2018;20:89.
8. Kleyer A, Finzel S, Rech J, Manger B, Krieter M, Faustini F, et al. Bone loss before the clinical onset of rheumatoid arthritis in subjects with anticitrullinated protein antibodies. *Ann Rheum Dis* 2014;73:854–60.
9. Berglin E, Johansson T, Sundin U, Jidell E, Wadell G, Hallmans G, et al. Radiological outcome in rheumatoid arthritis is predicted by presence of antibodies against cyclic citrullinated peptide before and at disease onset, and by IgA-RF at disease onset. *Ann Rheum Dis* 2006;65:453–8.
10. van Steenberg HW, van Nies JAB, Huizinga TWJ, Bloem JL, Reijnders M, van der Helm-van Mil AHM. Characterising arthralgia in the preclinical phase of rheumatoid arthritis using MRI. *Ann Rheum Dis* 2015;74:1225–32.
11. Ostergaard M, Peterfy C, Conaghan P, McQueen F, Bird P, Ejbjerg B, et al. OMERACT rheumatoid arthritis magnetic resonance imaging studies. Core set of MRI acquisitions, joint pathology definitions, and the OMERACT RA-MRI scoring system. *J Rheumatol* 2003;30:1385–6.
12. Haavardsholm EA, Ostergaard M, Ejbjerg BJ, Kvan NP, Kvien TK. Introduction of a novel magnetic resonance imaging tenosynovitis score for rheumatoid arthritis: reliability in a multireader longitudinal study. *Ann Rheum Dis* 2007;66:1216–20.
13. Arnett FC, Edworthy SM, Bloch DA, McShane DJ, Fries JF, Cooper NS, et al. The American Rheumatism Association 1987 revised criteria for the classification of rheumatoid arthritis. *Arthritis Rheum* 1988;31:315–24.
14. Aletaha D, Neogi T, Silman AJ, Funovits J, Felson DT, Bingham CO 3rd, et al. Rheumatoid arthritis classification criteria: an American College of Rheumatology/European League Against Rheumatism collaborative initiative. *Arthritis Rheum* 2010;62:2569–81.
15. van Steenberg HW, Aletaha D, Beart-van de Voorde LJJ, Brouwer E, Codreanu C, Combe B, et al. EULAR definition of arthralgia suspicious for progression to rheumatoid arthritis. *Ann Rheum Dis* 2017;76:491–6.
16. Boeters DM, Boer AC, van der Helm-van Mil AHM. Evaluation of the predictive accuracy of MRI-detected erosions in hand and foot joints in patients with undifferentiated arthritis. *Ann Rheum Dis* 2019;78:144–6.
17. Ten Brinck RM, van Steenberg HW, van der Helm-van Mil AHM. Sequence of joint tissue inflammation during rheumatoid arthritis development. *Arthritis Res Ther* 2018;20:260.
18. Hayer S, Redlich K, Korb A, Hermann S, Smolen J, Schett G. Tenosynovitis and osteoclast formation as the initial preclinical changes in a murine model of inflammatory arthritis. *Arthritis Rheum* 2007;56:79–88.

Supporting Information

Additional Supporting Information may be found in the online version of this article.

Supplementary file S1. MRI scanning and scoring protocol.

Supplementary file S2. Inter- and intrareader correlation.

Supplementary file S3. Patient selection flowchart.

Supplementary table S1. Baseline characteristics of CSA patients.

Supplementary table S2. Erosion scores, prevalence, and association with development of inflammatory arthritis in ACPA-negative patients with CSA.

Supplementary table S3. Erosion scores, prevalence, and association with development of inflammatory arthritis in ACPA-positive patients with CSA.

Supplementary table S4. Erosion scores, prevalence, and association with RA-development (1987 or 2010 criteria) in patients with CSA.

Supplementary table S5. Erosion scores, prevalence, and association with development of inflammatory arthritis in CSA patients fulfilling EULAR definition.

Supplementary table S6. Erosion scores, prevalence, and association with development of inflammatory arthritis in CSA patients included before 2015.

Supplementary table S7. Erosion scores, prevalence, and association with development of inflammatory arthritis in CSA patients without subclinical inflammation.

Supplementary table S8. Erosion scores, prevalence, and association with development of inflammatory arthritis in CSA patients with subclinical inflammation.

Please note that the editors are not responsible for the content or functionality of any supplementary material supplied by the authors. Any queries should be directed to the corresponding author.