

CASE REPORT

Atrial fibrillation: A never ending story?

Eva A. H. Lanthers¹ | Paul Knops¹ | Charles Kik² | Natasja M.S. de Groot¹ ¹Department of Cardiology, Erasmus MC, Rotterdam, The Netherlands²Department of Cardiothoracic Surgery, Erasmus MC, Rotterdam, The Netherlands**Correspondence**

Natasja M.S. de Groot, Department of Cardiology, Erasmus MC, RG-619, Doctor Molewaterplein 40, 3015 GD, Rotterdam, The Netherlands.

Email: n.m.s.degroot@erasmusmc.nl

Funding information

Erasmus Medisch Centrum, Grant/Award Number: Fellowship; CVON-AFFIP, Grant/Award Number: 14728; Stichting Coolsingel, Grant/Award Number: 212; LSH-impulse grant, Grant/Award Number: 40-43100-98-008; Hartstichting, Grant/Award Number: 2012T0046

Abstract

Atrial fibrillation (AF) often recurs after ablative therapy. In our patient, intraoperative epicardial mapping during therapy-resistant AF revealed highly dissociated atrial conduction patterns and that long lines of conduction block throughout the entire atria. Given the extensiveness of the substrate, it is not surprising that ablations were not successful.

Conduction patterns during therapy-resistant atrial fibrillation (AF) are highly dissociated and show long lines of conduction block. As long as the presence and extensiveness of the arrhythmogenic substrate underlying AF remains poorly understood and cannot be evaluated in the individual patient, none of the present available antiarrhythmic treatment modalities will be effective.

KEYWORDS

ablation, atrial fibrillation, electrophatology, epicardial mapping, substrate

1 | INTRODUCTION

Atrial fibrillation recurrences after pulmonary vein isolation (PVI) may not only be caused by reconnection but also by the presence of an arrhythmogenic substrate elsewhere in the atria. In many patients (40%-60%), AF tends to recur, also after multiple initially successful PVIs.¹ Even additional substrate modification consisting of, for example, ablation of complex fractionated electrograms does not cure AF in the vast majority of these patients.²

Intraoperative high-resolution epicardial mapping provides insight into the severity of the arrhythmogenic substrate underlying persistence of AF. In the present case, we applied this technique to the entire atrial epicardial surface of a patient with a history of multiple failed ablations, to comprehend why currently available therapeutic strategies for AF were all prone to fail.

2 | CASE REPORT

We present a male patient with longstanding persistent AF, who was diagnosed with paroxysmal AF at the age of 31. Failed antiarrhythmic drug therapy included amiodarone, sotalol, and metoprolol. For prevention of thrombo-embolic events, he used a vitamin K antagonist.

At age 49, transthoracic echocardiography showed left atrial dilatation (55 × 65 mm) with secondary mitral valve insufficiency and mild left ventricular dilatation (end-diastolic dimension 61 mm). Left ventricular function was normal, and presence of coronary artery disease was ruled out by coronary angiography. The patient was referred to our hospital for mitral valve repair and concomitant surgical PVI (sPVI). A box lesion was created around the ostia of the pulmonary veins at the left atrial posterior wall using

the Epicor Cardiac Ablation System (St Jude/Abbott). With this device, isolation of the pulmonary veins is achieved by the use of high-intensity focused ultrasound. In addition, an mitral isthmus line was created extending from the caudal side of the box lesion to the mitral valve annulus (crossing the coronary sinus), and the left atrial appendage was amputated. Exit pacing was performed after surgical creation of the box lesion.

In the following years, he developed numerous AF recurrences in addition to a typical atrial flutter and multiple atrial tachyarrhythmias (AT), all requiring electrical cardioversion. As a consequence, three endovascular right-sided ablation procedures were performed, including the creation of a linear lesion across the cavo-tricuspid isthmus and two unsuccessful ablations of different right-sided focal ATs. Immediate success after the consecutive endovascular ablation procedures (procedures 2nd-5th) was confirmed by the presence of a bidirectional block and/or noninducibility of AT.

Seven years after the initial sPVI, he was referred for redo sPVI (age 55). As the patient participated in a research project (QUASAR MEC2010-393), an intraoperative, high-resolution epicardial mapping procedure of the right and left atria and Bachmann's Bundle was performed during a persistent AF episode.

A series of wavemaps, constructed during 790 milliseconds (ms) of AF, recorded at the right atrial free wall is shown in Figure 1. This site was selected as it was not targeted by any of the previous ablation procedures and thus represents physiological atrial conduction in this patient, without the presence of potential iatrogenic conduction block, caused by earlier ablation. Activation of atrial tissue was highly dissociated due to multiple epicardial breakthrough waves and lines of conduction block, resulting in 66 fibrillation waves in only 790 ms. Conduction block was omnipresent. In five consecutive wavemaps, the total lengths of all lines of conduction block were 78 mm (wavemap 1), 78 mm (wavemap 2), 48 mm (wavemap 3), 136 mm (wavemap 4), and 90 mm (wavemap 5). This corresponds with respectively 11.3%, 11.3%, 7.0%,

19.8%, and 13.1% of the mapping area. At all other mapping sites in the remainder of the atria, patterns of activation were highly complex and varied from beat to beat. Epicardial breakthrough waves (EBW) were present in all wavemaps. The total amount was 31 and varied from 5 (wavemap 1) to 8 (wavemap 5) EBW per wavemap. This translates to 39 EBW per second at this specific mapping site.

After redo sPVI, electrical isolation was confirmed by the presence of an entrance block. One day after surgery, AF recurred. In addition, the patient developed bradycardia (day 3) for which a permanent DDD pacemaker was implanted. Three years later, the patient still had ongoing AF episodes and a His bundle ablation was performed to control the ventricular heart rate.

3 | DISCUSSION

The present case emphasizes the major importance of knowledge of the presence and extensiveness of the arrhythmogenic substrate underlying AF in the individual patient. In our patient, the highly complex atrial activation patterns and numerous EBW are indicative of substrate mediated AF. It is therefore to be expected that PVI will not be effective in eliminating AF.

Prior studies showed that EBW are key elements of the arrhythmogenic substrate underlying AF³ and result most likely from endo-epicardial dissociation.⁴ Substrate modification, such as ablation of complex fractionated electrograms or ganglionic plexi, or deployment of linear lesions for AF was not executed. However, these therapies are focusing on the substrate as more or less localized pathology, whereas in this case, electropathology is present diffusely throughout the entire left and right atria and Bachmann's bundle. Hence, even additional substrate modifying techniques would not have cured AF in this patient given the extensiveness of the arrhythmogenic substrate and the asynchronicity of activation patterns. Given the ever-growing population of patients with therapy-resistant AF, further research into the

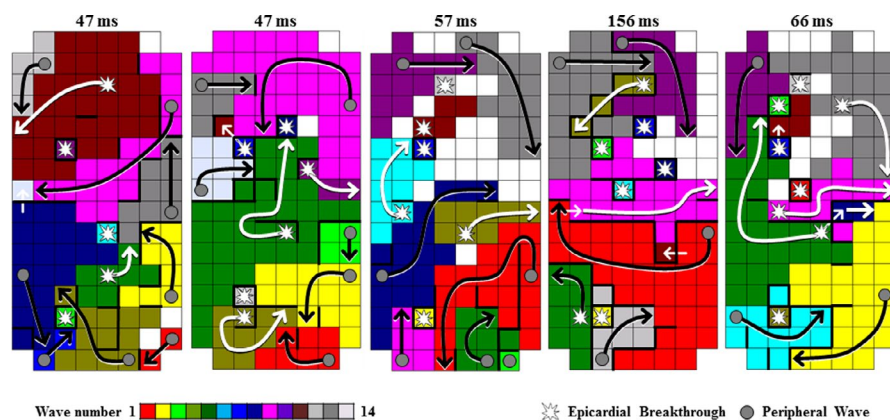


FIGURE 1 Patterns of activation. Wavemaps illustrating the high complexity of patterns of atrial activation during atrial fibrillation. Different colors indicate the consecutive fibrillation waves. Arrows indicate the main trajectory of each fibrillation wave. Black arrow: peripheral fibrillation wave. White arrow: epicardial breakthrough (“focal”) wave

arrhythmogenic substrate associated with AF persistence and ultimately development of new (patient tailored) therapeutic strategies are of utmost importance.

4 | CONCLUSION

The current case illustrates that as long as the presence and extensiveness of the arrhythmogenic substrate underlying AF remains poorly understood and cannot be evaluated in the individual patient, none of the present available antiarrhythmic treatment modalities will be effective.

ACKNOWLEDGMENT

Prof. dr NMS de Groot is supported by grants from the Erasmus Medical Center fellowship, Dutch Heart Foundation [2012T0046], LSH-Impulse grant [40-43100-98-008], CoolSingel Foundation [No.212], and CVON-AFFIP [No. 14728].

CONFLICT OF INTEREST

None declared.

AUTHOR CONTRIBUTIONS

Lanters EAH: performed data acquisition and data analysis and involved in writing manuscript and final approval of the article. Knops P: contributed in data analysis, writing manuscript, manuscript revision, and final approval of the article.

Kik C: contributed in data acquisition, concept development, manuscript revision, and final approval of the article. de Groot NMS: contributed in concept development, data analysis, manuscript revision, and final approval of the article.

ORCID

Natasja M.S. Groot  <https://orcid.org/0000-0002-0259-6691>

REFERENCES

1. Ganesan AN, Shipp NJ, Brooks AG, et al. Long-term outcomes of catheter ablation of atrial fibrillation: a systematic review and meta-analysis. *J Am Heart Assoc.* 2013;2:e004549.
2. Nademanee K, McKenzie J, Kosar E, et al. A new approach for catheter ablation of atrial fibrillation: mapping of the electrophysiologic substrate. *J Am Coll Cardiol.* 2004;43:2044-2053.
3. de Groot NM, Houben RP, Smeets JL, et al. Electropathological substrate of longstanding persistent atrial fibrillation in patients with structural heart disease: epicardial breakthrough. *Circulation.* 2010;122:1674-1682.
4. de Groot N, van der Does L, et al. Direct proof of endo-epicardial asynchrony of the atrial wall during atrial fibrillation in humans. *Circ Arrhythm Electrophysiol.* 2016;9(5):pii: e003648.

How to cite this article: Lanters EAH, Knops P, Kik C, de Groot NMS. Atrial fibrillation: A never ending story? *Clin Case Rep.* 2019;00:1–3. <https://doi.org/10.1002/ccr3.2415>