

# Novel Leptin Receptor Mutations Identified in Two Girls with Severe Obesity Are Associated with Increased Bone Mineral Density

Sabine E. Hannema<sup>a</sup> Jan M. Wit<sup>a</sup> Mieke E.C.A.M. Houdijk<sup>c</sup>  
Arie van Haeringen<sup>b,c</sup> Elsa C. Bik<sup>b</sup> Annemieke J.M.H. Verkerk<sup>d</sup>  
André G. Uitterlinden<sup>d</sup> Sarina G. Kant<sup>b</sup> Wilma Oostdijk<sup>a</sup> Egbert Bakker<sup>b</sup>  
Henriette A. Delemarre-van de Waal<sup>a</sup> Monique Losekoot<sup>b</sup>

<sup>a</sup>Department of Paediatrics, Willem Alexander Children's Hospital and <sup>b</sup>Department of Clinical Genetics, Leiden University Medical Center, Leiden, <sup>c</sup>Department of Paediatrics, Juliana Children's Hospital, Haga Hospital, The Hague, and <sup>d</sup>Department of Internal Medicine, Erasmus Medical Centre, Rotterdam, The Netherlands

## Established Facts

- Leptin receptor (LEPR) deficiency causes hyperphagia and severe early-onset obesity.
- Other features such as hypogonadotropic hypogonadism, reduced growth hormone secretion, hypothalamic hypothyroidism and altered immune function are more variable.
- Leptin has been implicated as an important factor in bone metabolism.

## Novel Insights

- Two girls with LEPR deficiency have a high bone mineral density, as assessed by dual-energy X-ray absorptiometry, which may be directly or indirectly related to leptin resistance.
- Bone age is remarkably advanced in the prepubertal girl, suggesting leptin resistance might also favor bone maturation.

## Key Words

Leptin · Leptin receptor · Obesity · Hypogonadotropic hypogonadism · Bone mineral density

## Abstract

**Background:** Recessive mutations in the leptin receptor (*LEPR*) are a rare cause of hyperphagia and severe early-onset obesity. To date, the phenotype has only been described in 25 obese children, some of whom also had altered

immune function, hypogonadotropic hypogonadism, reduced growth hormone secretion, hypothalamic hypothyroidism or reduced adult height. We provide a detailed description of the phenotype of 2 affected girls to add to this knowledge. **Methods:** Whole-exome sequencing and targeted sequencing were used to detect the *LEPR* mutations. RNA analysis was performed to assess the effect of splice-site mu-

H.A.D.-v.d.W. deceased on February 13, 2014.

tations. **Results:** In 2 unrelated girls with severe obesity, three novel *LEPR* mutations were detected. Longitudinal growth data show normal childhood growth, and in the older girl, a normal adult height despite hypogonadotropic hypogonadism and the lack of an obvious pubertal growth spurt. Bone age is remarkably advanced in the younger (prepubertal) girl, and bone mineral density (BMD) is high in both girls, which might be directly or indirectly related to leptin resistance. **Conclusion:** The spectrum of clinical features of *LEPR* deficiency may be expanded with increased BMD. Future observations in *LEPR*-deficient subjects should help further unravel the role of leptin in human bone biology.

© 2016 The Author(s)  
Published by S. Karger AG, Basel

## Introduction

Leptin is a key regulator of energy homeostasis. It is produced by adipocytes and signals information on the amount of energy stored as body fat to the brain. It binds to the leptin receptor (*LEPR*), which is expressed in the hypothalamus, where it influences satiety and plays an important role in the regulation of the hypothalamus-pituitary-gonadal axis. *LEPR* is also expressed in other brain regions such as the cortex, midbrain and hindbrain, where its role is not completely clear yet [1].

Recessive mutations of *LEPR* are a rare cause of hyperphagia and severe early-onset obesity [2, 3]. To date, the phenotype has only been described in 25 children [2–10]. All were severely obese; in some subjects, additional features were reported, e.g. (clinical features of) altered immune function/T-cell numbers [3, 4, 7, 10], hypogonadotropic hypogonadism [3, 6, 8], reduced growth hormone (GH) secretion [2, 8], hypothalamic hypothyroidism [2, 8], and reduced adult height [3]. No data are available on bone health in these patients, although *LEPR* is known to be involved in bone metabolism [11, 12].

Here, we describe the clinical and laboratory features of 2 girls with *LEPR* deficiency to further delineate the phenotype in childhood and adolescence. We show normal childhood growth, normal adult height in the oldest girl, and high bone mineral density (BMD) in both girls.

## Case Reports

### Patient 1

The girl was born at full term with a birth weight of 3,560 g. She suffered from pyelonephritis at the age of 4 months but experienced no other serious infections. She showed normal psychomotor development. From infancy, her appetite seemed insatiable and

she gained weight quickly (fig. 1a–d). Despite a restricted diet and exercise program, she remained severely obese. Weight at the age of 9.0 years was 75.7 kg (+3.4 SDS weight-for-height), BMI 33.1 (+4.6 SDS), with a lean body mass of 40.5 kg, a fat mass of 32.5 kg and a fat percentage of 43.7% measured by dual-energy X-ray absorptiometry with the Hologic Discovery A system (Hologic Inc., Waltham, Mass., USA). Growth accelerated between the age of 1 and 4 years, followed by stable growth along +2.3 SDS at the upper border of the target height (TH) range (+0.8 SDS  $\pm$  1.6) but close to maternal height SDS (185.2 cm, +2.4 SDS). Pubic hair first appeared at the age of 8.5 years; however, breast development had not started by the age of 9 years.

The family is of Dutch origin, with all grandparents being Dutch. The patient's father is obese (height 181 cm, weight 123 kg, BMI 37.5 at the age of 49 years) but had normal weight as a child. Her mother (height 186 cm, weight 76 kg, BMI 22.0 at the age of 38 years), sister (height 152 cm, weight 40 kg, BMI -0.1 SDS at the age of 12 years) and brother (height 122 cm, weight 25 kg, BMI +1.2 SDS at the age of 6.5 years) are not overweight.

Laboratory investigations at the age of 9.5 years showed a serum leptin level of 67.2  $\mu$ g/l, which is above the reference range based on individuals with a normal BMI (3.7–11.1  $\mu$ g/l) but within the range found in obese children (52.5  $\pm$  20.2  $\mu$ g/l in 151 children at the age of 12.3  $\pm$  2.4 years and with a BMI z-score +2.7) [13]. Thyroid function, plasma insulin-like growth factor 1 (IGF1; +1.1 SDS), fasting glucose, liver enzymes, total and LDL cholesterol were normal, and serum LH, estradiol, testosterone, FSH and androstenedione were consistent with prepubertal status. Fasting insulin was mildly elevated (23 mU/l), triglycerides were high (1.54 mmol/l, >95th centile) and HDL cholesterol was low (0.79 mmol/l, <5th centile for age).

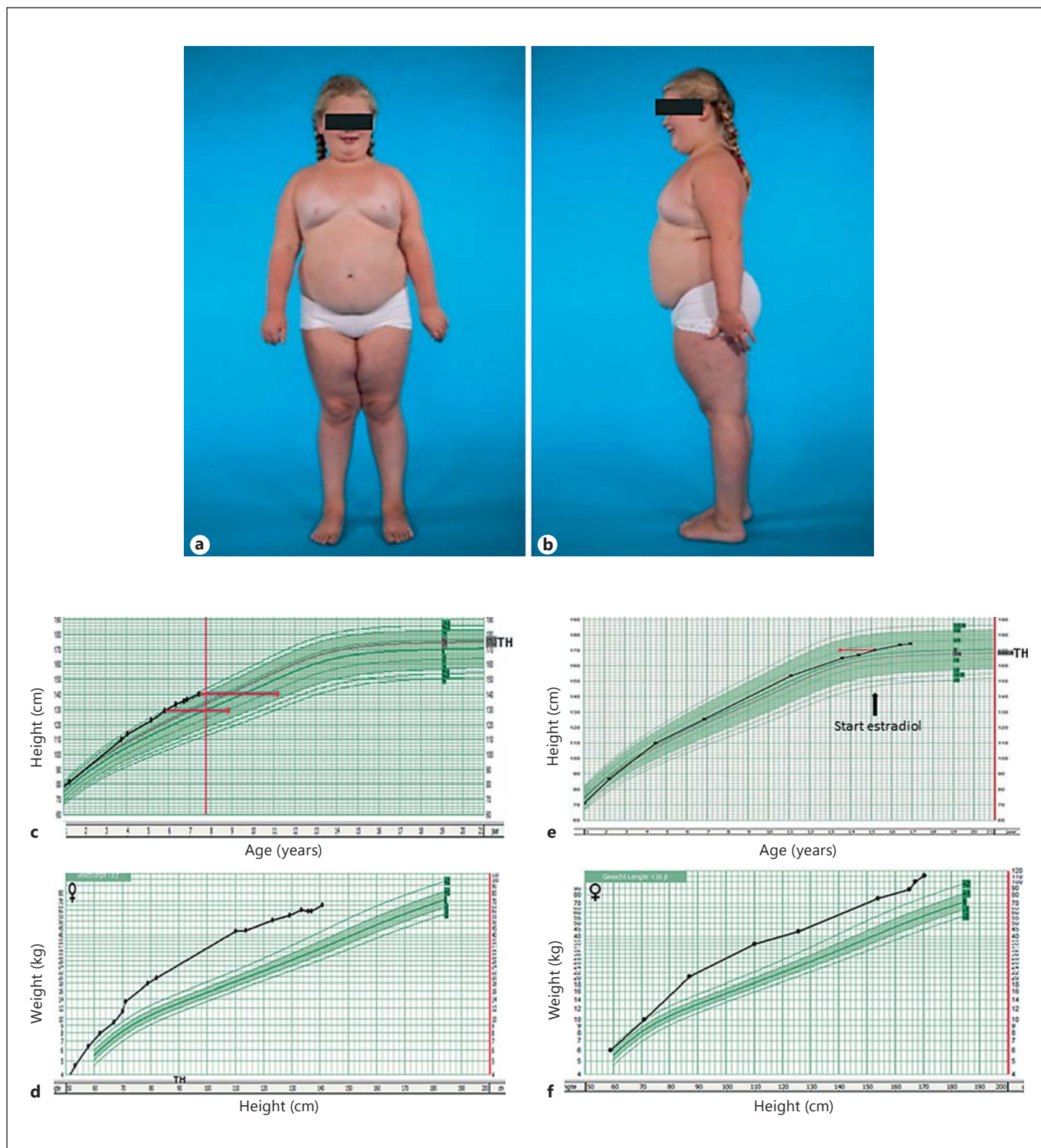
Bone age (BA) according to Greulich and Pyle [14], however, was remarkably advanced [12 years at a calendar age (CA) of 8.6 years], and dual-energy X-ray absorptiometry showed BMD z-scores of +2.7, +3.1 and +3.4 at the lumbar spine (LS), neck area of the left hip and of the right hip, respectively (reference data for BMD are from NHANES). LS bone mineral apparent density (BMAD) z-scores were +1.9 at the age of 8.6 years and +2.3 at the age of 6.7 years, calculated as described by Ward et al. [15].

### Patient 2

The girl was born at term with a birth weight of 3,600 g. Her development was normal, although walking was somewhat delayed. Parents reported a normal appetite and food intake throughout childhood. However, her weight increased dramatically after the age of 1 year, and various diets and exercise programs had no effect. She had no health complaints and grew along her TH SDS (fig. 1e, f). Breast development started around the age of 11 years, but menarche had not yet occurred at the age of 15.2 years (maternal menarcheal age was 14 years). Height was 170.3 cm (+0.5 SDS, close to the TH of 168.4 cm), weight was 110.3 kg, BMI was 38 (+3.8 SDS), and Tanner stage was B5P5A3. Pubic hair was Tanner 5, but remarkably sparse.

The family is of Dutch origin, with all grandparents being Dutch. Her father is overweight (height 180 cm, weight 87 kg, BMI 26.9). Her mother (height 168 cm, weight 57 kg, BMI 20.2) and sister (height 136 cm, weight 32 kg, BMI +0.8 SDS at the age of 9 years) are not overweight.

Fasting glucose was normal with elevated insulin (36.7 mU/l), and an oral glucose tolerance test revealed impaired glucose toler-



**Fig. 1.** **a, b** Photographs of patient 1 at the age of 6 years and 8 months, showing severe obesity but no dysmorphic features. **c–f** Growth charts. **c** Height for age of patient 1, showing early growth acceleration followed by steady growth at the upper border of the TH range. The shaded area represents  $-2$  to  $+2$  SDS. TH is indicated by ‘TH’ on the right hand side of the graph. Note the ad-

vanced BA, which is indicated by a dot connected by a horizontal line to the height data point. **d** Weight for height of patient 1, showing early-onset obesity. **e** Height for age of patient 2, showing normal growth but no pubertal growth spurt. **f** Weight for height of patient 2.

ance (2 h glucose 7.8 mmol/l). Serum leptin was 79.4 µg/l, which is above the reference range based on individuals with a normal BMI (3.7–11.1 µg/l) but comparable to levels found in severely obese individuals with normal *LEPR* [3]. Thyroid function, IGF1 (+0.5 SDS), androstenedione and cortisol were normal. DHEA-S was low (0.89 µmol/l, normal 1–12). Baseline gonadotropins (LH 0.3 mU/l, FSH 1.1 mU/l) and estradiol (37 pmol/l) were low, as well as the responses to a gonadotropin-releasing hormone (GnRH) test (LH and FSH 5.1 and 2.8 U/l, respectively), confirming hypogonadotropic hypogonadism. At the age of 15 years, estradiol supplementation was started. In the following 2 years, the patient grew 4 cm. BA was 13.5 years at a CA of 15.2 years [14]. BMD z-scores were +1.3 and +2.0 at the LS and proximal left femur, and the LS BMAD z-score was +1.7 [15].

## Methods

Genomic DNA was isolated from peripheral blood samples using the AUTOPURE LS Instrument (Gentra Systems, Minneapolis, Minn., United States). Cytogenetic microarray analysis was performed using the Affymetrix CytoScan HD Array according to the manufacturer's procedures. Copy number was assessed in the proband using ChAS software (Chromosome Analysis Suite; Affymetrix, El Segundo, Calif., USA). Sanger sequencing of the complete coding region including intron-exon boundaries was performed using standard procedures (primer sequences available upon request). Exomes were captured by the NimbleGen SeqCap EZ V2 kit, followed by Illumina paired-end sequencing (2 × 100 bp) with at least ×40 mean coverage. Whole-exome sequencing data were generated in the Human Genotyping Facility of the Genetic Laboratory at the Department of Internal Medicine, Erasmus Medical Centre. Downstream analysis was performed with an in-house pipeline [16].

Two peripheral blood cultures for each patient were set up for RNA analysis: one with and one without cycloheximide. RNA was isolated with the RNA-Bee (Bio-connect B.V., Huissen, The Netherlands) method using NucleoSpin® RNA II columns (NucleoSpin® RNA II kit; Macherey-Nagel, Düren, Germany) according to the manufacturer's instructions. RT-PCR was performed with home-made primers (sequences available upon request), and Sanger sequencing was performed according to standard procedures. The investigations in patient 1 were approved by the Medical Ethics Committee of the Leiden University Medical Hospital (P06.118), and the investigations in patient 2 were performed in the context of routine patient care. Informed consent was obtained from patients and parents.

## Results

In both patients, a monogenic cause of obesity was suspected because of severe early-onset obesity and lean family members. In patient 1, whole-exome sequencing was performed in the index, her parents and two siblings. This revealed two novel *LEPR* mutations in the index, a splice-site mutation c.1753–1dupG in intron 13

and a missense mutation c.2168C>T p.Ser723Phe in exon 16. RNA analysis of the splice-site mutation r.1753–1dupG showed that the splice-acceptor site shifts one nucleotide, causing the retention of an extra nucleotide in the mRNA and a frameshift with a premature stop codon p.Met585Aspfs\*2 (fig. 2, 3). The substituted serine (p.Ser723Phe) is a highly conserved amino acid (conserved in 11 species) in the fibronectin type III domain. The mutation of this residue is predicted to be pathogenic by in silico prediction programs [SIFT: deleterious (score 0.0; median 3.38); PolyPhen: probably damaging; HumDiv: score 1.000; HumVar: score 0.999; Mutation Taster: disease causing a p value of 1.0]. The mother and sister carry the missense mutation, the brother has two wild-type alleles and the father carries the splice mutation.

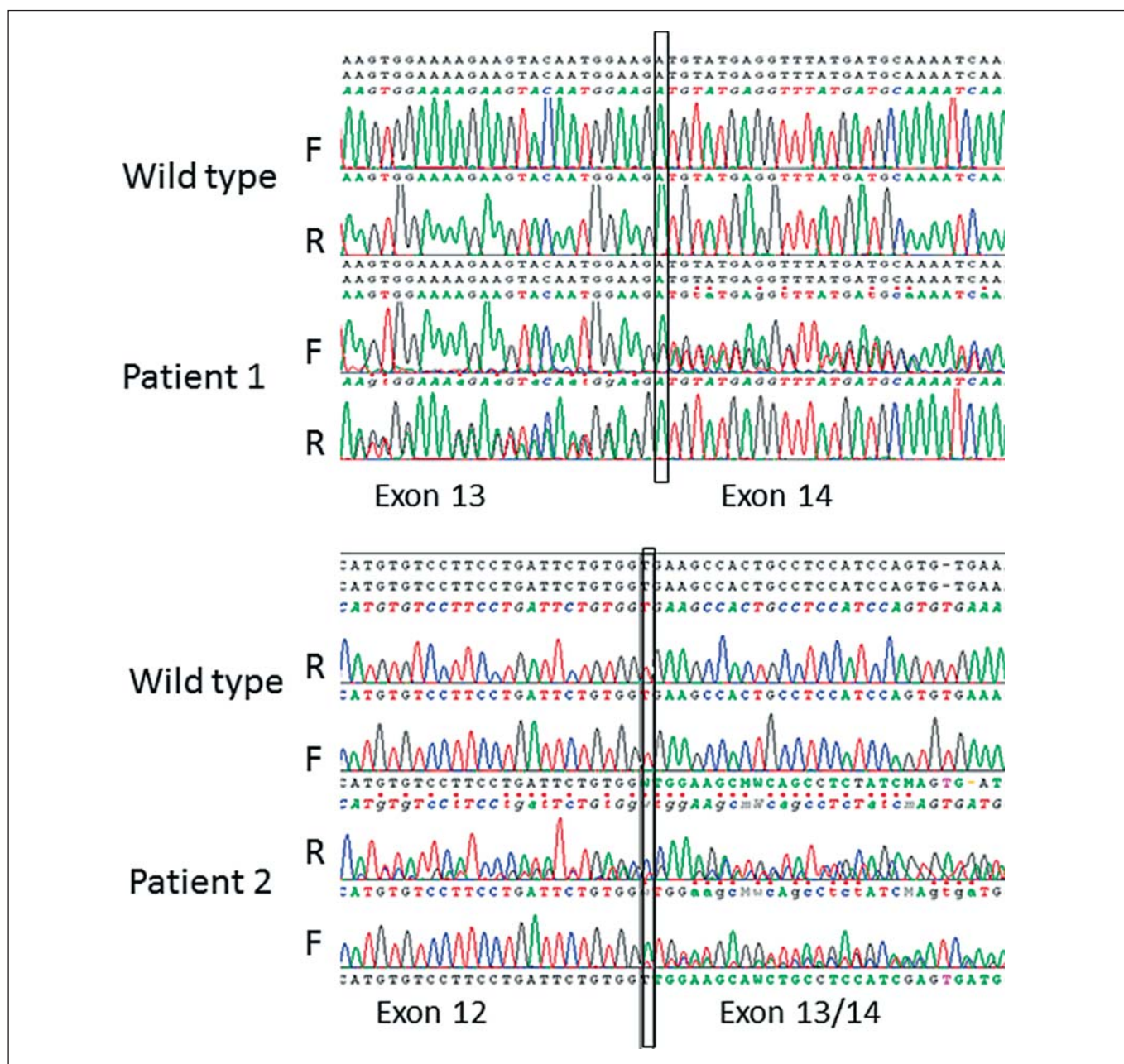
A CytoScan in patient 2 showed a paternal interstitial duplication on chromosome 2 containing part of the *CNTNAP5* gene. Since her father was not severely obese, we concluded that the duplication was likely to be a rare polymorphism without clinical significance. Of interest was a region of homozygosity of 7.5 Mb on chromosome 1 containing the *LEPR* gene. Sanger sequencing confirmed the presence of a novel homozygous *LEPR* mutation, c.1604–8A>G, in intron 12. mRNA analysis showed two transcripts, one with retention of 7 nucleotides from intron 12 (r.1604–7\_1604–1insTTTCTAG) and one missing exon 13 (r.1604\_1752del; fig. 2, 3). Both transcripts result in a frameshift and premature stop codon (p.Lys597Serfs\*34 and p.Val596Aspfs\*3, respectively). The transcripts were present at very low levels, indicating rapid degradation.

Once the *LEPR* mutations had been identified, laboratory tests were performed to exclude an immune deficiency. Lymphocyte subsets and T-cell proliferative responses to stimulation by aCD3, IL-2/CD28, PHA/IL2 and tetanus toxoid were normal in both patients.

## Discussion

These 2 girls, together carrying three novel *LEPR* mutations, show the classical phenotype of *LEPR* deficiency with severe obesity from the first year of life [3]. Patient 2 denies hyperphagia, which has been reported in all other patients, but appetite was not objectively assessed.

In patient 1, pathogenicity of the amino acid substitution variant was not confirmed by functional studies, but based on the evolutionary conservation of this amino acid and the in silico prediction, we consider it highly likely



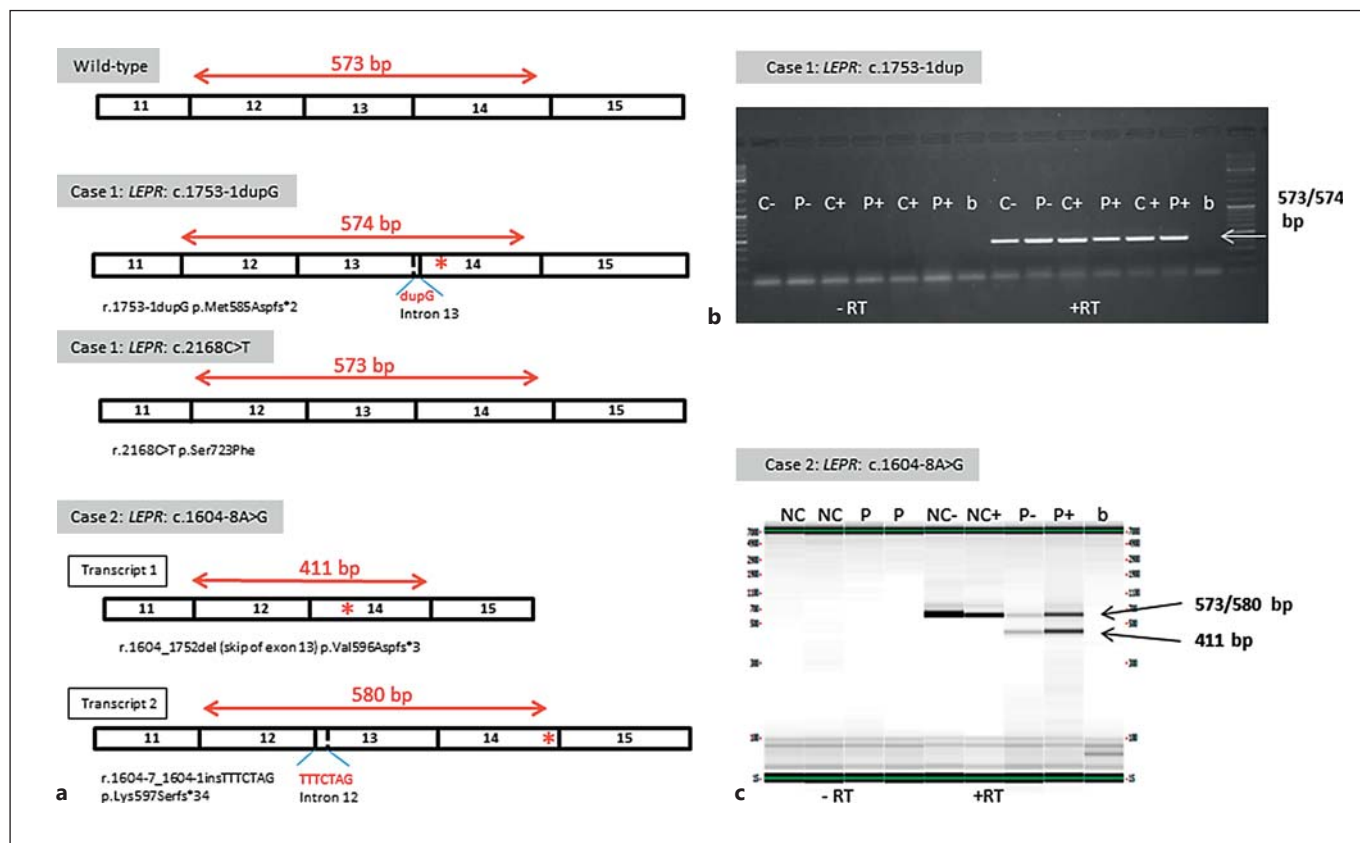
**Fig. 2.** Sanger sequencing results of the RNA of patient 1 (upper panel) and patient 2 (lower panel) compared to the wild-type sequence. Both patients show two transcripts. In patient 1, the wild type and mutant r.1753-1dupG transcript are visible, while in patient 2, the mutant transcript r.1604-7\_1604-1insTTTCTAG (ex-

ons 12-13) and the mutant transcript with the skip of exon 13 (r.1604\_1752del; exons 12-14) are seen. Exon numbers are indicated below the sequences. The vertical box indicates the first nucleotide of the exon. F = forward; R = reverse.

that this was a pathogenic mutation. RNA analysis showed that the splice-site mutation gave rise to a frameshift and premature stop codon. RNA analysis in patient 2 showed that the homozygous mutation, due to alternative splicing, resulted in two transcripts that were formed from the

same pre-mRNA. Both these mRNA molecules resulted in a frameshift and premature stop codon.

The father of patient 1 is obese (BMI 37.5), as has previously been reported in some heterozygous carriers [7] but not in others [3]. He had normal weight as a child and



**Fig. 3.** **a** Schematic representation of the wild-type and mutant transcripts in patient 1 and patient 2. Numbered boxes represent exons; fragment sizes are indicated. Premature stop codons are indicated with an asterisk. The wild-type product of exons 12–14 is 573 bp. The splice-site mutation in patient 1 gives a fragment of 574 bp. The amino acid substitution mutation is located in exon 16, i.e. outside this fragment. Patient 2 has two different transcripts resulting from one mutation: one with a skip of exon 13 (411 bp) and one with a 7-bp insertion (580 bp). **b**, **c** RT-PCR products of

patient 1 on agarose gel (**b**) and of patient 2 on Labchip (**c**). NC indicates the normal control, P the patient; – without and + with cycloheximide (inhibits nonsense-mediated decay); –RT without and +RT with reverse transcriptase. b indicates blank (no RNA). Fragment sizes are indicated on the right hand side. Fragments of 573, 574 and 580 bp cannot be discriminated with these techniques, but the Labchip 411-bp fragment that does not contain exon 13 is clearly visible.

only gained weight after adolescence. The fact that obesity did not develop until adulthood may be interpreted as evidence against a causal role of the obviously congenital *LEPR* mutation. However, the development of obesity during adulthood was also observed by others in heterozygous subjects [8]. The heterozygous mother and sister have normal weight.

Prepubertal *LEPR*-deficient children were reported to be tall [5], but to the same extent as equally obese subjects without *LEPR* mutations [3]. However, two *LEPR*-deficient sisters with poor growth and low GH secretion have also been described [2]. A lack of pubertal growth spurt with reduced adult height was described by some [3], although others reported normal adult height [6]. Our pa-

tient 1 showed growth acceleration during the first 4 years, followed by steady growth within the TH range, and patient 2 did not show an evident pubertal growth spurt but continued to grow along her TH SDS to achieve a normal adult height.

Patient 1 had a remarkably advanced BA (BA/CA ratio 1.4) despite prepubertal levels of estrogens and androgens. BA was more advanced than usually seen in children of similar BMI SDS and age (BA/CA ratio  $1.2 \pm 0.3$ ) [17]. A very advanced BA was previously reported in prepubertal children with leptin deficiency [11, 18–20], but a 13.8-year-old leptin-deficient girl with arrested puberty and low estradiol had a slightly retarded BA of 13.3 years [21]. Several studies also reported an advanced BA in

some, but not all, patients with lipodystrophy, who have low or undetectable leptin levels [11, 22]. The fact that advanced BA is reported in prepubertal children with absent/reduced leptin levels or *LEPR* mutations suggests that absent or decreased leptin signaling favors bone maturation. Elfeteriou et al. [11] interpreted the advanced BA as an indirect sign of premature bone formation caused by the absence of leptin as an anti-osteogenic factor. Interestingly, both our patients had relatively high BMD and BMAD levels. In the first patient, tall stature and advanced BA could partially explain the high BMD. However, the second patient had an average height for age and a retarded BA, and since she was hypogonadal, her BMD was expected to be low. Increased BMD may be related to obesity [23, 24], although other studies failed to confirm these findings [17]. This raises the question whether leptin itself might directly affect bone metabolism, which is possible as *LEPR* is expressed in (adult) osteoblasts and chondrocytes [25].

Data from animal models provide conflicting data on the effect of leptin on bone. In mouse models, defects in leptin signaling were found to result in an increased bone mass by some [26, 27]. In contrast, others found a reduced bone mass in leptin-deficient mice [28, 29]. Different effects of leptin administration on bone have been observed, possibly due to different routes of administration, with intracerebroventricular infusion being associated with bone loss [27] and peripheral administration with increased bone formation [30]. Age may also be a determinant of the effect of leptin, as a leptin antagonist was found to have a positive effect on bone formation in young mice but no effect in older mice [31].

The role of leptin in human bone metabolism also remains elusive. In obese subjects leptin levels are positively correlated to BMD z-scores [23], although this association may not be independent but mediated through fat mass [32]. Unravelling the link between leptin and bone in obesity is complicated by the finding of a state of leptin resistance in obesity. This was first observed in animal models and is evident from the fact that elevated leptin levels do not result in a return to normal weight [33].

In women with hypoleptinemia due to strenuous exercise treatment with recombinant methionyl, human leptin (metreleptin) increased the bone mineral content (BMC) of the LS but not at other sites [34]. However, the increased BMC may be mediated by the increase in estradiol levels and decrease in cortisol levels observed during metreleptin treatment [34]. A study of three leptin-deficient adults reported normal BMD at the LS in 2 females and low BMD (z-score  $-2.36$ ) in 1 male, who also suffered

from hypogonadism [35]. Farooqi et al. [20] described normal BMD in 3 leptin-deficient children, and BMD in these children continued to develop as expected for age and gender during metreleptin treatment, although actual z-scores were not provided. On the other hand, individuals, including children, with hypoleptinemia due to lipodystrophy were found to have an increased BMC SDS of the total body less head, also when adjusted for height, and an increased BMD at the LS and hip [22]. Treatment with recombinant leptin had no effect on BMD in individuals with lipodystrophy [22, 36].

These findings led us to hypothesize that in humans, decreased or absent leptin signaling favors an increase in bone mass. As seen within a group of individuals with lipodystrophy, BMC may not be outside the normal range in all affected subjects despite a clearly higher BMC of the group as a whole [22]. This might also explain why the 3 leptin-deficient children had a normal rather than an elevated BMD, although this remains speculative as no z-scores were provided so that it is unclear whether these children even had a BMD  $>0$  SDS. In older individuals, other factors such as hypogonadism may explain a low BMD despite reduced or lost leptin signaling.

Leptin signaling has been suggested to affect bone metabolism directly through effects on osteoblasts and indirectly through altered activity of the (sympathetic) nervous system, GH, IGF1, parathyroid and thyroid hormones, cortisol and estrogen [12]. The finding that obese subjects with a mutation in *MC4R*, which acts downstream of the *LEPR*, also have a high BMD [37] suggests that leptin may act on proopiomelanocortin-producing neurons and then through the melanocortin 4 receptor on paraventricular neurons to influence bone metabolism. The pathway further downstream is not clear. In the patients we describe herein, no abnormalities in the serum levels of IGF1, PTH or thyroid function were observed, although this does not exclude a role of these hormones in the bone phenotype.

Patient 2 had hypogonadotropic hypogonadism, which has previously been reported in several *LEPR*-deficient subjects [2, 3, 6, 8]. In leptin-deficient patients with hypogonadotropic hypogonadism, a normal response to GnRH has been described by some, which was seen as evidence for the hypothalamic origin of hypogonadism [35], but others found a low response to GnRH as we did [2]. *LEPR* is expressed by mouse gonadotropes and may be important in the regulation of GnRH binding [38]. This suggests that hypogonadism in *LEPR* deficiency may be due to a defect both at the hypothalamic and at the pituitary level. However, hypogonadism may change over

time, as a low response to GnRH was reported in a 16-year-old LEPR-deficient boy who had a normal response at the age of 19 years [6]. Another case with a low response to GnRH as a teenager later had spontaneous pubertal development and a natural pregnancy [39].

In previous studies, hyperinsulinemia or insulin resistance was observed in 10/10 and 5/9 LEPR-deficient subjects studied; 2 middle-aged subjects and 1 20-year-old had type 2 diabetes mellitus [3]. Patient 2 from the current study already has impaired glucose tolerance, suggesting that progression of hyperinsulinemia to type 2 diabetes mellitus may occur at a young age. Neither of the 2 patients had immune defects in contrast to 9 previously studied LEPR-deficient children [3, 4, 7].

In conclusion, we describe 2 girls with severe obesity caused by novel *LEPR* mutations. The longitudinal growth data show normal childhood growth; the older girl reached normal adult height despite hypogonadotropic hypogonadism and the lack of an obvious pubertal growth spurt. BA is remarkably advanced in the younger girl, and BMD is high in both girls, which might be re-

lated to leptin resistance. With the description of more patients with LEPR deficiency, it becomes obvious that the phenotype is variable, with early-onset obesity as a common feature and hypogonadotropic hypogonadism and immune deficiency for example as more variable features. More data on bone development in LEPR-deficient subjects should help further unravel the role of leptin in human bone.

## Acknowledgements

We thank the patients for their willingness to participate in this study. We thank Ms. ing. M.M. van Ostaijen-ten Dam for testing the T-cell proliferative responses in these patients. W.O. received unrestricted grant support from Novo Nordisk B.V.

## Disclosure Statement

J.M.W. is a consultant for OPKO, Versartis, Biopartners, Merck-Serono, Teva and Ammonett. The other authors have no conflicts of interest to declare.

## References

- 1 Farr OM, Tsoukas MA, Mantzoros CS: Leptin and the brain: influences on brain development, cognitive functioning and psychiatric disorders. *Metabolism* 2015;64:114–130.
- 2 Clement K, Vaisse C, Lahlou N, Cabrol S, Pelloux V, Cassuto D, Gourmelon M, Dina C, Chambaz J, Lacorte JM, Basdevant A, Bougneres P, Lebouc Y, Froguel P, Guy-Grand B: A mutation in the human leptin receptor gene causes obesity and pituitary dysfunction. *Nature* 1998;392:398–401.
- 3 Farooqi IS, Wangenstein T, Collins S, Kimber W, Matarese G, Keogh JM, Lank E, Bottomley B, Lopez-Fernandez J, Ferraz-Amaro I, Dattani MT, Ercan O, Myhre AG, Retterstol L, Stanhope R, Edge JA, McKenzie S, Lessan N, Ghodsi M, De Rosa V, Perna F, Fontana S, Barroso I, Undlien DE, O'Rahilly S: Clinical and molecular genetic spectrum of congenital deficiency of the leptin receptor. *N Engl J Med* 2007;356:237–247.
- 4 Mazen I, El-Gammal M, Abdel-Hamid M, Farooqi IS, Amr K: Homozygosity for a novel missense mutation in the leptin receptor gene (P316T) in two Egyptian cousins with severe early onset obesity. *Mol Genet Metab* 2011; 102:461–464.
- 5 Andiran N, Celik N, Andiran F: Homozygosity for two missense mutations in the leptin receptor gene (P316:W646C) in a Turkmenian girl with severe early-onset obesity. *J Pediatr Endocrinol Metab* 2011;24:1043–1045.
- 6 Le Beyec J, Cugnet-Anceau C, Pepin D, Alili R, Cotillard A, Lacorte JM, Basdevant A, Laville M, Clement K: Homozygous leptin receptor mutation due to uniparental disomy of chromosome 1: response to bariatric surgery. *J Clin Endocrinol Metab* 2013;98:E397–E402.
- 7 Vauthier V, Jaillard S, Journel H, Dubourg C, Jockers R, Dam J: Homozygous deletion of an 80 kb region comprising part of DNAJC6 and LEPR genes on chromosome 1P31.3 is associated with early onset obesity, mental retardation and epilepsy. *Mol Genet Metab* 2012;106: 345–350.
- 8 Huvenne H, Le Beyec J, Pepin D, Alili R, Kherchiche PP, Jeannic E, Frelut ML, Lacorte JM, Nicolino M, Viard A, Laville M, Ledoux S, Tounian P, Poitou C, Dubern B, Clement K: Seven novel deleterious LEPR mutations found in early-onset obesity: a  $\Delta$ Exon6–8 shared by subjects from Reunion Island, France, suggests a founder effect. *J Clin Endocrinol Metab* 2015;100:E757–E766.
- 9 Saeed S, Bonnefond A, Manzoor J, Shabir F, Ayesha H, Philippe J, Durand E, Crouch H, Sand O, Ali M, Butt T, Rathore AW, Falchi M, Arslan M, Froguel P: Genetic variants in LEP, LEPR, and MC4R explain 30% of severe obesity in children from a consanguineous population. *Obesity (Silver Spring)* 2015;23:1687–1695.
- 10 Saeed S, Bonnefond A, Manzoor J, Philippe J, Durand E, Arshad M, Sand O, Butt TA, Falchi M, Arslan M, Froguel P: Novel LEPR mutations in obese Pakistani children identified by PCR-based enrichment and next generation sequencing. *Obesity (Silver Spring)* 2014;22: 1112–1117.
- 11 Elefteriou F, Takeda S, Ebihara K, Magre J, Patano N, Kim CA, Ogawa Y, Liu X, Ware SM, Craigen WJ, Robert JJ, Vinson C, Nakao K, Capeau J, Karsenty G: Serum leptin level is a regulator of bone mass. *Proc Natl Acad Sci USA* 2004;101:3258–3263.
- 12 Upadhyay J, Farr OM, Mantzoros CS: The role of leptin in regulating bone metabolism. *Metabolism* 2015;64:105–113.
- 13 Alikasifoglu A, Gonc N, Ozon ZA, Sen Y, Kandemir N: The relationship between serum adiponectin, tumor necrosis factor-alpha, leptin levels and insulin sensitivity in childhood and adolescent obesity: adiponectin is a marker of metabolic syndrome. *J Clin Res Pediatr Endocrinol* 2009;1:233–239.
- 14 Greulich WW, Pyle SI: *Radiographic Atlas of Skeletal Development of the Hand and Wrist*, ed 2. Stanford, Stanford University Press, 1959.
- 15 Ward KA, Ashby RL, Roberts SA, Adams JE, Zulf MM: UK reference data for the Hologic QDR Discovery dual-energy X ray absorptiometry scanner in healthy children and young adults aged 6–17 years. *Arch Dis Child* 2007; 92:53–59.



- 16 Santen GW, Aten E, Sun Y, Almomani R, Gilissen C, Nielsen M, Kant SG, Snoeck IN, Peeters EA, Hilhorst-Hofstee Y, Wessels MW, den Hollander NS, Ruivenkamp CA, van Ommen GJ, Breuning MH, den Dunnen JT, van Haeringen A, Kriek M: Mutations in SWI/SNF chromatin remodeling complex gene ARID1B cause Coffin-Siris syndrome. *Nat Genet* 2012;44:379–380.
- 17 Klein KO, Larmore KA, de Lancey E, Brown JM, Considine RV, Hassink SG: Effect of obesity on estradiol level, and its relationship to leptin, bone maturation, and bone mineral density in children. *J Clin Endocrinol Metab* 1998;83:3469–3475.
- 18 Farooqi IS, Jebb SA, Langmack G, Lawrence E, Cheetham CH, Prentice AM, Hughes IA, McCamish MA, O'Rahilly S: Effects of recombinant leptin therapy in a child with congenital leptin deficiency. *N Engl J Med* 1999;341:879–884.
- 19 Gibson WT, Farooqi IS, Moreau M, DePaoli AM, Lawrence E, O'Rahilly S, Trussell RA: Congenital leptin deficiency due to homozygosity for the Delta133G mutation: report of another case and evaluation of response to four years of leptin therapy. *J Clin Endocrinol Metab* 2004;89:4821–4826.
- 20 Farooqi IS, Matarese G, Lord GM, Keogh JM, Lawrence E, Agwu C, Sanna V, Jebb SA, Perna F, Fontana S, Lechler RI, DePaoli AM, O'Rahilly S: Beneficial effects of leptin on obesity, T cell hyporesponsiveness, and neuroendocrine/metabolic dysfunction of human congenital leptin deficiency. *J Clin Invest* 2002;110:1093–1103.
- 21 von Schnurbein J, Moss A, Nagel SA, Muehleider H, Debatin KM, Farooqi IS, Wabitsch M: Leptin substitution results in the induction of menstrual cycles in an adolescent with leptin deficiency and hypogonadotropic hypogonadism. *Horm Res Paediatr* 2012;77:127–133.
- 22 Christensen JD, Lungu AO, Cochran E, Collins MT, Gafni RI, Reynolds JC, Rother KI, Gorden P, Brown RJ: Bone mineral content in patients with congenital generalized lipodystrophy is unaffected by metreleptin replacement therapy. *J Clin Endocrinol Metab* 2014;99:E1493–E1500.
- 23 Maggio AB, Belli DC, Puigdefabregas JW, Rizzoli R, Farpour-Lambert NJ, Beghetti M, McLin VA: High bone density in adolescents with obesity is related to fat mass and serum leptin concentrations. *J Pediatr Gastroenterol Nutr* 2014;58:723–728.
- 24 Leonard MB, Shults J, Wilson BA, Tershakovc AM, Zemel BS: Obesity during childhood and adolescence augments bone mass and bone dimensions. *Am J Clin Nutr* 2004;80:514–523.
- 25 Hess R, Pino AM, Rios S, Fernandez M, Rodriguez JP: High affinity leptin receptors are present in human mesenchymal stem cells (MSCs) derived from control and osteoporotic donors. *J Cell Biochem* 2005;94:50–57.
- 26 Takeda S, Eleftheriou F, Levasseur R, Liu X, Zhao L, Parker KL, Armstrong D, Ducy P, Karsenty G: Leptin regulates bone formation via the sympathetic nervous system. *Cell* 2002;111:305–317.
- 27 Ducy P, Amling M, Takeda S, Priemel M, Schilling AF, Beil FT, Shen J, Vinson C, Rueger JM, Karsenty G: Leptin inhibits bone formation through a hypothalamic relay: a central control of bone mass. *Cell* 2000;100:197–207.
- 28 Stepan CM, Crawford DT, Chidsey-Frink KL, Ke H, Swick AG: Leptin is a potent stimulator of bone growth in ob/ob mice. *Regul Pept* 2000;92:73–78.
- 29 Hamrick MW, Della-Fera MA, Choi YH, Pennington C, Hartzell D, Baile CA: Leptin treatment induces loss of bone marrow adipocytes and increases bone formation in leptin-deficient ob/ob mice. *J Bone Miner Res* 2005;20:994–1001.
- 30 Turner RT, Kalra SP, Wong CP, Philbrick KA, Lindenmaier LB, Boghossian S, Iwaniec UT: Peripheral leptin regulates bone formation. *J Bone Miner Res* 2013;28:22–34.
- 31 Solomon G, Atkins A, Shahar R, Gertler A, Monsonego-Ornan E: Effect of peripherally administered leptin antagonist on whole body metabolism and bone microarchitecture and biomechanical properties in the mouse. *Am J Physiol Endocrinol Metab* 2014;306:E14–E27.
- 32 Huang KC, Cheng WC, Yen RF, Tsai KS, Tai TY, Yang WS: Lack of independent relationship between plasma adiponectin, leptin levels and bone density in nondiabetic female adolescents. *Clin Endocrinol (Oxf)* 2004;61:204–208.
- 33 Frederich RC, Hamann A, Anderson S, Lollmann B, Lowell BB, Flier JS: Leptin levels reflect body lipid content in mice: evidence for diet-induced resistance to leptin action. *Nat Med* 1995;1:1311–1314.
- 34 Sienkiewicz E, Magkos F, Aronis KN, Brinkoetter M, Chamberland JP, Chou S, Arampatzis K, Gao C, Koniaris A, Mantzoros CS: Long-term metreleptin treatment increases bone mineral density and content at the lumbar spine of lean hypoleptinemic women. *Metabolism* 2011;60:1211–1221.
- 35 Ozata M, Ozdemir IC, Licio J: Human leptin deficiency caused by a missense mutation: multiple endocrine defects, decreased sympathetic tone, and immune system dysfunction indicate new targets for leptin action, greater central than peripheral resistance to the effects of leptin, and spontaneous correction of leptin-mediated defects. *J Clin Endocrinol Metab* 1999;84:3686–3695.
- 36 Moran SA, Patten N, Young JR, Cochran E, Sebring N, Reynolds J, Premkumar A, DePaoli AM, Skarulis MC, Oral EA, Gorden P: Changes in body composition in patients with severe lipodystrophy after leptin replacement therapy. *Metabolism* 2004;53:513–519.
- 37 Farooqi IS, Keogh JM, Yeo GS, Lank EJ, Cheetham T, O'Rahilly S: Clinical spectrum of obesity and mutations in the melanocortin 4 receptor gene. *N Engl J Med* 2003;348:1085–1095.
- 38 Akhter N, CarlLee T, Syed MM, Odle AK, Cozart MA, Haney AC, Allensworth-James ML, Benes H, Childs GV: Selective deletion of leptin receptors in gonadotropes reveals activin and GnRH-binding sites as leptin targets in support of fertility. *Endocrinology* 2014;155:4027–4042.
- 39 Dubern B, Clement K: Leptin and leptin receptor-related monogenic obesity. *Biochimie* 2012;94:2111–2115.