

Original article

Management of penetrating neck injuries; presenting an algorithm based on a prospective study

OJ Van Waes¹, KCAL Cheriex¹, PA van Riet¹, PH Navsaria², AJ Nicol², J Vermeulen¹

OJ Van Waes and KCAL Cheriex contributed equally to this work

1. Department of Trauma Surgery, Erasmus University Medical Centre, Rotterdam, the Netherlands

2. Department of Trauma Surgery, Groote Schuur Hospital, University of Cape Town, Cape Town, South Africa

All correspondence to:

Jefrey Vermeulen MD PhD
Erasmus University Medical Centre
Department of Trauma Surgery
Dr Molewaterplein 40
3015 GE Rotterdam
The Netherlands
Email: j.vermeulen.1@erasmusmc.nl

Funding : none

The results of the study are presented at the 2011 European Society for Trauma and Emergency Surgery congress in Milan, Italy (April 27-30) and at the 2010 Autumn meeting of the Dutch Society of Surgery in Veldhoven, The Netherlands (November 26).

Abstract

Background: Routine surgical exploration after penetrating neck injuries (PNI) leads to a large number of negative neck explorations and iatrogenic injuries. Selective non-operative management (SNOM) is gaining favour for patients with PNI. The present study was undertaken to assess SNOM in PNI and to present a management-algorithm.

Method: 77 subsequent patients, who presented at a tertiary referral centre for penetrating injuries were included in this prospective cohort study. All patients were protocol managed following ATLS guidelines and either underwent emergency surgery or were treated conservatively, based on clinical findings and additional investigations. Additional investigations were only requested on indication.

Results: Of all 77 patients, 8 patients were hemodynamically unstable at presentation. In 7 Foley catheter balloon tamponade (FCBT) was attempted, which was successful in 6. These patients underwent diagnostic angiography, which showed arterial injury in 5. All other presented patients (n=69) could be managed according to the SNOM protocol successfully, too. Angiography or computerized tomography scanning was performed in 41 patients, which showed arterial injury in 15 patients and were subsequently treated by surgery (n=7), radiological stenting (n=3), or conservatively. Indication for additional oesophageal investigation was set for 37, but all investigations were negative for injury. During follow up no injuries seemed to be missed at initial presentation.

Conclusion: FBCT is useful in patients with active bleeding from PNI. Stabilized patients should undergo additional investigation based on clinical findings only. SNOM according to the presented algorithm is a feasible and safe strategy for PNI.

Introduction

Penetrating neck injuries (PNI) are not very common in West European countries. The low incidence of this kind of trauma makes it impossible for trauma surgeons to gain experience in its management. Moreover, patients with stab wounds (SW) or gunshot wounds (GSW) usually are presented to the emergency department unannounced and therefore it is possible that the local trauma team is not adequately prepared for immediate clinical assessment, especially in smaller units such as county hospitals.

PNI is considered a difficult injury to manage because of complex anatomy, immediate proximity of vital structures and potential for rapid hemodynamic and airway deterioration.[1-3] A well-prepared trauma team is essential to improve outcome in PNI. In the past, routine neck exploration was common practise for these patients, resulting in a large number of unnecessary neck explorations and iatrogenic injuries.[4,5] Based on the experience from high-volume hospitals in developing countries, selective non-operative treatment (SNOM) is gaining favour.[6-8]

Groote Schuur Hospital is one of those high-volume hospitals and a tertiary referral trauma centre for penetrating injuries with over 200 patients with PNI each year.[6]. The department of trauma surgery has created a treatment protocol of PNI based on the SNOM principle.[6] The present study was undertaken to evaluate the feasibility of this SNOM protocol. Based on the results a management algorithm, which is useful for West European countries, is presented.

Patients and methods

All patients presenting with PNI at the Trauma unit of the Groote Schuur Hospital in Cape Town, South Africa were included in this prospective observational study with a period of three and a half months (September to December 2009). Inclusion criteria were patients with neck injuries that penetrated the platysma muscle and age > 18 yr. Patients who died within 24 hrs, due to other injuries than PNI were excluded from this study. Age, gender, mechanism of injury, type of injury (oesophageal, airway, vascular), Injury Severity Score, clinical manifestations and vitals, indications for additional investigations and treatment strategy of all patients were prospectively collected and analyzed in the light of outcome and length of hospital stay.

All patients were managed and treated according to the local protocol for PNI. A brief description of this SNOM protocol is stated below.[6] Patients with SW and GSW of the neck are resuscitated according to the Advanced Trauma Life Support (ATLS®) guidelines.

Hemodynamically stable patients, and patients who respond to initial resuscitation with 1-2 litres of crystalloid with normalized pulse rate, blood pressure, etc, were first evaluated with a thorough history and clinical examination. Wounds were described by different anatomic zones of the neck (figure 1).[9] A chest X-ray and a lateral cervical spine X-ray were performed in all patients, to look for signs of aerodigestive or vascular trauma. Patients with transmidline GSW underwent routine computerized tomography angiography (CTA).

Special investigations were requested according to a pre-established neck injury evaluation protocol based on symptoms found by clinical examination or signs of trauma on chest/lateral cervical spine X-ray (table 1). If any severe injury was found by additional investigations and surgical care was needed, patients were immediately transferred to the operating room for surgical intervention.

Hemodynamically stable patients with a negative history and clinical examination were admitted to the high-care trauma surgical ward, with 4-hourly clinical neck examination, hemodynamic and airway monitoring and kept sober. The 4-hourly examination was performed by the cutting-registrar on call and the senior of the nursing staff, who examined the patients on alarm symptoms mentioned in table 1. After 24 hours they were put on an oral diet and, if tolerated, were discharged the next morning. They were given a neck injury form that listed alarm symptoms of vascular/aerodigestive injuries, in which case they needed to return to the hospital.

Hemodynamically unstable patients were immediately transferred to the operating room. In patients with bleeding neck wounds haemorrhage control was attempted by using Foley catheter balloon tamponade (FCBT)(figure 2).[10,11] If haemorrhage control was not established, surgical exploration of the neck injury followed immediately. If haemorrhage was controlled by FCBT and the patient could be stabilized after resuscitation, angiography was performed to detect major arterial injury, and, if positive, patients still could be transferred to the operating room or were treated by endovascular stenting. A venous injury was diagnosed if angiography was normal. Without any serious arterial injury, the patient was observed for 48-72 hours, after which the Foley catheter was removed in the operating room. In case of re-bleeding, surgical intervention was performed.

The outcomes of the patients were assessed in order to validate the SNOM protocol of PNI. The results of this study were used to present a management protocol for PNI, which would also be valuable for West European countries.

Results

A total of 78 patients with PNI presented at the emergency department of the Groote Schuur Hospital during the study period. One patient died of accompanied abdominal bleeding within 24 hours after admission and was excluded from the study. The median New Injury Severity Score (NISS) of the 77 included patients was 25 (range 9-59). Some patients had multiple wounds to the neck, with a total of 84 neck wounds in 77 patients. Stab wounds (SW) were found in 79% of patients (67 wounds), with a predominant number of SWs in zone 2 of the left anterior triangle of the neck (table 2).

A total of 56 patients underwent one or more additional investigations because of suspected visceral injury. Thirty-seven of them underwent oesophogram/endoscopy because of clinical suspicion for oesophageal injury listed in table 1 (dysphagia/odynophagia n=17; prevertebral air n=10; odynophagia and prevertebral air n=5; lowered Glasgow Coma Scale n=3; other n=2). None of them showed any injury on additional barium swallow (table 2). In one patient, who underwent emergency surgery because of hemodynamic instability, an oesophageal perforation at the level of the 7th cervical vertebra was found during perioperative oesophagoscopy. The lesion was primarily repaired during neck exploration. No upper airway injuries were found or suspected in this study population.

A total of 10 patients underwent computerized tomography scanning as additional investigation (table 3). In 8 patients protocol CTA was performed because of transmidline GSW injury of the neck, although there were no clinical signs of active bleeding. None of them showed vascular injuries, but 4 of them were neurologically compromised with accompanied fractures.

A total of 7 patients were initially treated with FCBT because of bleeding from the neck wound. In one patient haemostasis could not be achieved and was surgically treated. The other 6, in whom haemostasis was achieved, were observed and underwent diagnostic angiography within 24 hours. Five of these patients showed arterial injury and could be treated by surgery (n=3; common carotid artery, internal carotid artery, subclavian artery), radiologic-assisted stenting (false aneurysm of subclavian artery) or conservatively (dissected

and occluded vertebral artery). The Foley catheters of both patients, who did not need to undergo surgery or stenting, were removed in the operating room 2 days after patient's presentation; in none of them re-bleeding occurred. Besides the patients with FCBT, another 25 patients underwent angiography on indication to assess vascular injury (table 3).

Overall, only two (2.6%) patients needed to undergo emergency exploration of the neck because of hemodynamic instability due to exsanguinating bleed, not improving during initial resuscitation. Eventually, another 7 (9.3%) patients underwent elective surgery and 3 (4.0%) were treated by radiological intervention, because of vascular injury (table 4). Of all patients, 65 (86.7%) patients could be treated conservatively. After conservative observation, none of the patients subsequently needed surgical intervention to treat (late onset) complications. Besides, none of the patients that were discharged from hospital returned to hospital because of alarm symptoms.

The median hospital stay was 2 days (± 4.6 , 1-36). Two patients (2.6%) died of cerebral ischemia. One patient after transmidline GSW did not wake up after general anaesthesia for emergency tracheostomy placement. A postoperative CT-scan of the brain of a patient after SW who underwent primary reconstruction of carotid artery injury showed multiple infarcts and was declared brain dead 5 days after surgery.

Discussion

In the Netherlands, as in the rest of West-Europe, the incidence of PNI is rather low. In Dutch trauma centres there is definitely a lot less experience with the management of PNI than, for example, in the USA or African countries. Due to this low incidence of PNI it is not possible for a trauma surgeon to get experienced with the management and treatment of this kind of trauma. In the past, routine neck exploration was the standard treatment for PNI, which has led to a high percentage of negative neck explorations (26%) and significant associated morbidity (51%).[6,8,12,13]

In high-volume trauma centres with a high number of patients with PNI, SNOM is becoming more and more accepted. SNOM is based on clinical examination and additional investigations.[13,14] Together they have shown to be a reliable indicator of clinically significant injury, with a sensitivity of 93-95% and a negative predictive value of 97%. [13-17].

Because of complex anatomy, PNI is considered a difficult injury to manage. These injuries can be life-threatening, especially when the major blood vessels are involved. A multidisciplinary approach to treatment is essential to improve outcome. After airway maintenance and hemodynamic stabilisation, further treatment can be initiated by interventional radiologist, oral and maxillofacial surgeon, neurosurgeon, vascular surgeon or ear nose and throat specialist when indicated by clinical examination of the patient. To achieve optimal treatment the hospital must have a well-organised and dedicated trauma unit.

All patients described in this study were presented in Groote Schuur Hospital, Cape Town, which is a high-volume, tertiary referral trauma centre for penetrating injury and in which a multidisciplinary management approach for this kind of trauma is guaranteed. About 200 patients with PNI are presented each year at this trauma centre.[6] The local management protocol for assessing and treating patients with PNI is based essentially on hemodynamic and airway status, together with a thorough physical examination. Initial management of GSW and SW is similar, as previous studies found no significant difference in the rate of successful SNOM between them.[6,15] Transmidline GSWs though, have a significant higher rate of injuries than other PNI.[18] Therefore a routine CT-scan is made in these patients in Groote Schuur hospital. In the present study 8 patients with a transmidline GSW underwent CTA. As none of them showed vascular, oesophageal or tracheal lesions, all patients were successfully treated conservatively. Mandatory neck exploration would not have been useful in these patients. Moreover, the usefulness of performing routine CTA in patients with transmidline GSW is debatable, especially when the patient is fully conscious.[15]

Oesophageal injuries are not very common and remain difficult to detect early, because clinical findings are not always obvious.[19,20] More than 90% of patients survive if the diagnosis is made within 24 hours, but the survival rate drops quickly after this time.[20] Patients presenting with blood in the mouth, odynophagia, dysphagia, or other clinical signs of oesophageal injury as listed in table 1, have a significantly higher incidence of (pharyng)oesophageal injuries than those without these clinical signs.[6] Because consequences after a missed oesophageal lesion could be dramatic, additional investigations are often done even with a low suspicion for oesophageal trauma. Missed pharyngeal lesions are less dramatic compared to oesophageal lesions.[21,22] Usually pharyngeal lesions can be treated conservatively with antibiotics alone, whereas oesophageal lesion needs aggressive (surgical) treatment with drainage of the mediastinum as mediastinitis is a common, but feared complication.[22-24]

In this study, 37 (48%) patients underwent barium swallow examination or endoscopy because of clinically suspected oesophageal injury. Nevertheless, none of them showed any injury on the additional investigation. During follow up of all patients, no oesophageal injuries were missed, which gives a negative predictive value of 100%.

Vascular injuries were more common encountered in the present study as listed in table 4. Although vascular injury at initial presentation after PNI is more frequently found, most of times emergency surgery is not necessary. In patients with profuse haemorrhage FCBT is indicated. Patients who are successfully stabilized with FCBT could subsequently undergo (semi-urgent) diagnostic angiography or CTA.[10,11] Especially venous injuries are compliant to FCBT and in those patients FCBT is often a definitive treatment.[10] Emergency neck exploration is only indicated for the persistent hemodynamic unstable patient. Hemodynamic stable or stabilized patients can be treated conservatively or should undergo treatment based on additional investigation.

In the present study 6 of 7 hemodynamic unstable patients in whom FCBT was attempted were stabilized and could undergo diagnostic angiography. The use of FCBT is known to be a reliable tool to arrest ongoing haemorrhage in multiple anatomic regions and for variable patterns of injury.[25] In two patients FCBT appeared to be a definitive treatment as no rebleeding occurred after removal of the Foley catheter. Furthermore, none of the patients that were treated conservatively, unexpectedly (re-) bled from a missed vascular injury during the observation period. All these findings indicate that initial SNOM of vascular injury is a feasible and safe approach in PNI.[10,11,25,26]

An alternative for conventional angiography could be CTA. Unfortunately, experience in performing CTA was limited in the institution at the time of the study, and most of the time not available after office hours. An advantage of using angiography though, is the possibility of interventional procedures (e.g., coiling or stenting) if indicated during the same session.

Nevertheless, for diagnostic evaluation of PNI, CTA has several advantages over conventional angiography. It is relatively fast, minimally invasive, has fewer potential complications.[1,13,27] Besides, it is readily available in most trauma centres in the Western countries. Moreover, no support of additional nonphysician staff is required, unlike with conventional angiography, and structures other than vascular structures can be visualised on CTA as well. Most important it is a reliable and accurate investigation with a sensitivity and specificity of 90% and 100% respectively, a positive predictive value of 100% and a negative predictive value of 98%.[1,13,27] Therefore CTA is more and more becoming the diagnostic tool of choice during initial evaluation of stable patients with vascular injury and therefore

also very useful in patients with PNI. It is advised to give oral contrast during CTA, in order to visualize oesophageal lesions.

Upper airway injuries were not encountered in this study, as they are fairly uncommon.[28] If clinical signs are present (table 1), a laryngoscopy/bronchoscopy is indicated. Conservative management of clinically minor airway injuries is safe, and tracheostomy should only be performed for destructive injuries or when the upper airway is compromised.[28,29]

In summary, clinical examination has a high negative predictive value for the absence of any injury, and can therefore dictate additional investigations to prove or exclude clinically significant injuries. The low failure rate in this study further validates the SNOM protocol for initial management of PNI. In suspected vascular injury, CTA could be the designated additional investigation, replacing conventional angiography. By giving oral contrast during scanning, oesophageal lesions could be detected as well. Management of GSW should not be different than management of SW, although one must realise that the severity of injury usually is more extensive due to the bullet track. Routine neck exploration in PNI is not indicated.

An algorithm for the initial management of PNI for Western countries is presented (figure 3). It is advised that all patients with penetrating injury are presented in level 1 trauma centres.

References

1. Munera F, Cohn S, Rivas LA. Penetrating injuries of the neck: use of helical computed tomographic angiography. *J Trauma* 2005; **58**: 413-418
2. Thal ER, Meyer DM. Penetrating neck trauma. *Curr Probl Surg* 1992; **29**: 51-56
3. Tallon JM, Ahmed JM, Sealy B. Airway management in penetrating neck trauma at a Canadian tertiary trauma centre. *CJEM*. 2007; **9**: 101-104
4. Demetriades D, Asensio JA, Velmahos G, Thal E. Complex problems in penetrating neck trauma. *Surg Clin North Am* 1996; **76**: 661-683
5. Apffelstaedt JP, Müller R . Results of mandatory exploration for penetrating neck trauma. *World J Surg* 1994; **18**: 917-199
6. Thoma M, Navsaria PH, Edu S, Nicol AJ. Analysis of 203 patients with penetrating neck injuries. *World J Surg* 2008; **32**: 2716-2723
7. Ngakane H, Muckart DJ, Luvuno FM. Penetrating visceral injuries of the neck: results of a conservative management policy. *Br J Surg* 1990; **77**: 908-910
8. Gouleke P, Goldstein A, Sclafani S, Mitchell W, Shaftan G. Routine versus selective exploration of penetrating neck injuries: a randomized prospective study. *J Trauma* 1984; **24**: 1010–1014
9. Roon AJ, Christensen N. Evaluation and treatment of penetrating cervical injuries. *J Trauma Injury Infect Crit Care* 1979; **19**: 391–397
10. Navsaria P, Thoma M, Nicol A. Foley catheter balloon tamponade for life-threatening hemorrhage in penetrating neck trauma. *World J Surg* 2006; **30**: 1265-1268
11. Gilroy D, Lakhoo M, Charalambides D, Demetriades D. Control of life-threatening haemorrhage from the neck: a new indication for balloon tamponade. *Injury* 1992; **23**: 557-559

12. Tisherman SA, Bokhari F, Collier B, Cumming J, Ebert J, Holevar M, et al. Clinical practice guideline: penetrating zone II neck trauma. *J Trauma* 2008; **64**: 1392-1405
13. Osborn RM, Bell RB, Qaisi W, Long WB. Computed tomographic angiography as an aid to clinical decision making in the selective management of penetrating injuries to the neck: a reduction in the need for operative exploration. *J Trauma* 2008; **64**: 1466-1471
14. Atteberry LR, Dennis JW, Menawatt SS, Frykberg ER. Physical examination alone is safe for evaluation of vascular injuries in penetrating zone II neck trauma. *J Am Coll Surg* 1994; **179**: 657–662
15. Sofianos C, Degiannis E, Van der Aardweg MS, Levy RD, Naidu M, Saadia R. Selective surgical management of zone II gunshot injuries to the neck: a prospective study. *Surgery* 1996; **120**: 785–788
16. Gonzalez RP, Falimirski M, Holevar MR, Turk B. Penetrating zone II neck injury: does dynamic computed tomographic scan contribute to the diagnostic sensitivity of physical examination for surgically significant injury? A prospective blinded study. *J Trauma* 2003; **54**: 61-64
17. Azuaje R, Jacobson LE, Glover J, Gomez GA, Rodman GH Jr, Broadie TA, et al. Reliability of physical examination as a predictor of vascular injury after penetrating neck trauma. *Am Surg* 2003; **69**: 804–807
18. Demetriades D, Theodorou D, Cornwell E, Asensio J, Belzberg H, Velmahos G, et al. Transcervical gunshot injuries: mandatory operation is not necessary. *J Trauma* 1996; **40**: 758-60
19. Demetriades D, Theodorou D, Cornwell EE, Berne TV, Asensio J, Belzberg H, et al. Evaluation of penetrating injuries of the neck: Prospective study of 223 patients. *World J Surg* 1997; **21**:41-47

20. Bladergroen MR, Lowe JE, Postlethwait RW. Diagnosis and recommended management of esophageal perforation and rupture. *Ann Thorac Surg* 1986; **42**: 235-239
21. Thompson EC, Porter JM, Fernandez LG. Penetrating neck trauma: an overview of management. *J Oral Maxillofac Surg* 2002; **60**: 918-923.
22. Stanley RB Jr, Armstrong WB, Fetterman BL, Shindo ML. Management of external penetrating injuries into the hypopharyngeal-cervical esophageal funnel. *J Trauma* 1997; **42**: 675-679
23. Normando R, Tavares MAF, Azevedo IU, Modesto A, Janahú AJL. Mediastinitis from perforation and rupture of the thoracic esophagus. *Rev Col Bras Cir* 2006; **33**: 361-364
24. Vogel SB, Rout WR, Martin TD, Abbitt PL. Esophageal perforation in adults: aggressive, conservative treatment lowers morbidity and mortality. *Ann Surg* 2005; **241**: 1016-1021
25. Ball CG, Wyrzykowski AD, Nicholas JM, Rozycki GS, Feliciano DV. A decade's experience with balloon catheter tamponade for the emergency control of hemorrhage. *J Trauma* 2011; **70**: 330-333
26. Larsen DW. Traumatic vascular injuries and their management. *Neuroimaging Clin N Am* 2002; **12**: 249-69
27. Schroeder JW, Baskaran V, Aygun N. Imaging of traumatic arterial injuries in the neck with an emphasis on CTA. *Am Soc Emergency Radiol* 2009; **17**: 109-122
28. Vassiliu P, Baker J, Henderson S, Alo K, Velmahos G, Demetriades D. Aerodigestive injuries of the neck. *Am Surg* 2001; **67**: 75-79

29. Mussi A, Ambrogi MC, Ribechini A, Lucchi M, Menoni F, Angeletti CA. Acute major airway injuries: clinical features and management. *Eur J Cardiothorac Surg* 2001; 20: 46-51

Tables

Table 1. Symptoms and signs associated with underlying visceral injuries after penetrating neck injury and investigation performed

Structure	Symptoms and signs	Investigation
Vascular	<ul style="list-style-type: none"> - Moderate to large haematoma - Pulsatile stable haematoma - Pulse deficit - Bruit - Any mediastinum changes on CXR - Foley catheter balloon tamponade 	Angiography/CTA
Pharynx/oesophagus	<ul style="list-style-type: none"> - Odynophagia - Dysphagia - Saliva leak from wound - Blood in nasogastric tube - Hematemesis - Subcutaneous emphysema - Prevertebral air on lat cervical spine - Pneumomediastinum on CXR - Lowered consciousness 	Oesophogram/Endoscopy
Larynx/ Trachea/bronchus	<ul style="list-style-type: none"> - Dysphonia/hoarseness - Tension pneumothorax - Severe surgical emphysema - Persistent air leak from chest drain 	Laryngo-/Bronchoscopy

CTA = Computerized tomography angiography; CXR = Chest X-ray

Table 2. Patients demographics

Patients	77
Male/female	70 / 7
Age, years ¹	26 (17-54)
NISS ¹	25 (9-59)
Mortality	2
Hospital stay, days ¹	2 (1-36)

Penetrating neck injury

Stab wound	67
Gunshot wound	17

Zone of neck injury

I	30
II	39
III	7
Posterior triangle	8

Suspected injury

Vascular

Angiography ²	31 (14)
CT-scan ²	10 (1)

Oesophagus

Barium swallow ²	34 (0)
Scopy ²	4 (1)

1. Values are median (range); 2. Values in parentheses are numbers of additional investigation with positive findings.

NISS = New Injury Severity Score; CT-scan = Computerized tomography scan

Table 3. Indications for additional vascular investigations and arterial injuries detected

Indication for investigation	Investigation	
	<i>Angiography</i>	<i>CTA</i>
Hematoma/blood loss with need for blood supply	8 (4)	
Hematoma/blood loss without blood supply (normal Hb)	6 (0)	
Foley Catheter Balloon tamponade	6 (5)	
Transmidline trajectory without signs of vascular injury		8 (0)
Pulsating Hematoma	4 (3)	
Pulse deficit upper limb	3 (2)	
Hemothorax	1 (0)	1 (1)
Bruit	1 (0)	1 (0)

Values in parentheses are numbers of additional investigation with positive findings.

CTA = Computerized tomography angiography; Hb = Hemoglobin

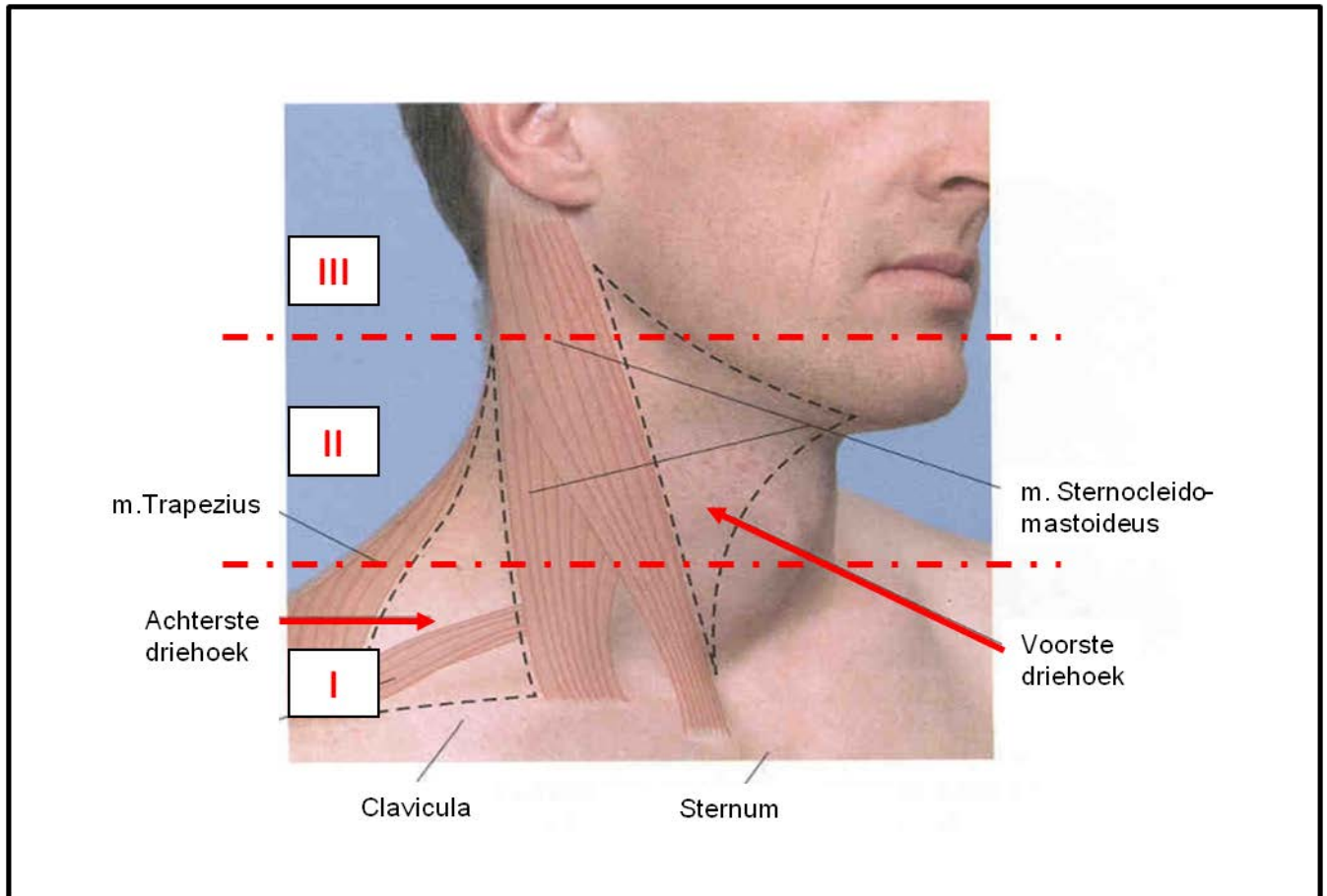
Table 4. Detected arterial injuries and treatment

Injury at radiography or CTA	Treatment
<i>Carotid artery injuries</i>	
Active bleeding com. carotid a.	Surgery
Arteriovenous fistula com. carotid a. and internal jugular v.	Surgery
Arteriovenous fistula int. carotid a. and jugular v.	Surgery
False aneurysm ext. carotid a.	Conservative
Dissected int. carotid a., without active bleeding	Conservative
<i>Central subclavian artery injuries</i>	
Dissected subclavian a. with active bleeding	Surgery
False aneurysm subclavian a.	Surgery
False aneurysm subclavian a.	Surgery
False aneurysm subclavian a.	Stenting
<i>Peripheral arterial injuries</i>	
Occlusion brachial a.	Surgery
False aneurysm costovertebral branch of subclavian a.	Stenting
Active bleeding lingual a.	Stenting
Occlusion vertebral a.	Conservative
Dissected vertebral a., without active bleeding	Conservative
Mammary a. lesion	Conservative

CTA = Computerized tomography angiography; Hb = Hemoglobin

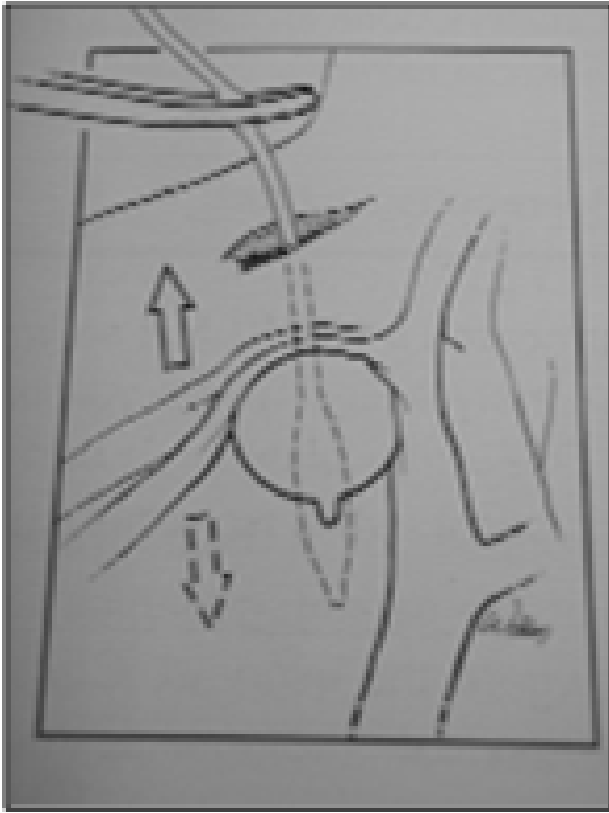
Figures

Figure 1. Entry zones of the neck for penetrating injury



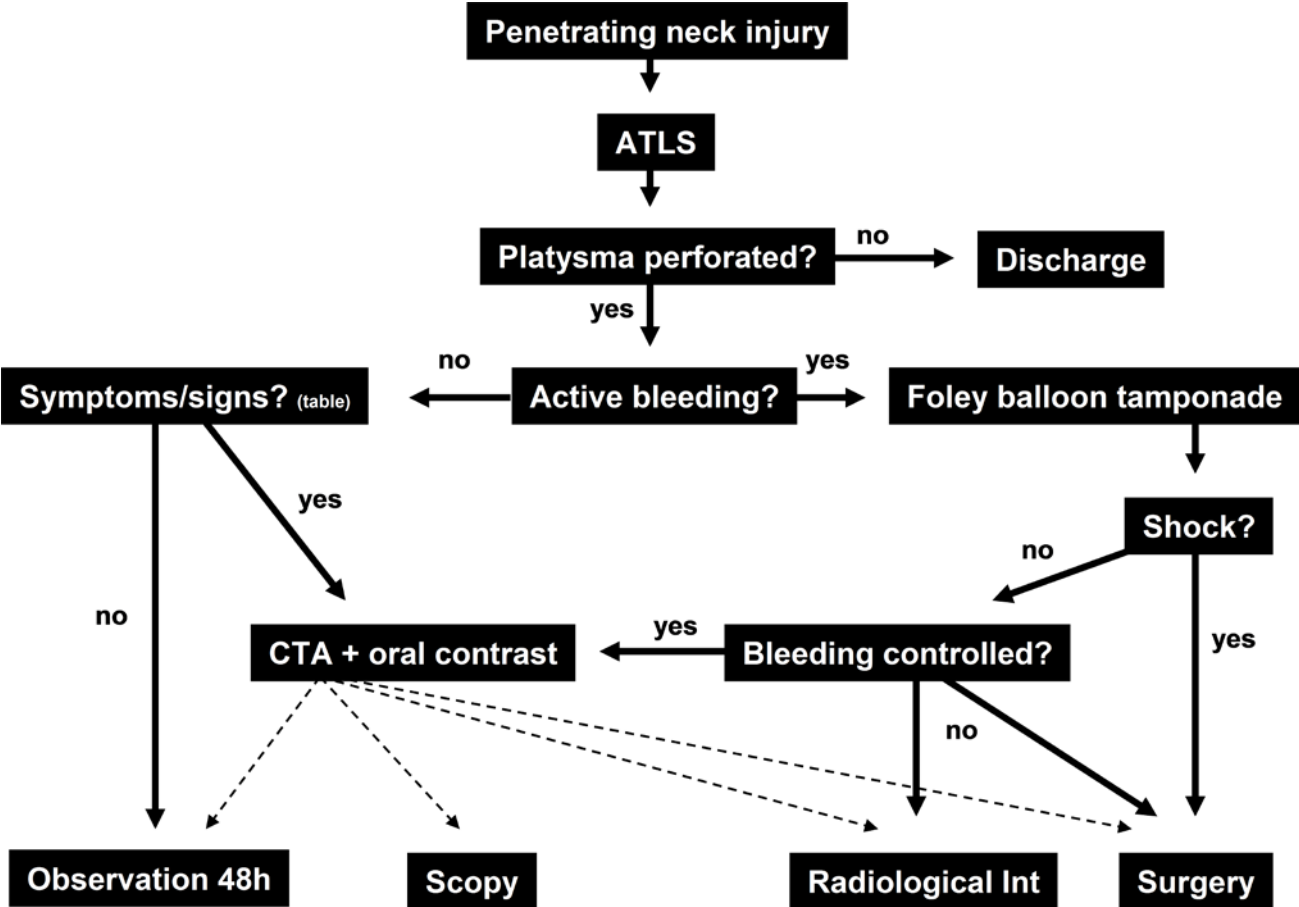
The neck is divided in a posterior triangle and an anterior triangle. The anterior triangle is subsequently divided into three horizontal zones.

Figure 2. Foley Catheter Balloon Tamponade



A Foley catheter is introduced into the bleeding neck wound following the wound tract. The balloon is inflated with 10-15 ml of water or until resistance is felt. The catheter is either clamped to prevent bleeding through the lumen. The neck wound is sutured around the catheter. Continuing bleeding around the catheter is an indication to proceed to surgery.

Figure 3. Algorithm for initial management of patients with penetrating neck injury



ATLS = Advanced Trauma Life Support; CTA = Computerized tomography angiography