

Prediction of Improvement of Contractile Function in Patients With Ischemic Ventricular Dysfunction After Revascularization by Fluorine-18 Fluorodeoxyglucose Single-Photon Emission Computed Tomography

JEROEN J. BAX, MD, JAN H. CORNEL, MD,* FRANS C. VISSER, MD,†
PAOLO M. FIORETTI, MD, FACC,‡ ARTHUR VAN LINGEN, PhD,† JOHANNES M. HUITINK, MD,†
OTTO KAMP, MD,† FRANCISCA NIJLAND, MD,† JOS R. T. C. ROELANDT, MD, FACC,‡
CEES A. VISSER, MD, FACC†

Leiden, Alkmaar, Amsterdam and Rotterdam, The Netherlands

Objectives. We evaluated the use of fluorine-18 fluorodeoxyglucose (FDG) and single-photon emission computed tomography (SPECT) to predict improvement of left ventricular ejection fraction (LVEF) after revascularization.

Background. FDG SPECT has recently been proposed for assessment of myocardial viability. However, FDG SPECT still awaits validation in terms of predicting improvement of contractile function after revascularization in patients with poor left ventricular (LV) function.

Methods. Fifty-five patients with contractile dysfunction (including 22 with LVEF <30%) underwent FDG SPECT during hyperinsulinemic glucose clamping and early thallium-201 SPECT (to assess perfusion). Improvement of LV function was evaluated 3 months after revascularization with echocardiography and radionuclide ventriculography.

Results. The 55 patients were arbitrarily classified into two groups: 19 with three or more viable, dysfunctional segments on

FDG SPECT and 36 with less than three viable, dysfunctional segments. LVEF increased significantly in the first group, from $28 \pm 8\%$ (mean \pm SD) before to $35 \pm 9\%$ ($p < 0.01$) after revascularization. In the second group, LVEF remained unchanged after revascularization ($45 \pm 14\%$ vs. $44 \pm 14\%$, $p = \text{NS}$). The 22 patients with severely depressed LV function were similarly classified into two groups: 14 with three or more viable segments on FDG SPECT in whom LVEF improved significantly ($25 \pm 6\%$ vs. $32 \pm 6\%$) and 8 with less than three viable segments in whom LVEF remained unchanged ($24 \pm 6\%$ vs. $25 \pm 6\%$).

Conclusions. This study shows that FDG SPECT can identify patients in whom LV function improves after revascularization. Because SPECT is widely available, this technique may contribute to more routine use of FDG for determination of viability.

(J Am Coll Cardiol 1997;30:377-83)

©1997 by the American College of Cardiology

Heart failure is an increasing problem in cardiology because of its increasing incidence over the past decade. In patients with extensive coronary artery disease, impaired left ventricular (LV) function is not necessarily an irreversible process because recovery of LV function after revascularization has been demonstrated, even in asynergic myocardial regions. In the early 1970s, different methods (including inotropic catecholamine infusions [1], nitroglycerin [2] and post-extrasystolic potentiation [3]) were proposed for identifying viable myocar-

dium and predicting functional recovery. The concepts of hibernation and repetitive stunning were introduced to explain such situations of reversibly impaired LV function (4,5). Rahimtoola (4) initially described hibernation as a chronic state of myocardial hypoperfusion accompanied by chronic contractile dysfunction that can be reversed after revascularization. More recently, this hypothesis was challenged by Vanoverschelde et al. (5) who pointed out that many segments with chronic contractile dysfunction that improved after revascularization had (near-) normal perfusion. They stated that repeated attacks of ischemia may also result in chronic contractile dysfunction, whereas rest perfusion may be normal in such cases.

Currently, positron emission tomography (PET) with fluorine-18 fluorodeoxyglucose (FDG) is considered one of the most accurate techniques for identifying viable myocardium (6,7). Reversibility of regional wall motion abnormalities after revascularization was demonstrated in regions with normal perfusion (indicating repetitive stunning [5]) or in hypoper-

From the Department of Cardiology, University Hospital Leiden, Leiden; *Department of Cardiology, Medical Center Alkmaar, Alkmaar; †Department of Cardiology/Nuclear Medicine, Free University Hospital Amsterdam, Amsterdam; and ‡Department of Cardiology, University Hospital Rotterdam, Rotterdam, The Netherlands. This study received the Mallinckrodt Benelux Research Award from Mallinckrodt Medical, Saint Louis, Missouri.

Manuscript received July 25, 1996; revised manuscript received March 31, 1997, accepted April 21, 1997.

Address for correspondence: Dr. Jeroen J. Bax, Department of Cardiology, University Hospital Leiden, Rijnsburgerweg 10, 2333 AA Leiden, The Netherlands.

Abbreviations and Acronyms

CABG	= coronary artery bypass graft surgery
FDG	= fluorine-18 fluorodeoxyglucose
LV	= left ventricle, left ventricular
LVEF	= left ventricular ejection fraction
PET	= positron emission tomography (tomographic)
PTCA	= percutaneous transluminal coronary angioplasty
SPECT	= single-photon emission computed tomography (tomographic)
Tl-201	= thallium-201

fused regions with relatively preserved FDG uptake (flow-metabolism mismatch, representing hibernating myocardium [4]), whereas regions with hypoperfusion and decreased FDG uptake (flow-metabolism match, indicating scar tissue) showed no recovery of function (8-18).

In addition, improvement of global LV function was seen in patients with viable myocardium on FDG PET (15,17,18). However, the majority of these studies included patients with only mild to moderate depressed LV function, whereas preoperative evaluation of viability bears most clinical relevance in patients with severely depressed LV function. In these patients, the perioperative risk for complications is high (19), but the potential gain in terms of prognosis is also high (20).

Relatively few PET devices are available for clinical use. Therefore, several laboratories have evaluated the feasibility of imaging myocardial FDG uptake with single-photon emission computed tomography (SPECT) using 511-keV collimators (21-26). However, no data are available on the diagnostic value of FDG SPECT for predicting functional recovery after revascularization. Hence, the aim of the present study was to evaluate whether FDG SPECT can predict improvement of regional and global LV function after revascularization. In addition, a subset of patients with poor LV function (LV ejection fraction [LVEF] <30%) were included.

Methods

Study patients. We prospectively studied 55 consecutive patients referred for coronary revascularization, 10 of whom had been included in a previous report (23) comparing FDG SPECT with low dose dobutamine echocardiography and thallium-201 (Tl-201) stress-reinjection. All patients had regional wall motion abnormalities at rest observed on ventriculography and two-dimensional echocardiography. Forty-five patients (82%) underwent coronary artery bypass graft surgery (CABG), and 10 (18%) had percutaneous transluminal coronary angioplasty (PTCA). The SPECT studies were performed in patients already scheduled for revascularization, and the results did not influence patient management.

Study protocol. All patients underwent early rest Tl-201 SPECT to evaluate myocardial perfusion, followed by FDG SPECT after placement of a hyperinsulinemic euglycemic clamp. Improvement of regional wall motion was determined from serial rest echocardiograms before and 3 months after

revascularization. To assess improvement of LVEF, 18 patients had radionuclide ventriculography before and after revascularization; in the remaining 37 patients, LVEF was calculated from the echocardiograms.

The SPECT studies were performed on the same day. Cardiac medication was continued during the study. Medication included beta-adrenergic blocking agents (n = 31), angiotensin-converting enzyme inhibitors (n = 31), nitrates (n = 37), calcium antagonists (n = 17), diuretic drugs (n = 13) and aspirin (n = 49). All patients were clinically stable during the study; none had unstable angina or myocardial infarction between revascularization and the scintigraphic studies or after the intervention. Each patient gave informed consent to the study protocol, which was approved by the ethics committees of the participating hospitals.

Tl-201 SPECT. To delineate regional myocardial perfusion, rest Tl-201 SPECT was performed as described previously (27). Briefly, a single dose of 111-MBq (3 mCi) Tl-201 chloride was administered intravenously at rest. Imaging was started 10 to 15 min after injection. A large field of view rotating dual-head gamma camera (ADAC Laboratories) was used, equipped with a low energy high resolution collimator. The energy was centered on the 89-keV photon peak with a 20% window and on the 167-keV photon peak with a 20% window. The dual-head gamma camera system was rotated over 360°, collecting 64 views for 30 s each. Data were stored in a 64 × 64, 16-bit matrix. From the raw scintigraphic data, 6-mm thick (1 pixel) transaxial slices were reconstructed by filtered backprojection using a Hanning filter (cutoff frequency 0.63 cycle/cm). Slices were not corrected for attenuation. Further reconstruction yielded long- and short-axis projections perpendicular to the heart axis.

FDG SPECT. After an overnight fast, subjects underwent a placement of hyperinsulinemic glucose clamp (28) to standardize metabolic conditions throughout FDG SPECT (see Hyperinsulinemic euglycemic clamping). FDG (185 MBq [5 mCi]) was injected after 60 min of clamping; another 45 min was allowed for myocardial FDG uptake (29,30). Data acquisition was performed with the same camera system as described for Tl-201, using the same acquisition time per projection (30 s) and the same matrix (64 × 64, 16 bit). For the detection of 511-keV photons, specially designed collimators were used (van Mullekom, Nuclear Fields, Boxmeer, The Netherlands) (31). Reconstruction of data was also identical to that for Tl-201 SPECT.

Hyperinsulinemic euglycemic clamping. For this purpose, two catheters were placed in the left and right antecubital veins. One catheter was used for separate infusions of glucose and insulin. The contralateral catheter was used for the administration of FDG and to draw plasma samples to monitor glucose levels. Insulin (Human Velosulin, Novo Nordisk, 100 IU/ml) in 0.65% sodium chloride was used. To prevent adhesion of insulin to the infusion system, 3.8 ml of human albumin (20% Human Albumin, CLB) was added. The insulin infusion rate was 100 mU/kg per h and was not changed throughout clamping to achieve a hyperinsulinemic state.

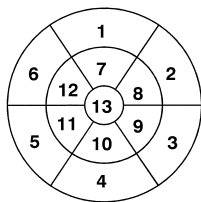


Figure 1. Thirteen-segment model used for SPECT and echocardiography: 1 = basal anterior; 2 = basal anterolateral; 3 = basal posterolateral; 4 = basal inferior; 5 = basal inferoseptal; 6 = basal antero-septal; 7 = distal anterior; 8 = distal anterolateral; 9 = distal posterolateral; 10 = distal inferior; 11 = distal inferoseptal; 12 = distal antero-septal; 13 = apex.

Glucose infusion (500 ml of 20% glucose with 20 ml of 14.9% potassium chloride to prevent hypokalemia) was started at a rate of 6 mg/kg body weight per min and was adjusted every 10 min to maintain normoglycemia. This was done according to acutely determined plasma glucose levels.

Image analysis. The FDG and TI-201 SPECT data were analyzed as described previously (23). Briefly, circumferential profiles (60 radii, highest pixel activity/radius) from the available FDG data, and TI-201 short-axis slices were generated (after alignment of the TI-201 and FDG short-axis slices) and displayed in a polar map format. The polar maps were divided into 13 segments, as demonstrated in Figure 1 (for exact comparison with the 13 echocardiographic segments, see below).

The segment with the highest TI-201 uptake was considered *normal*. The activity of this area was normalized to the mean activity of the same area of a normal database (obtained in nine normal male subjects, mean [±SD] age 43 ± 10 years [21]), and all other polar map data were adjusted correspondingly. The area of normal perfusion was projected on the FDG polar map, and the same normalization procedure was followed. For this purpose a database of FDG activities in the aforementioned normal subjects was used (21). Segments with a TI-201 activity <2 SD below the normal reference value were considered abnormal. TI-201 and FDG activities were expressed as percentage of the corresponding normal reference values.

Definition of myocardial viability. A segment was considered *viable* if the perfusion was normal, or if the FDG uptake was relatively increased (>7%, as previously described [23]) in a perfusion defect (flow-metabolism mismatch). Segments with a perfusion defect and concordantly decreased FDG uptake (flow-metabolism match) were considered *necrotic*.

Assessment of improvement of regional dysfunction. Regional wall motion was assessed by rest echocardiography before and after revascularization. Echocardiographic images were recorded on videotape. Four standard views of the LV were obtained: parasternal long- and short-axis views and apical two- and four-chamber views. The images were reviewed off-line, and consensus was achieved by two observers (J.H.C., P.M.F.) unaware of the SPECT data. For exact alignment of the echocardiographic and SPECT data, the LV was divided

into 13 comparable segments, as previously reported (23): one apical segment, six distal segments (anterior, anterolateral, inferolateral, inferior, inferoseptal and antero-septal) and six basal segments (comparable to the distal segments) were identified (see also Fig. 1). For the echocardiographic data, these segments were derived from the parasternal long- and short-axis views; for the SPECT data, they were derived from the polar maps.

Both inward wall motion and wall thickening were analyzed. Each segment was assigned a wall motion score of 0 to 3: normal = 0; hypokinetic = 1 (decreased endocardial excursion and systolic wall thickening); akinetic = 2 (absence of endocardial excursion and systolic wall thickening); and dyskinetic = 3 (paradoxical outward movement in systole). The preinterventional and postinterventional images were compared on a segmental basis. Postinterventional improvement of regional wall motion was considered present if systolic thickening (hypokinesia or normokinesia) was detected in a segment that was akinetic or dyskinetic at baseline or if normal wall motion was detected in segments that were hypokinetic at baseline. Only segments that were successfully revascularized were analyzed on the basis of a review of the CABG and PTCA reports. Wall thickening was primarily utilized for the classification of septal wall motion, thereby preventing the problem of paradoxical septal motion after CABG (32). Previous results from our laboratory (33) showed a high interobserver (84%) and intraobserver (87%) concordance of rest wall motion analysis.

Assessment of improvement of global ventricular function. LVEF (before and after revascularization) was assessed by radionuclide ventriculography in 18 patients. Radionuclide ventriculography was performed at rest with the patient in the supine position after administration of 740 MBq of technetium-99m. Images were acquired with a small field of view gamma camera (Orbiter, Siemens Corp.) oriented in the 45° left anterior oblique position with a 5° to 10° caudal tilt. LVEF was calculated from the 45° left anterior oblique view by an automated technique. In 37 patients, LVEF was calculated by cross-sectional echocardiography utilizing the apical biplanar Simpson's technique (34). Improvement of global function after revascularization was defined arbitrarily as an increase in LVEF >5%.

Statistical analysis. Results are expressed as mean value ± SD. Patient data were compared using the Student *t* test for paired and unpaired data when appropriate. Comparison of proportions was performed using chi-square analysis. A *p* value <0.05 was considered significant.

Results

Patient characteristics. The clinical characteristics of the study patients are presented in Table 1. Fifty-one patients (93%) had a previous infarction. The time interval of infarction to the SPECT study was >1 month in 93% of patients. Eight patients had diabetes mellitus type II that was well regulated with oral hypoglycemic agents. All patients had significant coronary artery disease on angiography (>50%

Table 1. Clinical Characteristics of 55 Study Patients

Male/female	49/6
Age (yr)	62 ± 10
Previous infarction	51 (93%)
Q wave on ECG	36 (71%)
Anterior	18 (50%)
Inferior	18 (50%)
Angina, NYHA class	2.2 ± 0.8
Functional NYHA class	1.9 ± 0.9
Coronary disease	
1-vessel disease	7 (13%)
2-vessel disease	11 (20%)
3-vessel disease	37 (67%)
LVEF (%)	39 ± 14
Previous CABG	11 (20%)
Previous PTCA	4 (7%)

Data presented are mean value ± SD or number (%) of patients. CABG = coronary artery bypass graft surgery; ECG = electrocardiogram; LVEF = left ventricular ejection fraction; NYHA = New York Heart Association; PTCA = percutaneous transluminal coronary angioplasty.

reduction in lumen diameter of at least one major epicardial coronary artery). They had an average of 2.5 ± 0.7 stenosed vessels. The 55 patients had a mean LVEF of $39 \pm 14\%$, 22 of whom had an LVEF $<30\%$ (mean LVEF $24 \pm 6\%$).

Baseline characteristics. Of the 715 segments analyzed by echocardiography, 410 (57%) had normal and 305 (43%) abnormal wall motion before revascularization. The mean number of abnormal segments/patient was 5.5 ± 3.1 . Twenty-four segments were excluded from analysis because of inadequate revascularization (based on review of the PTCA/CABG reports). Thus, 281 dysfunctional segments were analyzed: 128 (46%) segments were hypokinetic, and 153 (54%) were akinetic/dyskinetic. Forty-nine (17%) dysfunctional segments had normal perfusion on Tl-201 SPECT.

Prediction of improvement of regional contractile function by FDG SPECT. Using recovery of wall motion abnormalities on echocardiography as the reference standard for the presence of viable tissue, the 281 segments with abnormal wall motion at baseline were classified into two groups: segments with improvement after revascularization (group I, $n = 94$) and segments without improvement (group II, $n = 187$). In group I the segmental wall motion score decreased from 1.59 ± 0.49

Figure 2. Two short-axis slices from a patient with a flow-metabolism match. Both Tl-201 (left) and FDG uptake (right) are virtually absent in the anterior wall. On rest echocardiography, the anterior wall was akinetic before revascularization and did not improve in wall motion after intervention. Rest LVEF was 24% before and 22% after revascularization.

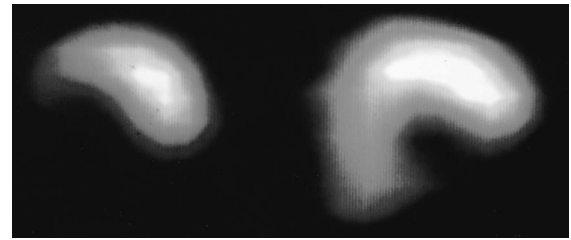
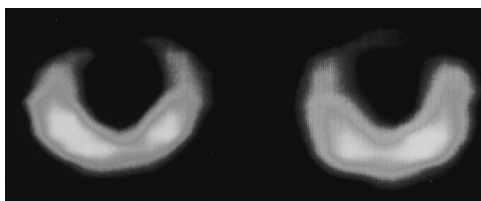


Figure 3. Two short-axis slices from a patient with a flow-metabolism mismatch. In the inferoseptal region, Tl-201 uptake (left) is decreased, with preserved FDG uptake (right) in the septal region. Rest echocardiography revealed akinesia in the inferior and septal regions before revascularization. After intervention, wall motion improved in the septal region. LVEF improved from 29% to 37% after revascularization.

to 0.49 ± 0.50 , whereas in group II it remained unchanged (by definition).

Twenty-eight of the segments in group I had normal perfusion, 52 had a flow-metabolism mismatch, and 14 had a match. In group II, 21 segments had normal perfusion, 46 had a mismatch, and 120 a match ($p < 0.01$ vs. group I). The sensitivity and specificity were thus 85% and 75%, with a positive and negative predictive value of 63% and 91%, respectively. Examples of two patients, one with a match and one with a mismatch, are demonstrated in Figures 2 and 3.

Prediction of functional recovery in different subgroups.

The sensitivity and specificity for the detection of functional recovery were determined in different subsets of segments (Table 2): 1) The segments were divided according to severity of wall motion abnormalities (hypokinetic vs. akinetic/dyskinetic). In hypokinetic segments, the sensitivity and specificity were 82% and 66%, respectively. In akinetic/dyskinetic segments, the sensitivity and specificity were 87% and 84%, respectively. 2) The segments were classified according to the different myocardial regions. The sensitivity and specificity for the detection of functional recovery in the apical, anterior and lateral regions were 86% and 76%, respectively, whereas in the inferior and septal regions, these values were 84% and 75%,

Table 2. Sensitivity and Specificity of Fluorine-18 Fluorodeoxyglucose Single-Photon Emission Computed Tomography for Predicting Functional Recovery After Revascularization in Different Subsets of Segments

	Sensitivity [% (no. of segs)]	Specificity [% (no. of segs)]
Total group (n = 281)	85 (80/94)	75 (141/187)
Hypokinetic segs (n = 128)	82 (32/39)	66 (59/89)
Akinetic/dyskinetic segs (n = 153)	87 (48/55)	84 (82/98)
Ant/apic/lat segs (n = 139)	86 (44/51)	76 (67/88)
Inf/sept segs (n = 142)	84 (36/43)	75 (74/99)
Segs of pts with LVEF $\geq 30\%$ (n = 109)	80 (33/41)	81 (55/68)
Segs of pts with LVEF $<30\%$ (n = 172)	89 (47/53)	72 (86/119)

Ant = anterior; apic = apical; Inf = inferior; lat = lateral; LVEF = left ventricular ejection fraction; pts = patients; segs = segments; sept = septal.

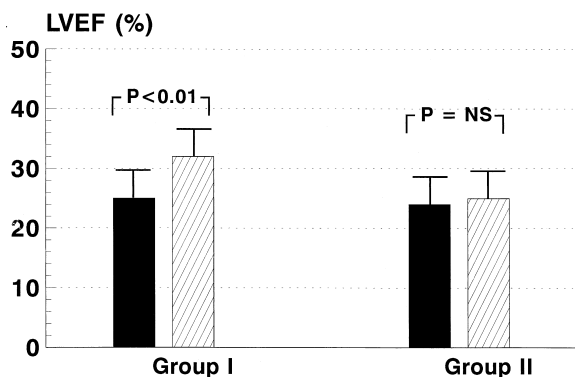


Figure 4. LVEF before (solid bars) and after revascularization (hatched bars) in patients with LVEF <30%. In patients (n = 14, group I) with three or more viable segments on FDG SPECT, LVEF increased from 25 ± 6% to 32 ± 6% (p < 0.01). Conversely, in patients (n = 8, group II) with two or less viable segments, LVEF remained unchanged (24 ± 6% vs. 25 ± 6%, p = NS).

respectively. 3) The segments were classified according to LVEF (LVEF ≥30% or <30%; 22 patients had LVEF <30%). The sensitivity and specificity in segments of patients with LVEF ≥30% were 80% and 81%, respectively. In the segments of patients with LVEF <30%, these values were 89% and 72%, respectively.

Effect of revascularization on global LV function. The patients were arbitrarily classified into two groups: group A included 19 patients with three or more viable, dysfunctional segments on FDG SPECT; group B included 36 patients with two or less viable, dysfunctional segments.

LVEF increased significantly in group A, from 28 ± 8% before to 35 ± 9% (p < 0.01) after revascularization. In group B, LVEF remained unchanged after revascularization (45 ± 14% vs. 44 ± 14%, p = NS). We then focused on the patients (n = 22) with LVEF <30% because improvement of LVEF has the most clinical relevance in this patient group (Fig. 4). In patients (n = 14) with three or more viable segments, LVEF improved significantly, from 25 ± 6% to 32 ± 6% (p < 0.01).

Conversely, in patients (n = 8) with two or less viable segments, LVEF remained unchanged (24 ± 6% vs. 25 ± 6%, p = NS). When an improvement of LVEF >5% was considered significant, FDG SPECT correctly identified 12 (100%) of 12 patients with improved LVEF as having enough viable myocardium (three or more viable segments) to allow improvement of global LV function. Similarly, 8 (80%) of 10 patients with no improvement in LVEF were identified as having no or too little viable myocardium (two or less viable segments) to allow recovery of global LV function.

Discussion

This study expands the earlier studies with FDG SPECT (21-26) and demonstrates that semiquantitative FDG SPECT can predict reversibility of contractile function after revascularization. Significant improvement of global LV function was observed in patients with three or more viable segments on FDG SPECT.

Findings of the present study. In the present study, 33% of segments with abnormal wall motion improved after revascularization. The segments that improved in function demonstrated either normal perfusion, possibly representing repetitive stunning (5), or a flow-metabolism mismatch, most likely representing hibernation (4). The majority of segments without functional improvement showed a flow-metabolism match, suggesting scar tissue (6,7). The sensitivity and specificity were 85% and 75%, respectively, with a positive and negative predictive value of 63% and 91%, respectively. The results obtained with FDG SPECT are in line with previous results obtained with FDG PET. Reanalysis of the available data on FDG PET predicting functional recovery after revascularization showed sensitivities ranging from 71% to 100% (weighted mean 88%) and specificities ranging from 38% to 86% (weighted mean 72%) (Table 3) (8-16).

Table 3 also shows that the majority of the studies did not include many patients with severely depressed LV function. In the present study, 22 patients with poor LVEF were included;

Table 3. Sensitivity and Specificity of Fluorine-18 Fluorodeoxyglucose Positron Emission Tomography for Detecting Improvement in Regional Contractile Function After Revascularization*

Study (ref no.)	No. of Pts	Mean (±SD) LVEF (%)	Sensitivity [% (no. of segs)]	Specificity [% (no. of segs)]
Marwick et al. (8)	16	NA	71 (25/35)	76 (38/50)
Tamaki et al. (9)	20	NA	78 (18/23)	78 (18/23)
Gropler et al. (10)	34	NA	83 (38/46)	50 (35/70)
Tamaki et al. (11)	43	41 (NA)	88 (45/51)	82 (65/79)
Knuuti et al. (12)	43	53 (±11)	92 (23/25)	85 (50/59)
Lucignani et al. (13)	14	38 (±5)	93 (37/40)	86 (12/14)
Carrel et al. (14)	23	34 (±14)	94 (16/17)	50 (3/6)
Tillisch et al. (15)	17	32 (±14)	95 (35/37)	80 (24/30)
Tamaki et al. (16)	11	NA	100 (40/40)	38 (6/16)
Weighted mean			88 (277/314)	72 (251/347)

*Data were obtained in nine studies with a total of 221 patients undergoing revascularization (based on reanalysis of data from references 8 to 16). NA = not available; ref = reference; other abbreviations as in Table 2.

the sensitivity and specificity of FDG SPECT were not different in these patients, in whom prediction of functional recovery has the most clinical relevance.

Another important finding of this study was that the patients with three or more dysfunctional but viable segments on FDG SPECT improved in global function. These findings were even more dramatic in the group of patients with LVEF <30%. This finding corroborates previous data (15,17,18) and emphasizes that a substantial amount of viable myocardium needs to be present to establish improvement of global LV function after revascularization.

Methodologic considerations. In this study, early rest Tl-201 SPECT was used to measure regional perfusion because regional FDG uptake should be compared with regional perfusion. Melin and Becker (27) demonstrated that initial myocardial uptake of Tl-201 was proportional to regional perfusion (determined with microspheres), even under ischemic conditions.

The FDG SPECT study was performed during hyperinsulinemic euglycemic clamping. The clamping technique results in superior image quality (35), particularly in patients with diabetes mellitus (36). In addition, the clamping technique minimizes regional inhomogeneity in myocardial FDG uptake (37). Moreover, Hariharan et al. (38) recently emphasized that uptake and retention of FDG in the myocardium is linearly related to glucose utilization only under steady state conditions, as can be obtained by clamping.

Viability was assessed by comparing regional perfusion with FDG uptake. However, Tl-201 and FDG have different photon energies, which may lead to differences in attenuation, especially in the inferoseptal region of the myocardium. However, in a study performed in normal subjects (21), it was shown that no differences between tracer activities occurred in the different regions of the myocardium. Moreover, in the present study we demonstrated that sensitivity and specificity for the detection of recovery were comparable in the anterior, lateral and apical regions versus the inferior and septal regions. Both the previous study (21) and the present one suggest that photon differences have limited impact on the diagnostic accuracy.

Limitations of the study. The echocardiographic data were analyzed visually, whereas the SPECT data were analyzed semiquantitatively. Measuring systolic wall thickening quantitatively with magnetic resonance imaging may allow more precise comparison between contractile function and SPECT data (39).

We divided the myocardium into 13 comparable segments, both on echocardiography and SPECT; nevertheless, some misalignment between the two techniques may have affected the diagnostic accuracy of FDG/Tl-201 SPECT in the prediction of functional recovery.

Several aspects of our study may have influenced the sensitivity and specificity of FDG/Tl-201 SPECT for detecting improvement after revascularization. We did not perform angiography or some form of stress testing after the intervention to assess adequate revascularization. Reocclusion may

have prohibited some viable segments to recover and may have influenced the results.

Functional follow-up was performed 3 months after the revascularization; some viable segments may need more time to recover after revascularization. However, the optimal moment for assessing functional recovery is still controversial; La Canna et al. (40) showed immediate recovery after revascularization, whereas Vanoverschelde et al. (41) suggested that a longer time interval is needed for recovery of some viable segments.

We compared FDG SPECT with rest perfusion as assessed with rest Tl-201 SPECT. The early rest image was used to allow assessment of perfusion to discriminate between flow-metabolism matches and mismatches. Other studies (42-44) have shown that Tl-201 rest-redistribution imaging can also identify viable myocardium. Therefore, future studies should be performed to compare FDG SPECT with Tl-201 rest-redistribution to establish the exact merits of both techniques in the prediction of functional recovery after revascularization.

In the present study we reported on the diagnostic accuracy of FDG SPECT to assess improvement of both regional and global LV function. For the individual patient, improvement of global function is more important than improvement of regional function. Moreover, the segments within one patient are not independent, possibly influencing the results. However, to allow comparison with published reports on FDG PET (to compare the relative merits of FDG SPECT and FDG PET in the prediction of functional recovery after revascularization), we included the sensitivity/specificity of FDG SPECT to predict improvement of regional function.

Clinical implications and conclusions. The finding that FDG SPECT can predict improvement of LV function after a revascularization procedure has important clinical implications, especially in patients with severe LV dysfunction. These patients have a poor long-term survival on medical therapy, which may improve after surgical revascularization (20), but also have high surgical risks (19). In the present study we demonstrated that in patients with three or more viable segments on FDG SPECT, LVEF increased significantly, whereas LVEF remained unchanged in patients with less than three viable segments on FDG SPECT. Therefore, the detection of dysfunctional but viable myocardium (which is likely to recover after revascularization) with FDG SPECT may help to identify patients who will benefit most from a revascularization procedure.

At present, FDG PET is considered one of the most accurate techniques for assessing myocardial viability. However, PET is not widely available for routine clinical use. FDG SPECT may contribute to a more routine use of FDG imaging for viability studies, provided that there is routine availability of 511-keV collimators and optimized distribution of FDG. Additional studies comparing FDG SPECT with the other radionuclide techniques (Tl-201 and Tc-99m sestamibi imaging) and stress-echocardiography are needed to establish the relative merits of these techniques in the prediction of functional recovery.

References

1. Horn RH, Teichholz LE, Cohn PF, Herman MV, Gorlin R. Augmentation of left ventricular contraction pattern in coronary artery disease by an inotropic catecholamine. The epinephrine ventriculogram. *Circulation* 1974;49:1063-71.
2. Helfant RH, Pine R, Meister SG, Feldman MS, Trout RG, Banka VS. Nitroglycerin to unmask reversible asynergy: correlation with postcoronary bypass ventriculography. *Circulation* 1974;50:108-13.
3. Dyke SH, Cohn PF, Gorlin R, Sonnenblick EH. Detection of residual myocardial function in coronary artery disease using post-extra systolic potentiation. *Circulation* 1974;50:694-9.
4. Rahimtoola SH. The hibernating myocardium. *Am Heart J* 1989;117:211-21.
5. Vanoverschelde J-L, Wijns W, Depre C, et al. Mechanisms of chronic regional posts ischemic dysfunction in humans: new insights from the study of noninfarcted collateral-dependent myocardium. *Circulation* 1993;87:1513-23.
6. Schwaiger M, Hicks R. The clinical role of metabolic imaging of the heart by positron emission tomography. *J Nucl Med* 1991;32:565-78.
7. Schelbert HR. Positron emission tomography for the assessment of myocardial viability. *Circulation* 1991;84 Suppl I:122-31.
8. Marwick TH, MacIntyre WJ, Lafont A, Nemecek JJ, Salcedo EE. Metabolic responses of hibernating and infarcted myocardium to revascularization. *Circulation* 1992;85:1347-53.
9. Tamaki N, Yonekura Y, Yamashita K, et al. Positron emission tomography using fluorine-18 deoxyglucose in evaluation of coronary artery bypass grafting. *Am J Cardiol* 1989;64:860-5.
10. Gropler RJ, Geltman EM, Sampathkumaran K, et al. Comparison of carbon-11-acetate with fluorine-18-fluorodeoxyglucose for delineating viable myocardium by positron emission tomography. *J Am Coll Cardiol* 1993;22:1587-97.
11. Tamaki N, Kawamoto M, Tadamura E, et al. Prediction of reversible ischemia after revascularization: perfusion and metabolic studies with positron emission tomography. *Circulation* 1995;91:1697-705.
12. Knuuti MJ, Saraste M, Nuutila P, et al. Myocardial viability: fluorine-18-deoxyglucose positron emission tomography in prediction of wall motion recovery after revascularization. *Am Heart J* 1994;127:785-96.
13. Lucignani G, Paolini G, Landoni C, et al. Presurgical identification of hibernating myocardium by combined use of technetium-99m hexakis 2-methoxyisobutylisonitrile SPECT and fluorine-18 fluoro-2-deoxy-D-glucose positron emission tomography in patients with coronary artery disease. *Eur J Nucl Med* 1992;19:874-81.
14. Carrel T, Jenni R, Haubold-Reuter S, Von Schulthess G, Pasic M, Turina M. Improvement of severely reduced left ventricular function after surgical revascularization in patients with preoperative myocardial infarction. *Eur J Cardiothorac Surg* 1992;6:479-84.
15. Tillisch J, Brunken R, Marshall R, et al. Reversibility of cardiac wall-motion abnormalities predicted by positron tomography. *N Engl J Med* 1986;314:884-8.
16. Tamaki N, Ohtani H, Yamashita K, et al. Metabolic activity in the areas of new fill-in after thallium-201 reinjection: comparison with positron emission tomography using fluorine-18-deoxyglucose. *J Nucl Med* 1991;32:673-8.
17. Maes A, Flameng W, Nuyts J, et al. Histological alterations in chronically hypoperfused myocardium: correlation with PET findings. *Circulation* 1994;90:735-45.
18. Vom Dahl J, Eitzman DT, Al-Aouar ZR, et al. Relation of regional function, perfusion and metabolism in patients with advanced coronary artery disease undergoing surgical revascularization. *Circulation* 1994;90:2356-66.
19. Mickleborough LL, Maruyama H, Takagi Y, et al. Results of revascularization in patients with severe left ventricular dysfunction. *Circulation* 1995;92 Suppl II:73-9.
20. Alderman EL, Fisher LD, Litwin P, et al. Results of coronary artery surgery in patients with poor left ventricular function (CASS). *Circulation* 1983;68:785-95.
21. Bax JJ, Visser FC, van Lingen A, et al. Relation between myocardial uptake of thallium-201 chloride and F18-fluorodeoxyglucose imaged with SPECT in normal individuals. *Eur J Nucl Med* 1995;22:56-60.
22. Delbeke D, Videlefsky S, Patton JA, et al. Rest myocardial perfusion/metabolism imaging using simultaneous dual-isotope acquisition SPECT with technetium-99m-MIBI/fluorine-18-FDG. *J Nucl Med* 1995;36:2110-9.
23. Bax JJ, Cornel JH, Visser FC, et al. Prediction of recovery of myocardial dysfunction following revascularization; Comparison of F18-fluorodeoxyglucose/thallium-201 single photon emission computed tomography, thallium-201 stress-reinjection single photon emission computed tomography and dobutamine echocardiography. *J Am Coll Cardiol* 1996;28:558-65.
24. Martin WH, Delbeke D, Patton JA, et al. FDG-SPECT: correlation with FDG-PET. *J Nucl Med* 1995;36:988-95.
25. Burt RW, Perkins OW, Oppenheim BE, et al. Direct comparison of fluorine-18-FDG SPECT, fluorine-18-FDG PET and rest thallium-201 SPECT for the detection of myocardial viability. *J Nucl Med* 1995;36:176-9.
26. Sandler MP, Videlefsky S, Delbeke D, et al. Evaluation of myocardial ischemia using a rest metabolism/stress perfusion protocol with fluorine-18 deoxyglucose/technetium-99m MIBI and dual-isotope simultaneous-acquisition single-photon emission computed tomography. *J Am Coll Cardiol* 1995;26:870-88.
27. Melin JA, Becker LC. Quantitative relationship between global left ventricular thallium uptake and blood flow: effects of propranolol, ouabain, dipyridamole and coronary artery occlusion. *J Nucl Med* 1986;27:641-52.
28. DeFronzo RA, Tobin JD, Andres R. Glucose clamp technique: a method for quantifying insulin secretion and resistance. *Am J Physiol* 1979;237:E214-23.
29. Phelps ME, Hoffman EJ, Selin C, et al. Investigation of [18F]2-fluoro-2-deoxyglucose for the measure of myocardial glucose metabolism. *J Nucl Med* 1978;19:1311-9.
30. Gallagher BM, Fowler JS, Gutterson NI, et al. Metabolic trapping as a principle of radiopharmaceutical design: some factors responsible for the biodistribution of [18F] 2-deoxy-2-fluoro-D-glucose. *J Nucl Med* 1978;19:1154-61.
31. Van Lingen A, Huijgens PC, Visser FC, et al. Performance characteristics of a 511-keV collimator for imaging positron emitters with a standard gamma-camera. *Eur J Nucl Med* 1992;19:315-21.
32. Righetti A, Crawford MH, O'Rourke RA, Schelbert H, Daily PD, Ross J Jr. Interventricular septal motion and left ventricular function after coronary bypass surgery: evaluation with echocardiography and radionuclide ventriculography. *Am J Cardiol* 1977;39:372-7.
33. Arnese M, Cornel JH, Salustri A, et al. Prediction of improvement of regional left ventricular function after surgical revascularization: a comparison of low-dose dobutamine echocardiography with 201-Tl SPECT. *Circulation* 1995;91:2748-52.
34. Folland ED, Parisi AF, Moynihan PF, Jones DR, Feldman CL, Tow DE. Assessment of left ventricular ejection fraction and volumes by real-time, two dimensional echocardiography: a comparison of cineangiographic and radionuclide techniques. *Circulation* 1979;60:760-6.
35. Knuuti J, Nuutila P, Ruotsalainen U, et al. Euglycemic hyperinsulinemic clamp and oral glucose load in stimulating myocardial glucose utilization during positron emission tomography. *J Nucl Med* 1992;33:1255-62.
36. Vom Dahl J, Herman WH, Hicks RJ, et al. Myocardial glucose uptake in patients with insulin-dependent diabetes mellitus assessed quantitatively by dynamic positron emission tomography. *Circulation* 1993;88:395-404.
37. Hicks RJ, Herman WH, Kalf V, et al. Quantitative evaluation of regional substrate metabolism in the human heart by positron emission tomography. *J Am Coll Cardiol* 1991;18:101-11.
38. Hariharan R, Bray M, Ganim R, Doenst T, Goodwin GW, Taegtmeyer H. Fundamental limitations of [¹⁸F]2-deoxy-2-fluoro-D-glucose for assessing myocardial glucose uptake. *Circulation* 1995;91:2435-44.
39. van Ruge FP, Van der Wall EE, Spanjersberg S, et al. Magnetic resonance imaging during dobutamine stress for detection and localization of coronary artery disease: quantitative wall motion analysis using a modification of the centerline method. *Circulation* 1994;90:127-38.
40. La Canna G, Alfieri O, Giubbini R, Gargano M, Ferrari R, Visioli O. Echocardiography during dobutamine for identification of reversible dysfunction in patients with chronic coronary artery disease. *J Am Coll Cardiol* 1994;23:617-26.
41. Vanoverschelde J-L, Melin JA, Depre C, Borgers M, Dion R, Wijns W. Time-course of functional recovery of hibernating myocardium after coronary revascularization [abstract]. *Circulation* 1994;90 Suppl I:1-378.
42. Dilisizian V, Perrone-Filardi P, Arrighi JA, et al. Concordance and discordance between stress-redistribution-reinjection and rest-redistribution thallium imaging for assessing viable myocardium: comparison with metabolic activity by positron emission tomography. *Circulation* 1993;88:941-52.
43. Ragosta M, Beller GA, Watson DD, Kaul S, Gimple LW. Quantitative planar rest-redistribution ²⁰¹Tl imaging in detection of myocardial viability and prediction of improvement in left ventricular function after coronary bypass surgery in patients with severely depressed left ventricular function. *Circulation* 1993;87:1630-41.
44. Perrone-Filardi P, Pace L, Prastaro M, et al. Assessment of myocardial viability in patients with chronic coronary artery disease: rest-4-hour-24-hour ²⁰¹Tl tomography versus dobutamine echocardiography. *Circulation* 1996;94:2712-9.