

Nasogastric tube syndrome induced by an indwelling long intestinal tube

著者	Sano Naoki , Yamamoto Masayoshi , Nagai Kentaro , Yamada Keiichi, Ohkohchi Nobuhiro
journal or publication title	World journal of gastroenterology
volume	22
number	15
page range	4057-4061
year	2016-04
権利	<p>(C)The Author(s) 2016.</p> <p>This article is an open-access article which was selected by an in-house editor and fully peer-reviewed by external reviewers. It is distributed in accordance with the Creative Commons Attribution Non Commercial (CC BY-NC 4.0) license, which permits others to distribute, remix, adapt, build upon this work non-commercially, and license their derivative works on different terms, provided the original work is properly cited and the use is non-commercial. See:</p> <p>http://creativecommons.org/licenses/by-nc/4.0/</p>
URL	http://hdl.handle.net/2241/00142048

doi: 10.3748/wjg.v22.i15.4057

Nasogastric tube syndrome induced by an indwelling long intestinal tube

Naoki Sano, Masayoshi Yamamoto, Kentaro Nagai, Keiichi Yamada, Nobuhiro Ohkohchi

Naoki Sano, Masayoshi Yamamoto, Kentaro Nagai, Keiichi Yamada, Department of Surgery, Tsukuba Medical Center Hospital, Ibaraki 305-8558, Japan

Naoki Sano, Nobuhiro Ohkohchi, Department of Surgery and Organ Transplantation, Faculty of Medicine, University of Tsukuba, Ibaraki 305-8575, Japan

Author contributions: Sano N, Yamamoto M and Ohkohchi N designed the report; Sano N, Nagai K and Yamada K collected the patient's clinical data; Sano N, Yamamoto M and Ohkohchi N wrote the paper.

Institutional review board statement: This case report was reviewed and approved by the University of Tsukuba Institutional Review Board.

Informed consent statement: Informed consent was obtained from the patient for publication of this case report and any accompanying images.

Conflict-of-interest statement: The authors declare no conflicts of interest.

Open-Access: This article is an open-access article which was selected by an in-house editor and fully peer-reviewed by external reviewers. It is distributed in accordance with the Creative Commons Attribution Non Commercial (CC BY-NC 4.0) license, which permits others to distribute, remix, adapt, build upon this work non-commercially, and license their derivative works on different terms, provided the original work is properly cited and the use is non-commercial. See: <http://creativecommons.org/licenses/by-nc/4.0/>

Correspondence to: Nobuhiro Ohkohchi, MD, PhD, Professor, Department of Surgery and Organ Transplantation, Faculty of Medicine, University of Tsukuba, 1-1-1 Tennodai, Tsukuba, Ibaraki 305-8575, Japan. nokochi3@md.tsukuba.ac.jp
Telephone: +81-29-8533221
Fax: +81-29-8533222

Received: August 27, 2015
Peer-review started: August 31, 2015
First decision: September 29, 2015
Revised: October 14, 2015

Accepted: December 30, 2015
Article in press: December 30, 2015
Published online: April 21, 2016

Abstract

The nasogastric tube (NGT) has become a frequently used device to alleviate gastrointestinal symptoms. Nasogastric tube syndrome (NTS) is an uncommon but potentially life-threatening complication of an indwelling NGT. NTS is characterized by acute upper airway obstruction due to bilateral vocal cord paralysis. We report a case of a 76-year-old man with NTS, induced by an indwelling long intestinal tube. He was admitted to our hospital for treatment of sigmoid colon cancer. He underwent sigmoidectomy to release a bowel obstruction, and had a long intestinal tube inserted to decompress the intestinal tract. He presented acute dyspnea following prolonged intestinal intubation, and bronchoscopy showed bilateral vocal cord paralysis. The NGT was removed immediately, and tracheotomy was performed. The patient was finally discharged in a fully recovered state. NTS be considered in patients complaining of acute upper airway obstruction, not only with a NGT inserted but also with a long intestinal tube.

Key words: Nasogastric tube syndrome; Nasogastric tube; Long intestinal tube; Acute upper airway obstruction; Tracheotomy

© **The Author(s) 2016.** Published by Baishideng Publishing Group Inc. All rights reserved.

Core tip: Nasogastric tube syndrome (NTS) is an uncommon but potentially life-threatening complication of an indwelling nasogastric tube (NGT). NTS is characterized by acute upper airway obstruction due to bilateral vocal cord paralysis. We report a

case of a 76-year-old man with NTS, induced by an indwelling long intestinal tube. He presented acute dyspnea following prolonged intestinal intubation, and bronchoscopy showed bilateral vocal cord paralysis. The NGT was removed immediately, and tracheotomy was performed to establish a safe airway. NTS be considered in patients complaining of acute upper airway obstruction, not only with a NGT inserted but also with a long intestinal tube inserted.

Sano N, Yamamoto M, Nagai K, Yamada K, Ohkohchi N. Nasogastric tube syndrome induced by an indwelling long intestinal tube. *World J Gastroenterol* 2016; 22(15): 4057-4061 Available from: URL: <http://www.wjgnet.com/1007-9327/full/v22/i15/4057.htm> DOI: <http://dx.doi.org/10.3748/wjg.v22.i15.4057>

INTRODUCTION

Nasogastric tube (NGT) is commonly used for a variety of indications since its first description by Hunter in 1790^[1]. Despite extensive adaptation, serious complications have occasionally been reported. Iglauer and Molt first described damage to the larynx due to an indwelling enteric tube in a case series in 1939^[2]. NTS was later formally defined by Sofferan *et al*^[3] in 1990. This syndrome consists of throat pain, the presence of a NGT, and vocal cord abductor dysfunction^[3]. It is encountered only rarely, but it is potentially life threatening.

To our knowledge, in all of the medical literature, a total of 20 case reports (Table 1) and 2 reviews (including the case report described) of NTS have been published through 2014^[3-14]. Of these cases, only one case was induced by indwelling a long intestinal tube^[6].

It is hypothesized that early and adequate investigation of throat pain and hoarseness in patients with an indwelling NGT or a long intestinal tube is critical to the diagnosis and timely management of NTS.

CASE REPORT

A 76-year-old man was admitted to the Tsukuba Medical Center Hospital for the treatment of sigmoid colon cancer. The physiological examination, abdominal X-ray (Figure 1A), and computed tomography (Figure 2) indicated colonic obstruction caused by a tumor in the sigmoid colon. Sigmoidectomy was performed urgently, and a long intestinal tube was placed into the jejunum during surgery for bowel decompression (Figure 1B). Six days after tube placement, the patient developed throat pain, acute inspiratory stridor, and oxygen failure. The long intestinal tube was removed immediately, and the patient was intubated to improve the oxygenation failure. When intubating, post-cricoid ulceration and arytenoid edema were observed.

To improve the laryngeal injury, the patient was extubated two days later. Because wheezing persisted even after extubation, the patient was submitted bronchoscopy, which showed bilateral vocal cord dysfunction. Tracheotomy was performed for dyspnea. Four weeks following tracheotomy, bronchoscopy showed improving bilateral vocal cord paralysis. Finally, the patient recovered one month after the onset of NTS and was discharged with the tracheotomy closed.

DISCUSSION

NGT is one of the most commonly used devices in hospital patient care. Most often, NGT is placed for days to weeks before digestive symptoms become manifest. NTS is a rare but potentially fatal complication of nasogastric intubation, comprising acute upper airway obstruction due to bilateral vocal cord paralysis. However, due to ignorance of this disease, it is believed that there have been fewer cases reported than have actually occurred. Bilateral vocal cord paralysis is the principal sign that has brought this condition to clinical awareness. We experienced an extremely rare case of NTS induced by indwelling a long intestinal tube^[6].

The term NTS was introduced by Sofferan in 1990 to describe the triad of throat pain, nasogastric intubation, and vocal cord paralysis man^[3]. Brousseau *et al*^[8] reported that 71% cases of NTS occurred in men, and 29% of cases occurred in women. Harmon *et al*^[13] reported that this syndrome developed in both children and adults. Brousseau *et al*^[8] also estimated a range of NTS onset from 12 h after intubation to 2 wk after extubation. Time to recovery from respiratory symptoms and vocal cords dysfunction has been reported at 1 d to 3 mo^[3-6,9,10,12,13]. In our case, the symptoms were present 6 d after long intestinal intubation, and a month was required for complete recovery.

Throat pain is an important symptom. Most often, the discomfort is correctly attributed to the NGT, but its significance is usually minimized. Unless the pain is closely followed by stridor, otolaryngologic consultation can be delayed by several days to more than a week after the initial complaint. Odynophagia and referred otalgia are additional symptoms that coexist within the broad framework of this syndrome.

Diabetes mellitus and immunocompromised states have been suggested as risk factors for NTS^[3]. Moreover, time to recovery have been reported to be longer in diabetic patients^[3]. In our case, the patient did not have diabetes mellitus. Because the number of NTS case reports is very small, the risk factors for the disease are currently unclear. It is necessary to accumulate further case reports.

It is important first to diagnose NTS accurately. If it is not suspected at the time of intubation, bronchoscopy might be omitted and the correct

Table 1 Case reports of nasogastric tube syndrome

Author	Year	Age (yr), sex	Tube	Treatment	Outcome
Sofferman <i>et al</i> ^[3]	1990	28, male	NGT	Removal of NGT, tracheotomy	Full recover
Sofferman <i>et al</i> ^[3]	1990	42, male	NGT	Removal of NGT, tracheotomy	Full recover
Sofferman <i>et al</i> ^[3]	1990	36, male	NGT	Removal of NGT, tracheotomy	Death
Sofferman <i>et al</i> ^[3]	1990	45, female	NGT	Removal of NGT, tracheotomy	Full recover
Apostolakis <i>et al</i> ^[4]	2001	77, male	NGT	Removal of NGT, tracheotomy	Not recover
Apostolakis <i>et al</i> ^[4]	2001	73, male	NGT	Removal of NGT, tracheotomy	Full recover
Leclerc <i>et al</i> ^[14]	2002	71, female	NGT	Tracheotomy	Not recover (cricoid necrosis)
Nehru <i>et al</i> ^[5]	2003	60, male	NGT	Removal of NGT, tracheotomy	Full recover
Sanaka <i>et al</i> ^[6]	2004	85, male	Long intestinal tube	Removal of long intestinal tube, tracheotomy	Full recover
Isozaki <i>et al</i> ^[7]	2005	73, male	NGT	None	Death
Isozaki <i>et al</i> ^[7]	2005	77, female	NGT	Removal of NGT	Death
Isozaki <i>et al</i> ^[7]	2005	79, female	NGT	Undescribed	Undescribed
Isozaki <i>et al</i> ^[7]	2005	72, female	NGT	Undescribed	Undescribed
Marcus <i>et al</i> ^[9]	2006	72, male	NGT	Removal of NGT, tracheotomy	Full recover
Vielva del Campo <i>et al</i> ^[12]	2010	70, female	NGT	Removal of NGT, tracheotomy	Full recover
Ohshima <i>et al</i> ^[11]	2010	62, female	NGT	Removal of NGT	Full recover
Harmon <i>et al</i> ^[13]	2014	2 mo, male	NGT	Removal of NGT	Full recover
Harmon <i>et al</i> ^[13]	2014	3 mo, female	NGT	Removal of NGT	Full recover
Harmon <i>et al</i> ^[13]	2014	3 mo, male	NGT	Removal of NGT	Full recover
Our case	2015	76, male	Long intestinal tube	Removal of NGT, tracheotomy	Full recover

NGT: Nasogastric tube.

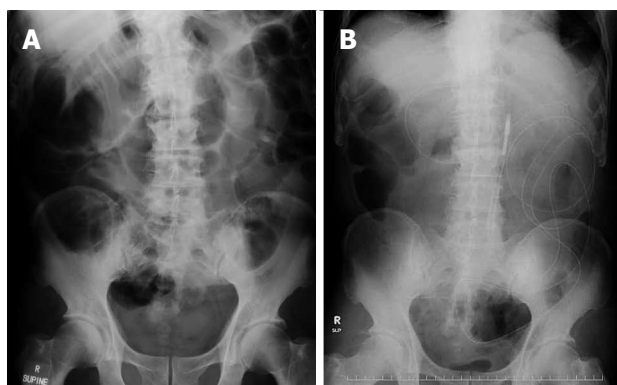


Figure 1 Abdominal X-ray. A: Intestinal obstruction at hospitalization; B: abdominal X-ray after long intestinal intubation.

diagnosis missed. The diagnosis of vocal cord paralysis and a post-cricoid ulcer can be excluded only by direct visualization of the entire post-cricoid area^[4]. The most common findings, using the scope of the pharynx and the larynx in all of the published cases, have been bilateral vocal cord paralysis and ulceration of the post-cricoid region^[8]. In our case, bronchoscopy showed only bilateral vocal cord paralysis induced by an indwelling long intestinal tube. The assessment of suspected cases of vocal cords paralysis in the setting of NGT or a long intestinal tube should include a full head and neck examination to exclude other causes and bronchoscopy to evaluate vocal cord function, ulceration, and the post-cricoid area, as well as ultrasound or computed tomography of the neck to exclude compressive pathologies.

The mechanisms of NTS can be explained in three parts^[3,8,9,12]. First, the mobile laryngeal structures rub against the fixed NGT. Second, while the patient

is supine, the cricoid bone compresses the tube against the supine. Finally, tonic contraction of the cricopharyngeus muscle pulls the tube against the delicate and thin post-cricoid mucosa. This combination generates local irritation, edema and eventual ulceration of the tissues, leading to impaired vocal cord function. It is believed that the upper airway is closed by the swelling that occurs due to the above mechanism.

The key treatment of NTS is removal of the NGT or long intestinal tube because it can lead to rapid resolution of respiratory distress. If a patient suffering from NTS requires prolonged bowel decompression, a percutaneous gastrostomy is an option. There have also been cases that improved only with the removal of the tube. However, when removal of the tube does not improve symptoms, tracheotomy will be required. Nehru *et al*^[5] reported that 77% of all NTS cases required tracheotomy. Tracheotomy is preferable to prolonged endotracheal intubation because the latter can delay the recovery of vocal cord function for several months. With regard to other treatments, parenteral corticosteroids should be used to reduce inflammation, and antibiotics should be used to prevent the formation of retro-cricoid abscesses. Moreover, the patient should refrain from oral ingestion for several days, with daily inspection of the larynx to detect reduction in arytenoid edema. If necessary, intravenous fluids, hyperalimentation, or gastrostomy could be required during this interval. In our case, the long intestinal tube was removed immediately, and tracheotomy was performed.

To prevent the onset of NTS, adaptation of the NGT or long intestinal tube insertion should be carefully determined. Moreover, a more narrow tube diameter

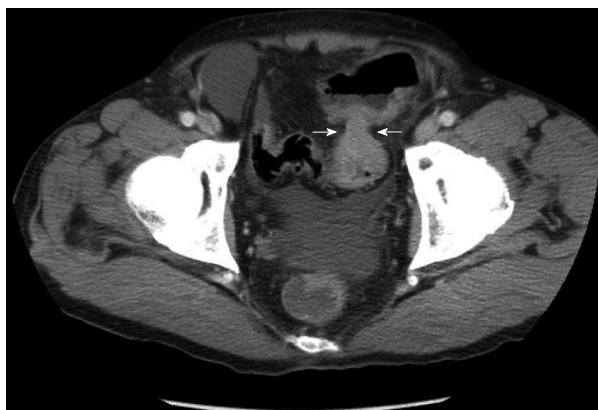

Figure 2 Computed tomography revealed sigmoid colon cancer. The white arrows indicated the site of stenosis due to the cancer.

should be chosen to reduce the pressure with which the tube presses against the organization. Friedman *et al.*^[15] reported that midline tube placement generated severe inflammation in the post-cricoid region more often than lateral tube placement. A long intestinal tube with a large diameter might be more easily placed in the midline than a NGT and lead to NTS.

In summary, we have reported a very rare but life-threatening case of the NTS induced by a long intestinal tube. We believe that this is only the second report of a case of NTS associated with a long intestinal tube for postoperative bowel decompression. NTS should be considered in all patients who present with throat pain, hoarseness, or shortness of breath after a nasogastric or a long intestinal intubation. It is hoped that careful attention to these conditions will prevent the full syndrome from becoming manifest. NTS requires prompt treatment, such as removal of the tube and tracheotomy, and close follow-up with bronchoscopy. If patients are properly diagnosed, almost all of them will eventually recover.

COMMENTS

Case characteristics

A 76-year-old man presented acute upper airway obstruction due to bilateral vocal cord paralysis.

Clinical diagnosis

The patients present acute upper airway obstruction following prolonged intestinal intubation, and bronchoscopy showed bilateral vocal cord paralysis.

Differential diagnosis

Diseases that cause acute upper airway obstruction such as the infection and foreign substances may be the main differential diagnosis.

Laboratory diagnosis

Except for desaturation, most laboratory values were within normal limits.

Imaging diagnosis

Bronchoscopy showed bilateral vocal cord paralysis.

Treatment

The key treatment is removal of the nasogastric tube or long intestinal tube. When removal of the tube does not improve symptoms, tracheotomy will be required.

Related reports

Very few cases of nasogastric tube syndrome have been reported in the literature. In most of the cases have been induced by an indwelling the nasogastric tube. The authors report a case induced by an indwelling long intestinal tube.

Term explanation

NTS is defined as nasogastric tube syndrome and NGT is defined as nasogastric tube.

Peer-review

The authors have described a case of nasogastric tube syndrome, which is rare and should, therefore, be reported. The patient was finally discharged in a fully recovered state by treatment with the appropriate diagnosis.

REFERENCES

- 1 **Sofferman RA**, Hubbell RN. Laryngeal complications of nasogastric tubes. *Ann Otol Rhinol Laryngol* 1981; **90**: 465-468 [PMID: 7305201 DOI: 10.1177/000348948109000510]
- 2 **Iglauer S**, Molt WF. Severe Injury to the Larynx Resulting from the Indwelling Duodenal Tube. *Ann Otol Rhinol Laryngol* 1939; **48**: 886-904
- 3 **Sofferman RA**, Haisch CE, Kirchner JA, Hardin NJ. The nasogastric tube syndrome. *Laryngoscope* 1990; **100**: 962-968 [PMID: 2395406 DOI: 10.1288/00005537-199009000-00010]
- 4 **Apostolakis LW**, Funk GF, Urdaneta LF, McCulloch TM, Jeyapalan MM. The nasogastric tube syndrome: two case reports and review of the literature. *Head Neck* 2001; **23**: 59-63 [PMID: 11190859]
- 5 **Nehru VI**, Al Shammari HJ, Jaffer AM. Nasogastric tube syndrome: the unilateral variant. *Med Princ Pract* 2003; **12**: 44-46 [PMID: 12566968 DOI: 10.1159/000068162]
- 6 **Sanaka M**, Kishida S, Yoritaka A, Sasamura Y, Yamamoto T, Kuyama Y. Acute upper airway obstruction induced by an indwelling long intestinal tube: attention to the nasogastric tube syndrome. *J Clin Gastroenterol* 2004; **38**: 913 [PMID: 15492616 DOI: 10.1097/00004836-200411000-00020]
- 7 **Isozaki E**, Tobisawa S, Naito R, Mizutani T, Hayashi H. A variant form of nasogastric tube syndrome. *Intern Med* 2005; **44**: 1286-1290 [PMID: 16415551 DOI: 10.2169/internalmedicine.44.1286]
- 8 **Brousseau VJ**, Kost KM. A rare but serious entity: nasogastric tube syndrome. *Otolaryngol Head Neck Surg* 2006; **135**: 677-679 [PMID: 17071292 DOI: 10.1016/j.otohns.2006.02.039]
- 9 **Marcus EL**, Caine Y, Hamdan K, Gross M. Nasogastric tube syndrome: a life-threatening laryngeal obstruction in a 72-year-old patient. *Age Ageing* 2006; **35**: 538-539 [PMID: 16754698 DOI: 10.1093/ageing/af042]
- 10 **Brousseau VJ**, Kost KM. Nasogastric tube syndrome. *J Otolaryngol* 2007; **36**: E96-E97 [PMID: 18076838]
- 11 **Ohshima M**, Hori E, Suzuki A, Katoh H, Itagaki T, Adachi Y, Doi M, Sato S. [Nasogastric tube syndrome suspected at the end of anesthesia]. *Masui* 2010; **59**: 495-497 [PMID: 20420143]
- 12 **Vielva del Campo B**, Moráis Pérez D, Saldaña Garrido D. Nasogastric tube syndrome: a case report. *Acta Otorrinolaringol Esp* 2010; **61**: 85-86 [PMID: 20061208 DOI: 10.1016/j.otorri.2009.03.006]
- 13 **Harmon J**, Balakrishnan K, de Alarcon A, Hart CK. The nasogastric tube syndrome in infants. *Int J Pediatr Otorhinolaryngol* 2014; **78**: 882-884 [PMID: 24725648 DOI: 10.1016/j.ijporl.2014.02.013]
- 14 **Leclerc C**, Perhirin M, De Rugy MG, Valdazo A. [Severe laryngeal

injury due to a nasogastric tube]. *Ann Fr Anesth Reanim* 2002; **21**: 306-309 [PMID: 12033100 DOI: 10.1016/S0750-7658(02)00608-1]

15 **Friedman M**, Baim H, Shelton V, Stobnicki M, Chilis T, Ferrara T,

Skolnik E. Laryngeal injuries secondary to nasogastric tubes. *Ann Otol Rhinol Laryngol* 1981; **90**: 469-474 [PMID: 7305202 DOI: 10.1177/000348948109000511]

P- Reviewer: Perakath B **S- Editor:** Gong ZM
L- Editor: A **E- Editor:** Liu XM





Published by **Baishideng Publishing Group Inc**

8226 Regency Drive, Pleasanton, CA 94588, USA

Telephone: +1-925-223-8242

Fax: +1-925-223-8243

E-mail: bpgoffice@wjgnet.com

Help Desk: <http://www.wjgnet.com/esps/helpdesk.aspx>

<http://www.wjgnet.com>



ISSN 1007-9327



9 771007 932045