

Sudden Hearing Loss Related to COVID-19 Adenovirus Vector Vaccine?

Abstract

There are increasing reports connecting the coronavirus disease 2019 (COVID-19) vaccinations and adverse otological events. These events are mostly explained by the immunological effects or the recorded thrombotic consequences of the vaccinations. The inner ear is liable to be insulted by the thrombosis of the terminal auditory artery causing sudden sensorineural hearing loss (SSNHL). We reported two cases that suffered from SSNHL within 2 weeks after the first dose of the Oxford–AstraZeneca vaccine without any previous hearing problems. These cases showed severe–profound hearing loss in the audiological evaluation. The first case presented with a vestibular hypofunction in the affected ear and received a course of systemic corticosteroids, followed by anticoagulants (heparin). The second case, instead, received six intratympanic injections of corticosteroid, followed by hyperbaric oxygen therapy. The audiological function partially recovered after the treatment in both cases, with complete vertigo recovery in the first case. These results revealed a kind of similarity of the clinical course in COVID-19- and non-COVID-19-associated SSNHL. Hyperbaric therapy showed to be helpful for improving the prognosis.

Keywords: Corticosteroids, coronavirus disease 2019, sensorineural hearing loss, thrombosis, vaccinations

Introduction

Coronavirus disease 2019 (COVID-19), caused by severe acute respiratory syndrome coronavirus-2, is a recent worldwide pandemic characterized by high mortality and morbidity rates. Therefore, when by the end of 2020 started to be available, vaccination has become a useful tool to control this highly infectious disease.^[1]

By the end of 2021, five vaccines for COVID-19 have been authorized in Italy, namely BNT162b2 (Pfizer–BioNTech), mRNA-1273 (Moderna), ChAdOx1 nCoV-19 (Oxford–AstraZeneca), Ad26.COV2.S (Johnson and Johnson/Janssen), and NVX-CoV2373 (Novavax).

Among the rare side effects after COVID-19 vaccination, one may consider Guillain–Barre syndrome, thrombosis with thrombocytopenia syndrome (Janssen), myocarditis (Pfizer–BioNTech and Moderna),^[2] and unusual cerebral blood clots with thrombocytopenia in healthy young people within 2 weeks after receiving Oxford–AstraZeneca vaccine (OAZV).^[3]

This is an open access journal, and articles are distributed under the terms of the Creative Commons Attribution-NonCommercial-ShareAlike 4.0 License, which allows others to remix, tweak, and build upon the work non-commercially, as long as appropriate credit is given and the new creations are licensed under the identical terms.

For reprints contact: WKHLRPMedknow_reprints@wolterskluwer.com

In some recent reports, a correlation was found between COVID-19 vaccinations and the development of otological adverse events such as sudden sensorineural hearing loss (SSNHL), tinnitus, and vestibular manifestations.^[4] SSNHL is defined as a unilateral sensorineural hearing loss of 30 dB or greater in at least three consecutive frequencies occurring over 72 h. It occurs due to inner ear cell damage mediated either by the patient's immune system or by vascular impairment.^[5]

In this study, we reported two cases of SSNHL after OAZV COVID-19 vaccination.

Case Reports

Case 1

A 58-year-old male patient, affected by hypertension without any previous hearing problem, visited our clinic for a sudden hearing loss that occurred 13 days after the first dose of OAZV COVID-19 vaccination on March 3, 2020. He also suffered from left aural fullness, tinnitus, and dizziness.

How to cite this article: Margani V, Covelli E, Elfarargy HH, Bandiera G, Filippi C, Buffoni A, *et al.* Sudden hearing loss related to COVID-19 adenovirus vector vaccine? Saudi J Otorhinolaryngol Head Neck Surg 0;0:0.

Received: 28-11-22 Revised: 09-01-23
Accepted: 12-01-23 Published Online: 20-03-23

Valerio Margani,
Edoardo Covelli,
Haitham H.
Elfarargy¹,
Giorgio Bandiera,
Chiara Filippi,
Antonella Buffoni,
Luigi Sabino,
Maurizio Barbara,
Simonetta Monini

Department of NESMOS,
Sapienza University – Faculty
of Medicine and Psychology,
¹Department of Otolaryngology,
Kafrelsheikh University,
Kafrelsheikh, Egypt

Address for correspondence:

Dr. Valerio Margani,
Department of NESMOS,
Otolaryngology Clinic,
Sant'Andrea Hospital Via di
Grottarossa 1035, 00189 Rome,
Italy.
E-mail: valerio.margani@uniroma1.it

Access this article online

Website: www.sjohns.org

DOI: 10.4103/sjoh.sjoh_56_22

Quick Response Code:



Otосcopy was unremarkable on both sides. Blood platelet values were within normal limits. Clinical vestibular evaluations by the video head impulse test and the cervical vestibular-evoked myogenic potentials revealed a left labyrinth hypofunction. Audiological examination showed a severe–profound hearing loss in all frequencies in the left ear, with a mean Pure tone average (PTA) (250–4000 Hz) of 108 dB HL, and normal thresholds in the contralateral ear [Figure 1a]. Computed tomography (CT) scan showed normal findings, while brain magnetic resonance imaging MRI showed small T2 bilateral hyperintense areas due to chronic vasculopathy, with normal appearance of the stato-acoustic bundle.

Systemic steroid treatment was initiated according to what was proposed by Filipo *et al.*^[6] The patient received 25 mg prednisone twice per day for 5 days, followed by tapering over the next 5 days (25 mg for 3 days and 12,5 mg for 2 days). Subsequently, he received 4000 U of enoxaparin by daily subcutaneous injection in the abdominal area for a further 2 weeks.^[7]

After steroid therapy, a partial hearing recovery was shown. The mean PTA (250–4000 Hz) became 61 dB HL and remained almost stable after treatment with heparin [Figure 1a]. Dizziness also completely disappeared after the medical treatment. One month after the corticosteroids course, the patient showed a negative autoimmune screening.

Case 2

A 60-year-old male patient, diabetic (type II diabetes mellitus, on insulin therapy) with mild coronary stenosis without any previous hearing problem, visited our clinic 14 days after developing sudden hearing loss. HL occurred 2 days after the first dose of OAZV COVID-19 vaccination on March 30, 2021. He also suffered from left aural fullness and tinnitus, with no associated vertigo.

Otосcopy was unremarkable on both sides. Blood platelet values were within normal limits. Clinical vestibular evaluations were within normal limits. Audiological examination showed a left severe–profound hearing loss, with a mean PTA (250–4000 Hz) of 91 dB HL, and normal thresholds in the contralateral ear [Figure 1b]. CT scan and brain MRI showed normal findings.

The patient underwent a course of corticosteroid intratympanic injections in the form of 5 mg of dexamethasone every 3 days for six sessions. Two days after the last intratympanic injection, the patient underwent a hyperbaric oxygen treatment.^[8]

At the end of the treatment, the patient showed a partial hearing recovery. The mean PTA (250–4000 Hz) became 53 dB HL [Figure 1b]. One month after the corticosteroids course, the patient showed a negative autoimmune screening.

Discussion

Many previous vaccinations, such as the influenza vaccine and meningococcal conjugate vaccine, were reported to cause SSNHL. Likewise, during phase 3 clinical trials of mRNA COVID-19 vaccines, several cases of facial paralysis were observed in the vaccine groups.^[9] In addition, many reports related COVID-19 vaccinations to the occurrence of cochleovestibular manifestations. Jeong and Choi reported two cases of SSNHL after Pfizer–BioNTech vaccination and one case after OAZV.^[10] Furthermore, Canales Medina and Ramirez Gómez reported five cases of SSNHL after OAZV and one case of vestibular neuritis after the same vaccine.^[11] Tsetsos *et al.* reported a case of SSNHL that occurred after OAZV.^[12] These reports resemble what we noticed about the occurrence of SSNHL in two cases within 2 weeks from their first dose of OAZV.

Although the relationship between the otological adverse events and COVID-19 vaccinations is not fully confirmed, many mechanisms have been suggested to explain the cochlear insult after vaccinations. An immunocomplex reaction may arise after vaccination, causing an autoimmune response with antibodies targeting the cochlea. There is also growing evidence that NOX-2-derived ROS is implicated in clotting and platelet activation, promoting an intrasignaling pathway that activates thrombin generation and platelet aggregation. Since the cochlea is supplied by one terminal

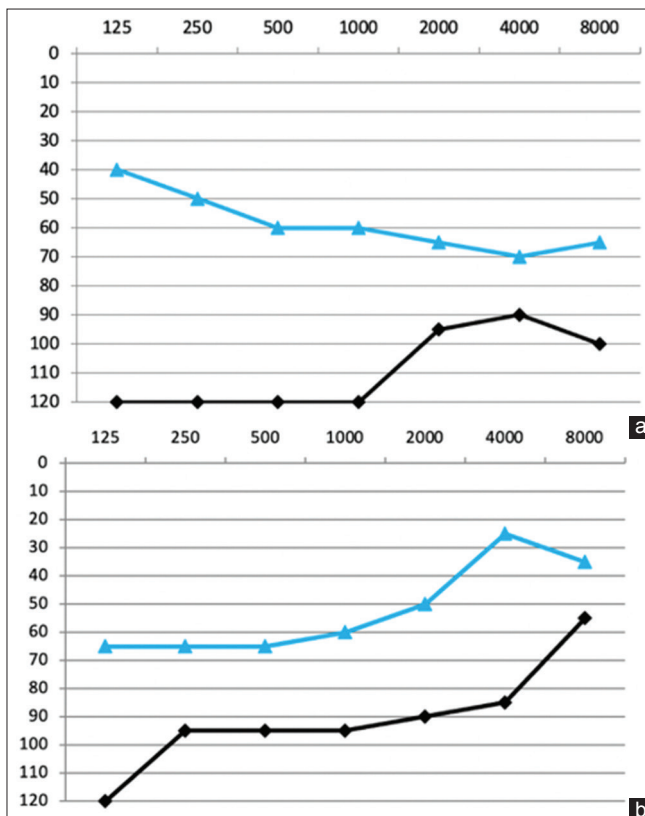


Figure 1: The pure tone audiometry of both cases. (a) The PTA of case 1. (b) The PTA of case 2. Black: Initial PTA; Blue: PTA at the end of the treatment

artery (the internal auditory artery), its thrombosis might be considered one of the main mechanisms.^[13]

A close relationship was found between the mRNA COVID-19 vaccines and thrombosis associated with thrombocytopenia and considered a rare side effect. According to the European Medicines Agency, these very rare adverse events occur in around 1 out of 100,000 vaccinated people, thus confirming that the vaccine's benefit outweighs the risks.^[14]

SSNHL is an emergency that requires early diagnosis and treatment within the first 10 days after the event and its spontaneous recovery has been reported in 32%–65% of the cases. Systemic corticosteroids represent the primary treatment while, in the lack of a positive trend, an intratympanic steroids injection course is recommended.^[6] Our second patient received corticosteroids in the form of intratympanic injection because of the delay in seeking medical care.

The negative inner ear and cerebellum-pontine angle MRI findings confirmed the sensory type of sudden hearing loss. In this study, the use of hyperbaric treatment showed to enhance peripheral vascularization which helped in the auditory improvement after the corticosteroid course. This resembled the effect of heparin in the other case. Therefore, the possible vaccine-induced thrombotic effect on inner ear terminal circulation may be highly considered in these cases.

A limitation of our study is represented by the evidence that viral infection, vascular ischemia, and autoimmune response are known suspicious causes of SSNHL regardless of vaccination. Nonetheless, SSNHL onset within days after COVID-19 vaccination has the possibility that vaccination is the significant cause due to temporal correlation.

SSNHL following COVID-19 vaccination, as reported by our study and many other reports, should not be neglected. Although there are no definitive explanations for this inner ear insult, the thrombotic and immunological mechanisms are highly suggestive. According to our experience, the clinical behavior of COVID-19-related SSNHL resembles the non-COVID-19 one, showing a positive response to corticosteroids either systemic or intratympanic. Hyperbaric therapy may play an adjuvant role in improving the audiological function under this situation.

Declaration of patient consent

The authors certify that they have obtained all appropriate patient consent forms. In the form the patient(s) has/have given his/her/their consent for his/her/their images and other clinical information to be reported in the journal. The patients understand that their names and initials will not be published and due efforts will be made to conceal their identity, but anonymity cannot be guaranteed.

Financial support and sponsorship

Nil.

Conflicts of interest

There are no conflicts of interest.

References

1. Degen C, Lenarz T, Willenborg K. Acute profound sensorineural hearing loss after COVID-19 pneumonia. *Mayo Clin Proc* 2020;95:1801-3.
2. Rosenblum HG, Hadler SC, Moulia D, Shimabukuro TT, Su JR, Tepper NK, *et al.* Use of COVID-19 vaccines after reports of adverse events among adult recipients of Janssen (Johnson & Johnson) and mRNA COVID-19 vaccines (Pfizer-BioNTech and Moderna): Update from the advisory committee on immunization practices – United States, July 2021. *MMWR Morb Mortal Wkly Rep* 2021;70:1094-9.
3. Ledford H. How could a COVID vaccine cause blood clots? Scientists race to investigate. *Nature* 2021;592:334-5.
4. Shemer A, Pras E, Einan-Lifshitz A, Dubinsky-Pertsov B, Hecht I. Association of COVID-19 vaccination and facial nerve palsy: A case-control study. *JAMA Otolaryngol Head Neck Surg* 2021;147:739-43.
5. Alexander TH, Harris JP. Incidence of sudden sensorineural hearing loss. *Otol Neurotol* 2013;34:1586-9.
6. Filipo R, Attanasio G, Russo FY, Viccaro M, Mancini P, Covelli E. Intratympanic steroid therapy in moderate sudden hearing loss: A randomized, triple-blind, placebo-controlled trial. *Laryngoscope* 2013;123:774-8.
7. Kim J, Jeong J, Ha R, Sunwoo W. Heparin therapy as adjuvant treatment for profound idiopathic sudden sensorineural hearing loss. *Laryngoscope* 2020;130:1310-5.
8. Rhee TM, Hwang D, Lee JS, Park J, Lee JM. Addition of hyperbaric oxygen therapy versus medical therapy alone for idiopathic sudden sensorineural hearing loss: A systematic review and meta-analysis. *JAMA Otolaryngol Head Neck Surg* 2018;144:1153-61.
9. Renoud L, Khouri C, Revol B, Lepelley M, Perez J, Roustit M, *et al.* Association of facial paralysis with mRNA COVID-19 vaccines: A disproportionality analysis using the World Health Organization pharmacovigilance database. *JAMA Intern Med* 2021;181:1243-5.
10. Jeong J, Choi HS. Sudden sensorineural hearing loss after COVID-19 vaccination. *Int J Infect Dis* 2021;113:341-3.
11. Canales Medina M, Ramirez Gómez M. Tinnitus, sudden sensorineural hearing loss, and vestibular neuritis as complications of the Astra Zeneca COVID-19 vaccine. *Cureus* 2022;14:e20906.
12. Tsetsos N, Poutoglidis A, Vlachtsis K, Kilmpasani A, Gougousis S. Sudden sensorineural hearing loss following the second dose of COVID-19 vaccine. *Cureus* 2021;13:e17435.
13. Chen X, Fu YY, Zhang TY. Role of viral infection in sudden hearing loss. *J Int Med Res* 2019;47:2865-72.
14. European Medicines Agency (EMA). “AstraZeneca’s COVID-19 Vaccine: Benefits and Risks in Context”. (Press release 23/04/2021). Available from: <https://www.ema.europa.eu/en/news/astrazenecas-covid-19-vaccine-benefits-risks-context>. [Last accessed on 2021 Dec 20].