





Free-style technique versus computed tomographic angiography-guided perforator selection in deep inferior epigastric perforator flap harvest: A prospective clinical study

Fabio Santanelli di Pompeo MD, PhD¹  | Guido Paolini MD, PhD¹ |
 Gennaro D'Orsi MD¹ | Matteo Atzeni MD, PhD²  | Carlo Catalano MD³ |
 Giuseppe Cannavale MD³ | Francesco Cilia MD³  | Guido Firmani MD¹  |
 Michail Sorotos MD, PhD¹

¹Department of Plastic Surgery, Faculty of Medicine and Psychology, Sapienza University of Rome - Sant'Andrea Hospital, Rome, Italy

²Department of Plastic Surgery and Microsurgery, Azienda Ospedaliera Universitaria Cagliari, Cagliari, Italy

³Department of Radiological Sciences, Oncology and Pathology, Sapienza University of Rome, Rome, Italy

Correspondence

Fabio Santanelli di Pompeo, Chair of Plastic Surgery, Sapienza University, c/o Sant'Andrea Hospital, Via di Grottarossa 1035-1039, 00189 Rome, Italy.

Email: fabio.santanelli@uniroma1.it

Abstract

Background: Computed tomographic angiography (CTA) is the preferred diagnostic tool in preoperative deep inferior epigastric perforator (DIEP) flap assessment, though some surgeons prefer approaching perforator selection with intraoperative findings alone.

Methods: This prospective observational study conducted between 2015 and 2020 assessed our intraoperative decision-making “free-style” technique for DIEP flap harvest. Any patient with indication for immediate or delayed breast reconstruction using abdominally based flaps and who received preoperative CTA was enrolled. Only unilateral cases performed by the same surgeon were considered. Allergy to iodine-based contrast media, renal impairment and claustrophobia were other exclusion criteria. Primary endpoint consisted in comparing operative times and complication rates between *free-style technique* and CTA-guided approach. Secondary endpoints included evaluation of agreement rate between intraoperative findings and CTA, and identification of variables affecting operative time and complication rate. Demographics, surgical information, agreement versus non-agreement and complications were collected.

Results: Starting from 206 patients, 100 were enrolled. Fifty were assigned to Group A, receiving DIEP flap with *free-style technique*. The other 50 were assigned to Group B, receiving DIEP flap with CTA-guided perforators selection. Study groups' demographics were homogenous. Operative time was statistically lower ($p = .036$) in *free-style* group (252.4 ± 44.77 min vs. 265.6 ± 31.67 min). Complication rates were higher in CTA-guided group (10% vs. 2%) though this was not significant ($p = .092$). Overall agreement rate in dominant perforator selection between intraoperatively and CTA-based assessment was 81%. Multiple regression analysis showed no variable increased complication rate, though CTA-guided

approach, BMI > 30 and harvesting more than one perforator were respectively associated with B-coefficient of 17.391 (2.430–32.351, 95% CI) [$p = .023$], 3.50 (0.640–6.379, 95% CI) [$p = .017$] and 18.887 (6.232–31.542, 95% CI) [$p = .004$], predicting increased operative time.

Conclusions: The *free-style technique* proved to be a useful tool for guiding DIEP flap harvest with good sensibility in detecting the dominant perforator suggested by CTA without statistically increasing surgery duration and complications.

1 | INTRODUCTION

Since its inception, the deep inferior epigastric perforator (DIEP) flap has been the technique of choice for autologous breast reconstruction (BR), gaining popularity for its low morbidity, superior cosmetic outcomes, and aesthetically pleasing donor site defects (Allen & Treece, 1994; Schaverien & Butler, 2017; Wu et al., 2008).

Performing this procedure requires a significant learning curve in terms of flap design, perforator selection and dissection (Laporta, Longo, Sorotos, Farcomeni, et al., 2017a; Rozen & Ashton, 2009; Santanelli et al., 2015). Diagnostic imaging has long been used for pre-operative perforator assessment to guide the surgeon and reduce operative times (Blondeel et al., 1998; Hallock, 2003; Pratt et al., 2012; Rozen, Garcia-Tutor, et al., 2010a). Computed tomographic angiography (CTA) in particular has been recognized as the possible gold standard for perforator selection as it provides high-resolution images with 3D reconstructions and a grid system to localize them (Hummelink et al., 2015; Lee & Mun, 2016a; Masia et al., 2006; Renzulli et al., 2020; Rozen, Ashton, Grinsell, Stella, Phillips, & Taylor, 2008b; Rozen, Ashton, Stella, Phillips, Grinsell, & Taylor, 2008a). On the other hand, concerns have been raised regarding CTA utility and efficacy, since several methodological biases in previous studies and technological procedure limitations have been described over time (Boer et al., 2017; Wade et al., 2018). In fact, some surgeons still prefer approaching flap harvest and perforator selection with intraoperative findings alone, while limiting the use of CTA to patients with previous abdominal surgery (Keys et al., 2013; Klasson et al., 2015).

Our team has performed DIEP-based BR since 2004 (Laporta et al., 2015; Laporta, Longo, Sorotos, & Santanelli di Pompeo, 2017b). We translated this experience in our “*free-style*” *technique*, used for dominant perforator selection with intraoperative visual feedback alone, without any guidance imaging.

We conducted a prospective observational study where the primary endpoint consisted in comparing operative times and complication rates between the *free-style* algorithm and the CTA-guided approach. The study was conducted hypothesizing that the *free-style* approach had OT and CR similar to those in a CTA-based approach. Secondary endpoints included the evaluation of agreement rate between the intraoperative findings and the CTA, and the identification of the variables affecting operative times and complication rates.

2 | PATIENTS AND METHODS

Between April 2015 and March 2020, we prospectively enrolled all patients scheduled for immediate or delayed DIEP flap BR at our facility for a prospective observational study, in accordance with the tenets of the Declaration of Helsinki. The study received Institutional Review Board approval by Sapienza University's Ethical Committee (Ref. CE 6881/2022), and was conducted in accordance with the Strengthening The Reporting of OBServational studies in Epidemiology (STROBE) checklist for cohort studies. All patients received and signed an informed consent for undergoing surgery and for participation in the study upon admission, which was on the day before surgery.

2.1 | Inclusion criteria

Recruited patients had an indication for undergoing unilateral BR with DIEP flap, that was either performed immediately at the time of mastectomy or that was delayed. All recruited patients received CTA scanning requested for completing oncologic staging or follow-up, but was subsequently used for pre-operative perforator assessment as well.

2.2 | Exclusion criteria

To standardize the sample population, we excluded patients requiring bilateral BR. We minimized the impact of operator-based differences, by excluding any patient whose BR was not performed by the senior surgeon (FSdP). Other exclusion criteria included allergy to iodine-based contrast media, renal impairment and claustrophobia.

2.3 | Surgical technique

Our unilateral DIEP flap technique consisted in harvesting the flap contralaterally to the mastectomy side, and rotating it by 180° to the chest wall. When available, the superficial inferior epigastric vein (SIEV) was always harvested and anastomosed to enhance venous outflow. The design always extended over the ipsilateral hemiabdomen, including Holm's perfusion zone III in part or in full, but never to zone IV. In immediate BRs, the procedure was carried-out by two

teams simultaneously: a team of plastic surgeons and one of breast surgeons.

No limitations were posed in regard to age, BMI, parity, smoking habit, BR timing or need for immediate contralateral balancing. Data collected were: demographics, surgical information (flap weight, timing of reconstruction, type of mastectomy, flap weight, number of perforators) and complications. Two series of 50 patients were enrolled in the study in two consecutive groups: Group A included 50 patients who underwent pre-operative CTA which was blinded to the senior surgeon but was assessed by a second surgeon only to appreciate the presence and patency of deep inferior epigastric artery (DIEA) and vein (DIEV). In this group, DIEP flap was harvested using the *free-style technique* and all patients signed an informed consent form which asked them to undergo a pre-operative CTA scan that would be blinded to the surgeon. Following the surgery, the senior surgeon reported all intraoperatively visualized perforators across the anterior fascia of the rectus abdominis muscle, using a Cartesian coordinate system used by the radiologist, specifying which one was the dominant. Six months after surgery, the surgeon blindly selected the best perforators from the CTA scans for each enrolled patient in this group. On the other hand, the Group B included 50 patients who underwent CTA-guided perforator selection of DIEP flap.

Patients were further divided according to agreement or non-agreement of the selected perforators, between the intraoperative report and the retrospective (for Group A) or preoperative (for Group B) decision based on CTA scans. We used the findings to assess the sensibility of the *free-style technique* in detecting the same perforator that would have been deemed appropriate by the same surgeon on CTA evaluation.

We assessed operative times from incision to end of surgery and flap-related complication rate. Flap-related complications were classified in the following manner: fat necrosis, defined as a palpable nodule greater than or equal to 1 cm according to the Rao grading system (Gill et al., 2004; Rao & Saadeh, 2014); partial flap necrosis, defined as fat necrosis >5 cm in diameter or tissue loss >10% of the flap; total flap loss, defined as a total necrosis of the flap, that required its surgical removal. Finally, we studied the impact of demographics, surgical information, CTA versus *free-style* approach, agreement versus non-agreement on surgery duration and complication rates.

2.4 | Free-style technique

Our *free-style* approach uses direct visualization to guide the perforator selection process, and is based on the following principles: the perforator with the largest vein should be considered as dominant, and thus should be selected. If the perforator with the largest vein is located close to the trans-umbilical line, it should be discarded, regardless of its row, if the dissection of the cranial edge of the flap causes a major bleeding below Scarpa's fascia (Figure 1). If medial and lateral veins are of equal size, the lateral (easy) or the medial (tedious) perforator should be used in case of a small Holm's perfusion zone III.

Conversely, the medial perforator should be used in case of large Holm's perfusion zone III. Additionally, in the latter case, the second-best perforator should be included as well. Furthermore, the second-best perforator should be harvested in flaps with a large perforator III (Rozen, Ashton, et al., 2010b) or in flaps with a design that cross over Holm's perfusion zone III (Holm et al., 2006). If said flaps are based on a dominant medial row perforator (MRP), the second-best perforator can be harvested from lateral row if its dissection requires the incision of less than 1/3 of the rectus abdominis muscle. Otherwise, it can be harvested from the medial row. If the flaps have a dominant lateral row perforator (LRP), the second-best perforator can be harvested from the medial row if its dissection requires the incision of less than 1/3 of the rectus abdominis muscle. Otherwise, from the lateral row instead. In small flaps, the harvesting of a second perforator should be reserved in cases where it entails little to no additional muscle/nerve damage. It should be duly noted that when harvested in series, a type 2 intercostal motor nerve branch might often need to be severed, thus being possibly more invasive than a minor damage only limited to muscle (Rozen, Ashton, Murray, & Taylor, 2008c). A third perforator can be harvested when the conditions allow it, similarly to the harvesting of a second perforator, and when its dissection does not require additional muscle/nerve damage. Small flaps (i.e., that include Holm's zone I and II) should be harvested preferably using a single LRP with the largest vein, or using an MRP if considerably larger. Finally, perforator selection must favor flap perfusion first, even if it comes at the cost of higher abdominal wall morbidity (muscle/nerve damage) and/or worst residual defect.

2.5 | CTA-guided perforator selection

In the CTA-guided group, the senior author visualized the CTA 1 day prior and immediately before surgery, but not intraoperatively. CTA-guided perforator selection took into consideration the caliber, location and extra/intramuscular course of the perforators. Preference was given to perforators with a large caliber, located not too close to the flap's cranial border and preferably more central, branching into the flap and with a short intramuscular course.

2.6 | CTA scanning method and protocol

We specifically chose our equipment to be similar to what has already been described in literature by Phillips et al. (2008), using a Siemens Somatom Sensation 64 tomography scanner (Siemens medical System; Erlangen, Germany) and 100 mL of intravenous Iomeron 400 (Iomeron[®], Bracco UK Ltd.) as contrast medium.

Patients were examined in the supine position, and all angiograms were acquired and reported by the same appointed experienced radiologist. The radiologist identified all perforators below the umbilicus, describing the caliber and branching pattern of the DIEA, according to Moon and Taylor classification

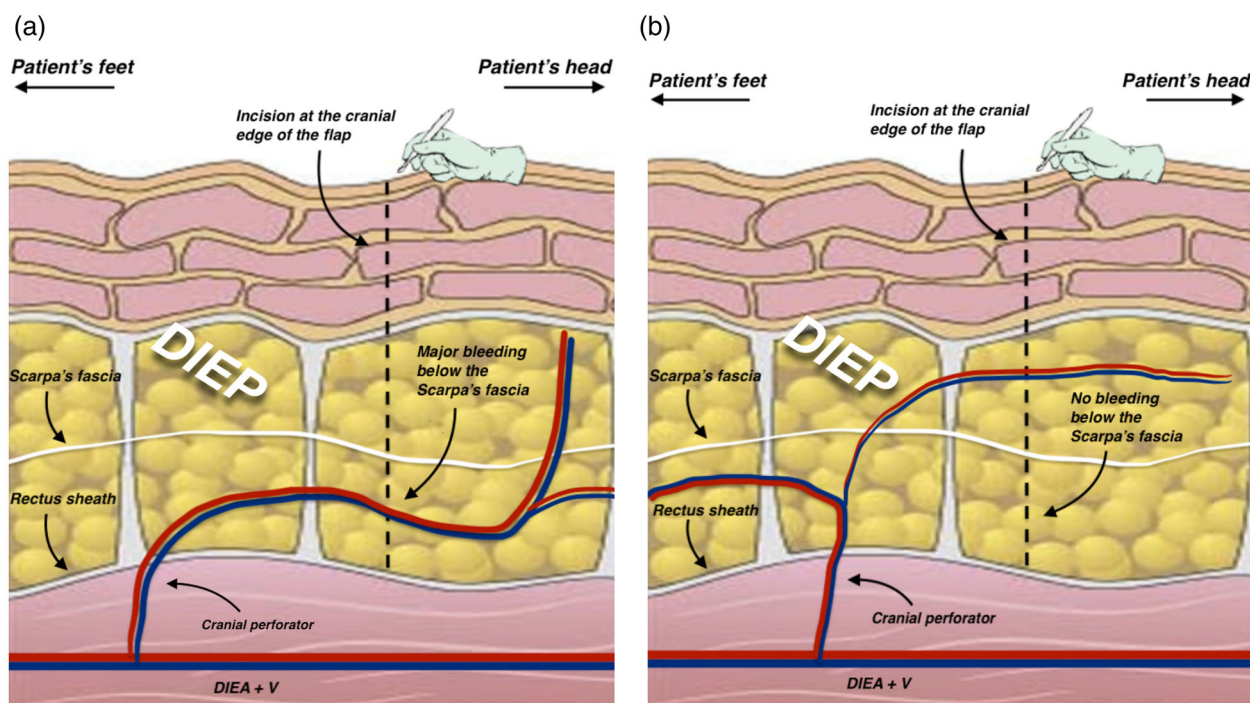


FIGURE 1 Schematic representation of the *free-style algorithm* when the dominant perforator was located close to the trans-umbilical line: (a) The dominant perforator close to the trans-umbilical line was discarded if a major bleeding occurred at a level deeper than the Scarpa's fascia, during the incision of the flap's cranial edge. (b) The dominant perforator located close to the trans-umbilical line was harvested if no bleeding occurred below the Scarpa's fascia during the incision of the flap's cranial edge. This main perforator was selected even if the bleeding occurred above the Scarpa's fascia, meaning that its main branch departed caudally, supplying blood into the flap.

(Moon & Taylor, 1988). Using a grid with the umbilicus set as 0-point, the lower abdomen was marked according to a Cartesian coordinate system. X- and Y-coordinates were respectively the horizontal and vertical axes of any point location where each perforator penetrates the anterior fascia of the rectus muscle.

2.7 | Statistical analysis

The two groups were analyzed for demographics, flap characteristics, surgery duration and complications using Chi-square for categorical variables and Mann-Whitney *U* for continuous variables. Logistic multiple regression analysis was used to analyze the impact of all variables on operative time and complication rate. Statistical calculations were performed using SPSS 20 (SPSS, Chicago, IL), considering a *p* value <.05 as significant.

3 | RESULTS

A total of 206 patients underwent DIEP flap-based breast reconstruction between April 2015 and March 2020. Following the exclusion criteria, 100 patients were enrolled in the study, out of which the first 50 were assigned to Group A and the following 50 were assigned to Group B (Figure 2).

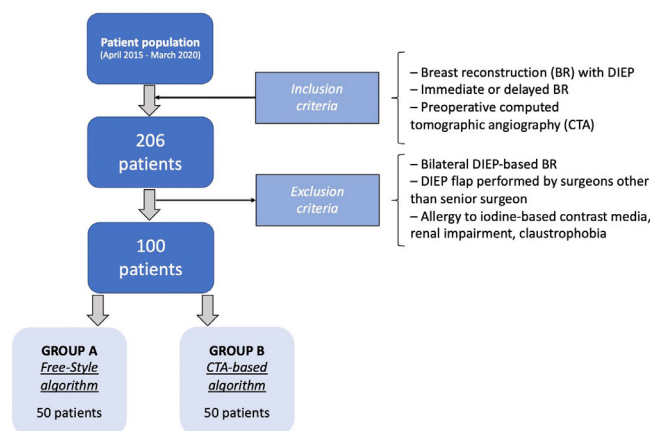


FIGURE 2 patient enrolment process, with reasons of inclusion/exclusion and final subdivisions.

The two patient groups were homogenous for age, BMI, smoking history (defined as active smokers if patients partook in the habit within the last year before surgery), parity, flap weight, timing of reconstruction, contralateral balancing, type of mastectomies and number of perforators for flap harvest. Mean follow-up was 57.4 months (range 36.9–73.8) for Group A and 24.0 months (range 13.1–41.6) for Group B. Additional venous drainage was accomplished using SIEV in 33 patients (66%) from Group A and 30 (60%) from Group B.

TABLE 1 Patients and flaps characteristics among the two groups

	Group A (free-style technique)	Group B (CTA-guided)	p value
Patients number	50	50	
Mean age (years)	52.9 ± 8.22	52.5 ± 10.33	.874
Mean BMI (kg/m ²)	24.9 ± 3.56	25.15 ± 3.32	.482
Smoking history	7 (14.0%)	10 (20.0%)	.424
Nulliparity	8 (16.0%)	5 (10.0%)	.372
Flap weight (grams)	603.4 ± 254.91	609.8 ± 175.49	.508
Reconstruction timing	Immediate: 42 (84.0%) Delayed: 8 (16.0%)	Immediate: 36 (72.0%) Delayed: 14 (28.0%)	.148
Contralateral symmetrization	Yes: 15 (30.0%) No: 35 (70.0%)	Yes: 9 (18.0%) No: 41 (82.0%)	.160
Mastectomy type	NSM: 11 (22.0%) SSM: 14 (28.0%) MRM: 25 (50%)	NSM: 12 (24.0%) SSM: 9 (18.0%) MRM: 29 (58.0%)	.490
Number of perforators	One perforator: 17 (34%) Two perforators: 27 (54%) Three perforators: 6 (12%)	One perforator: 20 (40%) Two perforators: 27 (54%) Three perforators: 3 (6%)	.371
Operative time (minutes)	252.4 ± 44.77	265.6 ± 31.67	.036
Total complication rate	1 (2.0%)	5 (10.0%)	.092
Fat necrosis	1 (2.0%)	1 (2.0%)	
Partial flap necrosis	0 (0%)	3 (6.0%)	
Total flap necrosis	0 (0%)	1 (2.0%)	

Note: Operative time was found to be statistically higher in Group B. Bold values indicates Significant values.

TABLE 2 Agreement and non-agreement groups between the intraoperative selected perforators and those suggested by CTA.

	Agreement group	Non-agreement group	p value
Patients number	81 (81%)	19 (19%)	
Mean age (years)	53.22 ± 9.17	50.47 ± 5.40	.152
Mean BMI (kg/m ²)	24.99 ± 3.42	24.96 ± 3.44	.975
Smoking history	9 (11.1%)	8 (42.1%)	.003
Nulliparity	10 (12.35%)	3 (15.79%)	.688
Flap weight (grams)	608.17 ± 218.21	599.74 ± 241.09	.979
Reconstruction timing	Immediate: 61 (75.3%) Delayed: 20 (24.57%)	Immediate: 17 (89.5%) Delayed: 2 (10.5%)	.180
Contralateral symmetrization	Yes: 23 (28.4%) No: 58 (71.6%)	Yes: 1 (5.3%) No: 18 (94.7%)	.034
Mastectomy type	NSM: 15 (18.54%) SSM: 19 (23.46%) MRM: 47 (58%)	NSM: 8 (42.1%) SSM: 4 (21.2%) MRM: 7 (36.8%)	.080
Number of perforators	One perforator: 32 (39.5%) Two perforators: 42 (51.8%) Three perforators: 7 (8.7%)	One perforator: 5 (26.3%) Two perforators: 12 (63.2%) Three perforators: 2 (10.5%)	.316
Operative time (minutes)	260.9 ± 37.30	250.8 ± 46.47	.307
Complication rate	Total 3 (3.7%) Fat necrosis: 2 (2.47%) Partial flap necrosis: 1 (1.23%) Total flap necrosis: 0 (0%)	Total 3 (15.8%) Fat necrosis: 0 (0%) Partial flap necrosis: 2 (10.5%) Total flap necrosis: 1 (5.2%)	.046

Note: Bold values indicates Significant values.

TABLE 3 Binary logistic regression analysis evaluating the impact of the variables in the incidence of complications.

	Odds ratio	95% C.I.	p value
Age	1.024	0.898–1.168	.724
Group B	2.886	0.192–43.460	.444
Non-agreement	1.091	0.070–17.020	.950
BMI (kg/m ²)	0.776	0.483–1.247	.295
Smoking history	11.785	0.756–183.760	.078
Nulliparity	0.744	0.589–1.456	.354
Flap weight (grams)	1.004	0.997–1.012	.242
Delayed reconstruction	1.220	0.054–27.753	.901
<i>Mastectomy type</i>			
SSM	1.310	0.047–36.830	.874
NSM	2.320	0.077–70.040	.628
Number of perforators	0.330	0.034–3.245	.342
Operative time (minutes)	1.029	0.995–1.063	.094

TABLE 4 Multiple regression analysis evaluating the impact of the variables in the incidence of operative time.

	B coefficient	95% C.I.	p value
Age	−.109	−.997–0.778	.807
Group B	17.391	2.430–32.351	.023
Agreement	13.752	−6.189–33.695	.174
BMI (kg/m ²)	3.509	0.640–6.379	.017
Smoking history	−7.446	−28.021–13.130	.474
Nulliparity	11.112	−11.119–33.342	.323
Flap weight (grams)	0.005	−0.043–0.053	.836
Timing of reconstruction	−4.415	−25.771–16.942	.682
Mastectomy type	5.034	−6.506–16.574	.388
Number of perforators	18.887	6.232–31.542	.004

Note: Bold values indicates Significant values.

Group A had a mean operative time of 252.4 ± 44.77 min and flap-related complication rate of 2.0%, consisting of only 1 fat necrosis (2.0%), but no partial (0%) or total flap necrosis (0%). Seventeen flaps (34%) were harvested based on a single perforator, while 27 flaps (54%) were based on two perforators and the remaining 6 flaps (12%) on three perforators. A total of 229 perforators were visualized intraoperatively on the ipsilateral side of the flap pedicle, whereas only 202 were identified using CTA, showing an accuracy of 88.2%.

In Group B, mean operative time was 265.6 ± 31.72 min and flap-related complications were 10.0%, which included one fat necrosis (2.0%), three partial flap necrosis (6.0%) and one case of total flap failure (2.0%). Twenty flaps (40%) were harvested based on one perforator, while 27 flaps (54%) were based on two perforators and 3 flaps (6%) on three perforators. A total of 235 perforators were visualized intraoperatively while only 198 were identified using CTA, showing an accuracy of 84.3%. Patients and flaps characteristics among the two groups are summarized in Table 1.

Overall agreement rate between dominant perforators reported intraoperatively or those selected retrospectively on CTA (for Group A) or preoperatively (for Group B) was 81%, and formed the agreement group. The remaining 19% of disagreement rate, formed the non-agreement group (Table 2). Group-specific agreement rate was 82% in Group A (41 flaps), and 80% in Group B (40 flaps). Mean operative time was found to be higher in the agreement group than in the non-agreement group (260.9 vs. 250.8 min), though this was not deemed statistically significant [$p = .307$]. Conversely, complication rate was significantly higher in non-agreement group compared to the agreement group (15.8% vs. 3.7%) [$p = .046$]. Binary logistic regression analysis showed that none of the included variables statistically increases the complication rate (Table 3). Multiple regression analysis showed that CTA-guided approach, BMI > 30 kg/m² and harvesting more than one perforator were respectively associated with B-coefficient of 17.391 (2.430–32.351, 95% CI) [$p = .023$], 3.50 (0.640–6.379, 95% CI) [$p = .017$] and 18.887 (6.232–31.542, 95% CI) [$p = .004$]. This suggested that CTA-guided perforator selection, high BMI and the harvesting of more than one perforator predicted an increase in operative time (Table 4).

4 | DISCUSSION

In the last 15 years, several studies have focused on DIEP flap perfusion, attempting to correlate perforator selection with fewer flap-related complications (Hemdb et al., 2018; Lee & Mun, 2018; Mohan et al., 2016; Rozen, Ashton, Stella, Phillips, & Taylor, 2008d). Some authors found MRP to be overall more reliable, not interfering with the course of intercostal nerves, and providing a better blood supply to Holm's zone III (Bailey et al., 2010; Lee et al., 2015; Rozen et al., 2019; Rozen, Ashton, Murray, & Taylor, 2008c) while other authors suggested using LRP, since they usually have an easier dissection through shorter intramuscular courses (Kamali et al., 2017; Lee et al., 2010; Munhoz et al., 2004; Uda et al., 2015; Wong et al., 2010). In our opinion, selecting perforators should be evaluated on a case-by-case scenario, evaluating the many facets correlated to a clinical case. We have crystallized our experience in the form of an algorithm as an alternative to using preoperative CTA, except for cases where deemed strictly necessary (i.e., previous abdominal surgery). This could be particularly helpful in developing areas of the world where preoperative CTA is not used on a routine basis for undeniable costs and infrastructure requirements (Kaviani et al., 2020; Vania et al., 2020).

The *free-style technique* is based on clinical judgment, and choosing the dominant perforator by visual assessment of the veins' size in the perforator complex. Venous outflow is the major contributing factor for perfusion-related complication in DIEP flaps. This is supported by studies from Rubino et al. who emphasized the correlation between flap weight and vein capacitance, and postulated that although any artery could provide blood supply to a flap, not all veins could drain it (Figus et al., 2012; Rubino et al., 2009). Therefore, larger perforator veins should always be favored, and SIEV should be added when possible.

Regarding our flap design, markings are placed on the hemiabdomen contralaterally to the mastectomy side. Flap is rotated by 180° to place the thickest part of the flap at the lower breast pole, giving it a more natural look without needing to trim the upper pole, which may increase surgery duration and bleeding. In standard cases, we have always found sufficient perforators to perfuse the flap contralaterally and never needed to switch to the ipsilateral hemiabdomen. We did not use couplers to perform anastomoses in our patient population. Regarding recipient vessels, axillary vessels were used in all cases, as we found them to be the ideal recipient site because of reduced operative time and increased possibility to perform a second vein anastomosis. Our recipient vessels of choice are the circumflex scapular vessels, due to following advantages: easy dissection, larger vessel caliber, and optimal flap in-setting (Santanelli Di Pompeo et al., 2015).

The senior surgeon used CTA prior to beginning this study, and surgery duration did not decrease from using CTA after the initial learning curve. Using the *free-style technique*, the senior surgeon selected intraoperatively the same perforator which was deemed appropriate from CTA assessment in 41 instances for group A, forming the agreement group and showing a sensibility of 82% in detecting the dominant perforator. We reported a similar agreement rate of 80% when using the CTA-guided selection, which confirmed the validity of the *free-style* technique. In the CTA-guided group, the harvested perforator differed from the one selected preoperatively on CTA in 10 out of 50 cases (20%). Particularly, the plan was changed in seven instances due to intraoperative evidence of a larger perforator which differed from the one recognized on the CTA scan, and in three instances for intraoperative finding of two lateral perforators in series which were deemed appropriate for flap perfusion, without the need for muscle resection. This disagreement between preoperative CTA and intraoperative findings could be attributed to notorious CTA limitations in venous imaging, namely the difficulty in preoperatively identifying “vein-only” or inconsistent venous perforators (Gravvanis et al., 2014). There are some discrepancies in literature concerning the agreement rate of CTA versus intraoperative perforator selection. Some authors report as high as 95.2% (Casares Santiago et al., 2014), 74% (Haddock et al., 2020), or 67.3% (Boer et al., 2017) while others revealed nearly half of DIEP flaps had been harvested with changes from the surgical planning due to insufficient information from preoperative CTA (Keys et al., 2013). Haddock et al. (2020) found in their study that when used for preoperative planning, CTA reduced operative time by over 1 h. However their study only includes bilateral DIEP patients, which is relevant since there is no concern for fat necrosis of zone III. Additionally, the authors mention that no flap was lost in the course of the study although complications were not an endpoint. Finally, all procedures were performed by two senior attending surgeons who routinely use preoperative CTA. The authors speculate that in the blinded group, surgery duration might have been longer because the surgeons felt less confident raising a flap based on a single perforator, tending to isolate more perforators. We believe that experienced surgeons will feel more comfortable approaching the procedure based on whatever learning curve they faced, and their results will improve using a technique they are accustomed to. In our study we did not record individual surgical steps and this can

potentially limit our ability to compare our results to that from similar studies. Another potential limitation is how the individual who elaborated the *free-style* technique is the same individual who performed all surgeries and this may be a bias. Instead, we believe that an experienced surgeon will not taint the results with the effects of a learning curve. Finally, another element from Haddock's study worth reflecting upon is the patients' difference in BMI: mean BMI of 30, while our Italian patients were closer to 25. While it was possible to raise a hefty proportion of our flaps using a single perforator (34% of group A, 40% of group B), that might have been harder to achieve in a population with larger BMI since using a single perforator in these cases might have led to higher complication rate, especially fat necrosis or partial flap necrosis (Lee & Mun, 2016b). However, multivariate analysis from our study showed that BMI did not affect complications. Nevertheless, the relatively small sample population hinders us from drawing conclusions regarding the effect of BMI on complication rate, which has been previously addressed in literature as a potential risk factor for higher morbidity (Patterson et al., 2022).

Rozen and Ashton (2012) believe that limitations in CTA imaging are probably due to how challenging it is to obtain optimal timing for image-acquisition (Pellegrin et al., 2013). It is beyond any shadow of doubt that the CTA introduces a bias linked to the radiologist's expertise, which may not always be consistent. The *free-style technique* overcomes these imaging difficulties because it strictly relies on the surgeon's skill. Additionally, we found that in CTA approach, even after dissecting the dominant perforator, there comes a time where all other perforators need to be exposed in order to clamp then sever them, thus avoiding unnecessary bleeding. From our standpoint, this does not add time to dissection. Conversely, searching for one specific perforator within a multitude and having to make sure it is the right perforator identified on CTA may add extra time to dissection.

To ensure the homogeneity of cohort groups regarding flap weights and operative time, bilateral DIEP flaps BR were excluded from the study since their perforasome only include Holm's zones I and II, and bilateral procedures are notoriously longer. Additionally, to exclude the possible effect of a learning curve on the results we only included patients operated by the senior author. Upon univariate analysis, we found surgery duration to be statistically lower in the *free-style* group A where the senior surgeon used the *free-style* technique for perforator selection. Moreover, multiple regression analysis confirmed that other than increased BMI and harvest of more than one perforator, the CTA-guided approach statistically increases operative time.

We found higher complication rate in the CTA-guided group B (10% vs. 2%) and in the non-agreement group, although this was significant only for the latter. Nevertheless, multivariate regression analysis actually showed that no variables, including the non-agreement group, affect the incidence of complications. This result confirms that even changing the selections of perforator recommended by the CTA does not necessarily increase complications.

The second tenet of the *free-style technique* lies in choosing a second perforator whenever possible. In our series, selection of a second or third perforator occurred in 33 cases on 50 (66%) for Group A and

in 30 cases on 50 (60%) for Group B. As reported in previous vascular studies (Wong et al., 2010), we agree that when performing the reconstruction of a large breast, a second perforator should be selected, reducing the risk of partial flap and/or fat necrosis. A third perforator might help vascularity in large flaps, however what is gained in flap viability may be jeopardized by a reduction in the pedicle's arc of rotation and increase in its risk of kinking (Grover et al., 2014). Even if some authors suggested that one of the benefits of using a CTA-based plan include the selection of perforators with shorter intramuscular course (Casey et al., 2009; Teunis et al., 2013), limitations to this kind of information are still present, such as a steep learning curve to intramuscular vessel interpretation, usually influenced by the increased content of water in the muscle, the evaluation of which eventually lies in the hands of the surgeon rather than the radiologist (Keys et al., 2013).

This study attempted to convert experience derived from our learning curve into a standard approach which could be helpful when a preoperative CTA is not strictly mandatory, or when it cannot be used on a routine basis, which applies to areas of the world where the expenses of this diagnostic tool cannot be covered consistently.

5 | CONCLUSION

The *free-style technique* proved to be a useful tool for guiding DIEP flap harvest with good sensibility in detecting the dominant perforator suggested by CTA without statistically increasing complication rate and surgery duration. Even though larger comparative series are necessary, we believe that the current data attest to the reliability of our technique. Hopefully, our free-style approach can serve other breast microsurgeons well and can be reprised in future research efforts for further validation.

CONFLICT OF INTEREST STATEMENT

We, hereby certify, that to the best of our knowledge no financial support or benefits have been received by author or any co-author, by any member of our immediate family or any individual or entity with whom or with which we have a significant relationship from any commercial source which is related directly or indirectly to the scientific work which is reported on in the article. None of the authors has a financial interest in any of the products, devices, or drugs mentioned in this manuscript.

DATA AVAILABILITY STATEMENT

The data that support the findings of this study are available from the corresponding author upon reasonable request.

ORCID

Fabio Santanelli di Pompeo  <https://orcid.org/0000-0002-1217-3668>

Matteo Atzeni  <https://orcid.org/0000-0002-3910-0194>

Francesco Cilia  <https://orcid.org/0000-0001-7675-0578>

Guido Firmani  <https://orcid.org/0000-0002-5806-1530>

REFERENCES

- Allen, R. J., & Treece, P. (1994). Deep inferior epigastric perforator flap for breast reconstruction. *Annals of Plastic Surgery*, 32(1), 32–38. <https://doi.org/10.1097/0000637-199401000-00007>
- Bailey, S. H., Saint-Cyr, M., Wong, C., Mojallal, A., Zhang, K., Ouyang, D., Arbique, G., Trussler, A., & Rohrich, R. J. (2010). The single dominant medial row perforator DIEP flap in breast reconstruction: Three-dimensional perforasome and clinical results. *Plastic and Reconstructive Surgery*, 126(3), 739–751. <https://doi.org/10.1097/PRS.0b013e3181e5f844>
- Blondeel, P. N., Beyens, G., Verhaeghe, R., van Landuyt, K., Tonnard, P., Monstrey, S. J., & Matton, G. (1998). Doppler flowmetry in the planning of perforator flaps. *British Journal of Plastic Surgery*, 51(3), 202–209. [https://doi.org/10.1016/s0007-1226\(98\)80010-6](https://doi.org/10.1016/s0007-1226(98)80010-6)
- Boer, V. B., van Wingerden, J. J., Wever, C. F., Kardux, J. J., Beets, M. R., van der Zaag-Loonen, H. J., & Theuvenet, W. J. (2017). Concordance between preoperative computed tomography angiographic mapping and intraoperative perforator selection for deep inferior epigastric artery perforator flap breast reconstructions. *Gland Surgery*, 6(6), 620–629. <https://doi.org/10.21037/gs.2017.09.13>
- Casares Santiago, M., García-Tutor, E., Rodríguez Caravaca, G., Del Cerro González, J., Klein, L. M., & Alonso-Burgos, A. (2014). Optimising the preoperative planning of deep inferior epigastric perforator flaps for breast reconstruction. *European Radiology*, 24(9), 2097–2108. <https://doi.org/10.1007/s00330-014-3243-5>
- Casey, W. J., 3rd, Chew, R. T., Rebecca, A. M., Smith, A. A., Collins, J. M., & Pockaj, B. A. (2009). Advantages of preoperative computed tomography in deep inferior epigastric artery perforator flap breast reconstruction. *Plastic and Reconstructive Surgery*, 123(4), 1148–1155. <https://doi.org/10.1097/PRS.0b013e31819e23e1>
- Figus, A., Wade, R. G., Gorton, L., Rubino, C., Griffiths, M. G., & Ramakrishnan, V. V. (2012). Venous perforators in DIEAP flaps: An observational anatomical study using duplex ultrasonography. *Journal of Plastic, Reconstructive & Aesthetic Surgery*, 65(8), 1051–1059. <https://doi.org/10.1016/j.bjps.2012.02.026>
- Gill, P. S., Hunt, J. P., Guerra, A. B., Dellacroce, F. J., Sullivan, S. K., Boraski, J., Metzinger, S. E., Dupin, C. L., & Allen, R. J. (2004). A 10-year retrospective review of 758 DIEP flaps for breast reconstruction. *Plastic and Reconstructive Surgery*, 113(4), 1153–1160. <https://doi.org/10.1097/01.prs.0000110328.47206.50>
- Gravvanis, A., Tsoutsos, D., Papanikolaou, G., Diab, A., Lambropoulou, P., & Karakitsos, D. (2014). Refining perforator selection for deep inferior epigastric perforator flap: The impact of the dominant venous perforator. *Microsurgery*, 34(3), 169–176. <https://doi.org/10.1002/micr.22193>
- Grover, R., Nelson, J. A., Fischer, J. P., Kovach, S. J., Serletti, J. M., & Wu, L. C. (2014). The impact of perforator number on deep inferior epigastric perforator flap breast reconstruction. *Archives of Plastic Surgery*, 41(1), 63–70. <https://doi.org/10.5999/aps.2014.41.1.63>
- Haddock, N. T., Dumestre, D. O., & Teotia, S. S. (2020). Efficiency in DIEP flap breast reconstruction: The real benefit of computed tomographic angiography imaging. *Plastic and Reconstructive Surgery*, 146(4), 719–723. <https://doi.org/10.1097/PRS.0000000000007148>
- Hallock, G. G. (2003). Doppler sonography and color duplex imaging for planning a perforator flap. *Clinics in Plastic Surgery*, 30(3), 347–vi. [https://doi.org/10.1016/s0094-1298\(03\)00036-1](https://doi.org/10.1016/s0094-1298(03)00036-1)
- Hembd, A., Teotia, S. S., Zhu, H., & Haddock, N. T. (2018). Optimizing perforator selection: A multivariable analysis of predictors for fat necrosis and abdominal morbidity in DIEP flap breast reconstruction. *Plastic and Reconstructive Surgery*, 142(3), 583–592. <https://doi.org/10.1097/PRS.0000000000004631>
- Holm, C., Mayr, M., Höfter, E., & Ninkovic, M. (2006). Perfusion zones of the DIEP flap revisited: A clinical study. *Plastic and Reconstructive Surgery*, 117(1), 37–43. <https://doi.org/10.1097/01.prs.0000185867.84172.c0>
- Hummelink, S., Hameeteman, M., Hoogeveen, Y., Slump, C. H., Ulrich, D. J., & Schultze Kool, L. J. (2015). Preliminary results using a

- newly developed projection method to visualize vascular anatomy prior to DIEP flap breast reconstruction. *Journal of Plastic, Reconstructive & Aesthetic Surgery*, 68(3), 390–394. <https://doi.org/10.1016/j.bjps.2014.11.006>
- Kamali, P., Lee, M., Becherer, B. E., Wu, W., Curiel, D., Tran, B. N. N., Tobias, A. M., Lin, S. J., & Lee, B. T. (2017). Medial row perforators are associated with higher rates of fat necrosis in bilateral DIEP flap breast reconstruction. *Plastic and Reconstructive Surgery*, 140(1), 19–24. <https://doi.org/10.1097/PRS.00000000000003413>
- Kaviani, A., Tabary, M., Zand, S., Araghi, F., & Nouraei, M. (2020). A study on breast reconstruction in a developing country: A comprehensive evaluation of the techniques and oncologic outcomes. *Annals of Plastic Surgery*, 84(5), 512–517. <https://doi.org/10.1097/SAP.0000000000002125>
- Keys, K. A., Louie, O., Said, H. K., Neligan, P. C., & Mathes, D. W. (2013). Clinical utility of CT angiography in DIEP breast reconstruction. *Journal of Plastic, Reconstructive & Aesthetic Surgery*, 66(3), e61–e65. <https://doi.org/10.1016/j.bjps.2012.09.025>
- Klasson, S., Svensson, H., Malm, K., Wassélius, J., & Velander, P. (2015). Preoperative CT angiography versus Doppler ultrasound mapping of abdominal perforator in DIEP breast reconstructions: A randomized prospective study. *Journal of Plastic, Reconstructive & Aesthetic Surgery*, 68(6), 782–786. <https://doi.org/10.1016/j.bjps.2015.02.002>
- Laporta, R., Longo, B., Sorotos, M., Farcomeni, A., Amorosi, V., & Santanelli di Pompeo, F. (2017a). Time-dependent factors in DIEP flap breast reconstruction. *Microsurgery*, 37(7), 793–799. <https://doi.org/10.1002/micr.30203>
- Laporta, R., Longo, B., Sorotos, M., Pagnoni, M., & Santanelli Di Pompeo, F. (2015). DIEP flap sentinel skin paddle positioning algorithm. *Microsurgery*, 35(2), 91–100. <https://doi.org/10.1002/micr.22269>
- Laporta, R., Longo, B., Sorotos, M., & Santanelli di Pompeo, F. (2017b). Tips and tricks for DIEP flap breast reconstruction in patients with previous abdominal scar. *Microsurgery*, 37(4), 282–292. <https://doi.org/10.1002/micr.22457>
- Lee, B. T., Chen, C., Nguyen, M. D., Lin, S. J., & Tobias, A. M. (2010). A new classification system for muscle and nerve preservation in DIEP flap breast reconstruction. *Microsurgery*, 30(2), 85–90. <https://doi.org/10.1002/micr.20717>
- Lee, K. T., Lee, J. E., Nam, S. J., Han, B. K., & Mun, G. H. (2015). Is Holm Zone III safe from fat necrosis in medial row perforator-based deep inferior epigastric perforator flaps? *Microsurgery*, 35(4), 272–278. <https://doi.org/10.1002/micr.22328>
- Lee, K. T., & Mun, G. H. (2016a). Volumetric planning using computed tomographic angiography improves clinical outcomes in DIEP flap breast reconstruction. *Plastic and Reconstructive Surgery*, 137(5), 771 e–780 e. <https://doi.org/10.1097/PRS.00000000000002045>
- Lee, K. T., & Mun, G. H. (2016b). Effects of obesity on postoperative complications after breast reconstruction using free muscle-sparing transverse rectus abdominis myocutaneous, deep inferior epigastric perforator, and superficial inferior epigastric artery flap: A systematic review and meta-analysis. *Annals of Plastic Surgery*, 76(5), 576–584. <https://doi.org/10.1097/SAP.0000000000000400>
- Lee, K. T., & Mun, G. H. (2018). Perfusion of the DIEP flaps: A systematic review with meta-analysis. *Microsurgery*, 38(1), 98–108. <https://doi.org/10.1002/micr.30024>
- Masia, J., Clavero, J. A., Larrañaga, J. R., Alomar, X., Pons, G., & Serret, P. (2006). Multidetector-row computed tomography in the planning of abdominal perforator flaps. *Journal of Plastic, Reconstructive & Aesthetic Surgery*, 59(6), 594–599. <https://doi.org/10.1016/j.bjps.2005.10.024>
- Mohan, A. T., Zhu, L., Wang, Z., Vijayasekaran, A., & Saint-Cyr, M. (2016). Techniques and perforator selection in single, dominant DIEP flap breast reconstruction: Algorithmic approach to maximize efficiency and safety. *Plastic and Reconstructive Surgery*, 138(5), 790 e–803 e. <https://doi.org/10.1097/PRS.00000000000002716>
- Moon, H. K., & Taylor, G. I. (1988). The vascular anatomy of rectus abdominis musculocutaneous flaps based on the deep superior epigastric system. *Plastic and Reconstructive Surgery*, 82(5), 815–832. <https://doi.org/10.1097/00006534-19881000-00014>
- Munhoz, A. M., Ishida, L. H., Sturtz, G. P., Cunha, M. S., Montag, E., Saito, F. L., Gemperli, R., & Ferreira, M. C. (2004). Importance of lateral row perforator vessels in deep inferior epigastric perforator flap harvesting. *Plastic and Reconstructive Surgery*, 113(2), 517–524. <https://doi.org/10.1097/01.PRS.0000100812.37842.A8>
- Patterson, C. W., Palines, P. A., Bartow, M. J., Womac, D. J., Zampell, J. C., Dupin, C. L., St Hilaire, H., & Stalder, M. W. (2022). Stratification of surgical risk in DIEP breast reconstruction based on classification of obesity. *Journal of Reconstructive Microsurgery*, 38(1), 1–9. <https://doi.org/10.1055/s-0041-1727202>
- Pellegrin, A., Stocca, T., Belgrano, M., Bertolotto, M., Pozzi-Mucelli, F., Marij Arnez, Z., & Cova, M. A. (2013). Preoperative vascular mapping with multislice CT of deep inferior epigastric artery perforators in planning breast reconstruction after mastectomy. *La Radiologia Medica*, 118(5), 732–743. <https://doi.org/10.1007/s11547-012-0887-5>
- Phillips, T. J., Stella, D. L., Rozen, W. M., Ashton, M., & Taylor, G. I. (2008). Abdominal wall CT angiography: A detailed account of a newly established preoperative imaging technique. *Radiology*, 249(1), 32–44. <https://doi.org/10.1148/radiol.2483072054>
- Pratt, G. F., Rozen, W. M., Chubb, D., Ashton, M. W., Alonso-Burgos, A., & Whitaker, I. S. (2012). Preoperative imaging for perforator flaps in reconstructive surgery: A systematic review of the evidence for current techniques. *Annals of Plastic Surgery*, 69(1), 3–9. <https://doi.org/10.1097/SPA.0b013e318222b7b7>
- Rao, A., & Saadeh, P. B. (2014). Defining fat necrosis in plastic surgery. *Plastic and Reconstructive Surgery*, 134, 1202–1212.
- Renzulli, M., Clemente, A., Brocchi, S., Gelati, C., Zanotti, S., Pizzi, C., Tassone, D., Cappabianca, S., Cipriani, R., & Golfieri, R. (2020). Preoperative computed tomography assessment for a deep inferior epigastric perforator (DIEP) flap: A new easy technique from the Bologna experience. *Acta Radiologica*, 62, 1283–1289. <https://doi.org/10.1177/0284185120963899>
- Rozen, W. M., & Ashton, M. W. (2009). Improving outcomes in autologous breast reconstruction. *Aesthetic Plastic Surgery*, 33(3), 327–335. <https://doi.org/10.1007/s00266-008-9272-1>
- Rozen, W. M., & Ashton, M. W. (2012). The venous anatomy of the abdominal wall for deep inferior epigastric artery (DIEP) flaps in breast reconstruction. *Gland Surgery*, 1(2), 92–110. <https://doi.org/10.3978/j.issn.2227-684X.2012.06.01>
- Rozen, W. M., Ashton, M. W., Grinsell, D., Stella, D. L., Phillips, T. J., & Taylor, G. I. (2008b). Establishing the case for CT angiography in the preoperative imaging of abdominal wall perforators. *Microsurgery*, 28(5), 306–313. <https://doi.org/10.1002/micr.20496>
- Rozen, W. M., Ashton, M. W., Le Roux, C. M., Pan, W. R., & Corlett, R. J. (2010b). The perforator angiosome: A new concept in the design of deep inferior epigastric artery perforator flaps for breast reconstruction. *Microsurgery*, 30(1), 1–7. <https://doi.org/10.1002/micr.20684>
- Rozen, W. M., Ashton, M. W., Murray, A. C. A., & Taylor, G. I. (2008c). Avoiding denervation of rectus abdominis in DIEP flap harvest: The importance of medial row perforators. *Plastic and Reconstructive Surgery*, 122(3), 710–716. <https://doi.org/10.1097/PRS.0b013e318180ed8b>
- Rozen, W. M., Ashton, M. W., Stella, D. L., Phillips, T. J., Grinsell, D., & Taylor, G. I. (2008a). The accuracy of computed tomographic angiography for mapping the perforators of the deep inferior epigastric artery: A blinded, prospective cohort study. *Plastic and Reconstructive Surgery*, 122(4), 1003–1009. <https://doi.org/10.1097/PRS.0b013e3181845994>
- Rozen, W. M., Ashton, M. W., Stella, D. L., Phillips, T. J., & Taylor, G. I. (2008d). The accuracy of computed tomographic angiography for mapping the perforators of the DIEA: A cadaveric study. *Plastic and Reconstructive Surgery*, 122(2), 363–369. <https://doi.org/10.1097/PRS.0b013e31817d61ed>
- Rozen, W. M., Bhullar, H. K., & Hunter-Smith, D. (2019). How to assess a CTA of the abdomen to plan an autologous breast reconstruction.

- Gland Surgery*, 8(Suppl 4), S291–S296. <https://doi.org/10.21037/gs.2019.04.10>
- Rozen, W. M., Garcia-Tutor, E., Alonso-Burgos, A., Acosta, R., Stillaert, F., Zubieta, J. L., Hamdi, M., Whitaker, I. S., & Ashton, M. W. (2010a). Planning and optimising DIEP flaps with virtual surgery: The Navarra experience. *Journal of Plastic, Reconstructive & Aesthetic Surgery*, 63(2), 289–297. <https://doi.org/10.1016/j.bjps.2008.10.007>
- Rubino, C., Ramakrishnan, V., Figus, A., Bulla, A., Coscia, V., & Cavazzuti, M. A. (2009). Flap size/flow rate relationship in perforator flaps and its importance in DIEAP flap drainage. *Journal of Plastic, Reconstructive & Aesthetic Surgery*, 62(12), 1666–1670. <https://doi.org/10.1016/j.bjps.2008.05.045>
- Santanelli Di Pompeo, F., Longo, B., Sorotos, M., Pagnoni, M., & Laporta, R. (2015). The axillary versus internal mammary recipient vessel sites for breast reconstruction with DIEP flaps: A retrospective study of 256 consecutive cases. *Microsurgery*, 35(1), 34–38. <https://doi.org/10.1002/micr.22266>
- Santanelli, F., Longo, B., Cagli, B., Pugliese, P., Sorotos, M., & Paolini, G. (2015). Predictive and protective factors for partial necrosis in DIEP flap breast reconstruction: Does nulliparity bias flap viability? *Annals of Plastic Surgery*, 74(1), 47–51. <https://doi.org/10.1097/SAP.0b013e31828d994d>
- Schaverien, M. V., & Butler, C. E. (2017). Complications in DIEP flap breast reconstruction after mastectomy for breast cancer: A prospective cohort study comparing unilateral and bilateral reconstructions. *Annals of Surgical Oncology*, 24(6), 1451–1453. <https://doi.org/10.1245/s10434-017-5809-3>
- Teunis, T., Heerma van Voss, M. R., Kon, M., & van Maurik, J. F. (2013). CT-angiography prior to DIEP flap breast reconstruction: A systematic review and meta-analysis. *Microsurgery*, 33(6), 496–502. <https://doi.org/10.1002/micr.22119>
- Uda, H., Tomioka, Y. K., Sarukawa, S., Sunaga, A., & Sugawara, Y. (2015). Comparison of abdominal wall morbidity between medial and lateral row-based deep inferior epigastric perforator flap. *Journal of Plastic, Reconstructive & Aesthetic Surgery*, 68(11), 1550–1555. <https://doi.org/10.1016/j.bjps.2015.06.028>
- Vania, R., Pranata, R., Berfan, A., & Budiman, B. (2020). Can pedicled TRAM flap be a satisfying alternative to free TRAM in developing countries?—A systematic review and meta-analysis. *Acta Chirurgica Belgica*, 120(6), 375–382. <https://doi.org/10.1080/00015458.2019.1637601>
- Wade, R. G., Watford, J., Wormald, J. C. R., Bramhall, R. J., & Figus, A. (2018). Perforator mapping reduces the operative time of DIEP flap breast reconstruction: A systematic review and meta-analysis of pre-operative ultrasound, computed tomography and magnetic resonance angiography. *Journal of Plastic, Reconstructive & Aesthetic Surgery*, 71(4), 468–477. <https://doi.org/10.1016/j.bjps.2017.12.012>
- Wong, C., Saint-Cyr, M., Mojallal, A., Schaub, T., Bailey, S. H., Myers, S., Brown, S., & Rohrich, R. J. (2010). Perforasomes of the DIEP flap: Vascular anatomy of the lateral versus medial row perforators and clinical implications. *Plastic and Reconstructive Surgery*, 125(3), 772–782. <https://doi.org/10.1097/PRS.0b013e3181cb63e0>
- Wu, L. C., Bajaj, A., Chang, D. W., & Chevray, P. M. (2008). Comparison of donor-site morbidity of SIEA, DIEP, and muscle-sparing TRAM flaps for breast reconstruction. *Plastic and Reconstructive Surgery*, 122(3), 702–709. <https://doi.org/10.1097/PRS.0b013e3181823c15>

How to cite this article: Santanelli di Pompeo, F., Paolini, G., D'Orsi, G., Atzeni, M., Catalano, C., Cannavale, G., Cilia, F., Firmani, G., & Sorotos, M. (2023). Free-style technique versus computed tomographic angiography-guided perforator selection in deep inferior epigastric perforator flap harvest: A prospective clinical study. *Microsurgery*, 1–10. <https://doi.org/10.1002/micr.31031>