



## Ectopia cordis: prenatal diagnosis, perinatal outcomes, and postnatal follow-up of an international multicenter cohort case series

Edward Araujo Júnior, Luiza Graça Coutinho, Nathalie Jeanne Bravo-Valenzuela, Patrícia Aquino, Luciane Alves da Rocha, Giuseppe Rizzo, Gabriele Tonni, Maria Respondek-Liberska, Maciej Slodki, Aline Wolter & Roland Axt-Fliedner

**To cite this article:** Edward Araujo Júnior, Luiza Graça Coutinho, Nathalie Jeanne Bravo-Valenzuela, Patrícia Aquino, Luciane Alves da Rocha, Giuseppe Rizzo, Gabriele Tonni, Maria Respondek-Liberska, Maciej Slodki, Aline Wolter & Roland Axt-Fliedner (2023) Ectopia cordis: prenatal diagnosis, perinatal outcomes, and postnatal follow-up of an international multicenter cohort case series, *The Journal of Maternal-Fetal & Neonatal Medicine*, 36:1, 2203791, DOI: [10.1080/14767058.2023.2203791](https://doi.org/10.1080/14767058.2023.2203791)

**To link to this article:** <https://doi.org/10.1080/14767058.2023.2203791>



© 2023 The Author(s). Published by Informa UK Limited, trading as Taylor & Francis Group



Published online: 20 Apr 2023.



Submit your article to this journal [↗](#)






View related articles [↗](#)



View Crossmark data [↗](#)

## Ectopia cordis: prenatal diagnosis, perinatal outcomes, and postnatal follow-up of an international multicenter cohort case series

Edward Araujo Júnior<sup>a,b</sup> , Luiza Graça Coutinho<sup>a</sup>, Nathalie Jeanne Bravo-Valenzuela<sup>c,d</sup>, Patrícia Aquino<sup>d</sup>, Luciane Alves da Rocha<sup>e</sup>, Giuseppe Rizzo<sup>b,f</sup>, Gabriele Tonni<sup>g</sup> , Maria Respondek-Liberska<sup>b,h</sup>, Maciej Slodki<sup>b,h,i</sup> , Aline Wolter<sup>i</sup> and Roland Axt-Fliedner<sup>b,j</sup>

<sup>a</sup>Department of Obstetrics, Paulista School of Medicine, Federal University of São Paulo (EPM-UNIFESP), São Paulo, Brazil;

<sup>b</sup>The International Prenatal Cardiology Collaboration Group, Lodz, Poland; <sup>c</sup>Department of Pediatrics, Pediatric Cardiology, School of Medicine, Federal University of Rio de Janeiro, Rio de Janeiro, Brazil; <sup>d</sup>Postgraduate Program in Health Sciences (Fetal Medicine), Itinerant Continuing Medical Education, Rio de Janeiro, Brazil; <sup>e</sup>Postgraduate Program in Health Sciences, Medical School, Federal University of Amazonas (UFAM), Manaus, Brazil; <sup>f</sup>Department of Obstetrics and Gynecology, Fondazione Policlinico Tor Vergata, Università di Roma Tor Vergata, Rome, Italy; <sup>g</sup>Department of Obstetrics and Neonatology, Istituto di Ricovero e Cura a Carattere Scientifico (IRCCS), AUSL di Reggio Emilia, Reggio Emilia, Italy; <sup>h</sup>Prenatal Cardiology Department, Research Institute Polish Mother's Memorial Hospital, Lodz, Poland; <sup>i</sup>Faculty of Health Sciences, The Masovian State University, Plock, Poland; <sup>j</sup>Department of Obstetrics and Gynecology, Division of Prenatal Medicine, University-Hospitals Giessen and Marburg Campus, Giessen, Germany

### ABSTRACT

**Objective:** This study aimed to analyze prenatal diagnosis, perinatal outcomes, and postnatal follow-up in fetuses with ectopia cordis (EC).

**Methods:** This retrospective analysis accessed 31 patients with EC who were either diagnosed or referred to a tertiary Fetal Medicine centers for EC diagnosis in Brazil, Germany, Italy, and Poland. We analyzed prenatal diagnosis, perinatal outcomes, and follow-up in these patients.

**Results:** Our study included a cohort of 31 fetuses with EC, 4 and 27 of whom had partial and complete protrusion of the heart through a ventral defect in the thoracoabdominal wall, respectively. EC was diagnosed by fetal echocardiography at a mean gestational age of  $20.3 \pm 8.6$  weeks (range, 8–35 weeks). Of the four cases, in which the karyotype was performed, all of them had a normal result (1 – 46,XX and 3 – 46,XY). Five patients showed conotruncal abnormalities and six ventricular septal defects. Termination of pregnancy (TOP) was performed in 15 cases (48%) and seven pregnant women had spontaneous fetal demise (22.5%). Of the seven fetuses that were born alive, four of them died, and three infants underwent surgery. Among these three infants, all of them survived, one was 5 months, 13 years old and 29 years old at the time of study completion.

**Conclusions:** Ectopia cordis is associated with high mortality rates and intracardiac/extra-cardiac defects. Ventricular septal defects and conotruncal anomalies were the more common intracardiac defects associated with EC. However, in this cohort of fetuses with EC the incidence of PC was lower than reported in the literature.

### ARTICLE HISTORY

Received 20 May 2022

Revised 10 April 2023

Accepted 12 April 2023

### KEYWORDS

Ectopia cordis; pentalogy of Cantrell; omphalocele; chest wall deformity; congenital heart disease

## Introduction

Ectopia cordis (EC) is a rare defect where in a portion of the heart or its entirety is located outside the thoracic cavity. When the sternum fails to develop, a thoracic wall defect may arise. The annual incidence of EC ranges from 5.5 to 7.9 per million live births. EC accounts for 0.1% of all heart defects [1]. In 1671, Neil Stensen reported the first known case of EC, but only in 1706, the anomaly was described for the first time by Haller [2,3].

Despite being the most frequently identified fetal heart anomaly when present in the first trimester ultrasound, EC is usually diagnosed using conventional ultrasound in the second trimester [4–6]. It can occur either in the isolated form or as associated with other malformations [1]. Internal cardiac anomalies are commonly observed in fetuses with EC [7]. The association between EC and omphalocele may suggest pentalogy of Cantrell (PC), which consists of a group of anatomical malformations resulting from five midline birth

**CONTACT** Edward Araujo Júnior  [araujojred@terra.com.br](mailto:araujojred@terra.com.br)  Rua Belchior de Azevedo, 156 apto. 111 Torre Vitoria, CEP 05089-030, São Paulo, SP, Brazil.

© 2023 The Author(s). Published by Informa UK Limited, trading as Taylor & Francis Group

This is an Open Access article distributed under the terms of the Creative Commons Attribution License (<http://creativecommons.org/licenses/by/4.0/>), which permits unrestricted use, distribution, and reproduction in any medium, provided the original work is properly cited. The terms on which this article has been published allow the posting of the Accepted Manuscript in a repository by the author(s) or with their consent.

defects such as lower sternum and abdominal wall defects (including omphalocele), anterior congenital diaphragmatic hernia, diaphragmatic pericardial defects, and intracardiac defects [8,9].

A wide spectrum of anatomical variations can occur in EC because the heart pulses directly beneath the skin to completely move out of the cavity. In general, EC can be categorized depending on the location of the heart as cervical, cervicothoracic, thoracic, thoracoabdominal, or abdominal [10]. However, the etiology of EC is not fully understood, and there are assorted theories. The first theory involves primary failure of heart descent and midline fusion in early embryological development. Another theory stated that EC may occur due to rupture of the chorion and/or yolk sac, leading to the formation of fibrous bands that prevent midline fusion because of the compression. The latest theory affirms that this may occur due to the lack of a functional bone morphogenetic protein (BMP2) gene, which mediates heart tube formation and ventral body wall closure [3,10,11].

This study aimed to analyze the prenatal diagnosis of EC, including perinatal outcomes and follow-up, in an international multicenter cohort of case series.

## Methods

Between 1992 and 2021, 31 fetuses with EC were identified at the Fetal Medicine Unit of tertiary centers in Brazil, Germany, Italy, and Poland. EC was defined as a heart located outside the thorax. Two cases already have been published previously [4,8].

All fetal echocardiographic examinations were performed by a perinatal cardiologist with similar experience in fetal echocardiography and reviewed by one specialist in perinatal cardiology per each participant center. The examinations were performed through the transabdominal route. The fetal heart was examined using standardized imaging techniques including two-dimensional echocardiography, spectral Doppler, M-mode, and color Doppler flow mapping. Fetal echocardiographic and ultrasound data such as detailed cardiac and extracardiac anomalies were collected from patient's health records.

Maternal data were collected from archived records within and outside of the institution. We also collected data on fetal structural cardiac defects, indication of echocardiography, whether the EC had complete or partial protrusion, gestational age at diagnosis, and diagnosis of non-cardiac fetal abnormalities (both structural and genetic or chromosomal). Data of perinatal outcomes such as termination of pregnancy

(TOP), spontaneous fetal demise, and gestational age at each event were also collected.

In liveborn patients prenatally diagnosed with EC, we collected data on the diagnoses of cardiac and non-cardiac conditions, whether the newborn underwent cardiac surgery, and the outcomes before and/or after the procedure. In all liveborn cases, the prenatal diagnosis of structural heart defects (EC and intracardiac defects) was confirmed after birth by echocardiography and afterward the extracardiac malformations were by postnatal physical examination and imaging exams. Only three patients had their diagnosis confirmed by necropsy (two TOP and one neonatal death).

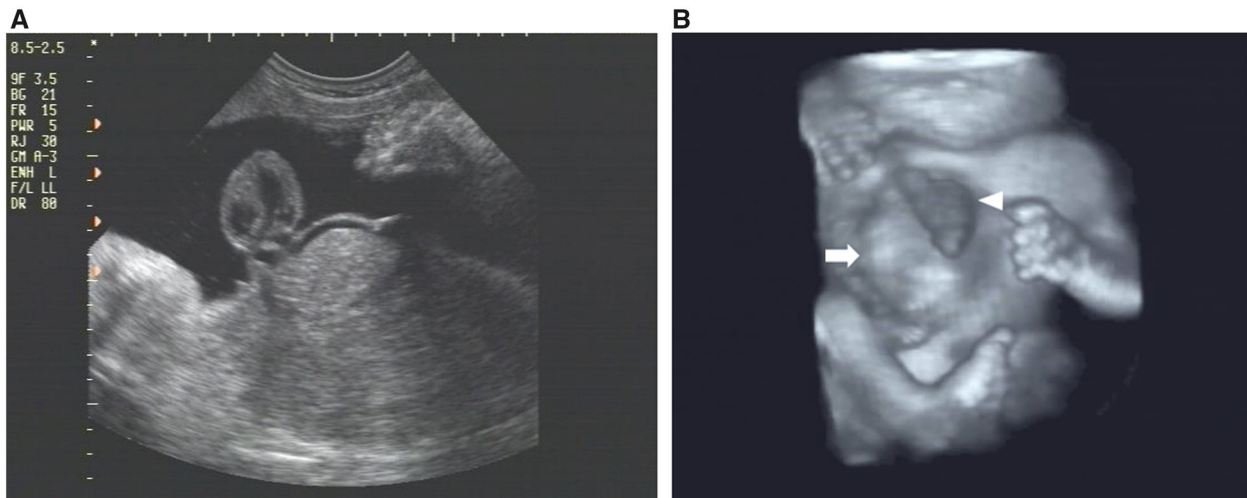
## Results

Our study included a cohort of 31 fetuses with EC, four of whom had partial EC and 27 had complete protrusion of the heart through a ventral defect in the thoracoabdominal wall. [Figures 1](#) and [2](#) demonstrate images of complete and partial EC in both two- and three-dimensional ultrasound. EC was diagnosed by fetal echocardiography at a mean gestational age of  $20.3 \pm 8.6$  weeks (range, 8–37 weeks) and the mean maternal age was  $28 \pm 8.4$  years (range, 19–42 years). The patients were referred for fetal echocardiography about 1–2 weeks after the detection of the EC by obstetric ultrasonography.

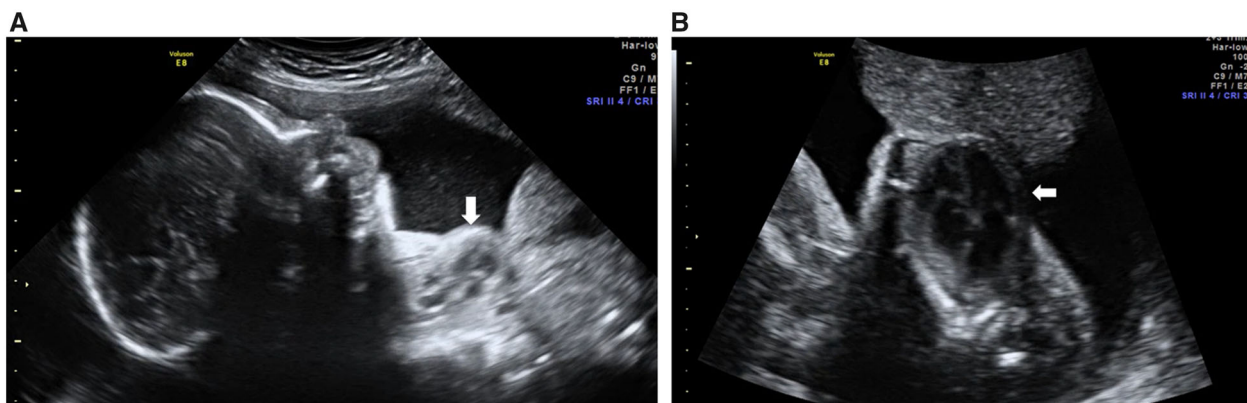
Four fetuses had a normal karyotype; however, 27 fetuses did not have their karyotype analyzed. Some issues related to genetic testing such as difficulties on accessing genetic testing in some centers, parental refusal for genetic material collecting, TOP and spontaneous fetal demise may explain the small number of fetuses whose karyotype were analyzed. Normal karyotype tests (4 – 46, XY) were observed in cases 8, 27, 28, and 31. The preimplantation screening test was performed in case 8, who was a fetus with EC associated with PC. In cases 27 and 28, the EC was not associated with cardiac defects and/or PC.

Regarding to the perinatal outcomes, one patient was lost of follow-up (case 29). Fifteen mothers elected to TOP. In almost all of them, the EC was associated with intracardiac anomalies and/or PC (cases 5, 7, 11, 13, 17, 18, 20, 21, 22, 23, 27, 28, and 30) neonatal death. [Figure 3](#) shows the postnatal images of the cases 5 and 11. Perinatal outcomes of this cohort are described in [Figure 4](#) and [Table 1](#).

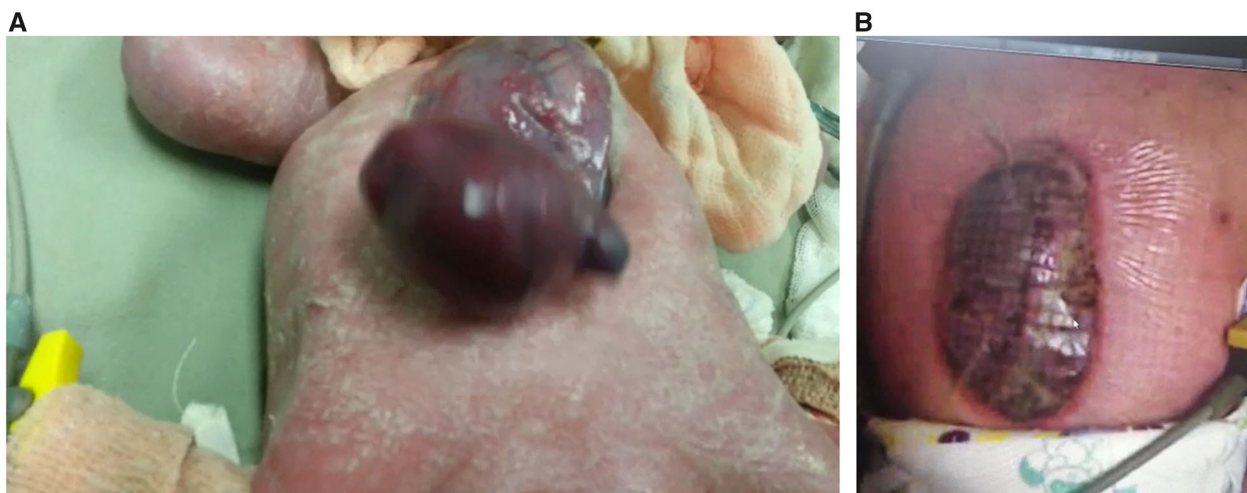Four patients had conotruncal abnormalities, i.e. two had tetralogy of Fallot, one had truncus arteriosus, and three had a double-outlet right ventricle.



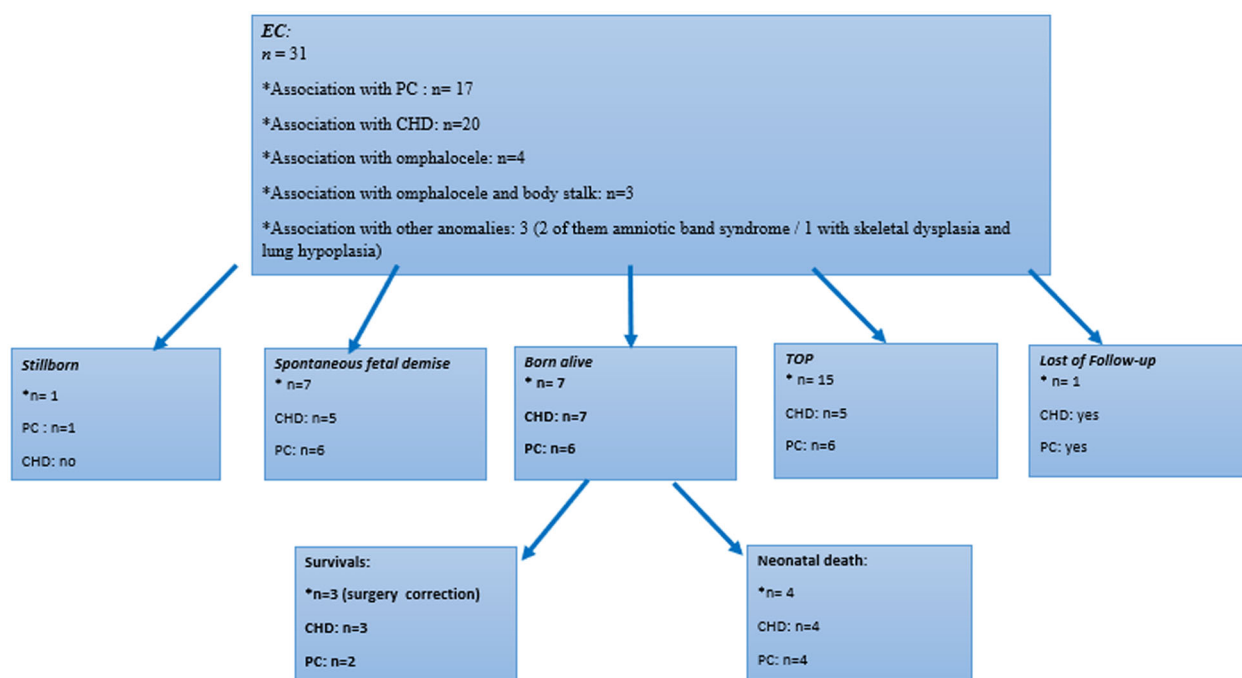
**Figure 1.** #Case 1. (A) Two-dimensional ultrasound in the sagittal view showing the complete ectopia cordis at 33 weeks of gestation. (B) Three-dimensional ultrasound in the rendering mode showing the ectopia cordis (head arrow) and the omphalocele (arrow) at 34 weeks of gestation.



**Figure 2.** #Case 2. Two-dimensional ultrasound in the sagittal (A) and four-chamber (B) views showing the partial ectopia cordis (arrow) at 29 weeks of gestation.



**Figure 3.** Immediate postnatal images of the newborns of the #cases 3 (A) and 4 (B) showing the complete ectopia cordis.



**Figure 4.** Flowchart demonstrating the EC case series: characteristics and perinatal outcomes. PC: pentalogy of Cantrell; EC: ectopia cordis; *n*: number of cases; CHD: congenital heart disease; TOP: termination of pregnancy.

Ventricular septal defect was diagnosed in four fetuses, and in two of them the VSD was associated with an overriding of the aorta. Indeed, all the types of intracardiac anomalies associated with EC that were observed in this data are described in Table 1.

Termination of pregnancy occurred in 15 cases (48%) and spontaneous fetal demise in seven cases (22.5%). Only three patients had undergone necropsy, which confirmed the prenatal diagnosis (cases 1, 27, and 28).

Seven of 31 fetuses were born alive. Almost all patients with EC who were born alive were diagnosed with PC (6/7). Four of them had neonatal death, while three patients underwent surgery to correct the defects and all of them survived after surgery. Of the four neonates who died without surgery, one died shortly due to severe intracardiac defects (tricuspid atresia with pulmonary valve stenosis) and the others did not undergo surgery due to the lack of a team specialized in EC. Regarding intracardiac defects, these patients had right ventricle outflow tract defects (one had tetralogy of Fallot, one had pulmonary valve atresia with VSD, and one had pulmonary artery enlargement). Neonatal death (shortly after birth) and intracardiac defects were more prevalent in fetuses with EC associated with PC than in cases with no PC. Among the survivors, two of them had PC. Apart from the PC defects, these patients had a pulmonary artery enlargement and pulmonary atresia with VSD (cases

15 and 31, respectively). The other newborn had an omphalocele in addition to the tetralogy of Fallot (case 26). All of them, successfully underwent surgery, and one was 5 months, 13 years old and 29 years old at the time of study completion. All survivors are in a good condition and the younger one is waiting for second stage sternum reconstruction. Figure 5 shows the intraoperative postnatal surgery of the case 3. Figure 6 shows the magnetic resonance imaging T2-weight in sagittal view of the case 6. Table 1 summarizes the retrospective cohort of 31 EC cases, including information on the prenatal diagnosis, perinatal outcomes, and postnatal follow-up. Associated anomalies, prenatal diagnosis, perinatal outcomes, and postnatal follow-up of the 31 cases of EC are demonstrated in Figure 4 and Table 1.

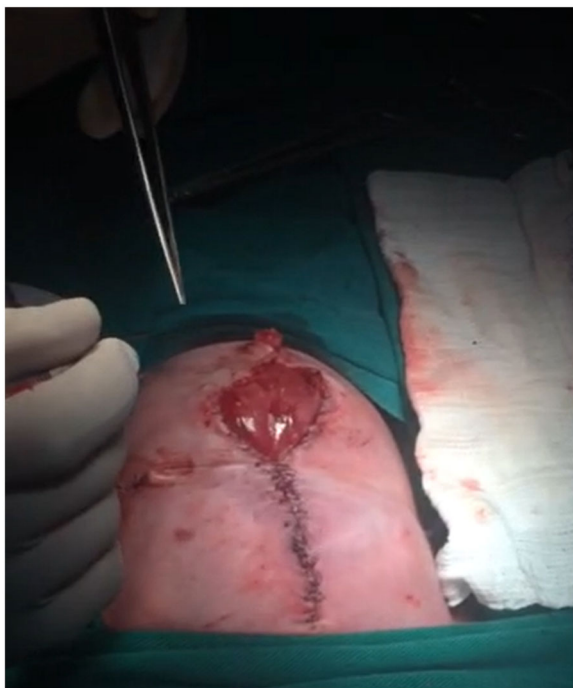## Discussion

The association of EC and omphalocele may be suggestive of PC but does not constitute the diagnosis. PC is usually defined as a group of five types of malformations including: omphalocele, anterior congenital diaphragmatic hernia, diaphragmatic pericardial defects, and EC associated with intracardiac defects. Previous studies have demonstrated that approximately 75–77% of fetuses with EC have PC [10,12]. Also taking into account the above criteria, our study showed that only 17 (54.8%) fetuses with EC were

**Table 1.** Prenatal diagnosis, perinatal outcomes, and postnatal follow-up of 31 cases of ectopia cordis.

Case	City (country)	Maternal age (years)	Diagnosis GA (weeks)	Type of EC	Karyotype	Necropsy	Intracardiac anomalies	Postnatal surgery	Perinatal outcomes and postnatal follow-up	Association with PC
1	Sao Paulo (Brazil)	27	33	Complete	-	Yes	Ventricular septal defect	No	Neonatal death	Yes
2	Sao Paulo (Brazil)	32	29	Partial	-	-	No	No	Stillborn	Yes
3	Sao Paulo (Brazil)	42	22	Complete	-	-	Ventricular septal defect	Yes	Neonatal death	Yes
4	Manaus (Brazil)	20	28	Complete	-	-	Tricuspid atresia, pulmonary valve stenosis	No	Neonatal death	Yes
5	Rio de Janeiro (Brazil)	31	24	Partial	-	-	Double right ventricle outlet (Taussig-Bing)	-	Termination of pregnancy	Yes
6	Rio de Janeiro (Brazil)	42	28	Complete	-	-	Ventricular septal defect	No	Neonatal death	Yes
7	Rome (Italy)	26	8	Complete	-	-	-	-	Termination of pregnancy	Yes
8	Reggio Emilia (Italy)	45	11	Complete	46, XY (preimplantation) ICS-FIVET from ovum-donation	-	-	-	Termination of pregnancy	Yes
9	Lodz (Poland)	37	27	Complete	-	-	Ventricular septal defect overriding aorta	No	Fetal death	Yes
10	Lodz (Poland)	29	30	Complete	-	-	Double right ventricle outlet (type VSD)	No	Fetal death	No (omphalocele)
11	Lodz (Poland)	27	31	Complete	-	-	Pulmonary venous anomalous return	No	Termination of pregnancy	No (omphalocele)
12	Lodz (Poland)	27	25	Complete	-	-	No	No	Fetal death	Yes
13	Lodz (Poland)	33	17	Complete	-	-	Atrioventricular septal defect	No	Termination of pregnancy	No (amniotic band syndrome)
14	Lodz (Poland)	20	20	Complete	-	-	No	No	Termination of pregnancy	Yes
15	Lodz (Poland)	-	15	Complete	-	-	Pulmonary artery enlargement	Yes	Alive	Yes
16	Lodz (Poland)	19	16	Complete	-	-	Truncus arteriosus	No	Fetal death	No (amniotic band syndrome)
17	Lodz (Poland)	27	17	Complete	-	-	Ventricular septal defect	No	Termination of pregnancy	No (skeletal dysplasia, lung hypoplasia)
18	Lodz (Poland)	20	13	Complete	-	-	Tetralogy of fallot	No	Termination of pregnancy	Yes
19	Lodz (Poland)	24	13	Complete	-	-	Ventricular septal defect overriding aorta	No	Fetal death	Yes
20	Lodz (Poland)	28	30	Complete	-	-	Double right ventricle outlet (type Taussig-Bing)	No	Termination of pregnancy	No
21	Lodz (Poland)	-	13	Complete	-	-	No	No	Termination of pregnancy	No (omphalocele)
22	Lodz (Poland)	32	14	Complete	-	-	No	No	Termination of pregnancy	No
23	Lodz (Poland)	23	22	Complete	-	-	No	No	Termination of pregnancy	Yes
24	Lodz (Poland)	32	15	Complete	-	-	Atrioventricular septal defect	No	Fetal death	No
25	Lodz (Poland)	30	24	Complete	-	-	Pulmonary atresia + VSD	No	Fetal death	No
26	Lodz (Poland)	22	37	Complete	-	-	Tetralogy of fallot	Yes	Alive	No (omphalocele)
27	Giessen (Germany)	39	11	Complete	46, XX	Yes	No	No	Termination of pregnancy	No
28	Giessen (Germany)	31	9	Complete	46, XY	Yes	No	No	Termination of pregnancy	No (body stalk syndrome)
29	Giessen (Germany)	30	35	Partial	-	-	Pulmonary atresia + VSD	?	Lost follow-up	Yes
30	Giessen (Germany)	33	14	Complete	-	-	No	No	Termination of pregnancy	No (body stalk syndrome)
31	Giessen (Germany)	23	19	Partial	46, XY	-	Pulmonary atresia + VSD	Yes	Alive	Yes

EC: ectopia cordis; GA: gestational age; PC: pentalogy of Cantrelli; VSD: ventricular septal defect.

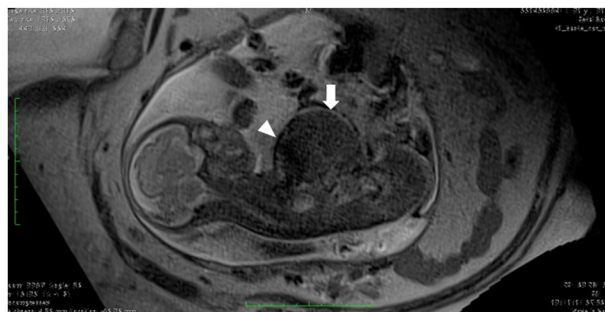


**Figure 5.** Intraoperative image of the postnatal surgery of the #case 3 within the first day of postnatal life.

diagnosed with PC [13]. The other 14 patients had other congenital anomalies that did not correspond to PC malformations.

Congenital heart disease is often observed in fetuses with EC [7]. Previous studies affirm that ventricular septal defects and conotruncal abnormalities (tetralogy of Fallot and double-outlet right ventricle were the most common conotruncal anomalies) are the more common intracardiac defects in EC [12,14]. We found that 12 of 31 patients had these types of malformations, six with VSD and six with conotruncal anomalies (two had tetralogy of Fallot, one had truncus arteriosus, and three had a double-outlet right ventricle). Therefore, conotruncal abnormalities and VSD were the most frequently detected congenital heart diseases among our patients.

The gestational age at which EC can be diagnosed mainly depends on the extent of the malformation and type of EC; complete EC, with the entire heart exposed, is more likely to be diagnosed with the current screening ultrasound protocols, while the diagnosis of thoracoabdominal EC may be more difficult. Studies have reported that EC cases are diagnosed by gestational age as early gestation such as 10 weeks [6,14,15]. Corroborating with data from the literature, in our study, six fetuses were diagnosed with EC in the first trimester and all of them with complete EC, which is consistent with the findings of previously published literature [4,5,10].



**Figure 6.** Fetal magnetic resonance imaging of the #Case 6 at 28 weeks of gestation showing the ectopia cordis (head arrow) and omphalocele (arrow).

EC is associated with high mortality rates, even when diagnosed *in utero*. Twenty-seven of all fetuses culminated in spontaneous fetal demise, stillborn, neonatal death, or TOP. In this scenario, it is crucial to consider that the high rate of pregnancy termination (almost 50% in our study) is a bias that contributes to the overestimation EC-related perinatal mortality. Escobar-Diaz et al. [10] showed in their study that all non-survivors had complete EC with PC-associated EC, while all six survivors had partial EC. These authors also showed that patients with thoracic EC had higher mortality rates [10]. Smith et al. [12] reported that it is more likely for patients with better outcomes to have more limited thoracoabdominal defects, as compared with EC involving complete protrusion. Conversely, in our data, the survivors had complete EC and the majority of them had associated PC. However, the high rate of pregnancy termination option (nearly 50% in our study) is a bias that contributes to overestimating EC-related perinatal mortality.

Even after initial stabilization and corrective surgery, patients with EC experience considerable postnatal morbidity and mortality. The features that seem to influence this result are maturity and birth weight, suggesting that morbidity may be affected by the increased risk of infection, underdevelopment of the lungs, and the immaturity of multiple organ systems. Smith et al. [12], in a large multicenter cohort with EC, observed worse outcomes in preterm and very low-birth-weight infants. Although other studies related to the outcome might also be influenced by the additional malformation, severity of cardiac and noncardiac abnormalities, and surgical timing, these data were not collected [12]. In our data, all the patients that underwent surgery were full-term with adequate birth weight. Among the three newborns that underwent surgery, all of them survived, and currently they are still alive.

The postoperative outcome of EC may vary depending on prematurity, birth weight, type of EC, and extent of exteriorization of the cardiac defect (EC involving partial or complete protrusion). Better perinatal outcomes have been reported in mild cases of thoracoabdominal defects [12,16]. Although a variety of features have been related to the postnatal prognosis of corrective surgery for EC, the procedure of placing the heart back completely inside the thoracic cavity is, by itself, a great challenge. Compression of the heart and its great vessels into the neonatal thoracic cavity carries a low cardiac output even more in a small thorax, as in neonates with a low birth weight. In this setting, Amato et al. [17] suggested placing the heart partially within the thoracic cavity in the first stage, and the defect could be reduced slowly over the following weeks. Indeed, patients with complex intracardiac defects may have further undergone another surgical approach by steps [17–22]. In general, the first stage involves temporary coverage of the chest wall with a synthetic material, and the second stage comprises definitive reconstruction with dorsal muscles, autologous bone, and cartilage grafts, or alloplastic materials [21–24]. In three cases of our series (cases 15, 26, and 31), the surgery was performed within the first days of postnatal life including the complete accommodation of the heart into the chest cavity with successful surgical approach.

Although in the literature there is a unique report of a patient with EC who survived without surgical correction, EC is a congenital heart disease that requires surgical management [6,17,18,25]. Despite the poor prognosis of EC, there is a chance of survival when the reconstructive surgery is performed, especially when the first surgical approach occurs during the neonatal period [6,12].

Indeed, this article describes main characteristics (intracardiac and extracardiac associated anomalies) and the perinatal outcomes of an EC cohort case series, being crucial to antenatal parental counseling.

## Conclusions

EC is associated with intra and extra-cardiac defects and high mortality rates. The majority of this cohort of EC demised due to TOP, spontaneous fetal demise, or neonatal death. Despite the poor outcome of EC, all survivors were those who were born alive and underwent surgery. Similarly, to the literature, in this study, ventricular septal defects and conotruncal anomalies were the more common intracardiac defects associated with EC. However, the incidence of PC was lower

than reported in the literature. Fetal echocardiography and cardiac ultrasonography are crucial in the prenatal assessment of EC enabling detailed *in utero* diagnosis, being fundamental to antenatal parental counseling.

## Disclosure statement

No potential conflict of interest was reported by the author(s).

## Funding

The author(s) reported there is no funding associated with the work featured in this article.

## ORCID

Edward Araujo Júnior  <http://orcid.org/0000-0002-6145-2532>

Gabriele Tonni  <http://orcid.org/0000-0002-2620-7486>

Maciej Slodki  <http://orcid.org/0000-0002-0160-8013>

## References

- [1] Nzomvuama A, Nader J, Remadi JP. Ectopia cordis: an uncommon fatal disease. *Ann Thorac Surg.* 2021; 112(3):e201.
- [2] Gabriel A, Donnelly J, Kuc A, et al. Ectopia cordis: a rare congenital anomaly. *Clin Anat.* 2014;27(8):1193–1199.
- [3] Kaplan LC, Matsuoka R, Gilbert EF, et al. Ectopia cordis and cleft sternum: evidence for mechanical teratogenesis following rupture of the chorion or yolk sac. *Am J Med Genet.* 1985;21(1):187–202.
- [4] Araujo Júnior E, Zanforlin Filho SM, Guimarães Filho HA, et al. Diagnosis of pentalogy of Cantrell by three-dimensional ultrasound in third trimester of pregnancy. A case report. *Fetal Diagn Ther.* 2006;21(6): 544–547.
- [5] Karim JN, Bradburn E, Roberts N, et al. First-trimester ultrasound detection of fetal heart anomalies: systematic review and meta-analysis. *Ultrasound Obstet Gynecol.* 2022;59(1):11–25.
- [6] Repondek-Liberska M, Janiak K, Wloch A. Fetal echocardiography in ectopia cordis. *Pediatr Cardiol.* 2000; 21(3):249–252.
- [7] Medina-Escobedo G, Reyes-Mugica M, Arteaga-Martinez M. Ectopia cordis: autopsy findings in four cases. *Pediatr Pathol.* 1991;11(1):85–95.
- [8] Araujo Júnior E, Carrilho MC, Toneto BR, et al. Pentalogy of Cantrell: prenatal diagnosis, delivery, and immediate postnatal surgical repair. *J Neonatal Surg.* 2017;6(2):32.
- [9] Cantrell JR, Haller JA, Ravitch MM. A syndrome of congenital defects involving the abdominal wall, sternum, diaphragm, pericardium, and heart. *Surg Gynecol Obstet.* 1958;107(5):602–614.
- [10] Escobar-Diaz MC, Sunderji S, Tworetzky W, et al. The fetus with ectopia cordis: experience and



- expectations from two centers. *Pediatr Cardiol.* 2017; 38(3):531–538.
- [11] Gavrilov S, Lacy E. Genetic dissection of ventral folding morphogenesis in mouse: embryonic visceral endoderm-supplied BMP2 positions head and heart. *Curr Opin Genet Dev.* 2013;23(4):461–469.
- [12] Smith BJ, Flyer JN, Edwards EM, et al. Outcomes for ectopia cordis. *J Pediatr.* 2020;216:67–72.
- [13] Pakdaman R, Woodward PJ, Kennedy A. Complex abdominal wall defects: appearances at prenatal imaging. *Radiographics.* 2015;35(2):636–649.
- [14] Türkyilmaz G, Avcı S, Sıvrıköz T, et al. Prenatal diagnosis and management of ectopia cordis: varied presentation spectrum. *Fetal Pediatr Pathol.* 2019;38(2): 127–137.
- [15] Sepulveda W, Wong AE, Simonetti L, et al. Ectopia cordis in a first-trimester sonographic screening program for aneuploidy. *J Ultrasound Med.* 2013;32(5): 865–871.
- [16] Engum SA. Embryology, sternal clefts, ectopia cordis, and Cantrell's pentalogy. *Semin Pediatr Surg.* 2008; 17(3):154–160.
- [17] Amato JJ, Zelen J, Talwalkar NG. Single stage repair of thoracic ectopia cordis. *Ann Thorac Surg.* 1995;59(2): 518–520.
- [18] Morello M, Quaini E, Nenov G, et al. Extrathoracic ectopia cordis. *J Cardiovasc Surg.* 1994;35(6):511–515.
- [19] Watterson KG, Wilkinson JL, Kliman L, et al. Complete ectopia cordis with double outlet right ventricle: neonatal repair. *Ann Thorac Surg.* 1992;53(1):146–147.
- [20] Morales JM, Patel SG, Duff JA, et al. Ectopia cordis and other midline defects. *Ann Thorac Surg.* 2000; 70(1):111–114.
- [21] Lampert JA, Harmaty M, Thompson EC, et al. Chest wall reconstruction in thoracoabdominal ectopia cordis: using the pedicled osteomuscular latissimus dorsi composite flap. *Ann Plast Surg.* 2010;65(5): 485–489.
- [22] Mohan R, Peralta M, Perez R, et al. Chest wall reconstruction in a pediatric patient with ectopia cordis. *Ann Plast Surg.* 2010;65(2):211–213.
- [23] Ley EJ, Roth JJ, Kim KA, et al. Successful repair of ectopia cordis using alloplastic materials: 10-year follow-up. *Plast Reconstr Surg.* 2004;114(6):1519–1522.
- [24] Kim KA, Vincent WR, Muenchow SK, et al. Successful repair of ectopia cordis using alloplastic materials. *Ann Plast Surg.* 1997;38(5):518–522.
- [25] Jahan Y, Rahman A. Ectopia cordis: 6-year survival without surgical correction. *Fetal Pediatr Pathol.* 2021; 40(5):540–542.