



## Monaldi Archives for Chest Disease

eISSN 2532-5264

<https://www.monaldi-archives.org/>

**Publisher's Disclaimer.** E-publishing ahead of print is increasingly important for the rapid dissemination of science. The **Early Access** service lets users access peer-reviewed articles well before print / regular issue publication, significantly reducing the time it takes for critical findings to reach the research community.

These articles are searchable and citable by their DOI (Digital Object Identifier).

The **Monaldi Archives for Chest Disease** is, therefore, e-publishing PDF files of an early version of manuscripts that undergone a regular peer review and have been accepted for publication, but have not been through the typesetting, pagination and proofreading processes, which may lead to differences between this version and the final one.

The final version of the manuscript will then appear on a regular issue of the journal.

E-publishing of this PDF file has been approved by the authors.

Monaldi Arch Chest Dis 2023 [Online ahead of print]

*To cite this Article:*

Rotolo N, Cattoni M, De Maio S, et al. **The surgical approach of late-onset tracheoesophageal fistula in a tracheostomized COVID-19 patient.** *Monaldi Arch Chest Dis* doi: 10.4081/monaldi.2023.2490

 ©The Author(s), 2023  
Licensee [PAGEPress](https://www.pagepress.org/), Italy

Note: The publisher is not responsible for the content or functionality of any supporting information supplied by the authors. Any queries should be directed to the corresponding author for the article.

All claims expressed in this article are solely those of the authors and do not necessarily represent those of their affiliated organizations, or those of the publisher, the editors and the reviewers. Any product that may be evaluated in this article or claim that may be made by its manufacturer is not guaranteed or endorsed by the publisher.



**The surgical approach of late-onset tracheoesophageal fistula in a tracheostomized  
COVID-19 patient**

Nicola Rotolo, Maria Cattoni, Silvia De Maio, Luca Filipponi, Pau Mateo-Ramos,  
Andrea Imperatori

Research Center of Minimally Invasive Surgery and Thoracic Surgery, Department of Medicine  
and Surgery, University of Insubria, Varese, Italy

**Corresponding author**

Nicola Rotolo MD,  
Center of Minimally Invasive Surgery  
Center of Thoracic Surgery  
Department of Medicine and Surgery  
University of Insubria  
Viale Guicciardini 9, 21100 Varese – Italy  
E-mail: [nicola.rotolo@uninsubria.it](mailto:nicola.rotolo@uninsubria.it)

**Funding:** none

**Contribution:** All authors have significantly contributed to the paper and have read and approved the final version of the manuscript and agreed to be accountable for all aspects of the work.

**Conflict of interest:** none

**Availability of data and materials:** All data underlying the findings are fully available.

**Ethics approval and consent to participate:** No ethical committee approval was required for this case report by the Department, because this article does not contain any studies with human participants or animals. Informed consent was obtained from the patient included in this study.

**Consent for publication:** The patient gave her written consent to use his personal data for the publication of this case report and any accompanying images.

**Conference presentation:** Presented as oral communication at the 22<sup>nd</sup> National Congress of Italian Society of Thoracic Endoscopy in Rome, Italy - 2022, October 1<sup>st</sup>

### **Abstract**

In the COVID-19 era the tracheal complications due to prolonged mechanical ventilation have significantly increased. Acquired tracheoesophageal fistula is one of those in ventilated COVID-19 patients. Thus, the knowledge of their management in such fragile patient is crucial. We report a case of tracheoesophageal fistula in a 56-year-old female under prolonged mechanical ventilation for COVID-19 bilateral pneumonia and discuss its management. A surgical approach was proposed. By a collar-shaped transverse cervicotomy access, we transected the trachea at level of fistula en-bloc with the tracheostoma. The esophageal lesion was longitudinally repaired in two-layers. Protective left strap muscle was sandwiched between esophagus and trachea. The tracheal end-to-end anastomosis was completed without a re-tracheostoma. Even if surgical approach of tracheoesophageal fistula in COVID-19 patients has not been tested before, surgery remains the treatment of choice according to the multidisciplinary board.

**Keywords:** tracheoesophageal fistula; COVID-19; tracheal resection and reconstruction; prolonged mechanical ventilation, esophageal repair

### **Introduction**

Tracheoesophageal fistula (TEF) is a rare complication of prolonged mechanical ventilation (PMV), with a reported incidence of 0.3-3% [1]. In the SARS-CoV-2 pandemic era, the increasing number of patients with COVID-19 bilateral pneumonia requiring PMV has led to a rise in airway injuries such as TEF. Thus, the knowledge of the appropriate management (preoperative preparation, supportive therapy and surgical timing and techniques) of TEF is fundamental to improve the outcomes of post COVID-19 patients with this rare condition.

This case report describes the surgical management of a late-onset TEF in a female treated with PMV for severe respiratory failure in COVID-19 bilateral interstitial pneumoniae. Patient's informed consent for this case publication was obtained.

### **Case Report**

A 56-year-old female with arterial hypertension and a past-history of hysteroannexectomy for ovarian neuroendocrine tumor was admitted to the Emergency Room for a 7-day worsening dyspnea and a positive molecular test for COVID-19. The chest computed tomography scan showed a bilateral interstitial pneumoniae involving 60% of the lung parenchyma with no sign of pulmonary embolism. The patient was supported with oxygen first and, when the respiratory exchanges got worst, she was intubated and transferred to the Intensive Care Unit (ICU) where, several days later, underwent percutaneous tracheostomy. Two months later, a negative result of a COVID-19 molecular test was obtained, the clinical conditions improved, the PMV was discontinued, and the patient was discharged from ICU with the tracheostomy. After 15 days of spontaneous breathing the patient developed persistent cough and gastric secretions were found in her sputum, arising the suspect of TEF. The swallowing studio followed by bronchoscopy and esophagoscopy confirmed the presence of a 3 cm TEF laid in the anterior wall of the middle third of the esophagus and the posterior wall of the trachea, at the height of the tracheostomy tube cuff (Figure 1A). Due to the patient's progressive worsening of clinical conditions as well as the laboratory data, after a multidisciplinary board discussion, surgical treatment was chosen as therapeutic method.

The surgery was performed as follows. First, a transgastric jejunal tube was placed for postoperative nutrition support and a nasogastric tube was introduced to easily identify and isolate the esophagus during surgery, and to reduce the acid reflux on the suture during the postoperative time. Tracheal surgery was approached with Grillo's technique through a collar-shaped transverse cervicotomic access at the tracheostomy site and a diamond shaped cut around the stoma [2]. Platysma muscle was raised superiorly to the hyoid bone and inferiorly up to the manubrium. Strap muscles were identified and retracted laterally. The trachea was

hardly isolated due to peri-tracheostomy antero-lateral scars using Metzenbaum's curved scissor and rarely using the electrosurgical knife. Then, it was en-bloc transected with the tracheostomy stoma anteriorly and the fistula posteriorly, allowing a full exposition of the 3 cm esophageal lesion (Figure 1B). The crossfield mechanical ventilation was started. The esophagus was dissected, isolated, and sutured under the nasogastric tube guidance. A two-layer esophageal repair was performed to longitudinally close the lesion, using mucosal inverting absorbable interrupted sutures and muscular everting interrupted sutures [4/0 polydioxanone (PDS)] placing knots about 4 mm apart. The left strap muscle was transected superiorly and fixed with four opposed stitches between the esophagus and the trachea to cover the tracheal and the esophageal sutures. Finally, tracheal end-to-end anastomosis was completed with uninterrupted suture on the posterior wall and interrupted suture on the cartilaginous part using 4/0 PDS, without any laryngotracheal release maneuver. No re-tracheotomy at the end of the surgery was done. A 19 French vacuum drainage was left in place for 5 days. The chin-to-chest stitch was removed on the postoperative day 9.

The postoperative course was characterized by the need of mechanical ventilation for 15 days after surgery due to COVID-19 pulmonary long-term effects, however uneventful, and being cautions to place and keep the orotracheal tube cuff distal to the tracheal suture. The barium swallow studio performed on postoperative day 22 was negative (Figure 1C) and the patient started with oral feeding without any complications. On postoperative day 24 she was transferred to a rehabilitation hospital and then discharged to home. At 4-month follow-up, the patient was in good general condition, complaining only of dysphonia. The fiberoptic-tracheoscopy performed at that time showed a left vocal cord paralysis and an asymptomatic mild reduction of the tracheal lumen at the suture level.

## **Discussion**

Bilateral interstitial pneumoniae COVID-19 related has increased the number of patients requiring PMV with higher risk to develop TEF [3,4]. Therefore, having a complete scenario of TEF management in this specific group of patients is fundamental to guarantee the most appropriate treatment.

Acquired non-malignant TEF is known to be the result of the compression of the tracheal membranous wall and the esophagus wall between the PMV tracheal tube cuff anteriorly and the nasogastric tube posteriorly [5]. Cuff overinflation, high airway pressure, excessive endotracheal tube motion, old age, female gender, hypotension, diabetes, steroids, and infections are all known factors to facilitate the evolution of TEF [4-7]. COVID-19 patients

requiring PMV for respiratory failure present almost all these risk factors and, also COVID-19 specific conditions. First, COVID-19 determines a direct infection of the airways, causing an inflammatory infiltrate of the mucosa and submucosa, weakening the tracheal wall. Then, these patients generally require a nasogastric tube for nutrition support, frequent sessions of prone position with the need of repositioning the endotracheal tube, finally they are all treated with high dose of steroids to improve the respiratory exchange. Thus, in the presence of symptoms of TEF in COVID-19 patients requiring PMV, the suspicion of TEF should be always considered.

Early diagnosis and treatment of TEF is fundamental because it improves the possibility of a favorable outcome [7]. The barium swallow studio, followed by bronchoscopy and esophagoscopy are generally required to confirm the TEF and to evaluate its length and location, that are fundamental data to plan the most appropriate treatment.

Several reports reveal that surgery is the treatment of choice in selected cases since spontaneous closure of TEF is a rare event, generally involving patients with a small cervical fistula [5,8,9]. Two surgical approaches are proposed to repair the TEF: the anterior approach with a tracheal resection and reconstruction or the left lateral approach with direct repair of the trachea and the esophagus. However, surgery is challenging in both cases. In a series published by Dhiwakar *et al.*, tracheal resection and reconstruction was performed in 64 % of 141 TEF, with better outcome in terms of fistula healing (99% vs 89%), need of further interventions (76% vs 61%) and long-term appliance free trachea (93% vs 76%) when compared to the lateral approach [8]. Regarding the anterior approach, our experience finds us in agreement with Dhiwakar and coworkers: it lets (1) a direct and excellent exposure of the esophageal lesion after tracheal resection; (2) a vertical and more comfortable closure of the esophagus; (3) a simple horizontal suture of the posterior tracheal wall and (4) the ability to remove the tracheostomy in selected cases as we did in our case. In both approaches, after the tracheal and esophageal repair, a pedicle of strap muscles is generally mobilized and positioned inferiorly to protect the esophageal repair and to separate both suture lines as we did in our case with the left sternohyoid. Alternatively, the sternocleidomastoid or the fascia lata can be used [8].

To date, only 3 cases of post COVID-19 patients surgically treated for TEF are reported in literature. Patients' characteristics and treatment are described in Table 1 [4,7,10].

Tracheal complications after TEF repair are not negligible: 24% and 39% in the anterior and lateral approach, respectively. Postoperative complications generally require further interventions such as tracheostomy, Montgomery tube insertion, laser therapy for granuloma and tracheal dilatation. To reduce the risk of postoperative complications it is suggested to

repair TEF in patients weaned from mechanical ventilation support. In fact, the risk of postoperative complications in patients requiring PMV during the postoperative stay is higher, ranging between 32-56%, and mostly represented by tracheal anastomosis complications or fistula recurrence [2,5,7,11,12]. However, in post COVID-19 patients, waiting for the perfect timing for surgery sometimes means that patient will not be able to reach this final treatment because of the TEF worsening and patient's clinical condition decreasing [13]. This explains the choice of some authors and ours to proceed to TEF repair even in patients who could require PMV support after surgery. In these patients to perform a tracheostomy a couple of rings under the tracheal anastomosis could be taken into consideration to guarantee postoperative patient mechanical ventilation [7,10]. However, tracheostomy is generally avoided [14]. In our case, the patient's good preoperative condition led us to complete the surgical procedure without performing a tracheostomy. The need of postoperative PMV was successfully satisfied intubating the patient under endoscopic guidance and positioning the endotracheal's tube cuff distal to the anastomosis, with no postoperative anastomotic complications or TEF recurrence. During treatment's planning, placing a feeding jejunostomy should be taken into consideration to offer the patient an adequate nutrition support, since after the diagnosis of TEF the nasogastric tube removal is generally recommended [5,9,13,15]. In our case we decided to place a percutaneous endoscopic transgastric jejunostomy since the patient had already a percutaneous gastrostomy performed during her first stay in the ICU. However, surgical jejunostomy could be taken into consideration, too [10]. Other important preoperative precautions in a patient with TEF are to keep the head of the patient bed's elevated, to replace the endotracheal tube or the tracheostomy cannula downstream from the fistula in patients requiring PMV and to insert a draining gastrostomy [5,9,13]. All these precautions have the aim to significantly reduce the risk of the tracheobronchial tree contamination.

For patients not suitable for surgery there are some alternatives to be considered as esophageal or airway stenting. Recently, in a case series of 4 COVID-19 patients on veno-venous extracorporeal membrane oxygenation, TEF was approached endoscopically with one-time esophageal endoscopic suture, downstream tracheostomy cannula replacement and percutaneous endoscopic gastrojejunostomy, with a success rate of 75% (3 case of 4) [9].

## **Conclusions**

To conclude, the TEF remains a feared complication mainly in fragile patients especially in those requiring PMV for COVID-19 bilateral interstitial pneumoniae. The prompt diagnosis is fundamental to an early start of patient's supportive therapy and to plan the most appropriate treatment. Surgery remains the TEF's treatment of choice, however the high rate of postoperative morbidity, mainly in those requiring postoperative PMV, should lead clinicians to carefully assess the patient's suitability for this intervention without further delay.

## References

1. Couraud L, Ballester MJ, Delaisement C. Acquired tracheoesophageal fistula and its management. *Semin Thorac Cardiovasc Surg* 1996;8:392-9.
2. Grillo HC, Moncure AC, McEnany MT. Repair of inflammatory tracheoesophageal fistula. *Ann Thorac Surg* 1976;22:112-1.
3. Fiacchini G, Forfori F, Guarracino F, Bruschini L. Potential mechanisms of laryngotracheal injuries in patients with COVID-19 subjected to invasive ventilation. *Respir Care* 2021;66:1927-8.
4. García-Herreros LG, Jiménez A, Cabrera LF, et al. Early presentation of post-intubation tracheoesophageal fistula with severe tracheal stenosis in COVID-19 patient. *Ann R Coll Surg Engl* 2021;103:e144-7.
5. Reed MF, Mathisen DJ. Tracheoesophageal fistula. *Chest Surg Clin N Am* 2003;13:271-89.
6. Wolf M, Yellin A, Talmi YP, et al. Acquired tracheoesophageal fistula in critically ill patients. *Ann Otol Rhinol Laryngol* 2000;109:731-5.
7. Rosati R, De Nardi P, Dell'Acqua A, et al. Tracheoesophageal fistula in a COVID-19 ventilated patient: A challenging therapeutic decision. *Case Rep Surg* 2021;2021:6645518.
8. Dhiwakar M, Ronen O, Supriya M, Mehta S. Surgical repair of mechanical ventilation induced tracheoesophageal fistula. *Eur Arch Otorhinolaryngol* 2020;277:323-31.
9. Negaresh M, Hoseininia S, Samadi Takaldani AH, et al. Implanting jejunostomy tube as conservative management of tracheoesophageal fistula in a COVID-19 patient. *Clin Case Rep* 2021;9:e05151.
10. Pereira C, Silva R, Campello GC, Moura F. Tracheoesophageal fistula in a COVID-19 patient. *Saudi J Anaesth* 2021;15:447-9.
11. Puma F, Vannucci J, Santoprete S, et al. Surgery and perioperative management for post-intubation tracheoesophageal fistula: case series analysis. *J Thorac Dis* 2017;9:278-86.
12. Rotolo N, Cattoni M, Imperatori A. Complications from tracheal resection for thyroid carcinoma. *Gland Surg* 2017;6:574-8.
13. Cuaño Mina PMG, Pilapil Agsalud JC, Larrazabal Bagaporo RJ, Villalobos RE. Acquired tracheoesophageal fistula in a pregnant patient with COVID-19 pneumonia on prolonged invasive ventilation. *BMJ Case Rep* 2021;14:e244016.



14. Mathisen DJ, Grillo HC, Wain JC, Hilgenberg AD. Management of acquired nonmalignant tracheoesophageal fistula. *Ann Thorac Surg* 1991;52:759-65.
15. Granata A, Martucci G, Rizzo GEM, et al. Combined endoscopic treatments for tracheo-esophageal fistula developed during V-V ECMO for severe COVID-19: A case series. *Artif Organs* 2022;46:506-8.

**Table 1.** Tracheoesophageal fistula surgical treatment in COVID-19 patients: literature review.

<b>Authors</b>	<b>Year</b>	<b>Surgical approach</b>	<b>PO tracheostomy</b>	<b>Flap interposition</b>	<b>Complications</b>
Rosati et al. [7]	2021	LA	yes	sternocleidomastoid	LN palsy; TS
García-Herreros et al. [4]	2021	TR	yes	sternocleidomastoid	LN palsy; TS
Pereira et al. [10]	2021			<i>Unspecified surgical treatment</i>	
Rotolo et al.*	2022	TR	no	strap muscle	LN palsy

PO=postoperative; LA=lateral approach; LN=laryngeal nerve; NA=not available; TR=tracheal resection and reconstruction; TS=tracheal sub-stenosis; \*=current case

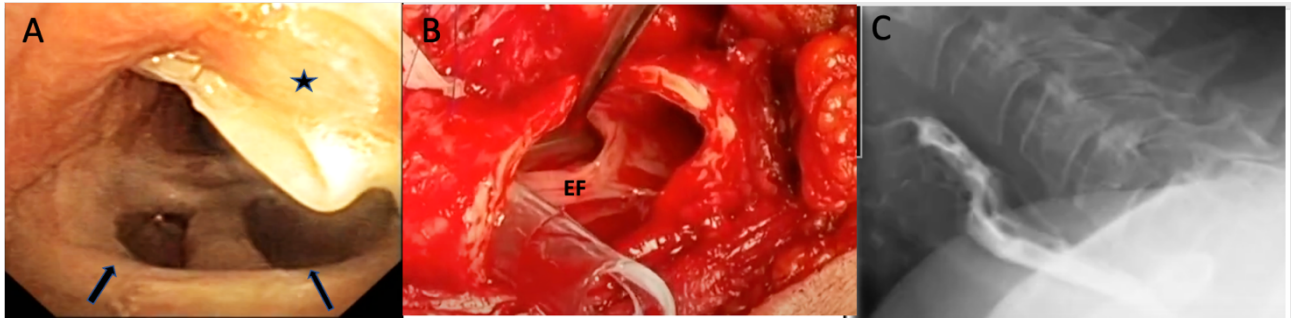


Figure 1. Tracheoesophageal fistula. A) Bronchoscopy vision of the 3 cm tracheoesophageal fistula of the anterior wall of the esophagus and the posterior wall of the trachea (arrows), at the height of the tracheostomy tube (asterisk); B) The surgical exposition of the tracheoesophageal fistula (EF) after tracheal resection; C) The barium swallow studio performed on postoperative day 22 showing a complete repair of the defect.