

## IMAGES OF THE MONTH

### Summertime skin rash

#### Question

A 4-year-old boy was referred for a 5-day history of papular lesions on his trunk and buttocks, apparently appeared few days after bathing in a seawater pool. His sister, who played with him in the pool, had a similar, but milder dermatologic picture. Lesions got worse and increased in number despite local treatment with fusidic acid and oral amoxicilline-clavulanate (Fig. 1). He was afebrile and in good clinical condition. A cutaneous swab was performed and it revealed the causative germ. The skin eruption resolved after 48-h of topical treatment with ciprofloxacin. What is the most likely diagnosis? (Answer on page 963)

Dr Francesca Peri <sup>1</sup>

Dr Irene Berti<sup>2</sup>

Dr Chiara Zanchi<sup>2</sup>

Professor Egidio Barbi <sup>1,2</sup>

<sup>1</sup>Pediatric Department, University of Trieste

<sup>2</sup>Pediatric Department, Institute for Maternal and Child Health Burlo Garofolo, Trieste, Italy

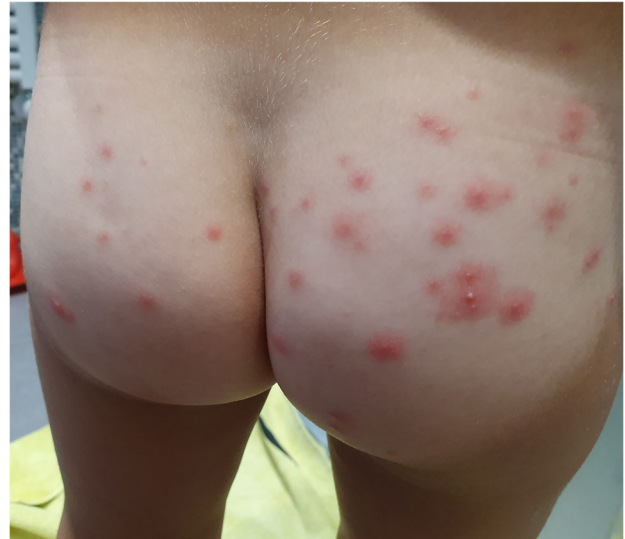


Fig 1 Papulopustular eruption on child's buttocks.

### Monozygotic twins with development delay and a characteristic electroencephalographic pattern: Just look at the face

#### Question


Two-year-old monozygotic-twin girls, born to non-consanguineously married couple, presented with development delay and generalised tonic seizures noticed since 6 months of age. The seizures worsened during fever and had partial response to anti-seizure medications. They also developed arrhythmic erratic multifocal myoclonic jerks involving all the four limbs, head and trunk since past 2 months. The best attained milestones were sitting with support, babbling, unidextrous grasp with no stranger anxiety. Examination revealed truncal hypotonia along with distinct facial appearance, microcephaly, happy demeanour, protruding tongue and tremulousness (Fig. 1a,b).

Electroencephalography (EEG) revealed high-voltage, arrhythmic, asynchronous delta background resembling hypsarrhythmia-like pattern (Fig. 1c). Neuroimaging was normal. (Answer on page 963)

Dr Bhanudeep Singanamalla <sup>1</sup>

Dr Chandana Bhagwat<sup>1</sup>

Dr Priyanka Madaan<sup>1,2</sup>

Dr Lokesh Saini <sup>1</sup>

Dr Priyanka Srivastava<sup>3</sup>

<sup>1</sup>Pediatric Neurology division, Department of Pediatrics, <sup>2</sup>Genetic Metabolic Unit, Department of Pediatrics, Post Graduate Institute of Medical Education and Research (PGIMER), Chandigarh and <sup>3</sup>Council of Scientific and Industrial Research, New Delhi, India