



# A prospective study to evaluate a new dental management protocol before hematopoietic stem cell transplantation

著者	Yamagata K, Onizawa K, Yanagawa T, Hasegawa Y, Kojima H, Nagasawa T, Yoshida H
journal or publication title	Bone Marrow Transplantation
volume	38
number	3
page range	237-242
year	2006-08
権利	(C) 2006 Nature Publishing Group
URL	<a href="http://hdl.handle.net/2241/89451">http://hdl.handle.net/2241/89451</a>

doi: 10.1038/sj.bmt.1705429

A prospective study to evaluate a new dental management protocol before  
hematopoietic stem cell transplantation

Kenji Yamagata<sup>1</sup>, Kojiro Onizawa<sup>1</sup>, Toru Yanagawa<sup>1</sup>, Yuichi Hasegawa<sup>2</sup>,  
Hiroshi Kojima<sup>2</sup>, Toshiro Nagasawa<sup>2</sup>, Hiroshi Yoshida<sup>1</sup>

*1 Department of Oral and Maxillofacial Surgery, Institute of Clinical Medicine,  
University of Tsukuba, Tsukuba, Japan*

*2 Division of Hematology, Institute of Clinical Medicine, University of Tsukuba,  
Tsukuba, Japan*

**Running title:** Pre-HSCT dental management protocol

*Correspondence:*

Hiroshi Yoshida D.D.S., PhD

Department of Oral and Maxillofacial Surgery, Institute of Clinical Medicine,

University of Tsukuba, 1-1-1 Tennodai, Tsukuba, Ibaraki, 305-8575, Japan

Tel: +81-29-853-3050

Fax: +81-29-853-3050

E-mail: [hyoshida@md.tsukuba.ac.jp](mailto:hyoshida@md.tsukuba.ac.jp)

**Summary:**

Pre-hematopoietic stem cell transplantation (HSCT) dental treatment is essential to prevent serious infections from oral sources during immunosuppression in patients who undergo HSCT therapy. This study was planned to establish a dental management protocol for these patients. Forty-one patients scheduled for HSCT to treat hematological malignancies were consecutively enrolled in the prospective trial. The dental status of all the patients was evaluated by clinical and radiographic examination at a median of 47 days before the commencement of HSCT therapy. Thirty-six patients had one or more dental diseases; the remaining 5 had none. Caries was found in 26 patients, apical periodontitis in 19, marginal periodontitis in 24, and partially erupted third molar in 11. Our policy is to preserve patients' teeth whenever possible, and therefore minimal dental intervention was planned. Treatment was completed for all 36 patients with dental pathologies, before the conditioning regimen began. All the patients received the scheduled HSCT therapy without alteration, interruption, or delay, and did not show any signs or symptoms associated with odontogenic infection while they were immunosuppressed. This protocol, therefore, appears to be appropriate for the pre-HSCT dental treatment of patients with hematological diseases.

**Keywords:** Dental management; Hematopoietic stem cell transplantation (HSCT); Apical periodontitis; Marginal periodontitis; Partially erupted third molar

## Introduction

Hematopoietic stem cell transplantation (HSCT) has become an essential treatment for many patients with malignant and nonmalignant hematological diseases, including acute and chronic leukemias, aplastic anemia, myelodysplastic syndromes, and lymphomas<sup>1,2</sup>. Although HSCT is an effective treatment modality for these patients, successful engraftment after HSCT requires adequate immunosuppression of the recipient, which is accomplished with total body irradiation, chemotherapy, or a combination of both. Their immunosuppressed status makes the patients more susceptible to infection, resulting in an increased risk of infectious complications, including the development of severe septicemia, that may be life-threatening<sup>2,3</sup>.

The oral cavity is a potential site of such infectious complications in patients receiving HSCT therapy, because it is an important port of entry for agents that can cause systemic infections<sup>4-7</sup>. To prevent these oral complications, pre-transplant comprehensive oral care has been incorporated into the preparatory steps for patients scheduled to receive HSCT therapy. This approach is supported by the National Institutes of Health consensus statement on oral complications of cancer therapy (1989), which states, “dental foci are potential sources of systemic infections that need to be eliminated or ameliorated before commencement of anticancer therapy.”<sup>8</sup> Therefore, to prevent significant morbidity, all sources of potential infection should be identified upon pre-transplant dental screening and treated appropriately<sup>2,9,10</sup>.

Not all previous studies have supported a need for pre-HSCT dental treatment. Melkos *et al*<sup>11</sup> reported there was no significant difference in the occurrence of infection originating from oral disease during and after HSCT therapy between patients with and without pre-HSCT dental treatments, but they did not describe in

detail the severity of the dental diseases of the patients in their study. Tolijanac *et al*<sup>12</sup> demonstrated that oncologic treatment outcomes were unaffected by the presence of chronic dental disease or acute exacerbations of these disease states in a pilot study in which no chronic dental diseases were treated regardless of severity, but the great majority of the patients in their study received only chemotherapy, which does not require the serious immunosuppression needed for HSCT therapy. Given the limitations of these studies, pre-HSCT dental therapy is still indicated to prevent odontogenic complications.

The potentially complicating oral conditions that have been identified are: dental caries, pulpitis, apical and marginal periodontitis, and partially erupted third molar. Dental care for these disorders includes tooth brushing instruction, scaling, restoration, pulpectomy, and endodontic treatment. Tooth extraction is recommended for severe dental disease. Such pre-HSCT dental treatments are anticipated to decrease the risk of local and systemic odontogenic infections during patient immunosuppression.

Considering the limited period available for pre-HSCT dental treatment<sup>13</sup>, minimal dental intervention to treat only the sources of potential infection is recommended. However, treatment protocols that clearly define the best treatment modality for patients at their pre-HSCT dental assessment are needed. We previously used retrospective data to construct a brief dental management protocol for patients scheduled to undergo HSCT therapy for hematologic diseases and evaluated its usefulness<sup>14</sup>. However, a protocol defining the appropriate detailed treatment modality according to the severity of each dental disorder remains to be described. This study was prospectively carried out to establish detailed treatment criteria for minimal intervention in potentially detrimental dental disorders and to judge the effectiveness of the protocol.

## **Patients and methods**

Seventy-one candidates for HSCT therapy were referred from the Division of Hematology, Tsukuba University Hospital to the Division of Oral and Maxillofacial Surgery, which is the same hospital that carried out the screening of dental pathology between 1998 to 2004. Of 71 patients with hematological malignancies, 41 underwent HSCT therapy; 30 did not because their general condition was poor or because no appropriate donor could be found. The 41 patients were consecutively enrolled into the prospective trial. The subjects were 22 males and 19 females, ranging in age from 17 to 58 years with a mean of 41.3 years. All participants gave informed consent prior to proceeding with treatment. The hematologic diagnoses were as follows: 14 patients had chronic myeloid leukemia, 7 had malignant lymphoma, 4 had acute myeloid leukemia, 4 had non-Hodgkin lymphoma, 4 had myelodysplastic syndrome, 3 had multiple myeloma, 3 had acute lymphoid leukemia, and 2 had other malignancies. Hematopoietic stem cells were collected from the bone marrow of 28 patients and from the peripheral blood of 13 (Table 1).

The dental status of all the patients was evaluated at the initial visit before HSCT by one experienced dentist. The screening examination consisted of a clinical examination of the hard and soft oral tissues and a radiographic survey, including panoramic and occasional periapical films for symptomatic teeth. All dental diseases encountered, including caries, apical periodontitis, marginal periodontitis, and impacted third molar, were recorded for each patient. Dental foci were defined as caries, apical and marginal periodontitis, and partially erupted third molar.

A new protocol was designed to preserve diseased teeth whenever possible, compared with the previous protocol<sup>14</sup> (see Figure 1). This protocol defines the pre-HSCT dental treatment modality for the dental foci identified, taking into account a patient's status and treatment schedule. We describe the details of the protocol below:

Teeth with mild or moderate caries are restored in patients with sufficient time for dental treatment, but observed in those without enough time. Decayed teeth with pulpitis are treated by pulpectomy and root canal filling. The residual roots are extracted.

Teeth with recently symptomatic apical periodontitis or asymptomatic apical periodontitis and periapical radiolucency of the maximal diameter greater than 5 mm are treated with root canal in patients whose schedule permits, but the teeth are removed if there isn't enough time for treatment. Asymptomatic apical periodontitis with periapical radiolucency of less than 5 mm is not treated.

Marginal periodontitis, teeth with gingival swelling, pain and purulent discharge, a probing depth greater than 8 mm, or severe mobility are removed, whereas teeth with marginal periodontitis but without these signs and symptoms are observed and tooth brushing instruction and/or scaling is provided.

Partially erupted third molars affected with pericoronitis or purulent drainage are extracted, and asymptomatic third molars are not treated.

All patients, including those without dental foci, are given tooth brushing instructions to exfoliate dental plaque.

For the HSCT procedure, all patients were admitted to a disinfected room. During the conditioning period, each patient experienced at least one episode of a

temperature higher than 38 degrees C and an absolute white blood cell count (WBC) of less than 1,000/ml lasting more than several days, as manifestations of their immunosuppressed status. The dental follow-up was conducted during the only HSCT hospitalization, which was approximately 3 weeks long. Any patient with local signs and symptoms consistent with odontogenic infections, such as swelling, pain, redness, and sensitivity of the gingiva surrounding the teeth had a dental consultation and was given treatment as necessary. The frequency and occurrence of oral complaints and complications were recorded on the patients' medical charts and investigated throughout the course of HSCT therapy, and the effectiveness of the new detailed protocol was assessed by the attending dentists and hematologists.

## **Results**

The dental status of all the patients was evaluated between 7 and 240 days before the commencement of HSCT therapy, with a median of 47 days. Dental treatment must be complete 10 days before HSCT therapy, to give the patient time to undergo the conditioning regimen for HSCT. The time available for dental treatment was less than 1 month for 13 patients, from 1 to 2 months for 11, from 2 to 3 months for 7, and more than 3 months for 10. The patients with duration of more than 2 months between dental examination and the commencement of HSCT therapy were re-examined to check new dental disease within 1 month before HSCT therapy. Thirty-eight of the 41 patients (92.7%) had one or more dental diseases. Caries was discovered in 101 teeth in 26 patients, pulpitis in 5 teeth in 2 patients, apical periodontitis in 43 teeth in 19



patients, marginal periodontitis in 94 teeth in 24 patients, and partially erupted third molar in 21 teeth in 11 patients (Table 2). Three patients had no dental disease.

Using the new protocol, 36 patients received one or more kinds of dental treatment. Of 101 caries in 26 patients, 40 cases in 12 patients were restored, and the remaining 61 teeth of 14 patients were not treated. All five cases of pulpitis were treated with pulpectomy and root canal filling. Of 43 teeth with apical periodontitis in 19 patients, 41 were asymptomatic and 2 were symptomatic. Periapical lesions greater than 5 mm were observed in 10 teeth in 8 patients and lesions smaller than 5 mm in 33 teeth in 11. Seven teeth with asymptomatic lesions greater than 5 mm in 7 patients were removed, 5 teeth in 4 patients, including 2 that were symptomatic and 3 that were asymptomatic, that had a lesion of over 5 mm were treated endodontically, and the remaining 31 teeth in 13 patients with asymptomatic apical periodontitis and periapical lesions of less than 5 mm were followed without treatment. Of 94 teeth affected with marginal periodontitis, 6 teeth of 5 patients were removed, and the remaining 88 teeth of 24 patients were preserved with scaling and professional tooth brushing instruction. Only 3 of 21 partially erupted third molars were symptomatic. One patient had 2 symptomatic lower third molars. All 3 symptomatic teeth were extracted, and 8 upper and 10 lower asymptomatic third molars were not treated (Table 3). The planned dental treatment was completed for 36 patients before the initiation of the conditioning regimen. There was no new dental pathology at re-examination. All 41 patients, including the 5 that did not require dental treatment, underwent HSCT therapy without showing signs or symptoms associated with odontogenic infection.

The median number of days in which patients' temperature was higher than 38 degrees C during HSCT was 4, ranging from 0 to 60 days, with no significant

difference between bone marrow transplantation (BMT) and peripheral blood stem cell transplantation (PBSCT). The median number of days which the patients had a WBC of less than 1,000/ml was 17 ranging from 6 to 75 days for BMT, and 10 ranging from 0 to 12 days for PBSCT. There was a statistical difference in the number of days of WBC less than 1,000/ml between the two HSCT modalities.

Only two of the 41 patients (4.9%) experienced gingival pain before and during HSCT therapy. One was a 31-year-old female who complained of mild pain at the lower anterior gingiva, where gingivitis had been induced by anti-cancer agents. Another was a 30-year-old male who complained of mild pain at the gingiva of the upper third molar, which was under observation as asymptomatic. In both cases, there were no symptoms except pain, and there was no possibility of odontogenic infection. The pain of both patients resolved spontaneously, without treatment, and the scheduled HSCT therapy could continue. Thus, no alteration, interruption, or delay of HSCT therapy was required for any patient.

## **Discussion**

Pre-HSCT dental screening to identify and treat potential oral sources of infection has become standard care in patients scheduled for HSCT therapy<sup>3,7</sup>. The principal aim of the screening is to reduce morbidity and mortality that may arise from oral complications associated with HSCT therapy during immunosuppression. Although all potential sources of oral infection should be eliminated by dental treatment before the initiation of the conditioning regimen, time limitations and the severity of a patient's disease status frequently interfere with complete treatment<sup>3,6,7,13</sup>. Given this restriction, the removal of potentially preservable diseased teeth may be

the only viable treatment option available, resulting in oral care that does not best serve the long-term oral needs of the patients, because the removal of multiple teeth may compromise nutrition during and after HSCT therapy <sup>15</sup>. As a further complication of extraction, there is an associated increased risk of infection, bleeding, or delayed wound healing that could require postponing the scheduled HSCT therapy <sup>16-18</sup>.

A comparison between patients with no dental foci or completed dental treatment and those with dental foci or no dental interventions demonstrated that the impact of dental foci on the occurrence of post-HSCT infections was not statistically significant <sup>11</sup>. Patients with chronic dental pathology were reported to be safe in proceeding with chemotherapy without dental intervention, as the conversion of chronic dental disease to an acute state during chemotherapy occurs infrequently <sup>12</sup>. These reports suggest that intensive pre-HSCT dental treatment is not necessary. Furthermore, patients should avoid the additional morbidity or mortality associated with needless treatment. Consequently, minimal dental intervention is recommended.

Our previous dental management protocol was evaluated as significantly beneficial as a pre-HSCT dental treatment for patients scheduled to undergo HSCT therapy, but included removing potentially salvageable teeth to prevent the occurrence of infection during the therapy <sup>14</sup>. From our experience and the desire to preserve teeth if possible, we designed a new protocol for minimal intervention, in which the treatment modality is decided according to the severity of the disease, and only severely diseased teeth are extracted. The time available to treat dental disorders in the current study was longer than in other reports <sup>13</sup>, resulting in the completion of the planned dental treatments prior to the conditioning regimen in all patients. It is important that the planned treatment be completed before HSCT therapy, even if

minimal dental intervention is adopted, so early dental screening and treatment is essential. However the patients with duration of more than 2 months between the dental examination and the commencement of HSCT therapy had the possibility of arising new dental disease after dental examination. Therefore, we considered that the re-examination should be carried out in order not to miss new dental disease within 1 month before HSCT therapy.

Most studies and the current protocol agree about the treatment modality for caries, symptomatic periapical lesion, severe advanced marginal periodontitis, and symptomatic partially erupted third molar<sup>3, 7, 17, 19, 20</sup>. However, considerable controversy remains as to the best treatment for asymptomatic periapical lesion, chronic marginal periodontitis, and asymptomatic partially erupted third molar, and different dentists manage these pathologies with approaches that vary from very conservative to aggressive.

As regards asymptomatic apical periodontitis, one study suggests that there is no increase in the incidence of infectious complications during HSCT therapy when teeth with post-endodontic periapical radiolucencies of greater than 1.5 mm are not treated<sup>19</sup>. Our previous study also showed that untreated periapical radiolucencies smaller than 2 mm did not convert to the acute stage during HSCT therapy<sup>14</sup>. However, treatment is commonly required for large periapical lesions in the healthy population. In the present study, we did not treat asymptomatic periapical periodontitis with apical radiolucencies that were smaller than 5 mm, and there was no occurrence of conversion to the acute stage or of infectious complications. The patient outcomes of the present study suggest that it is safe not to treat asymptomatic apical lesions smaller than 5 mm before immunosuppressive conditioning.

Chronic marginal periodontitis is the most common significant dental infection that affects HSCT patients<sup>4, 6, 21</sup>. A retrospective investigation reported that 64% of patients with chronic periodontal diseases had positive blood cultures associated with clinical signs of septicemia during the initial 100 days after HSCT<sup>15</sup>. However, because little data are available about the effect of pre-HSCT dental treatment for chronic periodontitis on the incidence of infectious complications, the treatment modality has varied from observing the affected teeth to removing asymptomatic teeth<sup>22-24</sup>. Teeth with a poor periodontal prognosis are generally extracted, but no relationship has been found between radiographic periodontal status and the incidence of septicemia<sup>15</sup>. In the present protocol, only symptomatic teeth with acute conversion, a probing depth greater than 8 mm, or severe mobility were extracted; teeth without these symptoms were treated with scaling, and the patient was instructed in proper brushing technique. There was no occurrence of infectious complications in these patients. These outcomes indicate that teeth with chronic marginal periodontitis, except for actively infectious teeth, can be treated conservatively.

There are two basic treatment options for managing an impacted, asymptomatic third molar. Some advocate prophylactic extraction as soon as possible<sup>22, 25</sup>, whereas others prefer a more conservative approach<sup>17, 26</sup>, because the risk of developing diseases associated with the third molar may be further reduced if the patient has good oral hygiene. In one study, 40% of patients who underwent the prophylactic removal of partially erupted or impacted third molars, which were symptomatic or asymptomatic, experienced postoperative complications, such as bleeding, alveolitis, trismus, or infection, in the course of intensive cancer therapy, including BMT<sup>17</sup>. The complication rate among these patients was much higher than that reported in healthy population<sup>27</sup>. In that report, the symptoms of most non-extracted symptomatic third

molars were treated with antibiotics and analgesics, but the impact on the outcomes of the scheduled HSCT therapy was not described. In the current protocol, symptomatic third molars were removed, and asymptomatic third molars were untreated, and there was no occurrence of odontogenic infection <sup>17</sup>. The outcomes obtained using this management approach indicate that extraction for symptomatic third molars and non-intervention for asymptomatic ones is a safe treatment.

After completing the dental treatments, which followed the newly designed protocol, all the patients received their scheduled HSCT therapy without alteration, interruption, or delay, and they did not experience signs or symptoms associated with odontogenic infection during the immunosuppressive stages. Consequently, the new protocol is likely to be appropriate for guiding the pre-HSCT dental treatment of patients with hematological diseases.

Some studies report that systemic oral assessment, regular encouragement of patient self-care, and consistent oral care may be the most important factors related to the prevention or amelioration of oral infection during HSCT therapy <sup>7, 21, 28</sup>. In addition to the management of oral diseases, patient caregivers should provide careful instructions in advance about oral care during the immunosuppressive stages. Before dental treatment, all patients in the present study were educated to exfoliate dental plaque, which produces dental caries and marginal periodontitis. The extent to which the dental instruction influenced the absence of oral infection in the present study is unknown, but we believe the instruction was beneficial. Further studies with a larger sample size are required to confirm the appropriateness of the newly designed dental treatment protocol.

## References

1. Bortin MM, Horowitz MM, Gale RP, Barrett AJ, Champlin RE, Dicke KA, *et al.* Changing trends in allogeneic bone marrow transplantation for leukemia in the 1980s. *JAMA* 1992; **268**: 607-12.
2. Appelbaum FR. Use of bone marrow and peripheral blood stem cell transplantation in the treatment of cancer. *CA Cancer J Clin* 1996; **46**: 142-64.
3. Centers for Disease Control and Prevention. Guidelines for preventing opportunistic infection among hematopoietic stem cell transplant recipients. *MMWR Recomm Rep* 2000; **49** (RR-10):1-128.
4. Overholser CD. Periodontal infection in patients with acute non-lymphocytic leukemia: prevalence of acute exacerbations. *Arch Intern Med* 1982; **142**: 551-4.
5. Sonis S, Kunz A. Impact of improved dental services on the frequency of oral complications of cancer therapy for patients with non-head-and-neck malignancies. *Oral Surg Oral Med Oral Pathol* 1998; **65**: 19-22
6. Peterson DE. Pretreatment strategies for infection prevention in chemotherapy patients. *NCI Monogr* 1990; **9**: 61-71.
7. Barker GJ. Current practices in the oral management of the patient undergoing chemotherapy or bone marrow transplantation. *Support Care Cancer* 1999; **7**: 17-20.
8. National Institutes of Health Consensus. Development Panel. Consensus statement: oral complications of cancer therapy. *NCI Monogr* 1990; **9**: 3-8.
9. Heimdahl A, Mattsson T, Dahllof G, Lonnquist B, Ringden O. The oral cavity as a port of entry for early infections in patients treated with bone marrow transplantation. *Oral Surg Oral Med Oral Pathol* 1989; **68**: 711-6.

10. Bergmann O. Oral infections and septicemia in immunocompromised patients with hematologic malignancies. *J Clin Microbiol* 1988; **26**: 2105-9.
11. Melkos AB, Massenkeil G, Arnold R, Reichart PA. Dental treatment prior to stem cell transplantation and its influence on the posttransplantation outcome. *Clin Oral Invest* 2003; **7**: 113-115.
12. Toljanic JA, Bedard JF, Larson RA, Fox JP. A prospective pilot study to evaluate a new dental assessment and treatment paradigm for patients scheduled to undergo intensive chemotherapy for cancer. *Cancer* 1999; **85**: 1843-8.
13. Elad S, Garfunkel AA, Or R, Michaeli E, Shapira MY, Galili D. Time limitations and the challenge of providing infection-preventing dental care to hematopoietic stem-cell transplantation patients. *Support Care Cancer* 2003; **11**: 674-677.
14. Yamagata K, Onizawa K, Yoshida H, Hasegawa Y, Nagasawa T. Dental management of patients before bone marrow transplantation. *Jpn J Transplant* 1998; **34**: 22-26 (abstract in English)
15. Akintoye SO, Brennan MT, Graber CJ, Mckinney BE, Rams TE, Barret AJ, *et al.* A retrospective investigation of advanced periodontal disease as a risk for septicemia in hematopoietic stem cell and bone marrow transplant recipients. *Oral Surg Oral Med Oral Pathol Oral Radiol Endod* 2002; **94**: 581-8.
16. Barasch A, Mosier KM, Ambrosion JAD, Giniger MS, Ascensao J, Peterson DE. Postextraction osteomyelitis in a bone marrow transplant recipient. *Oral Surg Oral Med Oral Pathol* 1993; **75**: 391-6.
17. Tai CCE, Precious DS, Wood RE. Prophylactic extraction of third molars in cancer patients. *Oral Surg Oral Med Oral Pathol* 1994; **78**: 151-5.



18. Overholser CD, Peterson DE, Bergman SA, Williams LT. Dental extraction in patients with acute nonlymphocytic leukemia. *J Oral Maxillofac Surg* 1982; **40**: 296-8.
19. Peters E, Monopoli M, Woo SB, Sonis S. Assessment of the need for treatment of postendodontic asymptomatic periapical radiolucencies in bone marrow transplant recipients. *Oral Surg Oral Med Oral Pathol* 1993; **76**: 45-8.
20. Raut A, Huryn JM, Hwang FR, Zlotolow IM. Sequelae and complications related to dental extractions in patients with hematologic malignancies and the impact on medical outcome. *Oral Surg Oral Med Oral Pathol Oral Radiol Endod* 2001; **92**: 49-55.
21. Majorana A, Schubert MM, Porta F, Ugazio AG, Sapelli PL. Oral complications of pediatric hematopoietic cell transplantation: diagnosis and management. *Support Care Cancer* 2000; **8**: 353-365.
22. Maxymiw WG, Wood RE. The role of dentistry in patients undergoing bone marrow transplantation. *Br Dent J* 1989; **167**: 229-33.
23. Lazarchik DA, Miller SJ, Winkler MP. Dental evaluation in bone marrow transplantation. *Gen Dent* 1995; **43**: 369-71.
24. Sonis ST, Woods PD, White BA. Pretreatment oral assessment. *NCI Monogr* 1990; **9**: 29-32.
25. Carl W. Bone marrow transplants and oral complications. *Quintessence Int* 1984; **10**: 1001-9.
26. Mercier P, Precious D. Risks and benefits of removal of impacted third molars. *Int J Oral Maxillofac Surg* 1992; **21**: 17-27.
27. Bruce RA, Frederickson GC, Small GS. Age of patients and morbidity associated with mandibular third molar surgery. *J Am Dent Assoc* 1980; **101**: 240-5.

28. Borowski B, Benhamou E, Pico JL, Laplanche A, Margainaud JP, Hayat M.  
Prevention of oral mucositis in patients treated with high-dose chemotherapy and  
bone marrow transplantation: a randomized controlled trial comparing two  
protocols of dental care. *Eur J cancer B Oral Oncol* 1994; **30**: 93-97.

**Table 1 Oncologic diagnosis and medical treatment**

<i>Disease</i>	No. of patients
Chronic myeloid leukemia (CML)	14
Malignant lymphoma (ML)	7
Acute myeloid leukemia (AML)	4
Non-Hodgkin's lymphoma (NHL)	4
Myelodysplastic syndrome (MDS)	4
Multiple myeloma (MM)	3
Acute lymphoid leukemia (ALL)	3
Others	2

<i>Medical treatment</i>	No. of patients
Bone marrow transplant (BMT)	28
Peripheral blood stem cell transplant (PBSCT)	13

**Table 2 Dental diseases**

Dental Disease	No. of patients	No. of teeth
Caries	26	101
Pulpitis	2	5
Apical periodontitis	19	43
Marginal periodontitis	24	94
Partially erupted third molar	11	21

\* More than one odontogenic disorder was diagnosed in some patients.

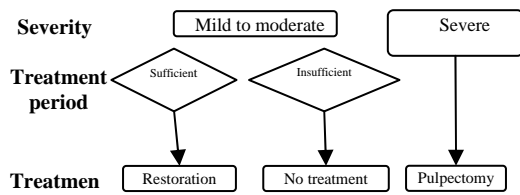
**Table 3 Dental treatment outcome**

Dental treatment	No. of patients	No. of teeth
Restoration	12	40
Scaling	24	
Professional tooth brushing instruction	21	
Extraction	10	14
Apical periodontitis	7	7
Marginal periodontitis	5	6
Partially erupted third molar	2	3
Pulpectomy	2	5
Endodontic treatment	4	5

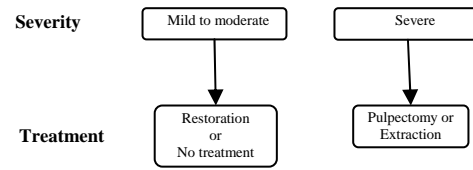
## Present protocol

## Previous protocol <sup>14</sup>

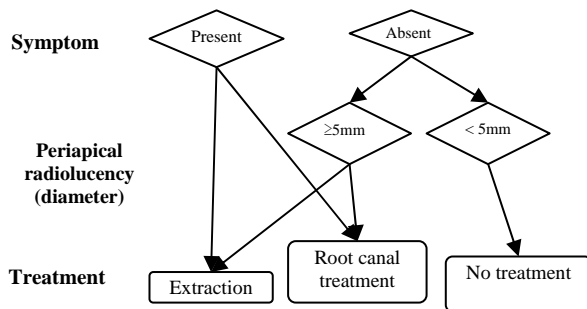
### Caries



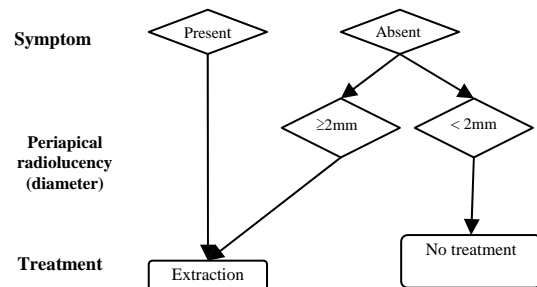
### Caries



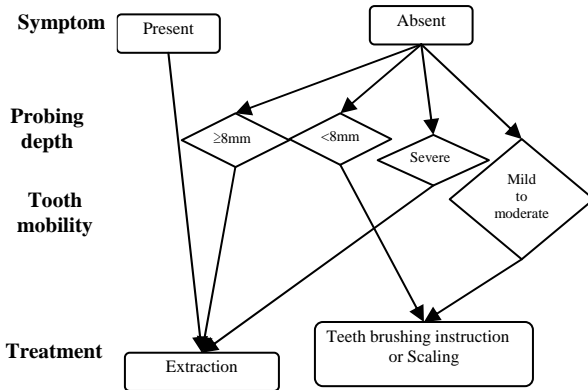
### Apical Periodontitis



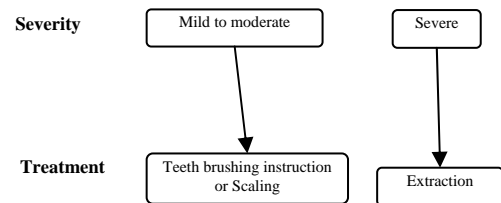
### Apical Periodontitis



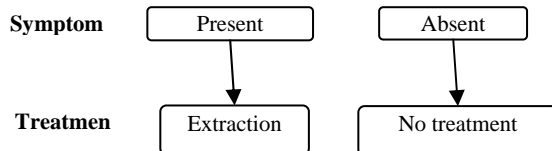
### Marginal Periodontitis



### Marginal Periodontitis



### Partially erupted third molar



### Partially erupted third molar

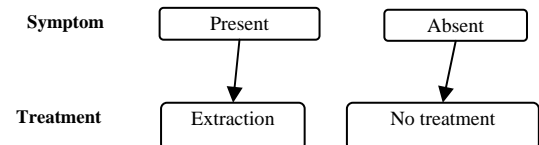


Figure 1 Dental treatment Protocol for HSCT candidates