

Journal of Nephrologist



Acute kidney injury due to cytokine storm in patients with COVID-19 infection

Sepehr Ebrahimi-Dehkordi¹, Hasan Banitalebi², Ali Hasanpour-Dehkordi^{3*}

¹Medical Faculty, Shahrekord University of Medical Sciences, Shahrekord, Iran

²Department of Diagnostic Imaging, Akershus University Hospital, Norway

³Social Determinants of Health Research Center, School of Allied Medical Sciences, Shahrekord University of Medical Sciences, Shahrekord, Iran

ARTICLE INFO

Article type:
Mini Review

Article history:
Received: 14 June 2020
Accepted: 1 July 2020
Published online: 22 July 2020

Keywords:
Acute kidney injury
Cytokine storm
COVID-19
Cytokines

ABSTRACT

Patients with severe acute respiratory syndrome coronavirus-2 (SARS-CoV-2) or COVID-19 represents usually a variety range of symptoms related to influenza-like syndrome and respiratory tract infections. Likewise, kidney involvement and acute kidney injury (AKI) were reported in many previous studies. Although a hypovolemic circulation would be the most common reason in patients with AKI, some strong proofs are suggesting a cytokine storm due to immune system exaggeration and inflammation-mediated tubular injury in COVID-19 infections. The inflammatory response in cytokine storm leads to the high release of cytokines mostly including TNF α , IL-1 β , IL-6, INF γ , IL-2, IL-7, and endothelial mediators. The main culprits in the AKI and consequent organ failure are resident leukocytes in specific tissues, activated following the cytokine release, and systemic inflammatory response. AKI management and cytokine profile evaluation should be highly emphasized in patients with COVID-19 to prevent the progression of chronic kidney disease or permanent renal failure. Treatment options in COVID-19 regarding no specific drugs should be supportive and based on stabilizing the patients; however, combination therapy with different antiviral have shown promising outcomes. As a result, utilizing the anti-TNF α and anti-IL-1 agents should be noticed if indicated. Additionally, the hematopoietic stem cell transplantation is a curative approach.

Implication for health policy/practice/research/medical education:

We are willing to convey the fact that COVID-19 patients need to be more concerned about the renal system complications and acute kidney injury, in particular. Evidentially, it has been suggested that the severe inflammatory response triggered by COVID-19-mediated infection may have a crucial role in tissue damage in kidney and renal failure development. Hence, the lethal renal complications should be minded, especially in elderly who met the COVID-19 infection.

Please cite this paper as: Ebrahimi-Dehkordi S, Banitalebi H, Hasanpour-Dehkordi A. Acute kidney injury due to cytokine storm in patients with COVID-19 infection. J Nephrologist. 2021;10(4):e37. DOI: 10.34172/jnp.2021.37.

Introduction

Severe acute respiratory syndrome coronavirus-2 (SARS-CoV-2) or COVID-19, nowadays, has stood in the center of attention and arisen a pandemic situation throughout the world. As it then cleared, the first transmission of COVID-19 occurred in seafood markets (1,2). Firstly, the pathogen reported in Dec 2019 in Wuhan, China, and then, spread rapidly in other countries. The COVID-19 related symptoms or even disease severity may be different interestingly in each person, however, the respiratory tract tends to be most affected. The cardinal manifestations

of COVID-19 infection often mimic an influenza-like syndrome including fever, dyspnea, non-productive cough, and myalgia. Infection is more severe in the elderly group (3). Additionally, based on next further investigations in hospital settings it has illustrated that kidneys are also one of the main sites of disease invasion accompanying higher morbidity, therefore, it gains serious clinical attention (4).

Materials and Methods

For this mini-review article, we used a variety of sources by searching in PubMed, Scopus, Embase, Google Scholar

*Corresponding author: Ali Hasanpour-Dehkordi, Email: alihassanpourdehkordi@gmail.com, hasanpour.A@skums.ac.ir

and Web of Science to collect current data about our title. The search was conducted using various keywords or their equivalents: COVID-19, angiotensin-converting enzyme 2 receptor, acute kidney injury, cytokine storm, cytokines, end-stage renal disease, hyperinflammatory syndrome and hemophagocytic lymphohistiocytosis

Kidney as a site of involvement in COVID-19

Following further molecular and physiological exploration about the manner that the COVID-19 virus could adhere and invade to the cells, a body of evidence suggests ACE2 (angiotensin-converting enzyme 2) receptors which are located in the lungs and kidneys act as the main bridging of virus entrance. ACE2 receptors not only mediate the COVID-19 receptors binding but also help the other respiratory viruses to enter into the cell, eventually. ACE2 receptors have been demonstrated to contribute the angiotensin I conversion to angiotensin II and have a crucial role in hemostasis maintenance. As a result, we can see the kidney involvement trace in COVID-19 infection (5–7). An observational clinical study in China on COVID-19 patients suggested evidence of kidney involvement by referring to laboratory findings including proteinuria, hematuria, high serum creatinine, and azotemia-associated acute kidney injury (AKI) (8). Concerning acute kidney failure, although the patient may not be diagnosed with AKI in the early stages of admission, a fraction of those will disclose the clinical and laboratory evidence of an overt AKI. COVID-19-related AKI has a remarkable tendency around five times to progress to end-stage renal disease (ESRD) and death. Besides, previous studies have demonstrated the occurrence of acute renal dysfunction, AKI, and high mortality rate even ranges between 60%-90% in other members of Coronaviruses family such as SARS-CoV and MERS-CoV which bold the importance of the exact renal management in these patients (9,10).

Clinical and laboratory findings in COVID-19-associated AKI

There is a clinical turning point around a week after admission which patients may experience symptoms more exaggerated. Paraclinical findings suggest a considerable increase in IL-6, ferritin, and C-reactive protein representing an ongoing inflammatory process that can lead to sepsis and consequent multi-organ damages such as kidney failure (11). There is a broad controversy about the exact mechanism of AKI in COVID-19; However, it seems that an underlying occult viral sepsis can develop a cytokine storm and progresses to kidney injury (12).

Cytokine storm and AKI in COVID-19

Cytokine storm is introduced as a category of potentially

lethal hyperinflammatory syndromes that promote a hemophagocytosis reaction. Secondary hemophagocytic lymphohistiocytosis (sHLH) includes as a subtype of cytokine storm which is characterized by non-remitting fever, hyperferritinemia, cytopenia, organomegaly and hypertriglyceridemia (13). A common form of sHLH is a virus-associated hemophagocytic syndrome which introduced by Risdall in 1979. viral pathogens like herpes viruses and Epstein–Barr virus particularly are the most commonly associated with infection-induced sHLH; However, bacterial, fungal, and parasitic pathogens may have a role in this phenomenon (14). Infrequently, the influenza virus could have a role in developing sHLH in children (15). A severe cytokine release syndrome like what have seen in HLH can develop AKI in patients (16). Moreover, there is a strong link between HLH and organ failure, including kidney failure. AKI is the most common consequence of HLH, for a variety of reasons. The most common mechanism described for AKI is an increase in capillary permeability and pre-renal azotemia. Surprisingly, patients with HLH have normal hemodynamics while there is severe tubular damage pathologically due to the infiltration of leukocytes. During AKI, the tubular component is more affected than the glomerular one, yet glomerular dysfunction can occur rarely followed by the destruction of podocytes structures by TNF α . After binding to receptors, TNF α mediates the accumulation of granulocytes and resident lymphocytes in the tissue, then activating apoptotic signaling kinase-1 (ASK1) in tubular cells, and eventually tissue injury (17–19).

Pathogenesis of kidney failure due to cytokine storm

The detrimental inflammatory response in cytokine storm may develop the organ dysfunction which usually progresses in the early and late phases. Both the pro-inflammatory cytokines including TNF- α , IL-1 β , IL-6, INF γ , IL-2, IL-7, granulocyte colony-stimulating factor, monocyte chemoattractant protein 1 and macrophage inflammatory protein 1- α , and also inhibitory cytokines (IL-10) are found in cytokine storm (20,21). After the onset of a cytokine storm, almost always excessive pro-inflammatory factors release from leukocytes which boost the activation of endothelial vascular cells. Endothelial cells lining the vascular bed in vital organs produce free mediators including endothelial leukocyte adhesion molecule 1/vascular cell adhesion molecule 1. These released mediators of endothelial cells, in turn, activate neutrophils, macrophages, and other types of leukocytes to adhere and help them to pass through the vascular wall called diapedesis and initiate the production of secondary inflammatory mediators such as prostaglandins and proteases to expand the tissue damage. Finally, in the advanced stage of undiagnosed cytokine storm that

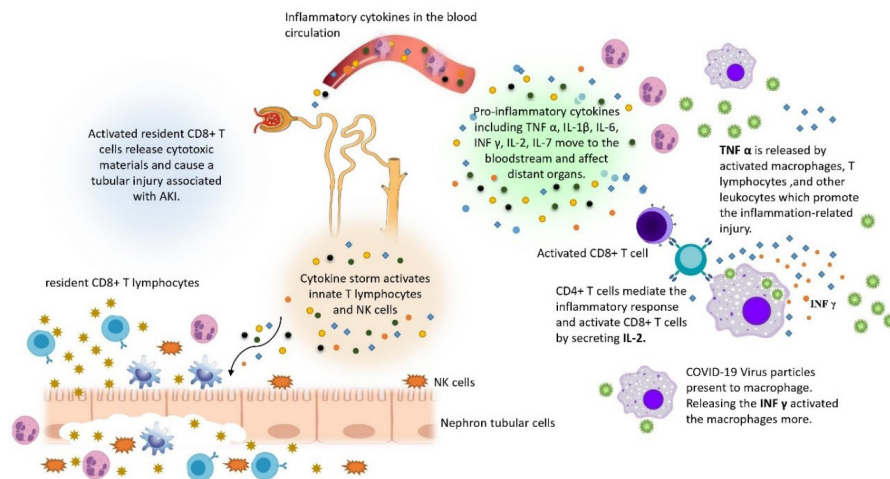


Figure 1. Molecular mechanism of distant tissue injury in viral-associated cytokine storm. Overproduction of immune mediators leads to a systemic inflammation response and affects tubular component of kidneys by activating the resident CD8⁺ T-cells.

can be significantly lethal, the circulating inflammatory mediators particularly reactive oxygen species and T cell cytokines arouse a systemic inflammatory response, pass within the bloodstream, and activate the resident innate leukocytes including CD8⁺ T cell and NK cells in specific organ tissues which are the main culprits for specific organ failure (22) (Figure 1).

Treatment

AKI advancement and the permanent sequelae leading to chronic kidney disease are more common in ICU-hospitalized COVID-19 subjects. Hence, as mentioned earlier, the kidneys function needs to be paid more attention clinically (10). Of all involved cytokines, IL-6 and TNF α are more likely to have a certain role in promoting the symptoms of cytokine storm. Therefore in a clinical view, the hyper inflammatory reactions due to cytokine storm or related causes have addressed with TNF α inhibitors and anti-IL-6 receptor antibodies (20,23,24). Additionally, one of the most helpful therapeutic strategies to harness the cytokines uprising is CD8⁺ T cell-derived INF γ inhibition and IL-1 β antagonists (25). Steroid (dexamethasone) and topoisomerase 2 inhibitor (etoposide) combination therapy can be a treatment approach according to previous researches. After the T cell silence, the patient is a candidate to receive the certain curative hematopoietic stem cell transplantation (26–28). Promising therapeutic response of familial HLH to ruxolitinib as a JAK1/2 inhibitor which reported by Maschalidi et al (29) and Das et al (30) may be considered for clinical perspectives by prohibiting T cell signaling pathways. Secondary hemophagocytic lymphohistiocytosis either occurs in viral infection or 3.7%-4.3% of sepsis cases (21). Besides the right management of cytokines profile and inflammatory indices, patients with COVID-19 infection usually need

to receive respiratory care conventionally. Additionally, if needed, kidney replacement therapy should be considered for a patient with AKI or impending kidney failure due to the cytokine storm. No specific vaccine or drug has been developed for this disease so far, and further trials continue. In addition to antiviral treatments including antiretroviral agents like lopinavir and ritonavir, nucleoside analog drugs like remdesivir have been shown to be effective as an anti-rheumatoid drug (31,32).

Conclusion

The impact of COVID-19 infection on the renal system needs to be considered, particularly in the elderly which represent the kidney impairment signs more severe. AKI in the context of tubular injury taught to be caused by a systemic inflammatory response; therefore, besides the supportive management and oxygen regulation, anti-inflammatory agents such as anti-TNF α , anti-IL-1, and anti-IL-6 should be administered if necessary.

Acknowledgments

Wholeheartedly, we appreciate all the colleagues who bested us to perform this investigation.

Authors' contribution

AHD, SE and HB were the principal investigators of the study. AHD and SE were included in preparing the concept and design. All of researchers revised the manuscript and critically evaluated the intellectual contents. All authors have read and approved the content of the manuscript and confirmed the accuracy or integrity of any part of the work.

Conflicts of interest

The authors state no conflicts of interest.

Ethical considerations

Ethical issues (including plagiarism, data fabrication, double publication) have been completely observed by the authors.

Funding/Support

None.

References

- Wang P, Lu J, Jin Y, Zhu M, Wang L, Chen S. Epidemiological characteristics of 1212 COVID-19 patients in Henan, China. medRxiv.2020.doi:10.1101/2020.02.21.20026112.
- Li Q, Guan X, Wu P, Wang X, Zhou L, Tong Y, et al. Early transmission dynamics in Wuhan, China, of novel coronavirus-infected pneumonia. *N Engl J Med.* 2020;382:1199–207. doi: 10.1056/NEJMoa2001316 .
- Lauer SA, Grantz KH, Bi Q, Jones FK, Zheng Q, Meredith HR, et al. The incubation period of coronavirus disease 2019 (COVID-19) from publicly reported confirmed cases: estimation and application. *Ann Intern Med.* 2020;172:577–82. doi: 10.7326/M20-0504.
- Lillie PJ, Samson A, Li A, Adams k, Capstick R, Barlow G, et al. Novel coronavirus disease (Covid-19): the first two patients in the UK with person to person transmission. *J Infect.* 2020. doi: 10.1016/j.jinf.2020.02.020.
- Zou X, Chen K, Zou J, Han P, Hao J, Han Z. Single-cell RNA-seq data analysis on the receptor ACE2 expression reveals the potential risk of different human organs vulnerable to 2019-nCoV infection. *Front Med.* 2020;14:185-92. doi: 10.1007/s11684-020-0754-0.
- Pan XW, Xu D, Zhang H, Zhou W, Wang LH, Cui XG. Identification of a potential mechanism of acute kidney injury during the COVID-19 outbreak: a study based on single-cell transcriptome analysis. *Intensive Care Med.* 2020;46:1114-6. doi: 10.1007/s00134-020-06026-1
- Chai X, Hu L, Zhang Y, Han W, Lu Z, Ke A, et al. Specific ACE2 expression in cholangiocytes may cause liver damage after 2019-nCoV infection. bioRxiv. 2020. doi: 10.1101/2020.02.03.931766.
- Cheng Y, Luo R, Wang K, Zhang M, Wang Z, Dong L. et al. Kidney impairment is associated with in-hospital death of COVID-19 patients. *MedRxiv.* 2020. doi: 10.1101/2020.02.18.20023242.
- Li Z, Wu M, Yao J, et al. Caution on kidney dysfunctions of COVID-19 patients. 2020. doi:10.2139/ssrn.3559601.
- Veerdonk F, Netea M, Deuren M, Meer J, Mast Q, Bruggemann R, et al. Kinins and Cytokines in COVID-19: A Comprehensive Pathophysiological Approach. Preprints. 2020. doi: 10.20944/preprints202004.0023.v1.
- Tisoncik JR, Korth MJ, Simmons CP, Farrar J, Martin TR, Katze MG. Into the Eye of the Cytokine Storm. *Microbiol Mol Biol Rev.* 2012;76:16–32. doi: 10.1128/mbr.05015-11.
- Sekine T, Galgano D, Casoni GP, Meeths M, Bryceson YT. CD8+ T Cell Biology in Cytokine Storm Syndromes. In: *Cytokine Storm Syndrome.* Springer; 2019. p. 141–61. doi: 10.1007/978-3-030-22094-5_9.
- Risdall RJ, McKenna RW, Nesbit ME, Krivit W, Balfour H, Simmons R, et al. Virus-associated hemophagocytic syndrome A benign histiocytic proliferation distinct from malignant histiocytosis. *Cancer.* 1979;44:993–1002. doi: 10.1002/1097-0142(197909)44:3<993::aid-cncr2820440329>3.0.co;2-5.
- Ünal Ş, Gökçe M, Aytaç-Elmas S, Karabulut E, Altan I, Özkaya-Parlakay A, et al. Hematological consequences of pandemic influenza H1N1 infection: a single center experience. *Turk J Pediatr.* 2010;52:570.
- Kantarjian H, Stein A, Gökbuğet N, Fielding A, Schuh A, Ribera J, et al. Blinatumomab versus chemotherapy for advanced acute lymphoblastic leukemia. *N Engl J Med.* 2017;376:836–47. doi:10.1056/NEJMoa1609783.
- Al-Lamki R, Wang J, Vandenabeele P, Bradley J, Thiru S, Luo D, et al. TNFR1-and TNFR2-mediated signaling pathways in human kidney are cell type-specific and differentially contribute to renal injury. *FASEB J.* 2005;19:1637-45. doi: 10.1096/fj.05-3841com.
- Al-Lamki RS, Mayadas TN. TNF receptors: signaling pathways and contribution to renal dysfunction. *Kidney Int.* 2015;87:281-96. doi: 10.1038/ki.2014.285.
- McGonagle D, Sharif K, O'Regan A, Bridgewood C. Interleukin-6 use in COVID-19 pneumonia related macrophage activation syndrome. *Autoimmun Rev.* 2020. doi: 10.1016/j.autrev.2020.102537.
- Shimabukuro-Vornhagen A, Gödel P, Subklewe M, Stemmler H, Schlößer H, Schlaak M, et al. Cytokine release syndrome. *J Immunother Cancer.* 2018;6:56. doi: 10.1186/s40425-018-0343-9.
- Mehta P, McAuley DF, Brown M, Sanchez E, Tattersall RS, Manson JJ. COVID-19: consider cytokine storm syndromes and immunosuppression. *Lancet.* 2020;395:1033-4. doi: 10.1016/S0140-6736(20)30628-0.
- Wang H, Ma S. The cytokine storm and factors determining the sequence and severity of organ dysfunction in multiple organ dysfunction syndrome. *Am J Emerg Med.* 2008;26:711–5. doi: 10.1016/j.ajem.2007.10.031.
- Grupp S, Kalos M, Barrett D, Aplenc R, Porter D, Rheingold S, et al. Chimeric antigen receptor–modified T cells for acute lymphoid leukemia. *N Engl J Med.* 2013;368:1509-18. doi: 10.1056/NEJMoa1215134.
- Davila M, Riviere I, Wang X, Bartido S, Park J, Curran K, et al. Efficacy and toxicity management of 19-28z CAR T cell therapy in B cell acute lymphoblastic leukemia. *Sci Transl Med.* 2014;6:1-10. doi: 10.1126/scitranslmed.3008226.
- Schmid JB, Ho C, Chrétien F, et al. Neutralization of IFN γ defeats haemophagocytosis in LCMV-infected perforin-and Rab27a-deficient mice. *EMBO Mol Med.* 2009;1:112–2. doi: 10.1002/emmm.200900009.
- Bergsten E, Horne A, Aricó M, Astigarraga I, Egeler R, Filipovich A, et al. Confirmed efficacy of etoposide and dexamethasone in HLH treatment: long-term results of the cooperative HLH-2004 study. *Blood, J Am Soc Hematol.* 2017;130:2728–38. doi: 10.1182/blood-2017-06-788349.
- Johnson TS, Terrell CE, Millen SH, Katz JD, Hildeman DA,

- Jordan MB. Etoposide selectively ablates activated T cells to control the immunoregulatory disorder hemophagocytic lymphohistiocytosis. *J Immunol.* 2014;192:84–91. doi: 10.4049/jimmunol.1302282.
27. Ehl S. Etoposide for HLH: the limits of efficacy. *Blood, J Am Soc Hematol.* 2017;130:2692–3. doi: 10.1182/blood-2017-10-808543.
28. Maschalidi S, Sepulveda FE, Garrigue A, Fischer A, de Saint Basile G. Therapeutic effect of JAK1/2 blockade on the manifestations of hemophagocytic lymphohistiocytosis in mice. *Blood, J Am Soc Hematol.* 2016;128:60–71. doi: 10.1182/blood-2016-02-700013.
29. Das R, Guan P, Sprague L, Verbist K, Tedrick P, An Q, et al. Janus kinase inhibition lessens inflammation and ameliorates disease in murine models of hemophagocytic lymphohistiocytosis. *Blood, J Am Soc Hematol.* 2016;127:1666–75. doi: 10.1182/blood-2015-12-684399.
30. Gao J, Tian Z, Yang X. Breakthrough: Chloroquine phosphate has shown apparent efficacy in treatment of COVID-19 associated pneumonia in clinical studies. *Biosci Trends.* 2020. doi: 10.5582/BST.2020.01047.
31. Naicker S, Yang C-W, Hwang S-J, Liu B-C, Chen J-H, Jha V. The Novel Coronavirus 2019 epidemic and kidneys. *Kidney Int.* 2020; 97(5):824–8. doi: 10.1016/j.kint.2020.03.001.

Copyright © 2021 The Author(s); Published by Society of Diabetic Nephropathy Prevention. This is an open-access article distributed under the terms of the Creative Commons Attribution License (<http://creativecommons.org/licenses/by/4.0>), which permits unrestricted use, distribution, and reproduction in any medium, provided the original work is properly cited.