

Journal of Nephrologist

CrossMark
click for updates

A case of glomerulonephritis showing remarkable segmental extracapillary proliferation; Is this a new category disease or not?

Seiji Hashimoto^{1*}, Risshi Kudo², Mamiko Shimamoto², Rie Yamamoto³, Tomochika Maoka³, Keisuke Kawashima³, Yuichiro Fukasawa⁴, Takao Koike⁵, Takashi Shigematsu⁶

¹Department of Nephrology, Kinan Hospital, Tanabe, Japan

²Department of Nephrology, JCHO Hokkaido Hospital, Sapporo, Japan

³Department of Nephrology, NTT East Japan Sapporo Hospital, Sapporo, Japan

⁴Department of Pathology Diagnosis, Sapporo City General Hospital, Sapporo, Japan

⁵Department of Internal Medicine II, Hokkaido University School of Medicine, Sapporo, Japan

⁶Department of Nephrology, Wakayama Medical University, Wakayama, Japan

ARTICLE INFO

Article type:
Case Report

Article history:
Received: 3 March 2018
Accepted: 10 June 2018
Published online: 29 June 2018

Keywords:
Extracapillary proliferation
Renal failure
Steroid therapy

ABSTRACT

Background: Significant capillary proliferation is common in post-streptococcal acute glomerulonephritis (PSAGN) after streptococci and is a prognostic disease. Focal segmental glomerulosclerosis is a disease characterized by segmental sclerosis although it may have a poor prognosis

Case Presentation: A 50-year-old man with nephrotic syndrome underwent renal biopsy, which showed marked endocapillary proliferation due to enlarged vascular endothelial cells and infiltration of lymphocytes. However, there was no mesangial cell proliferation, mesangial matrix increase, or crescent formation. Electron microscopy showed fusion of podocytes without any electron-dense deposits. Immunostaining for CD68 and CD3 was positive, and the presence of macrophages and T-cells was suggested. Steroid therapy, including pulse therapy, was performed, and then cyclosporine was added to steroid therapy. Although urinary protein decreased, his renal function did not respond well to steroid therapy, and the patient initiated dialysis 2 years later.

Conclusions: We report this case considering that it was nephritis of unknown origin showing segmental endocapillary proliferation that had not been recognized previously.

Case report

Implication for health policy/practice/research/medical education:

Here we presented a case considering that it was nephritis of unknown origin showing segmental endocapillary proliferation that had not been recognized previously.

Please cite this paper as: Hashimoto S, Kudo R, Shimamoto M, Yamamoto R, Maoka T, Kawashima K, et al. J Nephrologist. 2018;7(4):286-289. DOI: 10.15171/jnp.2018.56.

1. Background

Our understanding of renal diseases based on histological findings and their histological classification system is advancing. For example, an improved understanding of the role of the complement system in the pathogenesis of membranoproliferative glomerulonephritis (MPGN) led to a reclassification, and a new grouping of diseases known as the C3 glomerulopathies and C3 glomerulonephritis

has been proposed (1). On the other hand, the involvement of the complement cascade, streptococcal pyrogenic exotoxin B (SPEB) (2) and nephritis-associated plasmin receptor (NAP1r) have been identified as the risk factors for infection-related glomerulonephritis (3). We report a case of nephritis that did not fit into the existing classification scheme. The patient had nephrosis, and biopsy showed segmental endocapillary proliferation.

*Corresponding author: Seiji Hashimoto, seijinih@med.hokudai.ac.jp

As the disease was refractory to treatment, the patient developed renal failure.

2. Case Presentation

The patient was a 50-year-old man with a chief complaint of edema of the lower legs. He had been receiving treatment for diabetes mellitus at a local clinic for 20 years. His glycemic control was relatively good, with an HbA1c level of six or less. Recently, the patient had received dietary education alone and had not been taking medication. Last year, the patient was found to be positive for urinary protein and have renal dysfunction [serum creatinine (Cr); 1.3 mg/dL]. At that time, there was no antecedent infection, such as hemolytic streptococcus. Approximately six months later, the patient presented with exacerbated urinary findings (urinary protein ++; occult blood urine ++) and edema of the lower legs. Although diabetic nephropathy was considered in the differential diagnoses, the patient had no diabetic retinopathy and his glycemic control was relatively good. The patient was suspected of having primary glomerulonephritis and referred to our department. His past history was not remarkable. Family history was not remarkable except for mild diabetes mellitus in his father. Laboratory findings on admission are shown in Table 1. His urinary protein was 3.94 g/gCr, occult blood urine was +++, and Cr was 1.80 mg/dL, indicating nephrotic syndrome and renal dysfunction. The patient was admitted to the hospital and underwent renal biopsy. Specimens obtained from renal biopsy were 16 glomeruli, among which 7 were sclerotic. The characteristic

findings were glomerulus showing significant segmental endocapillary proliferation and glomerular capillary lumen filled with macrophages, lymphocytes, and endothelial cells (Figure 1). Extracapillary proliferation was also observed. Karyorrhexis was also observed in some of the cells (Figure 2). Glomerular capillary necrosis was seen in one of the cells. Adhesion was observed in two of glomeruli. Periodic acid-silver methenamine (PAM) staining showed rupture of the glomerular capillary wall with fibrin deposition. There was no mesangial cell proliferation, mesangial matrix

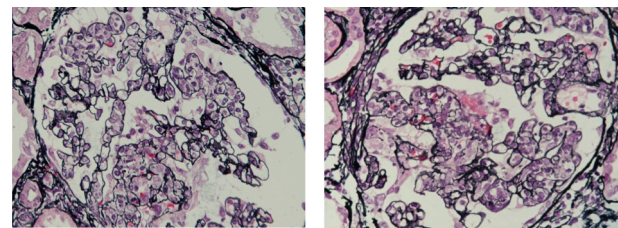


Figure 1. Histological findings of renal tissue; PAM and H&E staining $\times 400$

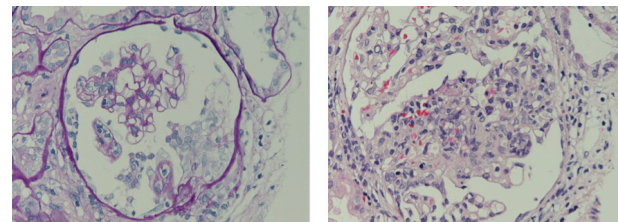


Figure 2. Histological findings of renal tissue; PAS staining $\times 400$ (Left), H&E staining $\times 400$ (Right)

Table 1. The test results on admission

Blood chemical			Immunology		
Total Protein	4.5	g/dL	IgA	347	mg/dL
Albumin	3.4	g/dL	IgM	185	mg/dL
AST	12	IU/L	IgG	645	mg/dL
ALT	10	IU/L	ANA	(-)	
LDH	234	IU/L	C3	86	mg/dL
BUN	30.7	mg/dL	C4	24	mg/dL
Cre	1.8	mg/dL	CH50	21	U/mL
Uric acid	7.4	mg/dL	ASO	<50	mg/dL
Sodium	140	mEq/L	RF factor	<25	mEq/L
Potassium	4.5	mEq/L	PR3-ANCA	<10	IU/mL
Calcium	7.7	mg/dL	MPO-ANCA	<10	IU/mL
Phosphorus	4.6	mg/dL	Anti GBM	<10	IU/mL
White blood cell	3790	/ μ L	Urine protein	3.94	g/g \cdot Cr
Hb	9.8	g/dL	Occult blood	(3+)	
Blood platelet	116000	/ μ L	Urine protein	(3+)	

AST: Aspartate aminotransferase, ALT: Alanine aminotransferase, LDH: Lactate dehydrogenase, γ -GTP: gamma-glutamyltransferase, BUN: blood urea nitrogen, Cr: creatinine, Hb: hemoglobin, IgA: Immunoglobulin A, IgM: Immunoglobulin M, IgG: Immunoglobulin G, ANA: Antinuclear antibody, C3: Complement component 3, C4: Complement component 4, CH50: Total complement activity, ASO: anti-streptolysin O antibody, RF: Rheumatoid Factor, PR3-ANCA: proteinase-3 anti-neutrophil cytoplasmic antibody, MPO-ANCA: myeloperoxidase-anti-neutrophil cytoplasmic antibody, GBM: glomerular basement membrane.

increase, or crescent formation. There was also no diabetic glomerulosclerosis. Tubular atrophy and interstitial fibrosis were seen in approximately 20% of glomeruli. There was tubular dilatation. Foamy degeneration was partially presented in the tubular epithelium. Moderate fibroelastosis was presented in the interlobular arteries. Hyaline sclerosis of arterioles was not seen. Immunostaining of the glomerular capillary was slightly positive for C1q, C3, and IgM, but there were no significant findings. Immunostaining for CD68 and CD3 was positive (Figure 3), and the presence of macrophages and T-cells was suggested. Electron microscopy showed enlargement and exfoliation of the endothelial cells and fusion of the foot processes and villous transformation. Slight increase of mesangial matrix with a fibrillar structure measuring 15 nm in diameter, mild thickening of the glomerular basement membrane, and subendothelial edema were observed, and these findings corresponded to the changes in diabetes mellitus. There were no electron-dense deposits (Figures 4 and 5).

We assumed that the patient had glomerulonephritis of suspected immunological etiology, because there

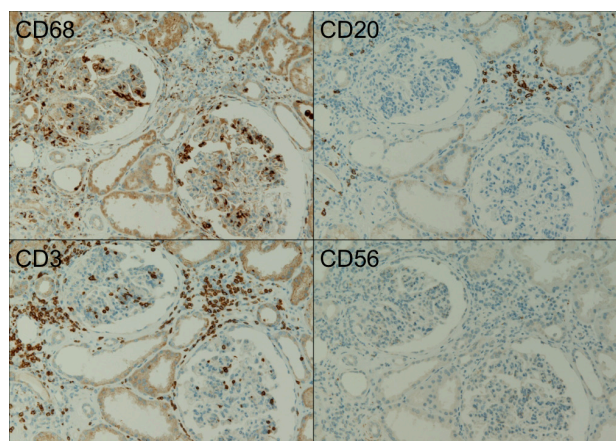


Figure 3. Immunohistochemical staining was positive for CD 3 and CD 68, and negative for CD 20 and CD 56.

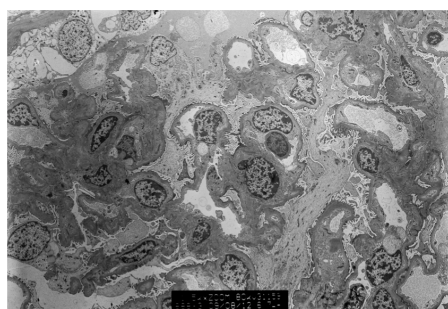


Figure 4. Electron microscopic findings.

was significant change in glomeruli and progressive deterioration of renal function. Steroid therapy, including pulse therapy, was performed, but the patient did not respond well. Then, cyclosporine was added to steroid therapy (Figure 6). After these treatments, urinary protein decreased from 4 to 2 g/day, however serum creatinine gradually increased, indicating gradual deterioration of renal function. Although treatment was continued, his renal function deteriorated further, and the patient initiated dialysis two years later. Steroid therapy was discontinued when dialysis was introduced.

3. Discussion

The patient presented with nephrotic syndrome refractory to steroid therapy, and developed chronic renal failure earlier than usual. The patient had specific histological findings characterized by marked segmental endocapillary proliferation.

Post-streptococcal acute glomerulonephritis (PSAGN) is also a disease showing marked capillary proliferation, but our patient had no antecedent infection and there was no evidence of hemolytic streptococcal infection. Histological examination showed cellular infiltration consisting mainly of monocytes, not of neutrophils, and

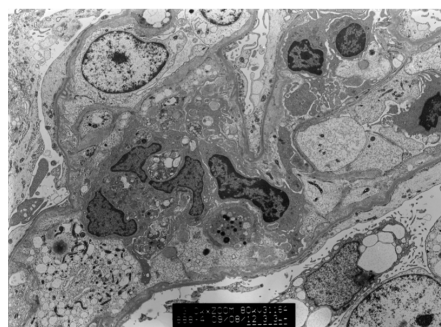


Figure 5. Electron microscopic findings.

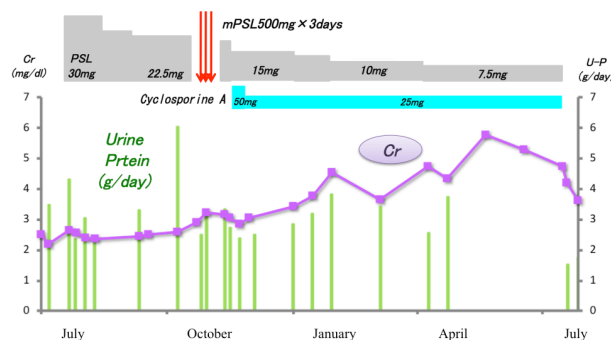


Figure 6. Clinical course. PSL: Prednisolone, mPSL: methyl-Prednisolone, Cr: creatinine,

electron microscope did not show “hump-like” deposits. These findings were inconsistent with the features of PSAGN. In addition, the clinical course of the present case was clearly different from that of acute nephritic syndrome (4).

Subsequently, pauci-immune crescentic glomerulonephritis (CGN) was also considered in the differential diagnosis. Our patient had extracapillary proliferation and glomerular capillary necrosis, which were consistent with features of CGN. However, there was no crescent formation, and the endocapillary proliferation was too significant for CGN. Clinically, his hematuria was relatively mild, and proteinuria was an earlier symptom. These findings were inconsistent with the clinical features of CGN. Furthermore, unlike patients with CGN, our patient did not respond well to steroid therapy (5).

Finally, the cellular variant of focal segmental glomerulosclerosis (FSGS) was also considered in the differential diagnosis. Segmental endocapillary proliferation and infiltration of monocytes and M ϕ can be observed in patients with FSGS. Clinically, nephrotic syndrome refractory to steroid therapy in our patient was consistent with clinical features of FSGS. However, our patient did not show segmental sclerosis, which is a clinical hallmark of FSGS. In addition, our patient had marked fibrinoid necrosis, extracapillary proliferation, and glomerular capillary necrosis, which were inconsistent with the clinical features of FSGS. According to the Columbia classification, the cellular variant of FSGS is not associated with fibrinoid necrosis of glomerular capillary (6).

Our patient was refractory to steroid therapy, and the clinical course was similar to that of MPGN. However, the histological findings of our case were incompatible with MPGN. We considered that the histopathological findings in our patient were interesting. We report this case considering that it was nephritis of unknown origin showing endocapillary proliferation that had not been recognized previously.

4. Conclusions

We report this case considering that it was nephritis of unknown origin showing segmental endocapillary proliferation that had not been recognized previously.

Authors' contribution

SH prepared the initial draft. TK and TS edited the final draft. RK, MS, RY, TM and KK were the patient's treating physician and supervised the manuscript preparation, collected information on the patient, and supported the writing of the manuscript. YF contributed histopathological interpretation.

Conflicts of interest

There were no points of conflicts.

Ethical considerations

Ethical issues (including plagiarism, data fabrication, double publication) have been completely observed by the authors. Written informed consent was obtained from the patient for publication of this case report and any accompanying images.

Funding/Support

None.

References

1. Cook HT, Pickering MC. Histopathology of MPGN and C3 glomerulopathies. *Nat Rev Nephrol.* 2015;11(1):14-22. doi: 10.1038/nrneph.2014.217.
2. Ando F, Sohara E, Ito E, Okado T, Rai T, Uchida S et al Acute poststreptococcal glomerulonephritis with acute interstitial nephritis related to streptococcal pyrogenic exotoxin B. *Clin Kidney J.* 2013;6(3):347-8. doi: 10.1093/ckj/sft045.
3. Kokuzawa A, Morishita Y, Yoshizawa H, Iwazu K, Komada T, Akimoto T et al Acute post-streptococcal glomerulonephritis with acute kidney injury in nephrotic syndrome with the glomerular deposition of nephritis-associated plasmin receptor antigen. *Intern Med.* 2013; 52(18):2087-91.
4. VanDeVoorde RG Acute poststreptococcal glomerulonephritis: the most common acute glomerulonephritis. *Pediatr Rev.* 2015;36(1):3-12. doi: 10.1542/pir.36-1-3.
5. Syed R, Rehman A, Valecha G, El-Sayegh S. Pauci-Immune Crescentic Glomerulonephritis. *Biomed Res Int.* 2015;2015:402826. doi: 10.1155/2015/402826.
6. Fogo AB, Lusco MA, Najafian B, Alpers CE. AJKD Atlas of Renal Pathology: Cellular Variant of Focal Segmental Glomerulosclerosis. *Am J Kidney Dis.* 2015;66(2):e7. doi: 10.1053/j.ajkd.2015.06.002.

Copyright © 2018 The Author(s); Published by Society of Diabetic Nephropathy Prevention. This is an open-access article distributed under the terms of the Creative Commons Attribution License (<http://creativecommons.org/licenses/by/4.0>), which permits unrestricted use, distribution, and reproduction in any medium, provided the original work is properly cited.