

Journal of Nephrologist

CrossMark
click for updates

Too late relapse of testicular cancer after 27 years; a case report

Hourieh Ansari¹, Ali Hajigholami^{2*}¹Family and Community Medicine Department, Faculty of Medicine, Isfahan University of Medical Sciences, Isfahan, Iran²Department of Internal Medicine, Faculty of Medicine, Isfahan University of Medical Sciences, Isfahan, Iran

ARTICLE INFO

Article type:
Case Report

Article history:
Received: 12 August 2017
Accepted: 2 November 2017
Published online: 19 November 2017
DOI: 10.15171/jnp.2018.07

Keywords:
Testicular cancer
Germ cell tumors
Testicular cancer

ABSTRACT

Background: Germ cell tumors (GCTs) are the most common solid tumors in young men, with a peak incidence at 25-35 years. Approximately 50% of the testicular GCTs are pure seminomas and 50% are non-seminomas. Late relapse of testicular cancer (LRTC) is a rare disease with the incidence rate of 2.6% and is defined as >2 years interval between initial treatment and recurrence.

Case Presentation: We report here a patient with nonseminomatous GCT who experienced relapse 27 years after his first diagnosis. He came with gross hematuria and huge abdominal mass. There was a giant retroperitoneal mass with invasion to the left kidney and other organs in computerized tomography. A biopsy was conducted and pathology revealed recurrence of malignant mixed nonseminoma GCT. The tumor was unresectable. Therefore patient was treated with four cycles of chemotherapy. PET scan was conducted after chemotherapy showed residue of tumor thus retroperitoneal lymph node dissection (RPLND) was done.

Conclusions: We concluded that with increasing lifespan of cancer patients, follow up of these patients for very late relapse must be conducted lifelong.

Implication for health policy/practice/research/medical education:

With increasing lifespan of cancer patients, follow up of these patients for very late relapse must be conducted lifelong.

Please cite this paper as: Ansari H, Hajigholami A. Too late relapse of testicular cancer after 27 years; a case report. J Nephrologist. 2018;7(1):19-21. DOI: 10.15171/jnp.2018.07.

1. Introduction

Around 1% of male cancers include testicular germ cell tumors (GCTs). They are the most common solid tumors in young men, with a peak incidence at 25-35 years (1). The cure rate following primary therapy with cisplatin-based chemotherapy or orchiectomy ± radiotherapy, in early or advanced stages of testicular cancers are ~95% and ~70%, respectively (1).

Testicular GCTs are highly curable malignancies while only 10%-30% of patients have recurrences within 2 years of primary treatment. Most of these relapses are recovered with chemotherapy ± surgery (1,2). Late relapse is defined as tumor recurrence more than 2 years after complete remission of initial treatment including chemotherapy. Many aspects of their main characteristics remain obscure, because of the rarity and heterogeneity

of late relapses (3,4). Late relapse in patients with a malignant germ cell tumor (MGCT) is 1% to 6% while, this rate for late relapse of testicular cancer (LRTC) is 2.6%. Accordingly late relapse in seminoma and nonseminoma patients are 1.4% and 3.2%, respectively (5,6).

Most of the site of tumor recurrence in both seminoma and non-seminoma tumors is the retroperitoneal space. Around 25%–30% of tumor recurrence is in the chest. Lungs in non-seminoma and mediastinal lymph nodes in seminoma will involve.

The risk of relapse in retroperitoneal space is reduced by retroperitoneal lymph node dissection (RPLND) and abdominal radiotherapy (6).

The overall cure rate is only about 50% with chemotherapy or complete surgical resection. Therefore, sufficient

*Corresponding author: Ali Hajigholami,
Email: alihajigholami@med.mui.ac.ir

management of the primary tumor is important to prevent the progression of late relapse (5). Management of LRTC is dependent on histologic subtypes. It seems that the choice of treatment in seminoma patients is cisplatin-based chemotherapies and surgical approach is considered in most earlier chemotherapy-treated nonseminoma patients (3).

This study reports a patient with nonseminomatous GCT who experienced relapse 27 years after his first diagnosis and achieved a second complete response with chemotherapy and surgery.

2. Case Presentation

A-22-year old male was presented with a solid mass in his left testis in February 1989. He underwent orchiectomy. The pathology revealed non-seminoma GCT. He had received four courses of chemotherapy. After 27 years in December 2016 he returned with a symptom of gross hematuria and huge abdominal mass.

He denied using drugs or anabolic steroids and was not alcohol drinker. Patient was not smoker. He also reported a normal sexual life, and he had three children. CT-scan shows, a huge retroperitoneal mass with invasion to the left kidney and other organs which measured 15 cm × 13 cm (Figure 1). No other abnormalities or lesions were seen.

His tumor markers including (AFP, HCG and LDH) was 4 ng/mL, 1 mIU/mL, 700 U/L respectively. The patient underwent a sonography guided biopsy while it was accompanied by a very severe and life-threatening hemorrhage. Then laparotomy for hemorrhage control was conducted. Additionally a wedge biopsy was taken (Figure 2).

In laparotomy the tumor was unresectable because of very extensive tumor invasion with adhesion to other organs. Pathology showed recurrence of malignant mixed nonseminoma GCT with features of mature teratoma (Figure 2). Because of absence of primary malignant lesion and presence of a history of testicular cancer, the patient was treated with four cycles of TIP (paclitaxel, ifosfamide and cisplatin). After this protocol, a positron emission tomography (PET) scan was conducted. In PET-scan residue of the tumor with size of 7 cm × 4 cm in medial of the left kidney was detected. RPLND was conducted in August 2017 (Figure 3).

3. Discussion

This is a very challenging and rare presentation of testicular GCT. Late recurrence usually defined as later than 2 years. In our case relapse was occurred 27 years after the first presentation. Following improvement in the treatment of cancers and increasing life span of these patients, however, several reports of very late relapse

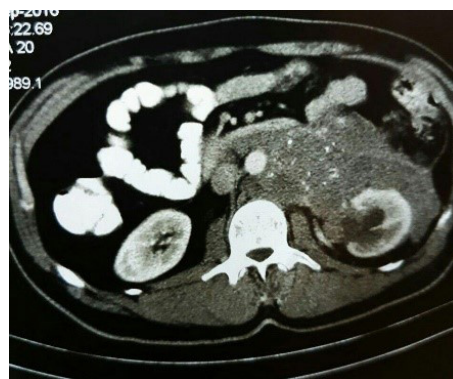

Figure 1. Huge retroperitoneal mass with invasion to the left kidney.

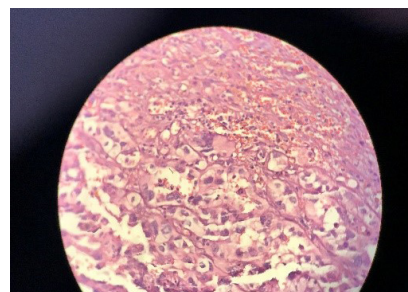


Figure 2. Nonseminoma germ cell tumor.

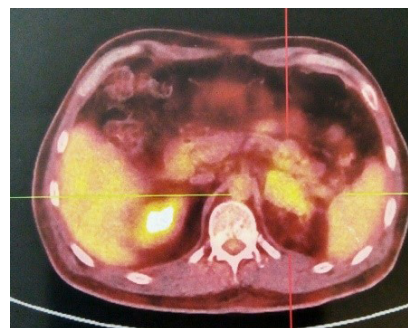

Figure 3. Residue of tumor in medial of left kidney.

of cancer patients such as renal cell carcinoma, breast cancer and pancreatic cancer have been reported (7-9). This suggests a necessity to a lifelong follow-up in these patients (7-9). The optimal duration of follow-up for GCT is not clear. Some advocates a lifelong follow-up only in patients who initially presented with metastatic disease, since this subgroup had a higher incidence of late relapse (10). In this patient a viable residue was remained after chemotherapy because of the teratoma part of tumor that was refractory to chemotherapy. In this case if recurrence was diagnosed earlier, treatment of the disease was much easier. This tumor has a hypervascular structure too. Hence, another point is a risk of bleeding with biopsy. In this patient with core needle biopsy a life

threatening bleeding occurred. This indicates that biopsy must be conducted with caution for bleeding through an open surgery.

4. Conclusions

We concluded that with increasing the lifespan of cancer patients, follow up of these patients for very late relapse must be conducted lifelong.

Authors' contribution

HA prepared the initial draft. AH edited the final draft. All authors read and signed the final paper.

Conflicts of interest

There were no points of conflicts.

Ethical considerations

Ethical issues (including plagiarism, data fabrication, double publication) have been completely observed by the authors. The patient has given his informed consent regarding this case report.

Funding/Support

None.

References

1. Detti B, Livi L, Scoccianti S, Meattini I, Gacci M, Lapini A, et al. Late relapse in testicular germ cell tumors. *Tumori*. 2006;93(5):428-31.
2. Aksoy S, Harputuglu H, Kilickap S, Akdogan B, Abali H, Erman M. Relapse of testicular cancer after 15 years. *Turkish J Cancer*. 2008;38(4):190-93.
3. Akar E, Tural D, Arslan D, Bassorgun CI, Yildiz O. Late relapse of testicular cancer: Recurrence after 24 years and treatment with chemotherapy alone. *J Cancer Res Ther*. 2015;11(3):661. doi: 10.4103/0973-1482.137915.
4. Oldenburg J, Alfsen G, Waehre H, Fosså S. Late recurrences of germ cell malignancies: a population-based experience over three decades. *Br J Haematol*. 2006;94(6):820-27.
5. Lipphardt ME, Albers P. Late relapse of testicular cancer. *World J Urol*. 2004;22(1):47-54.
6. Oldenburg J, Wahlqvist R, Fosså SD. Late relapse of germ cell tumors. *World J Urol*. 2009;27(4):493.
7. Messina C, Di Meglio A, Nuzzo PV, Boccardo F, Ricci F. Very late recurrence of renal cell carcinoma experiencing long-term response to sunitinib: a case report. *Tumori*. 2015;101(3):e79-81.
8. Xiao L, Hu X, Wang S, Yong-Sheng G, Yu Q, Gao S, et al. A case report of local recurrence developing 24 years after mastectomy for breast cancer recurrence from breast cancer after 24 years. *Medicine (Baltimore)*. 2016;95(22):e3807. doi: 10.1097/MD.0000000000003807.
9. Frei L, Stieger R, Bayerl C, Breitenstein S, Staerke RF. Resectable adenocarcinoma developing in the remnant pancreas 7 years after partial pancreatoduodenectomy for invasive ductal adenocarcinoma of the pancreas: a case report. *J Med Case Rep*. 2017;11(1):194-98. doi: 10.1186/s13256-017-1359-3.
10. Howard G, Conkey D, Peoples S, McLaren D, Hargreave T, Tulloch D, et al. The management and outcome of patients with germ-cell tumours treated in the Edinburgh Cancer Centre between 1988 and 2002. *Clin Oncol*. 2005;17(6):435-40.

Copyright © 2018 The Author(s); Published by Society of Diabetic Nephropathy Prevention. This is an open-access article distributed under the terms of the Creative Commons Attribution License (<http://creativecommons.org/licenses/by/4.0>), which permits unrestricted use, distribution, and reproduction in any medium, provided the original work is properly cited.