

A glyco-engineered anti-HER2 monoclonal antibody (TrasGEX) induces a long-lasting remission in a patient with HER2 overexpressing metastatic colorectal cancer after failure of all available treatment options

Colorectal cancer (CRC) is one of the most common forms of malignancies and the second leading cause of cancer-related death in Western countries.¹ Although

chemotherapy in combination with novel antiangiogenic or antiepidermal growth factor receptor (EGFR)-directed agents has significantly improved the survival time of patients with metastatic CRC (mCRC), patients with metastatic disease still face a very poor 5-year survival rate less than 10%.²⁻³ The human EGFR 2 (HER2) has proven as an effective drug target in breast and gastric cancers. In CRC, data about the therapeutic utility of anti-HER2 agents are sparse, and had been only reported for treatment-naïve or second-line-treated patients.⁴ There is only one clinical phase II study reporting the use of the first-generation HER2/neu-directed trastuzumab in combination with irinotecan in first-line or second-line setting. Although some activity of this drug combination has been observed, the study was terminated early due to insufficient patient recruitment.⁵ In this patient case, we report about the successful use of a novel glyco-engineered anti-HER2 monoclonal antibody (TrasGEX) with 10-fold to

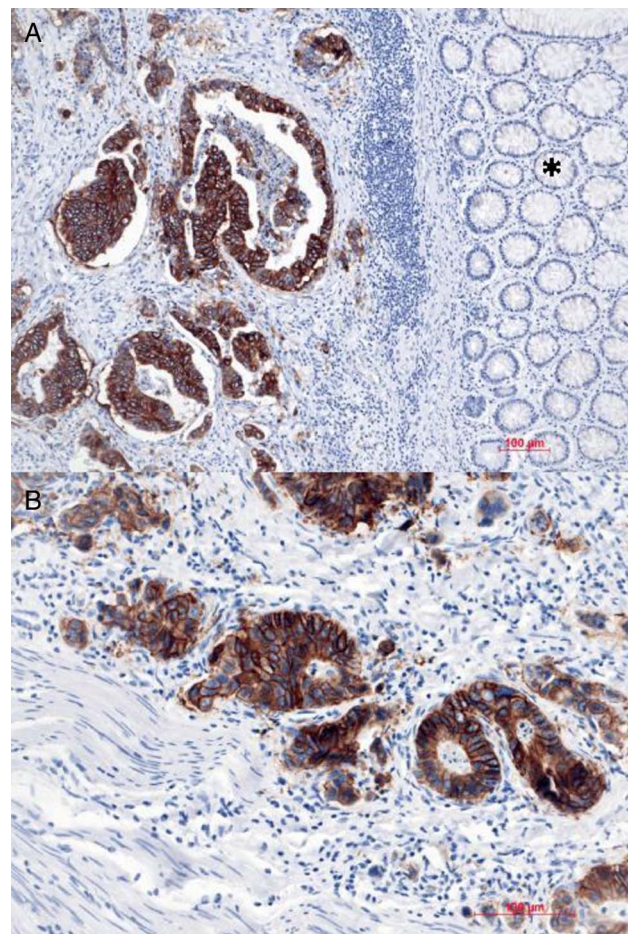


Figure 1 Representative picture of HER2/neu immunohistochemistry of colorectal cancer tissue. (A) A strong brown (+3) reaction in the tumour tissue indicates HER2/neu overexpression. In contrast, the surrounding normal colon mucosa (*) stains negatively (×100). (B) Higher magnification (×200) showing the homogenous, membranous staining pattern of the tumour cell.

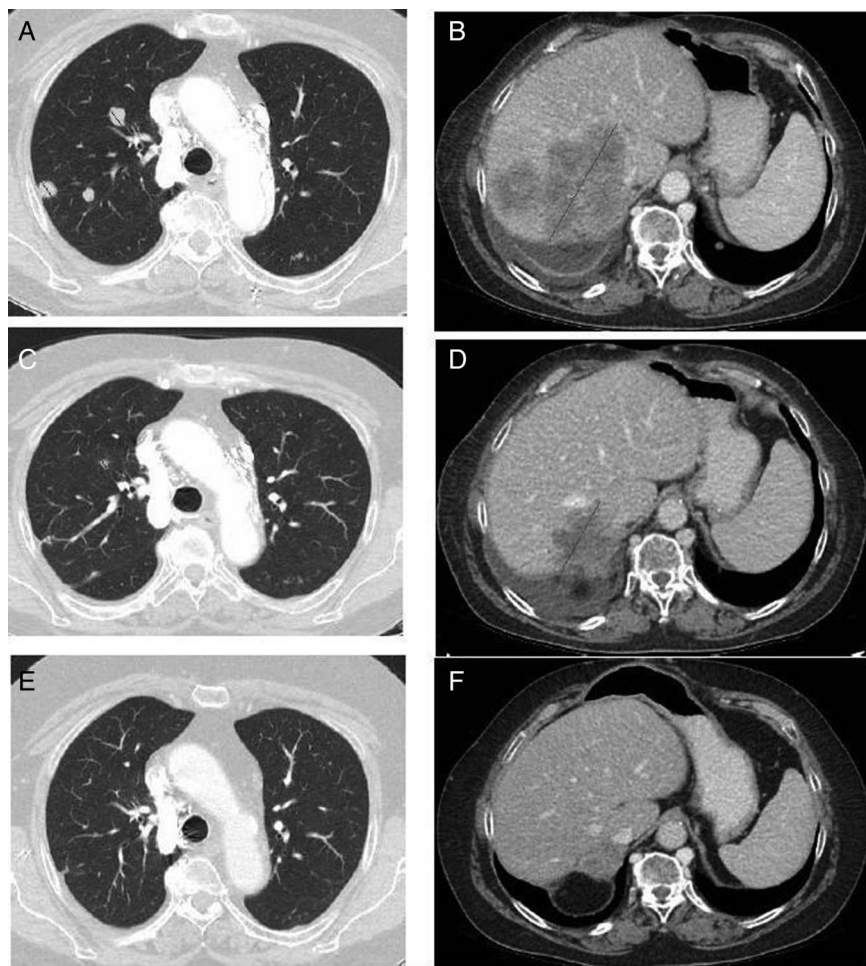


Figure 2 (A and B) Baseline imaging before therapy with TrasGEX has been initiated. (A) Multiple lung metastatic lesions with one target lesion of 2 cm in diameter (red lines) and (B) a liver metastasis with 11 cm in the largest diameter. (C and D) Three cycles later, the patient has a decrease of size in lung (C) and liver metastases (D). (E and F) Imaging 21 months (30 cycles) after initiation of TrasGEX. The target lung lesion diminished (E) and the target liver lesion measures 4.5 cm (F).

140-fold enhanced antibody dependent cellular cytotoxicity (ADCC) activity in a female patient with HER2/neu overexpressing mCRC and Fc γ RIII status F/V after failure of all other available treatment options.

A 61-year-old female Caucasian patient was newly diagnosed with CRC in December 2002, and consequently underwent a left hemicolectomy at the Department of Surgery, Medical University of Graz. A stage II pathological T4N0 CRC was found according to the 2002 tumour, node, metastases classification system. One month later, a single liver metastasis was diagnosed by CT, and pre-operative chemotherapy comprising eight cycles of FOLFOX4 was initiated. Five months later, a partial remission of the liver metastasis was achieved, and a resection of the liver metastasis (segment VI) was performed in July 2003. After a 30-month disease-free period and routine clinical

follow-up, a CT scan of the abdomen detected enlarged retroperitoneal lymph nodes. Based on an individual patient decision and treatment approach, the patient underwent lymph node resection and post-operative chemotherapy with seven cycles of FOLFOX4 regimen. Oxaliplatin had to be dose-reduced after two cycles due to a prolonged grade III leucopenia. Another 9 months later, the disease recurred with a solitary liver metastasis in segment VI and one single metastasis in the right suprarenal gland. The patient again underwent liver resection and subtotal right adrenalectomy in April 2007. Three months after surgery, solitary retroperitoneal lymph node metastases were detected and consecutively resected. After a 4-month disease-free period, a recurrence of metastasis in the liver was radiologically detected. Palliative chemotherapy with FOLFIRI/bevacizumab was administered for eight cycles, resulting in partial remission of the liver metastasis.

Unfortunately, half an year after a break of the therapy, the patient experienced a disease progression with spread to multiple metastases in both lungs and solitary liver metastasis. Rechallenge of FOLFIRI/bevacizumab (80% dose reduction of irinotecan due to prolonged haematotoxicity) resulted again in partial remission after 12 cycles. In February 2011, the disease progressed again, and after determining KRAS exon 2 mutational status (a KRAS wild-type was diagnosed by pyrosequencing) in the tumour tissue, a palliative therapy containing irinotecan (150 mg/m²) plus panitumumab (6 mg/kg) was administered every 2 weeks for five cycles. Despite the use of this combination therapy and the administration of another two palliative therapy approaches with FOLFOX/bevacizumab (4 cycles) as well as UFT (tegafur 2-1-1 day 1-28, leucovorin 2-2-2 day 1-28 for 4 months), no objective response or clinical benefit could be reached. A further molecular characterisation of the tumour tissue detected no mutations in KRAS/NRAS exons 3 and 4, as well as no BRAF V600E mutation. Facing the disease progression and the use of all currently available drugs, the patient consented to participate in the phase I TrasGEX clinical trial (ClinicalTrials.gov number NCT01409343). After consenting, a HER2/neu immunohistochemical expression in the tumour tissue was evaluated in March 2012 (Dako HercepTest). Around 95% of tumour cells showed a strong complete membranous staining pattern (3+), leading to the enrolment of the patient into the TrasGEX dose escalation protocol (figure 1A, B).

TrasGEX is a humanised IgG1 anti-HER2 antibody, and belongs to a group of antibodies, which are glyco-engineered by the GlycoExpress platform with a fully human glycosylation and optimised key sugar determinants, including fucose, galactose, sialylation and branching. Major optimisation for TrasGEX is an enhanced ADCC antitumour activity in combination with other variable domain-mediated antitumour activities. ADCC is mediated via the Fc γ RIIIa receptor on immune effector cells. Two allotypes of this receptor differing in amino acid position 158 (V158F) are known, which have different affinities to human IgG1, depending on the glycosylation of the glycans in the IgG1 Fc tail. This difference in receptor affinity results in a reduced natural killer cell activation for F-containing allotypes for antibodies generated in Chinese hamster ovary (CHO) or other rodent production systems and, therefore, in a reduced ADCC activity.

Patients with FcγRIIIa allotype (V/V) treated with trastuzumab (Herceptin) or cetuximab (Erbix) have a better clinical outcome than those with F/F or F/V.^{6–8}

According to the study protocol, the patient received 480 mg of TrasGEX intravenously over 4 h and every consecutive cycle on day 21 with an infusion time of 90 min. Three cycles later, the patient had a decrease of size in lung and liver metastases (sum of the longest diameters, target lesions in the liver and right lower lung lobe reduced from 19.7 to 11.1 cm (figure 2A, C), target lesion in the right liver lobe from 10 to 5.7 cm) (figure 2B, D), so, continuation of the targeted therapy according to the study protocol was performed. Until now, 21 months (30 cycles) after initiation of TrasGEX, the patient still has a partial remission of the disease (target liver lesion 4.5 cm), and presents in excellent clinical condition (figure 2E, F). Remarkably, over the whole study period, no side effects including cardiotoxicity (the left ventricular ejection fraction determined by echocardiography remained unchanged throughout the 21 months) occurred.

Florian Eisner,¹ Martin Pichler,¹ Steffen Goletz,² Herbert Stoeger,¹ Hellmut Samonigg¹

¹Division of Oncology, Department of Internal Medicine, Medical University of Graz, Graz, Austria
²GLYCOTOPE GmbH, Berlin, Germany

Correspondence to Dr Florian Eisner, Department of Internal Medicine, Medical University of Graz, Auenbruggerplatz 15, A-8036 Graz, Austria; florian.eisner@medunigraz.at

Acknowledgements Special thanks to all the contributors of the TrasGEX phase I clinical trial.

Competing interests None declared.

Patient consent Obtained.

Provenance and peer review Not commissioned; externally peer reviewed.



OPEN ACCESS



Open Access This is an Open Access article distributed in accordance with the Creative Commons Attribution Non Commercial (CC BY-NC 4.0) license,

which permits others to distribute, remix, adapt, build upon this work non-commercially, and license their derivative works on different terms, provided the original work is properly cited and the use is non-commercial. See: <http://creativecommons.org/licenses/by-nc/4.0/>



CrossMark

To cite Eisner F, Pichler M, Goletz S, et al. *J Clin Pathol* 2015;**68**:1044–1046.

Received 1 April 2015

Revised 22 July 2015

Accepted 31 July 2015

Published Online First 18 September 2015

J Clin Pathol 2015;**68**:1044–1046.

doi:10.1136/jclinpath-2015-202996

REFERENCES

- 1 Siegel R, Naishadham D, Jemal A. Cancer statistics. *CA Cancer J Clin* 2013;**63**:11–30.
- 2 Venook AP. Epidermal growth factor receptor-targeted treatment for advanced colorectal carcinoma. *Cancer* 2005;**103**:2435–46.
- 3 Damin DC, Lazzaron AR. Evolving treatment strategies for colorectal cancer: a critical review of current therapeutic options. *World J Gastroenterol* 2014;**20**:877–87.
- 4 Moorcraft SY, Smyth EC, Cunningham D. The role of personalized medicine in metastatic colorectal cancer: an evolving landscape. *Therap Adv Gastroenterol* 2013;**6**:381–95.
- 5 Ramanathan RK, Hwang JJ, Zamboni WC, et al. Low overexpression of HER-2/neu in advanced colorectal cancer limits the usefulness of trastuzumab (Herceptin) and irinotecan as therapy. A phase II trial. *Cancer Invest* 2004;**22**:858–65.
- 6 Bibeau F, Lopez-Crapez E, Di Fiore F, et al. Impact of FcγRIIIa-FcγRIIIa polymorphisms and KRAS mutations on the clinical outcome of patients with metastatic colorectal cancer treated with cetuximab plus irinotecan. *J Clin Oncol* 2009;**27**:1122–9.
- 7 Lejeune J, Thibault G, Ternant D, et al. Evidence for linkage disequilibrium between FcγRIIIa-V158F and FcγRIIIa-H131R polymorphisms in white patients, and for an FcγRIIIa-restricted influence on the response to therapeutic antibodies. *J Clin Oncol* 2008;**26**:5489–91.
- 8 Musolino A, Naldi N, Bortesi B, et al. Immunoglobulin G fragment C receptor polymorphisms and clinical efficacy of trastuzumab-based therapy in patients with HER-2/neu-positive metastatic breast cancer. *J Clin Oncol* 2008;**26**:1789–96.