



Title	Four cases of pseudomyxoma peritonei with ovarian tumors at our hospital
Author(s)	Yazawa, Riho; Yazawa, Hiroyuki; Fukuda, Kaoru; Ohara, Miki; Osuka, Fumihiko
Citation	Fukushima Journal of Medical Science. 69(1): 57-65
Issue Date	2023
URL	<a href="http://ir.fmu.ac.jp/dspace/handle/123456789/1960">http://ir.fmu.ac.jp/dspace/handle/123456789/1960</a>
Rights	© 2023 The Fukushima Society of Medical Science. This article is licensed under a Creative Commons [Attribution-NonCommercial-ShareAlike 4.0 International] license.
DOI	10.5387/fms.2022-41
Text Version	publisher

This document is downloaded at: 2023-05-15T03:21:35Z



## Four cases of pseudomyxoma peritonei with ovarian tumors at our hospital

Riho Yazawa<sup>1)</sup>, Hiroyuki Yazawa<sup>1)</sup>, Kaoru Fukuda<sup>1)</sup>, Miki Ohara<sup>1)</sup> and Fumihiko Osuka<sup>2)</sup>

<sup>1)</sup>Department of Obstetrics and Gynecology, Fukushima Red Cross Hospital, <sup>2)</sup>Department of Surgery, Fukushima Red Cross Hospital.

(Received November 24, 2022, accepted February 14, 2023)

### Abstract

We describe four cases of pseudomyxoma peritonei (PMP) that were diagnosed and treated at our hospital.

Case 1 : A 26-year-old woman with a large multicystic ovarian tumor and massive ascites was diagnosed with PMP originating from a borderline mucinous ovarian tumor. She underwent fertility-preserving staging laparotomy and was treated with three courses of intraperitoneal chemotherapy. There has been no recurrence in the 15 years since her first operation. Case 2 : A 72-year-old woman with a giant ovarian tumor and massive ascites was diagnosed with PMP originating from low-grade appendiceal mucinous neoplasm (LAMN). After laparotomy, the patient was managed conservatively because she did not want aggressive treatment. She has remained asymptomatic with a small amount of ascites for 3 years. Case 3 : A 82-year-old woman with ovarian tumors, massive ascites, and suspected PMP underwent emergency laparotomy due to appendiceal perforation and pan-peritonitis. She was diagnosed with PMP originating from LAMN. She has remained asymptomatic with a small amount of ascites for 2 years. Case 4 : A 42-year-old woman with multicystic ovarian tumors and massive ascites underwent laparotomy. She was diagnosed with PMP originating from LAMN. Since multidisciplinary treatment was indicated and desired, the patient was referred to a specialized facility where cytoreductive surgery and hyperthermic intraperitoneal chemotherapy was performed. The patient has done well since the treatment.

Although most cases of PMP originate from mucinous tumors of the appendix, female patients with PMP often present with ovarian tumors and are commonly referred to gynecology clinics. It is therefore important for gynecologists to be familiar with PMP and to be able to diagnose it accurately and select the most suitable management including multidisciplinary treatments.

**Key words :** pseudomyxoma peritonei, low-grade appendiceal mucinous neoplasm (LAMN), ovarian tumor, cytoreductive surgery, hyperthermic intraperitoneal chemotherapy.

### Introduction

Pseudomyxoma peritonei (PMP) is a rare disease, with an estimated incidence of approximately 1-2 cases per million<sup>1,2)</sup>, that is often associated with peritonitis carcinomatosa caused by accumulated mucus. It often has a clinically malignant course, but in recent years aggressive cytoreductive surgery (CRS) and hyperthermic intraperitoneal chemotherapy (HIPEC) have led to a dramatic improvement in

prognosis<sup>1)</sup>. In this article, we present four cases of PMP diagnosed as a result of giant ovarian tumors at our hospital, and discuss the epidemiology, classification, diagnosis, recent multidisciplinary treatment, and prognosis of PMP in the literature.

### Cases

Cases 1 and 2 were previously reported in 2020<sup>3)</sup>, and their courses are described briefly here.

Corresponding author : Hiroyuki Yazawa MD. E-mail : [ikyoku12@fukushima-med-jrc.jp](mailto:ikyoku12@fukushima-med-jrc.jp)

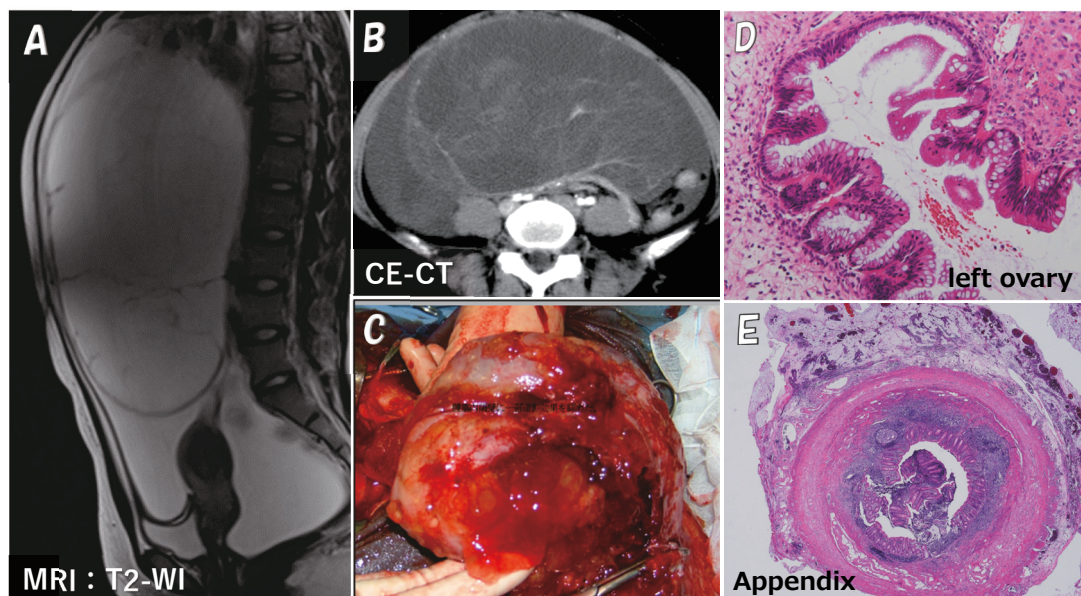
©2023 The Fukushima Society of Medical Science. This article is licensed under a Creative Commons [Attribution-NonCommercial-ShareAlike 4.0 International] license.  
<https://creativecommons.org/licenses/by-nc-sa/4.0/>

**Case 1 :** A 26-year-old woman with a giant abdominal tumor was referred to our department in 2007. She was diagnosed with a large multicystic ovarian tumor and massive ascites based on magnetic resonance imaging (MRI) (Fig. 1A) and computed tomography (CT) (Fig. 1B). Laparotomy was performed. A tumor in the left ovary had ruptured, leading to massive gelatinous mucinous ascites (Fig. 1C). Left adnectomy and appendectomy were performed. The postoperative pathological diagnosis was mucinous borderline tumor of the ovary (Fig. 1D). No tumor was detected in the appendix (Fig. 1E), leading to a diagnosis of PMP originating from a borderline ovarian tumor. The patient was treated with fertility-preserving staging laparotomy and three courses of intraperitoneal chemotherapy. There has been no recurrence in the 15 years since her first operation.

**Case 2 :** A 72-year-old woman with abdominal distension was referred to our department due to a giant abdominal tumor detected by MRI and CT in 2018 (Fig. 2A,B). Laparotomy was performed. A tumor in the left ovary had ruptured and there was gelatinous mucinous ascites throughout the abdominal cavity (Fig. 2C). Bilateral adnectomy, partial omentectomy, and appendectomy were performed (Fig. 2D). The postoperative pathological diagnosis

revealed low-grade appendiceal mucinous neoplasm (LAMN) (Fig. 2E) and mucinous cystadenoma of the ovary. The patient was diagnosed with PMP originating from LAMN based on immunohistochemical findings (Fig. 3, Table 1). Because she declined standard treatments for PMP, such as aggressive CRS and HIPEC, she was kept under observation. Four months after the first operation, the pelvic peritoneal mucinous tumor recurred. Tumor resection and active lavage with heated saline were performed laparoscopically. The patient has remained asymptomatic with a small amount of ascites for 3 years.

**Case 3 :** An 82-year-old woman with abdominal distention was referred to our department due to a giant ovarian tumor and massive ascites detected by MRI and CT in 2019 (Fig. 4A, 4B). The patient was suspected to have a malignant tumor. An ascites puncture was performed but the fluid was gelatinous, making drainage difficult. The cytological diagnosis of ascites was class III. The patient was diagnosed with PMP based on the nature of the ascites. Although informed consent was obtained regarding treatment, she did not desire treatment at that time and was kept under observation. She was again admitted to the hospital with an acute abdomen, diagnosed with perforation of the gastrointestinal



**Fig. 1.** MRI and CT results, and operative and histopathological findings in Case 1

A T2-weighted sagittal MRI image shows a multicystic ovarian tumor with a diameter of >20 cm and accumulation of massive ascites (A). Contrast-enhanced CT shows a contrast effect on the septum of a giant ovarian tumor (B). The tumor was partially ruptured, leaking and filling the abdominal cavity with jelly-like mucinous contents (C). The ovarian tumor was diagnosed as a mucinous borderline tumor with no noticeable cellular atypia, although some cysts showed protrusion of the epithelium into the lumen and cellular multilayering, and the appearance of island-like free cell masses in some cysts (D). The appendix exhibits massive mucus deposits on the serosal surface, but no neoplastic growths on the mucosal side of the lumen (E).



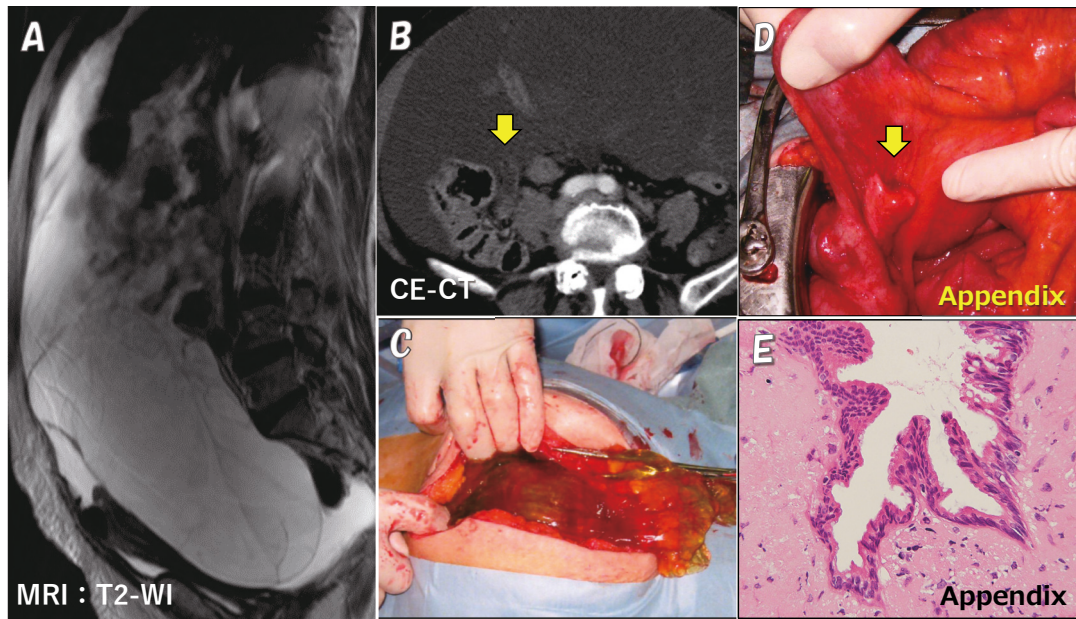


Fig. 2. MRI and CT results, and operative and histopathological findings in Case 2. A T2-weighted sagittal MRI image shows a multicystic ovarian tumor with a diameter of 19×14 cm and accumulation of massive ascites (A). Contrast-enhanced CT shows a slightly enlarged appendix (B, arrow). The tumor was partially ruptured, leaking and filling the abdominal cavity with jelly-like mucinous contents (C). The appendix is mildly enlarged (arrow), but macroscopically no findings of perforation are seen (D). Pathologically, the tumor cells consist of mucinous hypercylindrical epithelium with atypical weakly elongated oval nuclei, with a flat arrangement and sometimes papillary shape. Based on the weak cellular dysmorphism and the finding of compressible proliferation, a diagnosis of LAMN was made (E).

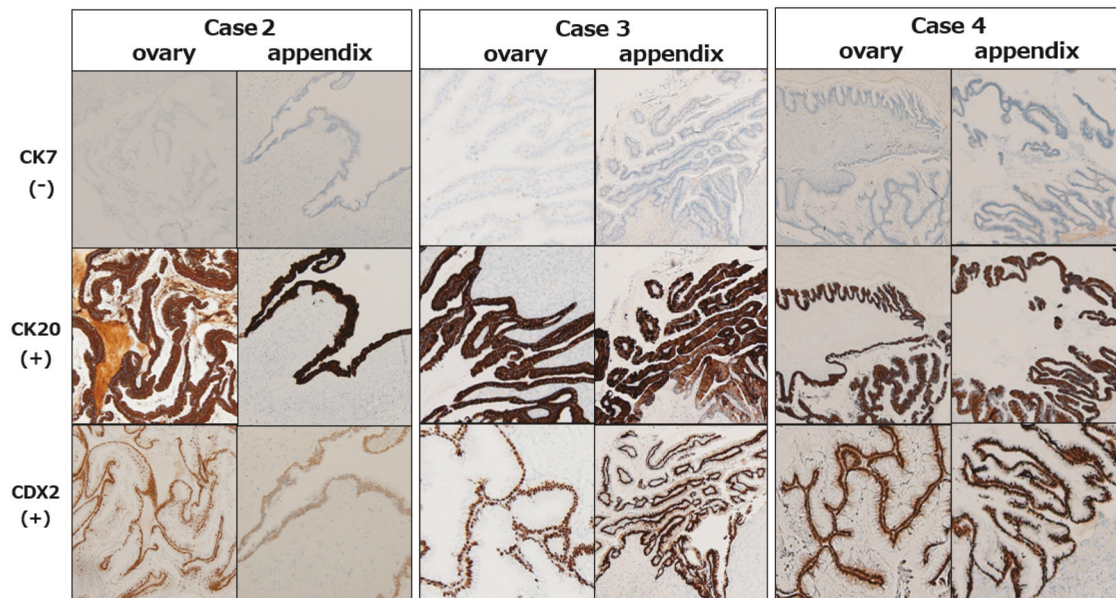


Fig. 3. Immunohistochemical staining findings in cases 2-4. In cases 2-4, immunohistochemical staining showed that both appendiceal and ovarian tumors were CK7-, CK20+, and CDX2+, findings indicative of a primary appendiceal tumor.

nal tract and generalized peritonitis (panperitonitis), and underwent emergency laparotomy (Fig. 4C). The diagnosis was perforation of the appendix (Fig. 4D, 4E), and she underwent partial cecal resec-

tion and bilateral adnexectomy. The postoperative pathological diagnosis revealed LAMN (Fig. 4F) and mucinous cystadenoma of the ovary. Immunohistochemical staining showed CK7-, CK20+, and

Table 1. Summary of the four cases.

case	age	ascites cytology	appendix swelling imaging / macroscopy	CA125	CA199	CEA	immunostain ovary / appendix CK7/CK20/CDX2	origin / pathology	PMP-classification / CC-score	postoperative therapy / current status
1	26	NA	—	55.7	171	16.6	NA	ovary	PMCA-I	IPC x 2
			—						M-BOT	CC-0
2	73	class III	+	55.5	2.2	15.2	-/+ / +	appendix	DMPA	no wish
			+				-/+ / +	LAMN	CC-2	recurrence
3	82	class III	—	141.1	10.4	40.1	-/+ / +	appendix	DMPA	no wish
			+				-/+ / +	LAMN	CC-1	palliative care
4	48	class III	—	84.4	3.7	21.8	-/+ / +	appendix	PMCA-I	<b>CRS+HIPEC</b>
			+				-/+ / +	LAMN	CC-1	observation

M-BOT : mucinous borderline ovarian tumor. LAMN : low-grade appendiceal mucinous neoplasm

IPC : intraperitoneal chemotherapy

DMPA : low-grade or diffuse peritoneal adenomucinosis.

PMCA-I : intermediate or hybrid between DMPA and high-grade or peritoneal mucinous adenocarcinoma

CC-score : completeness of cytoreduction score

CRS + HIPEC : cytoreductive surgery + hyperthermic intraperitoneal chemotherapy

NA : not available

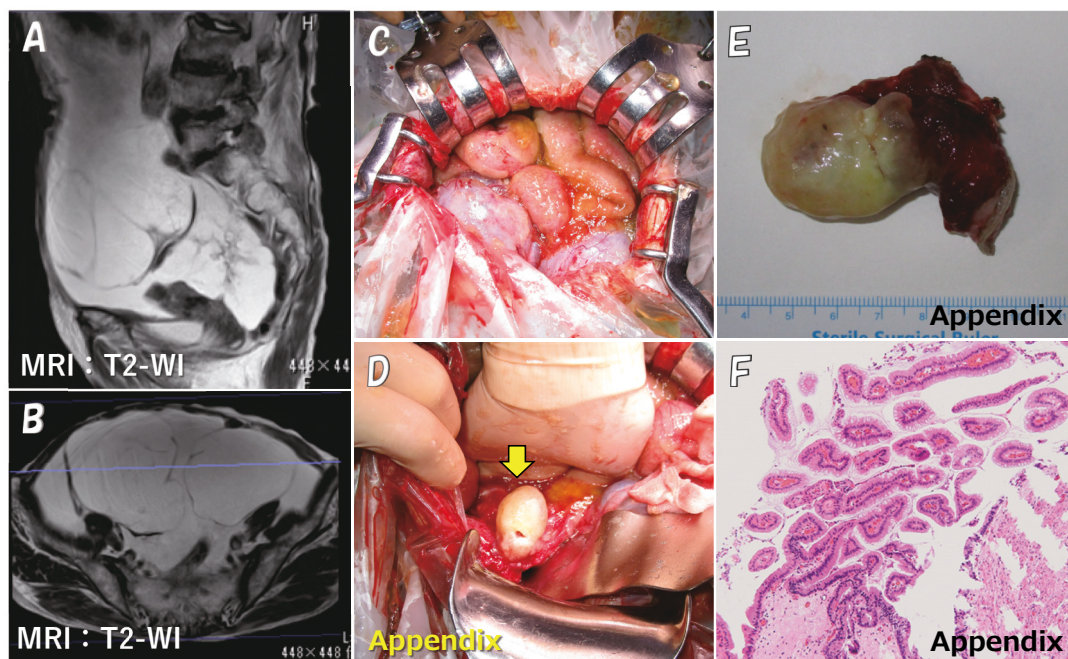


Fig. 4. MRI results, and operative and histopathological findings in Case 3.

T2-weighted sagittal and axial MRI images show bilateral multicystic ovarian tumors with diameters of 9 cm and 14 cm and accumulation of massive ascites (A, B). The tumor was partially ruptured, leaking and filling the abdominal cavity with jelly-like mucinous contents (C). The appendix is mildly enlarged and perforated (D, arrow; and E). The pathological diagnosis of the appendix was LAMN (F).

CDX2+ in both the appendix and ovaries (Fig. 3, Table 1), leading to a diagnosis of LAMN-derived PMP. Postoperatively, the patient continued to have a small amount of ascites without abdominal symptoms and was transitioned to palliative care.

Case 4: A 48-year-old woman was referred to our department in 2021 because of abdominal dis-

tention, ascites, and an ovarian tumor. MRI and CT showed a 14×9 cm multicystic ovarian tumor (Fig. 5A, 5B), with no obvious findings in the appendix. An ascites puncture was performed but the fluid was gelatinous and drainage was difficult. The cytological diagnosis was non-malignant ascites. As a result, PMP was diagnosed, and the pa-



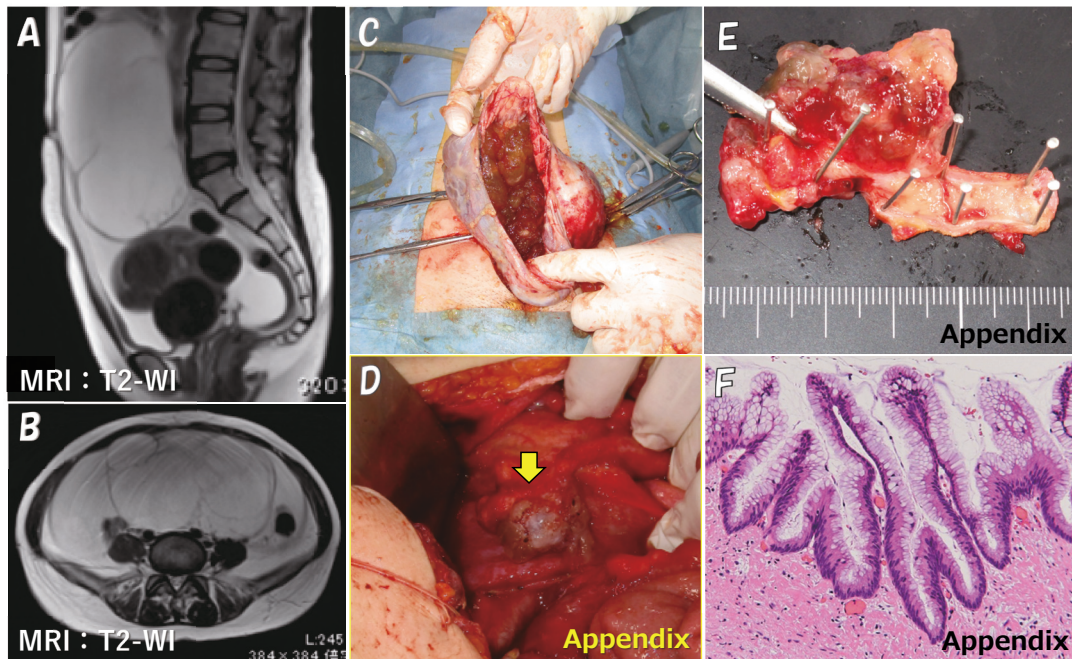


Fig. 5. MRI results, and operative and histopathological findings in Case 4.

T2-weighted sagittal and axial MRI images show a multicystic ovarian tumor with a diameter of 9×14 cm and accumulation of massive ascites (A, B). The tumor was partially ruptured, leaking and filling the abdominal cavity with jelly-like mucinous contents (C). The appendix is mildly enlarged and perforated (D, arrow; and E). The pathological diagnosis of the appendix was LAMN (F).

tient underwent an emergency laparotomy due to persistent abdominal distention. There was a 3100-ml accumulation of jelly-like ascites, and the left ovarian mucinous tumor had ruptured (Fig. 5C). The appendix was slightly swollen and ruptured (Fig. 5D). Total hysterectomy, bilateral adnexectomy, partial omentectomy, and appendectomy were performed (Fig. 5E). The postoperative pathological diagnosis revealed LAMN (Fig. 5F) and mucinous cystadenoma of the ovary. Based on immunohistochemical findings, the patient was diagnosed with PMP originating from LAMN (Fig. 3, Table 1). Postoperatively, the patient was managed by the surgery department. After informed consent regarding multidisciplinary treatment was obtained, the patient was referred to a specialized facility outside the prefecture, where CRS (resection of the remnant greater mesentery, spleen, lesser mesentery, gallbladder, cecum, inferior diaphragm peritoneum, hepatic peritoneum, abdominal wall peritoneum, etc.) +HIPEC (mitomycin C, 42°C, 1 hour) was performed. Her postoperative course was good and she was discharged 16 days postoperatively. She has been doing well in the 4 months since the multidisciplinary treatment.

Table 1 shows a summary of the four PMP cases. The tumor markers CA125 and CEA were ele-

vated in all cases, but CA199 was elevated only in case 1. In cases 2-4, intraoperative findings showed an enlarged or ruptured appendix, although this was apparent on preoperative imaging studies only in case 2. For all four cases, the PMP classification and the completeness of cytoreduction score (CC score) are shown in the table.

## Discussion

We report four cases of PMP experienced at our hospital. PMP is a disease in which a large amount of jelly-like mucus accumulates in the abdominal cavity (jelly belly) due to perforation of a mucinous tumor, usually in the appendix or ovary. In this condition, tumor cells leak into the abdominal cavity, seed, and grow in the peritoneum. Although distant metastasis is rare, the accumulation of mucinous ascites causes intestinal obstruction or dysfunction, therefore the disease often has a clinically malignant course even if it did not originate from a carcinoma<sup>1)</sup>. Moran *et al.* reported that PMP is rare, occurring in 1 in 1 million people<sup>2)</sup>. In Japan, a questionnaire survey conducted by the Ministry of Health, Labor and Welfare in 2011 and 2012 estimated its prevalence to be approximately 1.5 per 1 million people<sup>1)</sup>. Gastrointestinal tumors are the pri-

mary lesion in more than 90% of PMP cases, with mucinous tumors of the appendix being the most common origin<sup>4-6</sup>. When the mucus produced by a mucinous tumor accumulates and raises the intra-appendiceal pressure, the appendiceal wall perforates and ruptures relatively easily because of the “blind loop” appendiceal structure. This leads to peritoneal dissemination and metastasis, resulting in PMP<sup>5</sup>. Many cases of PMP with ovarian tumors are also due to disseminated metastases from appendiceal tumors<sup>4,7</sup>, and it is estimated that fewer than 10% of PMPs are associated with a primary ovarian tumor<sup>1</sup>.

Appendiceal tumors are rare, accounting for only about 0.5% of all gastrointestinal tumors<sup>8</sup>. Tumors are found incidentally in fewer than 1% of tissue specimens removed due to appendicitis<sup>9-11</sup>. Of these, mucinous tumor of the appendix (MTA) accounts for about 8%<sup>12</sup>. According to the WHO classification, MTA is classified as low or high grade according to the intensity of cellular atypia, and if the lesion extends beyond the appendix, even low-grade tumors are classified as malignant (invasive mucinous adenocarcinoma, low-grade)<sup>13</sup>.

Ronnett *et al.* classified PMPs into three types: low-grade or diffuse peritoneal adenomucinosis (DPAM), high-grade or peritoneal mucinous adenocarcinoma (PMCA), and intermediate or hybrid between DPAM and PMCA (PMCA-I)<sup>14</sup>. The prognosis of PMP varies widely by grade, with reported 5- and 10-year survival rates of 75% and 68% for DPAM, 50% and 21% for PMCA-I, and 14% and 3% for PMCA, respectively<sup>1,14,15</sup>.

Contrast-enhanced CT and MRI imaging are useful in confirming the nature of the tumor and ascites, and predicting the presence of distant metastases, peritoneal dissemination, and lymph node enlargement, as well as the staging of the ovarian tumor. In addition, findings of appendiceal mucocele or the findings of liver or spleen serosal surface compression due to myxoma seeding (scallop sign), although not seen in our cases, may also be useful as a preoperative diagnosis for PMP<sup>16-18</sup>.

In women with PMP, the coexistence of appendiceal and ovarian mucinous tumors has been found to occur in 1/3 to 2/3 of cases<sup>19,20</sup>, and Guo *et al.* reported that they coexisted in 20 (57%) of 35 PMP cases<sup>21</sup>. Immunohistochemically, CK7, CK20, and CDX2 can be useful markers in the search for primary and metastatic sites when mucinous tumors are present in both the appendix and ovary<sup>22</sup>. That is to say, the following two types of cases can be distinguished: cases with intestinal origin, CK7-/

CK20+/CDX2+, and cases with ovarian origin, CK7+/CK20-/CDX2-<sup>23</sup>.

In case 1 in this study, the removed appendix was pathologically confirmed to be completely free of neoplastic lesions, and the patient was diagnosed with PMP originating from ovarian mucinous tumor. In cases 2, 3, and 4, on the other hand, immunostaining results led to a diagnosis of PMP originating from appendiceal tumor with ovarian metastasis (Fig. 3, Table 1). In some cases, as in cases 2-4 in this study, the primary appendiceal lesion can have an almost normal shape due to perforation and is therefore difficult to identify on preoperative images. This makes the diagnosis of the primary lesion difficult, and immunohistological studies are therefore important.

As for primary ovarian PMP, there have been reports of PMP due to mucinous tumors arising from mature cystic teratoma (MCT), with Ronnett *et al.* describing three cases<sup>24</sup> and McKenney *et al.* reporting that 10 of 42 (24%) cases of ovarian mucinous tumors arose from MCT<sup>25</sup>. It has been speculated that such cases are more common than previously reported, that the original MCT component may be missed when the mucinous tumor is enlarged, and that most primary ovarian PMPs may be of MCT origin<sup>24</sup>. Ovarian mucinous tumors of MCT origin have morphologic and immunohistologic characteristics similar to those of appendiceal tumors, so their diagnosis requires caution<sup>26</sup>. PMP of ovarian origin has a better prognosis than that of appendiceal origin, and for PMP derived from ovarian MCT, there are no reported cases of recurrence even with surgical therapy alone<sup>27</sup>. PMP derived from borderline malignant ovarian tumors also has a good prognosis, so no evidence has been presented regarding the benefit of postoperative chemotherapy<sup>6,25,27</sup>.

The latest treatment for PMP is multidisciplinary therapy combining complete tumor resection by peritoneal resection with perioperative chemotherapy. In 1995, Sugarbaker *et al.* reported improved survival with aggressive CRS<sup>28</sup>, which involves resection of all grossly visible intra-abdominal tumors to the greatest extent possible, and if necessary, with resection of the greater mesentery, spleen, lesser mesentery, gallbladder, right hemicolon, sigmoid colon, rectum, small bowel, uterus, adnexa, upper abdominal peritoneum, and pelvic peritoneum<sup>28,29</sup>. HIPEC, in which anticancer agents are heated to 41-43°C and administered intraperitoneally for 90 minutes, is generally used for PMP perioperative chemotherapy, because systemic

chemotherapy is limited in its effectiveness due to restricted drug delivery to the peritoneal seeding site<sup>1,30,31</sup>. Recommended drugs include mitomycin C, cisplatin, docetaxel, gemcitabine, and irinotecan, which have relatively large molecular weights, and mitomycin C is most commonly used<sup>1,31,32</sup>. The size of the residual tumor after CRS is an important prognostic factor for the effectiveness of HIPEC treatment, and Sugarbaker *et al.* established the CC scoring system to classify this size into four categories (CC 0~3)<sup>30</sup>. HIPEC is expected to be effective in cases of complete cytoreduction (CC-0 and CC-1; residual tumor size <2.5 mm), but its effect is considerably limited when the residual tumor size is greater than 2.5 mm (CC-2 and CC-3)<sup>30,33</sup>.

Recently, the effectiveness of laparoscopic HIPEC has also been reported. In addition to being minimally invasive and easy to repeat as needed, the increased intraperitoneal pressure increases the drug delivery into the tumor<sup>34,35</sup>. In case 2 in the present study, the patient strongly desired minimally invasive surgery and chose a laparoscopic approach to remove the recurrent tumor. If the objective is to remove a single tumor and to perform intraperitoneal lavage, as in this case, minimally invasive laparoscopic surgery should be considered as an option, as it is easier to obtain the patient's consent.

The prognosis of PMP improved dramatically with the introduction of CRS+HIPEC in the 1990s. In 1994, Gough *et al.* reported that the 5- and 10-year survival rates of patients with PMP (including appendiceal and ovarian primary lesions) were only 53% and 32%, respectively<sup>36</sup>, but in 2019, Yonemura *et al.* reported 5- and 10-year survival rates of 76% and 61% respectively (appendiceal origin only)<sup>37</sup>. Other studies also reported that CRS+HIPEC resulted in good 8-, 10-, and 15-year survival rates of 68%, 63%, and 59%, respectively<sup>33,38</sup>. On the other hand, CRS+HIPEC is highly invasive and is associated with various adverse events (AEs) and complications that are often severe, including myelosuppression, sepsis, respiratory failure, thrombosis, intestinal perforation, fistula, abscess, and wound dehiscence<sup>39</sup>. Smeenk and Mohamed reported that treatment-related mortality was 0-11% and the incidence of grade III or higher AEs ranged from 12-68%<sup>40,41</sup>. As such, adequate informed consent is necessary before administering CRS+HIPEC.

Cases 2-4 in this study involved PMP originating from LAMN, DPAM, or PMCA-I according to the Ronnett classification, and CRS+HIPEC was indicated. The patient in case 3 opted not to undergo any treatment due to her advanced age, and the pa-

tient in case 2 wished to avoid highly invasive multidisciplinary treatment. The patient in case 4 was referred to a specialized center for CRS+HIPEC due to a desire for multidisciplinary treatment. Although CRS (yielding CC-1) and HIPEC took more than 11 hours and early postoperative chemotherapy was also performed, fortunately no adverse events occurred for her. The patient is expected to have a good prognosis.

## Conclusion

Since female PMP patients are often referred to gynecology clinics for ovarian tumor, even though PMP is a very rare and essentially surgical disease, it is very important for gynecologists to fully understand the pathogenesis of the syndrome. Although the number of facilities that can provide CRS+HIPEC for PMP is limited in Japan<sup>42</sup>, it is important to consider referring the patient to a specialized facility as soon as possible after diagnosis, in cases where treatment is indicated and desired by the patient.

## Conflict of interest

The authors have no conflicts of interest to declare.

## Patient consent

We obtained informed consent from the patients for the publication of this work.

## References

1. Yonemura Y. Treatment system for pseudomyxoma peritonei. MHLW Grants-in-Aid for Scientific Research (Research on Intractable Diseases) Summary Report : Research on the frequency and pathogenesis of pseudomyxoma peritonei in Japan and the development of treatment methods (H24 - Refractory, etc. (intractable) - designated - 007) 2012 Summary and sub-report. [http://pmp-jp.org/images/treat\\_system.pdf](http://pmp-jp.org/images/treat_system.pdf)
2. Moran B, Cecil T, Chandrakumaran K *et al.* The results of cytoreductive surgery and hyperthermic intraperitoneal chemotherapy in 1200 patients with peritoneal malignancy. *Colorectal Dis*, **17** : 772-778, 2015.
3. Kato A, Yazawa H, Mastuida H. Two cases of pseudomyxoma peritonei with ovarian tumors originating from mucinous tumors of ovary and appendix. *Fukushima Medical Journal*, **70** ; 7-18,



- 2022.
4. Acs G, Serous and mucinous borderline (low malignant potential) tumor of the ovary. *Am J Clin Pathol*, **123** : S13-S57, 2005.
  5. Smeenk RM, Van Velthuis MI, Verwaal VJ, *et al.* Appendiceal neoplasms and pseudomyxoma peritonei : a population based study. *Eur J Surg Oncol*, **34** : 196-201, 2008.
  6. McKenny JK, Soslow RA, Longacre TA. Ovarian mature teratoma with mucinous epithelial neoplasms : morphologic heterogeneity and association with pseudomyxoma peritonei, *Am J Surg Pathol*, **32** : 645-655, 2008.
  7. Ronnett BM, Kajdacsy-Balla A, Gilks CB *et al.* Mucinous borderline ovarian tumor : points of general agreement and criteria, and behavior. *Hum Pathol*, **35** : 949-960, 2004.
  8. Bendix F, Reimer A, Gastinger I, *et al.* Primary appendiceal carcinoma. Epidemiology, surgery and survival : results of a German multi center study, *Eur J Surg Oncol*, **36** : 763-77, 2010.
  9. Lai CW, Yue CT, Chen JH. Mucinous cystadenocarcinoma of the appendix mimics acute appendicitis, *Clin Gastroenterol Hepatol*, **11** : e11, 2013
  10. McGory M, Maggard M, Kang H, *et al.* Malignancies of the appendix : beyond case series reports, *Dis Colon Rectum*, **48** : 2264-2271, 2005.
  11. Shaib WL, Goodman M, Chen Z, *et al.* Incidence and survival of appendiceal mucinous neoplasm. A SEER analysis, *Am J Clin Oncol*, **40** : 569-573, 2015.
  12. Nuta OA, Quinto AAM, Municio AM, *et al.* Mucinous appendiceal neoplasms, diagnosis and surgical treatment. *Gir Esp*, **95** : 321-327, 2017.
  13. Misdaraji J, Yantiss R, Graeme-Cook F, *et al.* Appendiceal mucinous neoplasm : controversial issues. *Arch Pathol Lab Med*, **134** : 864-870, 2010.
  14. Ronnett BM, Zahn CM, Kurman RJ, *et al.* Disseminated peritoneal adenomucinosis and peritoneal mucinous carcinomatosis. A clinicopathologic analysis of 109 cases with emphasis on distinguishing pathologic features, site of origin, prognosis, and relationship to "pseudomyxoma peritonei". *Am J Surg Pathol*, **19** : 1390-1408, 1995.
  15. Ronnett BM, Yan H, Kurman RJ, *et al.* Patients with pseudomyxoma peritonei associated with disseminated peritoneal adenomucinosis have a significantly more favorable prognosis than patients with peritoneal mucinous carcinomatosis. *Cancer*, **92** : 85-91, 2001.
  16. Syed Ali Rizvi, Wajahat Syed, Ravi Shergill. Approach to pseudomyxoma peritonei. *World J Gastrointest Surg*, **27** ; 10 : 49-56, 2018.
  17. Chirihan Ayadi, Amine Naggar, Hajar Andour, *et al.* Appendiceal mucocoele with pseudomyxoma peritonei mimicking ovarian tumor with peritoneal carcinomatosis. *Radiol Case Rep*, **17** ; 3000-3004, 2022.
  18. Vahan Kependekian, Amanuel Kefleyesus, David Keskin, *et al.* *Cancers*, **14** ; 4434, 2022.
  19. Chuaqui RF, Zhuang Z, Emmert-Buck MR, *et al.* Genetic analysis of synchronous mucinous tumors of the ovary and the appendix. *Hum Pathol*, **27** : 165-171, 1996.
  20. Lee KR, Scully RE. Mucinous tumors of the ovary ; a clinicopathologic study of 196 borderline tumors ( of intestinal type) and carcinomas, including an evaluation of 11 cases with "pseudomyxoma peritonei". *Am J Surg Pathol*, **24** : 1447-1464, 2000.
  21. Guo AT, Song X, Wei LX, *et al.* Histological origin of pseudomyxoma peritonei in Chinese women ; Clinicopathology and immunohistochemistry. *World Gastroenterol*, **17** : 3531-3537, 2011.
  22. Zhou F, Chen X, Li Y, Huang L. Two independent primary mucinous tumors involving the appendix and ovary accompanied with acellular pseudomyxoma peritonei. *Int J Clin Exp Pathol*, **8** : 11831-11834, 2015.
  23. Baratti D, Kusamura S, Nonaka D, *et al.* Pseudomyxoma peritonei : Biological features are the dominant prognostic determinants after complete cytoreduction and hyperthermic intraperitoneal chemotherapy. *Ann Surg*, **249** : 243-249, 2009.
  24. Ronnett BM, Seidman JD. Mucinous tumor arising in ovarian mature cystic teratomas ; relationship to the clinical syndrome of pseudomyxoma peritonei. *Am J Surg Pathol*, **27** : 650-657, 2003.
  25. McKenny JK, Soslow RA, Longacre TA. Ovarian mature teratomas with mucinous epithelial neoplasms : morphologic heterogeneity and association with pseudomyxoma peritonei. *Am J Surg Pathol*, **32** : 645-655, 2008.
  26. Stewart CJR, Tukamoto T, Cooke B, *et al.* Ovarian mucinous tumor arising in mature cystic teratoma and associated with pseudomyxoma peritonei : report of two cases and comparison with ovarian involvement by low-grade appendiceal mucinous tumors, *Pathology*, **38** : 534-538, 2006.
  27. Saluja M, Kenwright DN, Keating JP. Pseudomyxoma peritonei arising from a mucinous borderline ovarian tumor : Case report and literature review. *Aust NZ J Obstet Gynaecol*, **50** : 399-403, 2010.
  28. Sugarbaker PH. Pseudomyxoma peritonei. A cancer whose biology is characterized by a redistribution phenomenon, *Am Surg*, **219** : 109-111, 1994.
  29. Rouzbohman M, Chetky R. Mucinous tumors of appendix and ovary : an overview and evaluation of current practice, *J Clin Pathol*. **67** : 193-197, 2014.
  30. Sugarbaker PH, Ryan DP. Cytoreductive surgery

- plus hyperthermic perioperative chemotherapy to treat peritoneal metastasis from colorectal cancer : standard of care or an experimental approach?, *Lancet Oncol*, **13** : e362-369, 2012.
31. Pablo CC, Esquivel J, Sugarbaker PH. Cytoreductive surgery and intraperitoneal chemotherapy for the treatment of peritoneal surface malignancy, *Clin Transl Oncol*, **5** : 192-198, 2003.
  32. Sugarbaker PH. Cytoreductive surgery and peri-operative intraperitoneal chemotherapy as a curative approach to pseudomyxoma peritonei syndrome, *Eur J Surg Oncol*, **27** : 239-243, 2001.
  33. Chua TC, Moran BJ, Sugarbaker PH, *et al.* Early- and long-term outcome data of patients with pseudomyxoma peritonei from appendiceal origin treated by a strategy of cytoreductive surgery and hyperthermic intraperitoneal chemotherapy, *J Clin Oncol*, **30** : 2449-2456, 2012.
  34. Passot G, Bakrin N, Issac S, *et al.* Postoperative outcome of laparoscopic vs open cytoreductive surgery plus hyperthermic intraperitoneal chemotherapy for treatment of peritoneal surface malignancies. *Eur J Surg Oncol*, **40** : 957-962, 2014.
  35. Arjona-Sanchez A, Ruflán-Pena S, Aanchez-Hidalgo JM, *et al.* Cytoreductive surgery and intraperitoneal hyperthermic chemotherapy (HIPC) by minimally invasive approach, an initial experience, *World J Surg*, **42** : 3120-3124, 2018.
  36. Gough DB, Donohue JH, Schutt AJ *et al.* Pseudomyxoma peritonei. Long-term patient survival with an aggressive regional approach, *Ann Surg*, **219** : 112-119, 1994.
  37. Yonemura Y, Canbey E, Wakama S, Sako S, Ishibashi H, Hiraon M, Motoi S, *et al.* Analysis of treatment failure after complete cytoreductive surgery for peritoneal metastasis from appendiceal mucinous neoplasm at a n Japanese high volume center for peritoneal surface malignancy. *Jpn Cancer Choemother*, **46**(2) ; 251-358, 2019.
  38. Papanton E, Ntatas K, Kyziridis D, Kalakonas A, Hristakis C, Tntes AA. Twenty-years' experience with cytoreductive surgery (CRS) and hyperthermic intraperitoneal chemotherapy (HIPEC) for pseudomyxoma peritonei (PMP). *JBUON*, **26** ; 1647-1652, 2021.
  39. Yan TD, Black D, Savady R, *et al.* A systematic review on the efficacy of cytoreductive surgery and perioperative intraperitoneal chemotherapy for pseudomyxoma peritonei. *Am Surg Oncol*, **14** : 484-492, 2007.
  40. Smeenk RM, Verwaal VJ, Zoetmulder FA, Toxicity and mortality of cytoreduction and intraoperative hyperthermic intraperitoneal chemotherapy in pseudomyxoma peritonei—a report of 103 procedures. *Eur J Surg Oncol*, **32** : 186-190, 2006.
  41. Mohamed F, Moran BJ, Morbidity and mortality with cytoreductive surgery and intraperitoneal chemotherapy : the importance of a learning curve. *Cancer J*, **15** : 196-199, 2009.
  42. Kitai T, Hirai T, Fujita T, *et al.* Survey on the incidence and management of pseudomyxoma peritonei in Japan. *Jpn J cancer Chemother*, **40** : 1043-1048, 2013.